




3 1761 05443119 2









MA  
B

# THE NERVOUS SYSTEM

## AND ITS CONSTITUENT NEURONES

*DESIGNED FOR*  
*THE USE OF PRACTITIONERS OF MEDICINE AND*  
*OF STUDENTS OF MEDICINE AND PSYCHOLOGY*

LEWELLYS F. <sup>Franklin</sup>BARKER, M.B., TOR.

ASSOCIATE PROFESSOR OF ANATOMY IN  
THE JOHNS HOPKINS UNIVERSITY  
AND ASSISTANT RESIDENT PATHOLOGIST TO  
THE JOHNS HOPKINS HOSPITAL

WITH TWO COLORED PLATES AND  
SIX HUNDRED AND SEVENTY-SIX  
ILLUSTRATIONS IN THE TEXT

NEW YORK  
D. APPLETON AND COMPANY  
1901

84443  
29/10/07

Copyright, 1899,  
By D. APPLETON AND COMPANY.

ELECTRONIC VERSION  
AVAILABLE

NO. 01001893

010-2498



TO  
WILLIAM OSLER, WILLIAM H. WELCH  
AND FRANKLIN P. MALL

SUCCESSIVELY MY TEACHERS IN BALTIMORE

AND TO MY FRIEND

JOHN HEWETSON

OF RIVERSIDE, CALIFORNIA

THIS VOLUME

IS GRATEFULLY AND RESPECTFULLY DEDICATED



Digitized by the Internet Archive  
in 2007 with funding from  
Microsoft Corporation

## PREFACE.

---

IN 1897 a series of articles was begun in the New York Medical Journal in which the attempt was made to present in as simple and concise a form as possible the main facts concerning the newer investigations into some phases of the anatomy and physiology of the nervous system. These articles were continued at intervals for two years, but the mass of material proved to be too great, and neurological publications increased so rapidly during this time that it soon became obvious that any adequate presentation of the subject must exceed the limits which could be allotted to it in a medical journal. The publication of a volume was accordingly decided upon, the introductory chapters of which consist of the articles (revised and brought up to date) which have appeared in the New York Medical Journal. The body of the book, however, dealing with the groups of neurones whose axones constitute the principal known tracts in the nervous system—centripetal, centrifugal, and associative—is now published for the first time.

In the first part of the volume the newer conceptions of the histology of the central and peripheral nervous organs are reviewed. In the succeeding chapters the attempt has been made to apply the neurone conception—that is, the cell doctrine—as consistently as possible, in the explanation and description of the complex architectonics of the nervous system. The term *neurone* is used throughout in the widest sense to mean *a cell belonging to the nervous system with all its parts*, not in the more restricted sense in which many authors employ it and to which objection has in many quarters quite properly been taken.

No apology is necessary for the rather profuse illustration of the volume, for all experience teaches that, in morphological studies especially, the form relations are more easily grasped from the examination of good pictures and models than in any

other way, and that one well-chosen illustration with a satisfactory legend is often of greater value to the student than many pages of laborious and exact description. Convinced of this fact, especial pains have been taken in the selection of the cuts. The bibliography has been extensively explored in order that the most instructive pictures of the various anatomical features extant in original articles might be drawn upon, and it is hoped that the bringing together in one volume of the results of recent investigators and skilled artists of many lands may be of service to neurological students, especially in English-speaking countries. For the original drawings and diagrams the author is deeply indebted to Mr. Max Broedel, Mr. H. Becker, and Mr. L. Schmidt. The two lithographic plates at the end of the volume are from Mr. Broedel's hand, as are also a large number of the original diagrams of conduction paths which illustrate different portions of Section VI. The series of drawings of transverse and horizontal sections through the medulla, pons, and midbrain have been prepared by Mr. L. Schmidt from exquisite serial sections kindly placed at the writer's disposal by his friend Dr. John Hewetson. The other original drawings are from preparations made in the anatomical laboratory of the Johns Hopkins University.

Of the illustrations borrowed from original articles, a few have been taken, by kind permission, from American and English publications. The majority are, however, derived from foreign sources—French, German, Italian, Russian, Dutch, Spanish, and Swedish. In every case credit has been given to the author of the original article containing the illustration, and in a majority of instances the title of and exact reference to the monograph or journal whence the figure has been derived have been appended.

Especial thanks are due to the publishers, Messrs. D. Appleton and Company, for their liberality in defraying the expense of the illustrations, especially of those in which several colors had to be employed, and for the faithful reproduction of the originals by the most modern methods.

The nomenclature employed throughout the book is almost exclusively that of the BNA. A few exceptions have been made—notably the use of the terms *dorsal* and *ventral* instead of *posterior* and *anterior* respectively, an obviously necessary deviation, and one which has been urged for a long time by



prominent American anatomists. Every effort has been made to maintain a uniform nomenclature throughout, and where descriptions or illustrations have been borrowed from other books or original articles, the author, for the sake of uniformity, has taken the liberty of translating the terms originally employed into those of the new nomenclature. A feature of the book, which has been responsible for the delay in publication and for greatly increased cost to the publishers, is the printing at the side of many of the cuts of the actual names of the objects illustrated, instead of reference letters and figures to be explained in legends. The advantage to the reader is obvious, and the author regrets that the method, despite the time and cost involved, has not been still more widely employed in the making of this book.

The sources of knowledge examined are sufficiently indicated in the numerous footnotes. There has been no attempt, however, to exhaust the bibliography, and only the more important references consulted have been cited. The student, and especially the beginner, will doubtless be helped more by a few references to masters and to recognized authors and special workers than by a full bibliography of the various topics taken up. Care has been taken to verify the various references at the different libraries in Baltimore, and especially at the surgeon-general's library in Washington. The writer has been so frequently delayed by errors in bibliographic references in neurological text-books and in medical journals that he will be particularly obliged to any reader who, detecting such errors in the present volume, will inform him of them, that they may be corrected.

It is an especial pleasure to acknowledge the help and stimulus in neurological work which the writer has received from various sources. The lectures of Professors Flechsig, von Frey, His, and Wundt in Leipsic in 1895; the admirable text-books of E. A. Schaefer, Foster and Sherrington, C. L. Dana, C. K. Mills, J. Dejerine, W. R. Gowers, S. Ramón y Cajal, W. von Bechterew, P. Marie, H. Obersteiner, A. van Gehuchten, A. von Kölliker, C. Wernicke, L. Edinger, and C. von Monakow; the various publications of Apáthy, Bastian, Beever, Bethe, Bolk, Berkley, Broadbent, Dogiel, H. H. Donaldson, Ewing, Flatau, Ferrier and Turner, Flechsig, von Frey, Goldscheider, Golgi, Held, Heuschen, Herrick, van Gieson, Hughlings Jackson,

Horsley and Schaefer, J. Loeb, Lugaro, Adolph Meyer, Mellus, Marinesco, Nissl, F. W. Mott, Patrick, Retzius, J. S. Risien Russell, Sano, Sherrington, Starr, Ramón y Cajal, Tartuferi, Tschermak, Warrington, and others, have been especially helpful. The author is particularly indebted to Dr. Franklin P. Mall, Professor of Anatomy in the Johns Hopkins University, for aid and encouragement in manifold ways in connection with the preparation of the text and illustrations. Thanks are also due to Drs. Flexner, Thomas, Berkley, Paton, Harrison, and Bardeen, and to various students in the Johns Hopkins Medical School, especially to those who have undertaken original research. Dr. Frank R. Smith has been kind enough to thoroughly revise the text, and also to read the final proofs. Miss Eleanore H. Watts has prepared the careful index of authors, and has been most helpful in the preparation of the manuscript and the legends for the figures. It is hoped that by the use of two varieties of type (one referring to the pages, the other to the numbers of the figures), the value of the indices will be increased.

THE JOHNS HOPKINS HOSPITAL,  
BALTIMORE, MD., *March 18, 1899.*

# CONTENTS.

## SECTION I.

	PAGE
THE HISTORY OF THE DEVELOPMENT OF THE NEURONE CONCEPT . . . . .	1
CHAP. I. INTRODUCTORY.	
II. THE STUDIES OF HIS, GOLGI, AND FOREL . . . . .	9
III. THE STUDIES OF RAMÓN Y CAJAL AND OTHERS WITH GOLGI'S METHOD . . . . .	20
IV. THE VITAL STAINING OF THE NERVE ELEMENTS . . . . .	31
V. THE TERM "NEURONE" AND THE NEURONE CONCEPTION . . . . .	39
VI. THE BEARING OF RESEARCHES SINCE 1891 UPON THE VALID- ITY OF THE NEURONE DOCTRINE. . . . .	43

## SECTION II.

THE EXTERNAL MORPHOLOGY OF NEURONES . . . . .	66
VII. THE EXTERNAL FORM OF THE CELL BODY AND OF THE DENDRITES . . . . .	66
VIII. THE EXTERNAL FORM OF THE AXIS-CYLINDER PROCESSES OR AXONES . . . . .	78
IX. COLLATERALS, SIDE FIBRILS, AND INTERNEURONAL SUB- STANCES . . . . .	90

## SECTION III.

THE INTERNAL MORPHOLOGY OF NEURONES . . . . .	101
X. STUDIES BY METHODS WHICH REVEAL THE INTERIOR OF NEURONES . . . . .	101
XI. VARIETIES OF NERVE CELLS DISTINGUISHABLE BY NISSL'S METHOD . . . . .	115
XII. THE NATURE OF THE TIGROID MASSES OR "STAINABLE SUB- STANCE" OF NISSL . . . . .	127
XIII. THE GROUND SUBSTANCE OR "UNSTAINABLE SUBSTANCE" OF NISSL . . . . .	135
XIV. SUMMARY OF OUR KNOWLEDGE REGARDING THE INTERNAL STRUCTURE OF NEURONES . . . . .	154

FIGURE	PAGE
24. Large pluripolar ganglion cell of the ventral paramedian field of the abdominal cord of <i>Lumbricus</i> . . . . .	54
25. The plexus of neuro-fibrils in some retinal cells of the third right eye of the leech . . . . .	55
26. A subepidermal sense cell, retinal cell from <i>Pseudo-branchellion</i> . . . . .	55
27. The distribution of the neuro-fibrils in the circular muscle fibre of the intestinal wall of <i>Pontobdella</i> . . . . .	56
28. Colossal ganglion cell (Type G) from the leech . . . . .	57
29. Three pear-shaped ganglion cells of Type K, in longitudinal section, from the leech . . . . .	59
30. The course and connections of the conducting paths in a transverse section of the somite of the leech . . . . .	61
31. Spinal ganglion of a newborn white mouse . . . . .	68
32. Motor cell of ventral horn of spinal cord from the human fœtus, thirty centimetres long . . . . .	69
33. Pyramidal cell of cerebral cortex of mouse . . . . .	70
34. Multipolar nerve cell from the cord of the embryo calf showing varicosities of the dendrites . . . . .	71
35. Neurones from the hippocampus of a puppy two days old . . . . .	73
36. Unipolar cell from a ganglion of <i>Lumbricus</i> . . . . .	74
37. Photomicrograph of a normal pyramidal cell from the cerebral cortex of a guinea-pig . . . . .	74
38. Photomicrograph of a normal Parkinje cell from the human cerebellar cortex . . . . .	75
39. Photomicrograph of the apical dendrite of a large pyramidal cell of the cerebral cortex showing the arrangement of the lateral buds or gemmules . . . . .	76
40. Neurone from the optic lobe of the embryo chick . . . . .	79
41. Golgi cell of Type II from the dorsal horn of the gray matter of the spinal cord of the newborn mouse . . . . .	80
42. Special cells (polyaxones) of molecular layer of cerebral cortex of a dog one day old . . . . .	81
43. Ramón y Cajal's cell from the superficial layer of the cerebral cortex of a fœtal cat . . . . .	81
44. Nerve elements from the retina of the ox . . . . .	82
45. Anaxone from the basket of a Purkinje cell of the cerebellar cortex . . . . .	82
46. Y-shaped division of sensory root fibres after entrance into spinal cord in a six-months human embryo . . . . .	83
47. End ramifications forming a basketwork about two Purkinje cells of the cerebellar cortex . . . . .	83
48. The relations in the olfactory glomeruli of the axones of the olfactory neurones of the first order to the dendrites of the mitral cells in birds . . . . .	84
49. Nucleus of termination of the sensory part of the nervus trigeminus of the cat . . . . .	84
50. A much-branched fibre from the optic thalamus of a mouse . . . . .	85



# LIST OF ILLUSTRATIONS.

xiii

FIGURE	PAGE
51. Three end arborizations of optic fibres from the optic lobe of an embryo chick . . . . .	86
52. The so-called "climbing fibres" of the cerebellar cortex from the brain of a child a month and a half old . . . . .	87
53. Disc-shaped expansions on nerve fibrillæ of the pig's snout and their relation to certain of the epithelial cells . . . . .	87
54. Developing myelin sheaths of different ages as seen through the polarization microscope . . . . .	88
55. Scheme showing the elements of the gray matter of the spinal cord . . . . .	91
56. Endings of collaterals from the dorsal funiculi in the gray matter of the spinal cord of the newborn rabbit . . . . .	92
57. Side fibril of Golgi on the axone of a motor cell of the ventral horn of the spinal cord . . . . .	93
58. Pericellular networks believed by Held to be formed by the terminals of axones . . . . .	95
59. Reproduction of a photogram of a perpendicular section through the tip of the head of the gyrus centralis anterior of a healthy adult man close to the falx . . . . .	97
60. Reproduction of a photogram from a perpendicular cortical section through the summit of the gyrus just in front of the sulcus cruciatus of an adult dog close to the falx . . . . .	98
61. Reproduction of a photogram of a perpendicular section through the cerebral cortex of a mole, 1 mm. in front of the crucial suture close to the falx . . . . .	99
62. Ganglion cell from the electric lobe of the brain of the torpedo . . . . .	103
63. Nerve cell from the region of the ventral column of gray matter of the spinal cord of <i>Gadus</i> . . . . .	105
64. Large motor ganglion cell from the ventral horn of spinal cord of ox . . . . .	109
65. Spinal ganglion cell from the ox showing clear spaces ( <i>Vacuolen</i> ) . . . . .	112
66. Spinal ganglion cell of <i>Rana Catesbiana</i> . . . . .	113
67. Nerve cell from olfactory bulb of rabbit . . . . .	116
68. Nerve cell from dorsal nucleus of proximal portion of medulla of rabbit . . . . .	117
69. Motor nerve cell from ventral horn of gray matter of spinal cord of rabbit . . . . .	118
70. Large cell from Ammon's horn of rabbit . . . . .	119
71. Nerve cell from ganglion on dorsal root of a cervical nerve of a rabbit . . . . .	119
72. Purkinje cell from the cerebellar cortex of the rabbit . . . . .	120
73. Nerve cell from the spinal cord of the dog in the so-called "chromophile" condition . . . . .	124
74. Motor nerve cell from the ventral horn of the gray matter of the spinal cord of the dog showing tigroid bodies . . . . .	125
75. Cell of ventral horn of gray matter of human spinal cord . . . . .	130
76. Nerve cell from Deiters' nucleus in the rabbit . . . . .	131

FIGURE	PAGE
77. Nerve cell from the gray matter of the lumbar cord of ox . . .	132
78. The endocellular network within a Purkinje cell of the cerebellum of <i>Strix flammea</i> . . . . .	140
79. Cross sections of two axones from the nervus trigeminus of <i>Petromyzon fluviatilis</i> . . . . .	142
80. Longitudinal and transverse section of medullated nerve fibres from the sciatic nerve of the frog showing one node of Ran- vier and two of Lantermann's segmentations . . . . .	143
81. Axis cylinder in long and cross section from a spinal ganglion in the lumbar region of an adult dog, showing neurosomes and axospongium . . . . .	144
82. Axone hillock of a spinal ganglion cell of the dog . . . . .	144
83. Cell from the ventral horn of the lumbar cord of an adult rabbit showing the axone and several dendrites . . . . .	146
84. Centrosome and attraction sphere inside a spinal ganglion cell of the frog . . . . .	148
85. Nerve cell showing reticular investment . . . . .	150
86. Pericellular networks believed by Held to be formed by the ter- minals of axones . . . . .	151
87. Networks about perikaryon and dendrites demonstrable by the method of Bethe . . . . .	152
88. Anterior portion of the body of a chick, the head distinctly differ- entiated; seen from the surface . . . . .	159
89. Median section through embryo human brain at the end of the first month . . . . .	160
90. Model of developing human brain . . . . .	161
91. Median section of foetal human brain during the third month . . . . .	162
92. Median section through adult human brain . . . . .	162
93. Section through medullary plate of rabbit showing germinal cell . . . . .	165
94. Section through neural tube which is beginning to close . . . . .	165
95. Section through wall of neural tube at a later stage . . . . .	166
96. Photomicrograph from a specimen through the neural tube of <i>Amblystoma</i> . . . . .	168
97. Section of spinal cord of a chick at the third day of incubation . . . . .	169
98. Section through half of neural tube showing the pear-shaped neuroblasts . . . . .	171
99. Transverse section of the spinal cord of a chick . . . . .	172
100. Transverse section through the upper thoracic cord of the human embryo . . . . .	173
101. Commissural cell or heteromeric neurone from the spinal cord of a <i>Pristiurus</i> embryo 30 mm. long . . . . .	174
102, 103. Transverse section through the medulla of the human em- bryo showing N. hypoglossus, N. vagus, and tractus soli- tarius . . . . .	174, 175
104. Section through a portion of the wall of the medulla of a human embryo showing neuroblasts wandering from the rhomboidal lip toward the middle line . . . . .	176

# LIST OF ILLUSTRATIONS.

XV

FIGURE	PAGE
105. Scheme of one half of the embryonic medulla at a later stage . . . . .	176
106. Transverse section through one half of the medulla oblongata of a human embryo at the eighth month . . . . .	177
107. Longitudinal section of the cerebral hemispheres of <i>Necturus</i> . . . . .	178
108. Reconstruction of human embryo at end of fourth week showing development of sensory ganglia . . . . .	180
109. Three stages of development in the early history of the spinal ganglia of the human embryo . . . . .	181
110. Transverse section of the embryonic cord of the chick . . . . .	182
111. Bipolar cell from the spinal ganglion of the pike . . . . .	182
112. Bipolar ganglion cell from the ganglion spirale of the pig . . . . .	182
113. Schematic representation of the gradual transition of the bipolar cells of the spinal ganglia to the so-called unipolar type . . . . .	183
114. Transformation of bipolar cells into unipolar cells in the Gasserian ganglion of the pig . . . . .	183
115. Feltwork about spinal ganglion cells of the cat formed by division of the axones of spinal ganglion cells of Type II . . . . .	184
116. Scheme of the reciprocal relations of the elements within the spinal ganglion, according to Dogiel . . . . .	185
117. Left auditory vesicle with the acustico-facial complex of a human embryo at the fifth week . . . . .	186
118. Ophthalmic vesicle showing stalk and groove in stalk from a human embryo of the fourth week, seen from below . . . . .	187
119. Developing eye of human embryo 10.2 mm. long . . . . .	187
120. Composite diagrammatic transverse section of the head of a human embryo to show the growing point in the nervous system, and the direction of the growth of the fibre . . . . .	188
121. Transverse section through the anterior part of the trunk of an embryo of <i>Scyllium</i> . . . . .	189
122. Photomicrograph of section through a nerve in the side of a human tongue . . . . .	190
123. Schematic representation of the nerve plexus of a heart of a human embryo after His Jr. . . . .	191
124. Diagram showing successive positions of the diaphragm during the development of the human embryo . . . . .	194
125. Schemes of transverse sections of younger and older Selaehian embryos to illustrate the development of the chief products of the middle terminal layer . . . . .	196
126. Human embryo fourteen to sixteen days old showing developing myotome . . . . .	197
127. Human embryo at the end of the third week showing developing myotome and sclerotome . . . . .	198
128. Scheme of bone and muscle segment . . . . .	199
129. Trunk segment of human embryo with one pair of nerves and the rudiment of the musculature of one extremity at the sixth week . . . . .	200
130. Reconstruction of a young human embryo enlarged five times,	

FIGURE	PAGE
illustrating the position of the <i>M. rectus abdominis</i> and its polymeric nature . . . . .	202
131. Fields on the external surface of the <i>os innominatum</i> corresponding to the attachment of the various muscles . . . . .	203
132. Outer surface of <i>os innominatum</i> showing attachments of the muscle masses derived from the myotomes innervated by the twelfth to the nineteenth thoraco-lumbo-sacral nerves . . . . .	204
133. Reconstructed form of pelvis of human <i>fœtus</i> , illustrating skeletal areas corresponding to the myotomes innervated by the 12th to the nineteenth thoraco-lumbo-sacral nerves . . . . .	205
134. Arrangement of the metazonal dorsal nerves for the <i>Mm. glutæi</i> . . . . .	207
135. Arrangement of the metazonal ventral nerves for the <i>Mm. flexores</i> . . . . .	207
136. Arrangement of the prozonal dorsal <i>N. femoralis</i> . . . . .	208
137. Arrangement of the diazonal ventral <i>N. obturatorius</i> . . . . .	209
138. Arrangement of the ventral and dorsal prozonal, diazonal, and metazonal nerves . . . . .	210
139. Six transverse sections through a right upper arm showing the relation of the (dark) ventroplanum to the (colorless) dorso-planum, as well as the position of the fourth to the sixth cervical sclerozones . . . . .	211
140. Transverse section through the musculature of the shoulder and chest showing the limits between ventral and dorsal derivatives of the myomeres . . . . .	212
141. Transverse section through the proximal portion of the humerus . . . . .	213
142. Transverse section through the distal part of the humerus . . . . .	213
143. Wallerian degeneration of nerve fibres after section . . . . .	224
144. Section through the cervical cord of a woman showing secondary degenerations following compression of the cord at the level of the second thoracic segment . . . . .	226
145. Section through the lumbar cord of a woman showing secondary degenerations following compression of the cord at the level of the second thoracic segment . . . . .	227
146. Section through human spinal cord in the upper thoracic region showing marked atrophy of right half of cord following amputation of right arm . . . . .	230
147. Transverse section through the medulla oblongata of a rabbit showing degeneration from injury to facial nerve on the right side . . . . .	232
148. Cross section through the medulla oblongata of a rabbit showing degeneration from injury to facial nerve on left side . . . . .	233
149. Cells from the nuclei of the oculomotor nerves of the cat thirteen days after section of the root fibres of the nerve on one side . . . . .	235
150. Four nerve cells from the nucleus nervi facialis of a rabbit fifteen days after section of the nerve root . . . . .	236
151. Ventral horn cells from the spinal cord of a case of multiple neuritis . . . . .	237



# LIST OF ILLUSTRATIONS.

xvii

FIGURE	PAGE
152. Nerve cell from cerebral cortex of dog showing alterations chiefly in the dendrites turned toward a thrombosed vessel . . .	238
153. Larger pyramidal cells from the second layer of the cerebral cortex showing advanced stages of degeneration following ricin poisoning of fourteen hours' duration . . .	239
154. Strong apical dendrites of pyramidal cells from the human cerebral cortex . . .	240
155. Frontal section through the mesencephalon showing vascular supply . . .	242
156. Caryocinetic figures in nerve cells in brain of dog three days after introduction of foreign body . . .	247
157. Scheme of the olfactory apparatus of mammals . . .	262
158. Section through the optic lobe of the embryo chick . . .	263
159, 160. Spinal cord of <i>Amphioxus</i> . . .	268, 269
161. Portion of spinal cord of new-born rabbit stained by the chrome-silver method . . .	271
162. Schematic drawing to illustrate the course of the primitive fibrils of the receptive and motor elements of the second antenna of <i>Carcinus Maenas</i> . . .	272
163. Section through ganglion on dorsal root of first thoracic nerve of cat . . .	276
164. Section through ganglion on dorsal root of first thoracic nerve of cat after intermittent electrical stimulation during five hours . . .	277
165. Camera-lucida drawing of occipital cortex of pigeon to show rested nerve cells . . .	278
166. Camera-lucida drawing of cortex of pigeon to show changes in cells indicating normal daily fatigue . . .	278
167. Sections through the superior cervical ganglion of the rabbit stained by Nissl's method . . .	279
168. Two motor cells from lumbar region of spinal cord of dog fixed in sublimate and stained in toluidin blue . . .	280
169. Effects of arsenic upon the nerve cell . . .	283
170. The effects of phosphorus poisoning upon the neurones . . .	284
171. The effects of veratrin poisoning upon the neurones . . .	285
172. Two spinal ganglion cells showing peripheral chromatolysis in arsenical poisoning . . .	286
173. A nerve cell from a part of the spinal cord deprived of blood for six hours through ligature of the abdominal aorta . . .	288
174. Cells from the nuclei of the oculomotor nerves of the cat thirteen days after section of the root fibres of the nerve on one side . . .	294
175. Cells from the human spinal cord in epidemic cerebro-spinal meningitis . . .	296
176. Four nerve cells from the nucleus nervi facialis of a rabbit fifteen days after section of the nerve root . . .	297
177. Similarity of changes produced in cell bodies of lower motor neurones (1) by cutting the axone and (2) by cutting the corresponding dorsal roots . . .	298

FIGURE	PAGE
178. Effects of poisoning with malon-nitril . . . . .	300
179. Effects of artificial increase of body temperature . . . . .	301
180. Recovery of ventral horn cell from changes produced by artificial increase of body temperature . . . . .	303
181. Effects of tetanus toxine upon the lower motor neurones . . . . .	304
182. More advanced stages of poisoning with tetanus toxine . . . . .	305
183. Spinal ganglion cell showing marked alterations following section of the sciatic nerve . . . . .	310
184. Spinal ganglion cell forty days after section of corresponding dorsal root . . . . .	311
185. Cross section of the central and peripheral nervous system of a man, illustrating the neural segment . . . . .	323
186. Plexus cervico-brachialis . . . . .	324
187. Plexus lumbosacralis . . . . .	326
188. The areas supplied by the cutaneous nerves of the head . . . . .	327
189. Areas supplied by the cutaneous nerves of the upper extremity . . . . .	328
190. The areas of the skin supplied by the cutaneous nerves of the lower extremity . . . . .	329
191. Diagram of the position of the nipple in the sensory skin fields of the fourth, third, and fifth thoracic spinal roots . . . . .	331
192. Cutaneous fields of dorsal roots of spinal nerves of monkey. Dor- sal view . . . . .	334
193. Cutaneous fields of dorsal roots of spinal nerves of monkey. Ven- tro-lateral view . . . . .	335
194. Mode of distribution of the dorsal root fibres of the lower cervical and thoracic nerves . . . . .	336
195. Mode of distribution of the dorsal root fibres of the lower cervical nerves and of the thoracic nerves . . . . .	337
196. Mode of distribution of the dorsal root fibres of the lumbar and sacral nerves . . . . .	340
197, 198. Referred pain in visceral disturbances . . . . .	342, 343
199, 200. Areas of pain sensation in visceral disease . . . . .	344, 345
201. Types of anæsthesia . . . . .	346
202, 203. Regiones corporis humani . . . . .	347, 348
204. Spinal cord in connection above with the medulla oblongata and pons . . . . .	351
205. Portions of the pars cervicalis of the spinal cord with nerve roots . . . . .	351
206. Scheme of peripheral spinal sensory neurones . . . . .	352
207. Sagittal section through seven spinal ganglia of embryo mouse 10 mm. long. Cervical region . . . . .	355
208. Peripheral centripetal neurones of various animals . . . . .	357
209. Large spinal ganglion cell from a healthy man with connective- tissue capsule . . . . .	358
210. Several types of spinal ganglion cells . . . . .	359
211. Nerve fibrils in the epithelial lining of the œsophagus . . . . .	362
212. Nerve fibrils in the epithelium of a vertical section of the rabbit's bladder . . . . .	363

## LIST OF ILLUSTRATIONS.

xix

FIGURE	PAGE
213. Termination in the form of trefoil end platelets on the ciliated cells of the frog's palate . . . . .	363
214. Vertical section through the cornea . . . . .	364
215. Transverse section through the skin of the ear of a white mouse three days old . . . . .	364
216, 217. Nerves and nerve endings in the human cornea . . . . .	366, 367
218. Medullated nerve fibre from the conjunctiva of man . . . . .	368
219. Nerve endings in epithelium of frog's palate . . . . .	369
220. A perpendicular section of the lower part of the epidermis between two papillæ which shows a large group of Merkel's <i>Tastzellen</i> . . . . .	369
221. A perpendicular section through the lower part of the epidermis between two papillæ, from a fœtus 30 cm. long, to show the development of the nerve endings about Merkel's <i>Tastzellen</i> . . . . .	369
222. Grandry's terminal nerve corpuscles from the duck's bill . . . . .	370
223. Flat preparation from the mucous membrane of the palate of a duck showing nerve fibres and nerve endings . . . . .	371
224. Tactile discs from two Grandry's corpuscles in connection with the axis cylinders of the nerve fibrils connected with them . . . . .	372
225. Nerve endings about a large hair from the dog . . . . .	372
226. Erectile body of a hair of the rat . . . . .	373
227. Nerves and nerve endings in the skin and hair follicles . . . . .	375
228. Nerve endings in the form of tactile discs beneath the glassy membrane of the hairs . . . . .	376
229. Longitudinal view of tooth of <i>Gobius</i> showing nerve terminals . . . . .	376
230. Nerve endings in the liver . . . . .	377
231. Periacinous plexus of nerve fibrils in the pancreas . . . . .	378
232. Nerve cells and nerve fibres in the villi and among the glands of the intestinum tenue of the guinea-pig . . . . .	379
233. Nerve endings in the salivary glands . . . . .	380
234. Section through the caput epididymidis of a young tomtat . . . . .	380
235. Nerve terminals in transverse section of the tubuli seminiferi of the rabbit . . . . .	380
236. Nerve endings in the mammary gland . . . . .	381
237. Two corpuscles containing nerve endings from the external connective-tissue sheath of the dog's prostate . . . . .	382
238. Free nerve endings in the basal membrane at the junction of the epidermis with the subcutaneous tissue . . . . .	383
239. Tactile corpuscle of Meissner from a section through the skin of the human toe . . . . .	384
240. Section through the skin of the toe . . . . .	385
241. Meissner's corpuscle . . . . .	385
242. Tactile corpuscle from the skin of the volar surface of the index finger of a man twenty-five years old . . . . .	386
243. Peripheral part of conjunctiva palpebrarum of man . . . . .	387
244. Terminal nerve corpuscles in the eyelids of man . . . . .	387
245. Semi-schematic section of the skin of the pulp of the fingers in	

FIGURE	PAGE
order to demonstrate the topography of Ruffini's "terminal nervous organs" . . . . .	388
246. Ruffini's nerve endings . . . . .	389
247. Terminal nerve corpuscle of Ruffini . . . . .	390
248. Transverse section of Ruffini's terminal corpuscle . . . . .	391
249. Oblique section of a terminal nerve corpuscle of Ruffini . . . . .	391
250. A nerve fibre dividing into seven secondary fibres to which are attached five <i>organes nerveux terminaux</i> of Ruffini . . . . .	392
251. End bulbs stained by the methylene-blue method . . . . .	393
252. Terminal corpuscle from the edge of the conjunctiva bulbi . . . . .	393
253. Herbst's corpuscles . . . . .	394
254. Corpuscle of Pacini of the mesentery of an adult cat . . . . .	395
255. Golgi-Mazzoni corpuscles . . . . .	397
256. Genital nerve corpuscles from the mucous membrane of the clitoris of the rabbit . . . . .	398
257. Genital nerve corpuscles from the mucous membrane of the glans penis of the rabbit . . . . .	399
258. Cross section of genital nerve corpuscle from the clitoris of the rabbit . . . . .	399
259, 260. Genital nerve corpuscles from human glans penis . . . . .	400, 401
261. End bulb from glans penis of a white mouse . . . . .	402
262. A branch of one of the anterior nerve fibres of the cornea . . . . .	403
263. Musculo-tendinous nerve ending of Golgi . . . . .	404
264. Tendinous expansion of one of the muscles of man . . . . .	406
265. A terminal musculo-tendinous organ in which a terminal nerve plaque occupies nearly the length of the tendon . . . . .	407
266. Human tendo calcaneus (Achillis) . . . . .	408
267. Tendinous expansion of one of the motor muscles of the eye of an ox . . . . .	409
268. A sensory nerve ending from exocardium of upper half of left atrium of the heart of the gray rat . . . . .	410
269. Nerve endings in the lung of the frog . . . . .	411
270. Sensory nerve endings in the ciliary body of birds . . . . .	412
271. Nerve endings in ciliary body demonstrated by the method of Golgi . . . . .	413
272. Muscular spindle from <i>Myoxus avellanarius</i> . . . . .	414
273. Middle third of a terminal plaque in the muscle spindle of an adult cat . . . . .	416
274. A striped muscle fibre in a human muscle spindle with <i>terminaisons à fleurs</i> . . . . .	417
275. Muscle spindle from intrinsic plantar muscles of a dog . . . . .	418
276. Surface view of cardiac muscle cells with nerve endings . . . . .	419
277. Intermuscular end arborization from the left wall of the trachea of the dog . . . . .	420
278. Longitudinal section of involuntary muscle showing nerve endings . . . . .	420
279. Nerve ending on the vas afferens in the cortex of the kidney . . . . .	421



# LIST OF ILLUSTRATIONS.

xxi

FIGURE	PAGE
280. Figures illustrating the dorsal funiculi in the cervical, thoracic, and lumbar regions of the spinal cord . . . . .	426
281. Upper half of lumbar enlargement of a foetus 35 cm. long . . . . .	428
282. Cross section through the spinal cord at the level of the third lumbar nerve . . . . .	429
283-290. The fibre systems in the spinal cord of the foetus . . . . .	431-434
291. The nerve tracts in a case of lumbar tabes (Trepinski) . . . . .	436
292. Secondary degenerations in the spinal cord after experimental section of dorsal roots . . . . .	440
293. Transverse section of the human spinal cord showing secondary degenerations following isolated lesion of the sixth thoracic spinal nerve . . . . .	445
294. Scheme of the course and termination of the fibres of the dorsal roots . . . . .	448
295. Secondary degeneration in the dorsal funiculi below a transverse lesion due to compression of the cord . . . . .	449
296. Longitudinal section in an almost sagittal direction at the level of the eighth thoracic nerve showing degenerated fibres in the dorsal funiculi after transverse lesion . . . . .	451
297. Descending degeneration below a transverse lesion at the level of the seventh thoracic segment . . . . .	454
298. Descending degenerations below a lesion (compression) of the spinal cord at the level of the eighth cervical nerve . . . . .	455
299. Sagittal longitudinal section at the level of the fifth sacral nerve from a case of compression of the cord at the level of C. viii. . . . .	456
300. Cross section through the spinal cord of a rabbit eleven days after compression of the aorta for one hour . . . . .	460
301. Transverse section through the medulla oblongata in the region of the decussatio lemniscorum . . . . .	462
302. Cross section through the medulla oblongata at the level of the lower half of the nucleus olivaris inferior . . . . .	462
303. Entrance of the fibres of the dorsal roots into the dorsal funiculus of the spinal cord of an embryo calf . . . . .	467
304. Scheme indicating the course followed by the central axones of the peripheral spinal centripetal neurones in the dorsal funiculi of the spinal cord . . . . .	469
305. Cross section through the spinal cord of a newborn babe, to show the collaterals . . . . .	471
306. Scheme of the structure of the spinal cord . . . . .	472
307. The developing cerebral nerves . . . . .	478
308. Transverse section through medulla oblongata of newborn child at level of decussatio lemniscorum . . . . .	479
309. Transverse section of medulla oblongata of newborn child passing through the nucleus olivaris inferior . . . . .	479
310. Transverse section of the medulla oblongata and cerebellum of new-born child showing nucleus dentatus . . . . .	480

FIGURE	PAGE
311. Transverse section through the medulla oblongata and cerebellum of newborn child; region of cochlear nuclei . . . . .	481
312. Transverse section through the cerebellum and medulla oblongata at the junction of the latter with the pons . . . . .	482
313. Transverse section through the pons and cerebellum at the level of the principal motor nucleus of the trigeminal nerve . . . . .	483
314. Transverse section through the isthmus rhombencephali of newborn babe . . . . .	484
315. Transverse section at the level of the colliculus inferior of corpora quadrigemina of newborn babe . . . . .	485
316. Transverse section through mesencephalon of newborn babe; level of superior colliculus. . . . .	486
317. Transverse section through superior colliculi and cerebral peduncle of newborn babe . . . . .	487
318, 319. Horizontal section through medulla, pons, and midbrain of newborn babe; level of nucleus nervi abducentis . . . . .	488, 489
320. Horizontal section through rhombencephalon and mesencephalon of newborn babe; level of fasciculus longitudinalis medialis . . . . .	490
321. Horizontal section through medulla, pons, and midbrain of newborn babe; level of the nucleus nervi oculomotorii and nucleus nervi trochlearis . . . . .	491
322. Horizontal section through the medulla, pons, and midbrain of newborn babe; level of decussatio brachii conjunctivi . . . . .	492
323. Horizontal section through medulla, pons, and midbrain of newborn babe; level of corpus trapezoidum . . . . .	493
324. Horizontal section through medulla, pons, and midbrain of newborn babe; level of nucleus olivaris and nucleus ruber . . . . .	494
325. Diagram of nuclei of cerebral nerves . . . . .	495
326. Endings of axones of N. vagus and N. glossopharyngeus . . . . .	496
327. Tractus solitarius of six-day-old cat . . . . .	496
328. Horizontal section through medulla, pons, and midbrain of newborn babe; level of nucleus nervi abducentis . . . . .	497
329. Cross section through rhombencephalon of four-day-old mouse; level of nucleus N. hypoglossi . . . . .	498
330. Sympathicus and N. vagus of human embryo. . . . .	499
331. Left auditory vesicle with acustico-facial complex; human embryo, fifth week . . . . .	500
332. Scheme of peripheral termination of N. vestibuli . . . . .	501
333. Isolated impregnated inter-epithelial end arborization from the macula acustica sacculi . . . . .	502
334. Lateral sagittal section through the N. vestibuli of foetal mouse . . . . .	503
335. Diagram of nuclei of cochlear and vestibular nerves . . . . .	506
336. Transverse section of medulla oblongata and cerebellum of newborn babe showing nucleus dentatus . . . . .	508
337. Transverse section through medulla oblongata at the junction of the latter with the pons . . . . .	510



FIGURE	PAGE
338. Pericellular endings of collaterals from axones of the nervi vestibuli in the nucleus nervi vestibuli lateralis . . . . .	512
339. Ganglion geniculi of newborn mouse . . . . .	513
340. Ventral view of cerebrum with portion of spinal cord . . . . .	515
341. Transverse section through the pons and cerebellum at the level of the principal motor nucleus of the trigeminal nerve . . . . .	516
342. Scheme of motor and sensory neurones; the axones of which enter into the formation of N. trigeminus. . . . .	517
343. Lateral sagittal section through pons and cerebellum of foetal mouse showing sensory portion of nervus trigeminus . . . . .	518
344. Transverse section through medulla oblongata and cerebellum of newborn child at level of ventral cochlear nucleus . . . . .	519
345. Same as Fig. 321 . . . . .	520
346. Transverse section through tractus spinalis N. trigemini of newborn rabbit. . . . .	521
347. Taste-bud . . . . .	526
348. Taste-buds. . . . .	527
349. Peripheral and central conduction paths connected with organon gustus. . . . .	528
350. Scheme of course of nerve impulses in olfactory apparatus of mammals . . . . .	529
351. Glomerulus olfactorius from a young cat . . . . .	530
352. Nasal mucous membrane innervated by N. olfactorii . . . . .	531
353. Transverse section through retina of man . . . . .	535
354. Scheme of structure of retina . . . . .	536
355. Scheme of visual conduction path . . . . .	537
356. Epithelial cells of the retina . . . . .	538
357. Section through retina of an adult dog . . . . .	538
358. Nerve cells of retina of an ox . . . . .	539
359. Perpendicular section through retina of an ox . . . . .	540
360. Structure of retina and visual lobe of <i>Eledone</i> . . . . .	542
361. Labyrinthus membranaceus in human embryo at the fifth month. . . . .	544
362. Section through cochlear region of labyrinthus osseus and membranaceus of guinea-pig . . . . .	545
363. Bipolar cells from ganglion spirale cochleæ of young mouse . . . . .	546
364. Spiral organ of Corti . . . . .	547
365. Same as Fig. 312 . . . . .	548
366. Same as Fig. 310 . . . . .	549
367. Diagram of nuclei N. cochleæ and corpus trapezoideum . . . . .	550
368. Entrance of N. cochleæ into central nervous system . . . . .	551
369. Termination of axones of N. cochleæ . . . . .	552
370. Sagittal section showing entrance of N. cochleæ in foetal mouse . . . . .	553
371. Mode of termination of axones of N. cochleæ in newborn cat . . . . .	554
372. Floor of fourth ventricle . . . . .	557
373. Transverse section at the junction of the medulla spinalis with the medulla oblongata . . . . .	558

FIGURE	PAGE
374. Transverse section through medulla oblongata at the level of decussatio pyramidum . . . . .	559
375. Transverse section through medulla oblongata showing nervus hypoglossus. . . . .	560
376. Transverse section of medulla oblongata at level of caudal end of nucleus olivaris inferior . . . . .	561
377. Transverse section of medulla oblongata, level of the middle of the nucleus olivaris inferior . . . . .	562
378. Transverse section through medulla oblongata at the level of the decussatio lemniscorum . . . . .	563
379. Fibre arcuata . . . . .	564
380. Same as Fig. 322 . . . . .	566
381. Same as Fig. 324 . . . . .	567
382. Course of axones from nuclei of dorsal funiculi to lemniscus and corpus restiforme . . . . .	571
383. Transverse section of medulla showing degeneration following destruction of nucleus funiculi gracilis . . . . .	572
384. Transverse section of medulla showing degeneration following destruction of nucleus funiculi gracilis at a higher level . . . . .	573
385. Frontal section through rhombencephalon of monkey after destruction of nucleus funiculi cuneati and of corpus restiforme. . . . .	574
386. Transverse sections through posterior half of pons and through midbrain . . . . .	578
387. Cross sections through human spinal cord . . . . .	582
388. Nerve cell from nucleus dorsalis, human embryo . . . . .	583
389. Frontal section at junction of pars thoracalis and pars lumbalis of spinal cord . . . . .	584
390. Transverse section through pars cervicalis of the cord . . . . .	585
391. Transverse section through upper third of medulla oblongata of human foetus . . . . .	586
392. Frontal section of medulla oblongata and cerebellum of seven months' foetus; level of nucleus vestibuli . . . . .	587
393. Frontal section of medulla oblongata and cerebellum of seven months' foetus at the level of nucleus dentatus . . . . .	588
394. Frontal section through rhombencephalon of monkey after destruction of nucleus funiculi cuneati and corpus restiforme . . . . .	589
395. Transverse section of spinal cord at the level of fourth cervical segment to show degeneration of Gowers' tract . . . . .	591
396. Scheme of course of fibres of the two principal tracts from spinal cord to cerebellum . . . . .	593
397. Degeneration of Gowers' tract above medulla oblongata . . . . .	595
398. Ascending degeneration of Gowers' tract . . . . .	596
399. Central sensory conduction paths in the spinal cord . . . . .	605
400. Tautomerie, heteromerie, and heceteromerie neurones in pars lumbalis of human spinal cord . . . . .	607
401. Transverse section through posterior part of pons . . . . .	610

FIGURE	PAGE
402. Section through medulla oblongata at level of <i>N. vagus</i> and <i>N. hypoglossus</i> . . . . .	612
403. Section through medulla oblongata; level of root of <i>N. glossopharyngeus</i> . . . . .	613
404. Cross section through isthmus rhombencephali . . . . .	615
405. Same as Fig. 321 . . . . .	616
406. Sagittal section of medulla, pons, and midbrain in child aged three months . . . . .	617
407. Same as Fig. 325 . . . . .	622
408. Section through nucleus <i>alæ cineræ</i> in child six weeks old . . . . .	623
409. Same as Fig. 329 . . . . .	624
410. Transverse section of medulla through nucleus commissuralis . . . . .	625
411. Same as Fig. 335 . . . . .	628
412. Section through rhombencephalon below the genu internum radicis <i>N. facialis</i> . . . . .	629
413. Frontal section through pons, showing Deiters' and Bechterew's nuclei in newborn mouse . . . . .	630
414. Same as Fig. 315 . . . . .	631
415. Same as Fig. 323 . . . . .	633
416. Same as Fig. 312 . . . . .	634
417. Transverse section through rhombencephalon of mouse showing Deiters' nucleus . . . . .	635
418. Oblique section through brain stem of newborn cat showing path from Deiters' nucleus to the cord . . . . .	636
419. Transverse section through Deiters' nucleus in the mouse . . . . .	638
420. Horizontal section through medulla, pons, and midbrain of newborn babe, level of decussatio brachii conjunctivi and nucleus reticularis tegmenti . . . . .	639
421. Same as Fig. 346 . . . . .	643
422. Transverse section through brain stem of young rat showing decussation from the nuclei <i>N. trigemini</i> . . . . .	645
423. Horizontal section of cerebellum showing marginal thickenings of the lingula . . . . .	648
424. Transverse section through cerebellum and medulla of human embryo showing nucleus dentatus . . . . .	649
425. Same as Fig. 310 . . . . .	650
426. Same as Fig. 314 . . . . .	651
427. Same as Fig. 318 . . . . .	652
428. Stillling's large and small "scissors" of the brain . . . . .	653
429. Same as Fig. 316 . . . . .	654
430. Same as Fig. 420 . . . . .	656
431. Same as Fig. 404 . . . . .	658
432. Same as Fig. 386 . . . . .	660
433. Frontal section through cerebellum and pons of foetal mouse showing <i>N. trigeminus</i> . . . . .	662
434. Lateral sagittal section through pons and cerebellum of foetal mouse showing sensory part of <i>N. trigeminus</i> . . . . .	663

FIGURE	PAGE
435. Transverse section through middle of superior colliculus . . .	669
436. Frontal section through human brain stem showing Forel's <i>Feld H</i> and the corpus Luysi . . . . .	670
437. Frontal section through hypothalamic region, human brain . . .	672
438. Frontal section through brain stem showing Forel's <i>Feld H</i> <sub>1</sub> and <i>H</i> <sub>2</sub> . . . . .	673
439. Frontal section through brain stem of man showing corpus Luysi . . . . .	676
440. Frontal section through decussatio brachii conjunctivi . . . . .	681
441. Frontal section through normal human brain at level of corpus geniculatum mediale . . . . .	682
442. Frontal section through human brain at level of nucleus hypothalamicus . . . . .	683
443. Frontal section through human brain at level of ansa lenticularis . . . . .	684
444. Frontal section through human brain at level of thalamus . . . . .	685
445. Isthmus rhombencephali in profile . . . . .	687
446. Scheme of fibres in superior colliculus . . . . .	688
447. Same as Fig. 378 . . . . .	689
448. Same as Fig. 314 . . . . .	690
449. Same as Fig. 323 . . . . .	691
450. Sagittal section of babe's brain showing capsula interna . . . . .	692
451. Same as preceding . . . . .	693
452. Same as Fig. 316 . . . . .	695
453. Same as Fig. 323 . . . . .	696
454. Schemes of course of lemniscus medialis . . . . .	698
455. Scheme of degeneration in a case of Hoessel and Fleehsig . . . . .	703
456. Scheme of central paths . . . . .	706
457. Degeneration after destruction of dorsal funiculi . . . . .	710
458. Cortical area of termination of lemniscus fibres in the cat . . . . .	712
459. Same as Fig. 406 . . . . .	719
460. Sagittal section through brain of foetal mouse showing fasciculus longitudinalis . . . . .	720
461. Same as Fig. 323 . . . . .	722
462. Same as Fig. 324 . . . . .	723
463. Same as Fig. 317 . . . . .	724
464. Same as Fig. 409 . . . . .	728
465. Same as Fig. 412 . . . . .	729
466. Sagittal section through human brain . . . . .	735
467. Frontal section through human brain . . . . .	736
468. Horizontal section through human brain . . . . .	737
469, 470. Scheme of general somæsthetic paths . . . . .	742, 744
471. Scheme of neurones superimposed in general somæsthetic paths . . . . .	745
472. Scheme of relations of anterior and posterior olfactory lobes . . . . .	750
473. Basal surface of human foetus, fifth month . . . . .	751
474. Basal surface of brain of man forty-three years old . . . . .	752
475. Rhincephalon of a man forty-three years old . . . . .	753



FIGURE	PAGE
476. Lower part of gyrus hippocampus . . . . .	753
477. Inferior anterior extremity of gyrus hippocampus . . . . .	754
478. Frontal section of bulbus olfactorius of young rabbit . . . . .	756
479. Transverse section of human bulbus olfactorius . . . . .	757
480. Horizontal section through bulbus and tractus olfactorius of man . . . . .	758
481. Mitral cells from mouse twenty-four days old . . . . .	759
482. Bulbus olfactorius of mouse twenty-four days old . . . . .	760
483. Same as Fig. 351 . . . . .	761
484. Bulbus et lobus olfactorius of rabbit in horizontal section . . . . .	762
485. Three olfactory granules from a cat . . . . .	763
486. Ventral part of frontal section of rabbit's brain showing basal ganglion . . . . .	764
487. Islands of pyramidal cells in tuberculum olfactorium of rabbit . . . . .	765
488. One of Calleja's islands in the olfactory tubercle of the rabbit . . . . .	766
489. Section through base of brain and hippocampus . . . . .	767
490. Cells from nucleus corporis mammillaris of a child . . . . .	769
491. Sagittal section through corpus mammillare of newborn mouse . . . . .	770
492. Frontal section through nucleus ruber and nucleus N. oculo- motorii of foetal mouse . . . . .	771
493. Oblique section through brain stem of cat four days old showing formatio reticularis . . . . .	773
494. Oblique section through brain stem of cat four days old showing the decussationes tegmenti . . . . .	773
495. Oblique section through brain stem of cat eleven days old showing origin of fibres of fasciculus longitudinalis medialis . . . . .	774
496. Transverse section through tela chorioidea ventriculi tertii . . . . .	775
497. Sagittal section of brain of a rabbit with bands of fibres in three planes . . . . .	776
498. Golgi preparation from peduncular region of mouse . . . . .	777
499. Diagram of Meynert's bundle . . . . .	777
500. Horizontal section of brain of <i>Cyprinus carpio</i> . . . . .	778
501, 502. Principal neurone systems of olfactory conduction path . . . . .	779, 780
503. Nerve cells from the retina of the chick . . . . .	785
504. Brains illustrating atrophy following removal of eye in newborn rabbit . . . . .	787
505. Removal of left half of chiasma opticum with the commissura inferior Guddeni in the rabbit . . . . .	788
506. Chiasma opticum and tractus opticus in human brain . . . . .	789
507. Scheme showing Henschen's investigations on relations of bundles in optic nerve, etc. . . . .	794
508. Absence of optic chiasm . . . . .	795
509. A portion of the right cerebral hemisphere to illustrate the basis cerebri . . . . .	797
510. Frontal sections through corpus geniculatum laterale of dog . . . . .	799
511. Horizontal section through cerebral peduncle and hypothalamus . . . . .	801
512. Corpus geniculatum laterale of newborn cat . . . . .	802
513. Pulvinar of mouse five days old . . . . .	803

FIGURE	PAGE
514. Transverse section of normal human optic chiasm . . . . .	806
515. Section of brain of child three months old showing optic chiasm . .	806
516. Brain of rabbit after removal of one eye and severance of tractus opticus . . . . .	807
517. Frontal section through human hypothalamus . . . . .	808
518. Frontal section through colliculus superior of the rabbit . . . . .	810
519. Transverse section through colliculus superior of rabbit . . . . .	811
520. Frontal section through occipital lobe . . . . .	813
521. Frontal section of human brain illustrating visual conduction path	814
522. Frontal section of human brain illustrating occipito-thalamic radiation . . . . .	815
523. Frontal section of human brain illustrating occipito-thalamic radi- ation, etc. . . . .	816
524. Posterior part of left cerebral hemisphere, medial surface . . . . .	817
525. Horizontal section from brain of child in second week of life . . . .	818
526. Normal and degenerated corpus geniculatum laterale . . . . .	819
527. Frontal section through nucleus habenulæ and thalamus of new- born mouse . . . . .	820
528. Section through cortex of the gyrus occipitalis superior . . . . .	822
529. Scheme of visual conduction paths . . . . .	824
530. Scheme of hypothetical decussation of axones from corpus genicu- latum laterale to lobus occipitalis . . . . .	825
531. Optic central paths illustrating von Monakow's view of represen- tation of the retina in the cortex . . . . .	827
532. Scheme of optic paths illustrating cortical and subcortical hemi- anopsia . . . . .	829
533. Visual conduction path . . . . .	833
534. Visual conduction paths . . . . .	834
535. Section of brain stem of newborn cat illustrating the separation of the fasciculus longitudinalis from the fibre system from the colliculus superior to the ventro-lateral funiculi and the relation of the lateral lemniscus to the colliculus inferior . . . . .	838
536. Transverse section of medulla oblongata showing cochlear nuclei.	842
537. Same as Fig. 313 . . . . .	844
538. Same as Fig. 323 . . . . .	845
539. Same as Fig. 314 . . . . .	846
540. Same as Fig. 440 . . . . .	847
541. Nucleus nervi cochleæ ventralis of newborn cat . . . . .	848
542. Nuclei terminales of nervus cochleæ of four-day-old rabbit . . . . .	850
543. Cross section of pons showing nucleus nervi cochleæ ventralis . . . .	853
544. Transverse section through nucleus olivaris superior . . . . .	855
545. Terminals of axones in the nucleus corporis trapezoidei. . . . .	856
546. Cell from nucleus corporis trapezoidei of newborn cat . . . . .	857
547. Cell from nucleus corporis trapezoidei of adult rabbit . . . . .	858
548. Transverse section through corpus trapezoideum of newborn mouse . . . . .	859
549. Nucleus semilunaris of newborn cat . . . . .	860



## LIST OF ILLUSTRATIONS.

xxix

FIGURE	PAGE
550. Cat's brain after section of lemniscus lateralis . . . . .	861
551. Transition of corpus trapezoideum into lemniscus lateralis . . . . .	863
552. Same as Fig. 314 . . . . .	865
553. Transverse section of colliculus inferior of cat . . . . .	866
554. Termination of axones of nervus cochleæ in the central nervous system . . . . .	867
555. Neurones with descending axones in the central acoustic paths . . . . .	869
556. Relations of lemniscus lateralis to corpora quadrigemina . . . . .	870
557. Optic and acoustic reflex paths . . . . .	871
558. Corpus trapezoideum in brain of rabbit . . . . .	872
559. Frontal section of human brain in which there was a lesion causing degeneration of corpus geniculatum mediale, nucleus ruber, substantia nigra, zona incerta, and colliculus inferior . . . . .	874
560. Sagittal section of babe's brain shortly after birth . . . . .	876
561. Sagittal section through brain of a babe at the end of the second month of life . . . . .	877
562. Frontal section through hemisphere of a child four and a half months old . . . . .	877
563. Nerve cells in the cortex of gyrus temporalis superior . . . . .	878
564. Horizontal section through brain showing relations of auditory sense area to the speech centres . . . . .	879
565, 566. Scheme of auditory conduction path . . . . .	880, 881
567. Scheme of structure of spinal cord . . . . .	886
568. Cells in a frontal longitudinal section through thoracic spinal cord of newborn babe . . . . .	889
569. Motor cell from ventral horn of spinal cord of rabbit . . . . .	890
570. Ventral horn cell from lumbar cord of ox . . . . .	891
571. Transverse section of spinal cord of <i>Lacerta agilis</i> . . . . .	891
572. Spinal cord in connection with medulla oblongata and pons. . . . .	893
573. Nerve plexuses and terminals from muscle of lizard . . . . .	894
574. Motor telodendrion from <i>Lacerta agilis</i> . . . . .	895
575. Motor nerve ending on the M. gastrocnemius of the frog . . . . .	896
576. Nerve ending on an intercostal muscle of the rabbit . . . . .	896
577. Scheme of lower motor neurone . . . . .	898
578. Muscle nuclei of human cervical cord . . . . .	905
579. Spinal cord of adult man showing grouping of nerve cells; level of C. II . . . . .	906
580. Transverse section of human spinal cord at level of C. V . . . . .	907
581. Transverse section of human spinal cord at level of C. VIII. . . . .	908
582. Transverse section of human foetal cord . . . . .	909
583. Grouping of cell bodies of lower motor neurones innervating various muscles . . . . .	910
584. Diagram of human spinal cord at level of C. III, from a case of poliomyelitis . . . . .	911
585. Columns of gray matter and motor nuclei of intumescentia cervicalis . . . . .	912
586. Columns of gray matter and motor nuclei of intumescentia lumbalis . . . . .	913

FIGURE	PAGE
587. Brain showing the origin and termination of nervi cerebrales, human embryo . . . . .	916
588. Cerebrum with portion of spinal cord, ventral surface . . . . .	918
589. First cephalic cavity, præcordial part of skull from <i>Lacerta viridis</i> . . . . .	920
590. Development of muscles of mastication . . . . .	921
591. Embryo of <i>Lacerta viridis</i> to show origin of muscles of tongue . . . . .	922
592. Diagram of sensory components of cerebral nerves of <i>Menidia</i> . . . . .	923
593. Same as Fig. 325 . . . . .	925
594. Same as Fig. 410 . . . . .	927
595. Transverse section at the junction of pars cervicalis of the cord with medulla oblongata showing nervus accessorius . . . . .	928
596. Same as Fig. 312 . . . . .	931
597. Same as Fig. 313 . . . . .	934
598. Sagittal section through rhombencephalon of fœtus . . . . .	935
599. Scheme showing motor and sensory neurones of nervus trigeminus . . . . .	936
600. Frontal section through brain stem of fœtal mouse showing nuclei of nervus trigemini . . . . .	937
601. Same as Fig. 321 . . . . .	939
602. Same as Fig. 314 . . . . .	940
603. Same as Fig. 317 . . . . .	941
604. Scheme of the nuclei nervorum oculo-motorium . . . . .	944
605. Nucleus originis et fila radicularia N. oculo-motorii of embryo duck . . . . .	946
606. Same as Fig. 557 . . . . .	948
607, 608. Schemes of reflex mechanism of spinal cord . . . . .	953
609. Section through medulla oblongata and upper cervical cord showing non-medullated olivo-spinal fasciculus . . . . .	955
610. Dorso-lateral view of nucleus olivaris inferior . . . . .	957
611. Ventral view of nucleus olivaris inferior. . . . .	958
612. Same as Fig. 311 . . . . .	961
613. Descending degeneration in spinal cord after section of corpus restiforme . . . . .	965
614. Degeneration following section of corpus restiforme . . . . .	966
615. Cross section of cervical cord showing degeneration after section of corpus restiforme of dog . . . . .	967
616. Section showing relation of nucleus lateralis superior through fasciculus longitudinalis medialis . . . . .	970
617. Section through pons showing degeneration after removal of left hemisphere. . . . .	971
618. Section showing degeneration of decussatio pyramidum after removal of left hemisphere . . . . .	972
619. Section through cervical cord showing degeneration after removal of left hemisphere . . . . .	973
620. Large pyramidal cells of cortex . . . . .	977
621. Diagram of giant pyramidal cells in gyrus centralis anterior in a man forty-three years old . . . . .	978
622. Normal Betz cell from human paracentral lobule . . . . .	979
623. Section through gyrus centralis anterior. . . . .	980

FIGURE	PAGE
624. Scheme of decussatio pyramidum . . . . .	982
625. Horizontal section through globus pallidus in newborn babe . . . . .	985
626. Horizontal section through nucleus lentiformis in newborn babe . . . . .	987
627. Horizontal section through nucleus lentiformis in newborn babe . . . . .	988
628. Horizontal section through nucleus lentiformis in newborn babe . . . . .	989
629. Section at right angles to the longitudinal fibres of the basis pedunculi (junction of upper with middle third); newborn babe, 50 to 51 cm. long . . . . .	990
630. Transverse section through the spinal cord of a newborn babe, about 50 cm. long; level of sixth cervical nerve . . . . .	991
631. Transverse section through the spinal cord of a newborn babe, about 50 cm. long; level of fourth lumbar nerve . . . . .	992
632. Early experiments of Beevor and Horsley at motor cerebral localization . . . . .	996
633, 634. Motor cerebral localization in the monkey . . . . .	998, 999
635. Comparison of motor representation in the bonnet monkey and in the orang-outang . . . . .	1001
636. Sagittal section through the brain of the monkey, illustrating the internal capsule . . . . .	1004
637. Position of fibres at various levels in the capsula interna of the monkey . . . . .	1005
638. Horizontal section through the right cerebral hemisphere cut at a distance of 61 mm. below its superior border . . . . .	1006
639. Drawn from a photograph (magnified twice) of the outer surface of a monkey's left hemisphere . . . . .	1009
640. Experimental stimulation of freshly cut substantia alba of dog's spinal cord . . . . .	1011
641. Degeneration following hæmorrhage of six months' duration in the nucleus lateralis thalami and in the lenticulo-optic portion of the capsula interna . . . . .	1013
642. Portion of pyramidal tract in cross section which has undergone secondary degeneration . . . . .	1015
643. Secondary degeneration of motor fibres from the pallium after extensive cerebral lesion . . . . .	1018, 1019
644. Non-medullated fibres in the lemniscus at birth corresponding to the centrifugal bundles of the lemniscus . . . . .	1021
645. Brain of monkey showing cortical area extirpated . . . . .	1024
646. Horizontal section of monkey's brain showing area of degeneration in internal capsule, following lesion of hallux centre . . . . .	1025
647. Degenerated area in Fig. 646, enlarged . . . . .	1025
648. Decussatio pyramidum, hallux lesion, showing degenerated fibres passing to fasciculus cerebro-spinalis lateralis of both sides . . . . .	1026
649. Spinal cord at the level of the eleventh thoracic root, hallux lesion. Bilateral degeneration . . . . .	1027
650. Section of spinal cord at the level of first cervical root; degeneration in right fasciculus cerebro-spinalis lateralis after excision of thumb centre of left hemisphere . . . . .	1028

FIGURE	PAGE
651. Horizontal section of monkey's brain showing location of degeneration following lesion of the facial area . . . . .	1029
652. Degenerated area in Fig. 651 enlarged . . . . .	1030
653. Horizontal section of monkey's brain through basis pedunculi showing location of degeneration following excision of an area marked F in Fig. 645 . . . . .	1031
654. Degenerated area in Fig. 653 enlarged . . . . .	1032
655. Scheme showing the probable course of impulses and the inter-neuronal connections in the cortex cerebri . . . . .	1034
656. Diagram of the cells of the cerebral cortex . . . . .	1035
657, 658. Schemes of upper and lower motor neurones . . . . .	1037, 1038
659. Scheme of frontal cerebro-cortico-pontal path . . . . .	1041
660. Frontal section through the region of the nucleus N. trochlearis and the decussatio brachii conjunctivi . . . . .	1042
661. Secondary degeneration following lesion in the left middle and inferior frontal gyri . . . . .	1043
662. Zone of the cerebral cortex, lesion of which causes degeneration of all the fibres of the basis pedunculi . . . . .	1046
663. Cortex of human brain illustrating the systems and plexuses of nerve fibres . . . . .	1050
664. Sagittal section through the brain of a babe shortly after birth illustrating the projection fibres to the somæsthetic area . . . . .	1051
665. Scheme of a transverse section through the brain showing the probable disposition of the commissural and projection fibres . . . . .	1054
666. Scheme of the commissura anterior cerebri . . . . .	1056
667. Scheme of an antero-posterior section through the cerebrum showing the disposition of the axones of association neurones which connect the lobus frontalis with the lobus occipitalis . . . . .	1059
668. Vertical transverse section of the left occipital lobe to show the origin and course of the short association fibres of the lobus occipitalis . . . . .	1060
669. Facies medialis hemisphærii sinistri showing the eingulum, the fasciculus longitudinalis inferior, and other bundles of association fibres . . . . .	1062
670. Marchi preparation showing degeneration in dog's brain after destruction of the lobus frontalis . . . . .	1063
671. Lateral surface of the left cerebral hemisphere . . . . .	1064
672. Vertical transverse section passing through the posterior part of the præcuncus, the fissura parieto-occipitalis, the fissura calcarina, etc. . . . .	1066
673. Two vertical transverse sections from a cerebral hemisphere, with agensis of the corpus callosum . . . . .	1068
674. Fasciculus occipito-frontalis, tænia semicircularis, and fasciculus uncinatus . . . . .	1069
675. View of lateral surface of right cerebral hemisphere showing sense centres and association centres . . . . .	1072
676. View of the medial surface of the left cerebral hemisphere showing sense centres and association centres . . . . .	1073



# THE NERVOUS SYSTEM AND ITS CONSTITUENT NEURONES.

---

## SECTION I.

### THE HISTORY OF THE DEVELOPMENT OF THE NEURONE CONCEPT.

---

#### CHAPTER I.

##### INTRODUCTORY.

The study of neurology—Older views regarding nerve cells and nerve fibres—Deiters' studies—Processes of nerve cells—Protoplasmic and axis-cylinder processes—von Gerlach's studies—Idea of a diffuse nerve network.

IN face of the many questions concerning bacterial toxicology, internal secretion, self-intoxication, serotherapy, and organotherapy, subjects all fraught with practical import sufficient to explain the absorbing interest in medical circles regarding them, one might have had some hesitation in choosing as a subject the title given above, were it not that this topic is the one which more than any other since the beginning of scientific records has occupied and must ever occupy the minds of thoughtful physicians in all countries of the world. And one cannot but feel that when these burning questions of to-day shall have been settled or supplanted by others, subsequently thought to be more important, the problems connected with the nervous system, that portion of man's organism which in the main is accountable for the high position he has assumed among the animals, by means of which, in addition to the advantages of reflexes and instinctive reactions, he is able not only to gather multiple experiences, but to communicate them to his fellows and to utilize them in bettering his condition, to study, to investigate, and to speculate—these problems will

still remain the most attractive and absorbing. At the end of a decade which has witnessed an unprecedented activity in this domain, the results of which have led to a complete revolution in our ideas concerning the elements of the nervous organs and their architectural relations, and have supplied us with a host of new methods of investigation, the study of neurology, especially of the human nervous system in health and in disease, is particularly alluring. Entirely new avenues of research have been opened up, and problems hitherto thought to be situated almost outside the limits of scientific inquiry now seem at least within human possibility.

It may be stated in the beginning that it has seemed to me advisable to gather together in as simple a manner as possible some of the more general results of modern neurological investigation and to hint rather at the outlook for the future than to detail at length the results of any single original research. Nor would it be possible in the space at my disposal to cite even the main results obtained in all the different directions in which neurological inquiry has been pursued. I shall have to be content with reviewing some of the main achievements in the departments with which I am most familiar, leaving it, however, to be distinctly understood that in the others many just as important conclusions have been arrived at and much fundamental experimentation is still in progress.

Entertaining as it could be made, it is not my purpose to give a review of the evolution of the various doctrines held at different times regarding the structure and function of the central and peripheral nervous system, nor to describe the gradual modifications and inventions in anatomical and histological technique which have been evolved with each new theory and which have opened up new fields for study. It will be necessary, however, in order to make clear the phenomenal advance represented by the ideas which at present prevail, to speak briefly of the unsatisfactory state of the views which immediately preceded them.

Considering the remarkable activity manifested during the epoch-making period of 1838-'40, when, incited by the publications of Schleiden and Schwann, anatomists busied themselves in ransacking all regions of the body, hunting for "cells," it is not surprising that a number of them turned their attention to the nervous organs, concerning the finer structure of which



little was then known. Ehrenberg, as early as 1833, in studying the spinal ganglia and the central nervous system, had undoubtedly seen the ganglion cells in the former and the medullated fibres in the latter, although he described them as capillary tubes. After him, Valentine and Purkinje gave better descriptions, the former of the spinal ganglion cells, the latter of the ganglion cells in the brain. Emmert, Henle, and Rosenthal studied the differences in size and number of the fibres in the ventral and dorsal roots of the spinal nerves.\* But to Remak and Helmholtz belongs the credit of showing that a portion, at least, of the processes of the nerve cells of vertebrates go directly over to form nerve fibres, at any rate in the sympathetic system. Von Kölliker in 1844 described the unipolarity of the cells in the ganglia of the dorsal roots, and the origin of medullated nerve fibres from them, although it was not until 1875 that Ranvier demonstrated the T-shaped division of the process at a distance from the cell, while the real explanation of the unipolarity and its relation to the bipolar condition in fishes was first worked out in the embryological studies of His.

With regard to the connection of the nerve cells, within the central nervous system itself, with conduction paths, the first observation is that of Wagner,† who in 1847, while studying the electric lobe of the torpedo's brain, found that of the numerous processes possessed by the nerve cells only one or rarely two remained unbranched and became connected with a nerve fibre, a finding which Remak in 1854 asserted also for the cord and brain of the ox, and which in the following year he stated was true in general of all motor cells. The most important obser-

---

\* The discovery that the ventral roots of the spinal nerves are concerned with motion, the dorsal roots with sensation, had been made earlier by the eminent British surgeon and anatomist, Sir Charles Bell. His views on the structure of the nervous system are contained in the following three works: (1) *Idea of a New Anatomy of the Brain*; Submitted for the Observations of his Friends, 36 pp. 8vo (London, 1811); (2) *An Exposition of the Natural System of the Nerves of the Human Body, with a Republication of the Papers Delivered to the Royal Society on the Subject of Nerves*, vii, 392 pp. 8vo (London, 1824); (3) *The Nervous System of the Human Body, etc.*, 4to (London, 1830; third edition, Edinburgh, 1844).

† Wagner, R. *Ueber der feineren Bau des elektrischen Organs im Zitterrochen*, 4to (Göttingen, 1847); also, *Neue Untersuchungen über den Bau und die Endigung der Nerven und die Struktur der Ganglien* (Leipzig, 1847).

vations and generalizations of this period were, however, made by Deiters, the distinguished investigator at Bonn, who, like many others who have successfully pursued scientific studies, died at a comparatively early age.\*

Deiters made an extremely careful study of the various processes of nerve cells with the best technical methods at his disposal and classed them all in two great groups: (1) Protoplasmic processes which were branched and the internal structure of

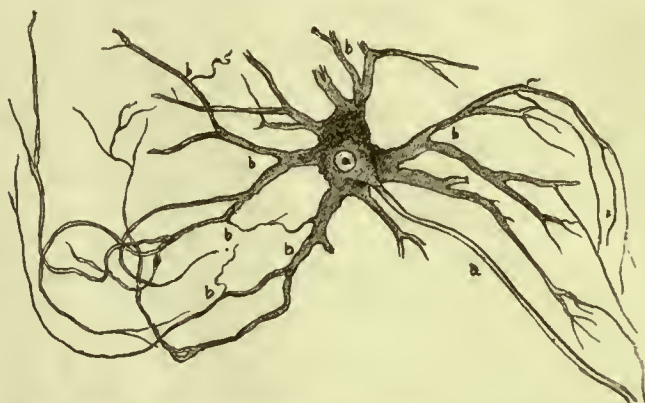

FIG. 1.—Multipolar ganglion cell from the ventral horn of the gray matter of the spinal cord of the ox. (After Deiters.) *a*, axis-cylinder process; *b*, protoplasmic processes.

which corresponded closely to that of the body of the nerve cell, the protoplasm of the process being granular, and sometimes even pigmented; and (2) axis-cylinder or nervous processes consisting of a rigid hyaline, more resistant substance which at a short distance from its origin in the nerve cell passed directly over into a medullated nerve fibre (Fig. 1).†

---

\* Otto Deiters' book, *Untersuchungen über Gehirn und Rückenmark des Menschen und der Säugethiere*, Braunschweig, 1865, was issued by Max Schultze, two years after the author's death.

† In reality, Deiters describes two kinds of axis-cylinder processes, coarse and fine, the description in the text applying to the former. He thought that the finer axis-cylinder processes could be present in large numbers on single nerve cells, arising from the protoplasmic processes and going over into the fine medullated fibres of the central nervous organs. These finer axis-cylinder processes have been recently proved by the delicate histological methods of Held to be the terminals of axis-cylinder processes of other cells thus ending on, not arising from, the cell with which they seem to be connected.

Waldeyer, in his excellent review of the more recent investigations into the anatomy of the nervous system,\* lays emphasis upon the point that despite the enormous value of his researches Deiters did not actually demonstrate the connection of a ganglion cell of the central nervous system with a peripheral nerve fibre, a fact to which Kölliker and Gerlach had previously made reference. The connections of the axis-cylinder processes of the cells of the ventral horns with the axis cylinders of the fibres of the motor roots of the spinal nerves were first absolutely established by the use of Weigert's mordant methods of staining the myelin sheath. † The counting experiments of Birge ‡ in Ludwig's laboratory showed a remarkable accordance in the number of ventral horn cells and that of the fibres in the ventral roots, and led many physiologists and anatomists to the belief that each motor fibre in the ventral root is connected with a corresponding cell within the gray matter of the cord.

More widely reaching in influence, for some time at least, were the studies of Gerlach\* with the gold method and the hypotheses which he based upon them, hypotheses which were responsible for an immense amount of polemical writing during the fifteen years which followed their introduction. Gerlach, by means of methods of isolation and treatment with chloride of gold, obtained pictures surpassing by far, in extent and delicacy, any obtainable with the older methods, and affording an entirely new concept of the complexity of the structure of the

\* Waldeyer, W. Ueber einige neuere Forschungen im Gebiete der Anatomie des Centralnervensystems. Deutsche med. Wchnschr., Leipz., 1891, Bd. xvii, S. 1244, 1267, 1287, 1331, 1352.

† Carl Weigert's methods and the carmin methods of Gerlach in conjunction with improved technique in sectioning have contributed enormously to the advance of investigations in neurology. For the application of Weigert's methods to the nervous system of lower animals the experiments of C. J. Herrick may be referred to with advantage. (Cf. Herrick, C. J., Report upon a Series of Experiments with the Weigert Methods—with Special Reference for Use in Lower Brain Morphology. The State Hospitals Bulletin, Utica, vol. ii, 1897, pp. 431-461.)

‡ Birge, E. A. Die Zahl der Nervenfasern und der motorischen Ganglienzellen im Rückenmark des Frosches. Arch. f. Anat. u. Physiol., Leipz., 1882. Physiol. Abth., S. 435-480.

\* v. Gerlach, J. Article, The Spinal Cord, in A Manual of Histology by S. Stricker. American Translation. New York, 1872.

gray matter of the spinal cord and brain. In addition to the bodies of the nerve cells and their main processes, protoplasmic

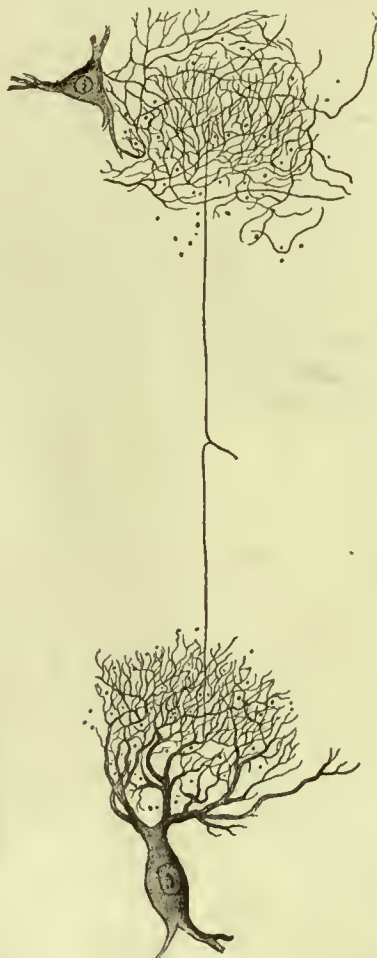

FIG. 2.—Network supposed by Gerlach to be formed of the protoplasmic processes of the nerve cells. A branching nerve fibre from the cord of the ox is shown whose two branches are connected with a fibre network which is in relation with two nerve cells. (After Gerlach.) This condition has been shown by Golgi's method *not* to accord with the facts.

and nervous, the new method revealed the most intricate and involved appearances, which led Gerlach to believe that he had discovered a most extensive and delicate diffuse network within



the gray matter (Fig. 2). Not satisfied with the simple description of his findings, he proceeded to set up an interesting hypothesis, based largely upon the physiological ideas which prevailed at the time, regarding protoplasmic continuity.\* He concluded that he had to deal with a complex nerve network,† consisting of a genuine reticulum of delicate fibrils resulting from the fusion of the ultimate dendritic branchings of the protoplasmic processes of the nerve cells of the central organs. From the far side of this network, through gradual fusion and concentration of the threads belonging to it, broader fibres slowly appeared, which finally were to be recognized as genuine nerve fibres, becoming medullated and forming the fibres of the dorsal roots (sensory fibres) and in part the white fasciculi of the spinal cord. Gerlach's view, therefore, was that the axis cylinders of motor nerve fibres represent nervous processes coming off directly from nerve cells, while the sensory fibres of the dorsal roots are to be looked upon as nerve fibres arising from nerve cells only indirectly through the intervention of a diffuse nerve network made up of their protoplasmic processes. Thus, according to his scheme, with which Boll and Haller essentially agreed, the whole nervous system represents a protoplasmic *continuum*—a veritable *rete mirabile* (Fig. 3). Such was the state of affairs at the time when what we are accustomed to call the “newer investigations” were begun. A more unsatisfactory condition of knowledge or a more prohibitive hypothesis can scarcely be conceived; all ideas of tracing out

---

\* This assumption of protoplasmic continuity has also been made use of by Mr. Herbert Spencer in the development of his doctrine of the genesis of nervous systems. *Principles of Psychology*, New York, D. Appleton and Company, vol. i, p. 520. The botanists, following especially the researches of Gardiner, teach at present that in plant tissues the protoplasm of all the cells forms a *continuum*, a fact which hinders many students of animal histology from asserting too positively the non-existence of such a *continuum* in the tissues of adult animals. The demonstration comparatively recently of the so-called plasma bridges connecting epithelial and endothelial cells, and also perhaps the elements of other tissues with one another, is interesting in this connection.

† In gold preparations it must have been extremely difficult, and was probably impossible, to distinguish a network from a feltwork. A German investigator, speaking of the frightfully intricate complex of fine nerve fibrils in the central nervous system, referred to it as the *Bierfilz der grauen Substanz*.

definite conduction paths or of localization of function within the central nervous system seemed well-nigh hopeless; in the

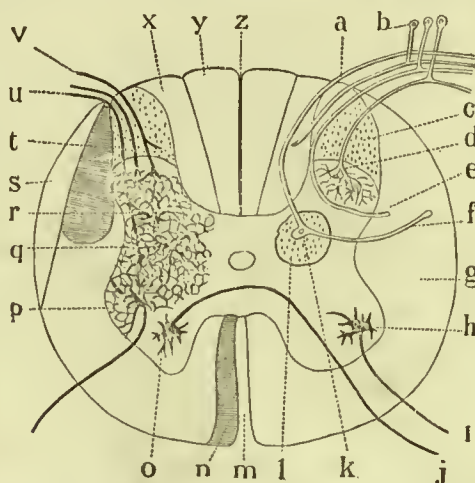


FIG. 3.—Scheme of connections of dorsal and ventral roots of spinal cord according to a discarded theory. (After Ramón y Cajal.) *a*, fibre of dorsal root supposed to have its origin in Clarke's nucleus; *b*, unipolar cells of spinal ganglion; *d*, termination of a dorsal root fibre in the reticulum of the dorsal horn; *e*, root fibre going to pass longitudinally in the lateral column; *f*, fibre from Clarke's nucleus directed toward the lateral column; *g*, lateral column; *h*, motor cell connected with fibre of ventral root; *i*, *j*, fibre of ventral root coming from a cell in ventral horn of opposite side; *k*, column of Clarke; *m*, ventral median fissure; *n*, column of Türk; *p*, cell of ventral horn, the protoplasmic processes uniting to form a network, *q*, in which the fibres of the dorsal root terminate; *r*, cells of dorsal horns, the protoplasmic processes of which are united to the network, *q*; *s*, ascending fasciculus of lateral column; *t*, lateral pyramidal tract; *u*, *v*, fibres of dorsal root terminating in the network; *x*, fasciculus cuneatus of Burdach; *y*, fasciculus gracilis of Goll; *z*, median dorsal sulcus.

general diffuse network investigators were halted by what appeared to be an insuperable barrier.



## CHAPTER II.

### THE STUDIES OF HIS, GOLGI, AND FOREL.

The newer investigations—Golgi's method—Types of nerve cells described by Golgi—Cell of Type I and cell of Type II—Golgi's hypotheses—Contributions of His and Forel—Opposition to the idea of a nerve network—Origin of the idea of a nerve feltwork or neuropilem—Doctrine of the individuality of the nerve elements—The principle of contact formulated.

THEN followed a series of researches, the majority of which date since the year 1880, and with which the names of Golgi, His, Forel, Kölliker, Ramón y Cajal, van Gehuchten, Retzius, and von Lenhossék are inseparably connected. These investigations led to a complete revolution in the ideas regarding the elements of which the nervous system is constructed and the mode in which these elements are put together in its architecture. It may surprise many to learn that the now world-famed Golgi's method was first described by its inventor, Camillo Golgi, of Pavia, as early as 1873.\* But little attention was paid to it by investigators in other countries, however, until more than twelve years later, when he published his voluminous article, *Concerning the Finer Anatomy of the Central Organs of the Nervous System*.† The method is now so well known that it is unnecessary to describe it here in detail. It will be recalled that it depends upon the treatment with a solution of nitrate of silver after previous immersion of the perfectly fresh tissue for a longer or shorter time in a solution of

---

\* Golgi, C. Sulla struttura della sostanza grigia del cervello. *Gazzetta medica italiana lombardia*, t. vi, 1873. Golgi's contributions to the bibliography of the nervous system have been collected and translated into German by Teuscher. Cf. Golgi, C., *Untersuchungen über den feineren Bau des centralen und peripherischen Nervensystems*, Jena, Fischer, 1894.

† Golgi, C. Sulla fina anatomia degli organi centrali del sistema nervoso. *Riv. sper. di freniatr.*, Reggio-Emilia, 1882, vol. viii, pp. 165, 361; 1883, vol. ix, pp. 1, 161, 385; 1885, vol. xi, pp. 72, 193.

bichromate of potassium.\* The nerve cells and their processes stain intensely black and stand out prominently on the white or yellow ground. The pictures obtained are in extent, clearness, and sharpness, at least as far as the external form of the element is concerned, incomparably superior to those obtainable by any other known technical method.† As a rule, cer-

---

\* The slow chromate of silver method recommended by Golgi is used as follows: Pieces of tissue are hardened in Müller's fluid for at least one or two months. They are then transferred to a bath of dilute silver-nitrate solution, where they remain for from one to three days, after which the tissue may be cut into sections, after very rapid imbedding.

The method now almost universally employed is the quick method in which osmic acid and potassium bichromate are used. Small pieces of living tissue, not exceeding four millimetres in thickness, are fixed, at a temperature of 25° C., for from one to four days in the following mixture, recommended by Ramón y Cajal: Bichromate of potassium, 3 gm.; distilled water, 100 c. c.; one-per-cent solution of osmic acid, 30 c. c. For each piece of tissue, four millimetres square, ten cubic centimetres of this mixture should be employed. After the fixation the pieces are quickly washed in distilled water, and then immersed in a 0.75-per-cent solution of silver nitrate. They are permitted to remain in the silver bath for from one to three days. They are then very rapidly imbedded in celloidin and cut into sections, serial if desired, with the aid of a microtome. The sections are to be quickly dehydrated by passing them through several dishes of ninety-five-per-cent alcohol. The clearing is best done with oil of bergamot (Berkley). On the slide the excess of oil is removed with blotting paper pressed directly upon the sections (Welch), and a drop of thick balsam is placed upon each section. No cover slip is to be applied. If desired, the sections may be mounted upon thin glass or isinglass, which may then be fastened to a glass slide by means of glass beads, the side on which the sections are being down, to protect them from dust (Edinger).

For some researches the modification of Cox can be especially recommended. According to W. H. Cox (*Imprägnation des centralen Nervensystems mit Quecksilbersalzen*. Arch. f. mikr. Anat., Bd. xxxvii (1891), S. 16), the fresh tissues are to be hardened for from two to five months in the following fluid: Of a five-per-cent solution of bichromate of potassium, 20 parts; five-per-cent solution of bichloride of mercury, 20 parts; distilled water, 40 parts. Mix, and add five-per-cent solution of chromate of potassium, 16 parts. The tissues are then to be washed for half an hour in ninety-per-cent alcohol, then imbedded and sectioned (preferably with the freezing microtome) as in Golgi's method. The sections are placed for from one to two hours in a five-per-cent solution of sodium carbonate, or in ammonia solution; then washed in distilled water, quickly dehydrated, cleared, and mounted in balsam without cover glass.

† Such pictures afford suitable objects for reproduction by photography. Compare the beautiful Atlas of Nerve Cells, of Starr, Strong, and Leaming,

tain only of the nerve structures present are found to be impregnated in a successful preparation. Whether this effect is dependent or not upon functional conditions of the tissues at

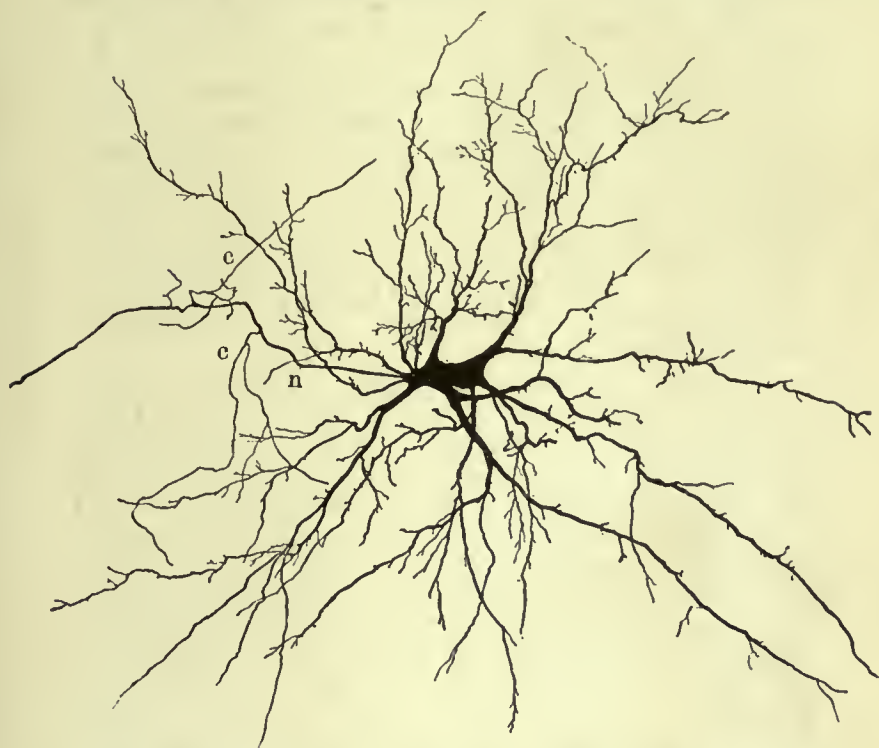

FIG. 4.—Golgi's cell of Type I. Cell from the optic tract of the cat lateral from the lateral geniculate body. (After Kölliker.) Radiating from the cell body are to be seen very many protoplasmic processes which show a broad wedge of origin and branch characteristically; the single axis-cylinder process *n* has a smooth surface and tolerably even calibre, which is maintained for a considerable distance from the cell. It gives off a few delicate lateral branches or collaterals, *c*.

the moment of immersion we do not as yet know; certain it is that a distinct advantage is gained, inasmuch as the elements are represented, as it were, in a diagrammatic manner, and the study of them is in a high degree facilitated.\*

---

New York, 1896, and the photographs by Hoen illustrating Berkley's publications.

\* A valuable critique of the Golgi method, its nature and results, is that of A. Hill, *The Chrome-Silver Method, Brain*, Lond., vol. xix, 1896, pp.

Golgi, by the application of these silver methods to the gray matter of the cerebro-spinal nervous system, recognized nerve structures varying in character, which he grouped into two main categories of nerve cells—cells of Type I and cells of Type II. The cell Type I (Fig. 4), as described by Golgi, agrees in the main with the general description of a central nerve cell given by Deiters, being characterized by much-branched protoplasmic processes (usually multiple) and a single axis-cylinder process. That the latter was unbranched, however, as Deiters maintained, Golgi denied, and his discovery of “side branches” upon the axis-cylinder processes, first of the pyramidal cells of the cerebral cortex, and later upon those of the Purkinje cells of the cerebellum, represents an advance of a degree of importance utterly beyond Golgi’s conception at that time.\*

These side branches given off by the axis-cylinder process of cell Type I are usually delicate, and exercise a hardly perceptible influence upon the calibre of the main fibre, which retains its individuality at least for a long distance from the cell. Golgi noted that these side branches exist also upon the motor fibres arising from the cells of the ventral horns, and that similar ones are given off by the fibres of the white fasciculi of the spinal cord, whence they run into the gray matter.

The branching of the axis-cylinder process shows quite a different behavior, however, in the cell of Type II (Fig. 5), and indeed it is the axis cylinder which is morphologically characteristic in the two classes of cells rather than the protoplasmic processes. The axis cylinder of a cell of Type II begins to divide almost immediately after its departure from the cell body which gives it origin, breaking up in a dendritic manner into a large number of fine branches, the main process retaining its individuality and being distinguishable for a comparatively short distance (Fig. 6), and never appearing to leave the gray matter.

Not taking into account certain observations upon neuroglia, it may be said that the most important contributions

---

1-42. C. Weigert has recently reviewed the technique of the Golgi method in Merkel-Bonnet’s *Ergebnisse der Anatomie u. Entwick.*, Bd. v, Wiesbaden, 1896, S. 7.

\* Waldeyer mentions that he himself noted the branching of the central process of the Purkinje cells as early as 1863.



of Golgi in the domain of neuro-histology\* consist in (1) the invention of the silver method of staining; (2) the recognition within the central regions of cells of different types (Type I and Type II); (3) the discovery of lateral branches from the axis-cylinder processes and the fact that the majority at any rate of the nerve cells possess only one axis-cylinder process; (4) the demonstration that the protoplasmic processes branch manifoldly without anastomosing, all running out to ultimately terminate blindly.

Unfortunately, Golgi, not contented with describing these objective findings, gave utterance to a number of hypotheses, particularly with regard to certain functional relations and to the ultimate fate of the side fibrils given off by the axis-cylinder processes, which led him and many after him into a whole labyrinth of errors. Concerning these I shall have something to say further on. For the present, it will suffice to state that Golgi believed that the cells of Type I were motor cells, and the cells of Type II sensory cells; that Gerlach's diffuse nerve network,

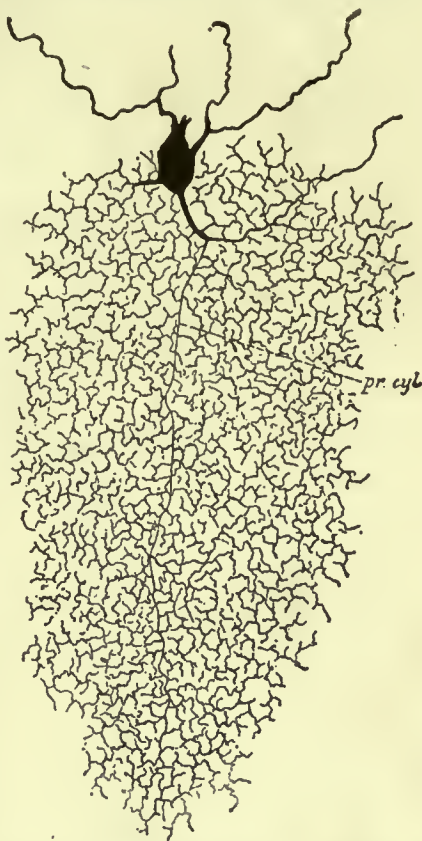

FIG. 5.—Nerve cell with short branched axis cylinder (*pr. cyl.*) from the granular layer of the cerebellum of a cat aged eight days. Golgi's cell Type II. (After Van Gehuchten.)

\* Golgi's fame as an investigator does not depend entirely upon his brilliant researches on the nervous system. His studies of the different varieties of malarial parasites transformed clinical ideas upon the subject and would alone have sufficed to make his name lasting.



arising from the anastomosis of protoplasmic processes and connected with sensory fibres on the distal side of the net-

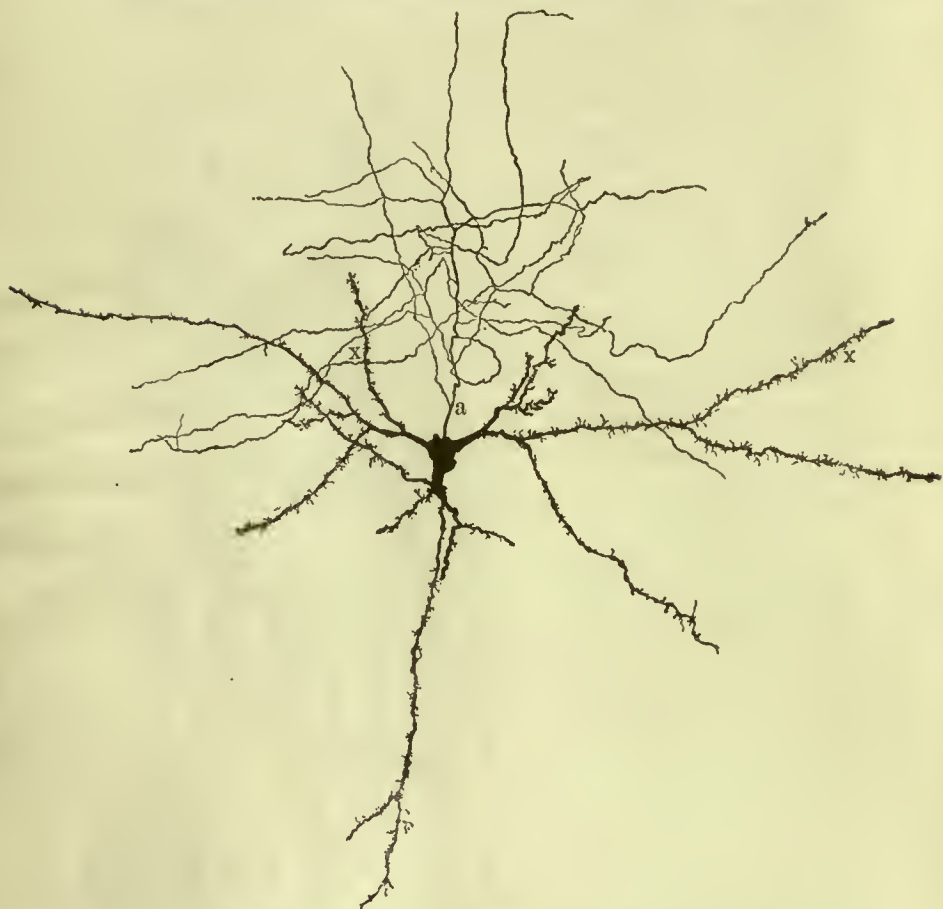

FIG. 6.—Golgi's cell of Type II or dendraxone from the cerebrum of a cat. (After Kölliker.) The coarse protoplasmic processes, *x*, are easily distinguishable from the axis-cylinder process, *a*, though the latter soon loses its identity, exhausting itself by multiple division at a short distance from the cell.

work, had no existence in fact, but that there did exist a diffuse nerve network (*intreccio*) within the gray matter\* made up of

---

\* Golgi has never pictured this network, and in all his writings he has spoken of it in a very indefinite manner and with great reserve. For example, in his *Studi sulla fina anatomia degli organi centrali del sistema ner-*

the many branches of the axis cylinders of the cells of Type II and the side fibrils of the axis cylinders of the cells of Type I. Protoplasmic processes, in his opinion, possess no nervous function, but represent simply portions of the protoplasm of the nerve cell which run out to be connected with the blood-vessels or neuroglia cells in order to gather nourishment from them. Golgi believed that the dorsal root fibres on entering the cord branch freely and terminate by becoming a part of the diffuse nerve network in the gray matter, the sensory impulses reaching the axones of the motor fibres through their side fibrils, which, he thought, are connected with the distal side of the general network. In this way the dendrites and the cell body are excluded from the reflex arc (Fig. 7). Epoch-making as were his actual discoveries, the admixture with facts of such hypotheses was indeed unfortunate.

The credit, I think with justice, has been given by both van Gehuchten and von Lenhossék to His, of Leipsic, and to Forel, of Zürich, for having directed the first telling blows against the doctrine of a diffuse nerve network and in favor of the independence of the individual nerve elements. The distinguished anatomist\* has since the year 1881 busied himself, in the main, with the study of the morphology and histogenesis of the nerve organs, and his results in this field may justly be classed among the most striking achievements of a life of indefatigable activity.

---

voso, Milano, 1886, p. 31, he says: "Out of all these branchings of the different nerve processes there arises, of course, an extremely complicated texture which extends throughout the whole of the gray substance. That out of the innumerable further subdivisions by means of complicated anastomoses there arises a network, in the strict sense, and not simply a felt-work, is very probable; indeed, one would be inclined from some of my preparations to believe in it, but the extraordinary complication of the texture does not permit this to be declared as certain." In a later article, *La rete nervosa diffusa degli organi centrali del sistema nervoso; suo significato fisiologico* (Rendiconti del R. Istituto Lombardo, ser. ii, vol. xxiv, 1891, pp. 595, 656; Transl. in Arch. ital. de biol., Turin, 1891, t. xv, pp. 434-463), Golgi has dealt with this topic at length, replying to the objections which have been urged against the existence of the diffuse nerve network and commenting upon its physiological significance.

\* The monographs of His upon the chick and his researches upon the anatomy of human embryos contain results of personal work which represent a goodly proportion of what is reliable in modern embryology.

His investigations led him early to the conclusion that from the beginning the forerunners of the nerve cells—the neuroblasts—are entirely distinct from and independent of one another. They appear at first as oval or pear-shaped cells with smooth cell bodies entirely devoid of processes; later, at the end of the cell originally directed away from the outside of the

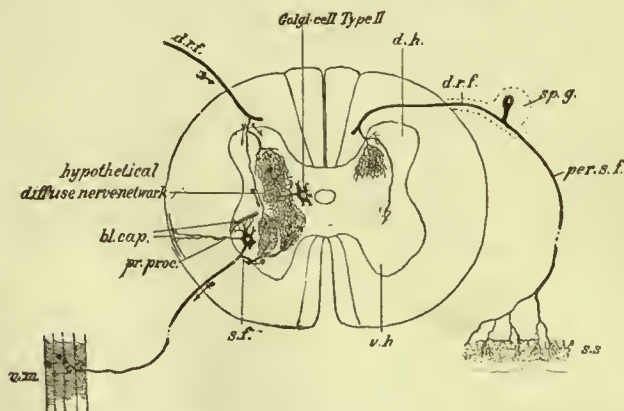


FIG. 7.—Schematic representation of the diffuse nerve network supposed by some investigators to be formed by means of the side fibrils of cell Type I and the axones of cell Type II. The sensory fibres of the dorsal root are shown entering into connection with this diffuse nerve network, and the course of impulses concerned in simple reflexes according to this view is shown by the direction of the arrows. By this means the cell body and protoplasmic processes were supposed to be excluded from the reflex arc. The dendrites were supposed to be purely nutritive in function, passing out, to be connected with the walls of blood-vessels, whence the nutrient supply was derived, as shown in the figure. All the evidence goes to show that this view is *incorrect*. *v. h.*, ventral horn of gray matter; *d. h.*, dorsal horn; *s. f.*, side fibril from axis cylinder of motor cell of ventral horn passing back into the hypothetical diffuse nerve network; *pr. proc.*, protoplasmic process of motor cell of ventral horn passing through white matter to blood capillary of the pia; *bl. cap.*, blood capillaries (1) in the gray matter, (2) in the pia, with which the protoplasmic processes were supposed to be connected or related; *d. r. f.*, fibre of dorsal root sending branches into the gray matter to terminate in the diffuse nerve network; *Golgi cell Type II*, cell in the gray matter, its much-branched axis-cylinder process helping to form the diffuse network; *sp. g.*, spinal ganglion; *per. s. f.*, peripheral sensory nerve fibre; *s. s.*, sensory surface; *v. m.*, voluntary muscle innervated by fibre of ventral root.

body, there arises a projection which corresponds to the subsequent axis cylinder of a nerve fibre. The protoplasmic processes do not develop till afterward and branch soon after their appearance. The fibres of the dorsal roots of the spinal nerves represent processes of cells situated in the spinal ganglia and their terminations lie free inside the spinal cord. In these early stages there is no anastomosis between the different processes of a single nerve element, nor could His make out in the later

developmental periods any evidence of the fusion of the processes of one cell with those of another.\* His, therefore, opposed the idea of a diffuse network, attributing the appearances which suggested it to the existence of a most complex felt-work (*Neuropilem*) composed of the finer subdivisions of the processes of the nerve cells.

It was in 1887 that Nansen published his comprehensive article on the structure of the nervous system,† in which he attempted to show that the axis-cylinder processes of the nerve cells are made up of multiple tubes of minute size. It is of no little interest that the celebrated Arctic explorer at this early period recognized the high importance of the discoveries of Golgi. On page 71 of his article he says:

"I think it is indeed also very strange that neither Rawitz nor Haller (nor most modern writers) are acquainted with the excellent papers on the central nervous system of vertebrates by Golgi. They quote a great many other and less important writers, but they do not seem to know this eminent histologist who, in my opinion, has really introduced a new epoch in our researches into the structure of the nervous system." Nansen pictures distinctly, in Figs. 111 and 112 accompanying his report, the bifurcation of the fibres of the dorsal roots of the spinal nerves.

The criticism which appeared at this period from the pen of Forel, the celebrated Zürich psychiatrist,‡ is of extreme value from a historical standpoint. Well versed in the results of pathological anatomy and experimental pathology, and acquainted with the earlier work of His, Forel, in a short essay, discussed the status of neuro-histology at the time, including in his criticism the results and hypotheses of Golgi. He recognized fully the importance of Golgi's objective findings, but

---

\* At the end of an article, *Zur Geschichte des menschlichen Rückenmarkes*, dated 1886, His says: "Als feststehendes Princip vertrete ich dabei den Satz: dass jede Nervenfasern aus einer einzigen Zelle als Ausläufer hervorgeht. Diese ist ihr genetisches, ihr nutritives und ihr funktionelles Centrum: alle anderen Verbindungen der Faser sind entweder nur mittelbare oder sie sind sekundär entstanden."

† Nansen, F. *The Structure and Combination of the Histological Elements in the Central Nervous System*. Bergens Museum Aarsberetning for 1886. Bergen, 1887.

‡ Forel, A. *Einige hirnanatomische Betrachtungen und Ergebnisse*. Arch. f. Psychiat. und Nervenkr., Berl., Bd. xviii, 1887, S. 162-198.



with peculiar keenness of perception sifted out the facts from the hypotheses. He entered a strong protest against the network theory and spoke for the maintenance of the individuality of the nerve elements. Forel recognized the importance of the "caprice" of the Golgi method in staining an element only here and there as bearing upon the independence of the nerve units, but it is his utilization of the studies of secondary degenerations which makes his communication of the deepest significance. He pointed out that not only does the distal end of a divided motor fibre undergo rapid disintegration after section (Wallerian degeneration), but that also, in contradiction to the doctrine of Waller, the proximal end undergoes cellulipetal degeneration, though often much more slowly (von Gudden's law), when the division of the fibre has occurred at the point of exit of the motor nerve from the central system. Forel further emphasized the fact that when degeneration involves a tract of nerve fibres it extends only as far as the termination of the tract. If atrophy of nerve cells and nerve fibres occurs beyond the termination of the tract, it is of a fundamentally different character from that which affects the tract undergoing typical secondary degeneration. Whereas in the latter process a rapid and complete disintegration with absorption occurs, in the other case there is, as a rule, only a diminution in the calibre of the nerve fibres and a shrinking in size of the nerve cells (so-called indirect atrophy).

To illustrate this point, Forel, happily it would seem, chose the experimental degenerations produced by von Gudden and von Monakow in the domain of the sensory conduction path leading from the retina to the cerebral cortex. Whereas if, on the one hand, in an animal like the rabbit in which the decussation of the fibres in the optic chiasm is almost total, one eye be extirpated, there results almost total degeneration of the corresponding optic nerve, and of the opposite optic tract, together with a considerable diminution in size of the lateral geniculate body, owing to the disappearance not of its nerve cells but of the gelatinous substance between the cells (consisting of the terminal ramifications of the optic fibres which have entered it); on the other hand, if the visual area of the cerebral cortex be extirpated, the lateral geniculate body of the same side degenerates, but in an entirely different way. In the latter instance it is not the gelatinous substance which disappears, but the nerve cells



themselves vanish. The obvious deduction from the pathological findings is that between the retina and the occipital cortex at least two nerve units are interposed, one extending from the retina to the optic centres at the base of the brain, and the second from the latter centres to the cortex of the cerebrum. The limits of a given degeneration under pathological conditions correspond in extent to those of the unit or units involved in the lesion. Finally, for the first time do we find stated clearly in this article the principle of contact as an explanation of the correlations of the nerve cells and their processes within the gray matter, a principle the formulation of which has been of considerable influence in the development of neurological knowledge, but one which, as we shall see later, is not wholly in accord with the facts.

## CHAPTER III.

### THE STUDIES OF RAMÓN Y CAJAL AND OTHERS WITH GOLGI'S METHOD AND WITH MODIFICATIONS OF THAT METHOD.

Researches of Ramón y Cajal—Denial of occurrence of anastomoses among nerve elements—The collateral branches of the axis-cylinder processes—Tendency to external morphological uniformity among the nerve elements—Transition forms between cells of Type I and cells of Type II—The cells in sensory and motor regions—Studies of other investigators.

THE contributions of Forel and His, well supported and convincing as they were, did not, however, suffice to eradicate the older ideas of a reticulum from minds in which they were as firmly established as are most prejudices and preconceived ideas taken in with mother's milk. To appreciate discoveries based partly upon pathological experience, but largely upon studies in histogenesis, a field whose fruits had not yet attained the appreciation they deserved, a conservative medical world required, for its awakening, influences still more arousing. These were soon forthcoming and from an unexpected quarter.

If we may believe a popular rumor, something more than ten years ago a young doctor in Spain, a country remarkable from a medical standpoint up to his time for its barrenness in original research, applied for a position in microscopy, which was refused him. His pride wounded keenly, he renounced his social relations, purchased a small library on histological subjects, paid special attention to certain technical methods, worked like a slave at his subject, and a decade later found himself famous. Santiago Ramón y Cajal has left Barcelona behind him and is now professor at Madrid, has lectured before international audiences, and has won the admiration and respect of the whole scientific world; he is a medical *immortel*. The story, even if it be not true, is certainly well invented. Beginning with two articles in the year 1888, one upon the retina of

birds\* and the other upon the nerve fibres of the molecular layer of the cerebellum,† Ramón y Cajal exhibited during the next few years a most astonishing productive activity,‡ which, judging from the nature of his articles in current journals, is by no means yet exhausted.

A brief inquiry into the contributions of Ramón y Cajal can not fail to make clear why they almost immediately attracted close attention in widely distant quarters. Leaving out of consideration the immense mass of detailed discoveries with which Ramón y Cajal has enriched the finer anatomy of the spinal cord and brain, the salient features of his work, those which make it so significant as regards our present concept of the elementary structure, are (1) the demonstration (apparently definite at the time) of the complete independence of at least the majority of the nerve elements, the branches of the axis cylinders forming anastomoses no more than those of the dendrites; (2) the appreciation of the widespread occurrence and significance of the lateral branches (collaterals) of the axis-cylinder processes; and (3) the demonstration of the striking uniformity in general structure of the majority of the nerve elements in all parts despite multiple minor morphological variations.

Golgi, as I have said, had denied the existence of a network made up of anastomosing protoplasmic processes, but believed in a diffuse nerve reticulum composed of the united fibrils resulting from the complicated subdivisions of the axis cylinders of cells of Type II and the lateral fibrils of the axis cylinders of cells of Type I. The Spanish investigator emphatically denied

\* Ramón y Cajal, S. Estructura de la Rétina de las Aves. *Revista Trim. de Histología Normal*, etc., Nos. 1 y 2, Mayo y Agosto de 1888. Quoted by von Lenhossék.

† Sobre las Fibras Nerviosas de la Capa Molecular del Cerebello. *Revista Trim. de Hist.*, etc., Agosto, 1888. Quoted by von Lenhossék.

‡ I have references to no less than nine articles on the nervous system bearing his name, published during the year 1890 alone. It would occupy too much space to give here a complete list of his publications. An epitome of his views is to be found in *Les nouvelles idées sur la structure du système nerveux chez l'homme et chez les vertébrés*, French by Azoulay, Paris, 1894, and in the Croonian Lecture, *La fine structure des centres nerveux*, Proceedings of the Royal Society, London, vol. lv, 1894, pp. 444-468. This lecture was delivered in French and published in the same language. A brief but inaccurate abstract of it in English was printed in the *British Medical Journal*, 1894, i, p. 543.

the existence of any such diffuse nerve network. He maintained that in the cerebro-spinal nervous system the axis-cylinder processes and their lateral branches, belonging to

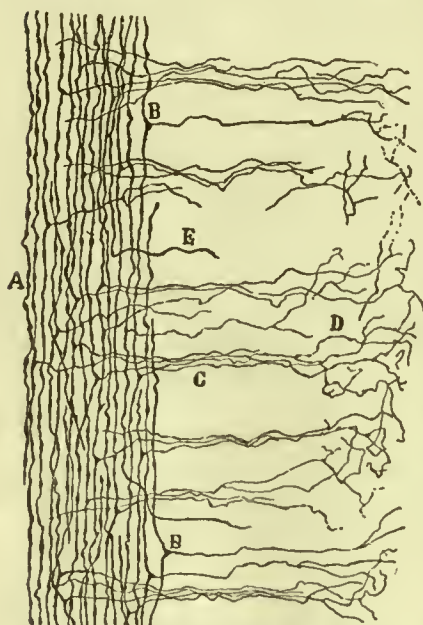


FIG. 8.—Longitudinal sagittal section of dorsal funiculus of the spinal cord of a cat fifteen days old. (Method of Golgi.) *A*, fibres of dorsal funiculi; *B*, collateral; *C*, group of collaterals running ventral-ward; *D*, end arborization of some collaterals in the gray matter of the dorsal horn; *E*, axis cylinder of a nerve cell. (After Ramón y Cajal.)

no matter what nerve cell, always run out to end free within the gray matter.\* They often enter into close proximity to other nerve cells and interlace with their protoplasmic processes, but nowhere could any evidence, by means of the method he employed, be found of actual union—the interrelations of the nerve elements depending entirely upon contact or contiguity, not upon organic connection. This was proved, he believed, to be true not only of embryonic structures, but also of the tissues of the adult, so that the neuropile of His and the contact principle of Forel met with full confirmation in the researches of Ramón y Cajal.

The side fibrils discovered by Golgi upon some of the axis-cylinder processes were made by Ramón y Cajal an object of special study. Particularly fortunate in this regard was his application of the silver staining to the embryonic cord.† He found that in embryo chicks after the fifth day of incubation it was easy to stain many of the axis cylinders of the white fasciculi, but was astonished to find coming off from each

\* In his earlier publications Ramón y Cajal made certain reservations and spoke of possible exceptions, but later he denied all anastomosis between the processes of nerve cells, thus going too far, as will be seen later.

† Ramón y Cajal, S. Sur l'origine et les ramifications des fibres nerveuses de la moelle embryonnaire. *Anat. Anz.*, Jena (1890), Bd. v, pp. 85, 111.



fibre, with a slightly wedge-shaped origin at right angles or almost at right angles, a considerable number of fine collateral branches (Figs. 8 and 9). These collateral branches penetrated deeply into the gray matter of the cord and terminated in free end arborizations among the nerve cells and their protoplasmic processes. The fine nerve plexus, described in the bibliography as occurring about the ganglion cells, was attributed by Ramón y Cajal largely to the interlacing of great numbers of the fibrils constituting these end arborizations of the collaterals. Such

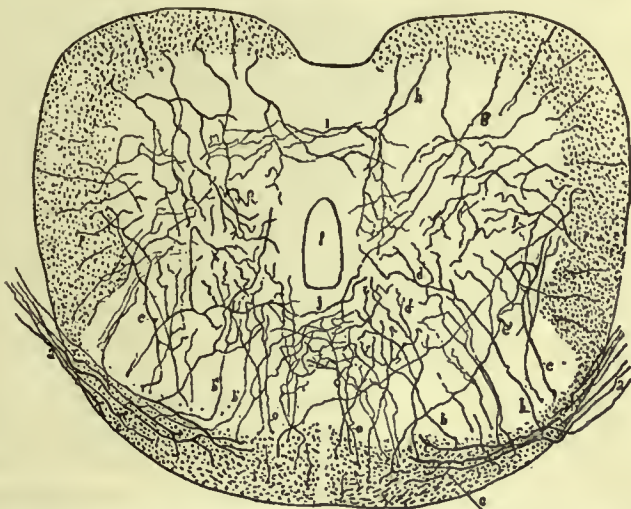


FIG. 9.—Transverse section of the spinal cord of a chick at the ninth day of incubation. (Method of Golgi.) *a*, fibres of dorsal root; *b*, collaterals from the dorsal root fibres; *c*, collaterals from the ventral funiculi; *d*, end arborizations of collaterals; *e*, collaterals going to form the dorsal commissure. (After Ramón y Cajal.)

collateral branches occur in all the white fasciculi, and further, they show a tolerably constant disposition in all regions of the vertebrate spinal cord.\* On the ventral root fibres of

\* As to the nature of the collaterals, Ramón y Cajal says (*op. cit.*, p. 90): "Que représentent ces fibrilles collatérales que nous venons de mentionner? À notre avis, il s'agit probablement de fibres de connexion cellulaire que tous les tubes de la substance blanche envoient à la grise à fin de mettre en contact réciproque des corpuscles nerveux placés relativement à de grandes distances. L'absence de myéline au niveau des contacts (corps des cellules et arborisations des collatérales) faciliterait particulièrement la communication de l'ébranlement nerveux."



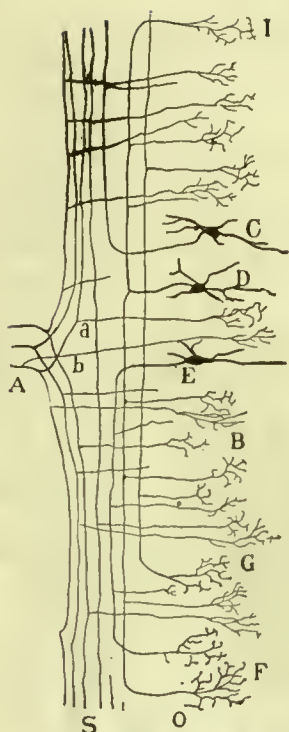


FIG. 10.—Schematic representation of section of dorsal funiculus cut longitudinally parallel to entrance of dorsal roots. (After Ramón y Cajal.) A, dorsal root; S, white substance; O, gray substance; C, cell of gray matter sending its axis-cylinder process upward in dorsal funiculus; D, another cell sending an axis cylinder into the white matter; this process bifurcates, yielding an ascending and a descending fibre; E, another cell sending an axis cylinder downward in the dorsal funiculus; I, F, and G, terminal arborizations of axis-cylinder processes; B, terminal arborizations in the gray matter of collaterals from the white substance; a, collateral from one of the divisions of a dorsal root fibre; b, collateral from the main trunk of a dorsal root fibre before its Y-shaped division.

the chick and the calf he could find no collaterals, but concerning the fibres of the dorsal roots the most interesting relations came to light. In preparations of the cord and dorsal roots of chicks from the seventh to the twelfth day of incubation he showed that the fibre representing the central process of a cell in the spinal ganglion runs through the dorsal root as far as the surface of the cord, into the substance of which it penetrates obliquely. Inside the cord\* the axis cylinder undergoes a distinct Y-shaped division into two strong terminal branches, one ascending, the other descending, both soon assuming a longitudinal direction, evidently constituents of the dorsal fasciculi of the cord. Fine collateral branchings could be seen coming off not only from the main axis cylinder, but also from its two branches of division at different levels on their way up or down the cord (Fig. 10). These passed forward through or medial to the substantia gelatinosa of Rolando to end, some among the cells of the dorsal horns, many of them among the cells of the ventral horn. As to the ultimate fate of the ascending and descending fibres resulting from the Y-shaped

\* Ramón y Cajal (*Anat. Anz.*, 1890, Bd. v, p. 92) says, "Dans l'épaisseur de la région du cordon de Goll." This should probably read "cordon de Burdach."

division, Ramón y Cajal could not at the time make any definite statement.\*

The great numbers of medullated fibres passing more or less in bundles from the dorsal fasciculi into the gray substance had been generally recognized and could not indeed have very well been overlooked, so prominent a part of the picture do they form in sections of the medullated spinal cord stained by Weigert's method (*vide* Fig. 11). The observers thought them to be (1) medullated axis cylinders passing from the cells of

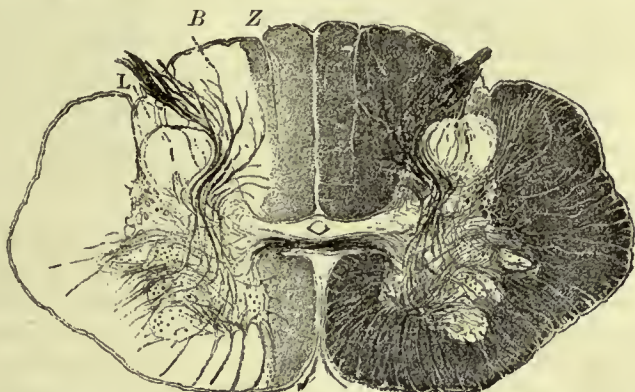


FIG. 11.—Cross section of the cervical spinal cord of a child two years old, showing medullated collaterals passing in from the dorsal fasciculi and running forward toward the ventral horns. (After von Kölliker.) Z, fasciculus gracilis (Goll); B, fasciculus cuneatus (Burdaehi); L, fasciculus of Lissauer.

the gray matter into the white fasciculi, and (2) fibres of the dorsal roots or of the dorsal white fasciculi turning in to terminate in the gray matter. Ramón y Cajal proved that the

---

\* Through a combination of the results attained by Golgi's method, by the methods of secondary degeneration and Flechsig's embryological method, we have now tolerably accurate ideas as to the course and destination of the fibres of the dorsal white fasciculi of the cord, their relations to the gray matter of the medulla spinalis and that of the medulla oblongata. Von Lenhossék has made an extremely careful study of the various groups of collaterals pertaining to these fibres, and has given us in a monograph (*Der feinere Bau des Nervensystems im Lichte neuester Forschungen, zweite Auflage*, Berlin, 1895) a most interesting and reliable *résumé* of the facts at present known about the finer anatomy of the cord, including the results of his own brilliant researches upon the spinal cord of human beings. Ramón y Cajal's treatise (*L'anatomie fine de la moelle épinière; Livraison iv of Babes' Atlas der path. Histologie des Nervensystems*, Berlin, 1895) may also be consulted in this connection.

majority of these do not represent main axis cylinders at all, but are collateral branches, a finding which has been confirmed over and over again by subsequent investigators in all countries.\* They represent structures of enormous importance, a large portion of them (*Reflexcollateralen* of Kölliker) representing the most direct path of nerve communication between the sensory surfaces of the body and the ventral horn cells governing the voluntary muscles. We find in the sensory fibres, with their subdivisions and collaterals given off at different levels of the cord and medulla,† the anatomical mechanism concerned in the simple and more complex reflexes, and probably in many of the instinctive reactions, and we have further, as His says, not far to go to find the explanation of the well-known fact that the same sensory impulses which permit consciousness to be affected also account for the setting free of reflexes.

Amid manifold variations in type, Golgi had been struck with the wonderful similarity of the nerve cells throughout the whole of the central nervous system. He had even, it will be remembered, attempted to reduce all nerve cells to the two types before mentioned, and from his studies regarding the mode of distribution of cells of these types he had concluded that the first type of nerve cells belonged to the motor or psycho-motor, the second type to the sensory or psycho-sensory regions.‡ With the advent of Forel's critique and of Ramón y

---

\* Some of the fibres of the dorsal roots certainly enter the gray matter before undergoing the Y-shaped division; some medullated fibres pass from the gray matter backward (centrifugal fibres of dorsal roots in the lower vertebrates, and fibres of dorsal fasciculi whose cells of origin are situated within the gray matter of the cord).

† It was Kölliker who showed that the sensory cerebral nerves undergo Y-shaped division in almost exactly the same manner as do the sensory spinal nerves.

‡ Golgi, in his article entitled *Anatomical Considerations regarding the Doctrine of Cerebral Localization*, in 1882 detailed the results of his studies on the cortex, from which he concluded that the cells of Type I and Type II were not separated from one another in the single convolutions, but were always associated with one another in all parts of the cortex, and that accordingly there were not only evidences against the strict separation of the two main functions, movement and sensation, but also positive grounds for the assertion that in the different cortical zones there was no absolute separation of the sensory and motor functions, and that the anatomical seats of these functions must to a certain degree be intermingled. It is surprising

Cajal's demonstrations the distinctions between these two types lost, in the main, the significance which had been attached to them. The only essential difference between cell Type I and cell Type II was shown to lie in the length and mode of branching of the axis cylinder. Whereas that of the first type first

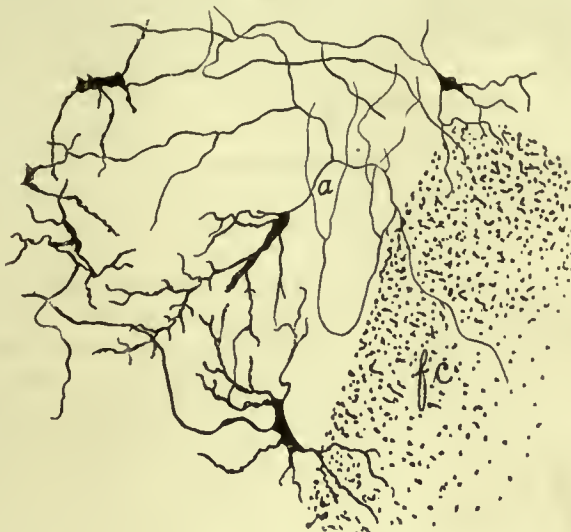


FIG. 12.—Cell from the gray matter of the spinal cord representing a form intermediate between that of Golgi's cell Type I and that of Golgi's cell Type II. (After von Lenhossék.) The much-branched axis-cylinder process *a* can be followed into the fasciculus cuneatus of Burdach, *f. c.*

showed an end arborization at a considerable distance from the cell, that of the second type broke up almost immediately after leaving its cell of origin into its terminal filaments. While a cell of Type I, through its long axis-cylinder process going directly over into a nerve fibre, is put into position to affect other cells in widely distant domains,\* the cells of Type II, the axis-cylinder processes of which rarely, if ever, leave the gray matter, are destined to influence other cells in the immediate neighborhood. These latter in all probability do not always act as servants of main conduction, but are to be looked upon

---

how near—even with false premises—an approach to actual relations can be arrived at!

\* The axis cylinders of some of the pyramidal cells of the cerebral cortex attain a length of nearly one metre.



as having a definite local function, probably of no mean significance.\* They occur in motor as well as in sensory areas, and there is no ground at all for attributing to them, as Golgi did, an exclusively sensory function. Further evidence has recently been forthcoming in that transitional forms between the cells of Type I and those of Type II, the hypothetical existence of which von Monakow postulated, have actually been described. Von Kölliker and von Lenhossék, for example, have described cells in the spinal cord (Fig. 12) with axis cylinders which, in addition to manifold branching, give off one main stem which acts quite like the axis-cylinder process of a cell of Type I, and recently von Bechterew† has referred to similar forms among the stellate cells of the molecular layer of the cerebellum (Fig. 13).

It has become obvious, therefore, from the striking general morphological agreement, that if we are to seek for data regarding the functional characteristics of nerve cells, we must look for them elsewhere than simply in the external form relations which they manifest; even the direction assumed by an axis-cylinder process does not always permit a decision as to the motor or sensory function of the cell to which it belongs. While perhaps the majority of sensory axones in the central nervous system run upward and of motor axones downward, there are plenty of exceptions to this, among them the descending limbs of the bifurcated fibres of the dorsal roots.

Ramón y Cajal's application of the Golgi staining, almost of the nature of a rediscovery, attracted the most widespread attention, and anatomists everywhere, casting other problems temporarily aside, set to work with the silver stain. In Ger-

---

\* These cells have been designated *Schaltzellen* by von Monakow, *intermediate cells* by Schäfer, *Vereinigungszellen* by von Bechterew. The term *association cells* has also been applied to them. The name *Dendraxonen*, applied by von Lenhossék, seems to me most suitable as distinguishing them from cells of Type I or *Inaxonen*. Schäfer's name *projection cell* for the cell of Type I may easily lead to confusion, and I think is better avoided. Von Monakow (Arch. f. Psychiat. u. Nervenkr., Bd. xx, 1889, S. 781) seems to have been the first to recognize the significance of Golgi's cells of Type II as *Schaltzellen*.

† Von Bechterew, W. Die Lehre von den Neuronen und die Entladungstheorie. Neurol. Centralbl., Leipzig, Bd. xv, 1896, S. 50; 103.



many, von Kölliker,\* von Lenhossék, Waldeyer, and Edinger; in Belgium, van Gehuchten; in Sweden, Retzius; in England, Schäfer and Andriezen; in America, Berkley and Strong, to say nothing of a whole host of other investigators in this and other countries, went busily to work with the osmo-bichromate mixture and silver nitrate, and within a surprisingly short period we have been supplied with information regarding the

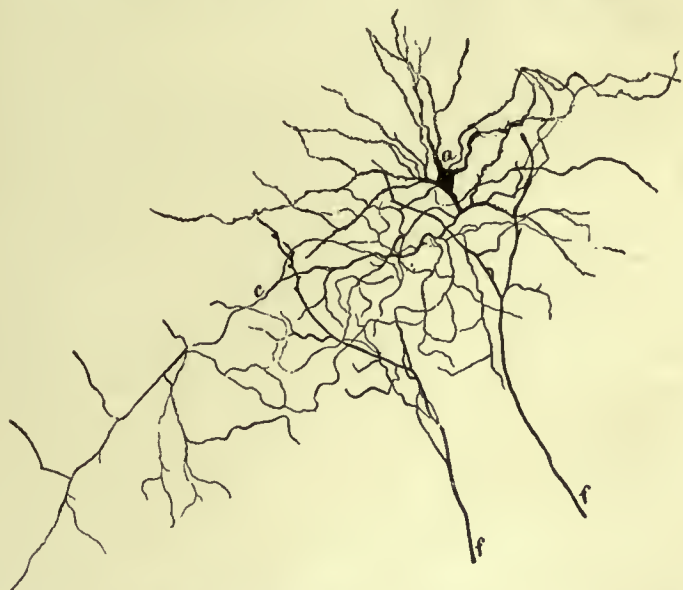

FIG. 13.—A transitional form, *a*, between Golgi's cell of Type I and cell of Type II from the molecular layer of the cerebellum. (After von Beehterew.) The much-branched axis-cylinder process *c* retains its identity for a considerable distance from the cell body. The fibres *f, f*, are axis-cylinder processes of other neurones which are giving off branches in the neighborhood of the cell *a* and its protoplasmic processes.

form and local reciprocal relations of the nerve units in the most various portions of the cerebro-spinal and sympathetic nervous system. The views advanced by Golgi and Ramón y

---

\* Von Kölliker visited Golgi in 1887, and called attention in that year to the great significance of the Italian's observations (cf. *Die Untersuchungen von Golgi über den feineren Bau des centralen Nervensystems*. Anat. Anz., Jena, Bd. ii (1887), No. 15, S. 480). From this time on he has busied himself extensively with the silver method, and has made contributions of very high importance for the development of the neurone concept of the nervous organs.

Cajal have been most thoroughly sifted, have undergone manifold confirmation and certain necessary corrections, until at present we are in a position to form a concept of the organization of the nervous system, clearer, sharper, simpler, and more pleasing than could have been even imagined by the most fanciful dreamer of two decades ago.

## CHAPTER IV.

### THE VITAL STAINING OF THE NERVE ELEMENTS.

The method of vital staining introduced by Ehrlich—The results afforded by it.

SATISFACTORY and convincing as were these results with the silver method obtained by all who tried for them, the new ideas received important support, indeed, were in part established, through another method invented by one who fairly deserves the name of "chemical magician"—Ehrlich, of Berlin. To have worked out from a chemical basis and laboratory experiment a method for the differential color analysis of the leucocytes which has revolutionized our ideas of the blood and elevated hæmatology almost to a special branch of medical science; to have inaugurated with experiments with ricin and abrin a new era in investigations on immunity and antitoxine therapy; to have illustrated by the methods of staining living nerve cells and their processes with methylene blue the possibilities of an experimental pharmacology of which we could scarcely have dared hope, would surely have been enough in days less liberal than ours to have convicted their author of witchcraft and of being a menace to the common weal. Ehrlich realized that the ordinary histological methods of fixing and subsequent staining, though yielding important anatomical conclusions regarding the structure of the tissues, fail to give us very exact information regarding the properties of the living cells. Concerning pharmacology, it is his idea that a definite toxic substance can affect only those elements primarily to which it actually arrives and by which it is taken up in a specific manner. If such be the case, the determination of the laws governing the distribution of the substance are of prime importance, and the physiological action of the drug should be brought into accord with these.\* On account of our poverty in micro-

---

\* Ehrlich, P. Ueber die Methylenblaureaction der lebenden Nervensubstanz. Deutsche med. Wchnschr., Berl., 1886, Bd. xii, S. 49-52.

chemical reactions it was impossible for him at the time to experiment satisfactorily in this way with the alkaloids, but with certain aniline dyes the problem could more easily be approached. Experimenting along these lines, Ehrlich found that by injection *intra vitam* of a solution of methylene blue dissolved in salt solution into the blood-vessels of an animal, the axis cylinders of many of the nerve fibres (Fig. 14) as well



FIG. 14.—Nerve fibres from a frog injected with methylene blue. (Method of Ehrlich.) The axis cylinders are stained dark blue. In places the myelin sheath is somewhat stained. The nodes of Ranvier and the divisions of the fibres at some of the nodes are well shown. (After von Kölliker.)

as numerous (particularly sensory) nerve endings (Fig. 15) were stained after a time, when the animal was killed and the tissues exposed to the air, of an intense blue color, the other tissue elements remaining little or not at all affected. The staining was of only short duration, the color gradually fading, and with



the fading, as a rule, more or less diffuse staining of the other tissues occurred.

Ehrlich made some interesting comparative tests with dyes closely allied to methylene blue in order to obtain if possible a chemical explanation of the staining. Thus, he found that while fuchsin, methyl violet, and saffranin, which contain no sulphur, would not stain the nerves, thionin and dimethylthionin as well as methylene violet yielded a reaction similar to that obtained with methylene blue, so that the presence of one basic group (of one ammonium residue) in the molecule (instead of two, as in methylene blue) appeared to suffice for the reaction. He further experimented with the expensive sulphon of methylene blue (*Methylenazur*) and found that he could obtain with it the nerve staining, so that it appears to be a matter of indifference whether the sulphur in the molecule exists as a phenylsulphide or as a phenylsulphon. Finally, he made tests with Bindschiedler's green (*Dimethylphenylengrün*), which differs from methylene blue only in lacking sulphur. This substance, which is distinctly poisonous, will not stain the nerves, so that Ehrlich concludes that it is the entrance of sulphur into the molecule which determines the nerve coloring, although he reserves his judgment as to the exact rôle played by this element. The conditions in the nerve structures essential to the methylene-blue reaction he thought were (1) oxygen-saturation; (2) alkalinity. Whether or not he still holds to these ideas expressed in 1886, I am unable to say.

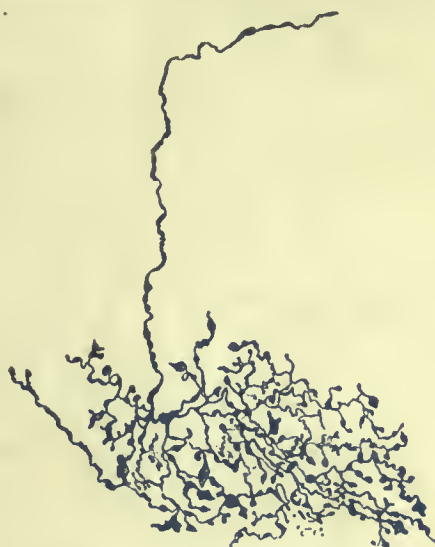

FIG. 15.—Sensory nerve ending stained with methylene blue (method of Ehrlich) in the exocardium of the left auricle of a gray rat. (After Smirnow.)

It was soon demonstrated by Arnstein that injection *intravitam* was unnecessary for the reaction, he having shown that as long as the tissues remained alive injection into the dead

animal gave results equally good. Mayer asserts that even several days after death the reaction is sometimes obtainable, and combats the idea of a "vital" staining. Certain it is that sections of tissue cut with a Valentin's knife soon after removal from the body and laid in a weak solution of the dye, stain beautifully. This fact I can assert from my own experience with human as well as with animal tissues.

One serious objection to the methylene-blue method was the transiency of the staining. Attempts were made to overcome this, Pal using iodide of potassium, Smirnow iodine and iodide of potassium, Dogiel an aqueous solution of ammonium pierate, Mayer and Retzius ammonium pierate and glycerin as a fixing agent, but no one of these methods was entirely satisfactory,\* and the preparation of thin sections of the stained and imperfectly fixed tissues remained an impossibility. Through the fortunate introduction of a fixing agent, which we owe to Bethe,† this difficulty has been almost entirely overcome, and

\* A very good epitome of the work done with the method up to 1891 is to be found in the collective review by H. Riese in the *Centralbl. f. allg. Path. u. path. Anat.*, Jena, Bd. ii (1891), S. 836-848.

† Bethe, A. Studien über das Centralnervensystem von *Carcinus Menas* nebst Angaben über ein neues Verfahren der Methylenblaufixation. *Arch. f. mikr. Anat.*, Bonn, 1894-'5, Bd. xlv, S. 579-622.

The method depends upon converting the soluble methylene-blue hydrochloride used in staining into an insoluble molybdate combination. For vertebrate tissues the following mixture may be recommended:

Ammonium molybdate.....	1 grm.;
Distilled water.....	10 c. c.;
Hydrogen peroxide.....	1 c. c.;
Hydrochloric acid, C. P.....	1 gtt.

For invertebrate tissues the following is employed:

Ammonium molybdate.....	1 grm.;
Distilled water.....	10 c. c.;
Hydrogen peroxide.....	0.5 c. c.

The solutions should in each instance be freshly prepared. The tissues should be immersed in the fluid (well cooled) at the acme of the staining, and kept in the ice box for from two to five hours. They are then left at the room temperature for a few hours, washed for half an hour in distilled water, dehydrated quickly in cold alcohol, and imbedded by means of repeated xylol clearing (to remove all alcohol) in balsam. After-staining with alum-cochineal is often helpful for contrast. In a more recent article, entitled *Eine neue Methode der Methylenblaufixation*, *Anat. Anz.*, Jena, Bd. xii, 1896, S. 438-446, Bethe has suggested further modifications of the method, useful for various special tissues.

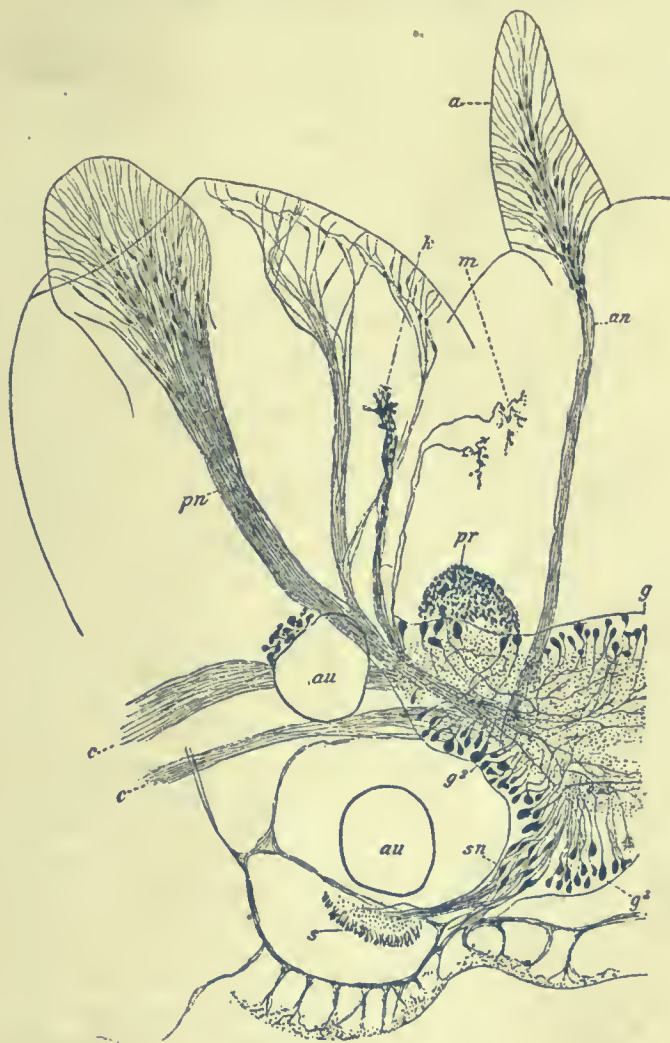

FIG. 16.—Left half of brain ganglion of *Nereis diversicolor* with the nerves connected with it seen from the dorsal surface. Methylene-blue staining, fixation by Bethe's method. (After G. Retzius, 1896, taken from Rauber's *Anatomie des Menschen*, 5. Aufl., Bd. ii, S. 856.) *g*, anterior group of ganglion cells; *g*<sup>2</sup>, lateral group of ganglion cells; *g*<sup>3</sup>, posterior group of ganglion cells; *sn*, bipolar cells of sensory type, the peripheral processes of which go to a spot in the skin (*s*), to end there; *pr*, anterior aggregation of coarse granules; *an*, antenna-nerve fibres; *a*, antenna; *m*, dendritically branched nerve fibre (muscular nerve); *k*, nerve branches, branching of coarsely granular fibres; *pn*, nerves to palp; *c*, commissural branches of neural cord going to subesophageal ganglion; *au*, pigmented eyes.

it is now possible not only to fix beautifully the structures at the height of the staining, Fig. 16, but also to imbed the tissues thus fixed in paraffin, which permits of the preparation of sections of any desired thinness and so to counter-staining by means of suitable dyes, for example, alum-cochineal.\*

I have laid some stress upon the introduction of the methylene-blue method, but not more, perhaps, than its importance warrants. As von Lenhossék has said, until the introduction of the Golgi stain, no one probably had seen a nerve cell with all its processes—a complete nerve unit in its totality. But even with the Golgi stain not every element impregnated can be followed throughout its whole extent. Indeed, it is perhaps the rule that where the medullary sheath begins the silver impregnation of the axis-cylinder process ceases. The staining of nerve endings in adult structures with the Golgi method, even with double and triple impregnations, succeeds only rarely. But just here lies the great value of Ehrlich's method. With a little care and a good sample of methylene blue the nerve endings and the axis cylinders of medullated fibres, with which they are continuous, can be stained in a way far surpassing in constancy and completeness the best results of the uncertain gold chloride procedure. Already most important contributions have been made with this method by Ehrlich, Dogiel, Retzius, Smirnow, Ramón y Cajal, von Lenhossék, Symonowicz, Huber, Bethe, and others, and it may safely be predicted that with the recent improvements it will be much more widely and successfully applied. That the method is also applicable to the study of pathological tissues removed by operation from human beings has been shown by

---

\* With Lavdowsky's modification of Ehrlich's method, together with Bethe's fixing procedure, I have been able to demonstrate nerve endings in human and animal tissues in a manner entirely superseding any other method known to me. The comparison of the gradual appearance of structure after structure and of detail after detail in the tissue during the staining to the development of a photographic negative, an illustration employed by Lavdowsky, is very apt. If the stain be pushed too far the picture becomes clouded, owing to diffuse staining of the other tissues with the blue—it has been "overdeveloped." The methods of vital injection of methylene blue used at Wood's Holl, Mass., have been described by Morill, A. D., *Amer. Naturalist*, vol. xxx, 1896, pp. 857-859. Huber has described the methods he employs in the *Journal of Applied Microscopy*, Rochester, vol. i, 1898, pp. 64-67.



the researches of Young, in which by means of it he has been able to demonstrate the presence of nerves in certain tumors.\*

The results hitherto attained with Ehrlich's methods have confirmed and elaborated those of the Golgi methods, except, perhaps, in one particular. Some observers, notably Dogiel, the distinguished Russian histologist, have maintained that in the methylene-blue specimens an anastomosis of the protoplasmic processes of one and of neighboring nerve cells can be demonstrated. Indeed, if his illustrations represent the actual conditions, it becomes necessary to somewhat modify the ideas regarding the relations of nerve cells founded on observations made with Golgi's method, for he has pictured not only the anastomosis in the retina of the dendrites of the nerve cells, but also a network formed by the union of axis-cylinder processes as well as the origin of nerve fibres from axis-cylinder networks and from networks of dendrites. Masius† also maintains that the dendritic processes anastomose with one another. This view, at first thought apparently inimical to the doctrine of the morphological and physiological independence of the nerve units, has been stoutly denied by Ramón y Cajal, von Lenhossék, and others, who have studied specimens stained both with Golgi's and Ehrlich's method, and it has been subjected to an especial searching criticism recently by Bouin. He denies the existence of anastomoses among the retinal elements, except the branchings of the cells which possess no axis-cylinder processes. I have myself, in a considerable experience with specimens stained by the methylene-blue method, been convinced that many of the appearances which closely resemble anastomosis, especially in specimens stained in bulk or in small pieces and fixed by Dogiel's method, are really optical illusions, since after long and tedious search with oil-immersion lenses in paraffin sections of methylene-blue preparations, fixed by Bethé's method, I have seldom been able to find any evidence of definite anastomosis. That anastomoses actually do occasionally occur can not, however, be longer

---

\* Young, H. H. On the Presence of Nerves in Tumors and of other Structures in them as Revealed by a Modification of Ehrlich's Method of "Vital Staining" with Methylene Blue. *Journal of Experimental Medicine*, N. Y., 1897, vol. ii, No. 1, pp. 1-12.

† Masius, Jean. *Recherches histologiques sur le système nerveux central*. *Arch. de biol.*, Gand, tome xii, 1892, pp. 151-167.

doubted; for not only have they been seen by investigators working with the methylene-blue method, but Tartuferi and others have found them in tissues impregnated by the chrome-silver procedure. The work of Bela Haller, Goepfert, and Edinger speaks also for the occurrence now and then of anastomoses even of a coarser sort between the processes of neighboring units. The much-used simile, however, that the processes (and their divisions) of nerve cells maintain, in the vast majority of instances, their identity throughout, interlacing perhaps with one another or with similar processes from other nerve cells, just as the branches of the trees in a dense forest may intermingle but remain independent of one another, the nerve elements being as separate and as independent as the trees and their branches and leaves, has apparently, *at least so far as embryonic tissues are concerned*, had its complete anatomical justification. Should occasional anastomoses between the processes of nerve cells be even proved to occur, or should it be true, as seems likely from the work of Held, Apáthy, and Bethe (*vide infra*), that in adult life reciprocal relations exist of a far more intimate sort than those that obtain in the embryo, the general validity of the doctrine of the individuality of the neurones would not be affected.

## CHAPTER V.

### THE TERM "NEURONE" AND THE NEURONE CONCEPTION.

Waldeyer's review, in 1891, of the newer investigations—The term *neurone* applied to the whole nerve unit—The neurone conception of the nervous system.

IN 1891 Waldeyer did great service to the new doctrine by bringing together within a brief compass and in a clear and convincing manner the results up to that time attained, comparing the experiments of the different investigators with one another and submitting all to his keen and critical judgment. His article\* perhaps has done more than any other single publication to make generally popular the doctrine of the individuality of the nerve elements for other reasons, but more especially from the fact that—and this is a point upon which von Lenhossék lays emphasis—besides his clear presentation of the established discoveries he introduced a term for the histological unit in the nervous system (including the whole element—cell body, protoplasmic processes, axis-cylinder processes, end arborization, and collaterals), dubbing it euphoni-ously in German *Neurón* (Greek,  $\delta$  νευρών; English, *neurōne*), a term which has been almost universally adopted by anatomists, physiologists, pathologists, and clinicians in various countries. Objections to the use of the word neurone as a designation for the nerve unit have been offered by Kölliker, Schäfer, and others. It is, however, so much more convenient a term than any other which has so far been suggested, and, moreover, has already entered so thoroughly into common usage, permeating the bibliography of all specialties, that I think it must be accepted; if so, the use of the term "neuron" as a name for the axis-cylinder process, as advocated by Schäfer in his admirable essay *The Nerve Cell Considered as the Basis of Neurology*,† is to be deprecated, and more particularly because a

---

\* Waldeyer, W. *Op. cit.*

† Schäfer, E. A. *Brain*, Lond., vol. xvi, 1893, pp. 134-169.

few distinguished teachers have been induced to continue the use of the term in this way, thus leading at times to considerable confusion. Since the word "neuron" has been employed by Schäfer to mean the axis cylinder (axone or neurite) and by Wilder to indicate the central nervous axis, and since the origin of the one term is the Greek *νευρον* and the origin of that suggested by Waldeyer is the Greek *νευρών*, the desirability of spelling the latter in English "neurone," and of pronouncing it *neurône*, is all the more obvious.\* In the accompanying illustration (Fig. 17) a typical example of a lower motor neurone is shown in diagram. The cell body with all its processes, including that extending to the muscle fibres, makes up the total mass of one neurone.

Enough has been said, I hope, to make clear what is meant by the "neurone concept" of the nervous system. To sum it up in a few words: The nervous system, aside from its neuroglia, ependymal cells, blood-vessels, and lymphatics, consists of an enormous number of individual elements or neurones. Each neurone in its entirety represents a single body cell. These units are at first *entirely* (if protoplasmic bridges be excepted) and continue throughout life *relatively* to be mor-

---

\* Kölliker (Handbuch der Gewebelehre des Menschen, 1893, Bd. ii, S. 2) states his objection as follows: "Das Wort *Neurôn*, *Neuronen*, das gut klingt, kann sprachlich nicht gebraucht werden, wie vorgeschlagen wurde, denn es bedeutet einen Sammelpunkt vieler Neuren oder Nerven. Von den Worten Neurodendren und Neurodendridien ist das letztere, obschon länger, als Uebersetzung von Nervenbäumchen doch vielleicht entsprechender." The adoption, however, of the better sounding word is in this instance easily intelligible, and, moreover, is not without many a precedent, as the philologist must sorrowfully grant. In the present case, however, Professor B. L. Gildersleeve, of the Johns Hopkins University, informs me that Kölliker's objection to *νευρών* will not hold, as it would apply equally well to *παρθενών*, which means "the house of the virgin." While the spelling *neurone* is not pleasing, for that matter neither are the spellings *anode* and *cathode*, which, after the analogy of *method*, should be spelled *anod* and *cathod*, but, under the circumstances, in order to anglicize Waldeyer's term, the use of the word and spelling *neurone* seems, as Professor Gildersleeve says, to be inevitable. Cf. Barker, L. F. Concerning Neurological Nomenclature. Johns Hopkins Hospital Bulletin, Balt., 1896, vol. vii, p. 200. Frank Baker, of Washington (New York Medical Journal, vol. lxi (1896), p. 373; and in Proc. Ass. Am. Anat., 1895, Wash., 1896, vol. viii, pp. 40-45), has suggested the term *neure*, corresponding to Rauber's *neura*, for the nerve unit, a nomenclature which has received the support of C. S. Minot.



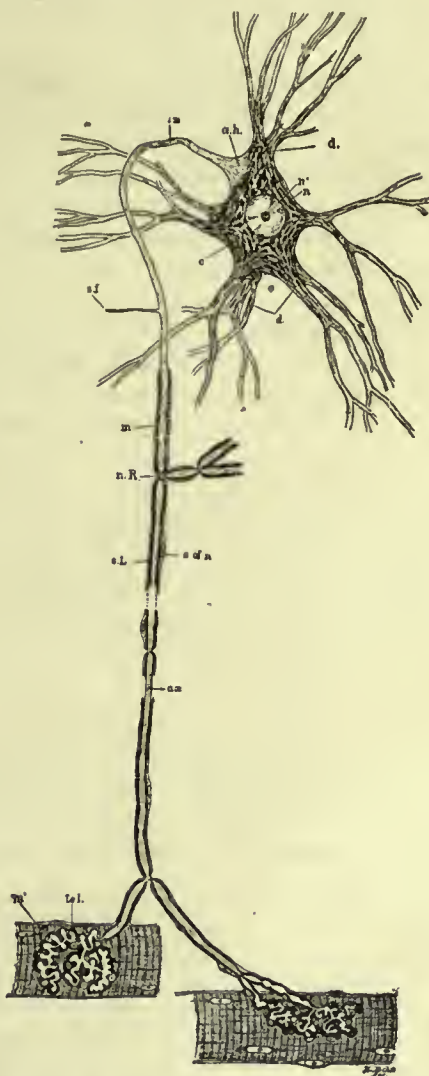


FIG. 17.—Scheme of lower motor neurone. The motor cell body, together with all its protoplasmic processes, its axis-cylinder process, side fibrils, or collaterals, and end ramifications, represent parts of a single cell or *neurone*. *a. h.*, axone-hillock devoid of Nissl bodies, and showing fibrillation; *ax.*, axis cylinder or axone. This process, near the cell body, becomes surrounded by myelin, *m.*, and a cellular sheath, the neurilemma, the latter not being an integral part of the neurone; *c.*, cytoplasm showing Nissl bodies and lighter ground substance; *d.*, protoplasmic processes (dendrites) containing Nissl bodies; *n.*, nucleus; *n'*, nucleolus; *n. R.*, node of Ranvier; *s. f.*, side fibril; *n. of n.*, nucleus of neurilemma sheath; *tel.*, motor end plate or telodendrion; *m'*, striped muscle fibre; *s. L.*, segmentation of Lantermann.

phologically, and in part, at least, physiologically, independent of one another.

There is no evidence of the existence of a diffuse nerve network either in the sense in which von Geirach or in that in which Golgi used the term, though should it be forthcoming, it would not, and Waldeyer stated this in his article, interfere with the neurone conception. The axis cylinder of every nerve fibre, just as much as every protoplasmic process, is an integral part of a neurone, and has an organic connection somewhere with a nerve cell. Nerve conduction paths may, and probably usually do, in higher animals at least, involve more than one neurone, the neurones being, as it were, superimposed upon one another to make simple or more complex neurone chains or chains of neurone groups, one individual neurone through its various processes being in a position to be affected by and in turn to affect several or many other neurones. Notwithstanding almost infinite minor variations in form, the neurones in the most different parts of the nervous system present surprisingly similar general external morphological characteristics. The nerve life of the individual, including all his reflex, instinctive, and volitional activities, is the sum total of the life of his milliard of neurones.\*

---

\* According to the estimations of Meynert, the cortex of the cerebral hemispheres alone contains twelve hundred millions of ganglion cells. Donaldson (*The Growth of the Brain, a Study of the Nervous System in Relation to Education*, 12mo, London, 1897, p. 159) states that for the total number of nerve cells in the central nervous system three thousand millions is a moderate estimate.

It may be recalled that C. Francke (*Die menschliche Zelle*, Leipz., 1891, p. 27) has estimated the total number of cells, leaving out the red blood-corpuscles, in an adult human body to be about four billions (3.996 billions). The most accurate estimates of the total number of red blood-corpuscles at our command make the number about twenty-two billions and a half, making a total of twenty-six billions and a half (26,500,000,000,000) of body cells. Donaldson's estimate for the nerve cells would, therefore, make them represent one nine-thousandth of the total number of cells, exclusive of the red blood-corpuscles, an estimate which probably falls below rather than above the truth. All such calculations are necessarily extremely crude, but afford opportunity for interesting study.

## CHAPTER VI.

### THE BEARING OF RESEARCHES SINCE 1891 UPON THE VALIDITY OF THE NEURONE DOCTRINE.

The reliability of the data upon which the neurone doctrine was founded—  
The cell doctrine—Confirmation of the work of His—Study of degenerations—Researches with the method of Marchi and with the method of Nissl—Anastomosis of dendrites—Studies of Held upon concrescence—Contributions of Apáthy.

It must now be asked (1) In how far, in the seven years which have elapsed since the neurone conception was distinctly formulated, choosing arbitrarily the article of Waldeyer as the date of this, have the data upon which it was based been found to be reliable? and (2) Can all the results of researches which have led to the discovery of new facts since that time be brought into accord with the neurone doctrine?\*

It has been seen from what has preceded that the foundation of the neurone doctrine is quadruple: (1) The *a priori* probability that the nervous system agrees with other parts of the body in being a cellular system; (2) the proof that in the embryo the nerve cells exist as independent units, many of which are capable of wandering for considerable distances from the site of their origin; (3) the fact that the nutrition of the nerve cells is most easily explicable from the standpoint of a doctrine which looks upon the nervous system as made up of units, which are not only anatomical but also physiological, since in pathological degenerative processes affecting a given unit or set of units, degeneration of a given type extends only

---

\* Cf. Barker, L. F. On the Validity of the Neurone Doctrine. Amer. J. Insan., Balt., 1898-'9, vol. lv, pp. 31-49. Three American reviews of the neurone doctrine may be referred to by the reader—one by A. O. J. Kelly, The Neuron. Univ. M. Mag., Phila., 1896-'7, vol. ix, pp. 276-293; the second by D. I. Wolfstein, The Histological Basis of the Neurone Theory, Cincin. Lancet-Clinic, n. s., vol. xxxix, 1897, pp. 565-579; the third by P. A. Fish, The Nerve Cell as a Unit. J. Comp. Neurol., Granville, 1898, vol. viii, pp. 99-112.

within the limits of that unit or set of units, any degeneration of other units being of an entirely different nature, and when resembling the former occurring much more slowly; and (4) the histological demonstration of the fact that, for reasons as yet too subtle for analysis, sometimes one unit, sometimes another, may be picked out by a particular method of staining or impregnation and brought exquisitely into view, others near by remaining only partially stained or entirely unaffected. In addition, the doctrine agrees well with all the known facts discovered by Edinger, Herriek, and others in the field of comparative anatomy.

Have these data been proved to be unreliable? With regard to the cell doctrine it may be said to be now universally held, although it is true that it does not explain all known facts, and that here and there a distinguished biologist draws attention to its "inadequacy."\* The embryological researches of His concerning the neuroblasts have been manifoldly confirmed by his own and by other methods. Not until we come to the studies of degeneration inside the nervous system do we find any appearance of discrepancy. The doctrines of von Gudden and von Monakow, on the whole, however, still hold. Lesion of a given set of neurones causes degeneration of the typical and generally recognized sort (that revealed by Weigert's method) only within the domains of that set. If large numbers of neurones belonging to a given system degenerate and are absorbed, there may be, it is true, after the lapse of a very long time, possibly total atrophy with absorption in neurones of another order (as probably occurred in the case reported by Flechsig and Hoesel, in which the corticopetal neurones of the general sensory path had been injured by a lesion involving the central gyri, and after many years many of the neurones, the axones of which go to make up the internal arcuate fibres of the medulla oblongata and the fibres of the lemniscus medialis, had entirely disappeared). But, as a rule, the tertiary change is one of shrinking and diminution of the calibre of the medullated fibres rather

---

\* Cf. Whitman, C. O. *The Inadequacy of the Cell Theory of Development*. Wood's Holl Biological Lectures, 1893; also in *J. Morphol.*, Bost., vol. viii, 1893, pp. 639-658; and Sedgwick, A., *On the Inadequacy of the Cellular Theory of Development, and on the Early Development of Nerves, particularly of the Third Nerve and of the Sympathetic in Elasmobranchii*. *Quart. J. Mier. Sc.*, Lond., vol. xxxvii, 1894-'5, pp. 87-101.



than complete disintegration and absorption (as the condition in which the brachium conjunctivum is ordinarily found after extensive disease of one cerebral hemisphere fully illustrates).

Since 1891 a vast deal of work upon degenerations has been done with two methods which are especially well adapted for yielding information, especially in tissues obtained too soon after the lesion to be of value for study by the method of Weigert.\* The first of these methods, that of Marchi, thus far speaks strongly in its results for the validity of the neurone doctrine. There is no evidence from its use that a degeneration following an injury extends beyond the limits of the neurone or neurones which the lesion involves. On the contrary, the method is mainly of value since it permits the following of a set of diseased fibres to their termination. By its aid the exact course and distribution of Gowers' tract as far as its ending in the cerebellar worm have been followed. This is only a single, although an important, example of its efficacy.

Investigators who have employed the second method, that of Nissl, and its various modifications have been extraordinarily active. The procedure is an extremely delicate one, and changes hitherto entirely unsuspected have been detected by it in various pathological conditions. Through it, in one respect at least, the neurone conception has been supported, for the method has demonstrated that, when any portion of an axone or its terminal ramifications is diseased, the whole neurone to which that axone belongs suffers, the changes which occur in the "stainable substance" or "tigroid" of the cell body and dendrites of a neurone after lesion to its axone being now generally recognized and appreciated. As Stirling of Manchester† emphasizes, the changes which occur after amputations also point to the individuality of the neurone unit. In another respect, however, the application of the method of Nissl has brought into view a phenomenon which at first glance appears to be opposed to the neurone conception. It has been found by Marinesco (though, curiously enough, he interpreted his observation differently), by Warrington,‡ and by van Gehuch-

---

\* The method of Marchi and that of Nissl, and the results to which they have led, will be referred to in more detail in subsequent chapters.

† Personal communication.

‡ Warrington, W. B. On the Structural Alterations observed in Nerve Cells. *J. Physiol., Lond. and Cambr.*, 1898, vol. viii, Nos. 1 and 2.

ten that in certain instances the cutting through of a cerebral sensory nerve between its ganglion and the central nervous system (or, in terms of the neurone conception, solution of continuity of the axones of sensory neurones of the first order) is followed by changes in the nucleus terminalis of the nerve quite like those which occur in the cells of the peripheral ganglion itself after section of the sensory nerve between the ganglion and the periphery of the body, or like those which follow in a motor nucleus upon section of the root fibres issuing from it. Highly interesting as the phenomenon is, and as yet insufficiently explained, it can hardly be said to in any way invalidate the neurone conception. The fact that an injury to one individual in a society leads to the detriment of certain other individuals with whom the former individual was most intimately associated, can not be considered as disproving the idea that the society is composed of individuals. And that, in the case of the neurones under consideration, the character of the injury in the peripheral and in the central neurone differ is obvious from the subsequent history of the two neurones in animals permitted to live for some time after the injury. In the one instance typical Wallerian degeneration with absorption quickly takes place, in the other there is at most slow secondary atrophy.

Histologically, there have been since 1891 repeated confirmations of the earlier single observations of coarse anastomoses of dendrites. In mammals the finding, except in the retina, is rare, though in lower forms, according to the recent observations of Bethe, Nussbaum, Schreiber, and Holmgren, it appears to be more common. I have myself seen it in the nervous system of rabbits, and have observed, what others have seen also—namely, the partial fusion of the cell bodies of two neurones. But these unusual conditions, even were they common, are surely of but little consequence when brought forward as arguments against the individuality and relative independence of the nerve units. If one thinks for a moment, the unreasonableness of the objection becomes obvious, for who would consider seriously the argument of an anthropologist who contended that the human race did not consist of separate units and individuals on the ground that cases of double malformations like the Siamese twins, the Janus-headed monsters, and the various instances of epignathi, thoracopagi, and *fœtus in fœtu* are known

to occur? Even if in the heart of Africa somewhere we should come to find that there existed a terrible and swift race such as Plato makes Aristophanes describe in the *Symposium*, we doubt very much if we should be willing to give up the general view that humanity is a mass of multiple units, though doubtless we should have to modify our conception as to the possibility of variety in the units, or admit a bond of union between them more intimate than that to which we are accustomed.

On the whole, however, it may be said with fairness that the control instituted by hundreds of histologists in various parts of the world has, practically, in every instance in which the method of Golgi or the method of Ehrlich has been employed, gone to confirm the conception that the neurone is a unit in the sense of Waldeyer.

Passing now to the last inquiry, let us examine the original contributions dating since 1891, and see if in them we can find any facts which necessarily nullify the validity of the neurone conception. In this connection only two researches present themselves which are likely to be brought forward by its antagonists. One of these is the investigation of Held concerning the kind of relation which exists between the terminal branches of an axone of one neurone and the cell bodies and dendrites of other neurones with which they are connected; the other is the much-talked-of research of Apáthy, emanating from the Zoölogical Station at Naples.

Held's\* communication is one of very great importance, representing, as it does, the most careful application of modern cytological technique to the study of the nerve cell and its processes. His findings concerning the tigroid and the ground substance of the protoplasm, brilliant as they are, do not concern us here. The observations of Held, however, which must here be taken into account are those in which he describes fusion of the terminals of the axone (including the end ramifications of the collaterals) of one neurone with the protoplasm of the dendrites and cell bodies of neurones of a higher order. Held agrees with other investigators that in embryonic tissues and in early youth the neurones are entirely independent of

---

\* Held. H., Beiträge zur Struktur der Nervenzellen und ihrer Fortsätze (zweite Abhandlung) Arch. f. Anat. u. Physiol., Anat. Abth., Leipz., 1897, S. 204-294.



one another (except for an occasional dendritic or other anastomosis). In these stages, which, by the way, correspond to those

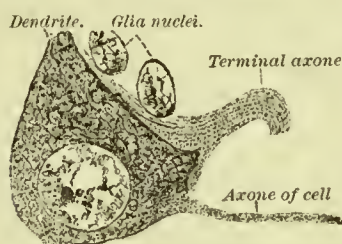


FIG. 18.—Cell from nucleus corporis trapezoidale of newborn cat. (After H. Held, Arch. f. Anat. u. Physiol., Anat. Abth. (1897), Taf. xii, Fig. 2.) Fixation with van Gehuchten's mixture; staining with iron-haematoxylin. The large axone is seen terminating upon the cell and exhibiting what Held calls conrescence relation. The small axone with its axone hillock is arising from the cell body shown in the figure.

of the majority of Golgi preparations, he finds, in areas especially well suited for the study (e. g., the nucleus of the trapezoid body), that when the terminal of an axone comes into contact relation with the cell body of another neurone one can always make out where the protoplasm of the one neurone ends and where that of the second begins, inasmuch as the line of demarcation is more refractive than the adjacent protoplasm (Fig. 18). Held finds, however, that this refractive limiting line is not demonstrable in the adult, and comes to the conclusion that during the process of growth the protoplasm of related neurones fuses.

Indeed, in some instances there is evidence that the termi-

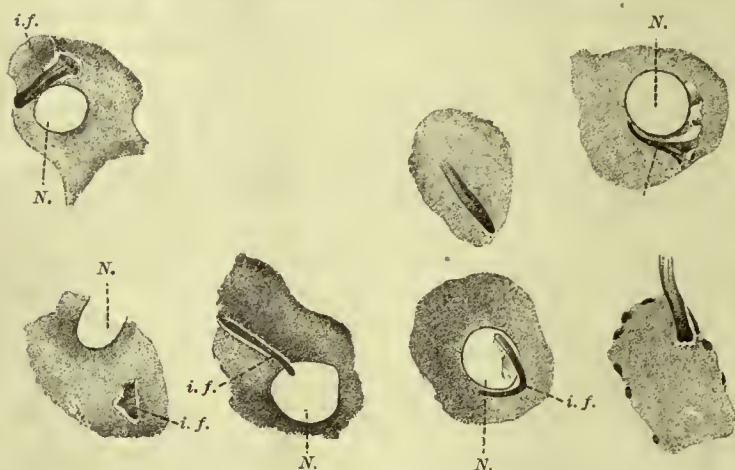


FIG. 19.—Cells from the nucleus corporis trapezoidale of the adult rabbit. (After H. Held, Arch. f. Anat. u. Physiol., Anat. Abth., Leipz., 1897, H. 3 u. 4, Taf. xii, Fig. 4.) Alcohol fixation; staining with iron-haematoxylin; different forms of intracellular fibres (*i. f.*) are shown. The fibre entering the cell in the lower right-hand corner of the figure is, according to Held, certainly an axis cylinder. N, nucleus.



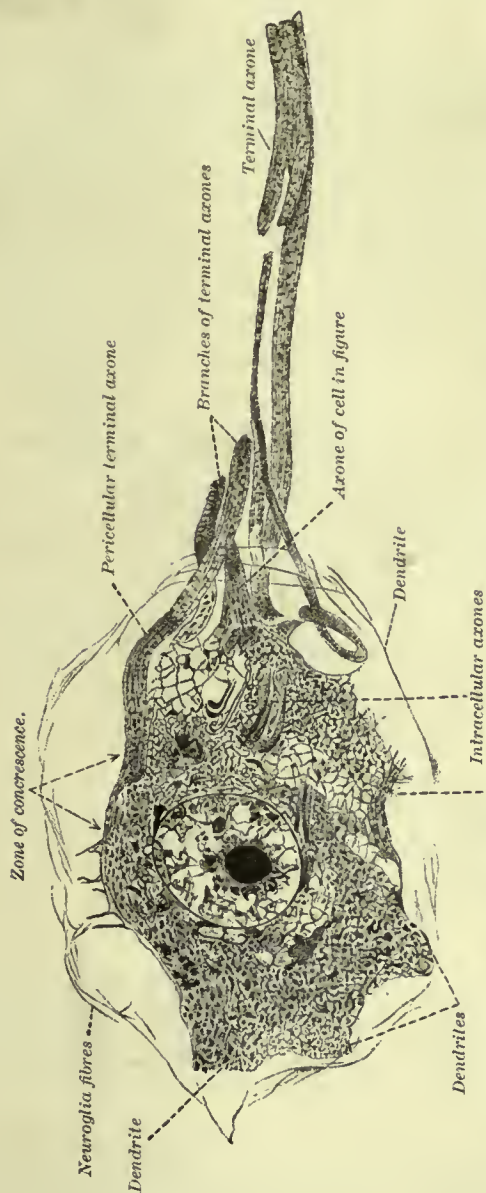


FIG. 20.—Cell from the nucleus corporis trapezoidi of an adult rabbit. Alcohol fixation; staining with iron-haematoxylin. (After Held, Arch. f. Anat. u. Physiol., Anat. Abth., 1897, Taf. xii, Fig. 7.) The axis cylinder arising from the cell body is shown as well as the terminals of many axones which appear to be fusing with the protoplasm on the surface of the cell or entering into its substance.

nals of one neurone plunge deep into the cell body of another neurone and even come into close proximity to the nucleus of the latter (Fig. 19). He describes the relation as one of "concrecence." Held's pictures are very convincing, and one must certainly admit that his work proves the existence of much more intimate relations among the neurones than the studies made with Golgi's method had led us to suspect (Fig. 20). And yet, in following Held's various articles closely, one finds that this histologist, notwithstanding the disappearance of the refractive line of demarcation, is able, *even in adult stages*, to distinguish the protoplasm which belongs to the terminal axone or collateral of the one neurone from the protoplasm of the cell body or dendrite of the other. By a lucky hit Held

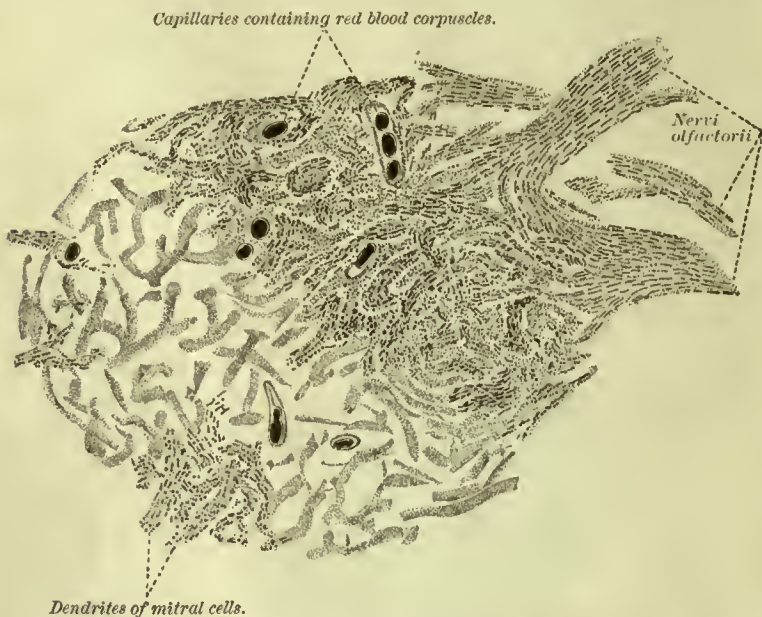


FIG. 21.—Glomerulus olfactorius from adult rabbit. (After H. Held, Arch. f. Anat. u. Physiol., Anat. Abth., Leipz., 1897, Taf. ix, Fig. 13.) Chrome-osmic fixation and staining by Altmann's method with acid fuchsin; slight differentiation. A distinct difference can be made out between the number of neurosomes in the beginnings of the dendrites of the mitral cells and the terminals of the nervi olfactorii. The middle part of the glomerulus has not been drawn.

seems to have discovered a method of staining certain minute particles (his neurosomes) in the ground substance of the protoplasm of the neurones—a method which stains them intensely

and leaves the other structures but dimly or not at all tinged. It would seem that, according to his report, the neurosomes are

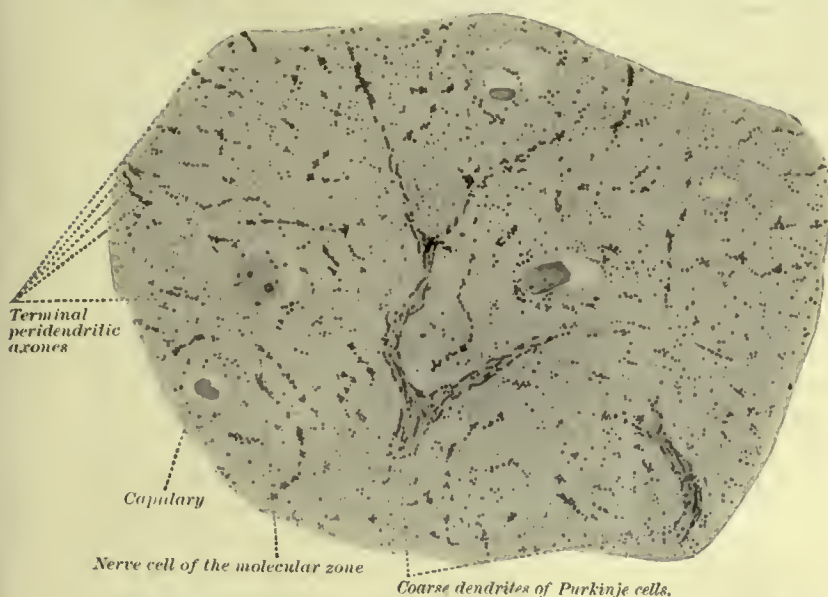


FIG. 22.—A portion of the molecular zone of the cerebellum of an adult rabbit. (After H. Held, *Arch. f. Anat. u. Physiol., Anat. Abth.*, Leipz., 1897, Suppl. Bd., Taf. xiii, Fig. 1.) Paraffin section 1.5 microns thick. Erythrosin-methylene-blue. The peridendritic branches of Ramón y Cajal's climbing fibres look like granular bands owing to the presence in them of large numbers of neurosomes.

far more closely aggregated in the axis cylinder, and especially in its terminal branches, than they are in the protoplasm of the cell body or of the dendrites of a neurone. Thus, in the olfactory glomeruli (Fig. 21) it is very easy to distinguish the axones of the nervi olfactorii from the dendrites of the mitral cells and of the brush cells, both of which, as is well known, enter into the formation of these curious bodies. Again, in the molecular layer of the cerebellar cortex, Held's neurosome method outlines accurately the position and relations of the terminals of the axones which climb trellislike along the trunks of the huge limbs of the cerebellar forest which is made up of the dendrites of the Purkinje cells (Fig. 22). Held's contributions, therefore, far from disproving it, are confirmatory of the neurone doctrine; and, as a matter of fact, Held represents one of the ablest of the German adherents of the doctrine.

Adverting finally to the investigations of Apáthy,\* one finds in them the greatest stumbling-block to those who, perhaps on account of lack of familiarity with the exact principles of the neurone doctrine and the history of its foundation, are inclined to think that it is jeopardized. A skilled technician, well known to the biological world as the author of a treatise on the technique of animal morphology, and generally recognized as a most careful and painstaking worker at the Naples Marine Laboratory, after several years of specially directed study, during which he has elaborated an entirely new mode of bringing certain finer structures within the nerve cells into view, has finally, in a long article of more than two hundred pages, presented the main results of his investigations upon the nervous tissues to the scientific world. While Apáthy has studied vertebrate tissues to a limited extent, the majority of his observations have been made upon invertebrates, especially upon the leech and the earthworm. His technical methods need not be entered into here. Suffice it to say that for the most part his technique is original with himself, consisting, in addition to a method of staining with methylene blue, of a hæmatin method, and an especially modified gold-chloride method which can be applied not only to fresh tissues but to fixed tissues as well. To sum up his views in a nutshell, Apáthy has been convinced for some twelve years that the nervous system is composed of two varieties of cellular elements entirely different from each other—"nerve cells" and "ganglion cells." The "nerve cells," the architecture of which is quite in accord with that of muscle cells, give rise, he thinks, to neuro-fibrils (Fig. 23). A neuro-fibril in turn passes out of a process of a "nerve cell" and then goes through a number of "ganglion cells," and ultimately, after leaving the last "ganglion cell," with which it is connected, passes more or less directly to a muscular fibre or to a sensory cell. The neuro-fibrils are (as conducting substance) for the "nerve cell" what the muscle fibrillæ are (as contractile substance) for the muscle cells. The pathways to be followed by the neuro-fibrils are predestined from the earliest embryonic stages, for they correspond, according to Apáthy, to the inter-cellular protoplasmic bridges.

---

\* Apáthy, S. Das leitende Element des Nervensystems und seine topographischen Beziehungen zu den Zellen. Mittheil. aus der zool. Station zu Neapel. Bd. xii (1897), H. 4, S. 495-748.



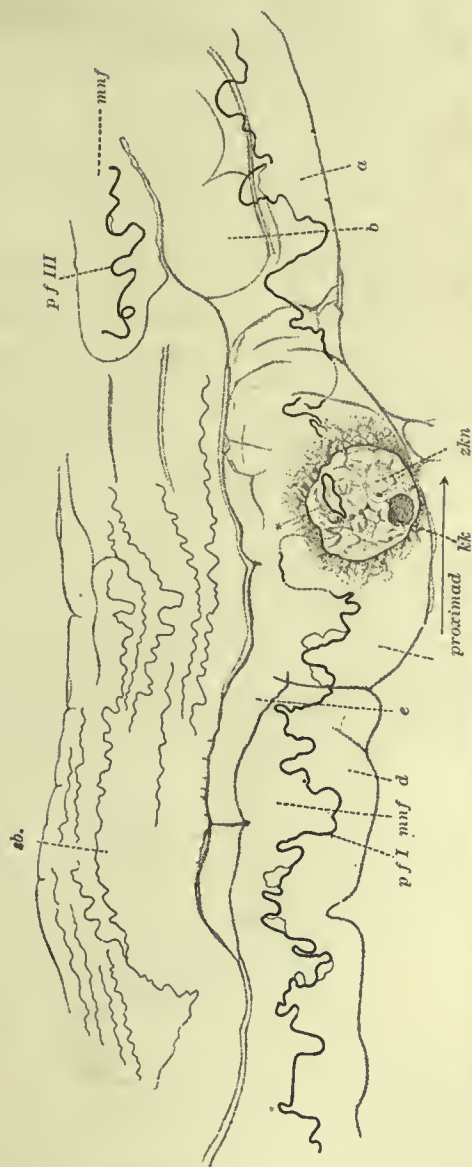


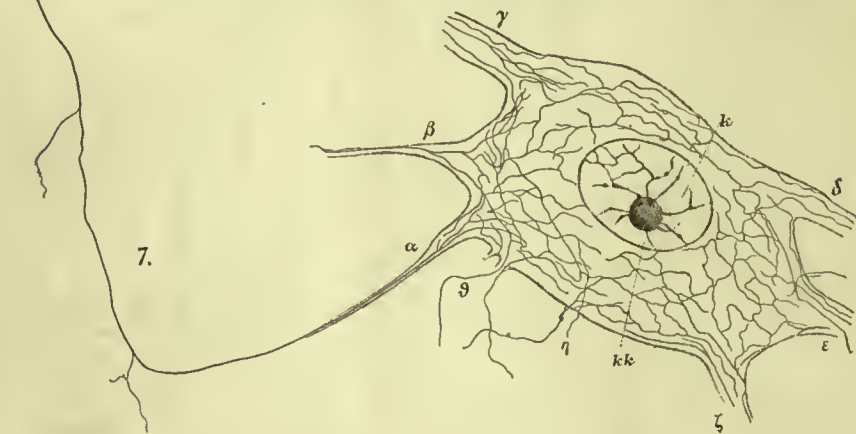
FIG. 23.—Motor-nerve spindle in longitudinal section of the right anterior nerve stem from the leech. (After S. Apáthy, Mith. aus der zool. St. zu Neapel, Bd. xii, 1897, H. 4, Taf. xxiv, Fig. 3.) The somatoplasm of the nerve cell is simply indicated around the cell nucleus *zkn*. Near this nerve spindle are seen some primitive fibrils in sensory bundles, *sb*; the contours of the motor nerve spindle correspond to a focus somewhat above the level of the nucleus; the branches of the motor nerve divide, *maf*, which are visible, are *a*, *b*, *d*, *e*. *pf I* represents the primitive fibril projected upon the surface of the drawing paper as far as it is contained in the section. The dotted points correspond to the place where it is not contained in the section. The asterisk indicates a division of the primitive fibril into two limbs.

Each neurofibril is, Apáthy states, made up of a large number—near its origin, at any rate—of “elementary fibrils,” and in the course which it follows elementary fibrillæ are being given off at short intervals, until finally the neuro-fibril itself may be reduced to a single elementary fibril. Apáthy as early as 1885 was able to follow the paths of single neuro-fibrils. Some of them grow toward the centre into the “ganglion cells” (Fig. 24), others toward the periphery into the sense cells (Fig. 25 and Fig. 26), or into muscle cells (Fig. 27) or blood capillaries.

The “ganglion cells” through which the neuro-fibrils pass, and which, if Apáthy is correct, supply the force which is to be conducted along them, appear to be complicated in structure.

Thus in the leech the body of the cell can be divided into a series of more or less concentric zones. At the periphery are two zones, an outer and an inner, consisting of neuroglia, which are more or less separated from the

FIG. 24.—Large pluripolar ganglion cell of the ventral paramedian field of the abdominal cord of lumbricus. (After S. Apáthy, Mitth. aus der zool. St. zu Neapel, Bd. xii, 1897, H. 4, Taf. xxvii, Fig. 7.) A primitive fibril, *spf* (?), is seen on its way to a ganglion cell becoming thinner, owing to the emission of the side fibrils. A very complicated intracellular reticulum of neuro-fibrils is to be made out in the formation of which the primitive fibrils of all the processes take part. *kk*, nucleolus; *k*, nucleus. *a* and *β* are processes containing one primitive fibril in each, which arriving in the cell body split up into several bifurcating neuro-fibrils. The primitive fibril in *a* can be followed for a very long distance, being thicker at a distance from the cell. The coarse longitudinal processes *γ* and *δ* contain a large number of primitive fibrils which, as far as they can be followed, do not unite to one fibril.



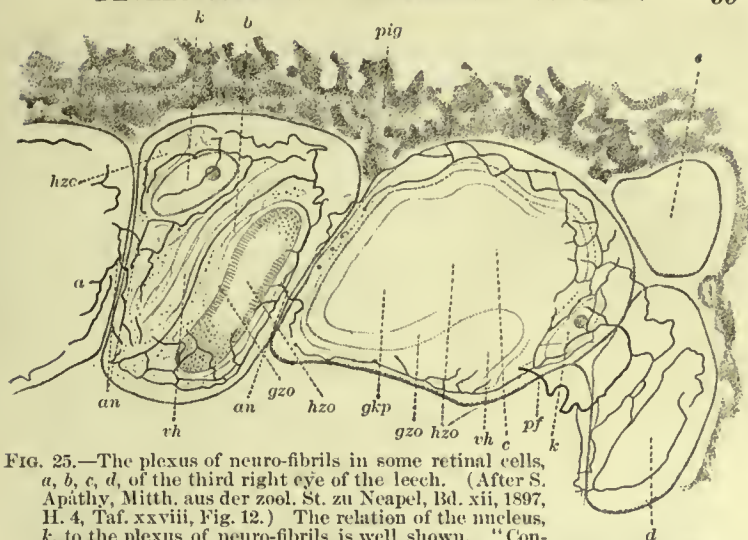


FIG. 25.—The plexus of neuro-fibrils in some retinal cells, *a, b, c, d*, of the third right eye of the leech. (After S. Apáthy, *Mitth. aus der zool. St. zu Neapel*, Bd. xii, 1897, H. 4, Taf. xxviii, Fig. 12.) The relation of the nucleus, *k*, to the plexus of neuro-fibrils is well shown. "Conducting" anastomoses visible between the cell *c* and *d*. *pf*, "conducting" primitive fibril; *an*, "conducting" anastomoses; *gzo*, radially striped zone of the vitreous of the retinal cells; *hzo*, clear zone of the vitreous of the retinal cells; *pig*, pigment; *vh*, projecting hillock of somatoplasm.

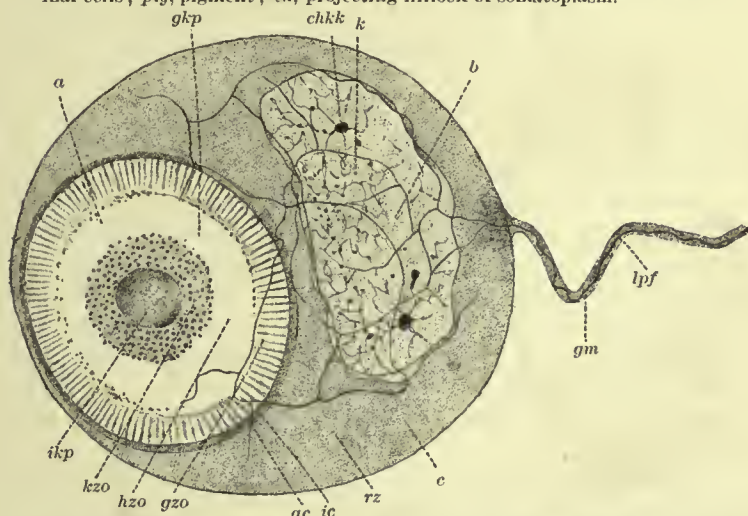


FIG. 26.—A subepidermal sense cell, retinal cell from pseudo-branchellion. (After S. Apáthy, *Mitth. aus der zool. St. zu Neapel*, Bd. xii, 1897, H. 4, Taf. xxxi, Fig. 9.) *a*, vitreous; *b*, cell nucleus; *c*, cell body; *ic*, the limiting line of the diameter of the vitreous; *ac*, the outer contour line of the periphery of the somatoplasm immediately adjacent to the vitreous; *gm*, probably thin glia membrane which accompanies the "conducting" primitive fibril, *lpf*, outside the peribrillar mantle as far as the cell. The peribrillar mantle is lost at the cell surface; *chkk*, chromatic nucleolus; *gkp*, vitreous of the retinal cell; *gzo*, radially striped zone of the vitreous; *hzo*, clear zone of the vitreous; *ikp*, internal body (*Innenkörper*) of the vitreous; *kzo*, granular zone of the vitreous.

cell body proper by the so-called outer alveolar zone. The periphery of the cell proper consists of an outer chromatic zone, inside of which is an "inner alveolar zone." Inside this

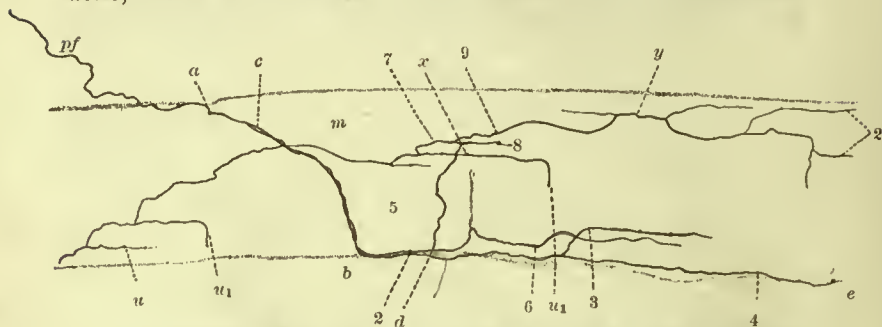


FIG. 27.—The distribution of the neuro-fibrils in the circular muscle fibre of the intestinal wall of pontobdella. (After S. Apáthy, *Mitth. aus der zool. St. zu Neapel*, Bd. xii, 1897, H. 4, Taf. xxxii, Fig. 3.) Only a relatively short piece of the long, band-shaped flattened-out muscle fibre is represented. The branching of the entering neuro-fibril can be followed through the whole thickness of the fibre. *pf*, "conducting" primitive fibril; *m*, muscle fibre; *u*, place where "conducting" primitive fibril turns and appears to end.

again is an inner chromatic zone, which in turn is separated from the nucleus by the so-called perinuclear zone. In the latter is situated a small centrosomelike body. Inside the ganglion cells a reticulum of fine fibrils derived from the neuro-fibrils in transit can be stained a beautiful deep violet color by Apáthy's chloride-of-gold method.

According to the size of the cells and to the arrangement of the neural reticulum inside, Apáthy distinguishes in the leech two main types: (1) the large ganglion cell, and (2) the small ganglion cell. It is to be borne in mind that the ganglion cells in this animal are unipolar, the so-called "stem processes" giving off near the cell body a number of processes which appear to be comparable to the dendrites of higher forms, the main continuation of the process representing probably the axone.

In the large type of ganglion cell (his Type G) the relations are described by Apáthy somewhat as follows: The neuro-fibrils arriving by way of the pyriform process of the cells enter the protoplasm, breaking up into elementary fibrils which diverge meridionally to ramify in the external chromatic zone. (The cells of this type possess no distinct internal chromatic zone.) Free anastomosis among the elementary fibrils inside the ganglion cell appears to be the rule. Having arrived at the



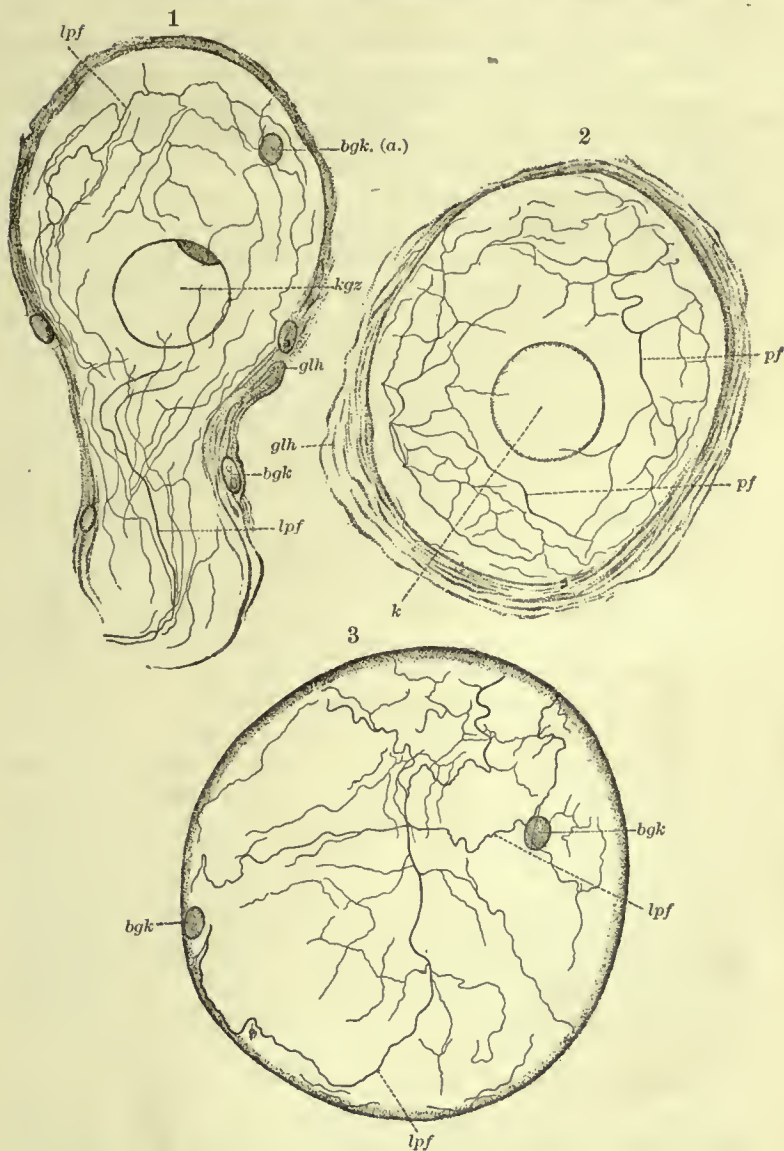


FIG. 28.—Colossal ganglion cell (Type *g*) from the leech. (After S. Apáthy, Mitth. aus der zool. St. zu Neapel, Bd. xii, 1897, H. 4, Taf. xxviii, Figs. 4, 5, and 6.)

(1) Posterior median section. *bgk*, connective-tissue nucleus; *glh*, glia sheath; *kgz*, nucleus of the ganglion cell; *lpf*, "conducting" primitive fibril. (2) Cross section. *k*, nucleus. (3) The meridianlike decussation of the neurofibrils at the pole of the cell is illustrated.

side of the cell most distant from the stem process the neuro-fibrils turn about and again plunge through the cell, converging to pass out of it by way of the pyriform process, which is thus seen to carry two sets of neuro-fibrillæ, which Apáthy believes serve in the one case for cellulipetal and in the other for cellulifugal conduction (Fig. 28).

In the small type of ganglion cell (his Type K) the relations, it would appear, are somewhat different. Here the pyriform stem process contains a single thick neuro-fibril in its centre, which Apáthy assumes to be cellulifugal and motor, and a number of finer neuro-fibrils peripherally placed, which he believes to be cellulipetal and sensory. He describes the finer peripheral neuro-fibrils as follows: They are seen to enter the cell body and, passing out to the peripheral part of its protoplasm, there to break up into a complicated plexus composed of anastomosing elementary fibrils in the outer chromatic zone. From this peripheral plexus there pass through the "inner alveolar" zone radial branches to the internal chromatic zone, in which is to be seen another fine plexus of elementary fibrils which, anastomosing and converging, finally form the single strong motor neuro-fibril, which passes out of the cell through the very centre of its pyriform process (Fig. 29).

In other animals studied by Apáthy there are cells with definite dendrites entirely separate from the axone and, in these the cellulipetal neuro-fibrils enter by way of the dendrites, ramify and anastomose freely inside the cell body, and then, reuniting, take their exit from the cell by way of the axone. Similar relations exist in the ganglion cells of the vertebrates which he has studied thus far. His descriptions of the neuroglia and the relations of the glia cells to the nerve cells, interesting as they are, need not now detain us, since they have but little bearing, if any, upon the topic under discussion.

As to the relations of the neuro-fibrils to sensory surfaces on the one hand and muscular tissue on the other, Apáthy makes very definite statements, especially in the last chapter of his article. A neuro-fibril entering the cytoplasm of an epithelial cell of a sensory surface in the leech breaks up (very much as in a ganglion cell) into a fine reticulum composed of the elementary fibrils. A large number of the constituent fibrils, however, perhaps the majority, leave the cell in order to take

part in the formation of a complicated interepithelial fibril plexus. For the interesting details concerning the innervation of the superficial epithelial cells and the subepidermal sense cells the original article should be consulted. In the muscular tissue, however, a very different distribution of the neuro-fibrils is encountered. A neuro-fibril here also breaks up into elementary fibrils which ramify inside the muscle cell. But although many of the fibrils emerge from it, instead of forming a complicated reticulum among the muscle cells they pass on

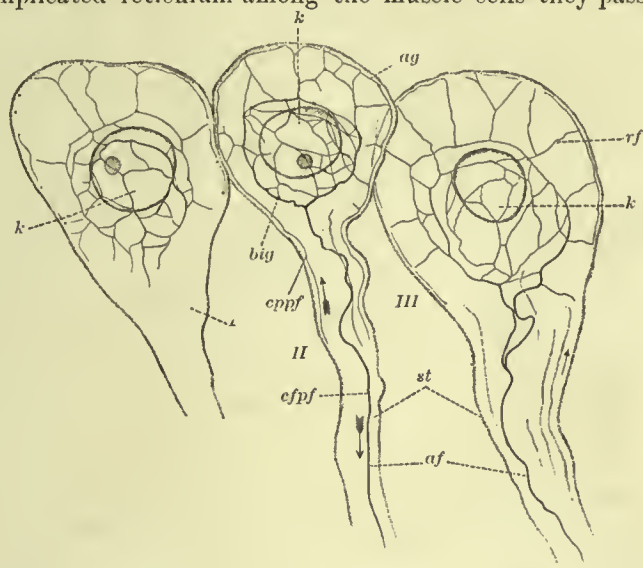


FIG. 29.—Three pear-shaped ganglion cells of Type K, in longitudinal section from the leech. (After S. Apathy, *Mitth. aus der zool. St. zu Neapel*, Bd. xii, 1897, H. 4, Taf. xxviii, Fig. 7.) The internal or perinuclear plexus of neuro-fibrils is well shown, as are also the radial fibres. The peripheral plexus is indicated. *af*, axis fibrils which Apathy takes to be motor; *ag*, external intracellular plexus of neuro-fibrils; *big*, internal perinuclear plexus of neuro-fibrils; *cypf*, cellulifugally "conducting" primitive fibril; *cpvf*, cellulipetally "conducting" primitive fibril; *k*, nucleus of the ganglion cell; *rf*, radial fibrils connecting the external plexus with the internal plexus of neuro-fibrils; *st*, stem processes of pear-shaped ganglion cells.

to enter and innervate other muscle cells. The neuro-fibril of a single axone would, therefore, through its elementary fibrils innervate perhaps a considerable number of muscle cells. One nerve cell may, Apathy states, be put into continuous relation, by means of one or more primitive fibrils, with several ganglion cells, and one fibril can be connected with a number of sense cells. But while one "ganglion cell" may be connected with

several "nerve cells," a given sense cell is never connected with more than one nerve cell.

From what has been said, and from a study of the accompanying illustrations, especially of Fig. 30, the main tenets of Apáthy may be gathered. And we must now ask whether, granting all his findings, and even his theories, to be in accord with the facts, the neurone doctrine would be nullified by them. Although the opinion has been expressed that it would have to be entirely given up, or very seriously modified, I must confess that such a view of the matter would seem to be, to say the least, premature. That the neurone conception, as it has been held by many, would have to be materially altered, there can be but little doubt, but many views of the neurone conception and what Waldeyer actually defined it to be are by no means identical. Nor can it be admitted, as a number of authorities, including apparently Apáthy himself, appear to assume, that in the research emanating from the Naples laboratory we have a confirmation of the doctrines of Gerlach, inasmuch as Gerlach's diffuse nerve network and its relation to axis-cylinder processes and dendrites involved conceptions somewhat different from those which Apáthy takes the responsibility of fathering. Apáthy's Elementargitter, however, stands very close to the conception of Gerlach.

It would seem, then, that were Apáthy's observations and theories in accord with the facts, the neurone doctrine, as conceived by Waldeyer, would not have to be seriously modified, much less abandoned. Some of the apparent novelty of his results depends upon the fact that, in the first place, he is dealing in the main with tissues which are not very familiar to many

FIG. 30.—Schematic representation of the course and connections of the conducting paths in a transverse section of the somite of the leech. (After S. Apáthy, *Mitth. aus der zool. St. zu Neapel*, Bd. xii, H. 4, 1897, Taf. xxxii, Fig. 6.) The two halves of the ganglion are shown with the motor ganglion cells, *mg*, and the sensory or simple connecting ganglion cells, *gst*. Three kinds of nerve spindles or nerve fibres are shown. The behavior of these inside the centre, their distribution in the central fibre mass, and their connections with the ganglion cells, are illustrated. Further, the behavior of these at the periphery is pictured: muscle fibres and epidermal and subepidermal sense cells, free end branchings in the epidermis, *fre*. At the point marked *us schl* is indicated a place where a sensory tube bends around in a longitudinal direction into the central fibre mass. The place *sbq* indicates where a sensory bundle turns in a longitudinal direction in the central fibre mass. "Conducting" bridges between the muscle fibres are shown at *nbr*. *an*—"conducting" anastomoses; *cu*, cuticula; *ep*, epithelium; *gz*, ganglion cell; *mf*, muscle fibrils; *mns*, motor-nerve spindle; *mpf*, motor primitive fibrils; *siz*, epithelial sense cell; *sc*, subcuticular layer of epidermis; *sb*, sensory bundle (one kind of sensory-nerve fibre); *ss schl*, sensory tube (the other sort of nerve fibre); *zkn*, nucleus of a "nerve cell" (not of a "ganglion cell").



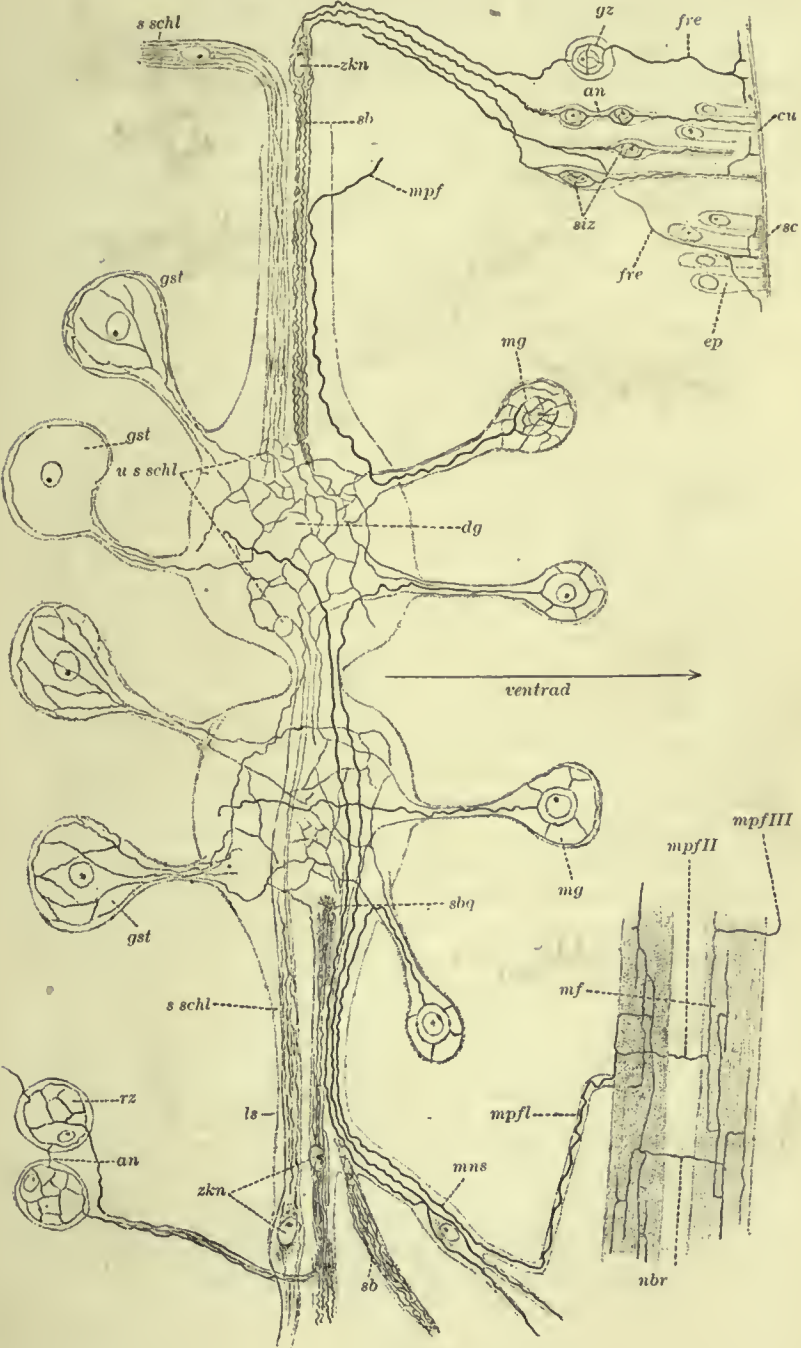


FIG. 30.

neurologists, namely, the nerve cells and fibres of invertebrate animals, and in the second place his publications thus far consist principally of an objective description of his own findings with particular methods devised by himself, and pay but little attention to the work of other investigators, so that the casual reader may, from lack of adequate comparative data, fail to distinguish between actually new discoveries and descriptions which may without unfairness be found to coincide in many respects with those of other students working with different methods. I feel convinced that when Apáthy fulfills his promise of supplying us with a still more lengthy communication in which the results of other investigators are to be compared with his own and properly valued, those who have been inclined to look upon all his observations as entirely unique will be disabused of their error. That many of his observations are entirely new must be frankly and thankfully admitted; that the technique he has introduced is altogether original, and evidently highly valuable and well worthy of extensive application and widespread control, must be freely granted.\* All that I wish to say, and that without any desire to detract from the merit of his laborious researches, is that an attentive analysis of the actual findings of Apáthy shows that there is far less absolutely novel and revolutionary in them than many seem to imagine. For, when one thinks of it, the form of the cells in invertebrates has long been known, the unipolarity of the elements has been generally figured and described, the fact that the pyriform process corresponds to both axis-cylinder process and dendrites is stated in the text-books, the irregularity in the distribution of the "chromatic substance" in the cells is easy to make out in Nissl preparations; the existence of the so-called intercellular bridges, if not for the cells in the

---

\* The remarks here made are not intended to be a criticism of the very important contribution of Apáthy, but rather to counteract an impression which seems to be gaining ground that the whole or at least a large part of our previous ideas concerning the architecture of the nervous system have been subverted by the results of his studies. Are we not more just and at the same time kinder to Apáthy if we simply accept gratefully and for what they are worth the wealth of new facts with which he has provided us, than we should be were we to give currency to the impression that they are entirely revolutionary and out of accord with the great principles which competent neurologists believe to be incontrovertibly established?

nervous system, at least for many of the cells of the body, is taught and demonstrated in every histological laboratory, and the fibrils in the processes and the reticula in the cell body have been the object of study and the topic of discussion, too often of bitter polemic, for at least two generations. The very neuro-fibrils upon which Apáthy bases his doctrine were first well seen, as the author himself states, by Kupffer in the tissues of vertebrates.

The essential novelties in Apáthy's contributions, in addition to his modifications of technique and his wonderful descriptions of the details of the fibrillary appearances inside the protoplasm of cells stained by his methods, which are undoubtedly of great value, are his deductions and hypotheses, of which all, in my opinion, may be permitted, at least for the present, to be judiciously skeptical. How does he know, for example, that the structures which stain violet by his gold method actually represent the conducting element in the nervous system? It may be true, but the Scotch verdict "Not proven" is here most applicable. Again, on what grounds does he separate the "nerve cell" so sharply as a different entity from the "ganglion cell" and how does he know that the "nerve cells" build the conducting element, and that the "ganglion cells" supply the force to be conducted? These *may* be the functions of these two sets of elements, but we must not neglect to point out that the evidence is not yet convincing.

As yet it is altogether too early to pass judgment upon Apáthy's views; much work must be done by his methods by other observers before the exact value of his findings can be properly estimated; but were all his statements true, is there any reason to doubt that neurones will continue to degenerate as units, as heretofore; that the nervous systems of our children will continue to be built up during development of repeatedly dividing neuroblasts in the way with which we are familiar, or that Golgi's method in the thirtieth century will have lost its power of demonstrating here and there a particular nerve unit or neurone in its entirety? Again, would the confirmation of the existence of continuous fibrils or fibril systems passing through a whole series of nerve elements necessarily militate against a unitary conception? I must say that I can see no reason why it should. Waldeyer, in his article in 1891, after discussing the probable modes of conduction by means of the neu-

rones, added, it would seem almost with prophetic insight, the following statement: "If we assume with Golgi and B. Haller the existence of nerve networks, the conception is somewhat modified, but we can still retain the nerve units. The limits between two nerve units would then always lie in a nerve network and not, anatomically at least, be exactly definable with our present methods." We do not regard the connective tissues as any the less cellular because they build white fibres, yellow elastic fibres and membranes, and reticulum; we do not look upon the studies of Weigert and Mallory, which deal with neuroglia fibrils and their relation to the neuroglia cells, as subversive of the doctrine that neuroglia cells exist; nor do we, because Kromayer and others have demonstrated, by particular methods, fibres running through the bodies of a number of epithelial cells, cry out that the cell doctrine must be given up. One might just as well assert that there are no organs in the body because there is a general vascular system. There may be units smaller than cells, and in all probability there are; there may be, and probably are, in the nervous system units other than those generally described, and it is important that we should find out all that there is to learn about them; but that the human body is made up largely of a mass of cells, and that the human nervous system is made up largely of great numbers of cell units, the so-called neurones, would seem to be facts too firmly established ever to be utterly overthrown.

NOTE.—In speaking of the nerve cells (or neurones) as individuals, it is not to be forgotten that in the animal and vegetable kingdoms we have to deal with individuals of different orders. Whereas some individuals consist of single cells and live as independent organisms, other individuals are united with one another to form a more complex creature, an individual of a higher order, as, for example, a multicellular animal or plant. Every individual possesses certain morphological and physiological characteristics and forms an elementary unit endowed with fundamental properties of life, possessing the power of assimilating food, of excreting waste substances, of increasing in size, of reproducing its kind, and of reacting in some way or another to stimuli which affect it from without.

An amœba, on the one hand, represents a unicellular organism, an independent vital unit, but an individuality of a very low grade. A multicellular animal is, on the other hand, a unit of a much higher grade, consisting as it does of a mass of amœbalike units, each of the latter possessing the fundamental properties of life, but each being somewhat less independent than a unicellular organism. The cells in such a complex cell state are none the less units because they are to a degree subordinated. Such units



may, however, become incapable of existence independent of their fellows. A multicellular individual (person) like a human being consists of an aggregate of billions of cells so intimately connected with and related to one another that the combined activities of the individual cells give the idea of unity, but each cell nevertheless continues to have a life history of its own. In such a democracy, as it were, it is not surprising that there should be morphological differentiation corresponding to the physiological division of labor necessary for the welfare of the whole. The specialization of activities renders each cell less independent than a cell of a single organism, but does not rob it entirely of its character as an individual. For a discussion of the question of "individualities" in Nature the reader is referred to the writings of Huxley, Nägeli, Haeckel, Spencer, and especially to O. Hertwig's *Allgemeine Anatomie und Physiologie der Gewebe*, Jena, 1898.

## SECTION II.

### THE EXTERNAL MORPHOLOGY OF NEURONES.

#### CHAPTER VII.

##### THE EXTERNAL FORM OF THE CELL BODY AND OF THE DENDRITES.

Neurones as cells—External morphology of neurones—The shape and size of the cell bodies—The protoplasmic processes or dendrites—Varicosities of the dendrites—The relation of the dendrites to the cell body—Adendritic neurones—Lateral buds or gemmules.

It is necessary to examine a little more closely into the morphological characteristics of the individual neurones. Neurones are in reality nothing more nor less than cells. They are curiously modified in structure and elaborately differentiated in function, but are none the less genuine cells of the animal body. It must be distinctly understood, however, that the nerve cell includes not only the cell body (perikaryon of Foster and Sherrington)\* and its protoplasmic processes, although these together make up the nerve cell of many of the textbooks, but also the axis-cylinder process with all its subdivisions, collaterals, and terminal ramifications. According to our modern definition, each and every portion of a neurone represents an integral part of a single body cell.†. As will be emphasized later, this view becomes of especial significance in the consideration of neurones in their physiological and pathological relations.

Neurones being cells of the body just as are liver cells or muscle cells, we should, notwithstanding their remarkable

---

\* A Text-Book of Physiology, by M. Foster, assisted by C. S. Sherrington, 7th ed., Part III. The Central Nervous System, Lond., 1897, pp. 915-1252, 8vo.

† The view expressed here seems to me to be logical. Some writers, I think, rather too sharply separate the axis-cylinder process as an entity apart from the rest of the nerve cell.

morphological differentiation corresponding to the high physiological functions for which they are destined, expect them to possess certain general characteristics common to all living cells. And in this expectation we are not disappointed. A nerve cell, like all others, possesses protoplasm and nucleus, the morphological characteristics of which, so far as they can at present be unraveled with the highest powers of the microscope, would scarcely seem to differ sufficiently from those of the elements of less noble tissues to account for their greater dignity of function.\* It may be that, although the microscope or the human eye will never be able to distinguish such morphological differences, chemical methods may enable us to arrive at much more satisfactory results. Despite this fact, however, thanks to some recent delicate histological methods, we are now in a position to make certain definite statements concerning the external and internal structure of different kinds of nerve cells.

In discussing the structure of the neurones, it will be convenient to speak first of the external morphological relations, best revealed by the methods of Golgi and Ehrlich, and secondly of the internal architecture of the neurone, our knowledge of which has been much increased since the introduction of the newer cytological technique, and especially from the application of the methods of Nissl, Held, and Apáthy. I have already spoken of the remarkable uniformity in type of the nerve cells in the most diverse parts of the central nervous system, and by my endeavors to emphasize this uniformity for the purpose at that moment in view some perhaps have been led to infer that the neurones are everywhere so similar as to be practically indistinguishable from one another. This is by no means the case; indeed, the method of Golgi has revealed a wealth of morphological peculiarities of which we were formerly able to obtain

---

\* It may be that with a wider view the differences in "dignity" of the different cells of the body would become minimal; but it is hard for human beings, so near their own cells, to conceive of the superficial epithelial cells of the skin shed in large numbers daily in the wear and tear of life as being of as high a grade as the cells which construct a poem, or the germ-cells, notwithstanding the fact that embryology teaches (1) that the nerve cells are derived from the same germ layer that gives rise to the epidermis, and (2) that in all probability every cell of the body has within it, though latent, substances endowed with the properties and potential energy which under suitable conditions would make it capable of developing into a complete human being.

no adequate conception. The method of Nissl too has revealed differences of internal structure of different cell groups which are equal in importance for purposes of classification to the external form relations discovered with Golgi's stain. Of these a description is given further on.

There are many neurones which, from the appearance of a single example stained black with silver, permit an absolute decision as to their source. Thus we are able at once to recognize the cells of the sensory ganglia (Fig. 31), the cells of Purkinje in the cerebellum (Fig. 38), the pyramidal cells of the cerebral cortex (Fig. 37), and certain of the cells of the hippocampus. The shape and size of the cell body, the number, size, and mode of branching of the protoplasmic and axis-cylinder processes, the relations of these to the cell body and to one another are some of the criteria which serve to guide one in making a distinction. A laudable beginning has been made to determine by the exact methods of reconstruction from serial

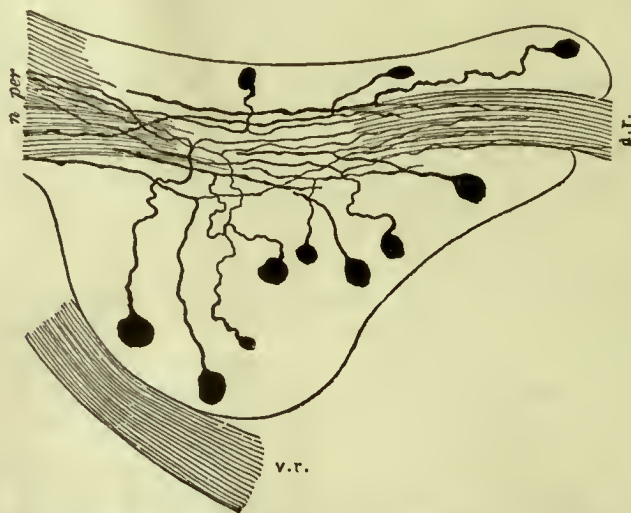


FIG. 31.—Spinal ganglion of a newborn white mouse. *d. r.*, dorsal root; *v. r.*, ventral root; *n. per.*, peripheral nerve. (After van Gehuchten.)

sections the precise external morphology of the nerve cells. We refer to the beautiful models of the reconstructed nerve cell exhibited by G. Mann at the sixty-sixth meeting of the British Association for the Advancement of Science at Liver-



pool in 1896, and at the meeting of the Anatomische Gesellschaft, in Kiel in 1898.

The bodies of the nerve cells vary much in size, measuring from four to a hundred and thirty-five microns and more in

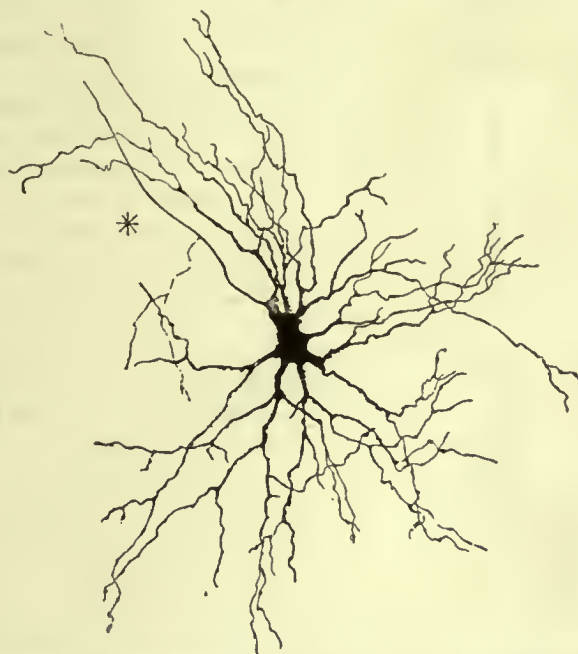

FIG. 32.—Motor cell of ventral horn of spinal cord from the human fetus, thirty centimetres long. (Method of Golgi; after von Lenhossék.)

diameter. Among the very small ones are the granules of the olfactory bulb and the small cells of the cerebellum, whereas the relatively huge protoplasmic masses, such as the larger cells of the ventral horns of the gray matter of the spinal cord and the spinal ganglia, or the cells of Purkinje in the cerebellum, are visible even to the naked eye. Starting originally as spherical germinal cells, the cell bodies, partly owing to the mode of origin of their processes, partly for reasons at present not clear, later assume, in different regions, very different shapes. The spherical spinal ganglion cell, the flask-shaped Purkinje cell, the multipolar ganglion cell of the ventral horns of the spinal cord (Fig. 32), the pyramidal cell in the cerebral cortex (Fig. 33), the spindle-shaped cell of certain regions are well-known and characteristic types.

Of the two main varieties of processes which come off from the cell body, the protoplasmic and the axis-cylinder processes,

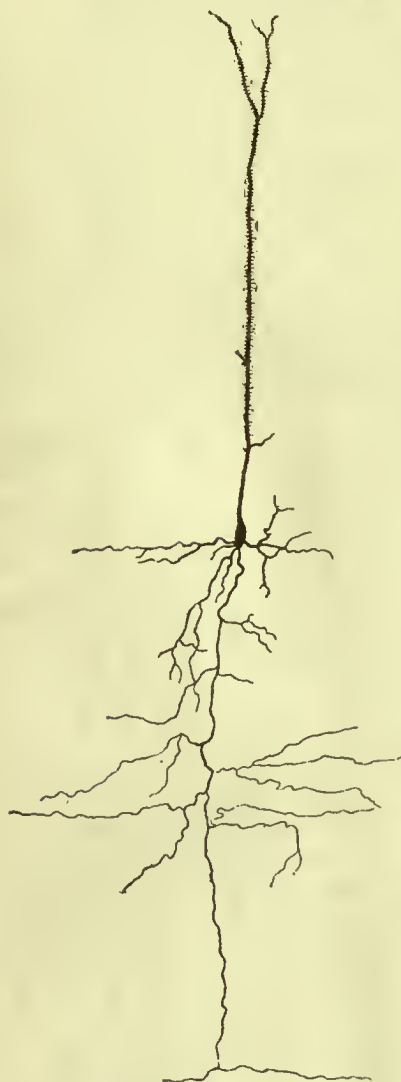


FIG. 33.—Pyramidal cell of cerebral cortex of mouse. (After Ramón y Cajal.)

the former, as might be inferred from their name, resemble more closely in appearance the cell body itself. These protoplasmic processes or, as they have been better named by His, dendrites (*Dendriten*), after their manner of branching, represent, as a rule, rather coarse projections of the protoplasm, which run out often in several directions from the general mass of protoplasm of the cell body.

Broad and thick, usually, at their origin, they grow gradually more narrow as they divide in a dendritic or antlerlike fashion, until the final subdivisions of a single dendrite may be distributed at a distance from the cell over a territory of no inconsiderable extent. All the subdivisions of a single dendrite finally run out to end free, never, so far as our present knowledge goes (with the exception of a few rare instances), anastomosing with one another, nor becoming united in any way other than by simple contact (Ramón y Cajal), by conerescence (Held), or by cell bridges and minute fibrillæ (Apáthy), with the processes of other neurones.\* The individual dendrites, not only of different cells, but also of the same cell, may vary considerably in length.

\* As van Gehuchten forcibly puts it, "Notez bien que je dis : dans l'état actuel de nos connaissances, les neurones sont des éléments indépendants ;

While in some types of cells all the protoplasmic processes are approximately equally developed, in other types—for example, in the pyramidal cell of the cerebral cortex—one dendrite may be enormously developed, being thick at its origin and extending for a long distance from the cell body, while the others are diminutive and comparatively insignificant in size and extent. The contour of a dendrite is often irregular rather than smooth and sharply defined. There may be nodular swellings (Fig. 34) at various points, though whether these are to be considered as normal appearances, as artefacts, or as pathological phenomena, does not yet seem entirely clear. There is, as a rule, no marked

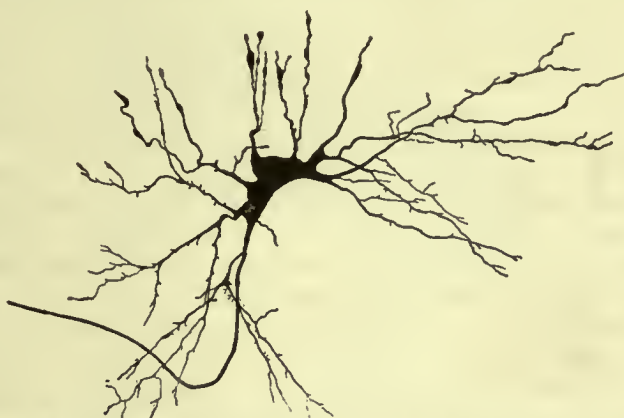

FIG. 34.—Multipolar nerve cell from the cord of the embryo calf showing varicosities of the dendrites. (After van Gehuchten.)

nodulation in normal specimens. Berkley, Monti, and others have observed marked distortions of the dendrites in certain pathological conditions. These will be referred to again in Section V.

The course of the dendrites, though sometimes tolerably straight, is usually devious; in fact, the irregularities in contour and direction are important distinguishing characteristics of this type of process. The character of the dendritic branching of the protoplasmic process varies much in cells of different parts of the central nervous system; whereas in some dendrites

---

cela veut dire qu'avec les méthodes d'investigation dont nous disposons actuellement, on ne voit pas de continuité, on ne voit pas d'anastomoses entre les éléments nerveux, et par conséquent on ne doit pas les admettre." But this rule, as we have seen, is relative, not absolute.

the branching commences at a short distance from their origin at the nerve cell and continues more or less regularly until the final divisions occur, in the dendrites of other cells a main trunk may extend for a considerable distance from the cell and then suddenly break up into a large number of terminal dendritically branching processes. The latter behavior is characteristic, for example, of the apical dendrites of the pyramidal cells of the cerebral cortex. The degree of complexity of the branching varies enormously; in some cells the dendrites are tolerably simple and but little branched; in others, the branching is most complex.

The territory occupied by these antlerlike divisions of the nerve cell may, as has been said, be very considerable. There are few greater surprises for the student in histology than his first view of a successful impregnation with the silver method of the dendrites of the Purkinje cells crowding with their dense feltwork the outer layer of the cerebellar cortex. The huge protoplasmic trunks coming off from the flask-shaped cell divide and subdivide with tropical luxuriance into widespread bushlike masses, occupying a wide territory and increasing the surface of the cell body, perhaps a hundred times or more. The significance of this cerebellar forest, as it has been called, of dendrites must be very great, but it has never as yet been satisfactorily explained; at present, we can form only hypotheses, at best very unsatisfactory, as to its meaning.

Very characteristic, too, for the different varieties of neurones is the relation of the dendrites to the surface of the cell body. In some instances, as in the motor cells of the ventral horns, they radiate out in all directions from nearly every region of the cell surface. In the cells of the hippocampus, or horn of Ammon, one or two dendrites proceed from one end of the more or less oblong or fusiform cell body, and a whole group of them are given off from the other end, while the sides of the cell body are smooth and sometimes give off no dendrites at all (Fig. 35). Other cell bodies, as is the case with some belonging to the nucleus dentatus cerebelli, yield dendrites from only one side. In the pyramidal cell of the cerebral cortex the main dendrite is given off from the apex of the pyramid, while the smaller lateral dendrites are yielded mainly by the angles at the base, the lateral surfaces and the basal surface itself giving off, as a rule, very few or no dendritic projections at all. Many



other examples might be given, but those mentioned will suffice to illustrate the importance of the origin, number, and distribution of the dendrites as factors in determining the morphological characteristics of a given neurone.

The occurrence of cell bodies entirely devoid of dendrites, the so-called adendritic neurones, has to be recognized. Indeed,



FIG. 35.—Neurones from the hippocampus (horn of Ammon) of a puppy two days old. (After Kölliker.) Two pyramidal cells (Golgi's cells of Type I) and one fusiform cell (Golgi's cell of Type II) are shown.

in invertebrates, as von Lenhossék, Retzius, and Apáthy have shown, they are very numerous and form in these animals no small proportion of the constituents of the nervous system. In such neurones, however, the pyriform stem process shows near the cell many accessory branchings (Fig. 36), which some believe to be of the nature of dendrites, though others look upon them as collaterals. The ultimate continuation of the main process is regarded by all as the axis-cylinder process of the cell.

The question has been fully discussed by von Lenhossék (*op. cit.*, S. 84 ff.). In the adult human nervous system the ma-

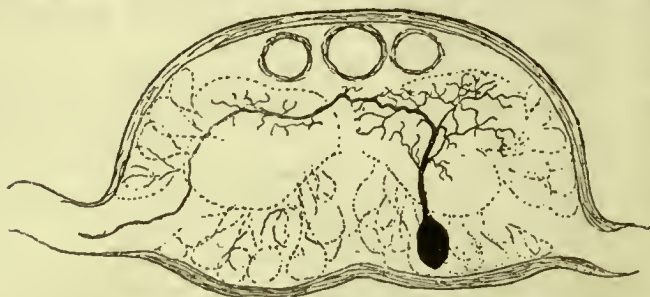


FIG. 36.—Unipolar cell from a ganglion of *Lumbricus*. (After von Lenhossék.) The cell body is devoid of dendrites; the accessory branches of the main processes are looked upon by some as dendrites, by others as collaterals.

jority of the neurones of the ganglia of the dorsal roots are histologically adendritic;\* though embryologically, and per-

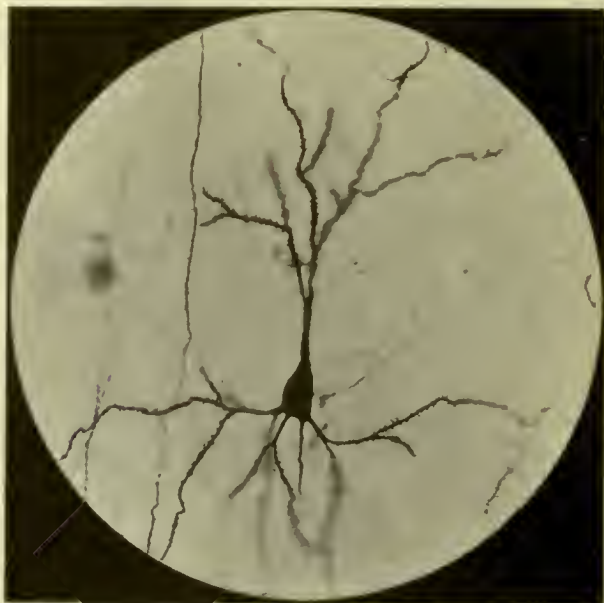

FIG. 37.—Photomicrograph of a normal pyramidal cell from the cerebral cortex of the guinea-pig. (After Berkley.) The single-branched apical dendrite and the basal dendrites show distinctly the lateral buds or "gemmules." The axone is relatively smooth.

---

\* Dendrites have, however, been demonstrated upon certain of the cells within the spinal ganglia.

haps also physiologically, the axone of the peripheral sensory nerve fibre is more of the nature of a dendrite. Microscopically, however, it has every appearance of an axis-cylinder process, and indeed must be regarded as the axis cylinder of a medullated nerve fibre. The dendrites within the central nervous system are, like the cell bodies, entirely devoid of myelin sheaths.

Another feature characteristic of the dendrites of some nerve cells deserves more than passing notice. Upon the sur-

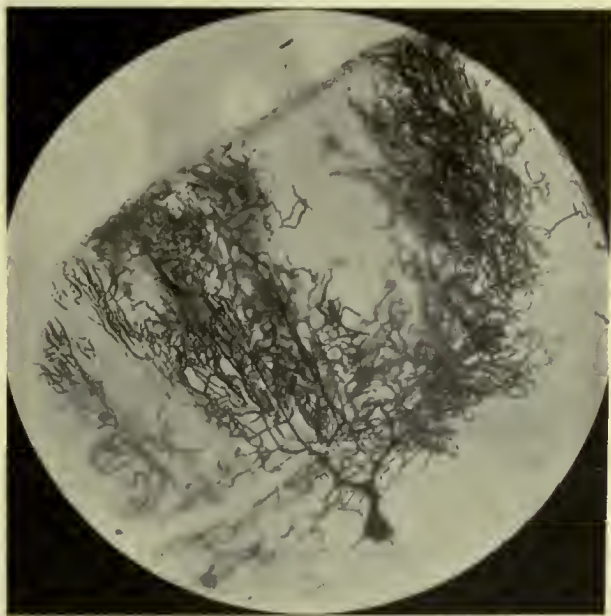


FIG. 38.—Photomicrograph of a normal Purkinje cell from the human cerebellar cortex. (After Berkley.)

face of the processes it is possible to make out minute lateral buds, which, although too small perhaps to deserve the name of branches, are still definite histological structures, probably of no mean significance. On the dendrites of the pyramidal cells (Fig. 37) of the cerebral cortex and upon those of the Purkinje cells in the cerebellum (Fig. 38) these lateral projections are very numerous and constant in silver preparations of healthy tissue. They are not unlike the projections into the liver cells from the bile capillaries, as revealed by Golgi's method, but ap-

pear in far greater numbers. Berkley, who has named these processes "gemmules,"\* thinks they are of very great significance for the contact of different neurones with one another (Fig. 39), and thus for the transference of impulses from neu-

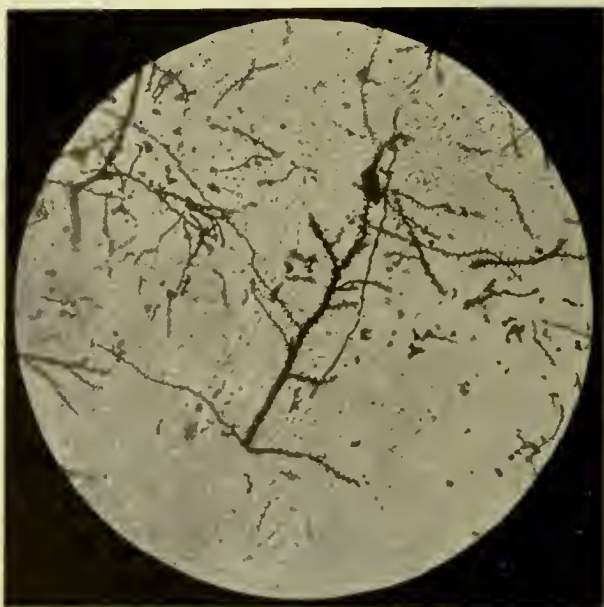


FIG. 39.—Photomicrograph of the apical dendrite of a large pyramidal cell of the cerebral cortex showing the arrangement of the lateral buds or gemmules. (After Berkley.)

rone to neurone. He asserts that in certain diseases, particularly in certain intoxications, it is these "gemmules" which are the portions of the neurone which first suffer, and he has even suggested that in paralytic dementia, for example, the early symptoms may be explicable by assuming the destruction of large numbers of these gemmules.

It has been objected that these lateral buds are demonstrable only by Golgi's methods, and that therefore one should hesitate before deciding that they are more than artefacts.

---

\* The selection of the term "gemmules" to designate these lateral buds is not entirely free from objection, inasmuch as the same word was used by Darwin in connection with heredity as a name for the minute elements which, according to his theory of pangenesis, are given off by the cells in different parts of the body, to be taken up later by the sexual cells.



Hill \* has recently stated that, although he finds them in nine cases out of ten, he believes them to be artefacts representing "the cell end of an unstainable nerve filament surrounded by a film of staining cell plasm." From the constancy of their appearance on the dendrites of certain only of the nerve cells, from their entire absence from those of certain others, and from the fact that they are most apparent and more sharply defined in the most successful impregnations, it seems, however, fair to conclude that they are definite histological structures. Moreover, Ramón y Cajal † has been able to demonstrate beautifully these lateral buds on the dendrites of the pyramidal cells of the cerebral cortex by means of the "vital staining" with methylene blue, and has pictured them in Fig. 1, *a*, of his article. These appearances can, therefore, be no accident, but whether the interpretations thus far advanced as to their significance are correct or not further knowledge and experience must determine.

---

\* Hill, A. Note on "thorns" and a theory of the constitution of gray matter. *Brain*, Lond., vol. xx, 1897, pp. 131-137.

† Ramón y Cajal, S. Las Espinas Colaterales de las Células del Cerebro Teñidas por el Azul de Metileno. *Revista Trimestral Micrográfica*, Madrid, vol. i, fasc. 2 y 3, Agosto, 1896, pp. 123-136.

## CHAPTER VIII.

### THE EXTERNAL FORM OF THE AXIS-CYLINDER PROCESSES OR AXONES.

The axis-cylinder processes or axones—Differential characteristics of dendrites and axones—The relations of the axones to the cell body—Dendraxones and Inaxones—Monaxones—Diaxones—Polyaxones—Anaxones—Schizaxones—Modes of termination of axones—Telodendria—The coverings of axones.

THE axis-cylinder processes or axones\* of nerve cells differ markedly in many ways from the dendrites. The appearances presented by an axone in Golgi preparations are so characteristic that after a little experience the observer will rarely have the slightest difficulty in distinguishing it from adjacent dendrites; indeed, a few days' study with the microscope of successfully impregnated specimens will do more to convince the student of the differences in type of dendrites and axones than will many pages of careful explanation.† On analysis, however, the structures admit of differentiative description. The axone differs from the dendrite in its mode of origin from the cell body, in its contour and calibre, and in its course and mode of branching; further, if long, it is usually medullated, and also shows differences in its accessory processes and in its method of termination.

Arising embryologically through a prolongation of the stem of the pear-shaped neuroblast (*vide infra*), in the adult the axone comes off from the cell body or from a dendrite (Fig. 40), in the latter case usually near the cell body, though sometimes at a long distance from it, by a narrow wedge-shaped beginning.

---

\* Kölliker's Neuraxôn is well shortened to the more simple *axone*, a term convenient and not likely to lead to any confusion. The designation *neurite* has also been applied to this process.

† It must be admitted, however, that in certain regions—for example, in the sympathetic ganglia and in the plexuses of Meissner and Auerbach—the dendrites and axones may resemble one another so closely that they can only with considerable difficulty be distinguished from one another.

This mode of origin makes the axone appear to be a more independent structure than the dendrite, since the latter, as is obvious from its broad, wedge-shaped origin and from the nature of its contents, is simply an attenuated portion of the body of the nerve cell. That the axone is, however, also a direct continuation of the protoplasm of the cell body, at least of the ground substance of that protoplasm, there can be no doubt, although, as will be pointed out later, certain substances, those which account in tissues fixed in alcohol for the so-called Nissl bodies, present in considerable amount within the cell body and dendrites, appear to be entirely absent from the axones, or to be present in them in such small quantities as to escape detection by the methods at present employed for demonstrating them.

The calibre of the axones varies much for the different cells, corresponding in general to the length of their course, a point which Schwalbe early pointed out and which von Lenhossék has recently emphasized. Unlike that of the dendrite, its calibre is, as a rule, maintained for a considerable distance from the cell. Even in the dendraxones (Golgi's cell, Type II; Kölliker's *Neuropodien*) the axone is sufficiently well characterized in this

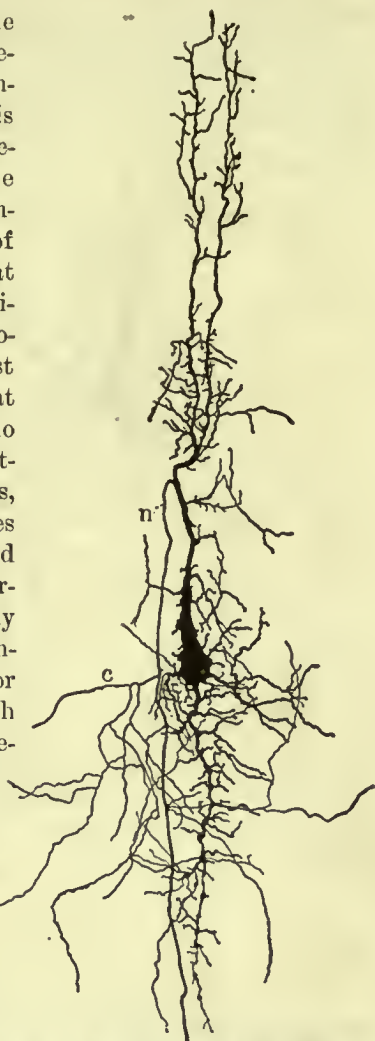


FIG. 40.—Neurone from the optic lobe of the embryo chick. (After Kölliker.) The large dendrite running toward the periphery of the lobe gives rise to an axone, *n*, which runs toward the centre, giving off in its course several collaterals. One of these, *c*, is much branched.

respect to permit easily of its identification (Fig. 41). We are often deceived from its narrow calibre as to the volume of an axis cylinder. This may be as much as a hundred and eighty-seven times that of the cell body (Donaldson).

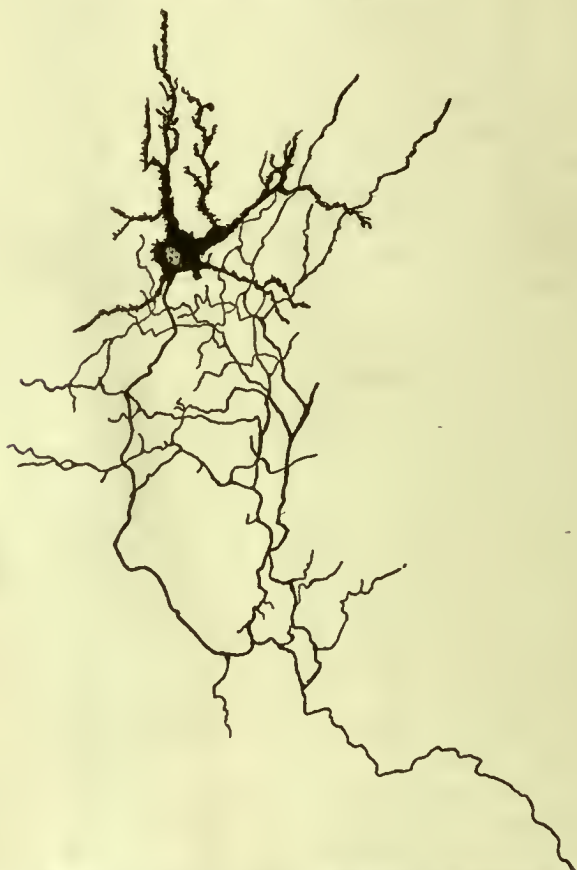

FIG. 41.—Golgi's cell of Type II from the dorsal horn of the gray matter of the spinal cord of the newborn mouse. (After von Lenhossék.) Even in such a dendraxone the axone is very easily distinguishable from the dendrites. The latter are only represented in part in the illustration.

The surface of the axone is smooth, its contour regular, and its course, as a rule, direct, so that in most instances the trained eye can recognize it in Golgi preparations at first glance standing out sharply like a piece of black thread on a white or yellowish background. The axones do not always, however, take the course to their destination which appears to be the shortest,



and the origin and significance of some of the curves and digressions, for example of the root fibres of the *nervus facialis*, are difficult to understand.

The length of the axones is in the highest degree variable. In the dendraxones, where dendritic branching of the axone

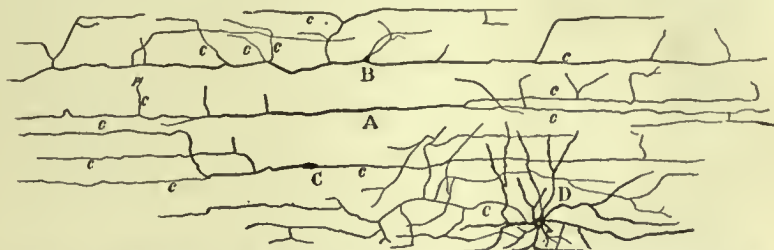


FIG. 42.—Special cells (polyaxones) of molecular layer of cerebral cortex of a dog one day old. (After Ramón y Cajal.) A, fusiform cell; B, triangular cell; C, another fusiform cell; D, polygonal cell with numerous dendrites and an axone which divides repeatedly; c, axones.

occurs soon after its departure from the cell, the total length before complete loss of individuality may amount to only a few millimetres, or even to a fraction of one millimetre. On the other hand, the axones of some of the motor neurones are fully half as long as the height of a man. Between these two extremes there is every possible degree of variation.

The neurones with long axones (inaxones of von Lenhossék, Golgi's cells of Type I, Kölliker's *heteropodere Nervenzellen*), as a rule, are monaxones—that is, they possess only one axone,

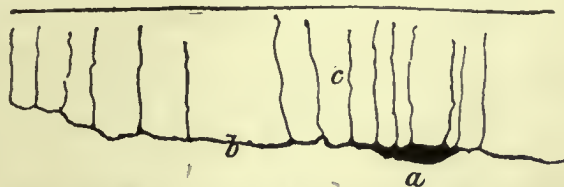


FIG. 43.—Ramón y Cajal's cell from the superficial layer of the cerebral cortex of a fetal cat. (After Retzius.) a, cell body; b, dendrite; c, axones.

though the spinal ganglion cells may, histologically at least (*vide supra*), be regarded as diaxones. There are neurones, too, which possess several axones. Among these, the so-called polyaxones, are the cells described by Ramón y Cajal in the outer layer of the cerebral cortex of certain animals (Figs. 42 and 43), from the horizontal dendrites of which as many as four or even



invariably ends "free." The termination of a branch of an axone by means of a definite end arborization about a single cell (Fig. 47) occurs, though not so frequently as many writers would lead one to think. The common mode of ending is by exhaustion through multiple division, this division being often spread over quite a wide

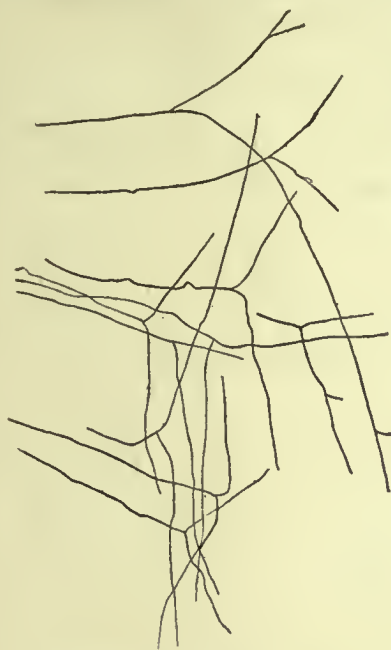


FIG. 46.

FIG. 46.—Y-shaped division of sensory root fibres after entrance into the spinal cord. Six-months human embryo. (After von K  lliker.) Axones which undergo such a division are called by von Lenhoss  k schizaxones.



FIG. 47.

FIG. 47.—End ramifications forming a basketwork about two Purkinje cells of the cerebellar cortex. (From Sch  fer, after Ram  n y Cajal.) *a*, axone; *b*, basketwork.

domain, so that the terminal branches of a single axone not infrequently come into the neighborhood of the dendrites and cell bodies of a considerable number of different neurones. It may not be superfluous to emphasize this fact, inasmuch as a great many diagrams hitherto published in text-books and not a few descriptive articles are entirely misleading; the intimate interdigitation or interweaving of the terminals of one axone exclusively with the dendrites of a second neurone, so frequently pictured, very rarely occurs, except in a few localities, as, for instance, in the olfactory glomeruli of some animals (Fig. 48). It is much nearer the truth to think of one neurone coming by means of the terminals of its axone or axones into contact with,

and thus perhaps being put into a condition to influence the processes or cell bodies of a few or of many other neurones ("avalanche conduction" of Ramón y Cajal). In the accompanying figure, which illustrates the terminal sensory nucleus of the trigeminus in the cat, the distribution of axones over a considerable area is clearly shown (Fig. 49); in Fig. 50 and in Fig. 51, the manifold branchings of some of the end ramifications of axones, as revealed by the method of Golgi, are also demonstrated.

A number of curious forms of termination have been de-

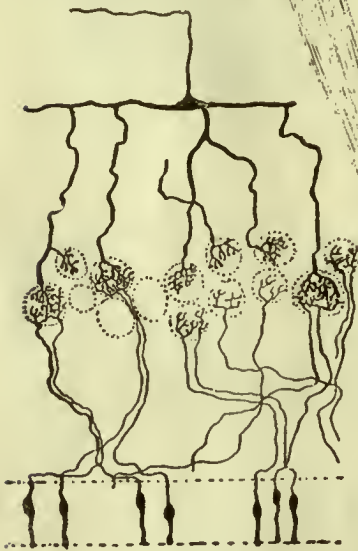

FIG. 48.

FIG. 48.—Scheme showing the relations in the olfactory glomeruli of the axones of the olfactory neurones of the first order to the dendrites of the mitral cells in birds. (After van Gebuchten.)

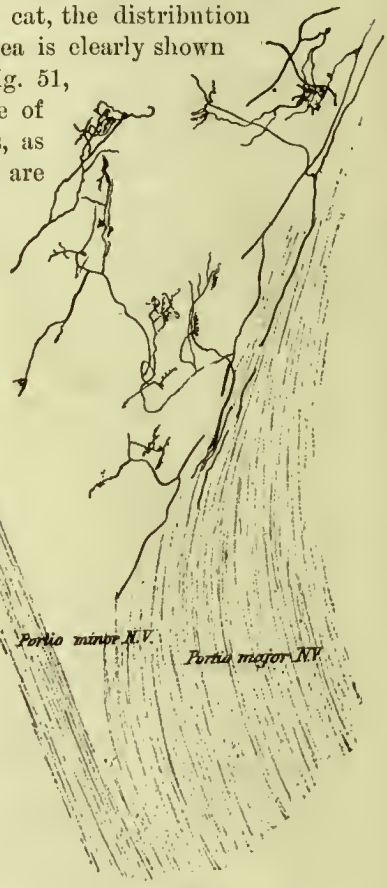

FIG. 49.

FIG. 49.—Nucleus of termination of the sensory part of the nervus trigeminus of the cat. (After Held.) The end ramifications of the single axis cylinders are seen to be distributed in widely separated areas, so that impulses coming along a single fibre to the nucleus may come in contact with a large number of neurones of the second order.

scribed in various parts of the central nervous system. One of the most interesting of these is that shown in Fig. 52, which



illustrates the mode of termination of the so-called "climbing fibres" in the cerebellar cortex. Many other modes of termination—for example, the diselike expansions to be seen in

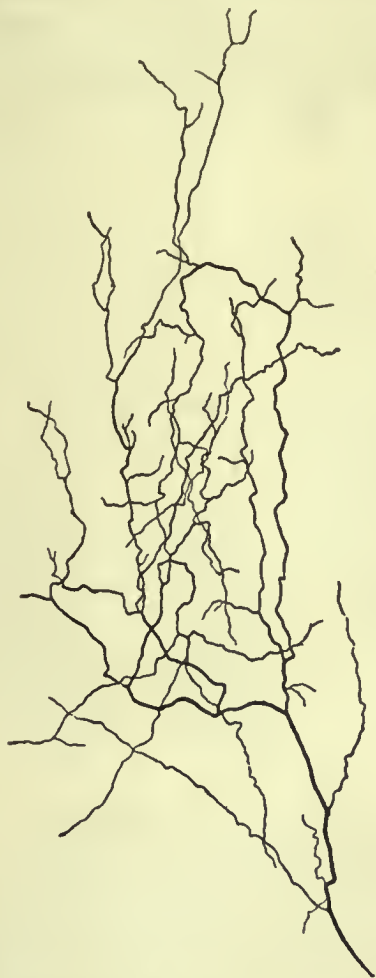

FIG. 50.—A much-branched fibre from the optic thalamus of a mouse. (After Kölliker.)

Meissner's corpuscles and in the tactile discs in epithelial surfaces (Fig. 53)—might be mentioned. The curious calyxlike terminals (Held) of axones met with in the nucleus corporis trapezoides are fully described and pictured in a subsequent

chapter (Section VI). It is to be remembered that within the central nervous system the terminals of the axones and collaterals may, in some instances, come in direct contact with the bodies of other neurones (*vide* Fig. 47), in other instances the second neurones are influenced perhaps mainly through their processes. The anatomical relation of one nerve cell with another is spoken of by Foster and Sherrington \* as a *synapsis*. †

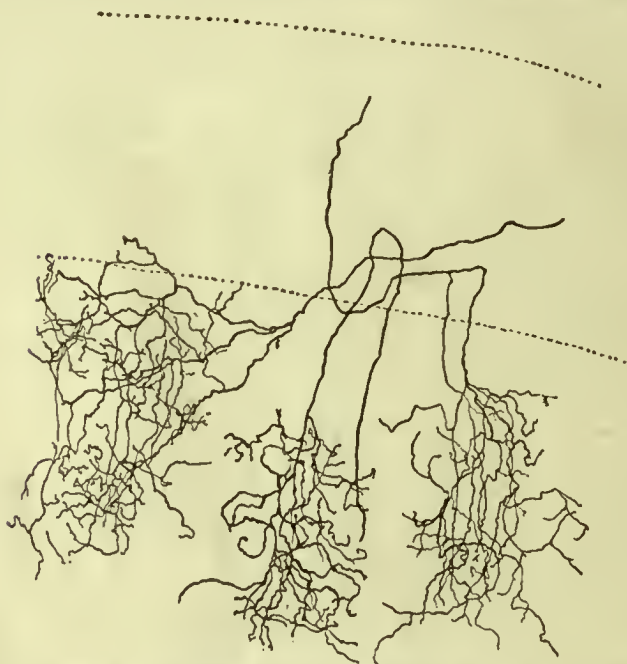


FIG. 51.—Three end arborizations of optic fibres from the optic lobe of an embryo chick. (After Kölliker.)

In the majority, although not all, of the inaxones the axis-cylinder processes are in the greater part of their course inclosed within a sheath. Dendraxonones, being for the most part entirely within the gray matter of the central nervous system, possess axonal processes which are, as a rule, devoid of such a protective covering. In the majority of peripheral spinal and cerebral nerves this covering consists of a relatively thick fatty layer forming the myelin sheath, external to which is a cellular layer, the neurilemma. Henle's sheath is the fibrous tissue

\* *Op. cit.*, p. 929.

† From σύν and ἄπτω, clasp.

often present external to the neurilemma. Within the central nervous system the myelin sheath is present, but the neurilemma appears to be absent, a fact which speaks strongly in favor of the view that the myelin sheath is the result of the productive activity of the axone rather than of the neurilemma cells, as many have believed. The sympathetic nerve fibres possess no myelin sheath, but are surrounded by a protecting layer of long, flat cells forming a sort of neurilemma. It is not my purpose here to refer in detail to the histology of these various sheaths of the axone; they have long been carefully studied, and are described at length, and, as a rule, correctly, in the text-books. I would only point out that the discovery of the fact that within the brain and spinal cord the axones of neurones destined for different functions receive their myelin sheaths at different periods in developmental history, and its application as a means of analysis of nerve tracts form the basis of Flechsig's embryological methods. By means of the recent method introduced by

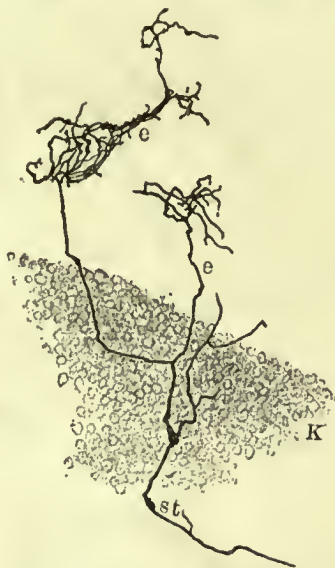

FIG. 52.—The so-called "climbing fibres" of the cerebellar cortex from the brain of a child a month and a half old. (After Kölliker.)

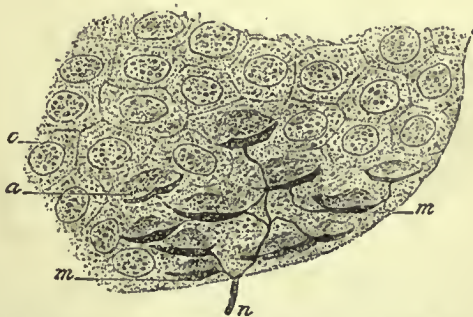

FIG. 53.—Disc-shaped expansions on nerve fibrillae of the pig's snout and their relation to certain of the epithelial cells. (From Schäfer, after Ranvier.) *n*, nerve fibre; *m*, meniscus or disc; *a*, epithelial cell in contact with disc; *e*, ordinary epithelial cell.

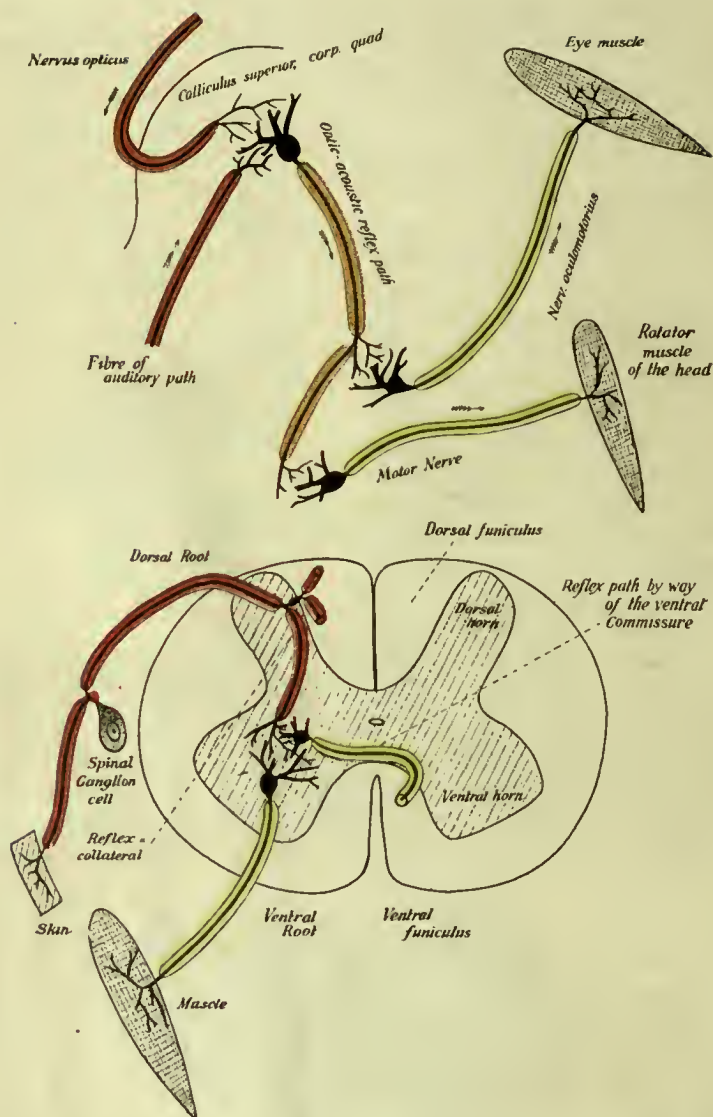


FIG. 54.—Developing myelin sheaths of different ages as seen through the polarization microscope. Schematic. (After H. Ambronn u. H. Held, Arch. f. Anat. u. Physiol., Anat. Abth., Leipz., 1896, Taf. ix.) The upper of the two figures represents the reflex path between the acoustic and optic nerves and the motor apparatus governing the movements of the head and eyes. The lower figure shows the reflex path through the dorsal and ventral roots of the spinal cord. Yellow fibres oldest; red fibres youngest.



Ambronn and Held,\* in which the polarization microscope permits the determination of the younger and older of medullated fibres of nearly the same age, the sphere of application of the myelinization method of study has been considerably widened. In Fig. 54 the sharpness of analysis made possible by means of the color differentiation is illustrated. Held † has tested recently by means of the polarization method the effects of stimulation upon the progress of myelinization. The work done upon these lines belongs to one of the most important epochs in the development of methods of neurological investigation, and to the application of Flechsig's method to the study of some of the higher nerve centres I shall later take occasion to refer. The portion of an axone nearest the cell body is with some exceptions devoid of myelin, as are also its terminal ramifications (motor end plates and naked telodendria within the central nervous system). Here and there in its course a medullated peripheral nerve fibre may suddenly lose its myelin sheath, be devoid of it for a certain distance, and again suddenly be covered by it (Schiefferdecker).

---

\* Ambronn, H., und H. Held. Beiträge zur Kenntniss des Nervenmarks. Ueber Entwicklung und Bedeutung des Nervenmarks; Ueber Beobachtungen an lebenden und frischen Nervenfasern und die Sichtbarkeit ihrer doppelten Contourirung. Arch. f. Anat. u. Physiol., Anat. Abth., Leipz., Jahrg. (1896), H. iii u. iv, S. 202, 214.

† Held, H. Ueber experimentelle Reifung des Nervenmarks. Arch. f. Anat. u. Physiol., Anat. Abth., Leipz., Jahrg. (1896), H. iii u. iv, S. 222.

## CHAPTER IX.

### COLLATERALS, SIDE FIBRILS, AND INTERNEURONAL SUBSTANCES.

Accessory branchings of the axones—The collaterals or paraxones—The side fibrils of Golgi—Substances between neurones.

BESIDES the main divisions of axones above described, the accessory branchings of the axones, the collaterals (von Lenhossék's *Paraxonen*; Retzius' *Cylindrodendriten*), and side fibrils (Golgi) must be considered. In Golgi preparations the point of origin of a collateral from the axone is usually marked by a slight thickening. In the spinal cord, collaterals from the fibres of the dorsal roots and from the fibres of the white fasciculi run in at different levels in great numbers into the white substance, so that a given nerve fibre may be connected not only with the gray matter in which its axone finally terminates, but accessorially by means of its collaterals with the gray matter of very many segments of the cord intervening between its origin and ultimate termination, a fact of incalculable importance in the explanation of roundabout conductions and of manifold reflex activities. According to von Lenhossék, and my own studies thus far support his statement, the portion of the axone nearest its cell of origin—that is, the cytoproximal portion—possesses many more collaterals than that distant from the cell body; indeed, the cytodistal portion of the axone may be almost or entirely devoid of collaterals. Owing to technical difficulties, the number of collaterals which may be given off by a single axone has never as yet been satisfactorily determined. Kölliker, in a longitudinal section of the spinal cord a few millimetres long, counted as many as nine collaterals from one fibre. It will be remembered that some of the fibres of the dorsal roots in their intramedullary course extend from the lumbar cord as far as the medulla oblongata, though it would be incorrect to calculate the number of collaterals *pro rata*, since, as has just been said, the cytodistal portions of the axone appear to be entirely free from accessory branchings.

Von Lenhossék, who has made exhaustive studies of the spinal cord, including that of human beings (Fig. 55), has never been able to find collaterals in the fasciculus gracilis Golli and does not believe that they exist there. Moreover, the number of collaterals varies much, not only for axones of the same fasciculus, but also and more particularly for the axones of different physiological systems. In the dorsal fasciculi of the spinal cord,

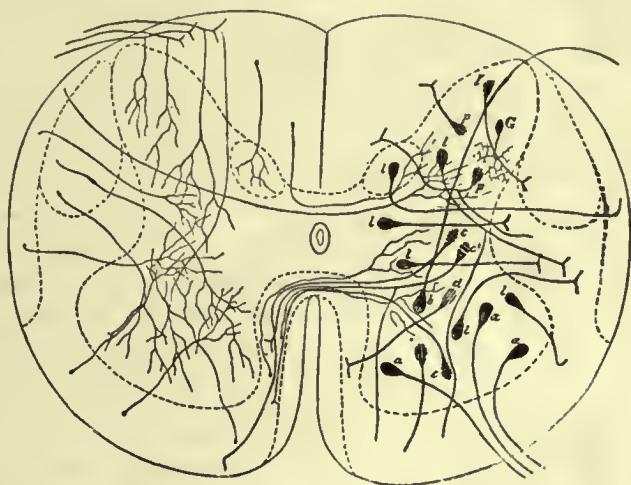


FIG. 55.—Scheme showing the elements of the gray matter of the spinal cord. On the left are shown the terminal axones and collaterals entering the gray matter from the white substance; on the right are to be seen the different nerve cells of the gray matter. (After von Lenhossék as modified by van Gehuchten.) *a*, ventral horn cells, the axones of which go into the ventral roots of the spinal nerves; *b*, cell, the axone of which passes into the dorsal root of a spinal nerve; *c*, *c'*, *d*, *l*, *p*, cells, the axones of which pass to the fasciculi of the white matter; *c*, heteromeric neurones; *c'*, heteromeric neurone; *d*, *l*, *p*, tautomeric neurones; *G*, Golgi's cell Type II, or dendraxone.

von Lenhossék has shown that the collaterals are most abundant in the entry zone; they are very numerous in the middle and ventral parts of the fasciculus cuneatus Burdachi, but occur in much smaller numbers in its dorsal peripheral part; and in the fasciculus gracilis, as has just been pointed out, they appear to be absent altogether. That they are absent in the fasciculus gracilis must not be taken to mean that these axones are entirely deprived of collaterals, inasmuch, as is well known, those belonging to the fibres constituting the fasciculus gracilis represent axones of dorsal root fibres, which lower down have run for some distance in the fasciculus cuneatus and only after a

longer or shorter course within the cord have passed over, or have been pushed over through the entrance of more fibres from dorsal roots higher up, into the fasciculus gracilis. That there are axones, however, which have no collaterals seems very prob-

able, and this is true for many axones of ventral horn cells and of the optic and olfactory peripheral sensory neurones.

The collaterals are often, it might perhaps be said generally, medullated, and an immense number of the very fine fibres revealed by Weigert's method

within the gray matter of the central system represent medullated collaterals. A great step forward was made when it became possible to recognize that the great mass of medullated fibres passing in from the dorsal funiculi of the cord do not represent the terminal branches of the fibres of the dorsal roots, nor even the main stems of these fibres on their way through the cord. The majority of these fibres represent collaterals and are not main branches of dorsal root fibres, by far the majority of the latter passing on up in the dorsal funiculi. Thanks to the extremely careful studies

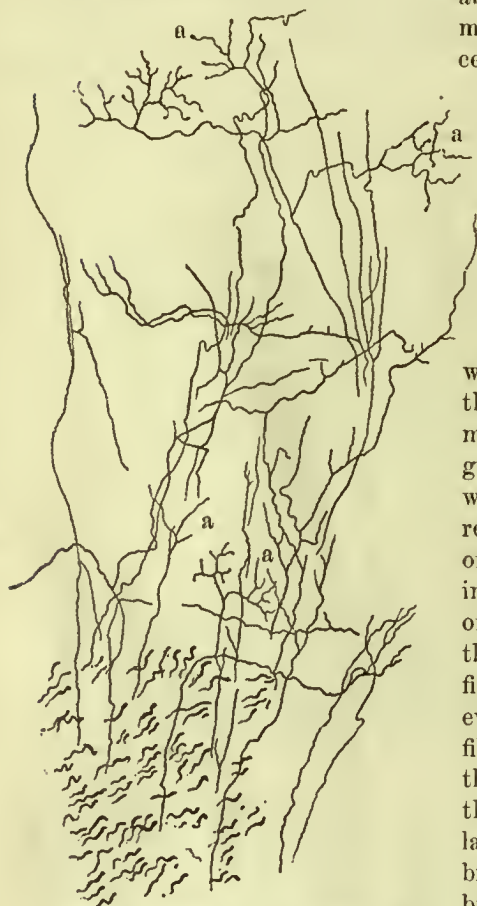


FIG. 56.—Endings, *a*, of collaterals from the dorsal funiculi in the gray matter of the spinal cord of the newborn rabbit. (After Kölliker.)

of von Lenhossék, Ramón y Cajal, and Kölliker, which supplement the embryological investigations of Flechsig, we are now able to recognize very different groups of these collaterals, including the reflex collaterals and others, groups differing in



origin, in their methods of termination, and, most interesting of all, probably in function. This new classification is destined to go far in rendering clearer the pathology of the spinal cord—indeed, it has already done much to elucidate many obscure problems connected therewith.

The free ending of the collaterals like that of the terminal axones is insisted upon by those who work with the method of Golgi (Fig. 56). After repeated division each little fibril runs out into a terminal end point which occasionally, though not always, appears slightly knobbed. The collateral may thus come in contact, by virtue of its end arborization, with the processes of several other neurones, and here as before the diagrammatic representation of collaterals surrounding exclusively the cell body or dendrites of a single neurone is to be emphasized as misleading. While it can not be denied that such a means of ending may occur, it is at least certain that it is not the only one, nor, I think, the most common. The importance of recognizing the real method of termination becomes more obvious in the consideration of the simultaneous affection of a whole series of neurones belonging to one functional neurone group. As to whether collaterals can be distributed in domains in which they can come into conduction relation only with the side fibrils or collaterals of axones of other neurones, I shall have something to say when discussing the possible functions of the different parts of the neurones.

Golgi distinguishes the side fibrils (Fig. 57), which run off from the axone into the gray matter immediately after its origin, from the regular collaterals which arise at a greater distance from the cell body. The former are non-medullated, the latter usually medullated. Though morphologically there seems to be no very obvious reason for such a division, von Lenhossék has recently expressed himself as of the opinion that the two

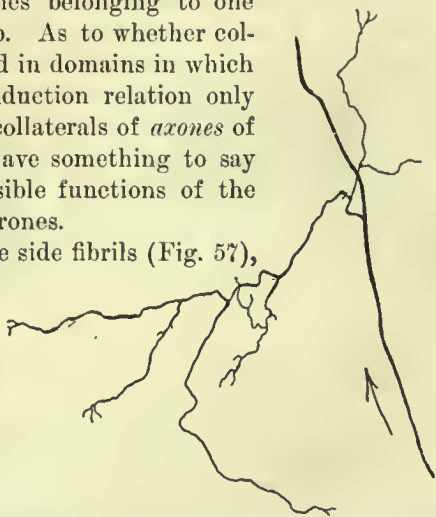


FIG. 57.—Side fibril of Golgi on the axone of a motor cell of the ventral horn of the spinal cord. The arrow indicates the cellulifugal direction. (After von Lenhossék.)

structures may be of different significance in their functional aspects, a subject to which it will also be necessary to return.

In sum, then, the cell body, dendrites, axones with their collaterals and telodendria represent the different portions of the neurones as discovered by the Golgi method. It is obvious that the closer the analysis, the more certain and distinct becomes the view of the relative morphological independence of the nerve units. Even of the existence of a soldering inter-substance we have very little evidence of a convincing nature. His assumes the presence of an unformed ground substance between the different processes, and suggests that this may be a constituent easily affected by influences of a general nature, especially those of nutrition. On the other hand, von Lenhossek argues that no one has seen this intermediate cement substance, and believes that it is possible to get along with the view which looks upon the plasma stream or lymph stream as the only substance saturating the final plexus of nerve processes and filling up the minimal interspaces of the tissue. Our knowledge of the lymphatics of the central nervous system is, however, deplorably deficient, and there is urgent need for further research in this direction.\* Ramón y Cajal's † hypothesis, according to which the penetration of neuroglia fibrils between the processes of neighboring neurones plays a part in the make and break of conduction paths, has as yet but little basis dependent directly upon anatomical observation.

To Held's views with regard to "concrecence" as a mode of interneuronal relation we have already referred in Chapter VI. In his third contribution to the structure of nerve cells Held ‡ mentions that by means of Golgi's method he has been

\* Cf. Binswanger, O. und H. Berger. Beiträge zur Kenntniss der Lymph-circulation in der Grosshirnrinde. Arch. f. path. Anat. (etc.), Berl., 1898, Bd. clii, S. 525-544.

† Ramón y Cajal, S. Algunas conjeturas sobre el mecanismo anatómico de la ideación, asociación y atención. Rev. de med. y cirug. práct. Madrid, 1895, vol. xxxvi, pp. 497-508. Translated into German in Arch. f. Anat. u. Physiol., Anat. Abth., Leipz., Jahrg. 1895, II. 4/6, S. 367-378. Cf. criticism by v. Kölliker, A. Ueber die neue Hypothese von Ramón von der Bedeutung der Neuroglia-Elemente des Gehirns. Sitzungsber. der phys.-med. Gesellsch. z. Würzburg, 1896, No. 8.

‡ Held, H. Beiträge zur Structur der Nervenzellen und ihre Fortsätze. Dritte Abhandlung. Arch. f. Anat. u. Physiol., Anat. Abth., Leipz., Supplementband, 1897, S. 273-312.

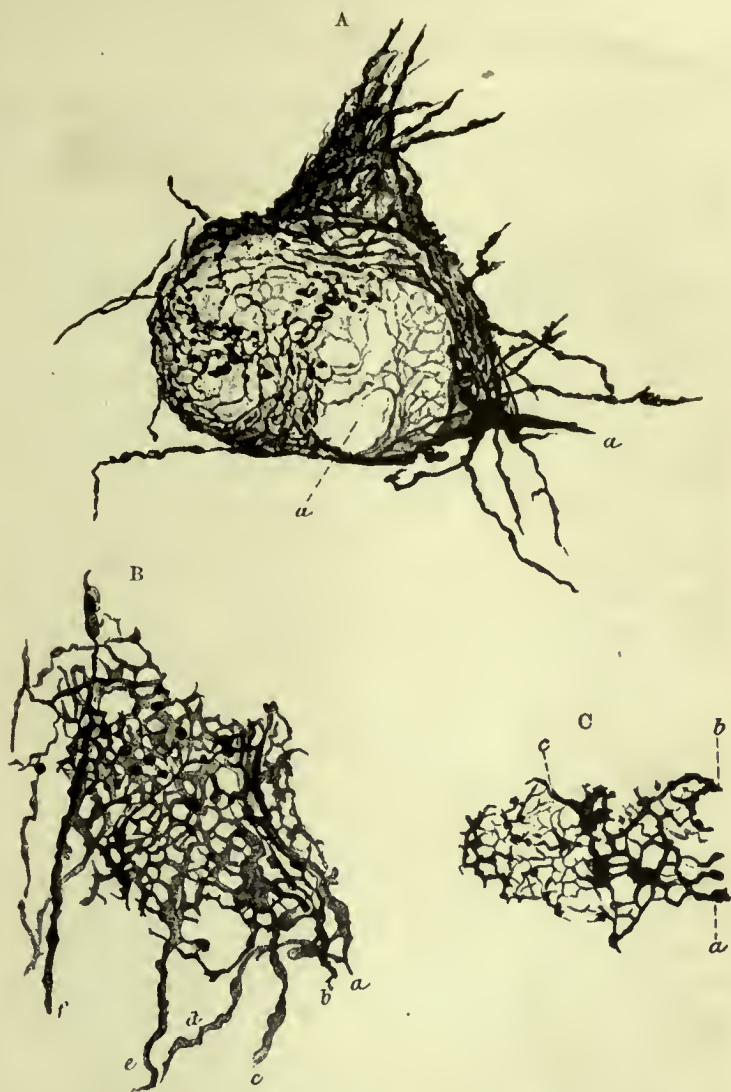

FIG. 58.—Pericellular networks believed by Held to be formed by the terminals of axones. Golgi preparations from a cat twenty days old. Sections  $70\ \mu$ . thick. (After H. Held, Arch. f. Anat. u. Physiol., Leipz., 1897, Anat. Abth., Suppl. Bd., Taf. xiv, Figs. 5, 7, and 8.) A. Cell with network from nucleus nervi cochlearis ventralis. The pericellular network surrounds the whole cell and a dendrite passing upward. The fibre *a* corresponds to one of the thickened fibres of the N. cochleæ described by Ramón y Cajal and Held. Beyond the thickened spot fibrils go to join the general pericellular network. B. Part of the network around a cell in the nucleus nervi vestibularis lateralis (Deiters). Held believes that the thickenings in the network may correspond to the aggregations of neurosomes which stain in iron-hæmatoxylin preparations. *a, b, c, d, e, f*, axones which help to form the network. C. Part of the network around a cell of the nucleus nervi cochlearis ventralis; the anastomoses of the coarser subdivisions of the fibres *a* and *b* and the larger swellings of the threads of the network are clearly visible.

able to show the formation by terminal axones of pericellular and peridendritic networks. This finding is illustrated in Fig. 58. The views of Apáthy as to the connection of many neurones with one another by means of neurofibrillæ have also been dealt with in Chapter VI.

As this book is being put through the press a novel idea with regard to intercellular substances has been suggested by Nissl.\* This investigator has through the researches of Becker, Apáthy, and Bethe (cf. Chapter XIII) recently been led to believe that certain fibrillary structures demonstrable by special methods within the protoplasm of the nerve cells are the elements actually concerned in nerve functions. On the ground of as yet rather meagre evidence he attempts to show that these fibrils also exist *outside* of the nerve cells and their processes, in certain places in great abundance. It is his opinion that the essential difference between the gray matter and the white matter of the central nervous system is not dependent, as those who have worked with Golgi's method contend, simply upon the enormous number of cell bodies, dendrites, and collaterals in the former and the immense number of medullated fibres in the latter, but rather upon the presence of a special morphological constituent. Since there is much evidence that the gray matter of vertebrates corresponds to the neuropil of invertebrates, and since in the latter Apáthy asserts that he can demonstrate as the principal constituent a network of naked neuro-fibrils (cf. Fig. 30, in Chapter VI), Nissl thinks it likely that the peculiar essential constituent of the gray matter of vertebrates is a mass of these extracellular nerve fibrils in the sense of Apáthy and Bethe. To this intercellular substance, together with the neuro-fibrils in the protoplasm of the nerve cells and their processes, he attributes the highest functions of the nervous system. He grants that our technique at present is absolutely insufficient to demonstrate the actual character of the intercellular substances, but believes that he has brought the proof that a specific constituent of the gray matter actually exists by a comparative study of the cerebral cortex of the motor area in man (Fig. 59), dog (Fig. 60), and mole (Fig. 61). It is obvious from a comparison of these three figures that the

---

\* Nissl, F. Nervenzellen und graue Substanz. Münch. med. Wchnschr., Bd. xlv, 1898, S. 988; 1023; 1060.



higher the animal the fewer cell bodies in areas of gray matter of equal size. Now this discrepancy is attributed by Ramón y Cajal and others to the easily demonstrable disproportionality

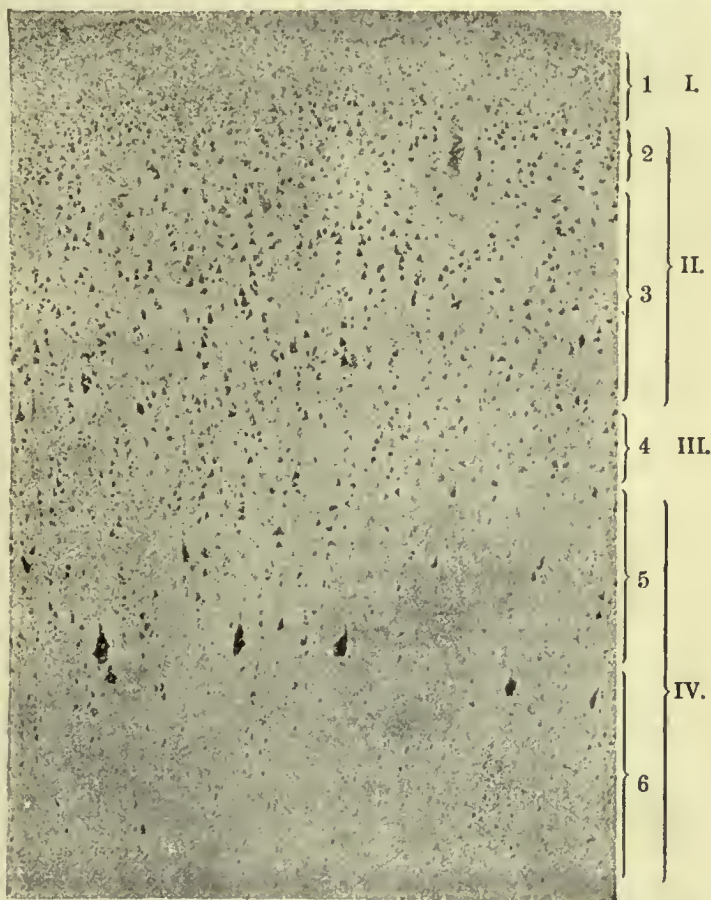


FIG. 59.—Reproduction of a photogram of a perpendicular section through the tip of the head of the gyrus centralis anterior of a healthy adult man close to the falx. Staining by Nissl's method. I. Layer poor in cells. II. Layer of pyramidal cells, containing 2 = layer of small pyramidal cells (= 2. Meynert's layer) + 3 = layer of large pyramidal cells (= 3. Meynert's layer). III. Layer of small cells (= 4. Meynert's layer). IV. Internal (6) and external (5) zone of the layer of medullated fibres (= 5. Meynert's layer). The region marked 5 corresponds to the ganglion-cell layer of Hammarberg and the region marked 6 to the spindle-cell layer. (After F. Nissl, Münch. med. Wehnschr., Bd. xlv, 1898, S. 1027, Fig. 3.)

of development of the dendrites and collaterals pertaining to the cerebral neurones of the different animals, but Nissl denies

the adequacy of this explanation. He asserts that many of the structures which appear to be, and are described as, dendrites of the pyramidal cells in Golgi preparations can not possibly

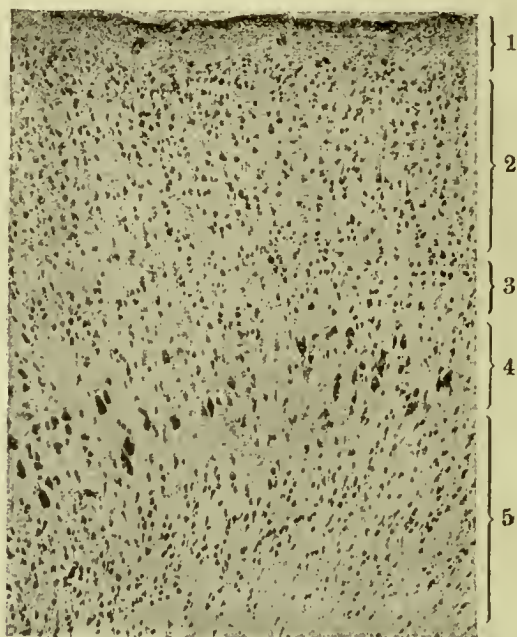


FIG. 60.—Reproduction of a photogram from a perpendicular cortical section through the summit of the gyrus just in front of the sulcus cruciatus of an adult dog close to the falx. Staining by the method of Nissl. 1 = cortical layer free from cells; 2, subdivisible into a narrower external and a broader internal zone, but in no way homologous with II of Fig. 59. On the other hand, 2 in Fig. 60 corresponds to 3 in Fig. 61; 3 in Fig. 60 corresponds to 4 in Fig. 61; (4 + 5) = layer of medullated fibres corresponding to 5 + 6 in Fig. 59, and also to 5 + 6 in Fig. 61. That is, 4 in Fig. 60 corresponds to 5 in Fig. 61, while 5 in Fig. 60 = 6 in Fig. 61. (After F. Nissl, *Munch. med. Wchenschr.*, Bd. xlv, 1898, S. 1027, Fig. 4.)

be dendrites at all, and maintains that in any case in layer II (Meynert's 2. and 3. layers) of Fig. 59, there must be a substance present which is entirely absent or at most present in but small amounts in the homologous layer in Fig. 60 and Fig. 61. A difference in the number of nerve-cell processes, glia cells, and glia fibres sufficient to account for the inequality in the different specimens is, he believes, absolutely impossible.

This view of Nissl's is certainly most interesting, and, coming from so high a source, worthy of the most thoughtful consideration. Should it turn out that besides the nerve cells (or

neurones) and the glia cells and their fibrils these peculiar inter-cellular substances do really exist, the writer confesses that he would not be much surprised. Nor is it unthinkable that inter-cellular substances in the nervous system, if present, could be of the highest functional importance, for in other tissues we have not a little evidence that intercellular substances play an important rôle in physiological processes. One has only to remember the fluids of the blood and the fibrils of the connective tissues, for example of tendons, to satisfy himself in this regard. No one, however, hesitates on this account to believe that blood cells and connective tissue cells exist, and that they are of paramount importance; similarly, even were interneuronal substances of great functional significance demonstrated in the nervous sys-

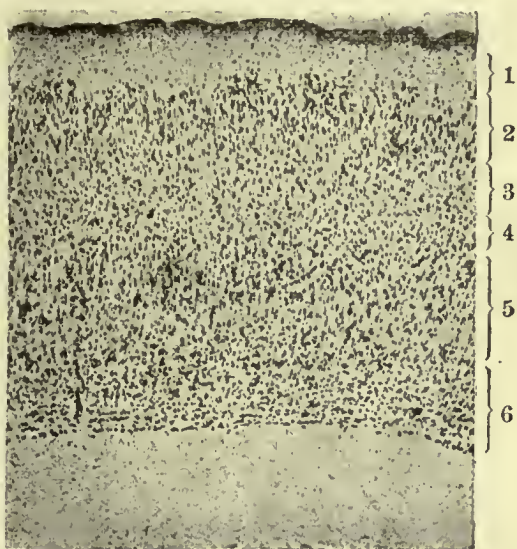


FIG. 61.—Reproduction of a photogram of a perpendicular section through the cerebral cortex of a mole, 1 mm. in front of the crucial suture close to the falx. Staining by the method of Nissl. 1 = external layer free from cells; 2, characteristic type of cell arrangement in all cortical areas connected with the olfactorius, especially in the lobus pyriformis; 3 (= 2 of Fig. 60, except the thin cell-layer adjoining the cell-free layer, which reminds one still of 2 of Fig. 61); 4 (= 3 of Fig. 60); 5 (= 4 of Fig. 60); 6 (= 5 of Fig. 60). (After F. Nissl, *Münch. med. Wehnschr.*, Bd. xlv., 1898, S. 1027, Fig. 5.)

tem, no one surely would draw the absurd conclusion that nerve cells or neurones do not exist, or that they are of but little functional value.

Brief reference only is necessary to the hypothesis of Rabl-

Rückhard \* and the modifications and extensions of it by Duval,† Tanzi, and others.‡ The whole doctrine by means of which sleep, anæsthesia, the phenomena of hysteria, double personality, etc., are to be explained by amœboid movements of the dendrites, or the so-called "retraction theory," appears to be based upon (1) the single observation of Wiedersheim with regard to amœboid movements of the processes of nerve cells in transparent animals like *Leptodora hyalina* and (2) the undulatory movements of the distal processes of the olfactory peripheral neurones. The idea has been severely criticised by von Kölliker,§ and it is worthy of note that a theory so feebly supported by facts has been so widely accepted and made the basis of a mass of clinical generalizations.

---

\* Rabl-Rückhard, H. Sind die Ganglienzellen amœboid? Eine Hypothese zur Mechanik psychischer Vorgänge. Neurol. Centralbl., Leipz., Bd. ix (1890), S. 199.

† Duval, M. Hypothèses sur la physiologie des centres nerveux; théorie histologique du sommeil. Compt. rend. Soc. de biol., Par., 1895, 10. s., ii, pp. 74-77.

‡ Tanzi. I fatti e le induzioni nell' odierna istologia del sistema nervoso. Rivista sperim. di freniatria, vol. xix (1893).

§ von Kölliker, A. Kritik der Hypothesen von Rabl-Rückhard und Duval über amœboide Bewegungen der Neurodendren. Sitzungsber. der phys.-med., Gesellsch., Würzburg (1895), 9. März.



## SECTION III.

### THE INTERNAL MORPHOLOGY OF NEURONES.

---

#### CHAPTER X.

##### STUDIES BY METHODS WHICH REVEAL THE INTERIOR OF NEURONES.

Internal morphology of neurones—Investigations of Remak, Max Schultze, and others—Doctrine of a fibrillary structure—Studies of Flemming and Dogiel—Method of Nissl—Stainable and unstainable substances of Nissl—Investigations of von Lenhossék.

SUFFICIENT has been said to make apparent the extraordinary significance of the methods of Golgi and of Ehrlich for the investigation of the nerve structures. Certain it is, that with regard to the external form of the neurones, the general interrelations of these cells and their processes, the origin of peripheral nerve fibres from cells in the nerve centres, and the establishment of the existence of channels accessory to the main conduction by means of collaterals, these methods have led to clearer and more definite knowledge than any others hitherto employed.

But a knowledge of the external form and connections of nerve cells is by itself necessarily insufficient, and if we are ever to gain any adequate idea of the relation of the morphology of nerve cells to their complex functions, the methods described must be supplemented by others which enable us to penetrate into the interior of the individual neurones, and to become acquainted with the structure of the protoplasm of which they are made up. Here we enter one of the most obscure domains in the whole of histology. We stand before the cells and their ultimate structure in the position occupied by histologists a century ago as regards the individual organs and tissues. The desirability of becoming conversant with the morphological relations existing inside the nerve cells becomes all the more

obvious when one thinks of the possibility of ultimately being able to trace a direct bearing of these upon function. When we remember not only the functions which the nerve cell possesses in common with all cells, but also the remarkable capacity it exhibits for responding to external irritation, and apparently for recording and reproducing the happenings which go on within it, processes which in groups of neurones we recognize in what we call habit and memory, the significance of such a possibility becomes evident.

Let us turn for a few moments to a consideration of the studies which have already been made with the object of gaining an insight into the internal structure of nerve cells. About half a century ago, Remak\* called attention to a fibrillary structure inside the axis cylinder and cell body of certain of the nerve cells; this was afterward further studied by Wolter and Leydig in invertebrates, and by Beale, Frommann, Deiters, Kölliker, and others in vertebrate tissues, but, it must be confessed, with no very complete agreement among the various investigators.

The most notable of the earlier researches are those of Max Schultze.† This observer studied nerve cells and nerve fibres from different parts of the central nervous system of different animals, and has given us an elaborate description of his findings, which, by the way, have done much to influence the articles in the text-books ever since. The fibrillary nature of the axis-cylinder process had been described before, but Max Schultze asserted that portions of the whole cell body are fibrillary, and further, that the fibrils are to be found within all the processes of nerve cells and not simply in the axis cylinder. The differences in appearance, he thought, depend upon the amount of interfibrillar granular substance present. This substance, he states, is scanty in the axis-cylinder processes, while in portions of the cell body and in the protoplasmic processes it is often abundant. An idea of Max Schultze's conception can be gained from a study of the illustration of the large nerve cell from the brain of the torpedo taken from his article (Fig. 62). Schultze asserted that

---

\* Remak, R. Neurologische Erläuterungen. Arch. f. Anat., Physiol. u. wissenschaft. Med., Berl., 1844, S. 463-472.

† Stricker, S. A Manual of Histology, American transl. 8vo. New York, 1872, pp. 134 *et seq.*

the fibrils which he described can easily be made out in fresh cells prepared in serum without any staining or fixing reagent, but that they are best demonstrated by bichromate solutions. He further added that the nucleus lies imbedded in the finely

granular fibrillated material of the central part of the cell, but does not appear to stand in any direct connection with the distinct fibrils

covering the external surface. It was also his idea that the fibrils which compose the axis cylinder result from the collection into a group of the fibrils from the arborescent processes of the cell; that is to say, that the fibrils which are seen traversing the substance of the ganglion cell do not originate in the cell,

but only undergo a kind of arrangement in it, and then pass to the axis-cylinder process or extend into the other branched processes.\*

In view of what we know now of the structure of nerve cells, and of what can

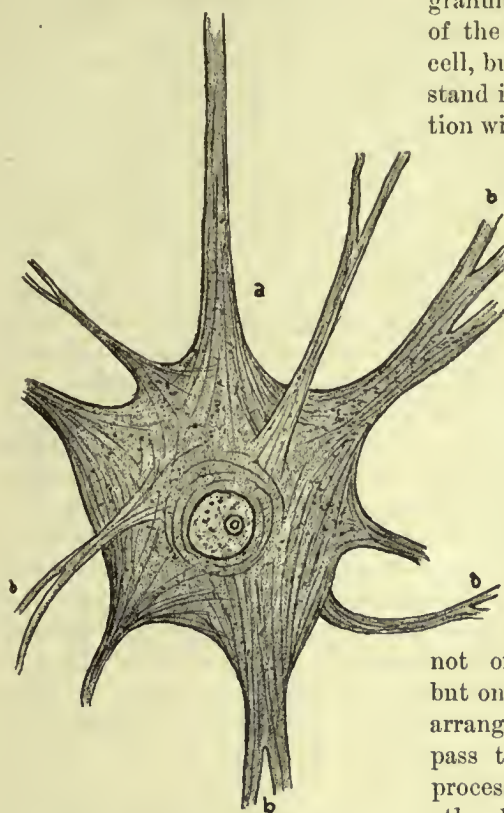


FIG. 62.—Ganglion cell from the electric lobe of the brain of the torpedo as pictured by Max Schultze. *a*, axis-cylinder process; *b*, protoplasmic processes.

be made out with the methods he employed, it is almost inconceivable how Max Schultze could have seen nerve cells as they appear in his figures (Fig. 62). That his view, however, is surprisingly near that held as the result of some of the most recent researches can not be denied. The study of the bibliography

\* *Op. cit.*, p. 137.

since his time is rendered difficult by the fact that different observers have used different terms to indicate the same thing—in fact, nowhere in histology, perhaps, has there been more confusion than in dealing with the granules and fibrils within nerve cells.

The doctrine of the fibrillary structure of the nerve cell was supported strongly by Boll, Schwalbe, and Ranvier. This view soon met with opponents, however, among whom Arndt and Key and Retzius were, before Nissl's publications, the most important. The first, in 1874,\* describing the structure of the spinal ganglion cells, spoke of the presence in them of different kinds of "elementary spherules," which varied in size and in general appearance. Key and Retzius† declared that the ground substance of the spinal ganglion cell was homogeneous, but that in it numerous strongly refractive round or oval granules were present; and they thought that the appearance of a concentric striation or fibrillation could be simulated through the arrangement of these granules in rows. Flemming, in 1882,‡ saw granules within the cells which would stain with nuclear dyes, azo dyes, and hæmatoxylin, but nevertheless affirmed a fibrillary structure of the central cells, and of a tortuous or much-curved threadwork within the spinal ganglion cells between the granules. He did not believe, however, that in the spinal ganglion cells there were long connected fibrils, such as the earlier observers had described, but thought that the cell body was in the main constituted of numerous, evenly distributed, very short threads, which showed sometimes finer or coarser thickenings upon them, observations which were supported subsequently by E. Müller.\* Flemming has recently

---

\* Arndt, R. Untersuchungen über die Ganglienkörper des Nervus sympathicus. Arch. f. mikr. Anat., Bonn, Bd. x, 1874, S. 208-241.

† Key, E. A. H. and G. Retzius. Studien in der Anatomie des Nervensystems und des Bindegewebes, 4to, Stockholm, 1876.

‡ Flemming, W. Beiträge zur Anat. u. Embryol. als Festgabe für J. Henle. 1882, Bonn, S. 12. In this article the previous bibliography is thoroughly reviewed. Cf. also, Ueber den Bau der Spinalganglienzellen bei Säugethieren, und Bemerkungen über den der centralen Zellen. Arch. f. mikr. Anat., Bonn, 1895, Bd. xlv, S. 379-394, and Die Structur der Spinalganglienzellen bei Säugethieren. Arch. f. Psychiat. u. Nervenkr., Berl., Bd. xxix (1897), H. 3, S. 969-974.

\* Müller, Erik. Untersuchungen über den Bau der Spinalganglien. Nord. Med. Ark., Stockholm, 1891, n. F., i, 1-55.



published two other articles\* in which he warmly supports the doctrine that fibrils exist inside the nerve-cell protoplasm. In Fig. 63, taken from one of these, the fibrils are pictured. Kronthal and Dogiel have also expressed themselves in favor of the view of a fibrillary structure for certain at least of the nerve cells.

Since 1885 there has been in certain quarters a lively reaction against this view, Nissl, of Frankfort (now of Heidelberg), and von Lenhossék, of Würzburg, representing its most vigorous opponents. In that year Nissl published the first of a series of articles† in which he laid stress upon the appearances to be made out in tissues hardened in alcohol and stained in basic anilines, such as magenta red and methylene blue. Although the structures described by Nissl had been observed earlier by Flemming and by Benda, it was through the introduction of Nissl's methods, which bring them especially well into view, that their arrangement in the protoplasm and their significance for the function of the cell could first be studied.

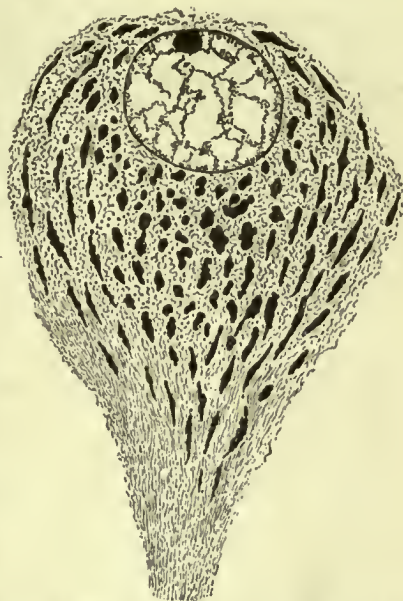


FIG. 63.—Nerve cell from the region of the ventral column of gray matter of the spinal cord of *Gadus*. Sublimate fixation; hæmatoxylin staining. (After Flemming.) The axone is seen coming off from the lower end of the cell. In the axone and at its origin in the cell body a fibrillary appearance is seen. In the interior of the cell body the spindle-shaped granular masses are deeply stained, while between them are Flemming's fibrils, cut generally obliquely or transversely.

\* Flemming, W. Ueber die Struktur centraler Nervenzellen bei Wirbeltieren. Anat. Hefte, I. Abth., 19. Heft (Bd. vi, H. 3).

† The principal contributions of Franz Nissl concerning the structure of nerve cells are the following: Ueber die Untersuchungsmethoden der Grosshirnrinde. Tagebl. d. 58. Versamml. deutsch. Naturf. u. Aerzte in Strassburg (1885), S. 506.—Ueber den Zusammenhang von Zellstruktur und Zellfunction in der centralen Nervenzelle. Tagebl. d. 61. Versamml. deutsch. Naturf. u. Aerzte in Köln (1888).—Die Kerne des Thalamus beim Kaninchen. Tagebl. der 62. Versamml. deutsch. Naturf. u. Aerzte in Heidelberg (1889).—Ueber

Nissl's early methods consisted of staining tissues hardened in alcohol with Magenta red or methylene blue and clearing in oil of origanum. The method has undergone several modifications, the most recent of which will be given here, inasmuch as it does not seem to be so generally known as it should be. In an article\* published in 1894 Nissl describes it as follows: Small blocks of tissue are hardened in ninety-six per cent alcohol and fastened by Weigert's method with gum arabic without imbedding. The sections are received in ninety-six per cent alcohol and stained in a watch glass. The stain is to be heated over the spirit flame until small bubbles arise which make a crackling noise ( $65^{\circ}$ — $70^{\circ}$  C.); sections are then transferred to aniline-oil alcohol until differentiated. The process of differentiation is ended when no more coarse clouds of color go off into the fluid. The section is then transferred to the slide, dried with filter paper, after which some drops of oil of eaje-

---

die Veränderungen der Nervenzellen am Facialiskern des Kaninchens nach Ausreissung des Nerven. *Allg. Ztschr. f. Psychiat., etc.*, Berl., Bd. xlviii (1891-'92), S. 197.—Ueber experimentell erzeugte Veränderungen an den Vorderhornzellen des Rückenmarkes bei Kaninchen mit Demonstration mikroskopischer Präparate. *Allg. Ztschr. f. Psychiat., etc.*, Berl., Bd. xlviii (1891-'92), S. 675-682.—Mittheilungen zur Anatomie der Nervenzellen. *Allg. Ztschr. f. Psychiat., etc.*, Berl., Bd. I (1893).—Ueber Rosin's neue Färbemethode des gesammten Nervensystems und dessen Bemerkungen über Ganglienzellen. *Neurol. Centralbl.*, Leipz., Bd. xiii (1894), S. 98; 141.—Ueber eine neue Untersuchungsmethode des Centralorgans speciell zur Feststellung der Localisation der Nervenzellen. *Centralbl. f. Nervenh. u. Psychiat.*, Coblenz u. Leipz., n. F., Bd. v (1894), S. 337-344; also in *Arch. f. Psychiat.*, Berl., 1894, Bd. xxvi, S. 597-612.—Ueber die sogenannten Granula der Nervenzellen. *Neurol. Centralbl.*, Leipz., Bd. xiii (1894), S. 676; 781; 810.—Mittheilungen über Karyokinese im centralen Nervensystem. *Allg. Ztschr. f. Psychiat.*, etc., Berl., Bd. li, 1894, S. 245.—Bernhard von Gudden's hirnanatomische Experimentaluntersuchungen. *Allg. Ztschr. f. Psychiat.*, etc., Berl., Bd. li, 1894, S. 527-549.—Der gegenwärtige Stand der Nervenzellen-Anatomie und Pathologie. *Centralbl. f. Nervenh. u. Psychiat.*, Coblenz u. Leipz., n. F., Bd. vi (1895), S. 1-21.—Ueber die Nomenklatur in der Nervenzellen-anatomie und ihre nächsten Ziele. *Neurol. Centralbl.*, Leipz., Bd. xiv (1895), S. 66; 104.—Mittheilungen zur pathologischen Anatomie der Dementia paralytica. *Arch. f. Psychiat.*, Berl., Bd. xxviii, 1896, S. 987-992.—Ueber die Veränderungen der Nervenzellen nach experimentell erzeugter Vergiftung. *Neurol. Centralbl.*, Leipz., Bd. xv (1896), S. 9.—Ueber die örtlichen Bauverschiedenheiten der Hirnrinde. *Arch. f. Psychiat.*, Berl., Bd. xxix, 1897, S. 1025-1027.—Die Hypothese der specifischen Nervenzellenfunction. *Allg. Ztschr. f. Psychiat.*, etc., Berl., Bd. liv (1897), S. 1-107.—Ueber Nervenzellen und graue Substanz. *München. med. Wehnsehr.*, Bd. xlv, 1898, S. 988, 1023, 1060.

\* *Centralbl. f. Nervenh. und Psychiat.*, 1894.

put are applied and the sections are again blotted with filter paper. A few drops of benzine are poured on, then some benzine-colophonium, and the slide is heated until all the benzine gas has been driven off.

The dye is made as follows: Methylene blue B. pat., 3.75; Venetian soap, 1.75; distilled water or soft water, 1,000. The differentiating fluid has the following composition: Ten parts of colorless aniline oil and ninety parts of ninety-six per cent alcohol. Nissl obtains his aniline oil directly from the factory at Höchst, and keeps it carefully protected from the light.

The benzine-colophonium is prepared by pouring benzine upon colophonium (white rosin) and allowing it to stand for from twenty-four to thirty hours. The fluid, transparent mass which results is ready for use; the desired thickness can be obtained either by the addition of benzine or by allowing it to evaporate. In mounting, while driving off the benzine gas, the material may catch fire, but if the flame be blown out immediately, no injury is done, and the alterations produced by burning are quite characteristic and easily recognizable.

The method of Nissl permits in some respects of a very exact morphological analysis of the bodies and nuclei of the cells. His method of elective staining distinguishes within the cell bodies always two, sometimes three, constituents which are sharply separable from one another and easily recognizable. One of these constituents of the protoplasm stains intensely blue by his method, and is spoken of by Nissl as the stainable or visible formed part of the nerve cell.\* The second constituent remains entirely unstained and is spoken of by him as the unstainable—that is, the visible unformed part of the nerve-cell body. In addition to these two constituents, in many nerve cells the well-known pigmentary deposits are visible.† Leaving

---

\* Nissl says: "Bruchstücke des färbbaren, *id est*, des sichtbar geformten Theiles des Nervenzellenkörpers." Neurol. Centralb., Leipz., Bd. xiii (1894), S. 676.

† The substances which stain black with osmic acid in many nerve cells, well known to all who have employed the method of Marchi in the study of human nerve centres, have recently been made the object of especial research by Rosin. Cf. Rosin, H. Ein Beitrag zur Lehre vom Bau der Ganglienzellen. Deutsche med. Wchnschr., Leipz. u. Berl., Bd. xxii, 1896, S. 495-497. Similar structures are abundant in the ganglion cells of the monkey, as I can assert from specimens shown to me by Dr. Mellus. This pigment appears as light yellowish masses in the large motor cells of the ventral horns of the spinal cord and in the motor nuclei of the me-



the pigment for the time being out of consideration, much is to be learned from a study of the characters of the stainable portion and its relation to the non-stainable portion of the cell body in different cells in various parts of the central nervous system, and upon such studies Nissl has built up an elaborate classification of nerve cells. This will be referred to in the next chapter. Any one who takes the trouble to use Nissl's method in the way that he has directed can easily convince himself of the reliability of his descriptions. The stainable portions in the nerve cells show a series of different forms; smaller and larger granules of regular or irregular shape, groups of granules, and rows of granules can be made out. Often the stainable masses are arranged in threads, sometimes smooth, sometimes rough, and varying in thickness, course, and length. Often larger structures, regularly or irregularly shaped, are to be seen, which stain with varying degrees of intensity. Some of them appear homogeneous; others show an internal constitution, complex and difficult to describe. Of the larger bodies, three varieties are especially noteworthy:

(1) The so-called nuclear caps (*Kernkappen*), stainable masses which possess the form of regular, sometimes of irregular cones, each hollowed out internally like a cap, corresponding to one pole of the nucleus upon which it sits. There may be two of these nuclear caps within one cell body, correspond-

dulla; in the pyramidal cells of Betz in the cerebral cortex; in the cells of the nucleus dorsalis and in other parts of the central nervous system. Curiously enough, when the pigment is present in masses in the nerve cell the tigroid aggregations appear to be absent from a portion of the protoplasm in which the pigment is situated. The pigment here described is not identical with that of the locus cœruleus, the substantia nigra, the substantia ferruginea, etc. The relation of the substance or substances here concerned to what we have been accustomed to look upon as pigmentary deposits should be further investigated. Rosin believes that the pigmentary substance is allied to fat. It not only stains black with osmic acid, but if the tissue be previously treated with alcohol and ether the osmic reaction, it is said, is not obtainable. Acetic acid has no effect upon the reaction. According to Pilez, Obersteiner, and others, the light yellow pigment appears at different periods of life in different nerve cells; thus in the cells of the spinal ganglia it is first found at the sixth year, while in the spinal cord it appears first at the eighth year of life. As age advances the amount of pigment in the nerve cells gradually increases, a fact entirely consonant with the idea that the pigment is a result of catabolic metabolism. Van Gieson refers to the pigment as "metaplasm granules."



ing to two opposite nuclear poles, and occasionally, according to Nissl, cells are seen in which three such caps are present.

(3) So-called wedges of division (*Verzweigungskegeln*), stainable masses which fill completely the angle at the point of division of a nerve-cell process.

(3) Spindles, oblong or spindle-shaped stainable masses which are thick in the middle and become thinner toward the end, occasionally running out into threadlike forms. One-sided and double-sided spindles exist.

Any one of these forms may be vacuolated, as has been pointed out by Nissl, von Lenhossék, Held, and others.

Von Lenhossék, who has also strongly opposed the idea of a fibrillary structure for nerve cells, has in the second edition of his book \* given us a very accurate description of the appear-

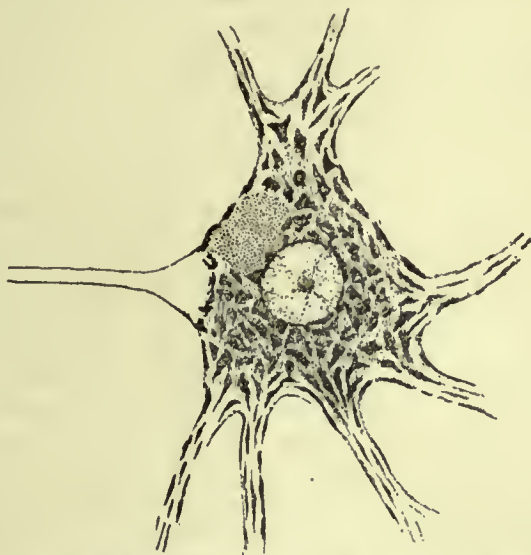

FIG. 64.—Large motor ganglion cell from the ventral horn of the spinal cord of the ox. Thionin staining. (After von Lenhossék.)

ances within the cells of the ventral horn and the cells of the spinal ganglia. Ventral horn cells, examined fresh or in an indifferent fluid, show little if any structure. The protoplasm is seen as a smooth, glistening, indistinctly granular substance in

---

\* von Lenhossék, M. *Der feinere Bau des Nervensystems im Lichte neuester Forschungen*, 2te Aufl., Berlin, 1895.

which sometimes a slight concentric arrangement and, in the region of the processes, an indistinct longitudinal striation can be made out. The yellowish granular pigment is very evident in the fresh cells. As a staining method, von Lenhossék has found that thionin (Fig. 64) yields results as good as, if not better than, those obtained with methylene blue, and my own experiments with this dye have been equally satisfactory, though in my experience crystalline deposits have been more frequent in preparations stained with thionin than in those stained with methylene blue. Von Lenhossék very properly objects to the term "granules" for the stainable substance, the masses ordinarily referred to being much too coarse to be so designated. He has pointed out, further, the differences in appearance dependent upon thickness of section and upon whether the median or tangential be the mode of sectioning employed. He has described the differences in size and concentration of the stainable masses in different animal species, and states that the chromophile masses are especially coarse, both relatively and absolutely, in the ventral-horn cells of the rabbit. He has laid stress upon the differences in appearance in the different parts of the cell; thus, the arrangement in the centre is often quite different from that visible at the periphery of the cell body, and the stainable masses in the dendrites again show different characters. He has further pointed out differences in internal character between the typically stellate-shaped cells of the ventral horns and the oval elements which are met with there, and attributes the differences in shape of the "chromophile corpuscles," as he calls the masses of stainable substance,\* to developmental rela-

---

\* The stainable substance of Nissl has recently been designated "tigroid" (from the Greek word *τιγροειδής*, spotted) by von Lenhossék, in an article entitled *Ueber Nervenzellenstructuren*. *Verhandl. d. anat. Gesellsch., Jena*, 1896, Bd. x, S. 15-21. Van Gieson in his publications refers to it as the "collagenous substance." In his article in the *Münchener medicinische Wochenschrift* of August, 1898, Nissl urges that a whole series of different substances which behave differently both morphologically and tinctorially in the "equivalent picture" are represented by what he calls the "stainable substance." He thinks it very wrong that these should be thrown all together and designated either "Nissl's substance" or "tigroid substance." He is willing, however, that the stainable substance of the motor nerve cells be called "Nisslsubstanz," and that that of the spinal ganglion cells be referred to as "Tigroidkörper." Until, however, we know more about the substances in the neurones which stain blue by the method of Nissl we need trouble ourselves but little with regard to such refinements of terminology.

tions. De Quervain\* has suggested that all the chromophile bodies represent multiples of fine granules, and von Lenhossék admits that the bodies are rarely limited by a sharp line, but that they, as a rule, show irregular, often jagged, margins, and often look at their borders as though they were broken up into small granules. He refuses to admit, however, that all such bodies represent aggregations of minute granules, a point about which more will be said when the work of Held is discussed. Von Lenhossék has studied with care the relations of the Nissl bodies in the dendrites, and finds that from always being few in number they cease to appear at a certain distance from the cell body, and as soon as the dendrite has reached a certain thinness. In the dendrites, their shape and general appearance are quite different from those of the interior of the cell body; they form long, narrow, straight, rod-shaped masses, often sharpened distinctly at the ends, so as to form definite spindles the long axes of which are parallel to that of the process. The varicosities on the dendrites in Golgi preparations von Lenhossék holds to be due to superficial collections of chromophile substance.† His description of the origin of the axone is particularly clear and accurate.

Schaffer‡ was the first to describe the peculiar behavior of the axone and the adjacent portion of the cell body as regards Nissl's staining. The axone itself, unlike the dendrites, is entirely free from the stainable substance of Nissl, as is also the portion of the cell body immediately adjacent, known as the axone hillock. This hillock is marked off by a tolerably sharp curved plane from the granular protoplasm of the cell body, and shows at its margin not infrequently a layer of especially fine granules. With Kronthal's method, the axone and axone hillock stain intensely in methylene blue, very much as in the vital staining of Ehrlich. But Benda found that when specimens thus prepared were cleared in creosote the axone and axone hill-

---

\* De Quervain, Fritz. Ueber die Veränderungen des Centralnervensystems bei experimenteller Kachexia thyreopriva der Thiere. Arch. f. path. Anat., etc., Berl., Bd. cxxxiii (1893), S. 481.

† The writer has frequently observed varicosities in the course of the dendrites in pathological tissues, and in these there appears always to be an accumulation of the tigroid masses.

‡ Schaffer, K. Kurze Anmerkung über die morphologische Differenz des Axencylinders im Verhältnisse zu den protoplasmatischen Fortsätzen bei Nissl's Färbung. Neurol. Centralbl., Leipz., Bd. xii, 1893, S. 849-851.

oek lost their color, and only the stainable substance of Nissl retained the dye in the cell body and the dendrites. Benda\* makes one exception to this statement. In the basal axones of the pyramidal cells of the cerebrum, especially of those known as the giant pyramidal cells of Betz, the collaterals which come off at right angles are visible when the preparations are stained by Benda's methylene-blue method. Just at the beginning of the collateral, a small wedge-shaped granule, in section triangular, takes up the methylene blue, the axone itself remaining quite unstainable. I have met with this observation nowhere else in the bibliography.

Von Lenhossék has not been able to make out definite fibrils in the cell body, and one gains the impression that he disbelieves in their existence. He has taken the trouble to stain the cells of the brain of the torpedo, the object of Max Schultze's classical description, by Nissl's method, and denies the existence of fibrils in them.

In his study of the spinal ganglion cells, von Lenhossék used specimens from the ox (Fig. 65) as well as human tissues.

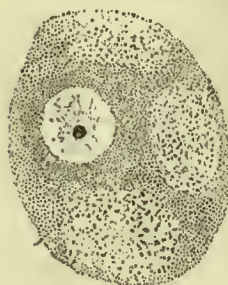


FIG. 65.—Spinal ganglion cell from the ox showing clear spaces ("Vacuolen"). Magenta staining. (After von Lenhossék.)

In the fresh cells, teased without the action of reagents under high powers, he could make out a distinct, finely granular consistence, the granules being closely and evenly arranged throughout the whole cell. He could not decide, however, from the fresh tissue whether he had to deal with actual granules or with the optic appearances of threads. In Nissl preparations, however, and in specimens stained in thionin the cell appeared nearly always to consist of two distinct layers—an internal perinuclear layer, which stained deeply in the basic dye, and a peripheral layer of lighter color, the two layers passing

gradually over into one another, although occasionally a sharp separation between the dark endoplasmatic and a lighter ectoplasmatic zone could be made out. Von Lenhossék could not find in the ox the concentric arrangement of the granules de-

\* Benda, C. Ueber die Bedeutung der durch basische Anilinfarben darstellbaren Nervenzellstrukturen. *Neurol. Centralbl.*, Leipz., Bd. xiv, 1895, S. 759-768.



scribed by Nissl in human spinal ganglion cells, at least in the majority of cells. He noticed the uneven size of the stainable masses and their arrangement into a networklike appearance, as described by other authors. In some cells of the spinal ganglia von Lenhossék found, in accordance with Flemming's observations, granules which are much coarser than those ordinarily seen in such cells, but he does not think a classification into coarsely granular and finely granular cells is desirable, inasmuch as both kinds lie everywhere intermingled and there appears to be no local connection between the extent of the cell and the size of its granules. Generally speaking, the coarser granulation is seen in the smaller cells, the large cells having always a finely granular structure, appearances which contrast strongly with those met with in the cells of the ventral horn. Von Lenhossék describes at some length what every one who has studied the spinal ganglia must be acquainted with—namely, the presence of clear areas in the protoplasm of some of the cells. These areas are to be found, as a rule, in the peripheral portion of the cell, sometimes as many as three or four being present in a single cell. They are spherical or elliptical in shape, often larger than the nucleus, and do not represent structureless

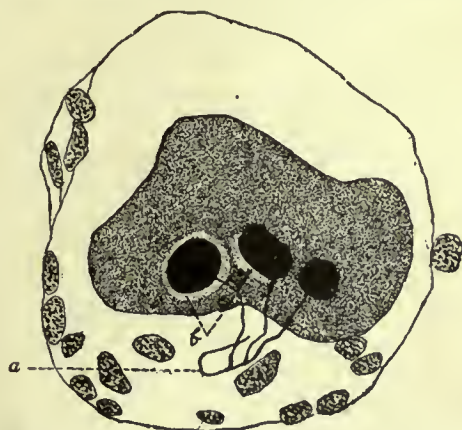

FIG. 66.—Spinal ganglion cell of *Rana Catesbiana*. (After Huber.) A side fibril, *a*, is to be seen dividing into three branches, each of which terminates in an end disc; the clear zone of protoplasm, *b*, beneath two of the discs is shown

spaces filled only with fluid, but contain normal ground substance, and besides often show in their interior a few granules widely separated from one another. The exact nature of these

vacuole-like spots is as yet not clear. It is not impossible that some of them correspond to the position of terminal end discs of side fibrils coming off from the axone and running back to the cell body, such as have been described by Huber, of Ann Arbor,\* in the spinal ganglion cells of the frog (Fig. 66). He states that there is usually found a clear zone of protoplasm surrounding the expanded end of the processes.

---

\* Huber, G. Carl. The Spinal Ganglia of Amphibia. *Anat. Anz.*, Jena, Bd. xii, 1896, No. 18, S. 417-425.

## CHAPTER XI.

### VARIETIES OF NERVE CELLS DISTINGUISHABLE BY NISSL'S METHOD.

Classifications of neurones based upon Nissl's staining method—Somatochrome, cytochrome, and caryochrome nerve cells—Arkyochrome, stichochrome, arkyostichochrome, and gryochrome nerve cells—Objections to Nissl's classification—Pyenomorphous, apyenomorphous, and parapyenomorphous conditions—Chromophile cells.

NISSL has spent several years in the most exact investigations of the nerve cells in the different parts of the nerve centres of man and animals, and has come to the conclusion that definite types or varieties of nerve cells exist, varieties which are constant not only in the same animal, but often exist characteristically in homologous localities in a whole series of animals. He has had some difficulty in finding suitable designations for these types of nerve cells. In the present state of our knowledge, a nomenclature based upon function, except, perhaps, for a few cell categories, is not justifiable, and Nissl has been compelled to classify the cells according to their morphological characteristics. According to him, all the cells in the nerve centres, except the so-called *chromophile* nerve cells, can be divided into two main classes.

The first group includes the nerve cells which possess a well-marked cell body which surrounds the nucleus completely on all sides, the protoplasm having a distinct contour. These cells Nissl calls *somatochrome* nerve cells.

To the second group (subdivided into two groups—cytochrome and caryochrome) belong those cells in which in Nissl preparations the nucleus is most in evidence; the nucleus has a clear contour, but only indications, as it were, of the cell body are present, an appearance due either to scanty development of the cell body or to the predominance in it of the unstainable substance. These cells often look as if they were naked nuclei, though by Golgi's method it can be shown that they may possess definite axones and dendrites. In some of these cells the

stainable substance may be present, though when it is, it is very unevenly distributed, being collected at definite points in the cell, the nucleus apparently being only partly surrounded by protoplasm. Such cells are to be seen in the substantia gelatinosa of Rolando. Nissl suggests that the nerve cells with an ill-developed cell body, in which the nucleus appears to be incompletely surrounded and does not exceed in size the nucleus of a neuroglia cell or of an ordinary leucocyte, be called "*granules*" (*Körner*) or *cytochrome* nerve cells. These cells are present in great numbers in the granular layer of the cerebellum. There are different varieties of these cytochrome cells, those in the

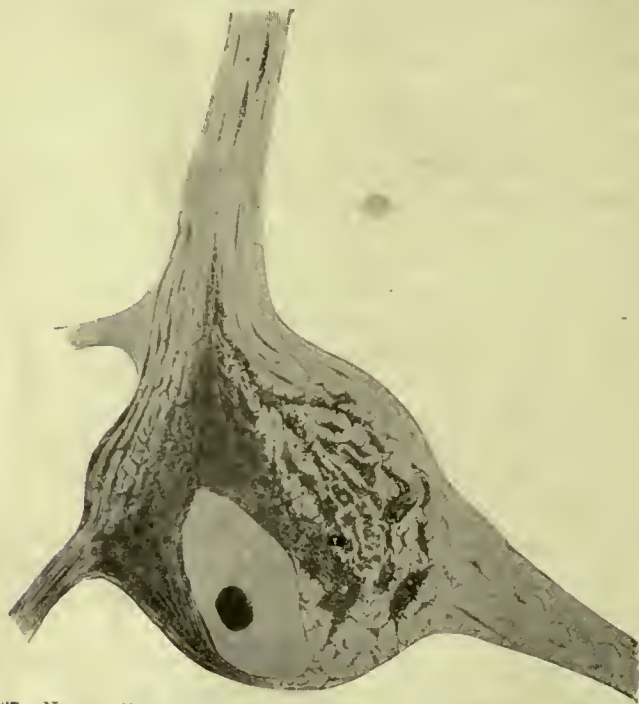

FIG. 67.—Nerve cell from olfactory bulb of rabbit. (After Nissl.) Somatochrome nerve cell of the arkyochrome variety in the parapyknomorphous condition.

cerebral cortex, those in the cerebellar cortex, and those in the olfactory bulb, for example, being by no means identical.

The second subgroup of cells in which the cell body is only indicated, but in which the stained nucleus is of the size of that of an ordinary nerve cell, or at any rate is larger than that



of a neuroglia cell, Nissl calls *caryochrome* nerve cells. Of these there are also distinct varieties—for example, those of the substantia gelatinosa of the spinal cord, and those of the

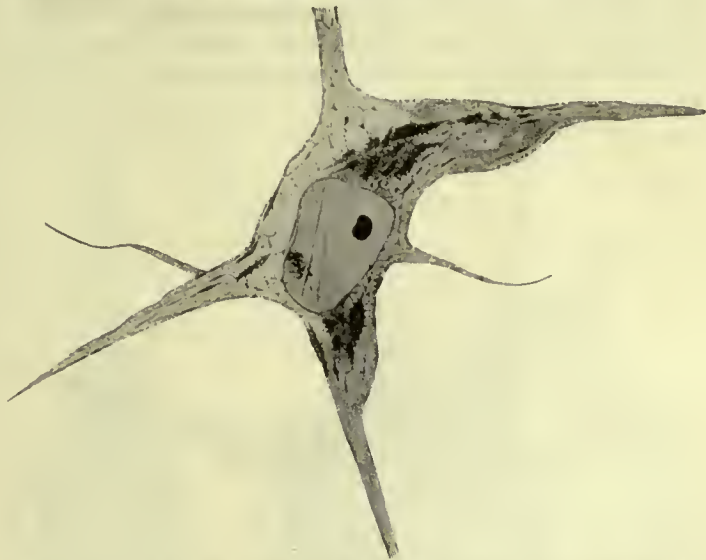

FIG. 68.—Nerve cell from dorsal nucleus of proximal portion of medulla of rabbit. (After Nissl.) Somatochrome nerve cell of enarkyochrome type in apyknomorphous condition.

ganglion habenulæ—types which for the present are designated simply by letters of the Greek alphabet.

The majority of the nerve cells, however, fall in the first group—that of the *somatochrome* cells—where the cell body, if we judge solely from its morphology, has apparently far greater relative importance than the nucleus. But this group contains a series of types of nerve cells which are distinguishable from one another in part through differences in the nuclei, but mainly through different relations of the stainable and unstainable constituents of the cell body. Nissl divides the somatochrome cells into four great groups: the *arkyochrome*, the *stichochrome*, the *arkyostichochrome*, and the *gryochrome* nerve cells. In the arkyochrome nerve cells the stainable portion of the cell body appears in Nissl preparations in the form of a network (*ἀρκυς*). The branches of this network appear to be distinctly connected, but Nissl notes that in many of the cells in this group there can be made out processes into which the distinct network of the perinuclear part of the cell body can go

over, so as to form a parallel-striped arrangement. As a sample of cells belonging to this group, Nissl pictures an arkyochrome olfactory cell (Fig. 67). Among the arkyochrome nerve cells, Nissl further distinguishes *enarkyochrome* forms from *ampharkyochrome* forms. The former show the stained constituent arranged in the form of a network which differs from

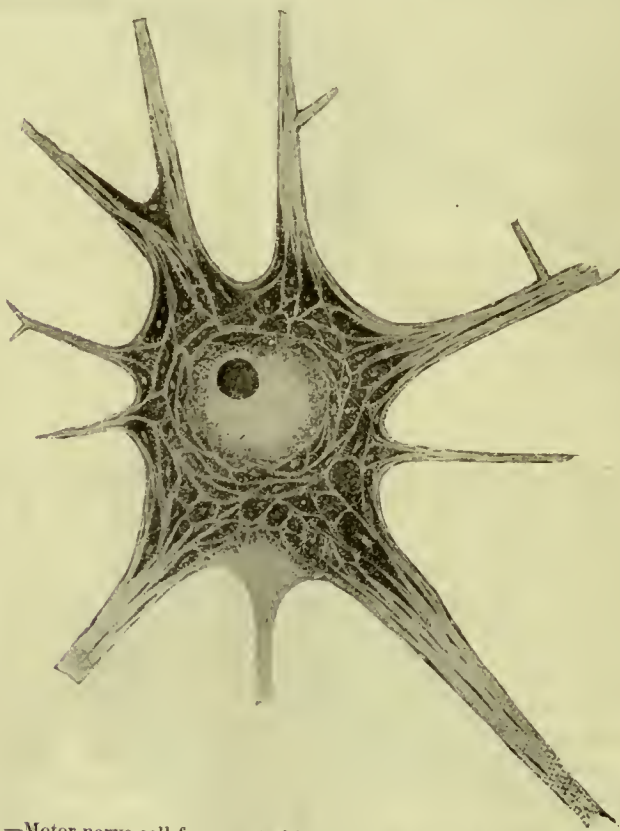


FIG. 69.—Motor nerve cell from ventral horn of gray matter of spinal cord of rabbit. (After Nissl.) Of the three lower processes, the middle one represents the axone. All the other processes are dendrites. The margins of the cells and of the masses of stainable substance appear too sharp in the reproduction. At the angle of the division of the large dendrite at the left superior angle of the cell is shown one of the "wedges of division" (*Verzweigungswinkel*). The spindle-shaped Nissl bodies are well shown, especially in the dendrites. This cell is classed by Nissl as a stichochrome nerve cell in the apyknemorphous condition.

the network in the ampharkyochrome cells, in which the intensely stained radiating nodal points of the network are con-

nected in the cell body by deeply stained very thick bridges, so that a further connected network of very deeply stainable substance is observable. Both enarkyochrome and ampharkyochrome cells are, according to Nissl, widely distributed throughout the central nervous system. The former occur in the spinal cord, but are most numerous in the large dorsal nucleus at the proximal end of the medulla (Fig. 68).



FIG. 70.

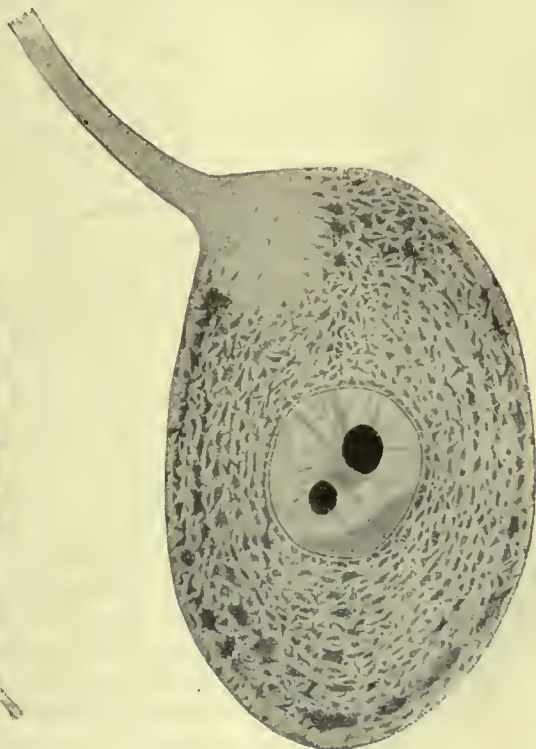

FIG. 71.

FIG. 70.—Large cell from Ammon's horn of rabbit. (After Nissl.) Somatochrome nerve cell of stichochrome variety in the pyknomorphous condition.

FIG. 71.—Nerve cell from ganglion on dorsal root of a cervical nerve of a rabbit. (After Nissl.) Stichochrome nerve cell in apyknomorphous condition. Two large nucleoli are shown within the nucleus. The axone at the upper end of the cell is seen to contain none of the stainable substance of Nissl.

In the second main group of somatochrome nerve cells, the stichochrome cells (*στίχος*), the stainable substance is arranged in the form of striæ which run in the same direction and usually parallel with the contour of the cell body, in part also with

the surface of the nucleus. These striæ, as a rule, are not continuous fibrils, but the striated arrangement is dependent in the main upon different stained elements, threads, spindles, and granules, more or less isolated and in rows. These various elements,



FIG. 72.—Purkinje cell from the cerebellar cortex of the rabbit. (After Nissl.) Somatochrome nerve cell of the arkyostichochrome variety in the apykno-morphous condition.

without being directly continuous, arrange themselves in rows running in the same direction within the cell body. Occasionally, in this group of nerve cells, there occur examples in which here and there a thread or a row of granules assumes a direction opposite to that of the general striation, an appearance, however, which would not prevent the cell from being included in this category. So far, Nissl has distinguished four types of stichochrome cells, represented by the nerve cells of motor nuclei (Fig. 69), the large cells of Ammon's horn (Fig. 70), certain cells of the cerebral cortex, and spinal ganglion cells (Fig. 71).

The third group of somatochrome nerve cells includes those of the so-called arkyostichochrome type, in which the striated appearance is united with a networklike structural character in the most intimate manner, so that one can not decide which mode of arrangement of the stainable substance is most characteristic of the cell. Nissl cites as a typical example of cells of this sort the Purkinje cells of the cerebellar cortex (Fig. 72).\*

Lastly, as a fourth group of somatochrome nerve cells, Nissl

\* Nissl in a recent article (*Allg. Ztschr. für Psychiat.*, Berl., Bd. liv (1897), S. 101) has given up the term "arkyostichochrome" and includes the cells formerly classed in the arkyostichochrome group among the arkyo-



describes the gryochrome ( $\gamma\rho\psi$ ) type, in which the stainable constituent of the cell body is entirely made up of small granules. The granules are not distributed, however, at random in the cell body, but tend to form threads or heaps, so that a distinct habitus can be attained. Nissl does not give pictures of cells of this type, but mentions that they are particularly, though not exclusively, found in the corpus striatum.

The whole series of types as revealed by his method may be classified therefore as follows:

GROUP I. SOMATOCHROME NERVE CELLS.—Cells in which the cytoplasm surrounds the nucleus completely and exhibits a distinct contour.

*A. Arkyochrome nerve cells.* The stainable substance in the cytoplasm appears to be arranged in the form of a network.

1. Type of enarkyochrome nerve cells.
2. Type of ampharkyochrome nerve cells.
3. Type of arkyochrome olfactory nerve cells, etc.

*B. Stichochrome nerve cells.* The stainable substance in the cytoplasm is arranged in the form of stripes running in a similar direction.

1. Type of motor nerve cells.
2. Type of large stichochrome cells of Ammon's horn.
3. Type of stichochrome cells seen in the cerebral cortex.
4. Type of nerve cells in the spinal ganglia, etc.

*C. Arkyostichochrome nerve cells.* Of these, up to the present, only one type has been distinguished; this would now be classed by Nissl among the arkyochrome cells.

1. Type of Purkinje cells of the cerebellar cortex.

*D. Gryochrome nerve cells.*

GROUP II. ALL NERVE CELLS NOT FALLING IN GROUP I.

*A. Cytochrome nerve cells.* Only traces of a cell body are present. The nucleus is of the size of the nuclei of ordinary leucocytes.

1. Cytochrome cells of Type  $\alpha$ .
2. Cytochrome cells of Type  $\beta$ , etc.

---

chrome cells. By far the majority of all the nerve cells in the body fall in the arkyochrome group.

*B. Caryochrome nerve cells.* Only traces of a cell body are present. The nucleus is of the size of ordinary nerve-cell nuclei, and is in every case larger than the nuclei of the glia cells.

1. Caryochrome cells of Type  $\alpha$ .
2. Caryochrome cells of Type  $\beta$ , etc.

It is Nissl's belief that this classification will, without being forced, include all nerve cells which can be found, although it is not impossible that further study may reveal forms which will necessitate an extension of the number of types. He lays stress upon the fact that between the single types transitional forms exist, sometimes rendering classification difficult. Benda has urged this as an argument against the existence of definite types, but without, as it would seem, any sufficient proof. The justification of the classification does not rest solely upon the establishment of the existence of the single types of cell structure, but is based largely upon the circumstance that cells of a wholly definite structure are situated throughout the animal series always in homologous localities. Any one who will take the trouble to stain nerve cells in different regions in different animals will be able to convince himself not only of the existence of definite types, but of their predominance in certain localities, and I can give no better advice to the beginner and to the doubting than that he study the regions suggested by Nissl in this connection—namely, the ventral and dorsal horns of the cord, the ganglion cell groups in the thalamus of rodents, in the corpus mammillare, in the pons, in the red nucleus, and in the nucleus of Deiters.

This elaborate nomenclature recommended by Nissl must not, however, be regarded as a permanent and satisfactory method of designating the varieties of nerve cells. On the contrary, it must be looked upon only as a temporary expedient. If, as is to be suspected, too much stress has been laid by Nissl upon the importance of his "stainable substance," which we now have some reason to believe represents only a portion of the supply of food stuffs in the nerve cell, such a classification can scarcely hope to stand the test of time. It would be as though an architect should attempt to classify houses according to their pantries and cellars, or an anthropologist to group men as types according to the contents of their stomachs

and intestines—methods of cataloguing useful enough at times, perhaps, but scarcely to be looked upon as ideal or permanent.

Nissl early pointed out that the single types of nerve cells may under certain circumstances show different staining relations; \* the individual members of a given group of cells belonging to one type may be palely, moderately, or intensely stained. These differences appear to depend upon the concentration of the stainable substance in the cell body. Nissl consequently designates the extremely darkly stained cells as *pyknomorphous* cells, or cells in which the stainable portions are arranged relatively most closely (*πυκνός*), while the very feebly stained cells he names *apyknomorphous*—that is, cells in which it is characteristic of the staining that the stainable masses are not arranged close to one another, but are tolerably widely separated by the non-stainable constituents of the cell body. Intermediate stages Nissl groups as *parapyknomorphous*. Flesch † described these appearances, speaking of *chromophilic* cells and *chromophobic* cells as well as transition forms, and attributed the differences to variations in the internal chemistry of the cells, which depended in part, he thought, upon differences in the development, in part upon differences in metabolism or of function.

Nissl goes further, and mentions that not infrequently the nucleus shows modifications which correspond in greater or less degree to the staining intensity of the cell body—for example, in the *apyknomorphous* cells the unstained nuclear juice is relatively more abundant than in the *pyknomorphous* examples, in which, as a rule, the nuclear framework and the stainable parts of the nucleus generally are relatively more abundant. This holds, he asserts, not only for the somatochrome cells, but also, though in less degree, for the caryochrome and cytochrome cells.

A curious and puzzling phenomenon is met with in the so-called *chromophile* ‡ nerve cells (Fig. 73). One sees often,

\* Allg. Ztschr. f. Psychiat., Berl., Bd. 1.

† Flesch, M. Ueber die Verschiedenheiten im chemischen Verhalten der Nervenzellen. Mitth. d. naturf. Gesellsch. in Bern (1887), Nr. 1169–1194, S. 192–199. Bern, P. Haller, 1888.

‡ The word *chromophile* is here used in the sense in which Nissl employs the term *Chromophilie* (Nissl, Allg. Ztschr. f. Psychiat., etc., Berl. (1896), Bd. lii, S. 8). Whether or not this is the sense in which the word is employed by Flesch and his pupils is not clear.

along with the other nerve cells, single cells or small groups of cells in which the stainable substance appears to be evenly diffused throughout the cell body, so that it is impossible to distinguish a stainable from an unstainable constituent in the cell. The explanation of these forms is as yet not entirely satisfactory. Nissl points out that they are always relatively smaller than pyknomorphous cells. It is nearly always possible

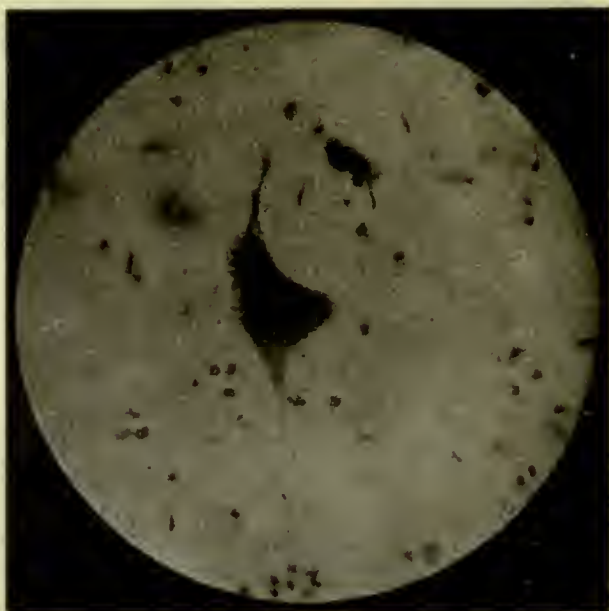

FIG. 73.—Nerve cell from the spinal cord of the dog in the so-called "chromophile" condition. This appearance is at least in the majority of instances an artefact due to the action of the reagents employed. The axon here, as in other nerve cells, appears to be free from the stainable substance.

to make out in alcohol preparations, as I have had many opportunities of observing, that at the periphery of the sections chromophile cells tend to be abundant, and there is no doubt, in my mind at least, that the majority of these correspond to the well-known artefacts which are so common in the periphery of tissues hardened in alcohol. But the chromophile cells are not entirely confined to the periphery of the sections; they may occur singly or in little groups in almost any portion of the tissue; it has seemed to me, however, that even then they are



more abundant in the neighborhood of the blood-vessels or larger tissue interspaces, and it is not impossible that in these situations they may represent artefacts due to the action of the alcohol. Nissl himself does not seem entirely clear as to their nature, but has recently expressed himself as of the opinion that they are in large part due to the action of reagents employed, although he does not deny that under certain circumstances they may have a pathological significance. For the

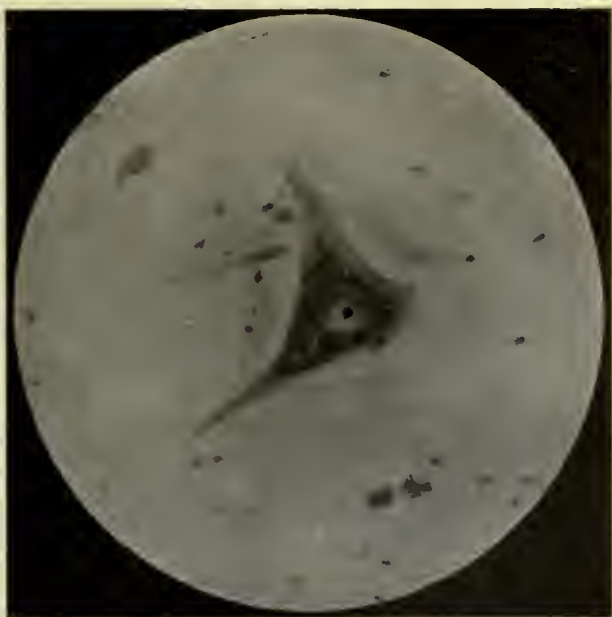

FIG. 74.—Motor nerve cell from the ventral horn of the gray matter of the spinal cord of the dog. Stained by Held's modification of Nissl's method. The tigroid bodies are distinctly visible in the protoplasm of the cell body, and especially in one of the dendrites. The axone is not shown. The borders of the nucleus are indistinct, owing to overlying cytoplasm, but the single, deeply stained nucleolus is very evident. Owing to the limits of the photographic method, the structures at only one focus show clearly.

present, however, inasmuch as they vary so markedly in appearance and localization that no normal can be established for them, he suggests that in the study of pathological alterations only those observations are of value which we know for certain to have been made upon cells which are not chromophile cells. A further study of these appearances is urgently needed, and it

is to be hoped that ere long we shall have a clearer conception regarding their significance.

In Fig. 74 is shown a nerve cell from the spinal cord of a dog. The photograph which Dr. A. G. Hoen has kindly made for me shows very well the appearances to be made out under relatively low powers.

## CHAPTER XII.

### THE NATURE OF THE TIGROID MASSES OR "STAINABLE SUBSTANCE" OF NISSL.

Nature of the "stainable substance" of Nissl—Views of Nissl, Benda, Rosin, and Held—Held's modification of Nissl's method and the results yielded by it—The influence of chemical reagents and of digestive fluids upon the Nissl bodies—Studies of Macallum and Scott.

IN medicine, as in theology and philosophy, the subjects which are most interesting and most discussed are those about which we know least, and it is not surprising, therefore, considering the scantiness of our knowledge, that the nature of these stainable portions of the substance of which the cell body is made up should have been the subject of much polemical writing. Indeed, between Nissl on the one hand and Rosin and Benda on the other (the two latter not being, however, entirely in agreement), a battle royal has been carried on in a series of articles in which too often personalities, tiresome to read and unworthy of the disputants, have been permitted to enter. Nissl has taken the ground that for the present, at least, we have no right whatever to make any positive statement regarding the chemical nature of these substances; he urges that for the time being we must remain content with a description of the morphological appearances met with in the specimens. His terms, "visible formed substance" and "organized substance," as applied to the stained portions of the cell body, introduced with the idea that they are purely objective, are in reality not so, and are, therefore, undesirable. To the term "stainable," if by this is meant "stainable by Nissl's method," there can be no objection. Rosin,\* whose studies were made largely with the triacid stain, having in mind the principles of elective staining formulated by Ehrlich, compares

---

\* Rosin, H. Ueber eine neue Färbungsmethode des gesammten Nervensystems nebst Bemerkungen über Ganglienzellen und Gliazellen. *Neurol. Centralbl.*, Leipz., Bd. xii (1893), S. 803-809. Also, *Entgegnung auf Nissl's Bemerkungen*, etc. *Neurol. Centralbl.*, Leipz., Bd. xiii (1894), S. 210-214.

the granules within the nerve cells—that is, the stainable substance of Nissl—with the basophile granules of the *Mastzellen* of Ehrlich, and concludes from his studies that the granule in the nerve cell is to be thought of more in a chemical than in a morphological sense. Benda, as regards the general significance of staining reactions, supports Rosin. Nissl has opposed Rosin's view, and has urged, first, that not all basic dyes will stain the substances concerned, and secondly, that certain acid dyes will stain them intensely, objections which he believes upset entirely Rosin's view based on Ehrlich's color theory. It is certain that basic dyes, like methylene blue and thionin, stain very beautifully the Nissl bodies; indeed, the method of Nissl depends upon this quality; but Nissl contends that the term *Basophilie* should be used only in the sense in which it has been previously defined by Ehrlich, in which event it is improper, he thinks, to apply it to the stainable substance of nerve cells. Rosin separates the "granules" in nerve cells from other basophile cell substances on account of their behavior toward the triacid mixture;\* and Benda inclines to the view that the granules in the nerve cells approach nearest in character to the  $\delta$ -granules of Ehrlich. He asserts that in numerous experiments with his method (formol freezing) he has found in the most diverse organs constituents of the cell body which behave, not only tinctorially but also morphologically, exactly as the stainable substances in nerve cells. He describes them in gland cells, liver cells, in cells of the pancreas, in the cells of some sarcomatous tumors, in certain connective-tissue cells, but especially in normal and pathological lymph glands. Ramón y Cajal † also asserts that the stainable substance of Nissl is not specific for the nerve cells, as he has demonstrated its presence in certain of the leucocytes and of the connective-tissue elements.

A flood of light has been thrown upon this portion of our subject through the recent researches of Hans Held. ‡ Held has studied the structure of nerve cells of different animals in a large number of different regions with a modification of Nissl's method, which he has himself devised.

---

\* Neurol. Centralbl., Leipz., Bd. xii (1893), S. 808.

† Ramón y Cajal, S. Estructura del protoplasma nervioso. Rev. trimest. microg., Madrid, vol. i (1896), pp. 1-30.

‡ Held, H. Beiträge zur Struktur der Nervenzellen und ihrer Fortsätze. Arch. f. Anat. und Physiol., Anat. Abth., Leipz. (1895), S. 396-416.



His modification, which I have used myself and of which I can speak in the highest terms, is as follows: The tissues are imbedded in paraffin, notwithstanding Nissl's objection that imbedding injures the nerve-cell structure. Held has found, and I can confirm his statement, that with careful paraffin imbedding no more artefacts are produced than when no imbedding at all is employed. On the contrary, it is possible with paraffin to obtain sections as thin as one micron, or even thinner, whereas sections prepared by Nissl's method are seldom thinner than from seven to eight microns, and it is by virtue of the possibility of obtaining thin sections that much of the increase in our knowledge of the nature of the stainable substances inside the cell has resulted. In order to study ordinary pathological alterations in the cells, however, sections from six to twelve or even thirty microns in thickness afford the most satisfactory results. Held fastens the paraffin section on the slide with dilute alcohol; the staining fluid consists of equal parts of Nissl's solution of methylene blue and soap and a five-per-cent aqueous solution of acetone. The sections are heated in this mixture until all smell of acetone has disappeared. (Held stains first with a solution of erythrosin, the erythrosin serving to bring out the other constituents of the cell body, the non-stainable substance of Nissl; for the study of the Nissl bodies alone this portion of his method can be dispensed with.) The sections, after staining, are allowed to remain in the blue solution until it has cooled, and are then differentiated in a one-tenth-of-one-per-cent solution of alum for from a few seconds to a few minutes, according to the thickness of the section. The specimens are then washed in water, dehydrated quickly in absolute alcohol, cleared in xylol, and mounted in benzine-colophonium. Held used as a fixing agent sometimes ninety-six per cent alcohol and sometimes picrosulphuric acid, as the latter shrinks the protoplasm less. In using this fixing agent, however, very small pieces must be employed, as it penetrates with difficulty. It has been stated by some that staining with the blue solution for twenty-four hours in the cold gives results fully as satisfactory as when heat is employed. M. Bettmann, working in this laboratory, finds that artefacts are much more frequent when high temperatures are employed. He has obtained his best results by staining for twenty-four hours at a temperature of 37° C.

Another excellent modification of Nissl's method is that of Mann, of Edinburgh.\* Sections of sublimate tissues are stained with a concentrated aqueous solution of toluidin blue. They are then differentiated, and may be counter-stained if desired. The

---

\* Mann, G. Ueber die Behandlung der Nervenzellen für experimentell-histologische Untersuchungen. Ztschr. f. wissensch. Mikr., Brnschw., Bd. xi (1894), S. 479-494.

toluidin-blue method has also been used by von Lenhossék\* with satisfaction, and recently Harris, of Philadelphia,† has published an article in which he gives a number of interesting details with regard to his modifications of this method of staining.

Held finds in sections from one half of a micron to one micron thick that the tigroid bodies present an exquisitely granular structure (Fig. 75). With high powers they are seen to be made up of masses of granules, some of the constituent granules being very small, others very coarse. They have a rounded form, and when not too close together appear in rows and radii. In some cells, where the constituent granules are very close to one another, a granular structure is recognizable only in extremely thin sections with the aid of strong immersion lenses and favorable illumination. But Held maintains that in reality all are composed of granules. In some cells the granules, instead of being grouped in clumps, appear to be more or less evenly distributed throughout the whole of the cell body.

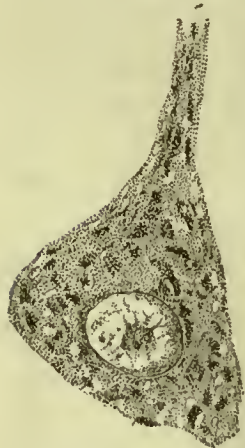

FIG. 75.—Cell of ventral horn of gray matter of human spinal cord. (After Held.) The tissue has been fixed in picrosulphuric acid and imbedded in paraffin. Sections one micron in thickness. Stained with erythrosin and methylene blue. The Nissl bodies are seen to be made up of masses of minute granules. The fine granulation of the ground substance is also apparent.

In many instances with the erythrosin-methylene-blue stain the granules are not in contact with one another, but are imbedded in a coagulumlike mass which stains violet and is easily distinguishable from the bright blue of the granules proper and the red of the ground substance—that is, unstainable substance of Nissl—lying between the tigroid bodies so that Held describes the tigroid bodies as being made up of two constituents, one granular, the other coagulumlike, with sometimes a third—namely, the vacuoles.

\* von Lenhossék, M. Ueber den Bau der Spinalganglienzellen des Menschen. Vortrag auf der Wanderversammlung südwestdeutscher Neurologen, Baden-Baden, 1896. *Arch. f. Psychiatr. n. Nervenkr.*, Berl., Bd. xxix (1896-'97), S. 346-380.

† Harris, H. F. Two New Methods of Staining the Axis-Cylinders of Nerves in the Fresh State. Some Microchemical Reactions of Toluidin-Ble. *Phila. M. J.*, vol. i, 1898, pp. 897-900.

Held describes in detail his study of fresh ganglion cells in physiological salt solution and in vitreous humor. Except the flat gray glistening nucleolus, with sometimes a vacuole and accessory nucleoli, and a homogeneous transparent nucleus limited by a narrow, doubly contoured membrane, nothing could be made out. A few dark granules only could be seen within the protoplasm, even in the most favorable cases, and he asserts that when he worked quickly the protoplasm remained almost absolutely free from granules. The tigroid bodies are invisible in fresh cells. Held treated the fresh cells with various reagents in order to make out, if possible, the action of swelling and fixing solutions upon the structure. He found that on adding methylene blue in dilute solution he obtained a result which led him to think that the blue acts upon fresh tissue as a fixing agent at the same time that it exercises a staining influence.\* With other fixing agents Held obtained dark masses after vacuolization, which he thinks represent the tigroid bodies. He believes, therefore, that we have no right to think of the tigroid bodies as of an organized nature or as representing preformed cell organs. Basing his experiments upon those of Fischer concerning the mode of action of fixing agents, he thinks that the tigroid bodies represent simply substances precipitated from solution by the action of the fixing mixtures. They are not visible in fresh protoplasm, but dark masses cor-




FIG. 76.—Nerve cell from Deiters' nucleus in the rabbit. Section three microns thick. The tissue has been exposed to the digestive action of a mixture of pepsin and hydrochloric acid at 40° C. for twelve hours. The ground substance has been dissolved out and the Nissl bodies alone remain. (After Held.)

\* In the histological course in the Johns Hopkins Medical School the treatment of freshly teased ventral horn cells with methylene blue is now employed as one easy and satisfactory mode of demonstrating the tigroid bodies in the cell bodies, and especially in the dendrites. I have repeatedly convinced myself of the homogeneous appearance of the protoplasm of the nerve cell when it is examined *immediately* after removal from the living body. Only after the lapse of a certain time do masses which correspond to the tigroid bodies become visible. I am at a loss, therefore, to understand the statements of Flemming and von Lenhossék, both investigators known for their accuracy and objectivity, when they assert that they have observed the tigroid bodies in fresh living cells.



responding to them are obtained on the addition of fixing reagents.

Held undertook a most careful and exact chemical study of the granules in alcohol tissues. Thus, he found that the tigroid bodies are insoluble in dilute and concentrated mineral acids, in acetic acid, boiling alcohol, cold or boiling ether, and in chloroform. On the other hand, they are easily soluble in dilute and concentrated alkalies. With pepsin-and-hydrochloric-acid digestion he found that the ground mass of the protoplasm vanished and that the tigroid bodies alone remained undigested (Fig. 76), the reverse of what occurred on treatment with lithium (Fig. 77). The tigroid bodies yielded no reaction with Milon's or Adamkiewicz's reagent. Held obtained, however, slightly positive results with Lilienfeld and Monti's microchemical test for phosphorus, and a considerable quantity of the gray matter of the spinal marrow after digestion with pepsin and hydrochloric acid examined by Siegfried, of the physiological laboratory of Leipsic, showed the presence of phosphorus. Held concludes, therefore, from these various reactions, that the Nissl bodies belong to the group of the nucleo-albumins, a view which agrees with the investigations of Halliburton, who found in the gray matter a nucleo-albumin which coagulated at from 55° to 60° C., and which contained as much as 0.5 per cent of phosphorus. We have here in Baltimore tested the tigroid masses a number of times for the presence of iron by Macallum's method, always with negative result. Warring-

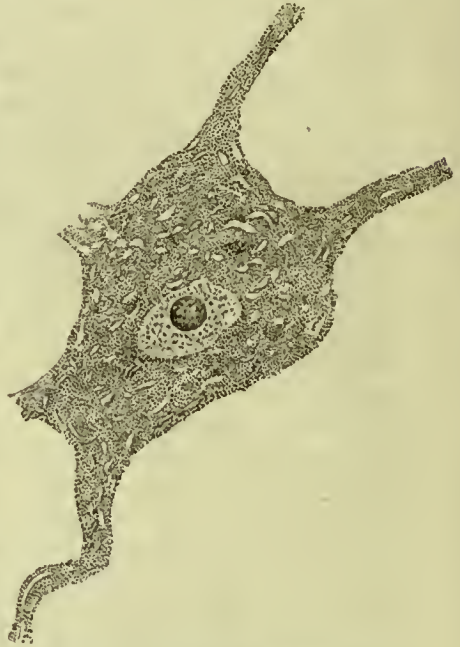

FIG. 77.—Nerve cell from the gray matter of the lumbar cord of the ox. Alcohol fixation. Treatment for four days in concentrated aqueous solution of lithium carbonate. The Nissl bodies have been dissolved out, and the ground substance alone remains. (After Held.)



ton, too, has applied the same test, but does not obtain any distinct reaction for iron.

Macallum \* himself, however, appears to have demonstrated the presence of iron in the substance. In his address before the physiological section of the British Medical Association, held in Edinburgh in July, 1898, he referred to some investigations undertaken by his pupil Scott, mentioned that iron and phosphorus exist in the substance, and stated that the Nissl spindles of the ventral-horn cells resist peptic digestion (as Held had shown), but that they are slowly digested with trypsin. He concludes accordingly that they are of the nature of a nucleo-proteid. Macallum has developed a method for the histological detection of phosphorus which seems to be more exact than the procedure of Lilienfeld. Instead of using pyrogallie acid as a reducing agent on tissues previously subjected to treatment with acid solution of ammonium molybdate, Macallum employs the hydrochlorate of phenyl-hydrazin, removing the excess with water. The lecithin may be removed from the tissues before applying the test by placing the slide, with section attached, into a Soxhlet apparatus and extracting with ether. By this method the portions of the tissue containing phosphorus assume a dark-green color.

Held believes that these nucleo-albumins, although invisible in the fresh protoplasm, are present in it in solution, and that they first take the form of Nissl bodies when the protoplasm is subjected to the action of fixing reagents. In further support of this view he found that with the different kinds of fixing reagents and with varying concentration of the same reagent entirely different histological pictures of the tigroid accumulations and of the masses lying between them could be obtained.†

---

\* Macallum, H. B. Some Points in the Micro-Chemistry of the Nerve Cells. Brit. M. J., Lond. (1898), vol. ii, p. 778.

† For example, forty-per-cent alcohol precipitates a part of the tigroid bodies much more finely granular than does ninety-six-per-cent alcohol, while the part of the granules otherwise thrown down in coagulumlike masses is not precipitated at all, so that one sees distinct spaces between the single fine granules in the larger Nissl bodies. As Nissl has always emphasized, however, for the study of pathological alterations, it matters little whether the Nissl bodies are preformed structures existing *intra vitam* or are the result of precipitation. The important point is that under normal conditions by definitely uniform methods perfectly constant microscopic pictures are obtained. Nissl has accordingly introduced the term "nerve-

If these investigations of Held are confirmed—and the accuracy with which this work has been conducted, as well as that of his previous contributions, leaves but little room for doubt upon this point—we must admit that his suggestion that they yield an index to the internal metabolism of the nerve-cell protoplasm is entirely reasonable, and that through fixation and staining we can obtain an idea of the stock in trade, as it were, at the moment inside of the nerve cells.

The relation of the stainable substance of Nissl to the nerve cells of the ventral horns has been studied by Macallum and Scott in embryo pigs. At a very early stage the ventral-horn cells are found to consist almost entirely of nucleus rich in chromatin, the protoplasm of the cell being but poorly developed. At a later period the cell body elongates, the nucleus becomes less rich in chromatin, and close to the nucleus a “cap” of peculiar nature, stainable with toluidin-blue, makes its appearance. Still later in development this stainable substance seems to be uniformly distributed throughout the cytoplasm, and finally the aggregations of the substance in the form of the spindles met with in the adult are encountered. Macallum and Scott, therefore, are of the opinion that the Nissl bodies are derived from the nucleus of the nerve cell.

---

cell equivalent” or “equivalent picture” (*Aequivalentbild*). By this he understands the microscopic picture of a nerve cell present in the tissue of an animal killed in a prescribed way and afterward treated by a definite method of preparation. He thus does not concern himself with the way a healthy nerve cell of living or dead tissue looks, but ever bears in mind a certain constant—namely, the “equivalent form” of the healthy nerve cell of the dead tissue. Any deviation from this normal “equivalent picture” of the nerve cell would indicate some alteration in the latter, and it is in this way that the alterations under physiological and pathological conditions can be described and judged.

## CHAPTER XIII.

### THE GROUND SUBSTANCE OR "UNSTAINABLE SUBSTANCE" OF NISSL.

Nature of the "unstainable substance" of Nissl—Acidophile reaction of Rosin—Comparison with sarcoplasm (Benda)—Fibrils in the "unstainable substance"—Becker's findings in ventral-horn cells—Studies of Apáthy and Bethe—Golgi's endoeellular network—Held's observations with erythrosin staining—The structure of axones—The axospongium—Neurosomes—Studies of Montgomery—Hypotheses concerning the conducting substance—The presence of centrosomes and attraction spheres in nerve cells—External reticular covering of perikaryon and dendrites.

If we are left in doubt, then, as to the exact nature and significance of the portions of the nerve-cell body stainable by Nissl's method,\* we are in a still greater dilemma as regards the character of the non-stainable part, the visible unformed substance of Nissl. While Nissl himself lays great stress upon the significance of the stainable substance, he grants that the non-stainable substance, or ground substance,† is probably just as important, indeed, possibly of much greater consequence. The quantitative relations of the two substances vary enormously in different nerve cells, almost as much, perhaps, as do their position relations. In the large motor cells of the ventral horns, for example, and in similar cells in the formatio reticularis, the stainable substance of Nissl preponderates by a considerable amount; in the Purkinje cells of the cerebellum, in the pyramidal cells of Betz, and in many other nerve cells, it is the ground substance which is often by far the more abundant.

Rosin's studies convinced him that the ground substance of nerve cells had a distinct elective affinity for acid dyes; he therefore speaks of this portion of the cell body as acidophile as contrasted with the basophile constituent, by which he means the stainable substance of Nissl. The majority of investigators,

---

\* Flemming's Interfilarmasse.

† Flemming's Filarmasse.

but by no means all, are agreed that the non-stainable substance of the cell body is closely allied to, if not identical in structure with, that of the axone and of the axone hillock. Others, however, look upon the axone as a specifically differentiated portion of the ganglion cell body, differing entirely from the rest of the cytoplasm in structure. Benda has advanced a number of interesting hypotheses in this connection, comparing the histogenesis of the nerve cell and its processes to the development of the striped muscle fibre. The cells which give rise to muscle fibres, the so-called sarcoblasts of Marchesini, contain a protoplasm which, in part, becomes differentiated to form the muscle fibrils, but in small amount persists as the so-called sarcoplasm of adult muscle. Benda describes the neuroblast of His as being made up of protoplasm and of paraplast,\* the latter belonging, according to him, to the non-stainable portion of the nerve-cell body. Benda thinks that the protoplasm of the neuroblast in the course of development is in part differentiated into a fibrillary substance constituting the nerve fibrils of the axone as well as portions of the cell body and dendrites, but in part remains undifferentiated, even in the fully developed nerve cell, as basophile neuroplassm, quite analogous to the sarcoplasm of muscle. Nissl has objected that these views are purely hypothetical, and states that the developmental course of a neuroblast can not be brought into analogy with that of a sarcoblast. Apáthy, when describing his "nerve cells" (as opposed to his "ganglion cells"), states that they produce neurofibrillæ just as muscle cells produce muscle fibrillæ. He also compares "nerve cells" with muscle

---

\* Von Kupffer (Ueber Differenzirung des Protoplasmas an den Zellen thierischer Gewebe, Schrift. d. naturw. Ver. f. Schlesw.-Holst., Kiel, Bd. i, 1875, H. 3, S. 229) first contrasted the "protoplasm" with the "paraplastm" of cells. He used the word protoplasm to indicate the internal or endoplasmic portions of the cell body—that is, those adjacent to the nucleus—while the word paraplastm designated the peripheral cell plasm. The terms had therefore only a topographical signification and had no reference to the finer protoplasmic structure, as have the words mitom and paramitom, spongioplasm and hyaloplasm. Many histologists have failed to recognize this fact—Benda, for example, quoted here, uses paraplastm in the sense of paramitom. In a recent article (Ueber Energiden und paraplastische Bildungen; Rektoratsrede, München, 1896) von Kupffer himself uses protoplasm to indicate the primary and active part of the cell, and refers to paraplastm as the secondary or passive part.



cells in their histogenesis, and believes that a "nerve cell" is no more capable of the highest functions of conduction before the appearance of the neurofibrillæ than is a muscle cell of the highest functions of contraction before its peculiar fibrillæ have been differentiated.

One thing would seem certain, if we have to deal in nerve cells with a fibrillary structure at all, the fibrils must be sought within the "non-stainable" portion (in the sense of Nissl) of the cell. Becker\* has asserted that he has stained electively with hæmatoxylin-copper the substance of the nerve cell which remains unstained by Nissl's method, and finds that it consists essentially of actual nerve fibrils. It represents, he says, the direct continuation of the primitive fibrils of the axone into the cell body and the dendrites, an idea which approaches closely to that advanced by Max Schultze. Becker's studies were made upon the motor cells, and Nissl has recently agreed that the existence of the fibrillary nature of this part of the cell body has been proved for these cells. He says, however, that Becker's method does not suffice for the decision of the question in all varieties of nerve cells, and that the nature of the structure in cells other than the motor cells must for the present remain undecided† The wonderful demonstrations of Apáthy of curiously complex fibrillary relations in the nerve cells have already been referred to at some length in Chapter VI, and need not be described again in this place. We await with considerable eagerness the appearance of Apáthy's second communication, in which he promises to compare his own findings with the observations and opinions of other investigators.

Stimulated by the results attained by Apáthy, Bethe‡ has attempted to demonstrate the fibres in the cells of vertebrates and especially in human nerve cells. The method of Apáthy does not appear to yield very satisfactory results when applied to the nervous system of higher mammals. Bethe, however, has

---

\* XX. Wanderversammlung der südwestd. Neurologen und Irrenärzte in Baden-Baden am 25. und 26. Mai 1895. *Archiv f. Psychiat. u. Nervenkr.*, Berl., Bd. xxvii (1895), S. 953.

† In a still later article, Nissl, on the ground of the preparations of Apáthy and Bethe, accepts a fibrillary structure for the nerve cells in general.

‡ Bethe, A. Ueber die Primitivfibrillen in den Ganglienzellen vom Menschen und anderen Wirbelthieren. *Morphol. Arb.*, Jena (1898), Bd. viii, S. 95-116.

developed a method, the details of which are not yet published, which stains the fibrils beautifully, even in the nerve cells of man. The principal points in the method are as follows: The Nissl bodies are first removed from the sections by treatment with ammonia, in which they are soluble. Later, the sections are treated with hydrochloric acid, and afterward with molybdic acid followed by toluidin-blue. The fibrils by this method stain of an intense blue color.

Bethe has been able to demonstrate the fibrils in different parts of the central nervous system in both cells and fibres as well as in the peripheral nerve fibres. In the axones of the peripheral nerves the fibrils appear distinctly stained, with delicate smooth contour running in a somewhat wavy course and nearly parallel to one another. Single fibrils can be followed for a distance of fifty microns and farther. They seem to be imbedded in a homogeneous ground substance. Bethe can find no indication of the honeycomb structure of Bütschli. In longitudinal sections no transverse fibrillæ can be made out connecting the longitudinal fibrils, and in cross sections of the axones the fibrils appear as isolated points in the homogeneous substance. The fibrils are more separated from one another in the axones in the peripheral nerves than in those inside the central nervous system, apparently owing to the presence of relatively larger amounts of the homogeneous substance.

The fibrils inside the nerve cells are so distinctly stained that Bethe is much impressed with their independence. He does not think that they are actually a part of the protoplasm since they seem to be so markedly differentiated from the latter. They occur everywhere in the unstainable substance of Nissl. Bethe differs from Apáthy with regard to the relation of the fibrils to one another inside the nerve cells; whereas Apáthy describes the formation of fine intracellular plexuses and networks through multiple anastomoses formed by the subdivisions of the fibrils within the cell protoplasm, Bethe is of the opinion that the fibrils do not unite at all inside the cells, and that the close perinuclear plexus which often resembles a network is in reality only a feltwork of isolated fibrils.

Thus far, Bethe has studied chiefly the Purkinje cells in the cerebellum, the pyramidal cells in the cerebral cortex, and the cells in the ventral horn and in the dorsal horn of the spinal cord.

His statements with regard to the fibrils in the dendrites and axones are of the deepest interest. He finds that not all the fibrils entering by means of dendrites into the cell body pass out by way of the axone; on the contrary, they are just as likely to pass out of the cell body by way of another dendrite, and, what is still more interesting, Bethe asserts that he has followed fibrils along one branch of a dendrite into another branch of the same dendrite, thus not entering the nerve cell at all. Again, in the pyramidal cells of the cerebral cortex he finds that most of the fibrils run longitudinally through the apical dendrites and cell body, but they are evenly distributed to all the processes at the base—that is to say, to the dendrites there as well as to the axone. The lateral dendrites of the cell are connected by means of another series of fibrils with one another and with the axone. Bethe is inclined, therefore, since he regards the fibrils as the conducting substance, to discount the general opinion that the nature of axones and dendrites is fundamentally different. As von Lenhossék says, however, in his critique\* of Bethe's paper, it is by no means proved that the interfibrillary substance is excluded from the conduction. Von Lenhossék emphasizes the fact that the marked differences between the axone and the dendrites in Golgi and Nissl preparations can not be without definite physiological significance. If the fibrils alone conduct, Bethe's studies would upset entirely the widespread view concerning the cellulipetal character of dendritic conduction. But this view of an exclusive cellulipetal conduction for the dendrites and exclusive cellulifugal conduction for the axones, has, in my opinion (cf. Section V), always been founded upon a totally insufficient basis of experience, and it would not be surprising should a conduction in both directions be proved, whether the views of Apáthy and Bethe are or are not in accord with the facts.

The statement is usually made that Golgi's method is inapplicable to the study of the interior of the nerve cells. As this volume is going through the press, Golgi† publishes a description of a fine network inside the cell body of the Purkinje cells demonstrable by a slight modification of the osmo-bichro-

---

\* Neurol. Centralbl., Leipz., Bd. xvii (1898), S. 944-947.

† Golgi, C. Sur la structure des cellules nerveuses. Arch. ital. de biol., Turin, t. xxx (1898), pp. 60-71.

mate procedure (Fig. 78). Similar networks have been seen by Veratti, an assistant of Golgi, in the large nerve cells which Golgi believes give origin to the axones of the nervus trochlearis. Golgi states that he can say

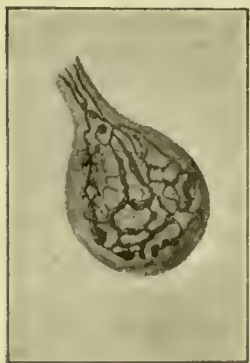

FIG. 78.—Endocellular network within a Purkinje cell of the cerebellum of *Strix flammea*, prepared by a "rejuvenescence" modification of the rapid Golgi method. (After C. Golgi, Arch. ital. de biol., Turin, t. xxx, 1898, p. 64.)

nothing concerning the significance of the endocellular network, but he is inclined to believe that his findings thus far are only a partial manifestation of finer and more complex structures. He feels sure, however, that this network has nothing in common with the classical description of Max Schultze and his school; that it has no analogies with the pictures discernible in Nissl preparations, and that it offers no correspondence with the interesting results of Apáthy concerning the nerve cells of invertebrates.

Held, in addition to his studies of the stainable part, has also turned his attention to the ground mass of the protoplasm of nerve cells; the full results of his research have been published

in an article of nearly one hundred pages, and beautifully illustrated with lithographic plates.\* He states that in sections fixed with alcohol, picrosulphuric acid, or chromic acid, it has a distinctly reticular appearance. In very thin sections he can make out granules which are extremely fine, staining on the limits of microscopic perceptibility. No fibrillæ could be observed except at the wedge of origin of the axone and in the more cytodistal portions of the dendrites, in which the tigroid masses cease to appear. Here he could make out, stained bright red in erythrosin, a fine longitudinal striation along with an arrangement of extremely fine granules in rows and pressed together, as it were, so as to give the appearance of fibrillæ. Held believed at first that he had before him the fibrils of Max Schultze. On using dilute solutions of

---

\* Held, H. Beiträge zur Structur der Nervenzellen und ihrer Fortsätze. Zweite Abhandlung. Arch. f. Anat. u. Physiol., Anat. Abth., Leipz. (1897), H. iii u. iv, S. 204-294.



chromic acid, however, and of ammonium bichromate, he did not obtain fibrils, but in the thinnest sections saw distinct foamlike structures; especially on staining with iron-hæmatoxylin without any subsequent differentiation, he obtained honeycomb pictures which correspond entirely to the pictures and descriptions of Bütschli. Held, in opposition to Max Schultze and H. Schultze among the older histologists, and Flemming, Benda, and Dogiel of the present time, is inclined to accept Bütschli's view that the fibrillæ of the older observations correspond to longitudinal layers of honeycomb cells which lie close over one another; Held will not grant, however, that the nerve cell actually possesses a honeycomb structure, since he believes that fixing agents with which it appears exercise a marked vacuolizing influence upon living nerve-cell protoplasm.\* He has worked with an extensive series of fixing reagents, including, in addition to the weak bichromate solutions used by Schultze, the fixing fluids which Bütschli has employed, and also the majority of the fluids now generally applied in the technique of modern cytology. The results he has obtained lead him to the view that the various differences met with in the descriptions of investigators in different laboratories are in large part due to the fixing factor. Nor does Held accept Rosin's view that of the two main substances in nerve cells one is acidophile and the other basophile. Relying rather upon the recent researches of A. Fischer,† and of the Italian investigator Galeotti,‡ he has come to the conclusion that the so-called elective stains depend more upon physical factors than upon purely chemical differences. In the first place, closely arranged granules absorb coloring matters much more intensely and hold them longer when subjected to differentiating fluids than loosely built parts; and secondly, the "covering power" (*Deckkraft*) of dyes has to be considered, since through covering-over constituents, stainings which are really only apparent can result.

---

\* Ramón y Cajal (*op. cit.*) has recently supported vigorously the doctrine of a honeycomb structure for the unstainable substance.

† Fischer, A. Zur Kritik der Fixierungsmethoden und der Granula. *Anat. Anz.*, Jena, Bd. ix (1894), S. 678-680; also *Neue Beiträge zur Kritik der Fixierungsmethoden*. *Anat. Anz.*, Jena, Bd. x (1894-'95), S. 769-777.

‡ Galeotti, G. Ueber die Granulation in den Zellen. *Internat. Monatschr. f. Anat. u. Physiol.*, Leipz., Bd. xii (1895), S. 440; 461.

Methylene blue, for example, is known to have a very high covering power.

Van Gieson, van Gehuchten, Ramón y Cajal, and others assert the existence of a distinct reticulum which extends throughout the cell body and all its processes (dendrites and axones). There may be, they think, a difference between the reticulum in the dendrites and that in the axones. Filling up the interstices in the reticulum and bathing it is the softer and more fluid part of the nerve cell, the cell sap. Van Gieson reports some interesting experiments made on the nerve cells of the cockroach, in which he has found it possible to squeeze out the cell sap, leaving behind only the cytotreticulum. He looks upon the cytotreticulum as the contractile part of the nerve cell-protoplasm, and believes that, extending into the dendrites, it may enter into the formation of the gemmules present on many of these processes.

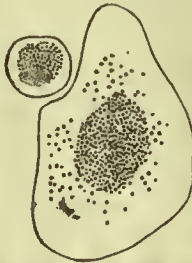

FIG. 79.—Cross sections of two axones from the nervus trigeminus of *Petromyzon fluviatilis*. (After Schiefferdecker.) The core of axone fibrils is surrounded by a peripheral layer of non-fibrillar neuropilasm.

The views which have been held regarding the structure of the axone are as divergent as those concerning the structure of the non-stainable portion of the nerve cell generally. The idea that it possesses a fibrillary structure, suggested by Remak and so strongly urged by Max Schultze and Fr. Schultze, Engelmann and von Kölliker, received important confirmation in the researches of Schiefferdecker.\* This histologist found, in the perfectly fresh nerve fibres of petromyzon, what he regards as undoubted evidence

of the existence of fibrils inside the axone (Fig. 79). The axones of the nerve cells of this animal consist, according to Schiefferdecker, of two essential constituents, the axone fibrils and a homogeneous substance, the axoplasm or neuropilasm. In petromyzon the axone fibrils tend to run in the centre of the axone, a large area at the periphery of the axone being entirely free from fibrils. This peripheral zone

---

\* Schiefferdecker, P., in Schiefferdecker u. Kossel, *Gewebelehre mit besonderer Berücksichtigung des menschlichen Körpers.*, Bd. ii, Brnswgw. (1891), S. 200.

consists entirely of neuroplasm, which also extends in among the fibrils of the central core. The fibrillary appearance is easy to make out in the axones of cyclostomes and molluscs (Rawitz).

Subsequent researches upon higher forms make it not improbable that a similar structure holds in them. It would seem, however, that in medullated nerve fibres the axone fibrils are more evenly distributed throughout the whole axone, the peripheral layer of pure neuroplasm being absent altogether or reduced to a very thin superficial film (Fig. 80). There are



FIG. 80.—Longitudinal and transverse section of medullated nerve fibres from the sciatic nerve of the frog (osmic acid and acid fuchsin). (After Biedermann.) The longitudinal section shows one node of Ranvier and two of Biedermann's segmentations. The fibrillary structure of the axone is shown in both long and cross section.

many histologists, however, who refuse to believe in the existence of actual fibrils inside the axones of higher animals. The doctrine of the fibrillary nature of the axone and unstainable portion of the protoplasm of the nerve cell has recently received support from the studies of Lugaro\* and of Levi.† The former too, in his studies of the nerve cell under pathological conditions—for example, after poisoning with lead and arsenic—finds that the fibrils may become very distinct inside the nerve cells.‡

Held's description of his findings in the axis cylinders of nerve cells is lengthy and detailed. With a large series of

\* Lugaro, E. Sul valore rispettiva delle parte cromatica e della acromatica nel citoplasma delle cellule nervose. Riv. di patol. nerv., Firenze, vol. i (1896), pp. 1-11.

† Levi, G. Su alcune particolarità di struttura del nucleo delle cellule nervose. Riv. di patol. nerv., Firenze, vol. i (1896), pp. 141-149.

‡ Lugaro, E. Sulle alterazioni degli elementi nervosi negli avvelenamenti per arsenico e per piombo. Riv. di patol. nerv., Firenze, vol. ii (1897), pp. 49-64.

fixing reagents, among which van Gehuchten's mixture (60 parts alcohol absol., 30 parts chloroform, and 10 parts acid.

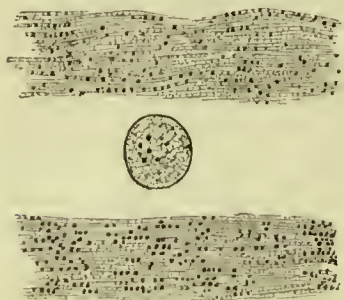


FIG. 81.—Axis cylinder in long and cross section from a spinal ganglion in the lumbar region of an adult dog. (After Held, *Arch. f. Anat. u. Physiol., Anat. Abth.*, 1897, II. 3 u. 4, Taf. x, Fig. 5.) Sublimate and acetone fixation; paraffin section 1.5 microns thick. Staining with erythrosin methylene-blue. Neurosomes and axospongium are clearly visible.

acet. glac.) yielded the most constant and satisfactory results, Held concludes that there can be no fibrillary structure of the axis cylinder if by the term fibrils one understands isolated threads running near one another. Instead of these, Held finds always a network-like appearance which in his thinnest sections is seen to be extraordinarily delicate and long-meshed. In this meshwork, which he designates the axospongium, are to be seen certain granules somewhat variable in size, though always very minute, which lie gener-

ally at the nodal points of the network, though sometimes in the spaces within the walls of the vacuole-like cavities.

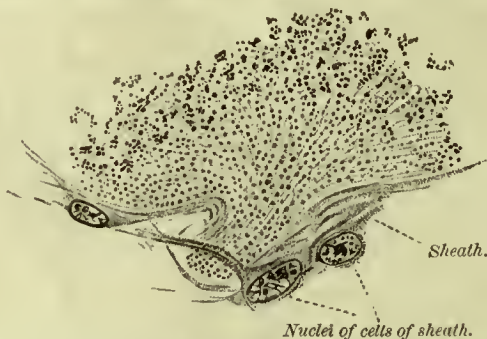

FIG. 82.—Axone hillock of a spinal ganglion cell of the dog. (After Held, *Arch. f. Anat. u. Physiol., Anat. Abth.*, 1897, Taf. ix, Fig. 4.) Fixation with sublimate-acetone; paraffin section 1.5 microns thick; staining with erythrosin methylene-blue. The Nissl bodies, the neurosomes, the cytospongium and the axospongium are visible. The arrangement of the neurosomes in rows and the longitudinal mesh formation of the axospongium is particularly distinct. The alteration in the appearance of the meshwork where the axone hillock goes over into the body of the cell is distinctly shown.

These granules—Held calls them neurosomes—are not, he states, regularly distributed either in longitudinal or cross sections of an axone (Fig. 81). The neurosomes appear to



have been observed before by Bütschli, Altmann, and others, though but little attention seems to have been paid to them. In the axone hillock the neurosomes present constantly a radially converging grouping (Fig. 82). They seem to be extraordinarily numerous in the terminals of many axones, for example, the mossy and climbing fibres of the cerebellar cortex, in those ending on the ventral horn cells (Fig. 83) and in the terminals of the axones of the peripheral olfactory neurones. Inasmuch as in the ground substance of the dendrites and cell bodies of the neurones the neurosomes are much less numerous, a ready method of distinguishing the protoplasm of terminal axones in cytological preparations from that of other portions of neurones which lie in direct contact (or conerescence) with one another is afforded us.\*

Montgomery,† in an able paper, has denied the existence of fibrillary structures in nerve cells. He supports the doctrine according to which hyaloplasm and spongioplasm are the two principal constituents of protoplasm.

Flemming‡ emphasizes again that he has admitted that his fibrils may be connected by oblique fibres running from one to another. He maintains that in any case the longitudinal fibrillation is always much more pronounced, and that it can often be seen when nothing in the way of a transverse fibrillation is discernible.

Various attempts have been made to connect the function of conduction through the protoplasm of the nerve cell with one or another of its finer histological constituents. Apáthy\* especially is convinced that his "neurofibrils" represent the essential anatomical basis for conduction, and he constantly refers to these fibrillæ as the conducting element (*das leitende Element*) in the nervous system. Bethe shares this view.

---

\* Held believes that the fibrils of some investigators—for example, those of Dogiel—are in reality identical with rows of neurosomes. He even hints that some of Flemming's fibrils represent bands of neurosomes; other fibrils described by Flemming are, Held believes, beams of the cytospongium.

† Montgomery, T. H. Studies on the Elements of the Central Nervous System of the Heteronemertini. J. Morphol., Bost., vol. xiii (1897), pp. 381-444.

‡ Flemming, W. Article Zelle in Merkel-Bonnet's Ergebnisse der Anat. u. Entwicklungsgesch., Bd. vi for 1896, Wiesbaden (1897), S. 218 ff.

\* *Op. cit.*

Axone.

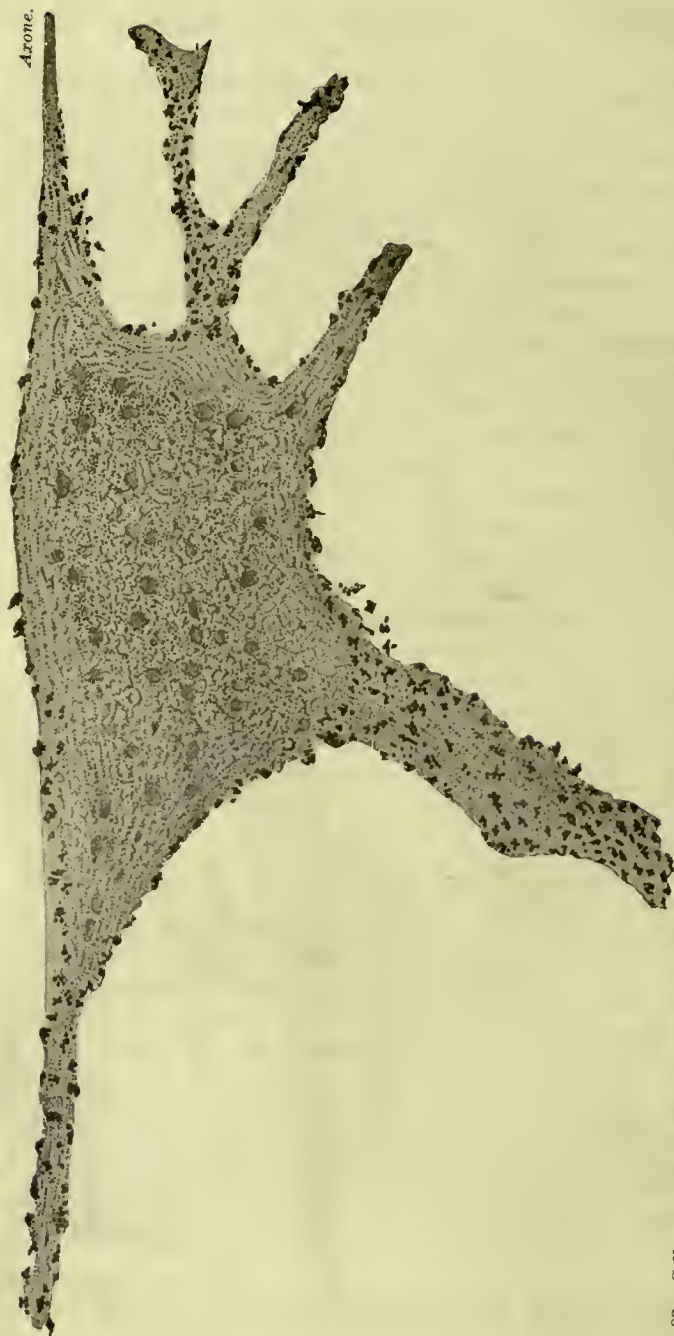

FIG. 83.—Cell from the ventral horn of the lumbar cord of an adult rabbit showing the axone and several dendrites. (After H. Held, Arch. f. Anat. u. Physiol., Leipz., Anat. Abth., 1897, Suppl. Bd., Taf. xii, Fig. 7.) The neurosomes of the end surfaces of axones terminating on the cell and its processes are stained black and look coarse. The neurosomes in the cell are finer and paler; in the dendrites and in the axone ciliated tigris. The nucleus is obvious. The nucleus was not in the plane of the section. The spherical bodies correspond to the partially precipitated tigris. Fixation in neutral chromate solution, Paraffin section five microns thick. Iron-haematoxylin staining.

It was and is still Leydig's \* opinion that the "hyaloplasm" of the nerve cell which fills up the meshes of the spongioplasm represents the conducting substance, a view which, in the main, was supported by Nansen, though the Arctic explorer assumed that the hyaloplasm is arranged, both in the axis cylinder and in the body of the nerve cell, in the form of "primitive tubules."

Other investigators assume that it is the spongioplasm which is active as the conducting agent—an opinion which would accord well with the ideas of MacCallum † with regard to the contractility of muscle.

The hypotheses of Leydig and Nansen have been vigorously opposed by Bütschli and by Pflueger. Bütschli himself is strongly of the opinion that the framework substance of the nerve-cell protoplasm, his *Wabengerüst*, must be considered to be the histological substratum of nervous conduction, since it alone extends continuously through the axis cylinder, and is accordingly the only structure in a position to underlie the phenomenon referred to. He brings forward in favor of his view the statement of Pflueger that nerve fibres can be excited only by means of currents directed longitudinally, not by currents directed transversely.

Held argues that, in view of the possibility that the so-called foam structure may be an artefact, due to the fixation of the protoplasm, it is premature to assume that the meshwork seen in fixed specimens is necessarily the conducting substance. Even if it does correspond to the structure of living protoplasm, it would be difficult to deny for the delicate transverse connecting bands the possibility of a function freely granted to the longitudinally running coarser beams of the meshwork. Held is inclined to look upon the ground substance of the protoplasm, *as a whole*, as accounting for the function of the propagation of stimuli, though he does not deny the possibility of the temporary existence of sections of this better or worse adapted for the function dependent upon alterations in vital chemical constitution.

As a matter of fact, *we do not know* the exact histological

\* Leydig, F. Der reizleitende Theil des Nervengewebes. Arch. f. Anat. u. Physiol., Anat. Abth., Leipz. (1897), S. 431-464.

† MacCallum, J. B. On the Histology and Histogenesis of the Heart Muscle Cell. Anat. Anz., Jena, Bd. xiii (1897), S. 609-620.

mechanism in the protoplasm of the neurone underlying the conduction of what we call nerve stimuli, and we should be willing to confess it. If we form hypotheses concerning it, let

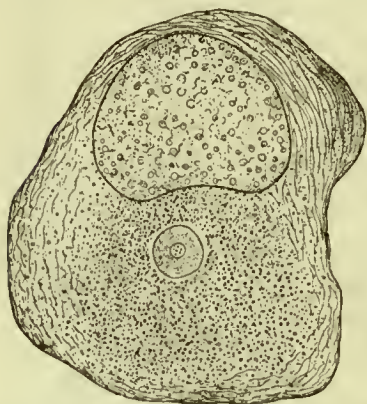


FIG. 84.—Centrosome and attraction sphere inside a spinal ganglion cell of the frog. (From Wilson, after von Lenhossék.) The attraction sphere is seen situated in the cytoplasm not far from the nucleus. Inside the attraction sphere is shown the single centrosome, which contains several centrioles.

us label them distinctly as such, and take care not to grow, through familiarity with them, into the idea that our hypotheses are actually proved facts.

Von Lenhossék\* has brought the nerve cell into still closer agreement with the general cellular structure. He has been able to demonstrate within certain of the spinal ganglion cells (Fig. 84) of the frog the presence of a definite centrosome and attraction sphere (*Centrosphäre*). Bühler† subsequently described a centrosome and attraction sphere together with archiplasmic radiations in the nerve cell of the brain of the lizard, while Dehler‡ has dem-

onstrated pole corpuscles and attraction spheres in the sympathetic cells of the frog. Up to the present time these structures, to which very important functions have been attributed by many cytologists, have not been demonstrated in the nerve cells of mammals, with a single exception to be mentioned immediately, but it is not improbable that the evidence for their existence in these also will soon be forthcoming. I find in the second portion of Kölliker's text-book, which has recently been published, that he has found centrosome and attraction sphere in a giant pyramidal cell of the posterior central gyrus of a

\* von Lenhossék, M. Centrosom und Sphäre in den Spinalganglienzellen des Frosches. *Arch. f. mikr. Anat.*, Bonn (1895), Bd. xlv, S. 345-369.

† Bühler, A. Protoplasma-Struktur in Vorderhirnzellen der Eidechse. *Verhandl. d. phys.-med. Gesellsch. zu Würzb.*, n. F., Bd. xxix (1895), S. 209-252.

‡ Dehler, A. Beitrag zur Kenntnis vom feineren Bau der sympathischen Ganglienzelle des Frosches. *Arch. f. mikr. Anat.*, Bonn, Bd. xlv (1895), S. 724-739.



thirty-year-old man.\* Schaffer † has also lately described centrosomes in the ganglion cells of cyclostomes, McClure ‡ in molluses, and Hamaker § in *Nereis*.

Margaret Lewis || has described centrosome and sphere with radiating fibrils in certain giant nerve cells of a new annelid (related to *Clymenella torquata*). She does not think, however, that the evidence yet suffices to prove that the central corpuscle and sphere of nerve cells and the centrosome and sphere of dividing cells are equivalent structures.

The significance for the cell economy of the centrosome and attraction sphere has been the subject of considerable controversial literature. While some histologists would make the centrosome the arch power, the seat of government, as it were, of the cell, and would give it precedence even over the nucleus, others, with Watase, look upon centrosomes merely as modified cytomicrosomes.

It must be confessed that in view of what we know of the relation of the centrosome to the phenomena of mitosis a *raison d'être* for this body within the nerve cell is at first thought difficult to find. It might be assumed, of course, that it has remained over from the last cell division. If the old view were correct, that ganglion cells fully formed never divide, little reason could, perhaps, be found for the persistence of the centrosome. The studies undertaken of late make it necessary, however, to hesitate before denying the possibility of division of adult nerve cells by karyokinesis; in such cells the centrosome could be of its ordinary significance. There is no ground as yet, however, for the statement that the centrosome possesses

\* Kölliker, A. Handbuch der Gewebelehre des Menschen, Bd. ii, Leipz. (1897), S. 812.

† Schaffer, J. Ueber einen neuen Befund von Centrosomen in Ganglien- und Knorpelzellen. Sitzungsab. d. k. Akad. d. Wissensch., Math.-naturw. Cl. Bd. cv, Wien (1896), S. 21-28.

‡ McClure, C. F. W. On the Presence of Centrosomes and Attraction Spheres in the Ganglion Cells of *Helix Pomatia*, with Remarks upon the Structure of the Cell Body. Princeton Coll. Bulletin, vol. viii (1896), No. 2, pp. 38-41.

§ Hamaker, J. I. The Nervous System of *Nereis virens* Sars. A Study in Comparative Neurology. Bull. of the Mus. of Comp. Zool. at Harvard Coll., vol. xxxii (1898), No. 6, pp. 89-124.

|| Lewis, Margaret. Centrosome and Sphere in Certain of the Nerve Cells of an Invertebrate. Anat. Anz., Jena, Bd. xii (1896), S. 291-299.

no functions other than those concerned in the division of the cell; indeed, it may have to do in many instances with motor activities of cells independent of those involved in mitosis. Besides, the existence of centrosome and sphere in many cells, which are not dividing and which exhibit no definite phenomena of motility, make it likely that these structures are of value to the cell in ways other than those hitherto suggested. The centrosome in nerve cells, as in other cells of the body, may appear solid or it may show numerous centrioles.

In closing this chapter reference may also be made to the peculiar and delicate investment of the cell bodies and dendrites of neurones first described by Golgi \* in his article on the spinal

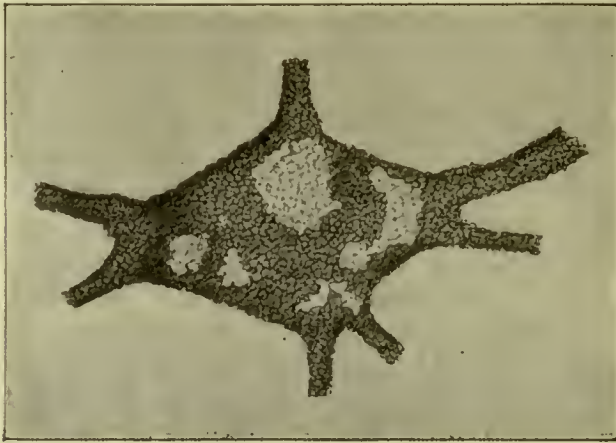


FIG. 85.—Nerve cell showing reticular investment. (After C. Golgi, *Arch. ital. de biol.*, Turin, t. xxx, 1898, p. 62.) The cell is from the ventral horn of the spinal cord of a cat.

cord in 1882, published in the *Encyclopédie médicale*. According to the Italian observer this investment presents various appearances; sometimes it is a reticular structure; sometimes it forms a continuous homogeneous layer; sometimes it appears

---

\* Cf. also Golgi, C. *Intorno all' origine del quarto nervo cerebrale e di una questione isto-fisiologica che a questo argomento si collega*. *Rendic. d. R. Accad. d. Lincei* (1893), ii. French Transl. in *Arch. ital. de biol.*, Turin, t. xix (1893), pp. 454-474. Also, *Sur la structure des cellules nerveuses*. *Arch. ital. de biol.*, Turin, t. xxx (1898), pp. 60-71.

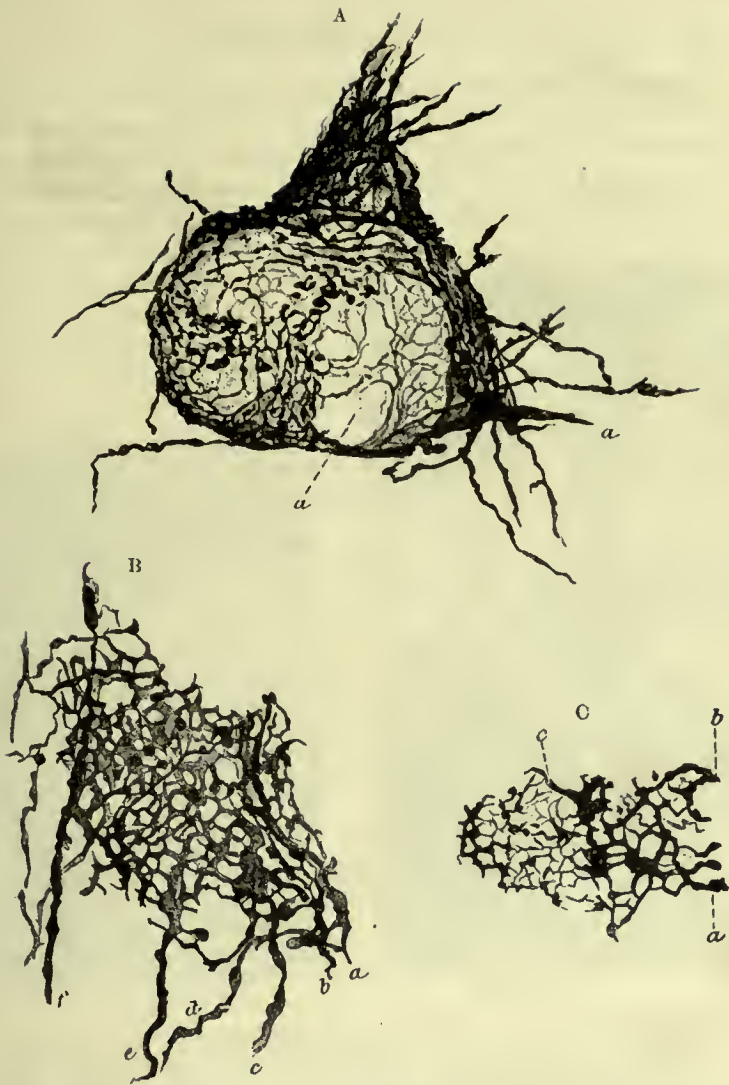
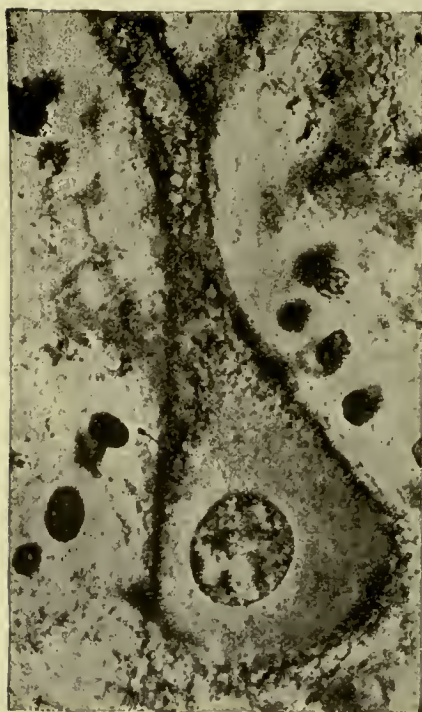
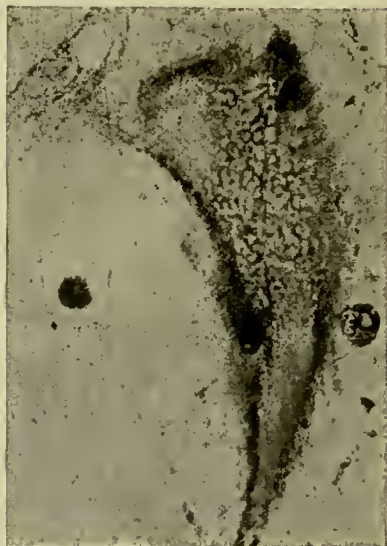

FIG. 86.—Pericellular networks believed by Held to be formed by the terminals of axones. Golgi preparations from a cat twenty days old. Sections  $70\ \mu$ . thick. (After H. Held, *Arch. f. Anat. u. Physiol., Leipz.*, 1897, *Anat. Abth., Suppl. Bd., Taf. xiv*, Figs. 5, 7, and 8.) A. Cell with network from nucleus nervi cochlearis ventralis. The pericellular network surrounds the whole cell and a dendrite passing upward. The fibre *a* corresponds to one of the thickened fibres of the N. cochleæ described by Ramón y Cajal and Held. Beyond the thickened spot fibrils go to join the general pericellular network. B. Part of the network around a cell in the nucleus nervi vestibularis lateralis (Deiters). Held believes that the thickenings in the network may correspond to the aggregations of neurosomes which stain in iron-haematoxylin preparations. *a, b, c, d, e, f*, axones which help to form the network. C. Part of the network around a cell of the nucleus nervi cochlearis ventralis; the anastomoses of the coarser subdivisions of the fibres *a* and *b* and the larger swellings of the threads of the network are clearly visible.

as a mosaic of delicate scales; not infrequently it presents markings which probably correspond to the imprints of nerve fibres or other fibres impinging on the nerve cell. The reticular variety seems to be most common; it may invest the whole of the cell body and be followed out upon the branching den-



A



B

FIG. 87.—Networks about perikaryon and dendrites demonstrable by the method of Bethe. (After F. Nissl, *München. med. Wchnschr.*, Bd. xlv, 1898, S. 1024, Fig. 1 u. 2.) A. Nerve cell from the nucleus dentatus of a dog. B. Nerve cell from Deiters's nucleus of a rabbit.

drites as far as the subdivisions of the second and third order; upon these branches, however, it loses its reticular nature in order to assume the character of a homogeneous layer. Golgi's illustrative figure is reproduced as Fig. 85. As to the exact nature of the substance concerned, Golgi speaks vaguely, suggesting that it may be of the nature of neuro-keratin, though his digestion experiments with trypsin and gastric juice are not



decisive. Similar investments have been described by Lugaro\* and by Martinotti.†

Held‡ describes and pictures (Fig. 86) pericellular and peridendritic networks demonstrable by Golgi's method, which he believes are formed by anastomosis of the subdivisions of the fine axones terminating there. In what relation these stand, if any, to the pericellular investment of Golgi, further work must determine. Bethe by his method also finds pericellular networks forming "stockings," as it were, drawn over the perikaryon and the dendrites. These are illustrated in Fig. 87.

---

\* Lugaro, E. Sulla struttura del nucleo dentato del cervelletto nell'uomo. *Monitore Zool.*, Firenze, vol. vi (1895).

† Martinotti, C. Su alcune particolarità delle cellule nervose del midollo spinale messe in evidenza colla reazione nera del Golgi. *Gior. d. R. Accad. d. med. d. Torino*, an. lix (1896). French Transl. in *Arch. ital. de biol.*, Turin, t. xxvii (1897), pp. 253, 254.

‡ Held, H. Beiträge zur Structur der Nervenzellen und ihrer Fortsätze. Dritte Abhandlung. *Arch. f. Anat. u. Physiol.*, Leipz. (1897), *Anat. Abth.*, Suppl. Bd., S. 272-312.

## CHAPTER XIV.

### SUMMARY OF OUR KNOWLEDGE UPON THE INTERNAL STRUCTURE OF NEURONES.

Conflicting views regarding cell organization in general—Summary of the existing state of knowledge concerning the internal structure of neurones.

It must be obvious that the idea entertained by any given investigator regarding the ultimate structure of the nerve cells is colored deeply by the opinion which he holds as to the nature and structure of protoplasm in general. Until some agreement has been arrived at among cytologists regarding the latter, we can scarcely hope for a unanimity of opinion concerning the former. It is not necessary here to discuss in detail the diverse theories bearing upon the nature of protoplasm. A whole series of them—the micellar theory of Nägeli, the network theory of Frommann, the thread-framework theory of Flemming, the foam or honeycomb theory of Bütschli, the plasome theory of Wiesener, the bioblast theory of Altmann, as well as many others—have been fully outlined and compared in several places.\* The majority of histologists and zoologists can not conceive of the cell as the elementary organism of the body, but postulate the existence of units or elementary organisms much smaller than cells.† Those who are interested in developmental

---

\* Cf. Hertwig, O. *Die Zelle und die Gewebe*, Jena, 1893; Carnoy, J. B., and H. Lebrun. *La cytodierèse de l'œuf. La vésicule germinative et les globules polaires chez les batraciens. Cellule, Lierre and Louvain*, t. xii (1897), pp. 189-295; and especially for a brief but thorough critical review consult Waldeyer, W. *Die neueren Ansichten über den Bau und das Wesen der Zelle. Deutsche med. Wehnschr., Leipz. u. Berl.* (1895), xxi, 703; 727; 764; 776; 800; 846. For an admirable review of the modern literature concerning the finer structure of the cell, in which many original observations are included, the book of E. B. Wilson, which has recently been published, entitled *The Cell in Development and Inheritance*, N. Y. (1897), 8vo, is heartily recommended.

† The reader who interests himself in this side of cytology is referred to

relations and their bearing upon heredity have perhaps gone furthest in this direction. Roux, an apostle of the mechanical theories of development, not only assumes the existence of elementary organisms within the cell, but classifies them into a number of varieties corresponding to their main characteristics—for example, into “idioplassonten,” “isoplassonten,” “automerizonden,” “autokineonten”; and those who are familiar with the writings of August Weismann will remember the enormous significance which is attached to his “biophores,” “determinants,” and “ids.”

In fine, the status of our knowledge about the internal structure of the protoplasm of nerve cells may perhaps be summed up as follows: A neurone is made up, like all other cells, of nucleus and protoplasm. In the latter a centrosome and a so-called attraction sphere are present; at least, they have been demonstrated in a certain number of nerve cells. The protoplasmic portion of the cell can be roughly divided into a peripheral exoplasmic portion and a central endoplasmic portion. In neurones, as in muscle cells, though less distinct in the former than in the latter, there is a tendency to a fibrillary structure, the fibrillation being more pronounced in the peripheral exoplasmic portion of both nerve and muscle cells than in the endoplasmic portion of the protoplasm. In both exoplasm and endoplasm there can be made out, in tissues which have been fixed, a more or less homogeneous ground substance in which are deposited larger and smaller masses of a granular nature. The ground substance corresponds, in tissues fixed with alcohol and stained by the methods of Nissl and Held, to the “unstainable substance” of Nissl, and the masses of granules to the “stainable substance” of Nissl and the pigment.

The “stainable substance” of Nissl (the tigroid substance of von Lenhossék) in tissues of healthy animals of the same age

---

the following: Graf, A., *The Individuality of the Cell, with an Introduction on the Application of Cellular Biology to the Problems of Pathology* by Dr. Van Gieson, *State Hosp. Bull., Utica* (1897), ii, pp. 169-188; Stöhr, A., *Letzte Lebenseinheiten und ihr Verband zu einem Keimplasma* Leipzig u. Wien (1897); Meyer, A., *Die Plasmaverbindungen und die Membranen von Volvox globator, aureus und tertius, mit Rücksicht auf die tierischen Zellen*, *Bot. Ztg., Leipz.*, Bd. liv (1896), No. 11-12; and von Kölliker, A., *Die Energiden von v. Sachs im Lichte der Gewebelehre der Thiere*, *Verhandl. d. phys.-med. Gesellsch. zu Würzb.*, n. F., Bd. xxxi (1897), S. 1-21.

and species, killed in a prescribed manner and submitted to the same method of fixing and staining, is tolerably constant in appearance and arrangement in the cell bodies and dendrites of the same groups of nerve cells, a fact of extreme importance for nerve anatomy and pathology. The axones, as well as their hillocks of origin in the bodies of the nerve cells, appear to be entirely devoid of the "stainable substance" of Nissl.

Whether the stainable substances represent bodies precipitated from solution through the action of reagents or bodies pre-existent though invisible, first brought into view through the action of fixing or staining reagents in the hardened tissues, in either case they appear to yield the chemical tests characteristic of the group of nucleo-albumins. Whether the staining reaction characteristic of the stainable substance depends upon chemical relations or upon purely physical conditions must, for the present, remain undecided.

The "unstainable portion" of the cell body—that is, the ground substance—though probably functionally much more important than the "stainable," is not so well understood; its nature and structure are still as obscure as those of protoplasm in general. It is here that the so-called fibrils of the various investigators (Flemming, Apáthy, Lugaro) occur. In this ground substance, aside from the Nissl bodies, very fine granules or nodule formations can be demonstrated which stain with erythrosin and with acid-fuchsine (Held's neurosomes), and in certain parts of the neurones these are arranged in rows, thus bringing the nerve cell into agreement with what has been observed in animal cells generally. The ground substance is easily vacuolizable, and the erythrosinophile granules apparently represent the nodal points of the meshwork which results from the vacuolization, though sometimes they appear to lie in the vacuolar cavities. With suitable methods not only can longitudinal markings connecting the nodal points be made out, but also more delicate transverse markings. As to the physiology of the various elementary histological constituents, we can say but little. The nucleus doubtless presides over the functions of nutrition. In some way or another the ground substance conducts what we call nerve impulses, whether as a whole or by means of fibrils, a network, walls of honeycomb spaces, hyaloplasm, rows of neurosomes, Apáthy's conducting primitive



fibrils, or Engelmann's longitudinal rows of neurotagmen and norman inotagmen, we do not know.\*

Should intercellular substances other than the lymph and neuroglia, of a fibrillary or more homogeneous nature, sometime be demonstrated, it would not be surprising, but thus far the proof for the existence of such substances is wanting.

We can scarcely hope for a clearer understanding of the structure of nerve cells until our general cytological knowledge has been extended. If too great a degree of importance appears to have been attached to the work which has been done upon the structure and nature of the substances within nerve cells, two ideas have influenced me; in the first place, the topic is one which has been too little considered in the text-books and too little respected by research workers in neurology; and, in the second place, the bibliography is becoming so complex, and in places so confusing, that I have felt that a connected *résumé* of the work of others, together with an expression of opinion regarding the relative value of the different researches based upon personal studies in this field, might not be unacceptable to those who from want of time or other reasons might find the bibliographic studies burdensome.

One thing is certain: before we can hope for a satisfactory pathology of the ganglion cell, we must have before us clearly, as Nissl states, a sharply defined anatomy of the nerve cells. The establishment of any relations, no matter whether they be structural or functional, so long as they are constant, must always be welcomed. We are too often inclined to undervalue an enthusiasm for facts, especially when these at the first view appear trivial and insignificant, but we have been taught the folly of such depreciation more than once in the progress of anatomical and especially of histological knowledge.

---

\* The general physiology and pathology of the neurone will be considered in Section V.

## SECTION IV.

### THE HISTOGENETIC RELATIONS OF THE NEURONES.

---

#### CHAPTER XV.

##### THE ORIGIN OF THE NERVOUS SYSTEM IN THE EMBRYO AND THE EARLIEST HISTOGENETIC STAGES.

Embryology of the nervous system—The medullary plate—The neural tube—Primary cerebral vesicles and their derivatives—Spongioblasts and neurospongium—The marginal veil (*Randschleier* of His)—Germinal cells (*Keimzellen* of His)—The neuroblasts—Origin of axones and dendrites.

HAVING had so much to say concerning the external appearances and internal structure of neurones in late embryonic and adult stages, it would scarcely be fair to close these morphological considerations without dealing to some extent with the form-relations to be met with in the domain of the nervous system earlier in the history of the organism. For not only has the study of the embryology of the nervous system, as I have pointed out, contributed enormously to the development of our modern conception of nervous organization, but the investigations, on account of the accuracy with which they have been pursued, and especially in view of the light they have thrown upon processes and arrangements which before their advent were almost hopelessly unintelligible, are surely worthy of our serious attention and command our thankful admiration.

The study of embryology attains its maximum of interest in the consideration of the development of the human nervous system. It is not my intention at this time to review what must already be familiar to all—the processes of fertilization and of segmentation, the formation of the medullary plate and of the medullary groove, the forerunners of the nerve tube—nor to describe how it is that the three bulgings (anterior, middle, and posterior cerebral vesicles) at the head end of this simple

tube (Fig. 88), which correspond, the *first* to the fore-brain (telencephalon) and inter-brain (diencephalon), the *second* to the mid-brain (mesencephalon), and the *third* to the hind-brain (meten-

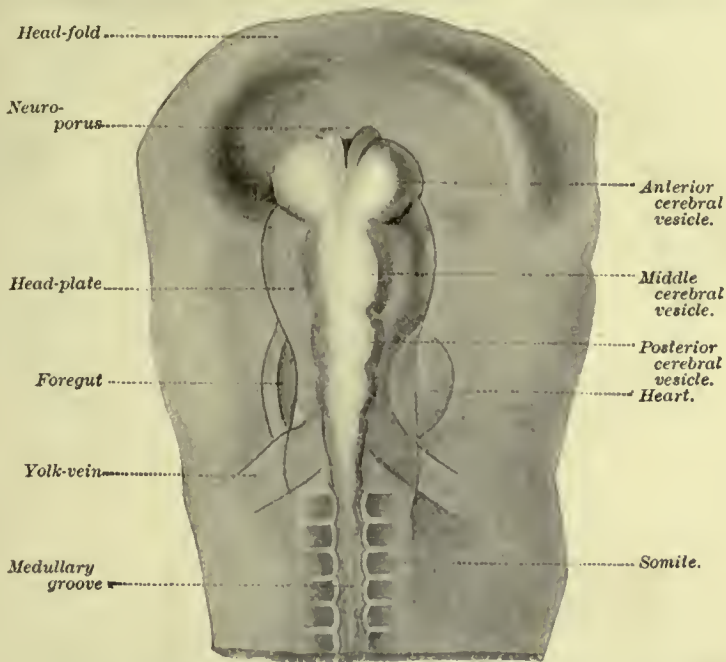


FIG. 88.—Anterior portion of the body of a chick, the head distinctly differentiated; seen from the surface. (After J. Kollmann, *Lehrbuch der Entwicklungsgeschichte des Menschen*, Jena, 1898, S. 199, Fig. 120.)

cephalon) and after-brain (myelencephalon), gradually undergo those metamorphoses which ultimately yield the complicated brain structure characteristic of the adult.\* The relations will

---

\*The results of the studies of His upon the gross morphology of the human nervous system during development have been made accessible to all through his publications, and especially by means of an excellent series of exact wax-model reproductions. Based upon these we have been supplied for the first time, too, with a nomenclature for the nervous structures which meets the demands of embryology, comparative anatomy, and clinical neurology—a nomenclature the use of which I can not too strongly recommend to those who have occasion, in writing or teaching, to make use of neurological terms. Cf. Section Neurologia, in *Die anatomische Nomenclatur. Nomina Anatomica. Verzeichniss der von der anatomischen Gesellschaft auf ihrer ix. Vers. in Basel angenommenen Namen. Eingeleitet und erläutert von W.*

be sufficiently clear if the reader study carefully the diagrams (Figs. 89-92) here inserted with their appropriate legends.

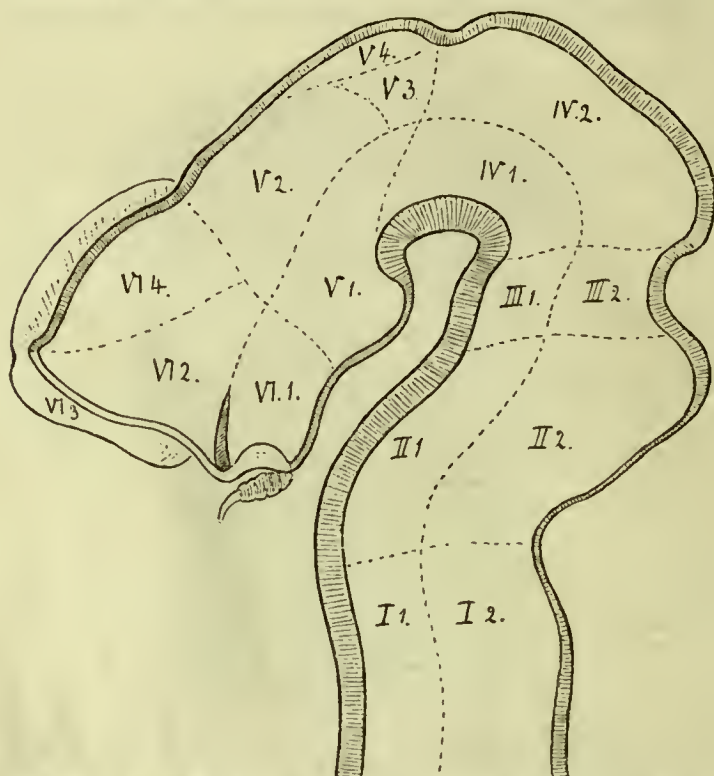

FIG. 89.—Median section through embryo human brain at the end of the first month. (After W. His, *Arch. f. Anat. u. Physiol., Anat. Abth.*, Leipz., 1893.)

- |                                     |   |
|-------------------------------------|---|
|                                     | I. Myelencephalon.                          |
| I. 1. Pars ventralis.               | I. 2. Pars dorsalis.                        |
|                                     | II. Metencephalon.                          |
| II. 1. Pons.                        | II. 2. Cerebellum.                          |
|                                     | III. Isthmus.                               |
| III. 1. Pedunculi cerebri.          | III. 2. Brachia conjunctiva, Vel. med. ant. |
|                                     | IV. Mesencephalon.                          |
| IV. 1. Pedunculi cerebri.           | IV. 2. Corpora quadrigemina.                |
|                                     | V. Diencephalon.                            |
| V. 1. Pars mammillaris hypothalami. | V. 2. Thalamus.                             |
|                                     | V. 3. Metathalamus.                         |
|                                     | V. 4. Epithalamus.                          |
|                                     | VI. Telencephalon.                          |
| VI. 1. Pars optica hypothalami.     | VI. 2. Corpus striatum.                     |
|                                     | VI. 3. Rhinencephalon,                      |
|                                     | VI. 4. Pallium.                             |

His, Leipz., 1895. This nomenclature has been closely followed in the present book, except that I have substituted the words *ventral* and *dorsal*



The derivatives of the three cerebral vesicles are outlined in the accompanying table on page 163.

Nor shall I permit myself to digress and describe to you how from the moment of fertilization, throughout the gradual process

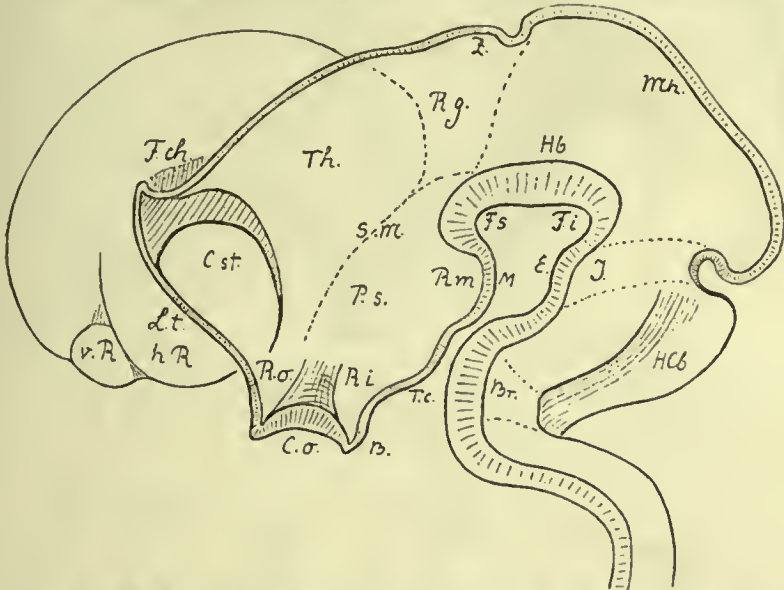


FIG. 90.—Model of developing human brain. (After W. His, Arch. f. Anat. u. Physiol., Anat. Abth., 1892.) *Br.*, pons curve; *C. o.*, chiasma opticum; *C. st.*, corpus striatum; *E.*, emenientia interpeduncularis of the isthmus; *F. ch.*, fissura chorioidea; *F. i.*, fossa interpeduncularis; *Hb.*, tegmental projection; *HCb.*, cerebellar hemisphere; *I.*, isthmus; *L. t.*, lamina terminalis; *M.*, corpus mammillare; *Mh.*, roof of mid-brain; *P. s.*, hypothalamus (pars subthalamica); *v. R.*, anterior olfactory lobe; *h. R.*, posterior olfactory lobe; *R. g.*, recessus geniculi; *R. m.*, recessus mammillaris; *R. i.*, recessus infundibuli; *R. o.*, recessus opticus; *S. m.*, sulcus Monroi; *T. c.*, tuber cinereum; *Th.*, thalamus; *Z.*, corpus pineale.

for *anterior* and *posterior* respectively, and perhaps in a few other particulars. Why the Commission on Nomenclature, usually so happy in its decisions, neglected to use the terms *ventral* and *dorsal*, instead of *anterior* and *posterior*, with regard to the roots of the spinal nerves, I find it difficult to understand. The nomenclature elaborated by Professor Wilder, of Cornell University, is used by a large number of American anatomists, and Mills has followed it consistently in his recent clinical text-book. The terms of Wilder and the equivalent terms of the Basel Commission are to be found in the article of Professor B. G. Wilder, entitled "Neural Terms—International and National." *J. Comp. Neurol.*, Granville, O., vol. vi (1896), pp. 216-352. In order to save space they have not been introduced in brackets in this book, but the reader accustomed to this nomenclature may refer to Professor Wilder's tables.

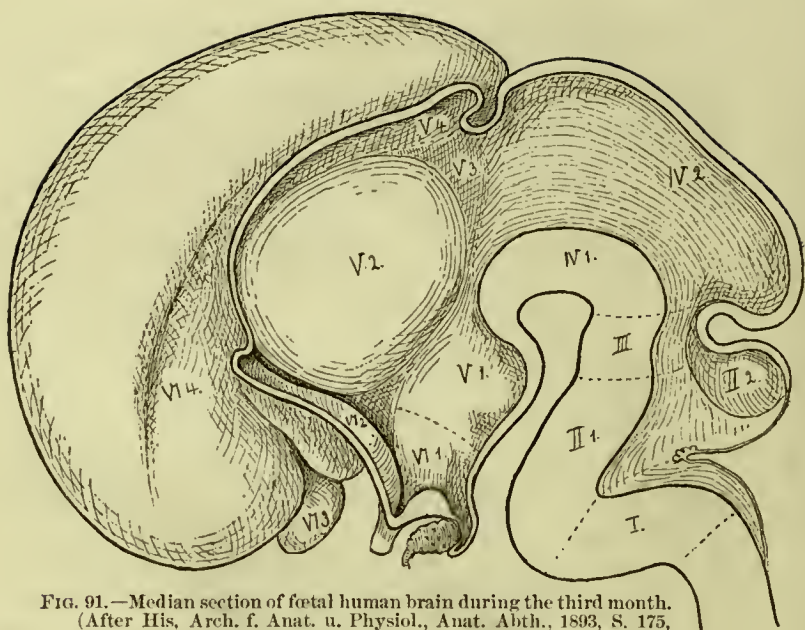


FIG. 91.—Median section of fetal human brain during the third month. (After His, Arch. f. Anat. u. Physiol., Anat. Abth., 1893, S. 175, Fig. 2.) The lettering is to be interpreted in the same way as for Fig. 89. (*Vide supra.*)

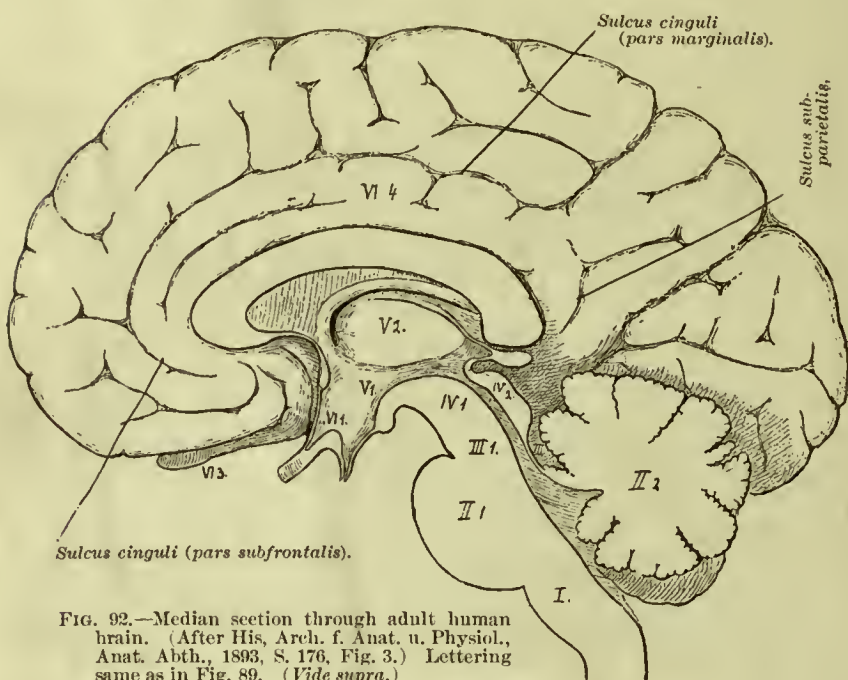
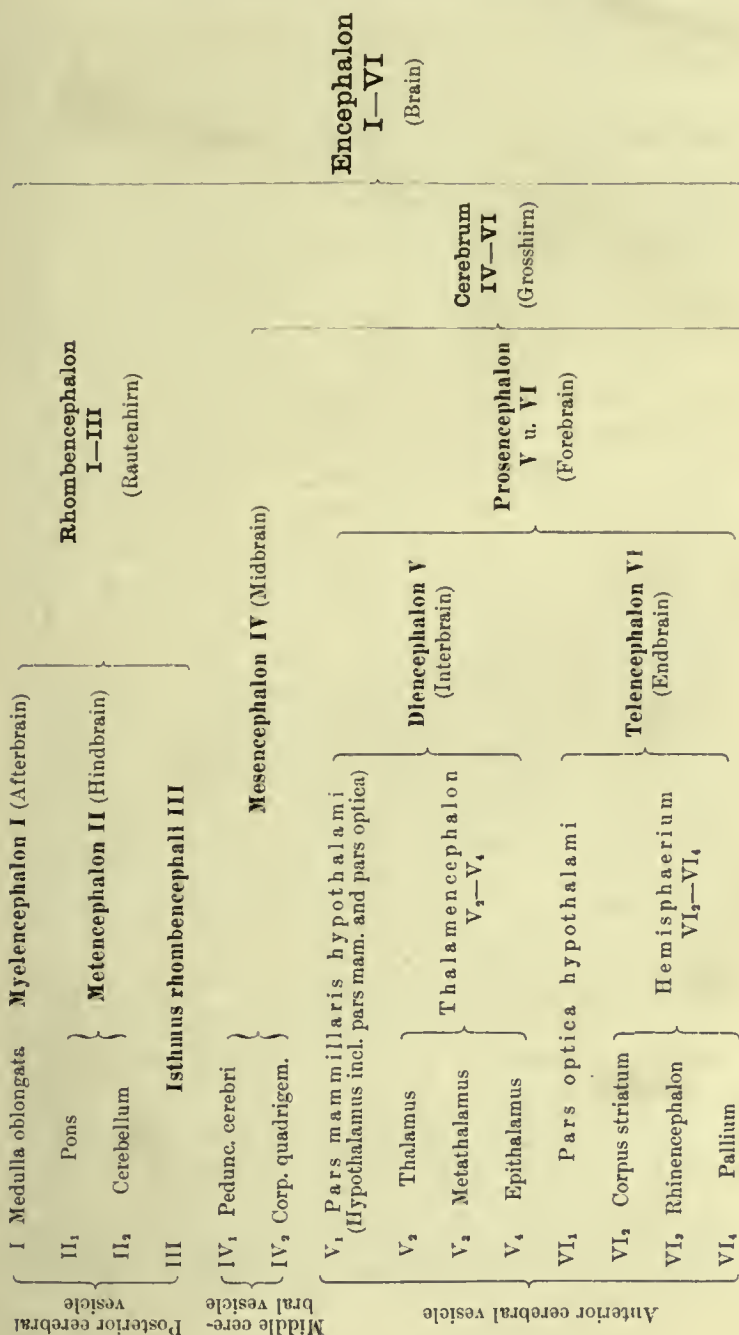


FIG. 92.—Median section through adult human brain. (After His, Arch. f. Anat. u. Physiol., Anat. Abth., 1893, S. 176, Fig. 3.) Lettering same as in Fig. 89. (*Vide supra.*)



of the development of the embryo, influences of different kinds, such as variations of temperature, of the oxygen supply, and of other conditions of environment, or trauma leading to injury of portions of the egg or of the segmentation cells, can give rise to those unfortunate caricatures of human beings which we commonly designate as monstrosities, and for the origin of which experimental teratology has during the past few years been attempting to supply us suitable explanations.\*

The histogenetic relations of the neurones and of their supporting structures must, however, be dwelt upon briefly; and the description here given is drawn largely from the writings †

\* Cf. Benda, C. Teratologie. Lubarsch-Ostertag. Ergebnisse der allgem. pathol. Morphol. u. Physiol. Wiesbaden (1895), S. 541.

† The principal publications of W. His which are interesting in this connection are (1) Anatomie menschlicher Embryonen. Leipz. (2) Ueber die Anfänge des peripherischen Nervensystemes. Arch. f. Anat. u. Physiol., Anat. Abth., Leipz. (1879), S. 455-482. (3) Zur Geschichte des menschlichen Rückenmarkes und der Nervenwurzeln. Abh. der math.-phys. Cl. der k. sächs. Ges. der Wiss., Bd. xiii, No. 6, Leipz. (1886), S. 479-513. (4) Zur Geschichte des Gehirns sowie der centralen und peripherischen Nervenbahnen beim menschlichen Embryo. Abhandl. d. math.-phys. Cl. d. k. sächs. Gesellsch. d. Wissensch., Bd. xiv, Leipz. (1887-'88), S. 339-392. (5) Die Neuroblasten und deren Entstehung im embryonalen Mark. *Ibid.*, Bd. xv, No. 4, Leipz. (1889), S. 313-372. (6) Die Formentwicklung des menschlichen Vorderhirns vom Ende des ersten bis zum Beginn des dritten Monats. *Ibid.*, Bd. xv, Leipz. (1889), S. 673-736. (7) Die Entwicklung des menschlichen Rautenhirns vom Ende des ersten bis zum Beginn des dritten Monats. I. Verlängertes Mark. *Ibid.*, Bd. xvii, Leipz. (1891), S. 1-74. (8) Zur allgemeinen Morphologie des Gehirns. Arch. f. Anat. u. Physiol., Anat. Abth., Leipz. (1892), S. 346-383. (9) Ueber das frontale Ende des Gehirnröhres. Arch. f. Anat. u. Physiol., Anat. Abth., Leipz. (1893), S. 157-171. (10) Vorschläge zur Eintheilung des Gehirns. *Ibid.*, S. 172-179. (11) Ueber mechanische Grundvorgänge tierischer Formenbildung. Arch. f. Anat. u. Physiol., Anat. Abth., Leipz. (1894), S. 1-80. (12) Ueber die Vorstufen der Gehirn und der Kopfbildung bei Wirbelthieren. *Ibid.*, 1894, S. 313-336. For the reports of two interesting addresses upon some of the general results of His's work the reader is referred to (1) His, W., Histogenese und Zusammenhang der Nerven Elemente. Verhhandl. d. x. internat. med. Cong. Berl., 4-9. Aug., 1890. Bd. ii, S. 93. Berl., 1891; and (2) His, W., Ueber den Aufbau unseres Nervensystems. Berl. klin. Wehnschr. (1893), S. 957 und 996. An excellent critical review in English of all the literature upon the development of the human nervous system in its early stages is to be found in C. S. Minot's Human Embryology, pp. 593-742, and in the article by the same author entitled Die frühen Stadien und die Histogenese des Nervensystems, in Merkel-Bonnet's Ergebnisse der Anatomie und Entwicklungsgeschichte. Bd. vi (for 1896). Wiesbaden (1897), S. 687. The subject is also



and lectures of His. At an early period, the medullary plate—which, as every one knows, has its origin in the external leaflike layer of the embryo, the ectoblast, the same layer which gives rise to the skin and its appendages—is made up of a single layer of nucleated epithelial cells placed side by side (Fig. 93). The planes corresponding to the two ends of the epithelial cells represent the upper and lower surfaces of the medullary plate, and, after the formation of the medullary or neural tube, the inner and outer surfaces of the wall of the tube, the inner surface of the wall of the tube thus obviously corresponding in its origin to the outer surface of the embryo. The nuclei of the epithelial cells of the plate do not all lie at the same level, but form several rows corresponding to differences in the distribution and arrangement of the protoplasm in the individual cells (Fig. 94). The nuclei are rarely, however, situated at the ends of the cell, so that very soon the medullary plate, as seen on transverse section, can be divided into three more or less distinct zones—a middle zone containing the nuclei and two border zones free from nuclei.

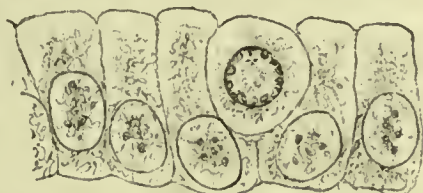

FIG. 93.—Section through medullary plate of rabbit. Among the epithelial cells a large round germinal cell with clear protoplasm is visible. (After His.)

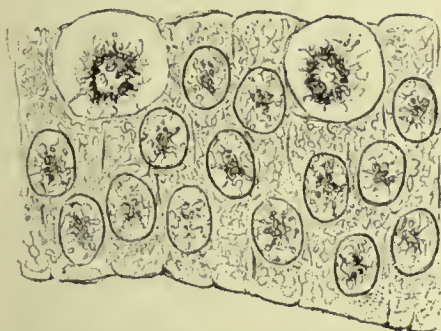


FIG. 94.—Section through neural tube which is beginning to close. The number of epithelial nuclei is considerably increased, and in the different cells they do not lie at the same level. Two large germinal cells are visible toward the inner surface. (After His.)

up of the protoplasmic ends of the epithelial cells and behave very differently in their further differentiation. In the protoplasm of both ends of the epithelial cells hyaline areas resem-

clearly presented in J. Kollmann's *Lehrbuch der Entwicklungsgeschichte des Menschen*. Jena, 1898. The many valuable contributions of von Kupffer, of Munich, may also be referred to.

bling vacuoles soon appear. In the distal ends of the cells (that is, the ends directed toward the outside of the body in the medullary plate, or those directed later toward the inside of the medullary tube) the cell bodies tend to collapse so as to form a series of striated pillars with spaces between the indi-

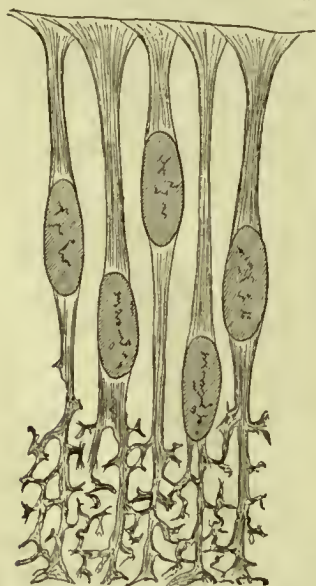

FIG. 95.—Section through wall of neural tube at a later stage. Differentiation of the two ends of the epithelial cells. (After His.)

vidual cells. The free ends of the cells retain their original breadth, and with those of neighboring cells form a thin limiting membrane. The proximal ends of the cells, instead of collapsing, assume a ragged, irregular appearance, the protoplasm becoming, according to His, manifoldly perforated, so that the framework between the perforations yields a reticulated appearance (Fig. 95). For a time the boundaries between the individual cells at the proximal ends are easily discernible,\* but very soon, through further development and extension, the cell boundaries disappear, and we have the appearance of a spongy network or of a closely felted thicket, the neurospongium of His. Whether we have to do in the threadwork with an actual closed network seems as

yet not quite certain. Ramón y Cajal, from the study of silver preparations, denies this, and also disputes the independence of the cell territories which His maintains for the neurospongium.

This thicket, which in the closed medullary tube forms the periphery of its wall, becomes more and more complex with further development. The feltwork, at first extremely close, shows later wider meshes, the whole spongy structure forming a *peripheral* or *marginal veil*—the *Randschleier* of His. As we shall see presently, the threads of this veil form a scaffolding of fine beams which later appear to play an important mechanical rôle in determining the course and direction of the developing

\*The epithelial cells at this stage of differentiation are spoken of by His as spongioblasts.

nerve fibres. Indeed, the marginal veil persists throughout life and appears to correspond in the adult to a part of the ependymal framework of the white matter of the whole of the central nervous system.\*

Very early in the history of the medullary plate there are to be made out in the intercellular spaces of the border zone, which corresponds to the distal ends of the epithelial cells, elements which have an entirely different appearance from those just described. These elements are designated by His as germinal cells (*Keimzellen*). They are, as a rule, at first spherical in shape, possess characteristic clear protoplasmic bodies, and their nuclei in well-fixed preparations are usually seen in the process of rapid division by karyokinesis (Fig. 96). The exact relations of these cells to the epithelial cells before described and to the other cells of the ectoblast still form the subject of some dispute. The idea that the *Keimzellen* are fundamentally different from the epithelial cells has been vigorously opposed by Kölliker,† Schaper,‡ and Vignal.\* The whole matter has been very recently subjected to a critical review by Schaper.¶ It is urged that the *Keimzellen* are really only

---

\*As His has pointed out, the transformation of epithelial cells into a framework penetrated by spaces and bounded by limiting membranes is not peculiar to the medullary plate. Very similar forms are to be met with in other ectoblastic derivatives—for example, the retina, the ear, the olfactory plate, and the portions of the ectoblast adjacent to the neural groove which correspond, in part at least, to the building places of the cells of the sensory ganglia.

† *Op. cit.*

‡Schaper, A. Zur feineren Anatomie des Kleinhirns der Teleostier. *Anat. Anz.*, Jena, Bd. viii, 1893, S. 705–720.—Die morphologische und histologische Entwicklung des Kleinhirns der Teleostier. *Ibid.*, Bd. ix (1893–94), S. 489–501; also, *Morphol. Jahrb.*, Leipz., Bd. xxi (1894), S. 625–708.

\*Vignal, W. Recherches sur le développement des éléments des couches corticales du cerveau et du cervelet chez l'homme et les mammifères. *Arch. de physiol. norm. et path.*, Par. (1888), 4. s., t. ii, pp. 228–254 et 311–338.—Recherches sur le développement des éléments des couches corticales du cerveau et du cervelet chez l'homme et les mammifères. *École prat. d. hautes études. Lab. d'histol. du Coll. de France. Trav.*, Par., 1888, t. xii, pp. 54–82.—Recherches sur le développement de la substance corticale du cerveau et du cervelet. *Ibid.*, pp. 83–112.

¶Schaper, A. Die frühesten Differenzierungsvorgänge im Centralnervensystem; kritische Studie und Versuch einer Geschichte der Entwicklung nervöser Substanz. *Arch. f. Entwicklungsmeehn. d. Organ.*, Leipz., Bd. v (1897), S. 81–132.



young proliferating forms of epithelial cells which afford material for a generation of indifferent cells. These latter may be further differentiated either into nerve cells or into glia

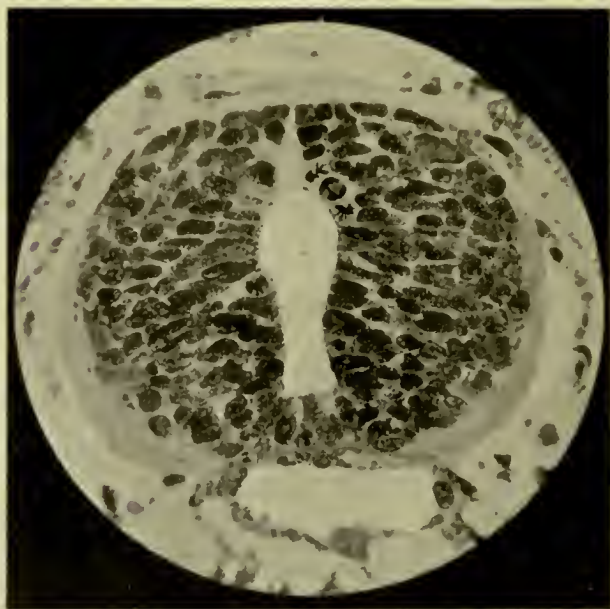

FIG. 96.—Photomicrograph by A. G. Hoen from a specimen of R. G. Harrison's through the neural tube of amblystoma. Several cells undergoing division by karyokinesis can be seen in the inner zone. A large number of epithelial nuclei are visible. The outer zone of the wall of the tube, which is free from nuclei and somewhat indistinctly shown, corresponds to the region of the marginal veil.

cells. Schaper has observed up to a certain period of development direct transition forms of *Keimzellen* to long epithelial cells, and pictures them. The number of spongioblasts (in the sense of His) is not sufficient to account for the origin of all the glia cells.

The spherical shape of the germinal cells is soon lost in the majority of instances, since at the extremity of the cell originally directed away from the outside of the body a short blunt projection appears which later becomes extended into a longer, more delicate process (Fig. 97). In silver preparations this process shows a conical pronged end knob, probably corresponding to the division of the fibre later. The protoplasm, also, instead of remaining evenly distributed throughout the



cell body, tends to accumulate at the point of origin of the process, forming a feebly striated protoplasmic cone on one side of the nucleus from which the process appears to take its origin. These pear-shaped cells, the derivatives of the *Keimzellen*, are termed by His *neuroblasts*. The nucleus of the cell body of the neuroblast corresponds to that of a future nerve cell, and the single process represents the developing axone. Of the existence of dendrites there is at this period of development no evidence, and studies in histogenesis have shown us that the dendrites appear ontogenetically much later than the axone, the latter being the first process of the young nerve cell to appear and for a long time existing alone, a fact that is of especial interest, as His suggests, when we remember that in

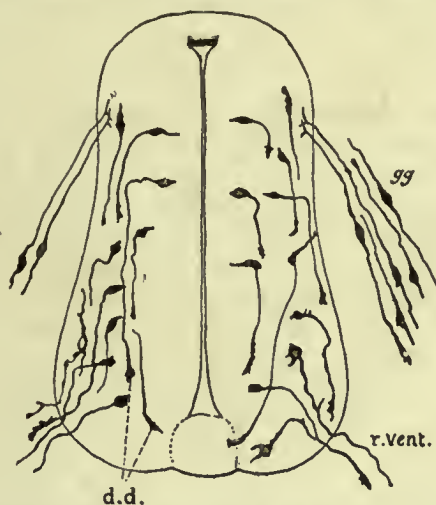


FIG. 97.—Section of spinal cord of a chick at the third day of incubation. (After Ramón y Cajal.) *gg*, cells of spinal ganglion; *dd*, ends of cells upon which the dendrites develop later. At the opposite poles are shown the embryonic axones, at the extremities of some of which there are bulbous swellings. The axones of the spinal ganglion cells divide on entrance into the cord. *r. vent.*, ventral root.

the young larvæ of frogs and fish before the feltwork formed by the dendrites of the nerve cells has appeared at all, there are already in full activity physiological mechanisms of no inconsiderable significance and complexity.

## CHAPTER XVI.

### THE DEVELOPMENTAL HISTORY OF THE SPINAL CORD AND MEDULLA OBLONGATA.

Wandering of neuroblasts—Fate of the axones in the spinal cord—Formation of ventral roots of spinal nerves and of the intrinsic fibres of the white funiculi of the spinal cord—Tautomerie, heteromeric, and hecateromeric neurones—Fasciculus cerebellospinalis—Wandering of neuroblasts in the medulla oblongata—Developmental history of the motor nuclei in the medulla, the formatio reticularis, the olivary bodies, and the pyramids—Relations of the white and gray matter in the cerebrum.

THE neuroblasts possess a certain degree of motility and are capable of altering their position. Following the radiating paths which correspond to the spaces between the epithelial cells of the medullary plate, they tend soon to leave the border zone at the inside of the nerve tube where they first appear, and to wander out toward the marginal veil, there to form often a sort of mantle layer (Fig. 98). In the marginal veil they appear to encounter an obstacle which prevents their further progress, although they may succeed in penetrating for a short distance into its meshes. The ganglion cells occasionally met with far out in the white matter of the adult spinal cord are to be looked upon as cells which have been able, through their active mobility in the neuroblastic stage, to attain a position more peripheral than that reached by their fellows.\*

The various wanderings of the different groups of nerve cells in the human cord have been carefully followed. † In the

---

\* His has noticed in selachian embryos occasionally cells which have even been able to reach the external border of the marginal veil, although they appeared afterward to become again surrounded by its meshes. Dohrn believes that in the region of the nervus oculomotorius there may be a permanent exit for motor cells. He brings these cells into connection with the oculomotorius ganglion of Schwalbe.

† His, W. Zur Geschichte des menschlichen Rückenmarkes und der Nervenwurzeln. Abhandl. d. math.-phys. Cl. d. k. sächs. Gesellsch. d. Wissensch., Leipzig, Bd. xiii (1886), S. 479-513.

formation of the mantle layer of neuroblasts the cells in the dorsal half tend to wander toward the ventral half and their processes are nearly all directed ventrally, the neuroblasts undergoing, as it were, a partial turning so as to become parallel to the surface of the marginal veil. Of the cells of the ventral half, a portion lying grouped together inside the marginal veil possess processes which, unlike those of the other neuroblasts, penetrate directly through the marginal veil to appear outside the embryonic cord, forming the ventral roots of the spinal nerves. The cell bodies of these neuroblasts represent the motor cells of the ventral horns of the gray matter, and their processes the axones of the motor spinal nerves (Fig. 99). The processes of the other neuroblasts do not go through the marginal veil, but remain within the spinal cord. The majority of them can advance, however, for a certain distance into the meshes of the neurospongium, but

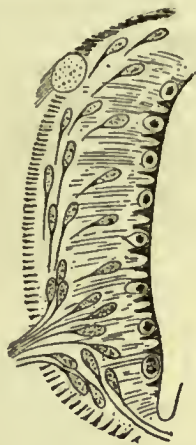

FIG. 98.—Section through half of neural tube showing the pear-shaped neuroblasts which are wandering out to form a sort of mantle upon the inner surface of the marginal veil. The axones of some of the neuroblasts have penetrated through the veil to form the ventral root of a spinal nerve. (After His.)

sooner or later meet in it with opposition, according to His, which leads to the directing of the processes upward and downward (Fig. 100). Hence arise the axones of the intrinsic fibres of the white funiculi of the spinal cord. Those of the neuroblasts which send their processes to help in the formation of the white matter of the same side of the cord correspond in the adult to the *tautomeric*\* neurones; those which send their processes through one of the commissures to the white matter of the other side, to the *heteromeric*† neurones (Fig. 101); and those of them whose processes divide into two, one going to each side of the cord, to the *hecatomeric*‡ neurones. The majority of the intrinsic fibres of the cord send their processes

\* A very satisfactory nomenclature suggested by van Gehuchten. The word *tautomeric* is taken from the Greek τὸ αὐτὸ μέρος, the same side.

† From ἕτερον μέρος, the other side.

‡ From ἐκάτερον μέρος, each side.

into the ventral and lateral funiculi of the white matter. Of the latter, a large bundle known as the *fasciculus cerebellospinalis* (direct cerebellar tract) receives its axones from the group of cells situated in the *nucleus dorsalis* (Clarke, Stilling).\* Comparatively few of the neuroblasts send their processes into the region of the dorsal funiculi, these, as well as the region of the pyramidal tracts, being occupied in the adult almost entirely by nerve fibres which may, in a certain sense, be looked upon as extrinsic to the spinal cord, since their axones in their origin are entirely independent of nerve cells lying in it.†

A very marked example of the wandering capacity of neuroblasts, and one to which His has frequently taken occasion to re-

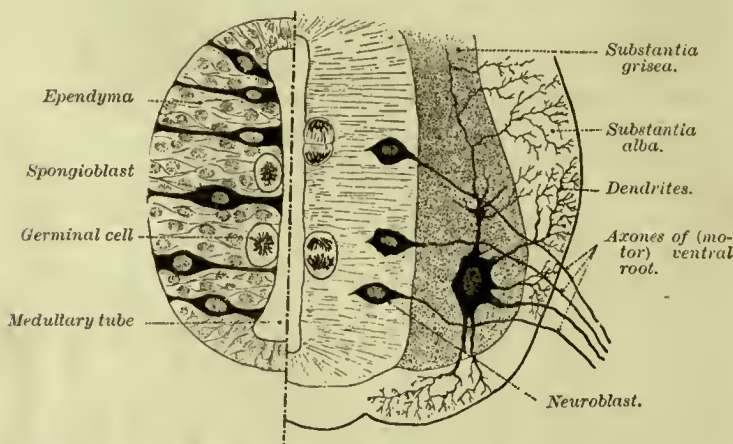


FIG. 99.—Transverse section of the spinal cord of a chick. Left side from two-day chick; right side from five-day chick. (After J. Kollmann, *Lehrbuch der Entwicklungsgeschichte des Menschen*, Jena, 1898, S. 500, Fig. 308.)

fer, is met with in the development of the medulla oblongata. In its early stages (Fig. 102) the region of the medulla is more or less pentagonal in shape, the fifth side being formed by the thin,

\* So far as I know, the actual connection of the axones of the cells of the *nucleus dorsalis* with the *fasciculus cerebellospinalis* has not been observed, although the evidence from secondary degeneration and from Golgi specimens gives sufficient warrant for the statement in the text.

† The axones of the fibres of the pyramidal tracts (*fasciculi cerebrospinales*) have their cells of origin in the convolutions of the so-called motor area of the cerebral cortex, while the axones of the majority of the fibres of the dorsal funiculi of the cord represent direct continuations of the central axones of the cells of the ganglia on the dorsal roots of the spinal nerves.



non-nervous roof. The lateral and the ventral walls of each half of the tube conform in structure, as regards neuroblasts and

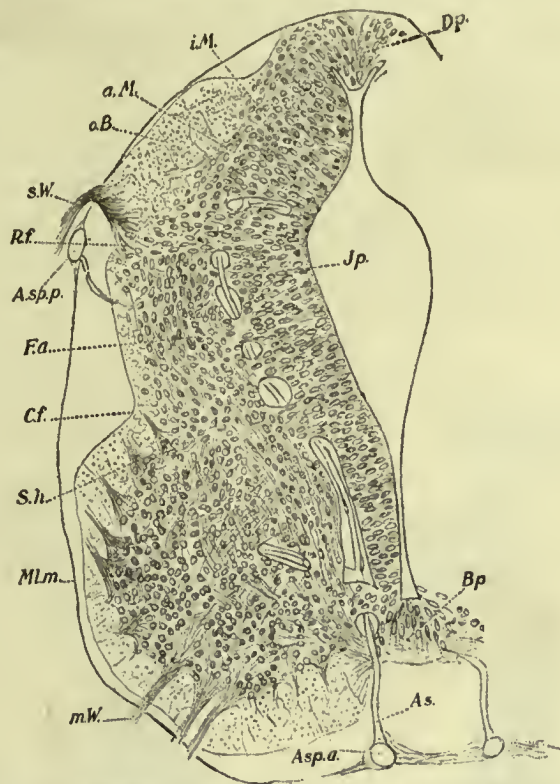


FIG. 100.—Transverse section through the upper thoracic spinal cord of the human embryo. (After W. His, Abhandl. d. math.-phys. Cl. d. k. sächs. Gesellsch. d. Wissensch., Leipz., Bd. xiii, 1886, No. 6, Fig. 2.) *a. M.*, external mantle layer; *A. sp. a.*, arteria spinalis ventralis; *A. sp. p.*, arteria spinalis dorsalis; *Bp.*, Bodenplatte; *Cf.*, cylinder furrow; *D. p.*, Deckplatte; *F. a.*, formatio arcuata; *i. M.*, internal mantle layer; *J. p.*, internal plate; *M. l. m.*, membrana limitans meningeae; *m. W.*, motor ventral root; *o. B.*, oval bundle of dorsal funiculus (not Flechsig's oval bundle); *R. f.*, marginal furrow; *s. W.*, sensory dorsal root; *S. h.*, cornu laterale.

spongioblasts, closely to that which I have described as characteristic of the spinal cord in its early stages. In the ventral plate, in a series of sections, can be made out quite early the groups of neuroblasts corresponding to the motor nuclei of the medulla (Nucl. N. hypoglossi, Nucl. N. accessorii, Nucl. N. vagi, and Nucl. N. glosso-pharyngei), and at this period these nuclei, as well as the bundle of fibres known as the tractus soli-

tarius (formed by sensory fibres from the N. vagus and N. glosso-pharyngeus, and so analogous to the dorsal funiculi in

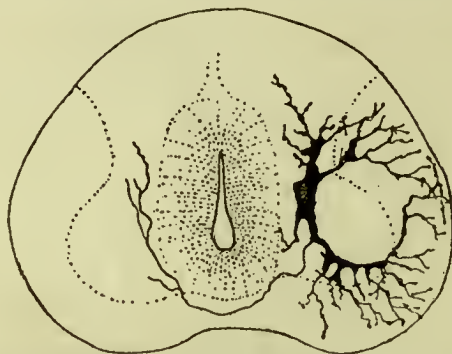


FIG. 101.—Commissural cell or heteromeric neurone from the spinal cord of a *Pristiurus* embryo 30 mm. long. (After M. von Lenhossék, *Der feinere Bau des Nervensystems*, etc., Berlin, 11 Aufl., 1895, S. 332, Fig. 49). The axone passes through the ventral commissure into the substantia grisea of the opposite side.

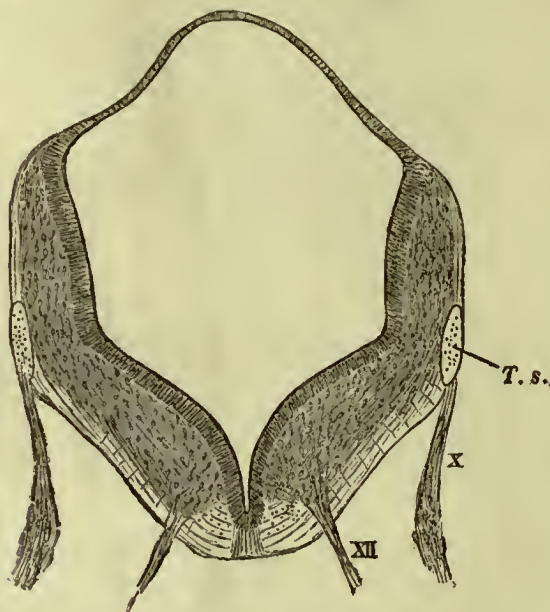


FIG. 102.—Transverse section through the medulla of the human embryo. *T. s.*, tractus solitarius; *X*, nervus vagus; *XII*, nervus hypoglossus. (After His.)

the spinal cord), are situated close to the outer surface of the medullary tube. As is well known, in the adult the motor nu-

clei in the medulla and the tractus solitarius are far removed from the ventral surface; indeed, they are situated close beneath the floor of the fourth ventricle (central canal), being separated from the surface by nearly the whole thickness of the ventral wall of the medulla, including the pyramids, the olivary bodies, and the formatio reticularis. The explanation of this is easy when the histogenetic relations are followed. Let us examine and see what has happened to bring about this remarkable morphological metamorphosis.

The medullary tube at the stage represented in the foregoing figure on further development shows in the human embryo a liplike lateral projection resulting from the bending over of the upper border of the thick lateral wall on each side (Fig. 103).

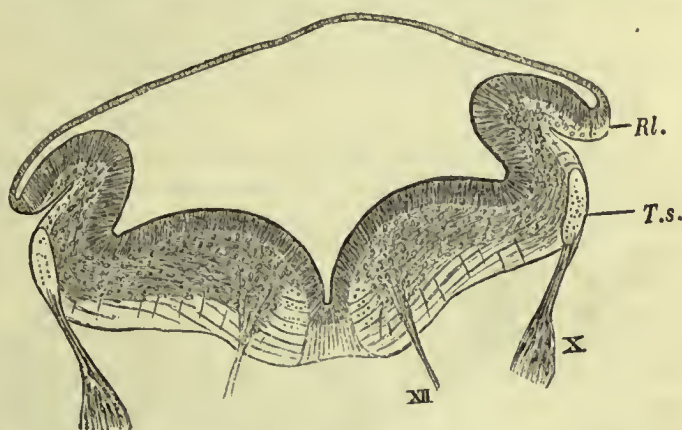


FIG. 103.—Transverse section through the medulla of the human embryo. (After Illis.) XII, nervus hypoglossus; X, nervus vagus; T. s., the tractus solitarius; Rl., rhomboidal lip.

This lip, which reaches on each side from the lower end of the medulla as far forward as the junction of the metencephalon with the mesencephalon—that is, as far as the isthmus—is of decisive significance for the further shaping of the medulla,\* and for the development of the cerebellum. The lip in the region we are considering bends well over and becomes adherent to the lateral wall, after which there is a visible egress of nerves

\* Franklin Dexter, of Harvard, has recently shown that in the rabbit the rhomboidal lip does not exist, the morphological changes apparently depending in this animal entirely upon the wandering capacities of the neuroblasts. Arch. f. Anat. u. Phys., Anat. Abth. (Leipz.), 1895, S. 423-437.

of neuroblasts (Fig. 104) from the lip into the lateral and ventral plates of the medulla, which lie medially to it. As they wander in, they pass ventrally as regards the tractus solitarius and

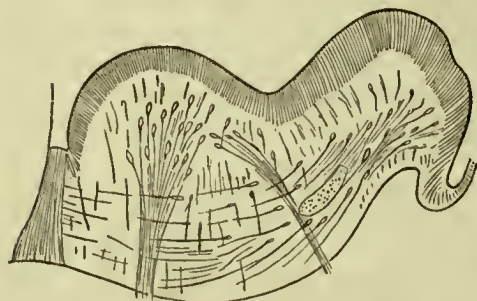


FIG. 104.—Section through a portion of the wall of the medulla of a human embryo. (After His.) Neuroblasts are shown wandering from the rhomboidal lip toward the middle line. The nucleus of the hypoglossal nerve is being buried in the depth.

motor nuclei and ventrally to the formatio reticularis, the latter in the meantime having been formed by cells in the neighborhood of the motor nuclei and solitary tract. Many of them pass medially almost as far as the raphe in the middle line. The motor nuclei and tractus solitarius, while retaining the same re-

lations to the central canal, now occupy in transverse section an entirely different position as regards the ventral surface of the medullary tube. Instead of lying superficially they are buried in the depth by the crowds of neuroblasts which have wandered in from the lateral regions. These neuroblasts arrange themselves so as to form the inferior olivary nucleus and the medial and lateral accessory olivary nuclei (Fig. 105), and last of all the burying is made still deeper by the appearance of the pyramids, great bundles of fibres, the last to be medullated in the medulla, which represent the processes of neuroblasts situated high up in the pallium of the fore-brain (telencephalon), which have grown down through the inter-brain (diencephalon), and mid-brain (mesencephalon), to the medulla to end at different

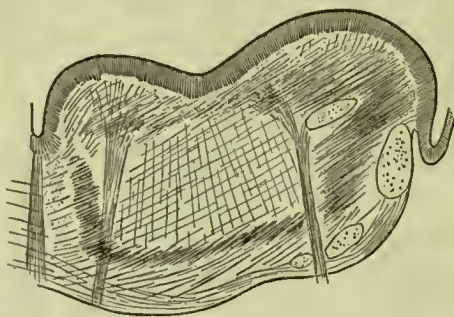


FIG. 105.—Scheme of one half of the embryonic medulla at a later stage. The gray masses corresponding to the olivary bodies have been formed, and the nucleus of the hypoglossal nerve and the tractus solitarius are far removed from the ventral surface. (After His.)



levels in the spinal cord. Thus the lamellation of the medulla in late embryonic stages and in the new-born (Fig. 106) must be looked upon, as His says, as the result of an epochal development of which the different stages are represented by the suc-

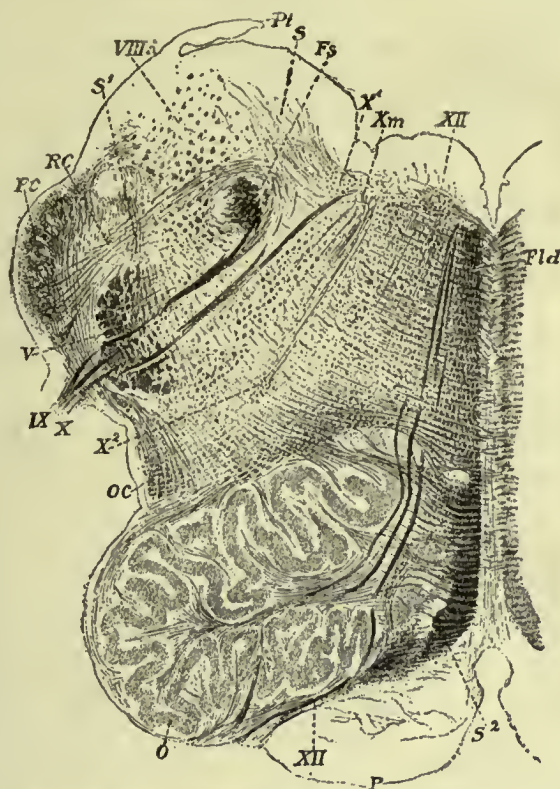


FIG. 106.—Transverse section through one half of the medulla oblongata of a human embryo at the eighth month. (After Kölliker.) *P*, pyramid not yet medullated; *O*, olivo with accessory olivary bodies; *OC*, fibre cerebello-olivares; *PC*, corpus restiforme; *IX*, *X*, N. glossopharyngeus and N. vagus; *X'*, nucleus of termination of sensory portion of N. vagus; *Fs*, tractus solitarius; *V*, tractus spinalis N. trigemini; *XII*, N. hypoglossus. Its nucleus of origin is seen near the floor of the fourth ventricle, far removed from the ventral surface; *Fld.*, fasciculus longitudinalis medialis; *S*<sup>2</sup>, stratum interolivare lemnisci.

cessive addition of (1) the motor nuclei; (2) the formatio reticularis; (3) the olivary masses; (4) the pyramids. As they lie, so they have developed. Their position is, as it were, the key to their developmental history.

Similar historical developments occur throughout the central nervous system, especially in the brain, where the structures present in the adult have arisen not simultaneously, but successively. So far, the different stages have not been worked out so well for any other part as for the medulla. Just here may be mentioned, however, a point with regard to which a good deal of interest has always been evinced. How is it that in the cerebrum the gray matter of the cortex is outside the white matter, whereas in the spinal cord the main masses of the white matter are outside the gray substance? Again, what are the genetic relations which exist between the gray matter of the cerebral cortex and that of the basal ganglia? To these questions histogenetic studies alone can afford the answer. Those who are interested are referred to the explanation offered by Mall as the result of his studies of the brain of *Necturus*.\* He believes that "in the gradual change of gray matter from the ventricle of the brain in lower animals to the cortex of the higher, the cell undergoes a half revolution, and the side which originally pointed toward the ventricle now points toward the surface of the brain." The relations of the gray matter to the white matter in a longitudinal section of the brain of *Necturus* are shown in the accompanying diagram (Fig. 107).

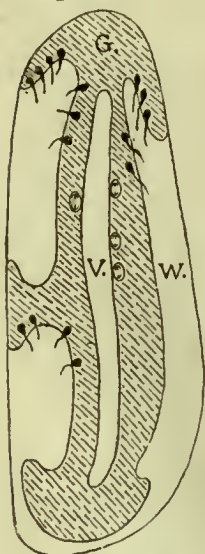


FIG. 107.—Longitudinal section of the cerebral hemispheres of *Necturus*. (After Mall.) V, ventricle; W, white matter; G, gray matter extending from the ventricle to form a rudimentary cortex. The growing point and the direction of the axone are indicated.

\* Mall, F. P. Histogenesis of the Retina in *Amblystoma* and *Necturus*. *J. Morphol.*, Bost., vol. viii (1893), pp. 415-432.

## CHAPTER XVII.

### THE DEVELOPMENT OF THE PERIPHERAL SENSORY NEURONES AND OF THE SYMPATHETIC NEURONES.

Origin of sensory ganglia, peripheral, sensory nerve fibres, dorsal roots of spinal nerves, and dorsal white funiculi of the spinal cord—The development of the organs of special sense—The ear—The eye—The nose—Wanderings of neuroblasts in the formation of the sympathetic nervous system.

WHEREAS the origin of the motor fibres of the peripheral nerves and the intrinsic intramedullary fibres is to be sought in the neuroblasts of the medullary tube, these do not give rise to the general peripheral sensory nerve fibres and the nerve fibres of the organs of special sense, nor to the fibres and cells of the sympathetic nervous system. How, then, is the origin of these to be explained? Concerning this there has been some dispute, but the skein is being gradually disentangled. From a given period of development on, one can make out near the medullary tube on each side groups of cells which represent the beginnings of the sensory ganglia of the dorsal roots of the spinal nerves, so that the cell bodies of all the sensory neurones of the first order are situated outside the neural tube—that is, outside the spinal cord and brain (Fig. 108).\* The studies of His, Marshall, Balfour, Beard, von Lenhossék, and others have taught us whence these cells are derived. All are agreed that they come from the ectoblast at the junction of the edges of the medullary plate with the adjoining ectoblast (Fig. 109), although there are a number of researches which make it probable that a certain number of the cells do not wander off until the medullary tube

---

\* That in development the system of the sensory ganglia can grow entirely independently of the presence of the medullary tube, or, perhaps more safely expressed, that the sensory ganglia may be present in the absence of a spinal cord, is well shown by the case described by von Leonova, O. Ein Fall von Anencephalie combinirt mit totaler Amyelie. *Neurol. Centralbl.*, Leipz., Bd. xii (1893), S. 218; 263.

has been pinched off from the ectoderm. In the front part of the head, corresponding to the sensory region of the trigeminus and especially to the acoustic-facialis area, there exist in the

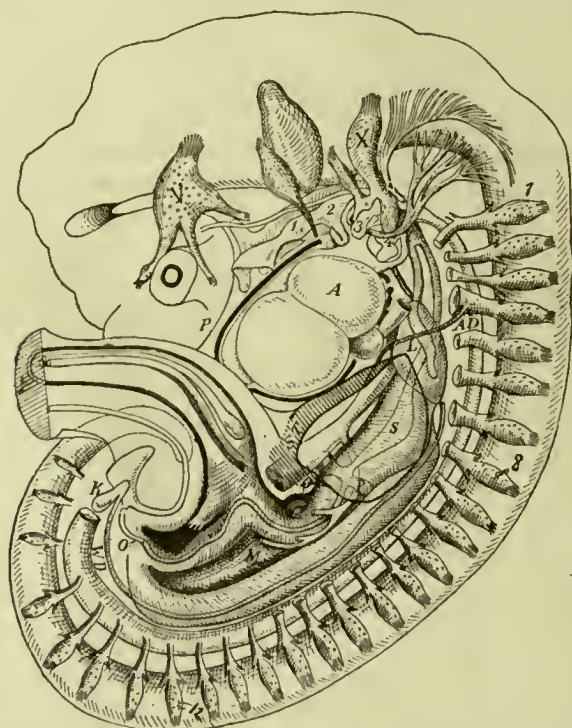


FIG. 108.—Reconstruction of human embryo at end of fourth week, showing development of sensory ganglia. (After Mall.) *V*, Gasserian ganglion; *X*, vagus ganglion; 1, first cervical ganglion; 8, last cervical ganglion; 12, last thoracic ganglion. The phrenic nerve is seen arising from the fourth cervical nerve.

ectoderm, at points corresponding to this junction, definite ridges which are crowded with dividing cells very like those that His takes to be the forerunners of the neuroblasts in the medullary tube.

In the region of the ear fossa these cells can often be seen heaped up as a compact column shoved in between the ectoblast and the medullary tube. In the trunk, however, no marked aggregations of germinal cells are visible at an early stage, and, according to His, the ganglia of the spinal nerves in human beings are formed of neuroblasts which collect in groups



after wandering out from the portions of the ectoblast adjacent to the medullary tube. According to others, the spinal ganglia are made up of neuroblasts which wander out from the dorsal edge of the medullary tube. Dr. Mall tells me that in *Necturus* he has observed a number of the ganglia of the tail having their origin in a pinching off of ganglionic masses from the ganglia lying farther headward.

The young cells giving rise to the nerve elements of the spinal ganglia divide by karyokinesis even for some time after they have arrived among the ganglionic groups. The further development of the individual cells, thanks to the researches of His, is now very well known. The cells assume a bipolar shape, one process growing from each pole. The process corresponding to the dendrite (that is, the one arising on the pole of the neuroblast, which originally was turned toward the external surface of the embryo) grows toward a peripheral sensory surface, the process corresponding to the axone growing centralward until it reaches the outer surface of the medullary tube, into the wall of which it penetrates. Bundles of these, assuming in the spinal cord a longitudinal direction, go to make up

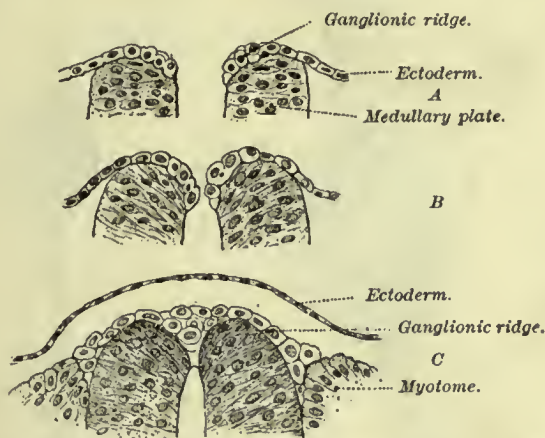


FIG. 109.—Three stages of development in the early history of the spinal ganglia of the human embryo. (After M. von Lenhossék.)

the primary dorsal funiculi, in the medulla, the analogous tractus solitarius, the radix descendens nervi vestibuli, and the tractus spinalis nervi trigemini. The relations of the dorsal roots to the spinal cord are well shown, as are those of some of

the cells of the ventral horns, in the accompanying figure, copied from van Gehuchten, which represents the development in the chick (Fig. 110). An earlier stage is well illustrated in

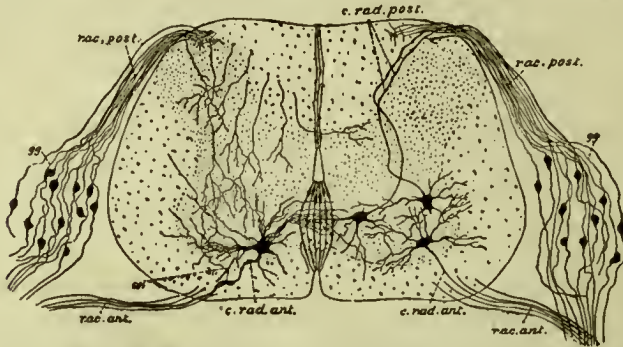
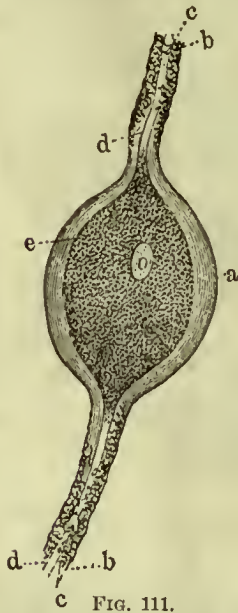


FIG. 110.—Transverse section of the embryonic cord of the chick. (After van Gehuchten.) *c. rad. ant.*, cells which give rise to axones of ventral roots; *c. rad. post.*, cells which give rise to the few centrifugal axones of dorsal roots; *col.*, collateral (side fibril) passing from axone of cell of the ventral horn back into the gray matter; *gg*, cells of spinal ganglia; *rac. post.*, dorsal root fibres; *rac. ant.*, ventral root fibres.



c FIG. 111.



FIG. 112.

FIG. 111.—Bipolar cell from the spinal ganglion of the pike. (After Kölliker.) *a*, sheath of the cell body; *b*, sheath of the nerve fibres; *c*, myelin sheath; *d*, axones; *e*, cell protoplasm; *o*, nucleus.

FIG. 112.—Bipolar ganglion cell from the ganglion spirale of the pig. (After Corti.)

Fig. 97 (*vide supra*). The two processes of the spinal ganglion cell, central and peripheral, go off from one edge of the cell, being at first in a direct line with one another, the nucleus and the main mass of the cell body, as His describes them, lying eccentric to the fibre. This bipolar condition is in some animals maintained throughout life. In the fish, for example, even in adults, nearly all the spinal ganglion cells are bipolar (Fig. 111), and it is of no little interest to find that in human beings, and in mammals generally, in the ganglion on the cochlear nerve (ganglion spirale, *cf.* Fig. 112) and in the ganglion

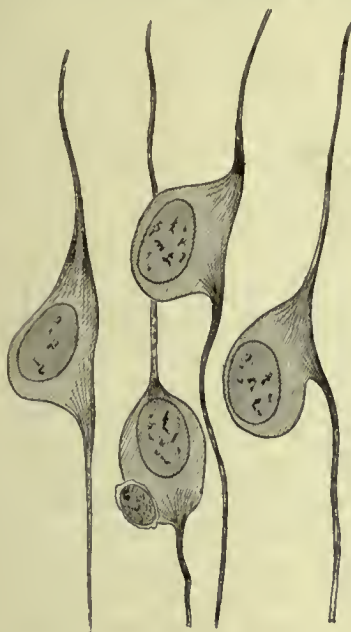

FIG. 113.

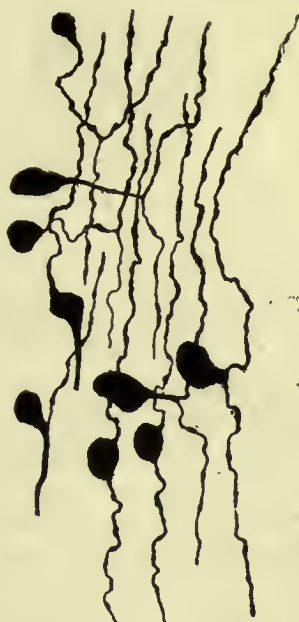

FIG. 114.

FIG. 113.—Schematic representation of the gradual transition of the bipolar cells of the spinal ganglia to the so-called unipolar type. (After His.)

FIG. 114.—Transformation of bipolar cells into unipolar cells in the Gasserian ganglion of the pig. (After van Gehuchten.)

on the vestibular nerve (ganglion vestibuli) this primitive bipolar condition of the cells is also maintained throughout the whole of life. But in all the other sensory ganglia of man there is a gradual transformation from the bipolar to the unipolar condition, typical of the adult spinal ganglia, recognized and described by Ranvier more than twenty years ago. Occa-

sionally, single bipolar cells persist even in the spinal ganglia of the adult, as recent research has shown. In the accompany-

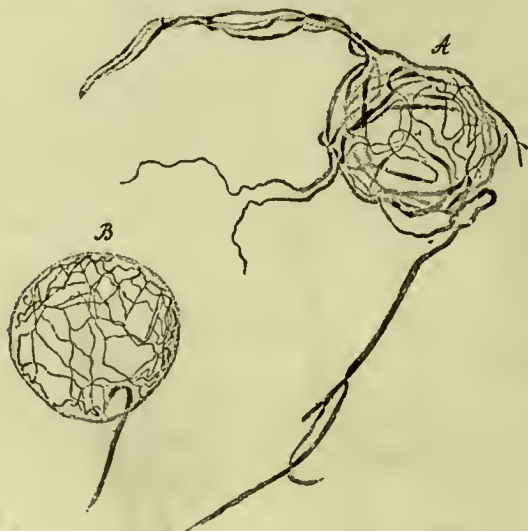

FIG. 115.—Feltwork about spinal ganglion cells of the cat formed by divisions of the axones of "spinal ganglion cells of the second type." (After Dogiel.) *A*, pericapsular plexus; *B*, circumcellular plexus.

ing diagram (Fig. 114) the early steps in the formation of the T-fibre of Ranvier are well illustrated. It is obvious that the change consists rather in the formation of a protoplasmic pedicle than in a gradual approximation and fusion of the central and peripheral fibres, as was formerly taught. The cells in the developing spinal ganglion of a guinea-pig stained by van Gehuchten by Golgi's method show very clearly the mode of transformation (Fig. 114). The sheath of the spinal ganglion cells appears to be mesoblastic in its origin, although some assert that it also has its origin from the ectoblast.

A few multipolar cells occur also in the spinal ganglia. These cells, previously seen in the embryo by Disse, von Lenhossék, Ramón y Cajal, and Spirlas, and thought to be rare and of little significance, are said by Dogiel to occur also in the adult.

Dogiel has recently given an account \* of a special hitherto

\* Dogiel, A. S. Der Bau der Spinalganglien bei den Säugethieren. Vorläuf. Mittheil. Anat. Anz., Jena, Bd. xii (1896), S. 140-152.



undescribed variety of cell in the spinal ganglia, which he names "spinal ganglion cell of the second type." The main axone of the cell breaks up inside the ganglion into a large number of medullated fibres, which finally lose their medullary sheath and terminate within the ganglion in a fine pericellular arborization about the spinal ganglion cells of the ordinary well-known type. The axones of the cells of his second type, according to Dogiel, form not only an extracapsular feltwork, but also a fine intracapsular feltwork about the spinal ganglion

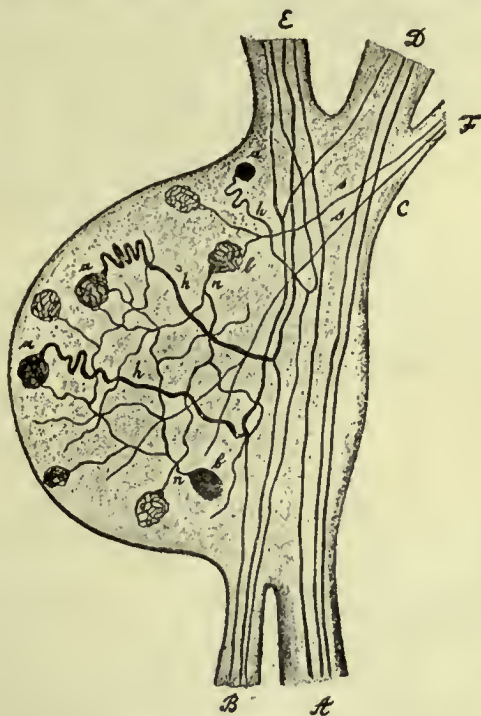


FIG. 116.—Scheme of the reciprocal relations of the elements within the spinal ganglion, according to Dogiel. *A* and *B*, ventral and dorsal roots; *C*, spinal nerve; *D* and *E*, ventral and dorsal divisions of spinal nerve; *F*, ramus communicans (sympathetic connection); *a*, *b*, spinal ganglion cells of the first and second type; *h*, trunk processes of cells of the first type which divide to form the axones of the peripheral and central fibres; *n*, axones of cells of the second type which end as a pericellular feltwork about the cells of the first type; *s*, sympathetic fibres which end as a circumcellular plexus about the cells of the second type.

cells (Fig. 115). The spinal ganglion cells of Type II are, he thinks, in turn surrounded by nerve endings from the sympathetic, a finding which, if confirmed and taken in connection

with the observations of Ehrlich, and especially with those of Ramón y Cajal, is of extreme significance in dealing with the functions of the spinal ganglia and the relations of the spinal and sympathetic systems to one another. I have reproduced in Fig. 116 Dogiel's schematic representation of his conception of these relations inside the spinal ganglia.

It would take too long to describe in detail the mode of development of the organs of special sense. It is interesting to find that the development in them conforms very closely to that met with in the sensory nerves in general. All the peripheral neurones in the organs of special sense, as in the spinal

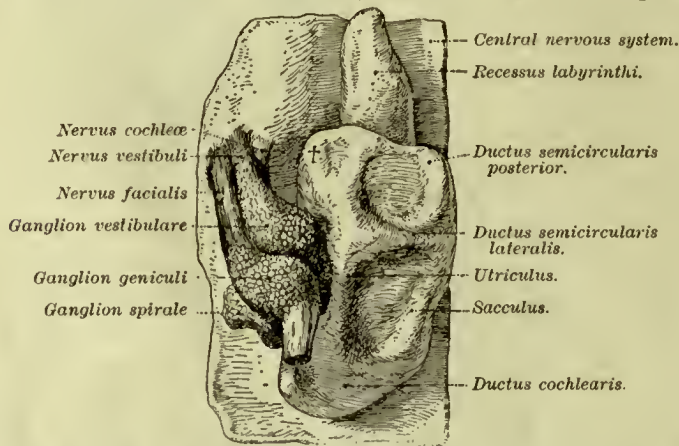


FIG. 117.—Left auditory vesicle with the acustico-facial complex of a human embryo at the fifth week. (After His, Junior, from Kollmann's text-book, S. 546, Fig. 333.)

ganglia, arise from cells of the ectoblast and pass through the neuroblastic stage, the axis-cylinder processes of the neuroblasts growing into the central organs to terminate in them in free endings. In the ear, for example, the ganglia connected with the cochlear and vestibular nerves contain cells whose two processes grow away from the ganglia, the one toward the periphery (to the cochlea or to the vestibule), the other toward the centre to the nerve tube at the junction of the medulla and pons (Fig. 117). These ganglia are in every way analogous to dorsal-root ganglia, their only peculiarities consisting in (1) the short distance which the peripheral process has to go before terminating; (2) the maintenance throughout life of the bipolar condition.

In the eye, too, all the nerve elements of the retina are of neuroblastic origin, and the axones of the cells of the ganglion-cell layer, growing backward, pass by way of the optic nerve

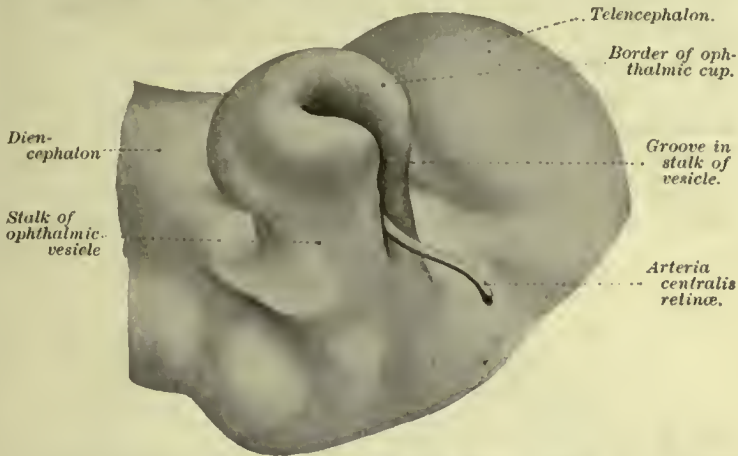


FIG. 118.—Ophthalmic vesicle showing stalk and groove in stalk from a human embryo of the fourth week seen from below. (After J. Kollmann, *Lehrbuch der Entwicklungsgeschichte des Menschen*, Jena, 1898, Fig. 346, S. 581.) The arteria centralis retinae has been drawn in from findings in a human embryo at the sixth week.

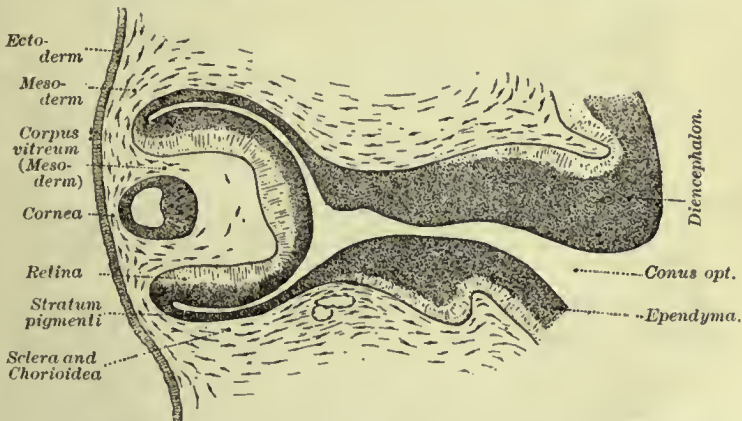


FIG. 119.—Developing eye of human embryo 10.2 mm. long. (After J. Kollmann, *Lehrbuch der Entwicklungsgeschichte des Menschen*, Jena, 1898, S. 576, Fig. 343.)

and of the optic tracts into the mid-brain and inter-brain. The eye differs somewhat in origin from all the other sense organs, in that the embryonic masses of neurones, making up the optic

vesicles from which the eyes are formed, grow out as lateral projections from the general medullary tube (Figs. 118 and 119). Later, however, they become practically separated from the central nervous system, and the final organic nerve connection is subsequently made by the growth of axones, from the nerve cells deposited at the periphery, back into the central nervous system (Fig. 120).\* The earliest portion of the retina to develop is the region of the fovea centralis.

The most peripheral olfactory sensory neurones deserve especial mention, since in the nose we find the only evidence in human beings of a condition quite general in invertebrate

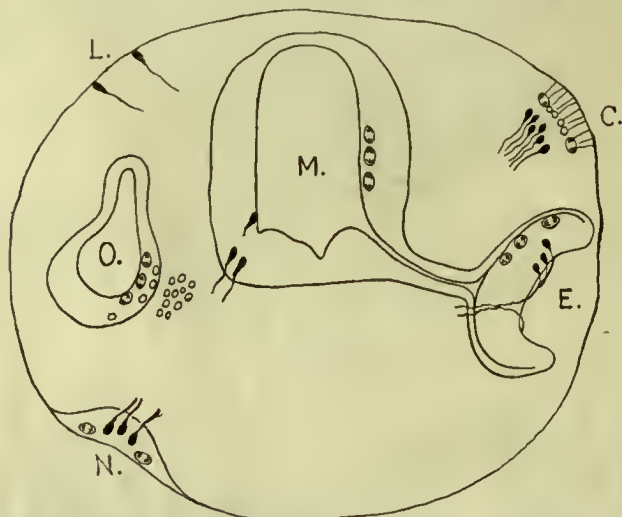


FIG. 120.—Composite diagrammatic transverse section of the head of a human embryo to show the growing point in the nervous system, and the direction of the growth of the fibre. *M*, medullary canal; *E*, eye; *O*, ear; *N*, nose; *C*, cephalopod eye; *L*, sensory cells from the skin of lumbricus. (After Mall.)

forms (*cf.* researches of von Lenhossék on the central nervous system of lumbricus, and the investigations of Retzius upon invertebrate forms). In the olfactory mucous membrane the early stages of the neuroblasts are present among the epithelial cells, just as in the ectoblastic ridges from which the spinal ganglion cells arise. But instead of these young cells wandering out from the epithelial plate, as appears to be the case with the cells of the spinal ganglia, in the nose they remain

\* *Cf.* Mall, F. P. *Op. cit.*



throughout life situated in the mucous membrane itself, the axones, which, by the way, never become medullated, growing upward and backward through the eribriform plate to enter the olfactory bulb, where they terminate in free end-arboriza-

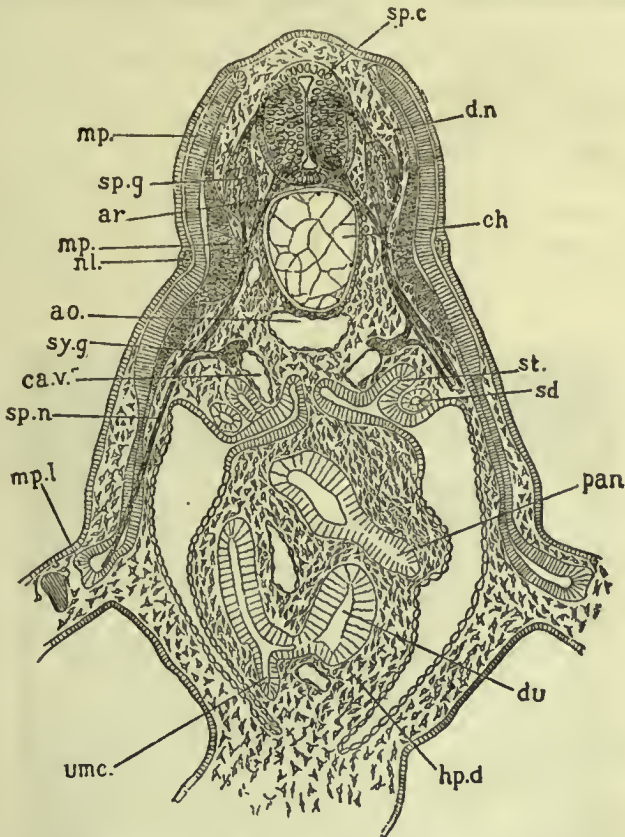


FIG. 121.—Transverse section through the anterior part of the trunk of an embryo of *Scyllium*. (After Balfour.) *sp. c.*, spinal cord; *sp. g.*, ganglion of dorsal root; *ar*, ventral root; *du*, dorsal, *sp. n.*, ventral branch of spinal nerve; *mp*, part of muscle plate already converted into muscle; *mp. l.*, part of muscle plate extending into the limb; *nl.*, nervus lateralis; *ao*, aorta; *ch*, notochord; *sy. g.*, sympathetic ganglion; *ca. v.*, cardinal vein; *sd*, segmental duct; *st*, segmental tube; *du*, duodenum; *hp. d.*, junction of hepatic duct with it; *pan*, rudiment of pancreas connected with another part of duodenum; *umc*, opening of umbilical canal (vitelline duct).

tions within the olfactory glomeruli. In these neurones, therefore, the only representative of a dendrite is the hairlike distal end of the olfactory sense epithelial cell, and the bodies of the

ganglion cells are more superficially placed than are those of any other mammal sense organ.

The sympathetic nervous system is that which shows in its development the most marked wanderings of the different constituent elements. Soon after the outgrowth of the spinal nerves toward the periphery there can be seen coming off from them at the dorsal edge of the cœlom, short visceral branches, which run over toward the aorta (Fig. 121). These appear before any sympathetic ganglia are present and correspond to the rami communicantes. All authors agree that the ganglion cells of the sympathetic ganglia have an origin in common with that of the spinal ganglia, although it would appear that Onodi's original view that the former were formed by a sort of pinching off of the latter is incorrect. According to His, the sympathetic ganglion cells are formed from unripe motile

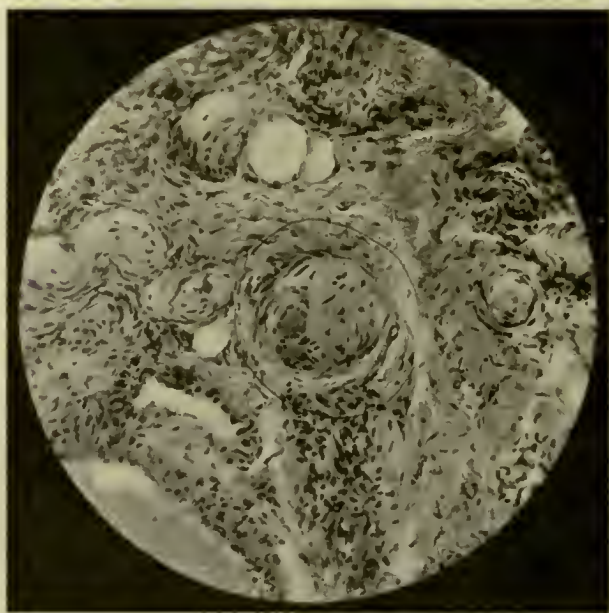


FIG. 122.—Photomicrograph by A. G. Hoen of section through a nerve in the side of the human tongue. Alcohol fixation—hæmatoxylin and eosin. Two sympathetic ganglion cells are visible inside the nerve trunk near its edge.

elements which wander out from the spinal ganglia into the regions subsequently occupied by the sympathetic chain. These wandering cells traveling in the paths of least resistance

tend to collect in groups, the sympathetic ganglia; in addition, scattered along the sympathetic nerve trunks throughout life, single ganglion cells remain demonstrable. Any one who

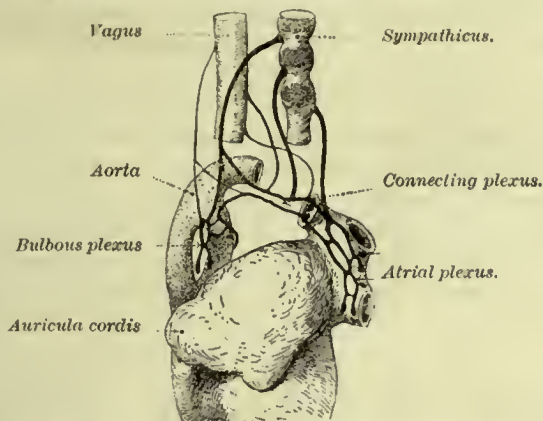


FIG. 123.—Schematic representation of the nerve plexus of a heart of a human embryo after His Junior. (From J. Kollmann, *Lehrbuch der Entwicklungsgeschichte des Menschen*, Jena, 1898, S. 562, Fig. 337.) The cardiac nerves from the vagus are delicate, those of the sympathetic coarse, in the figure.

has carefully studied even ordinary sections stained in hæmatoxylin and eosin from the heart, alimentary tract (plexuses of Auerbach and Meissner), the tongue (Fig. 122), the blood-vessels, the bladder, the sexual organs, and elsewhere, must be familiar with these ganglion cells, and it is now believed that all of them which are to be found in the viscera, amounting to thousands, or perhaps millions, of elements, have had their origin in this nomadic way. The younger His\* and Romberg have already worked out the mode of formation of the ganglia belonging to the heart, and have thus established for the first time a satisfactory anatomical basis for the physiology of the nerves of the heart, and a starting point whence perhaps

\* His, W., Jr., u. E. Romberg. Beiträge zur Herzinnervation. *Fortshr. d. Med.*, Berl., Bd. viii (1890), S. 374: 416. His, W., Jr. Demonstration von Präparaten u. Modellen zur Herzinnervation. *Verhandl. d. Cong. f. innere Med.* Wiesb., ix, 1890. His, W., Jr. Die Entwicklung des Herznervensystems bei Wirbelthieren. *Abhandl. d. math.-phys. Cl. d. k. sächs. Gesellsch. d. Wissensch.*, Bd. xviii (1893), No. 1. For a recent discussion concerning the innervation of the heart the reader is referred to the article by v. Leyden, *Kritische Bemerkungen über Herznerven*. *Deutsche med. Wehnschr.*, Leipz., u. Berl., Bd. xxiv (1898) [Discussion], Ver.-Beil., S. 145-147.

those puzzling clinical problems in connection with the cardiac neuroses may be advantageously approached (Fig. 123). It is true that so far as regards the exact history of the development in the other viscera, we are for the most part still profoundly ignorant, and a vast and attractive field lies here open to the investigator.

The sympathetic cells differ in many ways, both structural and functional, from all other ganglion cells, a fact which is not surprising when we consider the peculiarities of their origin and of their environment. Whereas all other nerve cells tend to be aggregated in large cell communities, more or less sharply separated off from the tissues in general, those of the sympathetic system are much more isolated, being gathered together only in small heaps, while in many instances single cells maintaining their existence far from all their fellows are completely isolated in the wilds of the body tissues, retaining communication with the centres only by means of their non-medullated axones. Under such circumstances it is perhaps but little wonder that these cells, like the pioneers of the backwoods, should present peculiarities both in habitus and conduct.



## CHAPTER XVIII.

### ON THE MECHANICAL FACTORS OF DEVELOPMENT AND THE HUMAN BODY AS A SEGMENTED ORGANISM.

Mechanical factors of development—The innervation of the diaphragm—Segmentation of the body—Metameres—Myotomes—Neurotomes—Angeiotomes—Sclerotomes—Enteromeres—Dermatomes—Sclerotozones—Part played by the marginal veil—Relation to the problems of heredity.

IN the study of the historical development of the nervous system, mechanical factors, of a very simple nature, when viewed close at hand, are continually met with. The results of the bending and shaping of the medullary tube in its early stages are apparently comparable in many respects, His thinks, with those which occur in a simple rubber tube when subjected to similar influences. The peripheral nerves in their outgrowth follow always, like blood-vessels in their advance, the channels of least resistance. In regions where there is much bending of the body—for example, in the neck and lumbar region—the nerve trunks converge to form the well-known plexuses.\* If a bundle of nerves in its outgrowth meet with any obstacle in its path, such as a bar of cartilage, a blood-vessel, or the wall of a cavity, the bundle tends to divide, a portion of the fibres passing on each side of the obstruction. In this way the curious distribution of many peripheral nerves, entirely obscure before these embryological studies, becomes explicable. An instructive example of the light afforded in certain dark corners by histogenetic studies is to be seen in the innervation of the diaphragm.

Von Baer † had pointed out that the diaphragm in mammals develops at first in the neck region and that it descends

---

\* Cf. His, W. Ueber den Aufbau unseres Nervensystems. Berl. klin. Wehnsehr., Bd. xxx (1893), S. 957; 996. Also in Wien. med. Presse, Bd. xxxiv (1893), S. 1477; 1521. Also in Wien. med. Bl., Bd. xvi (1893), S. 483; 497.

† v. Baer, K. E. Ueber Entwicklungsgeschichte der Thiere; Beobachtung und Reflexion., ii, S. 226.

later. He suggested its cervical origin as an explanation of the well-known fact that it is innervated (in the main at least) by a cervical nerve. Cadiat\* and His† recognized the mass of tissue which in the embryo is destined to give rise to the diaphragm. Mall‡ has studied the position of the diaphragm in several reconstructed human embryos, and his researches, taken together with those of Uskow§ and Ravn,|| show most clearly the shifting of the organs and the constantly changing relations accompanying the flexion and extension of the embryo. In Fig. 124 the position occupied by the diaphragm at various developmental stages is clearly shown. The position marked xliii corresponds closely to the position of the diaphragm in the adult; while xii, xviii, xix, ii, KO, and ix represent successive stages of the wandering process during development. When the phrenic nerve grows into the diaphragm the latter is in the cervical region, and the distance from the spinal cord to the muscle to

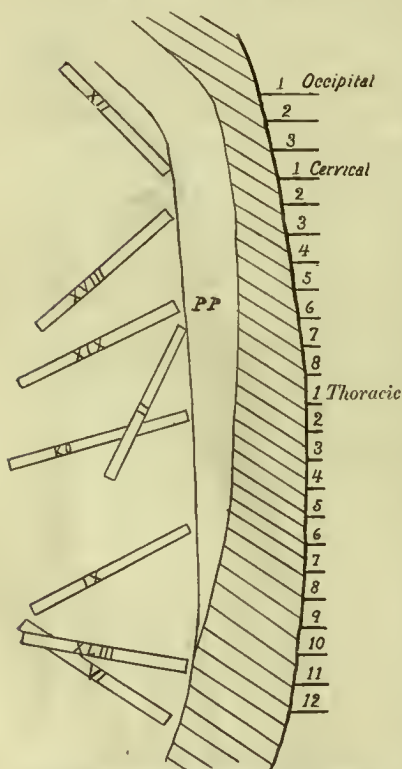


FIG. 124.—Diagram showing successive positions of the diaphragm during the development of the human embryo. (After Mall.)

\* Cadiat, O. Du développement de la portion céphalo-thoracique de l'embryon; de la formation du diaphragme, des plèvres, du péricarde, du pharynx et de l'œsophage, J. de l'anat. et physiol., etc., Par., t. xiv (1878), pp. 630-674.

† His, W. Anatomie menschlicher Embryonen, i, 1880; iii, 1885.

‡ Mall, F. P. Development of the Human Cœlom. J. Morphol., Bost., vol. xii, 1896-'97, pp. 395-453.

§ Uskow, N. Ueber die Entwicklung des Zwerchfells, des Pericardiums und des Cœloms. Arch. f. mikr. Anat., Bonn, Bd. xxii (1883), S. 143-219.

|| Ravn, E. Die Bildung des Sæptum transversum beim Hühnerembryo. Arch. f. Anat. u. Physiol., Anat. Abth., Leipz. (1896), S. 157-186.

be innervated is minimal. With the descent of the diaphragm the phrenic nerve grows and goes with it, so that in the adult we have an abdominal muscle innervated by a nerve of the neck. The work of His upon the recurrent laryngeal nerve, and of Nussbaum upon the wandering of muscles and their innervation, are of interest in this connection. As a matter of fact, an entirely new conception of the relations of the muscles to one another, and to the nerves and bones, has been gained through the anatomical studies of Huxley, Gegenbaur, Paterson, Dohrn, R. G. Harrison, Fürbringer, Mall, Eisler, Bolk, Ruge, van Wijhe, and others. Since from a morphological standpoint the muscles are most easily understood by considering them as end organs of the motor nerves some reference to the ideas at present held in this connection will here be in place.

As is well known, man, in common with a large series of animals, is a segmented organism. Even in the adult the vertebral column, the roots of the spinal nerves, the ribs, and the transverse bands of connective tissue in the rectus abdominis muscle give evidence of this. But when we go beneath the surface and study the segmentation of the body of man and other animals in the embryo, and compare the relations of adult structures with the embryological memberment, a conception of the anatomy of the human body is gained which is wholly foreign to and impossible for the ordinary student of the old-time dissecting room. This memberment or metamerism is most sharply to be made out in the embryo with the appearance of the primitive segments (protovertebræ, metameres, or *Ursegmente* of the Germans). The muscular system is originally laid down as a series of muscle segments (myotomes or somites) which are derived from the dorsal portion of the metameres. The segmentation is almost as clearly visible in the nervous system (neural segments, neuromeres, or neurotomes),\* in the

---

\* There is still dispute as to the neuromeres. The term was applied to the segmentation indicated by a series of alternating slight enlargements and constrictions of the medullary tube. Each enlargement is supposed to correspond to a pair of ventral nerve roots. The latter, however, appear to spring from the constriction between two neuromeres, and Minot (Human Embryology, page 605) suggests that the ventral roots arise from half of two adjacent *true* neuromeres. Cf. Platt, Julia B. Bull. Mus. Comp. Zool., at Harvard College, vol. xviii (1889), p. 171. Loey, W. A. Anat. Anz., Jena, Bd. ix (1894), S. 393. Neal, H. V. *Ibid.*, Bd. xii (1896), S. 377.

vascular system (vascular segment or intersegment or angiotope), and in the skeletal system (bone segments or sclerotomes); it is also to be made out probably, though much less distinctly, in the alimentary tract (enteromeres) and in the integument (dermatomeres). The overlapping or "telescoping" of the segments and of the segmental derivatives in general complicates the study in human beings, but without the conception of segmentation anatomy can not easily be understood.

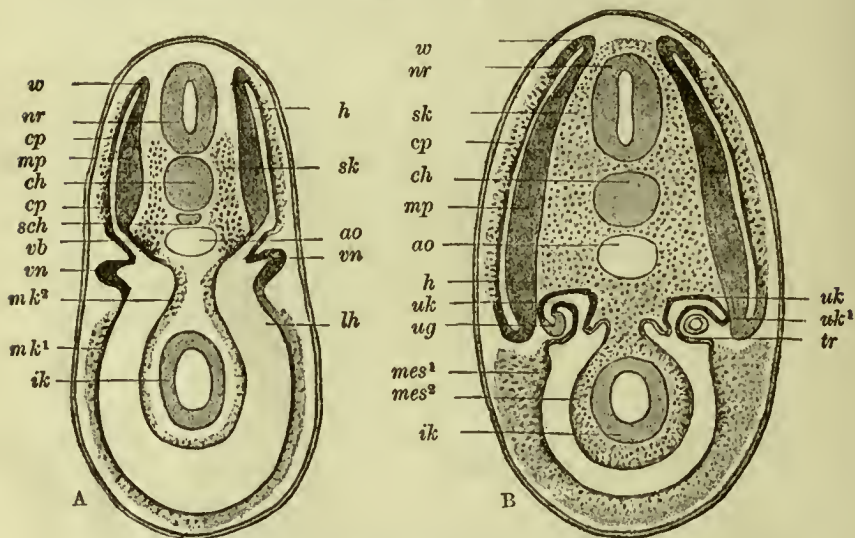


FIG. 125.—Schemes of transverse sections of younger and older Selachian embryos to illustrate the development of the chief products of the middle terminal layer. (After van Wijhe and Hertwig from A. Rauber, *Lehrbuch der Anatomie des Menschen*, Bd. i, Leipz., 1897, S. 52, Figs. 15, 16.)

A, transverse section through the region of the fore kidney of an embryo in which the musculo segment, *mp*, is being pinched off.

B, transverse section through a somewhat older embryo in which the muscle segments have been pinched off. *nr*, nerve tube; *ch*, chorda; *ao*, aorta; *sch*, subchordal column; *mp*, muscle plate of the primitive segment; *w*, zone of growth by which the muscle plate bends around into the skin plate, *cp*; *vb*, piece uniting the primitive segments with the body cavity from which the tubules of the primitive kidney, *uk*, develop; *sk*, skeletogenous tissue which arises by proliferation from the medial wall of the uniting piece, *vb*; *vn*, fore kidney; *mk¹*, *mk²*, parietal and visceral middle layer out of the walls of which the mesenchyme develops; *lh*, body cavity; *ik*, layer for intestinal glands; *h*, cavity of the primitive segment; *uk*, tubules of the primitive kidney; *uk¹*, point of separation of the tubules of the primitive kidney from the primitive segment; *ug*, duct of primitive kidney with which the kidney tubules have united on the right side; *tr*, connection of the tubules of the primitive kidney with the body cavity; *mes¹*, *mes²*, mesenchyme which has had its origin in the parietal and visceral middle layer.

Leaving out those of the head, the number of which is not yet exactly determined, the human body has from thirty-five to



thirty-seven primitive segments or metameres on each side; eight cervical, twelve thoracic, five lumbar, five sacral, and

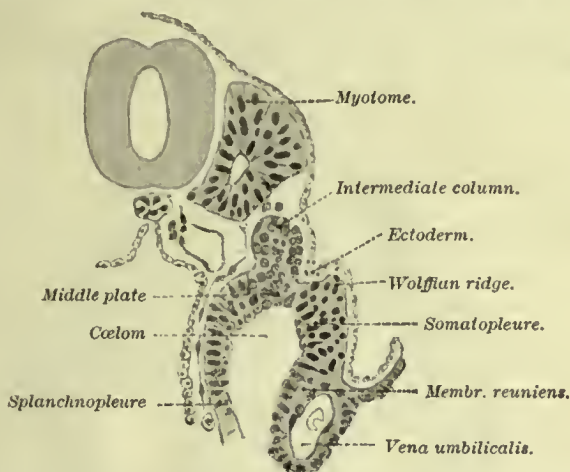


FIG. 126.—Human embryo fourteen to sixteen days old; left half of cross section  $\times 240$  to show developing myotome. (After J. Kollmann, *Lehrbuch der Entwicklungsgeschichte des Menschen*, Jena, 1898, S. 133, Fig. 71.)

from five to eight caudal. The primitive segments appear in the embryo as sharply defined masses in the mesoderm lateral from the chorda dorsalis and the medullary tube. They appear one by one, gradually increasing in number as the embryo grows, those in the cervical region being the first to become developed. Each metamere or primitive segment is divided into a dorsal portion and a ventral portion. The dorsal portion gives rise, as we have seen, to the myotome. The ventral portions of all the metameres are in the craniota fused to form a common cavity, the hypocœlom, sometimes called the ventral or unsegmented cœlom, which corresponds to the body cavity (pleuræ, pericardium, peritonæum), Fig. 125.

The appearances on section in the human embryo are represented in Fig. 126.

Each myotome or muscle segment is at first hollow, but later is seen to be filled with a core of cells, the so-called nucleus of the metamere (Remak's *Urwirbelkern*). These cells stream out from the medial side of each myotome to form the sclerotome or skeletal segment (Fig. 127), and there are accordingly as many sclerotomes as there are myotomes.

Corresponding to each metamere there is an artery and vein (vascular segment or angeiotome). Further, each metamere behind the head receives the motor root and the sensory root of one spinal nerve. This spinal nerve, including both the motor part and sensory part with its spinal ganglion, together with a

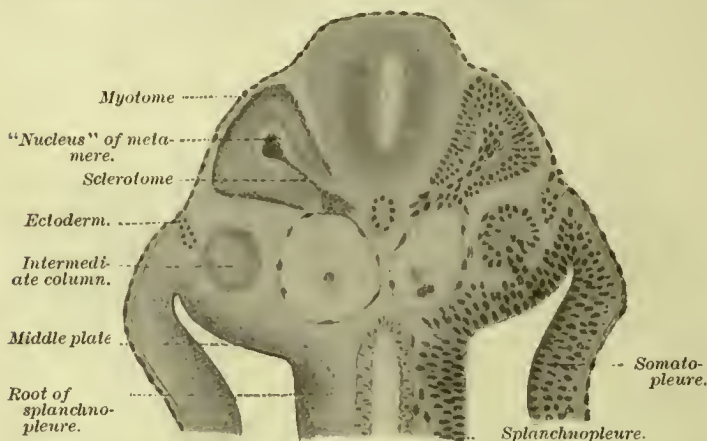


FIG. 127.—Human embryo at the end of the third week. Cross section at the level of the developing upper extremity to show developing myotome and sclerotome  $\times 100$ . (After J. Kollmann, *Lehrbuch der Entwicklungsge-schichte des Menschen*, Jena, 1898, S. 134, Fig. 72.)

portion of the medullary tube to which it belongs, represents one neural segment or neurotome.\*

The lines which in the embryo separate the primitive segments or metameres from one another are known as the inter-segmental lines. In these develop later those myosepta or myocommata which separate the myotomes from one another, and in the adult give origin to the ribs and the intermuscular septa.

The muscles of the body are divisible into (1) skeletal and (2) visceral muscles.

The skeletal musculature, which includes the eye muscles, the muscles of the trunk and of the extremities, arises from the myotomes. The visceral musculature, which includes the muscles of the alimentary tract and of the blood vascular system,

\* As will be pointed out in Section VI, Head thinks that a comparison of his studies with those of Sherrington indicate that the segment in the spinal cord does not exactly correspond to the nerve roots in its peripheral relations.

arises from the unsegmented mesoderm, especially from its visceral or splanchnic layer. There has been some dispute as to the nature of the muscles of the head (muscles of the eyes, tongue, jaws, and branchial arches), but the results of many investigators make it seem probable that they have their origin in atypical myotomes (ventral portions of head myotomes). Since they arise from the cells lining the cavities of the branchial arches, however, a number of investigators look upon them as belonging to the visceral musculature.

During development marked wanderings of the muscles take place, and it is exceedingly interesting to attempt to trace the relations of each embryonic myotome to the adult musculature. In general it would appear that each myotome of the trunk undergoes subdivision into a dorsal part and a ventral part, these two portions being separated from one another by connective tissue. The dorsal part of a myotome gives rise to the large muscular mass which occupies the costo-vertebral groove, Fig. 128, A 1. The ventral part of the myotome extends out into the ventral parietes (Fig. 128, A 2, 3, 4, 5), in the thorax, for example, helping to give rise to the intercostal muscles (2), the subvertebral muscles (3), the subcostal muscles (4), and the muscles of the upper extremity (5). The ventral musculature (Fig. 128, A 2, 3, 4, 5, and B v.) together with the dorsal musculature (Fig. 128, A 1, B d.) make up the parietal musculature derived from one myotome. The visceral musculature corresponds to the mass marked (6) in the figure.

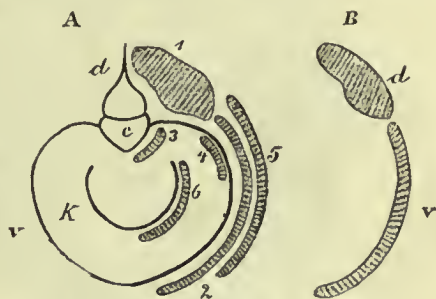


FIG. 128.—Scheme of bone and muscle segment. (After A. Rauber, *Lehrbuch der Anatomie des Menschen*, V Aufl., Leipzig, 1897, S. 466, Fig. 498.)

A.—c, body of vertebra; d, arcus vertebræ; v, arcus costarum; K, arcus visceralis; 1, dorsal part of muscle segment; 2-5, ventral part of muscle segment with its different subdivisions; 3, prevertebral; 4, subcostal; 2, intercostal; 5, portion for extremity; 6, visceral muscle.

B.—The parietal muscle segment brought to its simplest expression; d, dorsal part; v, ventral part.

The division of the parietal musculature into a dorsal portion and a ventral portion separated by a connective-tissue septum is very much more distinct in lower vertebrates than it is in man. The line of separation between the dorsal and

ventral musculature is known in these animals as the lateral line (*Seitenlinie* of the Germans),\* and here are situated an important series of sense organs known as the "sense organs of the lateral line." It is not unlikely that the so-called branchial sense organs (Beard), which appear temporarily in the region of the head in young embryos of higher forms, correspond to the sense organs of the lateral line of lower animals.

Each myotome has a neurotome corresponding to it by which it (along with the skin and other adjacent structures) is innervated. The ventral and dorsal roots of a spinal nerve unite to form a common trunk, the mixed nerve stem. The latter, the peripheral representative of one neurotome, divides into a dorsal ramus and a ventral ramus. The dorsal ramus in-

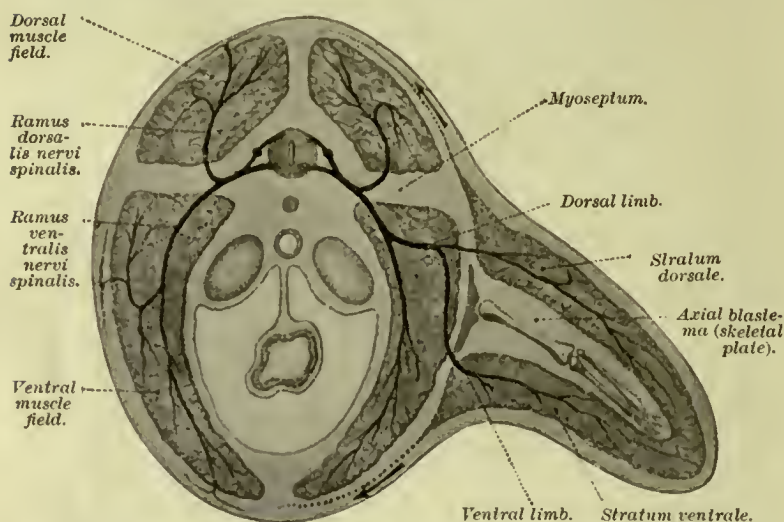


FIG. 129.—Trunk segment of human embryo with one pair of nerves and the rudiment of the musculature of one extremity at the sixth week, schematic. (After J. Kollmann, *Lehrbuch der Entwicklungsgeschichte des Menschen*, Jena, 1898, S. 289, Fig. 164.)

nervates the dorsal portion of the myotome, the ventral ramus the ventral portion of the myotome, Fig. 129.

At the time the union of the neurotome with the myotome occurs, the latter is in close proximity to the medullary tube,

\* Corresponding to this we have in human beings the deep layer of the fascia lumbodorsalis separating the dorsal musculature of the trunk from the ventral.



and the distance to be traversed by the outgrowing nerve is minimal. As development proceeds, however, the muscles change their position, in large part owing to their skeletal attachments, and become farther and farther removed from the places in which they originate. The displaced myotome derivatives carry their nerve branches with them; where the muscle goes, the nerve accompanies it. In the adult the easiest clew, as a matter of fact, to the myotomic origin of a given muscle is its nerve supply.

Some of the muscles of the adult body have been derived from more than one myotome. Thus, those arising from two myotomes are known as diplomeric muscles (e. g., the supraspinatus and infraspinatus muscles), those from more than two myotomes as polymeric muscles (e. g. the pectoralis major and minor muscles). In such instances the diplomeric or polymeric origin of a muscle is indicated in the adult by its diplomeric or polymeric innervation, for muscles derived from more than one myotome are innervated by nerves derived from the ventral roots belonging to more than one neurotome.

The origin of the muscles of the extremities and the innervation of these muscles are of especial interest. For our knowledge in this connection we are much indebted to Dohrn,\* P. Mayer,† Kästner,‡ Paterson,\* van Wijhe,|| van Bemmelen,△

\* Dohrn, A. Studien zur Urgeschichte des Wirbelthierkörpers. VI. Die paarigen und unpaaren Flossen der Selachier. Mittheil. aus der zool. Station zu Neapel, Bd. v (1884). Also, Die unpaare Flosse in ihrer Bedeutung für die Beurtheilung der genealogischen Stellung der Tunicaten und des Amphioxus, und die Reste der Beckenflosse bei Petromyzon. *Ibid.*, Bd. vi (1885).

† Mayer, P. Die unpaaren Flossen der Selachier. Mittheil. aus der zool. Station zu Neapel, Bd. vi (1885).

‡ Kästner, S. Ueber die allgemeine Entwicklung der Rumpf- und Schwanzmuseulatur bei Wirbelthieren; mit besonderer Berücksichtigung der Selachier. Arch. f. Anat. und Phys., anat. Abtheil., Leipz. (1892), S. 153-222; also Ueber die Entstehung der Extremitätenmuseulatur bei den anuren Amphibien. Verhandl. d. anat. Gesellsch., Jena, 1893, Bd. vii, S. 193-199.

\* Paterson, A. M. On the Fate of the Muscle Plate and the Development of the Spinal Nerves and Limb-Plexuses in Birds and Mammals. Quart. J. Mier. Sc., Lond., n. s., vol. xxviii (1887-'88), pp. 109-129.

|| van Wijhe, J. W. Ueber die Mesodermsegmente und die Entwicklung der Nerven des Selachierkopfes. Verhandl. d. k. Akad. v. Wetensch. Amst., Deel xxii (1888), pp. 1-30.

△ van Bemmelen, J. F. Ueber die Herkunft der Extremitäten- und

Kollmann,\* and in America, Ryder,† and especially R. G. Harrison.‡ The musculature of the extremities is derived in the

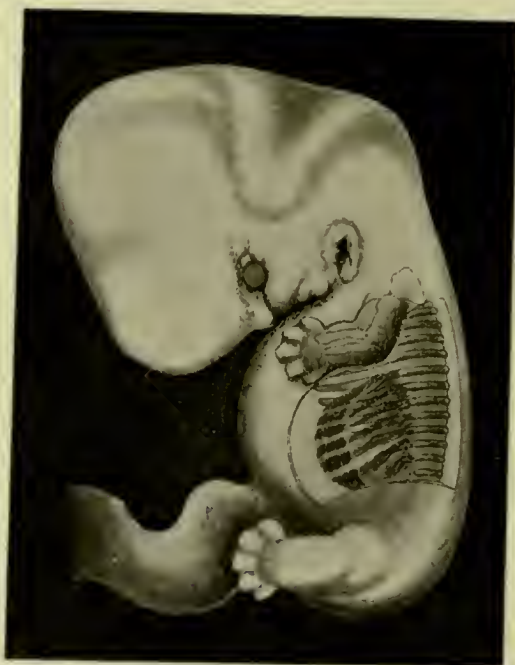


FIG. 130.—Reconstruction of a young human embryo enlarged five times, illustrating the position of the *M. rectus abdominis* and its polymeric nature. (After F. P. Mall, *J. Morphol.*, Bost., vol. xiv (1897-'98), Pl. B, Fig. 4.)

Zungenmuskulatur bei Eidechsen. *Anat. Anz.*, Jena, Bd. iv (1889), S. 240–255.

\* Kollmann, J. Die Rumpfsegmente menschlicher Embryonen von 13 bis 35 Urvirbeln. *Arch. f. Anat. und Phys.*, Leipz., Anat. Abtheil. (1891), S. 39–88.

† Ryder, J. A. A Contribution to the Embryography of Osseous Fishes with Special Reference to the Development of the Cod (*Gadus morrhua*). Annual Report U. S. Com. of Fish and Fisheries for 1882.

‡ Harrison, R. G. Ueber die Entwicklung der nicht knorpelig vorgebildeten Skelettheile in den Flossen der Teleostier. *Arch. f. Mikr. Anat.*, Bonn, Bd. xlii (1893); also The Development of the Fins of Teleosts. The Johns Hopkins University Circulars (1894), No. 111; also The Metamerism of the Dorsal and the Ventral Longitudinal Muscles of the Teleosts. The Johns Hopkins University Circulars (1894), No. 111; also Die Entwicklung der unpaaren und paarigen Flossen der Teleostier. *Arch. f. mikr. Anat.*, Bonn, Bd. xlvii (1895), S. 500–578.

main from muscle buds which are pinched off during development from the trunk myotomes. According to Harrison, a certain number of the muscles of the extremities are derived from the unsegmented mesenchyme rather than from the myotomes.

It seems likely that the relations of myotome to neurotome hold also for the extremities, but thus far, owing to the extremely complicated processes of development, it has been im-

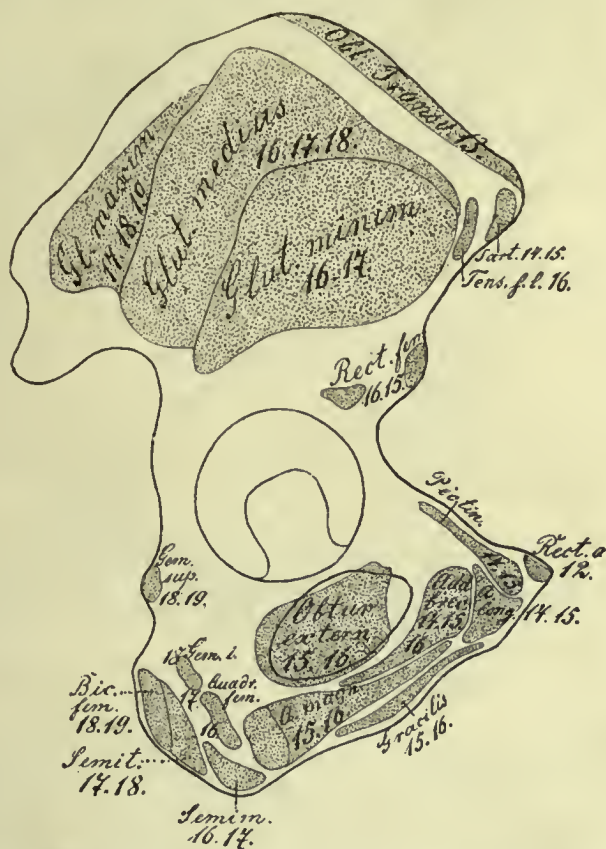


FIG. 131.—Fields on the external surface of the os innominatum corresponding to the attachment of the various muscles. The thoraco-lumbo-sacral nerves (12th–19th) governing the individual muscles are indicated. (After L. Bolk, *Morphol. Jahrb.*, Leipz., Bd. xxi, 1894, S. 242, Fig. 1.)

possible to determine this absolutely. Here also in the adult structure it seems probable, however, that the neurotome supply,

when it can be established, is a safe guide to follow in drawing conclusions as to the myotomic origin of the various muscles.

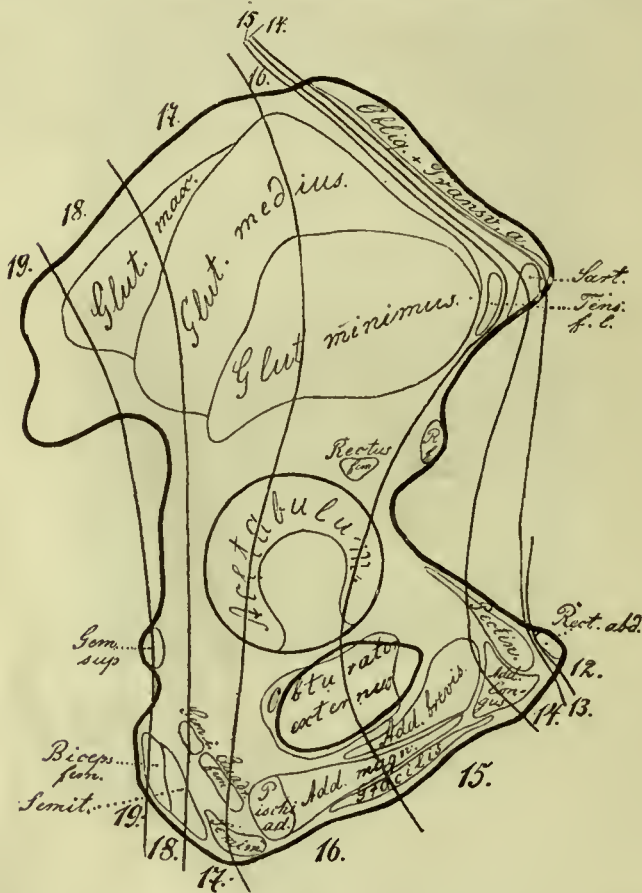


FIG. 132.—Outer surface of os innominatum. The lines bound the areas in which are found the attachments of the muscle masses derived from the myotomes innervated by the 12th to the 19th thoraco-lumbo-sacral nerves. The girdle zones on the bone between the lines are the so-called "sclero-zones." (After L. Bolk, *Morphol. Jahrb.*, Leipz., Bd. xxi, 1894, S. 245, Fig. 2.)

That these general principles hold for the human abdominal muscles and their innervation has recently been demonstrated by Mall,\* Fig. 130.

\* Mall, F. P. Development of the Ventral Abdominal Walls in Man. *J. Morphol.*, Bost., vol. xiv (1897-'98), pp. 347-366.



An extensive series of investigations undertaken by Bolk\* must here be referred to. His results regarding the innervation of the muscles of the pelvis and their bony attachments may be chosen as an example. As will be seen by reference to Fig. 131, there are successively attached to the ilium in a ven-

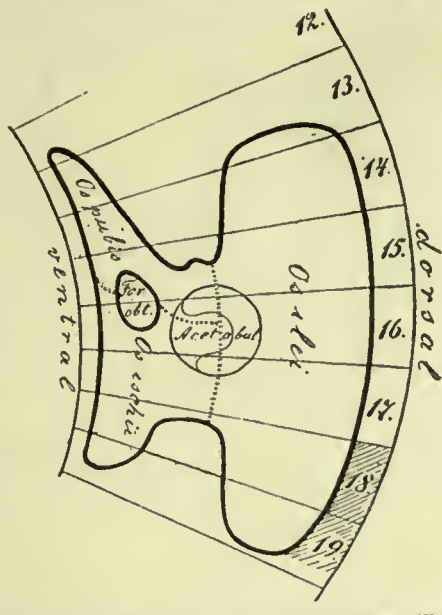


FIG. 133.—Reconstructed form of pelvis of human fetus, illustrating skeletal areas corresponding to the myotomes innervated by the 12th-19th thoracolumbo-sacral nerves. (After L. Bolk, *Morphol. Jahrb.*, Leipz., Bd. xxi, 1894, S. 256, Fig. 3.)

tro-dorsal direction the following muscles: (1) *M. sartorius*; (2) *M. tensor fasciæ latæ*; (3) *M. glutæus minimus*; (4) *M. glutæus medius*, (5) *M. glutæus maximus*; (6) *M. piriformis*.

\* Bolk, L. Beziehungen zwischen Skelet, Muskulatur und Nerven der Extremitäten, dargelegt am Beckengürtel, an dessen Muskulatur, sowie am Plexus lumbosacralis. *Morphol. Jahrb.*, Bd. xxi (1894), S. 241-277; also, Rekonstruktion der Segmentirung der Gliedmassenmuskulatur, dargelegt an den Muskeln des Obersehenkels und des Schultergürtels. *Morphol. Jahrb.*, Leipz., Bd. xxii (1894-'95), S. 357-379; also, Die Sklerozonie des Humerus; zugleich ein Beitrag zur Bildungsgeschichte dieses Skelettheiles. *Morphol. Jahrb.*, Leipz., Bd. xxiii (1895), S. 391-411; and Die Segmental-differenzirung des menschlichen Rumpfes und seiner Extremitäten. *Morphol. Jahrb.*, Leipz., Bd. xxv, II. 4, S. 465.

These muscles are innervated by a corresponding series of ventral roots, as is shown by the accompanying table.

TABLE I.

Serial sequence of the muscles according to their origin from the ilium in ventro-dorsal direction.	Innervation of the muscles by thoraco-lumbo-sacral spinal nerves.
1. <i>M. sartorius.</i>	14 15
2. <i>M. tensor fasciæ latæ.</i>	16 (17?)
3. <i>M. glutæus minimus.</i>	16 17
4. <i>M. glutæus medius.</i>	16 17 18
5. <i>M. glutæus maximus.</i>	17 18 19
6. <i>M. piriformis.</i>	18 19

Again, the following muscles are successively attached to the pubis and ischium in ventro-dorsal direction.

(1) *M. rectus abdominis*, *M. pectineus*, *M. adductor longus*, *M. adductor brevis*, *M. gracilis*, *M. adductor magnus*, *M. obturator externus*, portio ischiadica *M. adductor magni*, *M. quadriceps femoris* with the *M. gemellus inferior*, *M. semimembranosus*, *M. semitendinosus*, *M. biceps femoris*, *M. gemellus superior* (*obturator internus*). These muscles are in a similar way innervated by a series of ventral motor roots of spinal nerves passing in a cranio-caudal direction, as the following table makes clear :

TABLE II.

Serial sequence of the muscles according to their origin from the pubis and ischium in ventro-dorsal direction.	Innervation of the muscles by the following thoraco-lumbo-sacral spinal nerves.
1. <i>M. rectus abdominis.</i>	6-12
2. <i>M. pectineus.</i>	14 15
3. <i>M. adductor longus.</i>	14 15
4. <i>M. adductor brevis.</i>	14 15 16
5. <i>M. gracilis.</i>	15 16
6. <i>M. adductor magnus.</i>	15 16
7. <i>M. obturator externus.</i>	15 16
8. Portio ischiadica <i>M. adductor magni.</i>	16
9. <i>M. quadriceps femoris</i> + <i>M. gemellus inferior.</i>	16 17 18
10. <i>M. semimembranosus.</i>	16 17
11. <i>M. semitendinosus.</i>	17 18
12. <i>M. biceps femoris.</i>	18 19
13. <i>M. obturator internus</i> ( <i>gemellus superior</i> ).	16 17 18 19

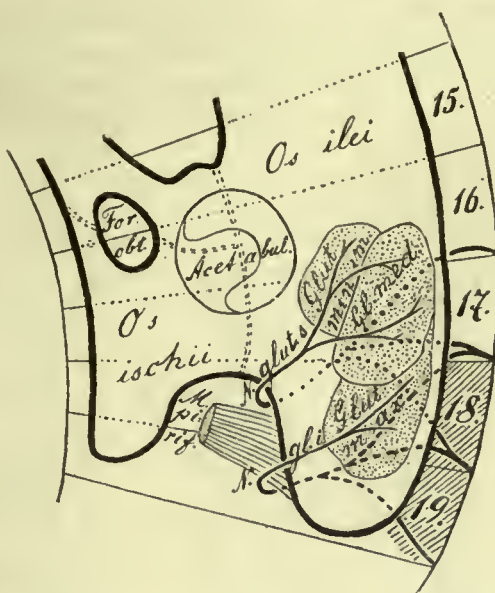


FIG. 134.—Arrangement of the metazonal dorsal nerves for the musculi glutæi.  
(After L. Bolk, *Morphol. Jahrb.*, Leipz., Bd. xxi, 1894, S. 260, Fig. 4.)

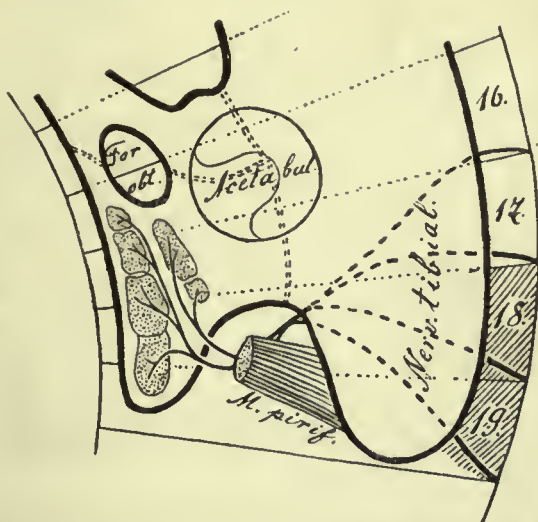


FIG. 135.—Arrangement of the metazonal ventral nerves for the Mm. flexores.  
(After L. Bolk, *Morphol. Jahrb.*, Leipz., Bd. xxi, 1894, S. 261, Fig. 5.)

Bolk has accordingly drawn a series of lines over the surface of the pelvis corresponding to the limits of the attachments of the derivatives of successive myotomes. The position of these

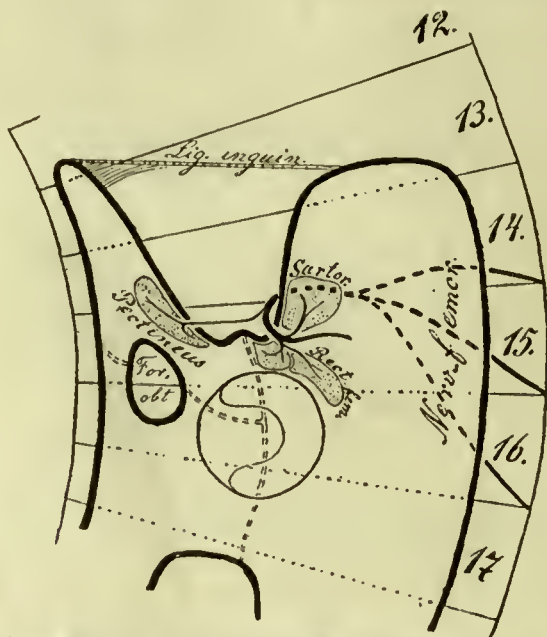


FIG. 136.—Arrangement of the prozonal dorsal N. femoralis. (After L. Bolk, *Morphol. Jahrb.*, Bd. xxi, 1894, S. 263, Fig. 6.)

lines corresponds to the myocommata or mesodermal septa which in the embryo separate the myotomes from one another. It seems likely that the distribution of one myotome stands in a definite relation to that of a given sclerotome. The surface of the bone giving attachment to the muscles derived from a given myotome is known as a sclerozone. In Figs. 131 and 132 the various sclerozones on the outer surface of the pelvis are demonstrated. It will be noticed that the muscles attached to the ventral surface of the pelvis have been derived from myotomes more anteriorly placed, while those attached to the dorsal part of the pelvis have originated in myotomes more caudally situated.

That the relations are much more simple in the embryo is not surprising, and Bolk has done anatomy an important service in pointing this out. In Figs. 133 to 138 the foetal



conditions are illustrated. The sclerozones at this period are limited by straight lines. The bone is much simpler in form, the complexity of the later relations of the muscles and nerves being in large part due to skeletal alterations. For a description of the (1) prozonal, (2) diazonal, and (3) metazonal nerve trunks\* ((1) N. femoralis, (2) N. obturatorius and (3) N. ischiadicus, Nn. glutæi and N. obturatorius internus) and the mechanical factors which have led to the curious distributions of muscles and nerves in the adult, the original article of Bolk may be consulted. An excellent epitome of portions of the re-

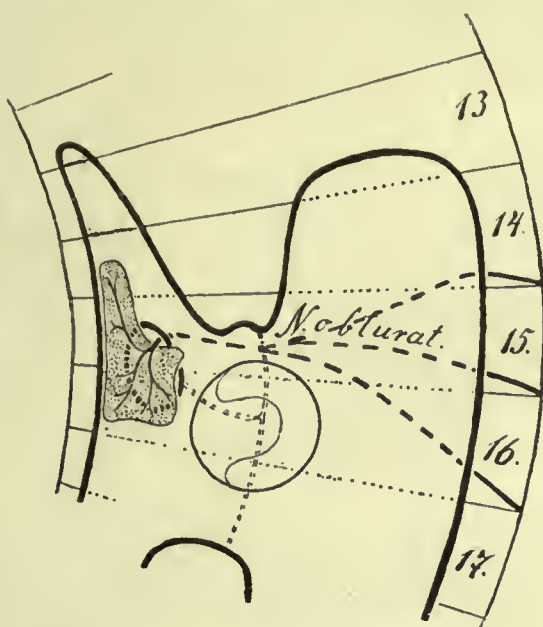


FIG. 137.—Arrangement of the diazonal ventral N. obturatorius. (After L. Bolk, *Morphol. Jahrb.*, Bd. xxi, 1894, S. 265, Fig. 7.)

search is given in the last edition of Rauber's Text-book of Anatomy.†

The sclerozonic anatomy of the humerus is indicated in Figs. 139 to 142. Bolk believes that the mesenchyme out of

\* Nomenclature of Max Fürbringer.

† Rauber, A. *Lehrbuch der Anatomie des Menschen*. V. Aufl., Leipz. (1898), Bd. ii, S. 566 ff.

which that portion of the skeleton which corresponds to a sclerozone is formed arises from the same segment as the myomere belonging to the sclerozone, but will not assert that the whole mesenchyme undergoes segmentation—that is, that a definite metamerism of its whole substance can be demonstrated.

It appears that the humerus is formed of the mesenchyme corresponding to the fifth, sixth, seventh, and eighth cervical myomeres. It is a curious circumstance that of the muscles of the humerus in the *proximal* part of the bone, all are derived from the dorsal layer of the musculature, none from the ventral (*cf.* stratum dorsale and stratum ventrale in Fig. 129). The only muscle of ventral origin at the proximal end of the hu-

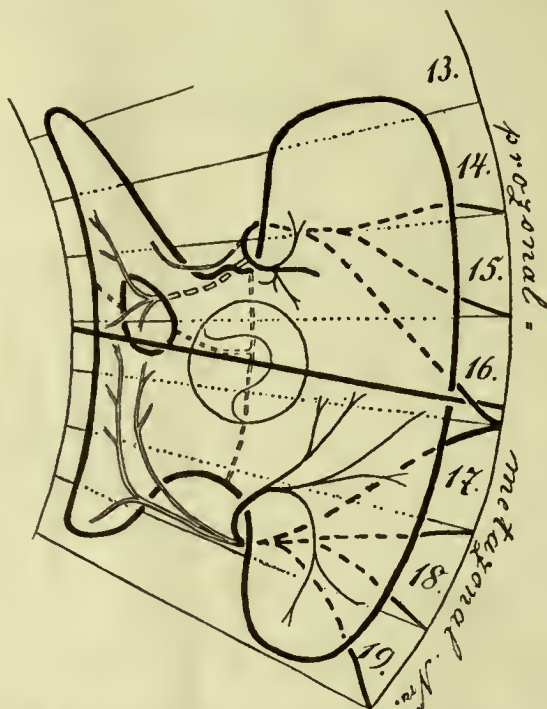


FIG. 138.—Arrangement of the ventral and dorsal prozonal, diazonal, and meta-zonal nerves. (After L. Bolck, *Morphol. Jahrb.*, Bd. xxi, 1894, S. 266, Fig. 8.)

merus is the long head of the biceps, which comes from the stratum ventrale derived from the fifth and sixth cervical myomeres. Even this is not connected with the ventral surface of

the axial blastema, but lies instead in the bicipital groove (sulcus intertubercularis), a fact which Bolk looks upon as evidence that the ventral mass of the axial blastema has in this region not been differentiated. Despite the fact that the sclerozones longitudinally considered take a tortuous course down the hu-

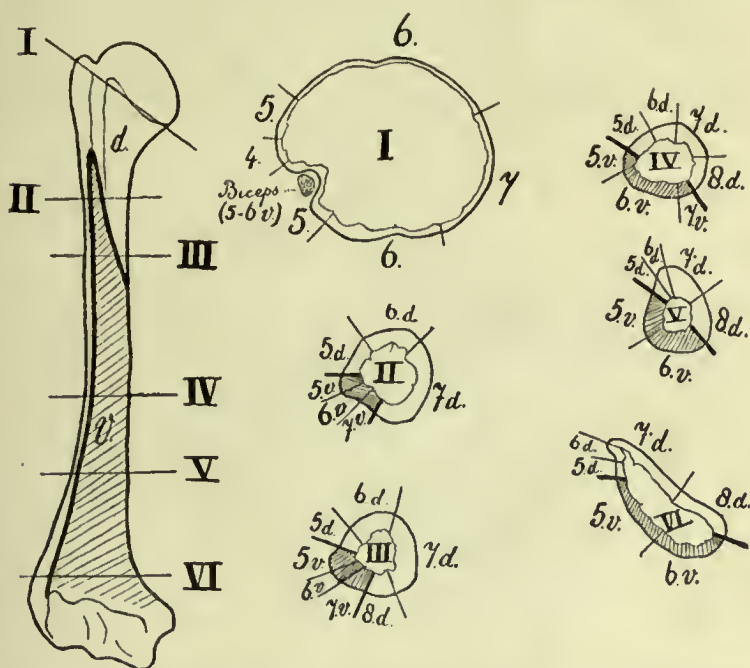


FIG. 139.—Six transverse sections through a right upper arm, I-VI, at the different levels indicated in the longitudinal view of the humerus. The relation of the (dark) ventroplanum to the (colorless) dorsoplanum, as well as the position of the 4-6 cervical sclerozones, are illustrated. (After L. Bolk, *Morphol. Jahrb.*, Leipz., Bd. xxiii, 1895, S. 401, Fig. 4.)

merus, they are reciprocally regularly arranged, as the cross sections of Fig. 139 show. That the ventral and dorsal musculature, even in the adult, form two sharply separable groups, and that in each of these groups the primitive segmental arrangement is discoverable, will be clear from a study of Figs. 140 to 142.

The most wonderful, however, of all the mechanical factors concerned in the development of the nervous system would seem to be those which, according to the ingenious hypotheses of

His, are connected with the marginal veil. It is almost like a fairy tale to be told that the direction of many millions of white fibres within the central nervous system during development depends upon simple obstructions offered at the proper time and in the right degree to the outgrowing processes of the neuroblasts. We have seen the long distances which certain of the axones have to travel from their cells of origin in order to reach the cell bodies and dendrites of the other neurones which they have to influence, some of the axones of the fibres of the pyramidal tract, for instance, having to extend

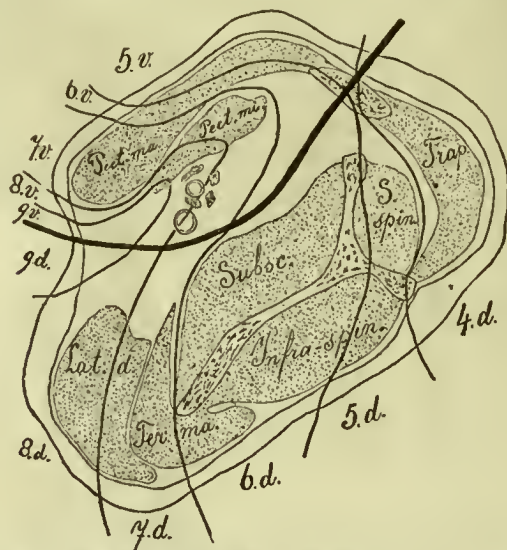


FIG. 140.—Transverse section through the musculature of the shoulder and chest. The heavy dark line indicates the limit between ventral and dorsal derivatives of the myomeres. The other lines show the limits of the products of the 4th-9th cervico-thoracic myomeres. (After L. Bolk, *Morphol. Jahrb.*, Leipzig, Bd. xxiii, 1895, S. 408, Fig. 10.)

from the gyri centrales to the lumbar region of the spinal cord. We have also noted the manifold metamorphoses passed through in some localities at several periods of development. And when one recalls these distances and complications, even when lessened and simplified by looking through the large end of the telescope of embryology, it seems almost inconceivable that mechanical factors alone should so direct the inherent activities of the growing tissues as to ultimately give rise to adult





the bodily and mental characteristics of the individual are hereditarily transmissible. As His finely puts it (the translation is free): "It is exactly in these last considerations that the key for the correct understanding of the special relations is to be sought. Like every other organic formation process, the origin of one's body and of its nervous system appears as the expression of a life process in course of progress (*im Gang befindlichen Lebensprozess*). The beginning of the process we do not know, for since time immemorial it has been striding forward, periodically producing new individuals and again destroying them. Each individual life is only a participating member of the life of its generation series, comparable to a single one of the waves resulting from the propagation of one wave over wide surfaces of the sea. Advancing from one member to another, the life of the generation passes through phases of the greatest simplicity in order to elevate itself again to summits of the greatest total energy. In those phases of the transference of life from member to member, the mass serving as the bearer of it sinks to a minimum. An imponderable amount of material suffices to carry over the life in a strictly regular way. And while life is a periodical process there is an all-pervading law which commands all its component processes and their internal connection. In such a mechanism one process goes over into another; each appears at a given time as a definite sequence of processes which have gone before, and at the same time as the necessary determinant of processes which shall come after. And even where processes of apparently different origin and significance reciprocally influence one another, yet they all act at the place assigned to them by the general law, and do no more and no less than is ordered."

It is now necessary to hasten on to the consideration of the neurone as the unit in physiological and pathological processes.

## SECTION V.

### THE NEURONE AS THE UNIT IN PHYSIOLOGICAL AND PATHOLOGICAL PROCESSES.

#### CHAPTER XIX.

##### INTRODUCTORY.

The cell doctrine and the nervous system—Physiology of the neurones—The metabolism and nutrition of neurones—Effect of alteration in blood supply—The food stuffs and excretory products of neurones—Constancy of function despite continual change.

FORTY years have passed since Virchow, in his *Cellular Pathology*,\* gave expression to the conviction that every animal appears as a sum of vital units, each of which exhibits in itself all the characteristics belonging to life. It was his belief that the character and the unity of life are referable not to any single locality of a higher organization—for example, to the brain of man—but rather to the definite constantly recurring arrangement (*Einrichtung*) which every single element bears within itself. According to this view, the composition of a larger body, of the so-called individual, always depends upon a social arrangement; it represents, in fact, a social organism, in which there is a mass of single existences related to one another in such a way that every element has its own special activity, and each, even when incited to activity by other parts, does its work of itself. While this concept, which led to a revolution in the prevailing ideas regarding pathology, was accepted for the body in general, its application to the nervous system, and especially to the brain, was for a long time very little emphasized and only recognized in a vague sort of way. And indeed this can hardly be matter of sur-

---

\* Virchow, R. *Die Cellularpathologie in ihrer Begründung auf physiologische und pathologische Gewebelehre*. Zwanzig Vorlesungen., xvi, pp. 440, 8vo, Berl., 1858.

prise when we consider the crudeness of knowledge at that time of the structures concerned. But with the establishment of the neurone concept of the nervous system the importance and applicability of such a view of its constituent organs can be more fully appreciated. Only after it had been clearly shown that the nervous system, like all other tissues, consists of elements more or less isolated and independent, and connected directly with one another apparently only by contact, concrescence, or protoplasmic bridges, and after we had learned to recognize the different structures which belong to the single elements, could the study of the functional units in the nervous system be satisfactorily approached.

An extensive series of physiological and pathological data concerning nerve cells and nerve fibres has been accumulated. Many of these data appear to be discordant or even actually contradictory. It will be of interest to consider briefly how some of them appear when regarded from our new visual angle, and to see in how far the new doctrine has brought into agreement results which were formerly adduced on both sides in support of conflicting views.

In a systematic description of the physiology of the neurones it would be necessary to consider not only the functions which they possess in common with all cells, including such fundamental phenomena as those of metabolism and reproduction, but also those which are peculiar to neurones in general and to neurones in particular. The facts already collected bearing on these points, if adequately discussed, would demand the space of a volume of considerable size, although they represent but an infinitesimal amount of knowledge compared with that which is still needed to explain all the complicated manifestations of the various parts of the nervous mechanism of mammals. I shall bring forward at this time only a few of the physiological and pathological considerations which seem to be of especial importance in relation to the morphological characteristics previously outlined. It will be most convenient to divide these into three classes: (1) Those bearing upon the metabolism of the neurones, (2) those concerning the phenomena of irritability as manifested by the neurones, and (3) those referring to the interdependence of the trophic function and the manifestations of irritability. From a discussion of these it will be found that the physiological independence of the



neurone is as marked a feature as might have been expected from our knowledge of its morphology.

*The Metabolism and Nutrition of Neurones.*—To the study of the nutritive processes in neurones or their metabolism—anabolic and catabolic—attaches a high degree of interest, although the subject is attended with great difficulties. Like all other cells of the body, the living neurones take up food materials into their substance, transform them, and gradually build them up through a series of synthetic processes into highly complex and extremely labile chemical compounds, which, in turn, undergo a series of decomposition reactions which culminate finally in the formation of more or less simple bodies, which we recognize as the excretory products of neurone metabolism. There is every reason to believe that in these various modifications of chemical materials by means of which the potential energy of the food is transformed into the kinetic energy which gives rise to what are called the “vital” manifestations of the neurones, chemical compounds come into existence, in some of the neurones at least, of a degree of complexity scarcely approached elsewhere on this planet, and before the nature of which the most advanced organic chemist stands utterly powerless and despondent. It is in the nervous system of all parts of the human body that the delicacy and complexity of the chemistry of metabolism are most in evidence. It is there that we find the best examples of the extreme instability of the “living” substances, in that the slightest influence will often suffice to bring about remarkable transformations and extensive functional manifestations in the cells. To quote from Pflueger: “What infinitesimally small active forces acting in a ray of light call forth the most powerful effects in the retina and in the brain! How entirely minimal are the active forces of the nerves; what wonderfully minute quantities of certain poisons suffice to completely destroy a large living animal!”

The dependence of the neurones upon nutritive influences is well shown in certain circulatory disturbances. When the nutrition of the brain falls below a certain minimum the mental capacities become clouded or may even vanish. In fainting, we have the proof that without an adequate supply of oxygenated blood complete consciousness can not be maintained even for a second. The blood supply to the nervous system is extremely well provided for by the circulatory apparatus of the

brain and spinal cord, though there would appear to be a grave imperfection in the arrangement of the arterial system which terminates in the so-called end arteries, so that the blocking of a single one leads inevitably to the death of the territory supplied by it.

As to the nature of the substances which represent the raw food stuffs of the neurones, we have as yet but little definite information. While ultimately the substances taken up as food stuff by the neurones must be derived from the general food ingested by the individual, this must undoubtedly have undergone most marked alterations before being presented to the nerve cells in the blood and lymph as material suitable for their sustenance. There is considerable evidence that some of the material at least must have already played a part in the metabolism of other organs, and, in a sense, as their excreta have first been rendered suitable for use by the nerve cells. The physiological law formulated so long ago, accredited to Treviranus, is probably as true for the nervous system as for the other organs of the body. A possible example of this is seen in the thyroid metabolism; in the absence of substances in the body derived from the thyroid gland, the nervous system undergoes very important and serious metabolic modifications evidenced by the remarkable nervous and mental phenomena with which all are now familiar. On restoring these substances to the body by the administration of a thyroid extract the symptoms may sometimes be made to disappear.\* It is likely, however, that the neurones find their staple foods in the main nutritive constituents of the blood as derived from the food digested in the stomach and intestines and purified by the lymph glands and liver. That the stainable substance of Nissl may represent deutoplasm—the contents of the larders of the nerve cell—is not at all improbable, inasmuch as Held † and Macallum have pointed out that they yield the reactions characteristic of the nucleo-albumins.

---

\* This assumption does not, of course, exclude the possibility that the relation of the thyroid to the nervous system may consist in the destruction or neutralization by the products of the former of a substance or series of substances which are inimical to the latter. In any event the disturbances in the neurones must be thought of as metabolic in character.

† This writer terms them the "rolling stock" (*Betriebsmaterial*) of the nerve cells.

There can be but little doubt that the individual neurones select from the blood or lymph quantities and varieties of food stuffs corresponding to their individual needs, and it is still more certain that the constructive metabolism in one neurone or set of neurones varies from that in another within certain limits which, though perhaps usually narrow, in some instances must be tolerably wide. Failing this, it would be impossible to understand, even with varying correlations, the different functional manifestations of which the individual neurones and groups of neurones in different parts of the nervous system are capable.

One striking feature in neurone metabolism is particularly to be noted. With chemical processes ever in progress, with syntheses and decomposition reactions going on all the time, the one set of reactions predominating perhaps at one moment, the second at another, both classes of changes occurring now with great rapidity and again with comparative slowness, but in any case always continuously—with all this “perpetual flux”—a certain constancy of structure and function is maintained. The best evidence, perhaps, of this physiological constancy, notwithstanding continual change (*Dauer im Wechsel*), is to be found in the consideration of the phenomena of memory. We now know that when certain cells are destroyed by disease or removed by the knife of the surgeon, the capacity for calling up certain memory pictures is lost. Certain psychical elements or constituents which had faded from consciousness, but could be reinstated by secondary suggestion before the cells were destroyed or removed, can afterward be no longer revived. This fact would almost justify us in believing that the “memory traces” are in some way or another laid down in the neurones, and are actually organically connected with them. These neurones with which the memory traces are in some way associated are continuously undergoing the metabolic changes, such as have just been described, and the wonder is not that we have such poor memories, but that they are as good as we find them to be. Far from being surprised that the reproduction of past experiences in consciousness is occasionally unfaithful, we can only wonder how it can reach the degree of accuracy with which we are familiar.

While emphasizing the maintenance of a certain constancy of function, and consequently of structure, despite the unend-

ing chemical alterations going on, we must admit that the metabolism in no individual is perfectly constant. This is shown in the first place, should illustration of what is so obvious be demanded, under normal conditions in the gradual increase and development of the faculties of the nervous system in early and middle life, and in their gradual decay as the end is approached. Again, taking memory once more for an example, it is probable that no reproduction of past experience is absolutely accurate, nor is the attempt to recall one and the same experience on two different occasions attended by the appearance in consciousness of exactly the same mental picture. Even when the focal constituents in consciousness are almost or precisely the same, the marginal setting of so-called "sub-conscious" elements may be at the two times entirely different. There is always more or less variation, the differences being often, perhaps, scarcely recognizable, but none the less existing.\* A whole array of evidence could be brought forward demonstrating functional alterations dependent upon disturbances of

---

\* This idea had not its birth with modern physiologists, for did not the wise Diotima of Mantinea tell it long ago to Socrates? Let me quote from *The Symposium of Plato* (Jowett's translation):

"For even in the same individual there is succession and not absolute unity; a man is called the same; but yet in the short interval which elapses between youth and age, and in which every animal is said to have life and identity, he is undergoing a perpetual process of loss and reparation—hair, flesh, bones, blood, and the whole body are always changing. And this is true not only of the body but also of the soul, whose habits, tempers, opinions, desires, pleasures, pains, fears, never remain the same in any one of us, but are always coming and going. And what is yet more surprising is, that this is also true of knowledge; and not only does knowledge in general come and go, so that in this respect we are never the same, but particular knowledge also experiences a like change. For what is implied in the word 'recollection' but the departure of knowledge, which is ever being forgotten, and is renewed and preserved by recollection, appearing to be the same although in reality new, according to that law of succession by which all mortal things are preserved, not by absolute sameness of existence, but by substitution, the old worn-out mortality leaving another new and similar one behind—unlike the immortal in this, which is always the same and not another. And in this way, Socrates, the mortal body, or mortal anything, partakes of immortality; but the immortal in another way. Marvel not, then, at the love which all men have of their offspring, for that universal love and interest is for the sake of immortality." The germ of the idea is also recognizable in the speculations of Heraclitus, and possibly in those of Anaximander.



neurone metabolism through deprivation of nutriment, the action of toxic agents, and other pathological influences. But even in these abnormal states it is the constancy of the function which impresses us most; the fact that, given a nervous system made up of a certain set of neurones, the activities inherent in them must necessarily lead to the manifestations of certain definite functional characteristics, the alterations capable of occurring under changes of environment,\* internal and external, normal and pathological, being compressed within certain rather narrow limits, limits which grow more and more restricted apparently with the increase of the age of the individual.†

The astronomer, supplied with certain data concerning the speed and direction of a given planet controlled in its motion by the attraction of definite forces, can predict with precision the position it will occupy at a given moment in the future. The botanist, informed of the species to which a given vegetable organism belongs, can foretell with tolerable accuracy what its behavior will be under given conditions of soil and climate. Were it permissible to introduce here an opinion, I should not hesitate to say that I am convinced that the laws underlying neurone metabolism ‡ are just as fixed and constant as are those of astronomy and botany, and that I can conceive of a knowledge of their nature and action which would enable one possessed of it to prophesy unerringly of the functional manifestations of a nervous system made up of a given set of neurones which must result upon exposure to a given environment.

---

\* In this connection the articles of Driesch, Herbst, and Loeb upon the effect of environment upon development may be read with profit. External stimuli can and undoubtedly do exercise an important influence upon development, but the character of the response is determined by the inherited organization.

† If the conviction expressed in the text be well founded, then, broadly speaking, *as his neurones are, so the man is*. In this sense, Goethe's words, in the mouth of Mephistopheles, can be made to bear a new and almost prophetic significance:

"Du bist am Ende—was Du bist,  
Setz Dir Perrücken auf von Millionen Locken,  
Setz Deinen Fuss auf ellenhohe Soeken,  
Du bleibst doch immer, was Du bist."

‡ The same remark has already been made regarding sociology in *Social Rights and Duties*, by Leslie Stephen.

That the neurologist is almost infinitely distant from any approximation to such astronomical accuracy with regard to the nervous system it is needless to remark. That he may never attain to such omniscience is altogether probable. But the fact that he has already learned that in the nervous system certain causes are followed by certain definite effects almost with mathematical accuracy should encourage and stimulate him to further research with the hope that the intricate laws in question may gradually be rendered less obscure and vague.

## CHAPTER XX.

### ON THE DEGENERATION AND REGENERATION OF NEURONES.

Changes which occur in a part severed from the rest of the neurone—Wallerian degeneration—Türk's degeneration—Effect on the whole neurone of injury to one or more parts of it—Changes following amputations—Experiments of v. Gudden, Forel, and others—Application of method of Marchi to the study of the central stump of a divided nerve—Studies of Nissl on changes in the cell bodies of neurones after section of their axones—Effects of injuries to dendrites—Studies of Warrington and others—Effects of injuries to the cell bodies of the neurones—Changes in lumbar cord after ligation of abdominal aorta—Experimental production of secondary degenerations—Value of the method of Marchi and the method of Nissl for pathological studies—The neurone as a whole a trophic unit—Regeneration of nerve fibres and nerve cells.

As regards the trophic relations of the neurones, it may without further preamble be asked (1) How far is the nutrition of the individual portions of a neurone affected by an interruption of their connection with the rest of the neurone? (2) How far, if at all, does the whole neurone suffer as a result of injury to any one of these individual constituents? In attempting to reply to both these questions it will be found that we possess data to draw upon which regard not all, but certain only of the individual portions of the neurone. We shall find, too, that an answer to one question must from the nature of things include a reply to the other. That the formulation of the two questions as just adopted is not superfluous will readily be granted, in that the contemplation of the subject from the two different standpoints will help us materially in understanding the reciprocal relations which recent research has demonstrated to exist.

As long ago as 1839, Nasse \* and Valentin † had proved that

---

\* Nasse. Ueber die Veränderungen der Nervenfasern nach ihrer Durchschneidung. Arch. f. Anat., Physiol. u. wissensch. Med., Berl. (1839), S. 405.

† Valentin, G. De functionibus nervorum cerebraliū et nervi sympathici, libri quattuor. 4to. Bernæ, 1839.

interruption of the connection of peripheral nerves with the central nervous system could lead to their degeneration. Their

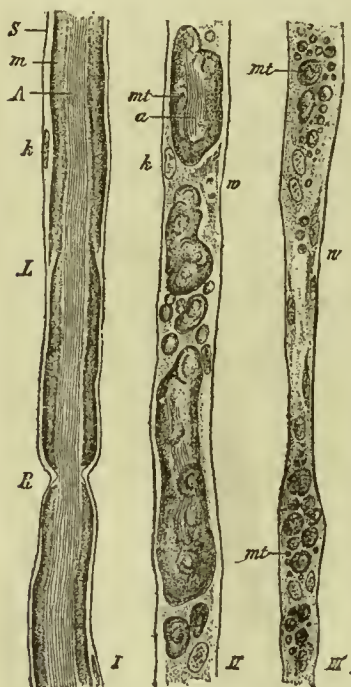


FIG. 143.—Wallerian degeneration of nerve fibres after section. *I*, normal nerve fibre; *II* and *III*, fibres showing different degrees of degeneration; *S*, neurilemma; *m*, medullary sheath; *A*, axone; *k*, nucleus of neurilemma cell; *L*, marking of Lanternmann; *E*, node of Ranvier; *mt*, drops of myelin; *a*, remains of axone; *w*, proliferating cells of neurilemma. Partly schematic. (After Thoma. *A Text-Book of Pathology and Pathological Anatomy*, vol. i, p. 505, Fig. 345.)

findings were confirmed by Stannius.\* Waller † made a thorough study of the subject and formulated the fundamental law of the physiology and pathology of the nervous system known by his name. By Wallerian degeneration we understand the changes which take place in the distal end of a peripheral nerve after it has been cut through. The details are familiar to every medical student, the coagulative breaking up of the myelin sheath, the dissolution of the axis cylinder, the neurilemma with its nuclei remaining for some time at least preserved (Fig. 143). Waller proved that if a motor nerve was severed there resulted complete degeneration of the fibres in the peripheral end, even to the muscles which they govern, the central end remaining apparently intact. As a matter of fact, the changes characteristic of Wallerian degeneration could not, as a rule, be traced farther in the central end than to the first node of Ranvier. If a sensory nerve is cut through peripheral

to a spinal ganglion there ensues complete degeneration of the sensory fibres as far as the sensory surfaces in which they

\* Stannius. Untersuchungen über Muskelreizbarkeit. *Arch. f. Anat., Physiol. u. wissensch. Med.*, Berl. (1847), S. 443–462.

† Waller, A. Experiments on the Section of the Glossopharyngeal and Hypoglossal Nerves of the Frog, and Observations of the Alterations produced thereby in the Structure of their Primitive Fibres. London, Edin-



begin.\* It was further shown by similar experiments that if the dorsal root of a spinal nerve was cut through at a point between the ganglion and the spinal cord, the portion of the nerve attached to the ganglion did not undergo the typical degeneration, while the portion still connected with the cord showed the characteristic degenerative phenomena, which could be traced throughout the whole course of its constituent fibres in the dorsal funiculi of the cord. The cells of the spinal ganglia have therefore been looked upon as trophic centres for the peripheral sensory nerves and their intramedullary continuations. This explanation was much simplified by the work of His, who demonstrated that the axone of the peripheral sensory fibre, the spinal ganglion cell, and the axone of the nerve fibre of the dorsal funiculus all represented parts of one and the same cell.

These degenerations in the domain of the peripheral nervous system were early shown to occur also within the confines of the central nervous system, the secondary descending degeneration of the pyramidal tract established by Türek † and the ascending secondary degeneration in the spinal cord after transverse lesion being quite analogous. We now know that the axis cylinders of the dorsal root fibres, with the exception of the few centrifugal fibres present in them, are axones of neurones whose cell bodies are situated within the spinal ganglia. We know that the axones of the motor peripheral nerves arise from the cell bodies of neurones situated within the ventral

---

burgh, and Dublin Philosophical Magazine, vol. xxxvii, No. 247, p. 65, July, 1850. Also in Philosophical Transactions of the Royal Society of London, 1850, p. 423, and in the Edinb. M. and S. J., vol. lxxvi (1851), pp. 369-376.—Sur la reproduction des nerfs et sur la structure et les fonctions des ganglions spinaux. Arch. f. Anat., Physiol. u. wissenseh. Med., Berl. (1852), S. 392-401; Compt. rend. hebdomadaire des séances de l'Acad. des sc., Par., t. xxxiv, p. 675.—Nouvelle méthode pour l'étude du système nerveux applicable à l'investigation de la distribution anatomique des cordons nerveux, et au diagnostic des maladies du système nerveux, pendant la vie et après la mort. Compt. rend. hebdomadaire des séances de l'Acad. des sc., Par., t. xxxiii, 1851, p. 606.—Expérience sur les sections des nerfs et les altérations. Compt. rend. Soc. de biol., Par., 2me s., t. iii (1857), pp. 6-8.

\* This appears to hold even for the sensory nerves connected with elaborate end organs, such as Meissner's corpuscles, although for a time these were thought to be exempt.

† Türek, Ludwig. Ueber secundäre Erkrankung einzelner Rückenmarksstränge und ihrer Fortsetzungen zum Gehirn. Ztschr. d. k.-k. Gesellsch. d. Aerzte zu Wien. (1852), ii, 511; 1853, ii, 289.

horns of the spinal cord, and that the axis cylinders of the fibres of the pyramidal tract are axones whose cells of origin are situated in the cerebral cortex. Converting, then, the Wallerian doctrine into terms of the neurone concept, the following general law may be laid down: Whenever it has suffered

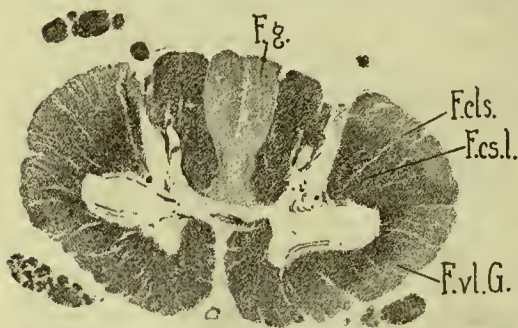

FIG. 144.—Section stained by Weigert's method through the cervical cord of a woman, showing secondary degenerations following compression of the cord at the level of the second thoracic segment. (After S. Rosenheim.) *F. g.*, fasciculus gracilis; *F. c.s.*, fasciculus cerebellospinalis (direct cerebellar tract); *F. c.s. l.*, fasciculus cerebellospinalis lateralis (lateral pyramidal tract); *F. v.l. G.*, fasciculus ventrolateralis Gowersi. Since the fibres in the fasciculus gracilis and many of those in the fasciculus cerebellospinalis and in Gowers's tract degenerate upward from the site of lesion, cells of origin of the degenerated fibres must be situated below the level of the second thoracic segment. The pyramidal tract is not degenerated; the cells which give origin to its axones are situated above the lesion. In the figure the degenerated areas are light, the normal areas dark.

a solution of continuity with a severing of its connection with the cell body and dendrites of the neurone to which it belongs, the axone, together with the myelin sheath covering it, undergoes in the part distal to the lesion acute and complete degeneration. This degeneration includes not only the main axone, but also its terminals, together with the collaterals and their terminals connected with it.\*

There has gradually developed, therefore, a general belief that what are called the "nerve cells" represent trophic centres for the nerve fibres in general.

The application of the Wallerian doctrine has aided immensely in unraveling the complicated relations existing inside the central nervous system. Thus, in a transverse lesion of the cord, for the bands of fibres which degenerate in sections above the site of the injury (Fig. 144), the "trophic centres" i. e., their cells (of origin) are to be sought below this level, and, *vice versa*, the cells of origin for tracts which degenerate in sections below the level of injury (Fig. 145) must be situated somewhere above this level.

\* Studies of degeneration of the spinal cord will convince any one of the accuracy of this statement regarding the collaterals.

Since the time of Waller and Türk the histology of the degeneration of nerve fibres after separation from their cells of origin has been studied by many—notably by Ranvier,\* Homén,† Howell and Huber, and Tooth.‡ The last, in the interesting Gulstonian Lectures for 1889, has reviewed succinctly the facts up to that date. The studies of von Notthaft\* are of especial value, in that they have yielded definite information concerning the state of the nerve fibres at various periods after the lesion. This investigator divides the changes which occur in a nerve after section into two stages. The first stage includes those which occur during the first three days. These alterations, which consist in fragmentation of the myelin and of the axone in the first one or two internodes on each side of the lesion, are, Notthaft believes, the direct result of the trauma. The true Wallerian degeneration (or the second stage) begins on the second or third day in the fibre distal to the lesion, and is the result of severance of connection with the central end, and not the direct result of the trauma. The axone swells and fragments, and the myelin breaks up into

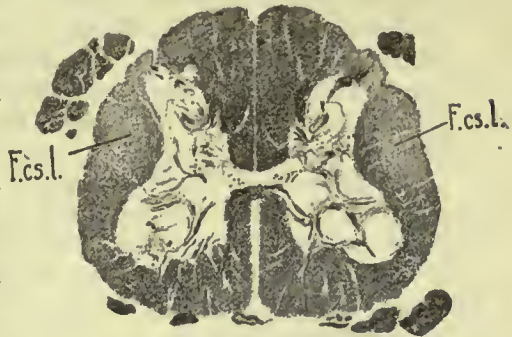

FIG. 145.—Section stained by Weigert's method through the lumbar cord of a woman, showing secondary degenerations following compression of the cord at the level of the second thoracic segment. (After S. Rosenheim.) Fasciculus cerebrosppinalis lateralis (*F. cs. l.*) is degenerated. The cells of origin of its axones are situated above the lesion (in the cerebral cortex).

\* Ranvier, L. *Leçons sur l'histologie du système nerveux*, Paris, 1878.

† Homén, E. A. *Experimenteller Beitrag zur Pathologie und pathologischen Anatomie des Rückenmarks* (speciell mit Hinsicht auf die secundäre Degeneration). *Fortschr. d. Med.*, Berl., Bd. iii (1885), S. 267-276; *Contribution expérimentale à la pathologie et à l'anatomie pathologique de la moelle épinière*. Helsingfors (1885), pp. 112, 7 pl., 8vo.

‡ Tooth, Howard H. *The Gulstonian Lectures on Secondary Degenerations of the Spinal Cord*. London, J. and A. Churchill (1889), pp. 1-71; also in *Brit. M. J.*, Lond. (1889), i, 753; 825; 873.

\* Notthaft, A. v. *Neue Untersuchungen über den Verlauf der Degenerations- und Regenerationsproeesse am verletzten peripheren Nerven*. *Ztschr. f. wissensch. Zool.*, Bd. lv (1893), S. 134-188.



droplets along the whole length of the nerve. Multiplication of the nuclei of the neurilemma is evident at the fourth day. At the sixth or seventh day liquefaction of the myelin commences, and this continues until the sixtieth or eightieth day, by which time all the myelin has been liquefied and a large part of it has been absorbed. After three or four months the myelin has entirely disappeared.

During the secondary degeneration of the white fibres within the central nervous system there is a proliferation of the neuroglia. The multiplication of the neuroglia cells begins in the white matter, according to Ceni,\* some forty-five or fifty days after the lesion. The neuroglia cells cease to multiply at about the hundredth day, after which there is a gradual disappearance of neuroglia nuclei with gradually progressing selective change.

Owing to the shortness of the dendrites (unless we look upon the peripheral sensory fibre as a dendrite), we possess no exact studies concerning their fate when severed from the cell bodies of the neurones to which they belong, but we have every reason to believe that they would undergo speedy and complete degeneration.

Viewing now the question from the other side, let us examine and see in how far the injury to one portion affects the nutrition of the whole of the rest of the neurone. The study of portions of the nervous systems from individuals who had died a certain length of time after amputation of an extremity soon afforded data which apparently stood in direct contradiction to the doctrine of the trophic centres as formulated by Waller. For, while Waller demonstrated the complete degeneration of the portion of the nerve fibre disconnected with the trophic centre, he maintained the integrity of that portion of the fibre left in connection with it. †

---

\*Ceni, C. Sur les fines altérations histologiques de la moelle épinière dans les dégénérescences secondaires ascendantes et descendantes. [Abstr.] Arch. ital. de biol., Turin, t. xxvi (1896-97), pp. 97-111; also in Arch. per le sc. med., xx, Torino (1896), pp. 131-194.

† This seemed to accord well with the well-known fact that some of the sensory nerves proximal to the lesion are capable of functioning for some time after amputation, producing sensations which often may give rise to no little mental disturbance and alarm on the part of the patient, since irritation occurring in the course of a sensory nerve fibre is attributed in consciousness to stimulation of the sensory surface from which it has been in



As early as 1829 Berard\* had noticed that in the spinal nerves supplying a limb amputated some time before, there was at autopsy distinct atrophy of the ventral roots. Vulpian, Cruveilhier, Haysen and Gilbert, Dickinson, Friedlaender and Krause, Homén, Vanlair, Grigorieff, and many other investigators busied themselves with the subject, and came to conclusions which were often at variance owing, as has been shown by Marinesco,† to the fact that the authors studied and described different phases of the alterations. Marinesco convinced himself that after amputation of a limb, or after section of a peripheral nerve, there occur in the central part definite pathological changes, the intensity of which depends upon the species, and especially upon the age of the animal and upon the length of time intervening between the injury and death. The younger the individual at the time of the amputation and the longer the time elapsing between the operation and death, the more marked are the alterations. The degeneration in the central stump of the divided nerve, although it appears much later than that in the distal portion, presents similar morphological appearances and is apparently an analogous process, although—and herein lies the vulnerable point of the Wallerian doctrine—the central end still maintains its continuity with the “trophie centre.” Not only do the sensory fibres distal from the spinal ganglia degenerate, but after a time large numbers of fibres in the dorsal roots proximal to the ganglia and their corresponding fibres with their collaterals and ter-

---

the habit of conducting impulses. The superstition referred to in the old play—

“Still in his dead hand clinched remain the strings  
That thrill his father's heart—e'en as the limb  
Lopped off and laid in grave, retains, they tell us,  
Strange commerce with the mutilated stump  
Whose nerves are twinging still in maimed existence”—

is not yet obsolete, as any one familiar with many of the rural districts of this country can testify. S. Weir Mitchell has given an interesting account of some of the sensations described as coming from the lost limbs in his monograph, *Injuries of Nerves, and their Consequences*, 8vo, Philadelphia, 1872.

\* Berard. Bull. Soc. anat. de Par., quatrième année, Bulletin No. 3, mai, 1829, deuxième édition (1846), p. 54.

† Marinesco, G. Ueber Veränderungen der Nerven und des Rückenmarks nach Amputationen; ein Beitrag zur Nerventrophik. Neurol. Centralbl., Leipz., Bd. xi (1892), S. 463; 505; 564.

minals in the dorsal funiculi of the cord undergo pathological changes and totally disappear. The motor fibres of the central stump gradually diminish in number; in some instances they appear to vanish almost totally, and a large number of the motor cells of the ventral horns dwindle in size (Fig. 146), and

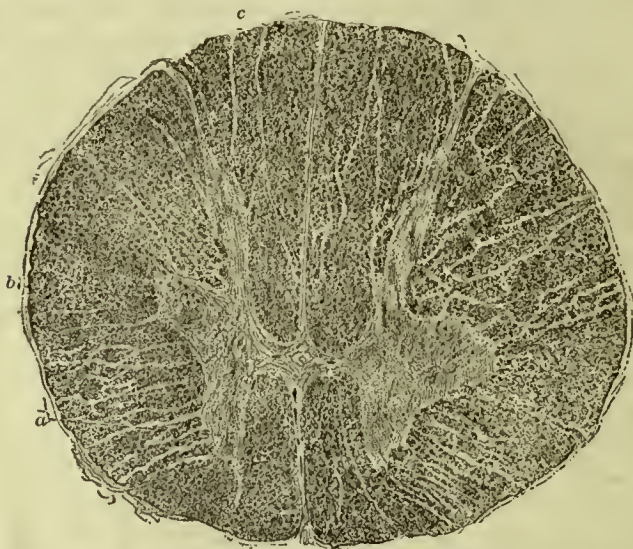


FIG. 146.—Section through human spinal cord in the upper thoracic region showing marked atrophy of right half of cord following amputation of right arm. (After G. Marinesco. *Neurol. Centralbl.*, Leipz., Bd. xi (1892), S. 506, Fig. 1.) The ventral horn is especially atrophied, as is also the fasciculus cuneatus in all its parts. The fasciculus gracilis (*c*) is intact. The atrophy of the cells in groups *a* and *b* is very evident.

may after a time be actually lost. The spinal ganglion cells do not show gross alterations for some time after both peripheral or distal fibres have degenerated (Friedländer and Krause, Homén, Vanlair, Marinesco), a finding which denotes that their trophic mechanisms differ in some way from those which are concerned in the nutrition of the cells of the ventral horns. I have thought that this may depend upon the possession by the spinal ganglion cells of a cellular capsule.\* It would be inter-

\* Another point to be remembered in explaining the difference in effect of division upon the peripheral motor and sensory nerves is the fact that, if current ideas of conduction are correct, on section of a motor fibre, it is perhaps the discharge of impulses which is prevented, while in the case of the sensory fibre it is at first the reception of impulses which is interfered with. It must not be forgotten, however, that even when a peripheral sensory

esting to note if the sympathetic ganglion cells, which are also encapsulated, act similarly and preserve their gross integrity after section of the nerve fibres belonging to them. I refer, of course, to gross integrity alone, inasmuch as there is much evidence, some of very recent date, from which we are compelled to believe that the finer structure of the nerve cell is always altered by the cutting through of its axone. According to the researches of Biedl (*vide infra*), cutting of a splanchnic nerve causes both cellulipetal and cellulifugal degeneration.

A series of investigations associated with the names of von Gudden,\* Forel, Mayser, Mendel, Bregman, Darkschewitsch, Nissl, and Flatau must now be considered. The first four investigators experimented by tearing spinal or cerebral nerves away from their connections with the central nervous system, especially in newborn or very young animals. These animals were allowed to live for several months, after which they were killed and the central portion of the nerve involved, together with the group of nerve cells corresponding to it, was studied microscopically. The histological examination revealed marked changes in the nucleus of origin. The cells present showed distinct atrophic alterations and many of them had entirely vanished, so that enumerations of the cells of the groups concerned revealed a decided discrepancy in the counts on the two sides. The nerve fibres in the central portion of the nerve had suffered degenerative changes, many of them having totally disappeared.

Bregman, in Vienna,† and Darkschewitsch,‡ in Koshewnikow's laboratory at Moscow, undertook the study of the central stump of motor nerves soon after the establishment of

---

nerve has been cut through, the corresponding cells in the spinal ganglia may yet perhaps receive some centripetal impulses from the viscera through the rami communicantes.

\* Gudden, B. von. *Gesammelte und hinterlassene Abhandlungen*. Herausgegeben von H. Grashey, Wiesbaden, 1889.

† Bregman, E. *Ueber experimentelle aufsteigende Degeneration motorischer und sensibler Hirnnerven*. Arb. a. d. Inst. f. Anat. und Physiol. des Centralnervensyst. a. d. Wien Univ., 1892, S. 73. Also in *Jahrb. f. Psychiat., Leipz., u. Wien*, Bd. xi (1892-'93), S. 73-97.

‡ Darkschewitsch, L. *Ueber die Veränderungen in dem centralen Abschnitt eines motorischen Nerven bei Verletzung des peripheren Abschnittes*. *Neurol. Centralbl., Leipz.*, Bd. xi (1892), S. 658-668.



the lesion, and were able to show by the delicate method of Marchi that extensive undoubted degenerative processes occurred in the fibres.\* In one case, in which the facial nerve

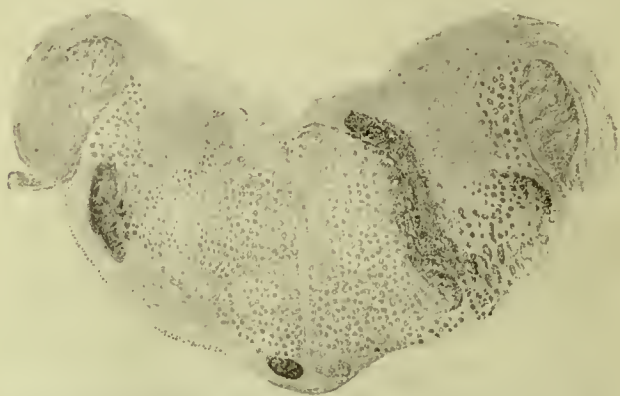


FIG. 147.—Transverse section through the medulla oblongata of a rabbit. The facial nerve of the right side was torn out of the Fallopiian canal and the animal killed fifty-eight days later. Thirty days before death both *nervi trigemini* were cut through incompletely intracranially according to Magendie's method. On the right side the corneal reflex was retained; on the left side it was absent and suppurative keratitis set in. The cerebral peduncle was also wounded on this side.

Treatment by Marchi's method. The nucleus and fibres of the right facial root completely degenerated; left facial nerve normal. From the raphe fibres go to both sides along the dorsal border of the *fasciculus longitudinalis medialis* and become lost beneath the bundle of facial fibres. These fibres—crossed facial root of the authors—remain normal. On the right side the dorsal part of the crescent-shaped cross section of the *tractus spinalis nervi trigemini* is degenerated; on the left side only the ventral part of the same. The left pyramid shows degenerated fibres. A few black masses are visible in the raphe, in the *fasciculus longitudinalis medialis* of both sides, in the left *nervus acusticus*, and in the *fibræ arcuatae externæ*. (After E. Bregman. *Arch. a. d. Inst. f. Anat. u. Physiol. des Centralnervensyst. a. d. Wien Univ.* (1892), Taf. vi, Fig. 1.)

had been operated upon, Bregman demonstrated complete degeneration of the fibres of the central stump at the twentieth day (Figs. 147 and 148).† Startling as were these re-

---

\* I am not sure but that these results come within the province of traumatic degeneration, in which event they would not contradict the Wallerian doctrine. Certainly, inside the spinal cord, pressure causes no such rapid degeneration in the proximal ends of injured fibres extending to their cells of origin.

† That there is no lack of interest at present upon this topic is shown by the fact that, at the meeting of the British Medical Association held in 1896, Fleming reported the results of his researches made in Munk's laboratory in Berlin. Cf. Fleming, R. A. *Ascending Degeneration in Peripheral Nerves and the Resulting Changes in Nerve Cells*. *Lancet*, London (1896), vol. ii,



sults in face of the fact that the trophic doctrine of Waller had held sway for forty years, they were eclipsed by others, which must now be considered. Nissl, with his methylene-blue-and-soap staining of alcohol tissues, found that he could actually demonstrate definite alterations within the nerve cells very soon after the solution of continuity of their axones. In rabbits, for example, after excision of a portion of the facial nerve on one side, characteristic alterations can be demonstrated, con-

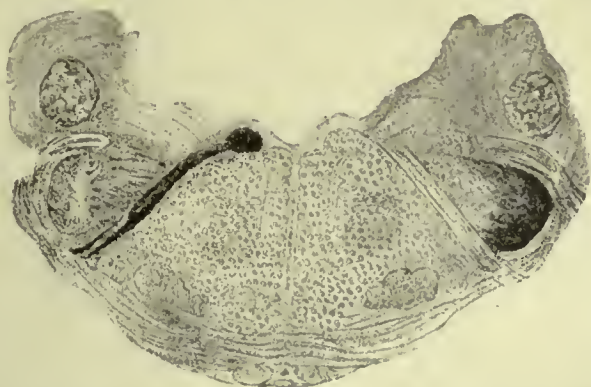

FIG. 148.—Cross section through the medulla oblongata of a rabbit corresponding to the distal part of the corpus trapezoidum. The facial nerve on the left side was torn out of the Fallopiian canal fifty-four days before the death of the animal. The nervus trigeminus on the right side was completely severed intracranially thirty-two days before the death of the animal. Treatment by Marchi's method. (After Bregman.) On the left side of the figure the root fibres of the facial nerve are completely degenerated. The right facial root contains a few black granules, but not more than one usually finds in the root bundles of the cranial nerves at their exit. The nervus abducens is normal on both sides. The so-called crossed facial root is normal on both sides. The tractus spinalis nervi trigemini is completely degenerated on the right side. In the neighboring substantia gelatinosa numerous bundles of degenerated fibres arranged in groups are visible. The dorsal portion of the tractus spinalis nervi trigemini runs out medially as a narrow stripe. In the corpus trapezoidum a few fibres are degenerated on both sides of the middle line. There are a few black granules in both acoustic nerves in both corpora restiformia, in the fasciculus longitudinalis medialis of both sides, and in the fibre arcuate externe.

sisting in the main of a rarefaction and finely granular change in the Nissl bodies of the cells of the seventh nucleus.\* He as-

No. 7, p. 508.—Some Notes on Ascending Degeneration (so-called) and on the Changes in Nerve Cells Consequent Thereon. *Brit. M. J.*, Lond. (1896), ii, pp. 918-921.—Ascending Degeneration in Mixed Nerves; a Critical Sketch with Experimental Results, *Edinb., M. J.* (1897), n. s., i, pp. 49-60.

\* "Darin, dass dieselben unter einer feinkörnigen Umwandlung rareficiren."

serts that while the changes are most marked if the animals are killed after from eight to fifteen days, to one acquainted with them alterations are recognizable within the cells of this nucleus as early as twenty-four hours after the operation. The findings, as might be expected, vary for the different forms of nerve cells and somewhat in the same form of cells in animals of different species. Even if the peripheral nerve is not cut through but is rendered temporarily incapable of functioning, the regressive alterations can be made to appear, as Nissl asserts he has shown, by the application of chemical substances (for example, common salt) to the trunk of the facial nerve, or by applying a temporary ligature to it. After these have reached a maximum (eighteen to twenty-two to thirty days) the appearances for a time do not alter materially, but Nissl thinks that later the majority of the cells, perhaps through the formation of other unions, begin slowly to recover, so that by the fiftieth or sixtieth day it may be difficult for the inexperienced to distinguish them from entirely healthy cells. Characteristic changes in the neuroglia accompany those found in the nerve cells. Of the importance of this method, which has been designated by Nissl as *Die Methode der primären Reizung*,\* I have already spoken in another place.† The method is a very delicate one—in fact, the most sensitive as yet introduced. Nissl cautions against drawing conclusions from its application before one has become skilled in the necessary technique. In order to obtain results of any value the operations must be done aseptically, and a long and intimate acquaintance with the appearances presented by the different varieties of cells occurring normally in the regions under examination is absolutely essential. The procedure has already been applied to determine a number of complicated relations existing within the nerve centres and is full of promise as regards the solution of many intricate questions, among which Nissl refers with especial hopefulness to those involved in the study of the eye-muscle nuclei.

---

\* Nissl, F. Ueber eine neue Untersuchungsmethode des Centralorgans speciell zur Feststellung der Localisation der Nervenzellen. Vortrag gehalten bei der Versammlung der sudwest. Neurologen und Irrenärzte in Baden-Baden, 3. Juni 1894. Centralbl. für Nerven- und Psychiat., Coblenz u. Leipz., Juli (1894), Bd. xvii, S. 337.

† Johns Hopkins Hospital Bulletin, vi (1895), p. 166.

Flatau,\* in Waldeyer's laboratory, examined the brains of four young cats, in which the third nerve had been cut intracranially by Gad, thirteen, eleven, three, and two days respectively after section. His description of the findings accords entirely with those of Nissl's investigations (Fig. 149). Held

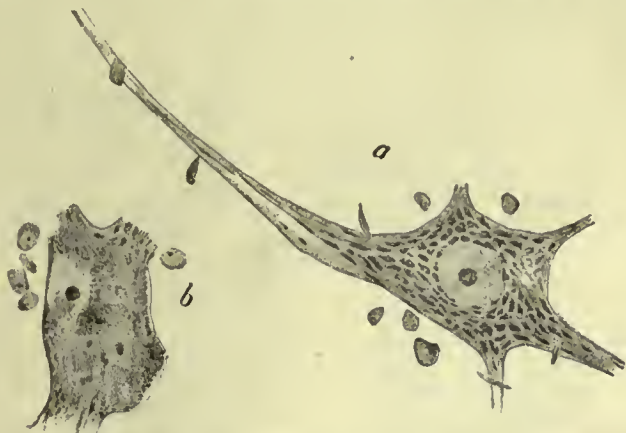


FIG. 149.—Cells from the nuclei of the oculomotorius nerves of the cat thirteen days after section of the root fibres of the nerve on one side. (After E. Flatau. *Fortschr. d. Med.*, Berl., Bd. xiv, 1896, Taf. i, Figs. 3 and 4.) *a*, cell from nucleus of side not operated upon, showing typical stichochrome arrangement of Nissl bodies; *b*, cell from nucleus of side operated upon. The homogeneous dustlike appearance is represented. Here and there single larger irregular Nissl bodies are visible. The nucleus is displaced to the side of the cell.

states that he has employed the method and found it to be useful, especially where the central relations are very complex. Sadovsky's researches † are also confirmatory of Nissl's studies. By both Nissl's method and Marchi's method Biedl ‡ has demonstrated that cellulipetal as well as cellulifugal degeneration occurs after section of the splanchnic nerve. Bernheimer \*

\* Flatau, E. Einige Betrachtungen über die Neuronenlehre im Anschluss an frühzeitige, experimentell erzeugte Veränderungen der Zellen des Oculomotoriuskerns. *Fortschr. d. Med.*, Berl., Bd. xiv (1896), No. 6, S. 201-225.

† Sadovsky, S. Névrite expérimentale par compression et lésions consécutives des centres nerveux. *Compt. rend. Soc. de biol., Par.* (1896), 10. s., t. iii, pp. 355-358.

‡ Biedl, A. Ueber die Centra der Splanchnici. *Wien. klin. Wehnschr.*, Bd. viii (1895), S. 915-919.

\* Bernheimer, S. Zur Kenntniss der Localisation im Kerngebiete des Oculomotorius. *Vorl. Mitth. Wien. klin. Wehnschr.*, ix (1896), No. 5. Also,

thinks he has been able by this method to decide as to the portions of the nucleus of the oculomotorius respectively concerned

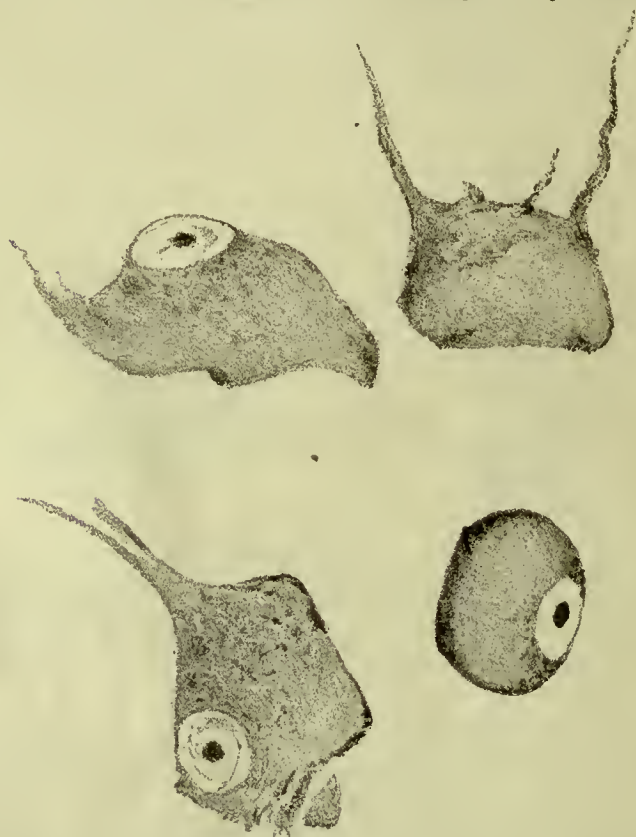


FIG. 150.—Four nerve cells from the nucleus nervi facialis of a rabbit fifteen days after section of the nerve root. Drawing made from one of J. Erlanger's preparations.

in the innervation of the extrinsic and intrinsic muscles of the eyeball. According to him, in the rabbit the four external eye muscles supplied by the oculomotorius nerve are governed by the ganglion cells of the distal and middle thirds of the nucleus (chiefly of the opposite side), while the cells of origin for the intrinsic muscles of the eyeball are to be sought in the most

---

Experimentelle Studien zur Kenntniss der Innervation der inneren und äusseren vom Oculomotorius versorgten Muskeln des Auges. Arch. f. Ophth., Leipz. (1897), Bd. lxiii, 3. Abth., S. 481-525.



proximal portions of the nucleus. J. Erlanger is at present engaged with me in the study of the spinal cords of animals from which pieces of nerves supplying muscles, and in some instances the muscles themselves, have been excised; the results of these investigations will be published later. In Fig. 150 are shown some cells from the *nucleus nervi facialis* fifteen days after section of the facial nerve. They may be compared with *a* of Fig. 149, which represents a normal motor cell.

As to the effects upon the cell body induced by injury to a portion of the terminals of the collaterals of a given axone, we have as yet no evidence.

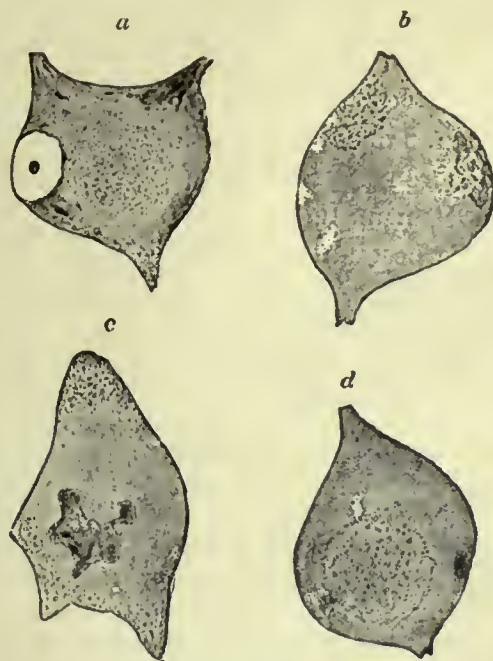


FIG. 151.—Ventral horn cells from the spinal cord of a case of multiple neuritis. (After Ballet and Dutil.) *a, b*, cells stained with picrocarmin; *c*, cell stained with hæmatoxylin; *d*, cell stained by Nissl's method. The alterations in the chromatic substance and the dislocation of the nucleus are well shown.

Experiments such as the foregoing place certain diseases—for example, the so-called peripheral neuritis—before us in an entirely new light, for it is obvious that even if the morbid process be confined at first exclusively to distal portions of the axones (the lesion, when of the nature of a focal necrosis, is

usually dependent upon poisons circulating in the blood), it does not remain localized in them, and, as we have seen, injury to an axone leads to alterations in the whole of the neurone to which it belongs. Ballet and Dutil\* have already described such changes in the cells of the ventral horns in cases of polyneuritis (Fig. 151). Many additional examples of the bearing of these experiments upon pathology might be given. From what has been said it is obvious that we must be very chary of

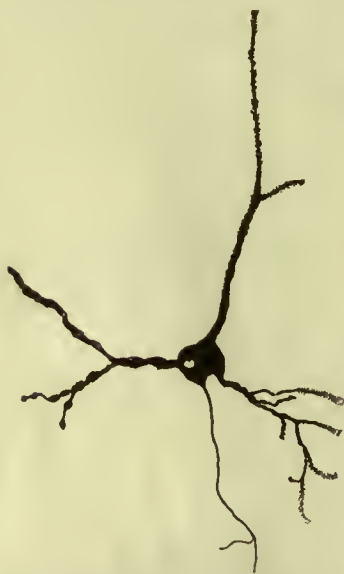

FIG. 152.—Nerve cell from cerebral cortex of dog. It shows alterations chiefly in the dendrites turned toward a thrombosed vessel. (After Monti. *Arch. ital. de biol.*, t. xxiv.)

denying the existence of alterations in the cell bodies of the neurones in a given disease, unless these have remained undiscovered with the most delicate methods now at our command. There can be but little doubt that in many cases in which the nerve cells have been described in the bibliography as being perfectly normal, very distinct pathological changes could have been demonstrated in them had Nissl's method been used for their detection. On the other hand, it must be borne in mind that in the very delicacy of these methods there lies the great danger that with them the inexperienced may easily be led to describe pathological findings where, in reality, none exist. I must confess that I am very

skeptical of accepting as facts the statements in any publication of work based on Nissl's methods where I am not sure that the results have been controlled by an investigator of experience.

Unfortunately, tissues fixed for staining by Nissl's method in alcohol or corrosive-sublimate solutions are not suitable for staining by the method of Weigert or by that of Marchi.

---

\* Ballet, G., et A. Dutil. Sur un cas de polynéurite avec lésions médullaires. *Bull. et mém. Soc. méd. d. hôp. de Par.*, 3 s., t. xii (1895), pp. 818-821.

Marina\* has tried to obviate this difficulty. His fixing mixture (formol and chromic acid) permits of staining of the tissues by the methods of Weigert, Nissl, and Van Gieson. The Nissl preparations are not, however, so beautiful as those prepared in the orthodox way.

As regards the effects on the whole neurone resulting from injury to its dendrites we have much less definite information. Leaving out of consideration injuries to peripheral sensory nerve fibres, which, as we have seen, correspond in their embryological origin to dendrites, and which, as I shall point out a little later, though conforming in their physiological behavior, at least so far as the conduction of nerve impulses is concerned, rather to what is

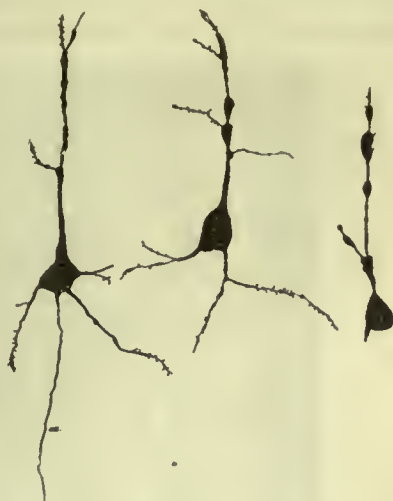


FIG. 153.—Larger pyramidal cells from the second layer of the cerebral cortex showing advanced stages of degeneration following ricin poisoning of fourteen hours' duration. The cells have lost the angularity of their contours. (After H. J. Berkley. Johns Hopkins Hosp. Rep., vol. vi, Pl. xii.)

generally true of dendrites than of axones, are nevertheless histologically indisputably axones, we have as data in this connection only the observations of Monti† and Berkley.‡ These observers, employing the silver method of Golgi, the former in cases of inanition and experimental cerebral embolism (Fig. 152), the latter in several varieties of intoxication (Fig. 153) and in

\* Marina, A. Eine Fixationsmethode, bei welcher sowohl die Nissl'sche Nervenzelle als die Weigert'sche Markscheidefärbung gelingt. *Neurolog. Centralbl.*, Leipz., Bd. xvi (1897), S. 166.

† An epitome of the work of Italian investigators with Golgi's method with regard to pathological alterations in nerve cells is to be found in the comprehensive review of C. Sacerdotti, in Lubarsch-Ostertag's *Ergebnisse der allgem. Pathologie u. path. Anat. des Menschen u. der Thiere*. Zweiter Jahrgang, 1895. Wiesbaden (1897), S. 799-806.

‡ Berkley, H. J. Studies on the Lesions produced by the Action of Certain Poisons on the Cortical Nerve Cell. *Johns Hopkins Hosp. Rep.*, Balt., vol. vi (1897), fasc. i, pp. 1-88.

terminal dementia (Fig. 154), have found that under certain circumstances the earliest lesions which appeared were those affecting the dendrites. These showed varicosities and distortion phenomena with loss of the gemmules and finer side branches;



FIG. 154.—Strong apical dendrites of pyramidal cells from the human cerebral cortex. *a*, normal dendrite; *b*, dendrite from a pyramidal cell in a case of terminal dementia; the gemmules have disappeared and the irregular calibre is well shown. (After H. J. Berkley.)

only subsequently did the cell body and axone show alterations. An effort has been made to attribute the changes in such cases in the axone and cell body to the disturbances in metabolism resulting from the loss of the dendrites. It would seem to me possible that the alterations in external form in a cell body and axone discovered by the method of Golgi may be due to the same causes as the preceding changes in the form of the dendrites and not simply be their metabolic sequel.

The researches of Warrington (*vide infra*) and others have



shown that if the impulses coming to a cell by way of the dendrites and cell body be cut off, changes in the whole neurone result. It would not be difficult to believe then that if the dendrites undergo serious injury of any sort marked alterations of the neurone must result, if for no other reason than the cutting off of centripetal impulses. Held's studies of the conerescence-relations between the terminals of axones and collaterals of one neurone and the dendrites and cell bodies of another are, it seems to me, well worthy of note by the pathologist. When one remembers that these delicate interneuronal communications are directly exposed to the lymph which bathes them, the possible deleterious effects of soluble poisonings circulating in the blood and lymph are not difficult to imagine.

That the cell body is of very great importance in the nutrition of the neurone is evidenced by (1) the existence in it of the nucleus with its surrounding endoplasm, and (2) its very intimate relations to the capillary plexuses within the gray matter (Fig. 155).\*

Besides, the effect of severe injury to the ganglion cell upon the rest of the neurone is now very generally appreciated. It has long been known that destruction of a ganglion cell leads inevitably to the decay and disappearance of the nerve fibre connected with it. A few interesting experiments may perhaps be recalled. Ehrlich and Brieger showed in 1884 that if a ligature be applied for thirty minutes or an hour close beneath the point of origin of the renal arteries of the rabbit, there results a permanent sensory and motor paralysis of the posterior extremities and of the bladder and rectum, owing to acute necrosis of the cells of the gray matter of the lumbar spinal cord. These experiments, repeated later by Herter, Spronek, Münzer and Wiener, and others, are invariably followed by complete degeneration of the whole of the neurones of which the necrotic cell bodies form a part, and the course of the degenerating fibres can after a few days be profitably studied by the method of Marchi. The removal of the nerve cell (either through chemical injury, cutting off of nutrition, or ablation) is, for the part remaining, equivalent to severing the axone, and the typical secondary degeneration always occurs.

---

\* Shimamura, S. Ueber die Blutversorgung der Pons- und Hirnscheukelgegend, insbesondere des Oculomotoriuskerns. *Neurol. Centralbl.*, Leipz. (1894), Bd. xiii, S. 685; 769.

This brings us to the utilization of experimentally produced secondary degenerations, by means of which important contributions have been and are being made to the anatomy of the central nervous system. No matter what nerve cell or group of nerve cells is destroyed, whether in the spinal cord, in the medulla, in the thalamus, or in the cerebral cortex, whether belonging to the projection systems or to the association sys-

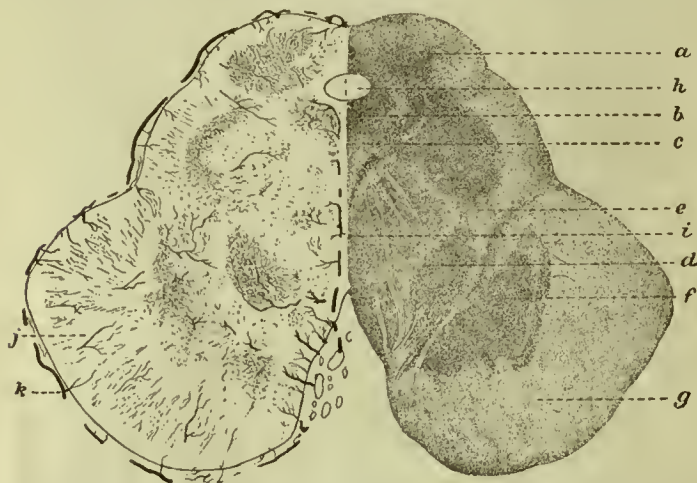

FIG. 155.—Frontal section through the mesencephalon showing vascular supply. (After S. Shimamura. *Neurol. Centralbl. Leipz.*, Bd. xiii (1894), S. 775, Fig. 4.) *a*, nucleus corporis quadrati; *b*, regio nuclei nervi oculomotorii; *c*, fasciculus longitudinalis medialis; *d*, lemniscus; *e*, substantia nigra; *f*, basis pedunculi; *g*, aqueductus cerebri; *i*, vessel running along near raphe; *j*, lateral blood-vessels; *k*, blood-vessel running along the basis pedunculi. The rich capillary supply to the groups of nerve cells is particularly well shown.

tems, the corresponding axone or axones, with their enveloping myelin sheaths, degenerate completely to their terminals. The method of Marchi permits us to make out the changes long before they assume the degree necessary for their recognition by Weigert's method. Indeed, nowadays practically every neurological investigator employs this procedure, so valuable is the information afforded by it.

This method, when employed in connection with that of Nissl, is of extreme value, not only for anatomy, but also for pathology, for it must now be evident that once we have demonstrated degeneration in a given set of nerve fibres we can prophesy almost with certainty the existence of lesions of some

sort in their cells of origin—lesions which, however, may obviously, from what has been said above, be, in a given case, either primary or secondary. The statement of this fact would seem to be all the more important in that it has been suggested by some investigators that apparently trivial injuries to neurones, so slight in the cell body as to exclude detection by all the cruder methods, may nevertheless in all probability suffice to give rise to easily demonstrable degenerative lesions in other parts of the neurones. Perhaps the most significant instance which can be cited is that met with in some forms of lateral sclerosis in human beings in which the pyramidal motor cells of the cortex show no marked lesions, though the most distal portions of the nerve fibres arising from them have gradually degenerated. While it is not impossible that here, as seems probable in some forms of disease of the peripheral nerves (alcoholic neuritis, lead-poisoning, etc.), the degeneration of the distal portion of the axones may be due to the direct action upon them of some toxine, the view is gradually gaining ground that in these cases we have to deal with some deleterious influence acting upon the cell body, or perhaps upon the whole neurone, which expresses itself in a manner accessible to recognition by our methods first in those portions of the neurones in which the nutritive influences are least active, presumably those most distal from the cell body and nucleus (Strümpell). Wollenberg's idea regarding the primary seat of the disease of the sensory neurones in tabes would involve a similar explanation, but many have objected to the assumption that in this disease the primary lesion is in the cell bodies of the spinal ganglia.

Inasmuch as in tabes we have not, as after section of a dorsal nerve root, a complete degeneration following the continuation of the fibres within the spinal cord, but rather an elective degeneration of the dorsal funiculi, certain only of the intramedullary continuations of the dorsal roots being involved in the disease process, at least in the early stages, it seems to me that one of two views has to be accepted for the explanation of its origin. Either this is to be sought in a slow intoxication of the cord, the toxine being one that influences deleteriously the sensory regions of the cord and by preference only certain parts of these, the individual bundles which succumb varying to a certain extent in different cases of the disease, or the toxic process is exerted in an elective way in the spinal gan-

glia, or possibly on the whole of the peripheral sensory neurone, certain only of the peripheral sensory neurones being affected, at least at first, and accordingly certain only of the fibres of the dorsal funiculi inside the cord. The former view has been supported by Erb, Strümpell, Möbius and others. A result of poisoning somewhat similar to that assumed in this doctrine of the origin of tabes has been observed in certain other intoxications. Further, nothing can be more obvious than that certain groups of neurones in a given individual are more susceptible than others to a given toxic agent; more than this, the same group of nerve cells in two individuals may react very differently to similar doses of the same poison. Our daily experience with the effects of alcohol, coffee, tea, and certain anaesthetics upon different individuals and upon ourselves under different circumstances are of interest in this connection. The toxins of syphilis, although we are entirely ignorant as to their nature, show a decided preference for certain parts of the cerebral cortex, other areas being less often affected. Hampe's observations concerning the differences in the psychic disturbances following carbon-bisulphide poisoning in different individuals are very convincing in this regard, as are also the careful psycho-pharmacological investigations of Hoch and Kraepelin\* concerning the caffeine and ethereal oils in samples of tea. It is Flechsig's idea that these variations in vulnerability of different groups of neurones, and of the different portions of the individual neurones, are to be traced back in large part to developmental conditions, a suggestion which is highly plausible in view of the evidence that can be brought forward in its favor.

The answers to the questions which we have formulated concerning the events occurring in the various component parts when cut off from the main body of the neurone, and the effects of lesions of individual portions of the neurone upon the neurone as a whole, are, of necessity, as yet very incomplete. Sufficient evidence, however, is at hand to render clear the fact that the neurone *as a whole* is a trophic unit, and that any attempt to locate the trophic function exclusively in any one portion of it must assuredly fail. We have seen that we possess reliable observations which all favor the view that injury to any part of it also affects to a greater or less extent the remainder of the neurone, and that no portion of a neurone is capable of existence for any great length of time after the severance of its

---

\* Hoch, A., u. E. Kraepelin. Ueber die Wirkung der Theebestandtheile auf körperliche und geistige Arbeit. Kraepelin's Psycholog. Arbeiten, Bd. i (1895), H. 2-3, S. 378-488.



connection with the rest of the nerve unit. And after all, when one thinks of it, this is not so very astonishing; indeed, it is rather a matter of surprise that the fact should have been questioned, after the knowledge had once been gained that a neurone as a whole represents a single cell, for we have long known that even in such presumably little differentiated protoplasm as that possessed by an amœba, an injury (for example, with silver nitrate) to one portion of the cell body is speedily answered by phenomena which concern the whole of the unicellular organism. How little likely that a nerve cell, the protoplasm of which represents the highest example of differentiation along the lines of irritability with which we are acquainted, should remain uninfluenced by irritation or destruction of one of its integral parts!

Many facts might be added in connection with regeneration of nerve fibres and nerve cells which have more or less bearing upon the trophic functions of the neurones. On the regeneration of nerve fibres an immense amount of work has been done,\* some very important contributions having been made by investigators in this country, especially by Howell and Huber.† It has long been known that on suitable apposition of the ends of a divided motor or sensory nerve, the axones of a central stump may grow out again to the periphery and function may again return. In the event of the re-establishment of connection and function, the regressive alterations which begin to appear in the central portions of the neurone almost immediately after section (Nissl) gradually give place again to the normal appearances. The investigations of Baer, Dawson, and Marshall, carried on under the direction of W. H. Howell (1897), speak in favor of the regeneration of the central axones of peripheral sensory neurones in the dorsal funiculi of the cord after experi-

---

\* Compare the excellent review and critique of the bibliography up to 1895 by H. Stroebe. *Die allgemeine Histologie der degenerativen und regenerativen Prozesse im centralen und peripheren Nervensystem nach den neuesten Forschungen. Zusammenfassendes Referat.* Centralbl. f. allg. Path. u. path. Anat., Jena, Bd. vi (1895), S. 849-960.

† Howell, W. H., and Huber, G. C. *A Physiological, Histological, and Clinical Study of the Degeneration and Regeneration in Peripheral Nerve Fibres after Severance of their Connections with the Nerve Centres.* J. Physiol., Cambridge, vol. xiii (1892), pp. 335-406, and vol. xiv (1893), p. 1; also Huber, G. C. *A Study of the Operative Treatment for Loss of Nerve Substance in Peripheral Nerves.* J. Morphol., Bost., vol. xi (1895), pp. 629-740.

mental lesion of a dorsal root between the ganglion spinale and the spinal cord.\*

Regeneration of severed nerve fibres within the spinal cord and brain is, unfortunately, very much less complete than in peripheral regions. Whether a nerve cell once entirely destroyed can have its place adequately filled by one formed by division from another nerve cell is a question of vital interest. The researches of Tigges, Mondino, Coën, Cattani, and Popoff are of importance in this connection. The newspapers have recently contained the most exaggerated and ludicrous accounts of the significance of the experiments of Vitzou.† According to his researches, there may be an actual new formation of nerve cells in the brain, and it is his opinion that the restitution of function after ablation experiments is to be attributed, not, as Luciani and Tamburini think, to the existence of secondary centres which take on the function vicariously, but directly to the newly formed nerve tissue. This view is not shared by Tedeschi,‡ of Pisa, although this investigator also asserts that he has demonstrated the possibility of a regeneration of the nerve cells (Fig. 156). It is highly desirable that these studies be repeated and extended, especially as the recent researches of Tirelli § on the spinal ganglia, and of Monti and Fieschi || on the sympathetic ganglia, go to support the prevalent view that in adult animals ganglion cells once destroyed are not regenerated. That there can be remarkable regeneration in embryonic stages,

---

\* Baer, W. S., Dawson, P. M., and H. T. Marshall. Regeneration of the Dorsal Root Fibres of the Second Cervical Nerve within the Spinal Cord. *J. Exper. Med., Balt.*, vol. iii (1899), No. 1.

† Vitzou, A. N. La néoformation des cellules nerveuses dans le cerveau du singe consécutive à l'ablation complète des lobes occipitaux. *Compt. rend. Soc. biol.*, September 16, 1895; also in *Compt. rend. Acad. d. sci., Par.* (1895), exxi, 445-447; and in *Arch. de physiol. norm. et path.*, Par. (1897), 5 s., t. ix, pp. 29-43, 1 pl.

‡ Tedeschi, A. Anatomisch-pathologische und experimentelle Untersuchungen über die Regeneration des Nervengewebes. *Vorl. Mitth. Centralbl. f. allg. Path. u. path. Anat.*, Jena, Bd. vii (1896), S. 449-451; also *Anatomisch-experimenteller Beitrag zum Studien der Regeneration des Gewebe des Centralnervensystems. Beitr. z. path. Anat. u. z. allg. Path.*, Jena, 1897, xxi, 43-72, 3 pl.

§ Tirelli, V. Dei processi riparativi nel ganglio intervertebrale. *Ann. di freniatr. e se. affini*, Torino, vol. v (1895), pp. 9-26; also *Transl. in Arch. ital. de biol.*, Turin, t. xxiii (1895-'96), pp. 301-316.

|| Monti, A., et Fieschi, D. Sur la guérison des blessures des ganglions sympathique. *Arch. ital. de biol.*, Turin, t. xxiv (1895-'96), pp. 401-413.

however, is fully established; witness the experiments of Roux, Loeb, and others. Flexner has recently studied with care the

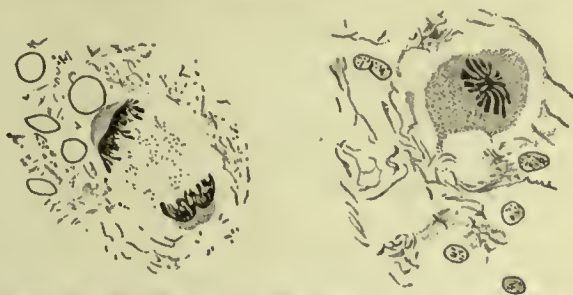


FIG. 156.—Caryocinetic figures in nerve cells in brain of dog three days after introduction of foreign body. (After Tedeschi.) Fixation in Flemming's mixture, saffranin staining.

process of regeneration in planarians with especial reference to the histological side.\*

Of these phenomena of regeneration it may be said briefly that they emphasize most strikingly the cellular nature of the neurones, and accord in nearly every particular with what *a priori* might have been expected.

I have purposely laid particular stress upon the unity which characterizes the trophic functions of the neurone, because the Wallerian doctrine of trophic centres has been so ingrained in our minds that it is difficult to disabuse them of the erroneous portions of it. In making this point, however, there has been no intention of giving the impression that all portions of the neurone are of equal value from the standpoint of nutrition. Such an idea would probably involve a fallacy even greater than the one from which we are being emancipated. Exactly the part played by the dendrites, by the cell body, and by the axone in the nutritive processes it is as yet impossible to say; but that each has an important function is certain, and that the rôle of the non-medullated portions of the neurone is somewhat different from that of the medullated seems very likely.

We have now to turn our attention for a short while to the phenomena of irritability as manifested by the neurones, and shall return later to consider the relations of the trophic functions to the nervous functions proper.

\* Flexner, S. The Regeneration of the Nervous System of *Planaria torva* and the Anatomy of the Nervous System of Double-Headed Forms. J. Morphol., Bost., vol. xiv (1897-'98), pp. 337-346.

## CHAPTER XXI.

### THE IRRITABILITY OF THE NEURONES.

The phenomena of irritability of the neurones—Applicability of the law of the conservation of energy in the domain of animal life—The problems to be solved—Unremitting character of the activity of the neurones—The majority of the nervous processes unconscious—Significance of the so-called “subconscious” and “infraconscious” centripetal and centrifugal impulses—Question of spontaneity of neurone activity—On the transference of an excitation from one neurone to another—The “neurone-threshold”—Importance of proper adjustment of stimuli—Edinger's theory of tabes—The specific energies of nerves.

THE physiologist of the present day sees in the functions of the nervous system, even in those which are most complicated, only certain manifestations of energy. Moreover, he believes that in neurones, as in all other cells of the body, and as in the world generally, the law of the conservation of energy during transformation holds, and consequently regards the phenomena of irritability, as exhibited by a neurone or by groups of neurones, as the kinetic representative of the potential forces of the cells and their food stuffs. The metabolic activities and the vital manifestations of the cell are concomitant processes—another example of the inseparable connection which exists between what we term matter and energy. There has been in many quarters a certain amount of hesitancy in accepting the view that the capacities of the nervous system, particularly those of the brain, are dependent directly upon the chemical and physical alterations which are continually going on within its constituents—a hesitancy which, though it has in the past proved a serious obstacle to progress, is happily now fast disappearing. For the plant, all the evidence goes to prove that under the influence of sunlight and heat marked chemical and physical changes take place within it which we recognize in its vital processes. In the animal, be it granivorous, carnivorous, or, like man, omnivorous, it is the chemical energy introduced as



food which represents in the main the source of the energy of the organism. The recent accurate calorimetric studies of Rubner\* are of much interest in this connection, and demonstrate in a most convincing way the applicability of the law of the conservation of energy in the domain of animal life. While, however, our present knowledge suffices to permit the recognition in groups of living cells of these broad general laws, which were formerly thought by many to be applicable only to inanimate nature, it must be admitted that in no single instance are the details of the transformations of energy known to us in any degree of completeness. We have not as yet discovered very much that is definite concerning the storing up of energy inside the individual neurones, and our information relating to the discharges of energy in these structures is even more scanty.

The physiologists have been struggling for fifty years or more to gain an insight into the nature of what they call nerve impulses, by which is to be understood the occurrences inside axones—for example, at the time when we have good reason to believe that they are functionally extraordinarily active. Their efforts have supplied us with a multitude of data, physical and chemical, interesting enough, no doubt, but which can serve as only the barest prolegomena to an explanation of the essence of the occurrences. If we are so badly informed concerning these elementary and fundamental phenomena we may very well be content to be modest for some time to come in our claims as regards a physiological psychology. It is by no means impossible that in the nervous system forms of energy are concerned which do not exist outside the animal body and which yet remain to be recognized and studied.

It would be easy enough to outline rapidly the most salient points with which we need to be better acquainted. The differences in neurones in different species of animals, the influence of heredity upon the structure of the neurones, the automatic activities in these cells, if indeed they have any which are absolutely automatic, the changes in neurones resulting from chemical and physical alterations in their environment, their powers of adaptation, and many other questions present

---

\* Rubner, M. Die Quelle der thierischen Wärme. Ztschr. f. Biol., Münch. u. Leipz., Bd. xxx (1894), S. 73-142.

themselves, the solution of any one of which would bring about a great advance in our knowledge. Truly, to find out the properties of a single neurone would be a task appalling enough, but when we remember that of the millions of neurones in one individual perhaps no two are just alike, the quest would seem hopeless. But instead of burying ourselves in pessimistic reflections, or being discouraged by what is at present unattainable, by what may perhaps forever remain to us unknowable, we may profitably turn to the consideration of some of the points which lie more within our ken.

One point, self-evident enough when one's attention is directed to it, but which often appears to have been overlooked in connection with the neurones, is the unremitting character of their activity. With a metabolism so complicated as that occurring within the nerve units it is inconceivable that there can be any period in which alterations in chemical structure, and consequently energy transformation, are not going on. From moment to moment, throughout all the hours of the day and night, analytic and synthetic processes are taking place, associated with the alterations in physical forces which necessarily accompany these changes. In common with everything that lives, the neurones know no absolute repose. As I have said, in speaking of their metabolism, periods of extravagant activity may alternate with periods of more economic change, but total rest is inconsonant with continuance of existence. We are forced to believe that what we ordinarily speak of as the passage of a nerve impulse represents, as it were, a stormy process in the nerve fibre, and that just as absence of a storm does not mean absence of weather, there are in all probability minor alterations, currents if you will, passing to or fro or to and fro in a given nerve fibre in the intervals between the more violent excitations. With increasing knowledge the importance of centripetal impulses which fall below the threshold of consciousness and of centrifugal impulses insufficient to call forth visible muscular contractions is becoming more and more evident. In a healthy individual perhaps the majority of the impulses passing from the periphery into the nerve centres have no share in the composition of the mental pictures, but these subconscious stimulations are doubtless of decisive significance for the nutrition of the elements concerned and for the processes of subconscious co-ordination. Similarly, the myriads

of impulses passing to the muscles without producing marked contractions in them must of necessity have to do not only with the proper metabolism of the motor neurones, but also with the nutritive processes in the muscles themselves. Indeed, there is much evidence to show that the nutrition of the muscles can be kept up very well in the absence of active muscular contractions so long as these less violent impulses pass regularly to them, but as soon as the latter are cut off the muscles speedily undergo atrophy. This fact is often extremely well illustrated in cases of hysterical patients, where, as is well known, there may be inactivity of certain muscles for very long periods without any very marked atrophy. By means of very delicate graphic methods it can be shown that the muscles in such patients are innervated when corresponding movements are thought of, just as in a healthy individual the hearing of the word "tower" is often associated with nerve impulses to the eye muscles, which tend to make the individual look up. The different tracings yielded by the automatograph during various psychic processes may be mentioned as interesting in this connection. The importance of the continuous passage of impulses along the sensory nerves for the carrying out of all complicated movements of the muscles, long emphasized by the observations upon tabes and also upon cases in which there have been lesions of the trigeminus, has been made even more strikingly evident by Mott, Sherrington, and others who experimented upon monkeys in whom the dorsal roots of certain of the spinal nerves had been cut. In such animals, although practically all the motor neurones (except the few possible motor axones of the dorsal roots) are intact, and the memory traces of previous movements must be believed to still exist, movements of the limbs innervated by the corresponding segments of the spinal cord, those which are complicated as well as many which are quite simple, are only very inaccurately carried out. The continuity of the nerve excitations can therefore scarcely be insisted upon too forcibly, and I am inclined to agree fully with Goldscheider when he says, "Es herrscht eine zeitliche Continuität von Erregungen in allen Bahnen des Nervensystems." As Donaldson,\* writing in this connection, beautifully puts it: "In this picturing the entire

---

\* *Op. cit.*, p. 284.

nervous system as a sensitive mechanism, it is evident that it must respond to the surrounding stimuli as does the water of a lake to the breeze; and such is the relation between the central system and its environment that the breeze is always blowing and the waves of change always chasing one another among the responsive elements. If there are no waves, then the cells are dead. The breeze still blows, but it falls on a frozen surface, on cells chilled and rigid beyond the power of response."

The influence of the arrival or non-arrival of external stimuli to the neurones upon their trophic and nervous functions will be referred to a little later. If among external stimuli we class not simply those outside the body, in which event a very minute fraction of the whole number of neurones would be directly accessible to external stimuli, but all those external to a given neurone, including those arriving through the lymph which bathes it, or by means of the processes of other neurones which enter into relations of conduction with it, we shall come to the conclusion that the limits of genuine spontaneity of action on the part of neurones are very narrow; indeed, some authors would deny its existence altogether. Von Lenhossék, for example, says: "Man darf den Satz wohl als gesichert betrachten, dass es keine Nervenzelle giebt, die ihre Nervenzirkulation aus sich selbst heraus, ohne äussere Impulse, spontan entfalten konnte." The reflex actions are very obviously dependent upon external influences, as are also the instinctive reactions, and what we call volitional movements are, when analyzed, apparently only reactions to external influences modified by memories. We must not lose sight of the fact, however, that there may be periods of considerable length intervening between the arrival of the external influence and the discharge of energy which it determines or helps to determine, just as we know that the springs of conduct often lie far removed from immediate acts. And it is just here that the laws bearing upon the summation of stimuli\* assume an especial interest, although they must be passed by now without discussion.

---

\* Cf. Du Bois-Reymond. Ueber die Auslösung von Reflexbewegungen durch eine Summe schwacher Reize, 1880; also the review of this subject by S. Exner. Entwurf zu einer physiologischen Erklärung der psychischen Erscheinungen I Theil, Leipz. u. Wien, 8vo (1894), Cap. ii, S. 49.



Of the physiology of the transference of an excitation from one neurone to another, a word may be in place. All our knowledge of sensation goes to indicate that a certain minimal amount of stimulation is necessary to call forth a reaction; for example, to stimulate a pressure point in the skin a certain amount of pressure, say from a hair, is required to elicit the sensation of touch. Any pressure less in amount will not suffice. That is to say, the touch point has a "threshold value."\* In the same way there are threshold values for the various cold points,† warm points, and pain points, and in connection with the special sense organs much work has been done upon the special threshold stimuli which will call forth sensations of light, smell, sound, and taste. It is obvious, if the neurone doctrine be true, that for the spreading of an impulse or excitation through the nervous system one neurone must act as the excitant upon the neurone or neurones beyond it which stand in conduction relation with it. It seems highly probable, therefore, that each neurone has a special threshold value. Goldscheider,‡ in a brilliant essay recently published, has defined the "neurone threshold" (*Neuronschwelle*) to be the degree of excitation of a neurone which just suffices to call forth a fruitful excitation in a neurone with which it is in contact; that is, that sufficient to call forth a sensation, a movement, etc. If this view be correct, the resistance in the passage of the excitation from neurone to neurone would, Goldscheider believes, lie at the point of contact or of conerescence of the neurones. A series of new problems are opened up by this suggestion, not only with regard to the easier propagation of impulses in habitual nerve processes (*Bahnung*) and with regard to the phenomena of inhibition (*Hemmung*), but also with regard to the therapy of nervous diseases, especially the explanation of phys-

---

\* Cf. v. Frey, M. Untersuchungen über die Sinnesfunctionen der menschlichen Haut. Erste Abhandlung: Druckempfindung und Schmerz. Abhandl. d. math.-phys. Cl. d. K. Sächs. Gesellsch. d. Wissensch., Bd. xxiii (1896), No. 3, S. 168-266.

† Barker, L. F. Ueber einen Fall von einseitiger, umschriebener und elektiver sensibler Lähmung. Deutsche Ztschr. f. Nervenhe., Leipz., Bd. viii (1895-'96), S. 348-358. Also Transl. in J. Exper. M., Balt., vol. i (1896), pp. 348-360.

‡ Goldscheider, A. Die Bedeutung der Reize für Pathologie und Therapie im Lichte der Neuronlehre, Leipz. (1898), 8vo, S. 1-88.

ical therapeutic methods like massage and hydrotherapy. The monograph comes to hand too late to be reviewed here in detail, but every neurologist will be repaid by a careful perusal of it.

The importance of normal adequate stimuli for the welfare of the neurones in health can no longer be questioned. As van Gehuchten has emphasized, without stimuli there can be no life. For the maintenance of absolutely perfect function the relation of stimuli to the reparative nutritive power of the cell must be absolutely and perfectly adjusted. Just here the *Ersatz-Theorie* of tabes elaborated by Edinger can be easily understood. Edinger, under the influence of Weigert, assumes that, if stimuli be received in excess, a nerve cell is no longer able in the intervals of active function to repair the loss sustained by the functional activity. As a result, progressive degeneration ensues. In certain diseases like tabes there is, in his opinion, an abnormal impairment of the power of restitution on the part of the nerve cell, so that a given neurone is no longer able to keep up its nutrition even when the stimuli reaching it are not in excess of what would be normal in a healthy body. As a therapeutic measure in tabes, therefore, he urges the importance of giving more than usual rest to the neurones which are degenerating. Thus, a man who has been compelled to be much upon his feet, and who suffers, say, from lumbar tabes, would be ordered rest in bed. In cases of brachial tabes, exercise of the arms would be interdicted. With beginning degeneration of the optic paths reading and all unnecessary use of the eyes would be proscribed. Edinger asserts that he has, in many instances, not only been able to arrest the progress of the disease in this way, but to markedly ameliorate symptoms already present.

In many cases of neurasthenia associated with pathological painful sensations in one part of the body, the symptoms can be relieved by increasing the number of stimuli entering the central nervous system by means of sensory neurones distributed to other parts of the body, by massage, faradization, hydrotherapy, etc. It is not impossible that the beneficial effects of counter-irritation are to receive their explanation in a similar way. It will be the task of the clinical neurologist in the future to decide from his study of a given case as to the existence of abnormal neurone-threshold values; further, what neurones are receiving an excess of stimuli and what neurones are being insufficiently stimulated, and to outline his treatment accordingly.

The doctrine of the specific energies of nerves, since the time of its formulation by Johannes Müller, has taken a prominent place in nerve physiology. The view of Müller has been much misunderstood and often misstated, and many modifications of it have been suggested.\* It has been left for the neurone doctrine to explain, if it can, why it is that on stimulation of the retina or of the optic nerve, for example, the response always occurs in one and the same manner; no matter whether the stimulation be by normal methods or by mechanical or electrical means, the sensation of light or of color alone is yielded; or how it happens that when a "cold point" in the skin is stimulated, whether it be with ice, the prick of a sharp toothpick, an electrical current, or a piece of hot wire (paradoxical cold reaction of von Frey), the sensation of cold always results.

The constancy of the quality of the reaction, despite the variability in the form of the external stimulus, is one of the most puzzling of the phenomena with which the neurologist has to deal. While some physiologists would attribute the whole essence of the process to the characters of the peripheral apparatus with which the nerves are connected, maintaining that the position of the centres at which the stimuli arrive at birth is a matter of little significance, others hold that the sort of response evoked is dependent entirely upon the central region affected by the stimulus, which would mean that the specific energies belong to the centres and are practically independent of the periphery. It seems to me that each of these doctrines, though supported by distinguished neurologists, is necessarily incomplete. Is it not much more likely that in the gradual process of development and modification peripheral and central organs have been correlatively differentiated? We can not think that the various modifications of apparatus mediating between the external physical influences and the most peripheral portions of the sensory neurones of different kinds represent accidental structures which have no physiological import, nor can we imagine that were the central projection fields in the cerebral cortex, at which the sensory impulses arrive from the different parts of the periphery, of no specific significance for the origin of the different sensations, they would present for the

---

\* For a clear and complete account of the doctrine the reader is referred to A. Goldscheider's article: *Die Lehre von den specifischen Energien der Sinnesnerven*, Berlin, 1881.

different sensations so absolutely specific a structure.\* The pathological cases again, in which direct irritation of these areas in the cortex has called forth definite sense perceptions, speak for a direct relation of these centres to the specific energies of the sensory nerves. Odors, images of colored objects, of muscular movements, and of sounds have been experienced by individuals suffering from the pressure of cysts and other bodies upon the corresponding cortical sense areas.

The question is still obscure, nor have we much promise that it will speedily be satisfactorily explained. Von Kölliker,† in a discussion of the physiological functions of the elements of the brain, thinks that all nerve cells possess in the beginning essentially the same function, and that the manifestation of function depends entirely upon the manifold external influences or stimuli which affect them, and upon the many possible modes of responding to these excitations.‡

\*“ Die handgreiflichen Unterschiede im Bau der Centralwindungen, der Rinde der Fissura calcarina, des Gyrus hippocampi, etc., sind schon lange bekannt, wenn auch sonderbarerweise nicht recht gewürdigt.” P. Flechsig, *Gehirn und Seele*, II Aufl., Anm. 31.

† *Op. cit.*, Bd. ii, S. 803-813.

‡ “So drängt sich doch zuletzt die Ueberzeugung zwingend an, dass alle Nervenzellen von Hanse aus wesentlich dieselbe Funktion besitzen, und dass das Inslebentreten derselben einzig und allein von den mannigfachen äusseren Einwirkungen oder Reizen, welche dieselben treffen und von den vielen Möglichkeiten einer Beantwortung dieser Erregungen abhängt.”



## CHAPTER XXII.

### THE NEURONE AS A UNIT OF NERVOUS FUNCTION.

Participation of all parts of the neurone in the phenomena of irritability—  
Functions of the cell bodies—Views regarding the nature of the  
dendrites.

WITH the concept we have gained of the neurone with all its parts, as a cell, and of the unity which characterizes the various steps in its metabolism, it would almost seem idle to devote time to the question of the existence of a unity in nervous function; the latter would appear to be a necessary corollary, and I should not discuss this topic at all were it not that some of the most distinguished investigators have assumed that only a part of the neurone is concerned in the actual nerve function, in the phenomena of irritability, in the transmission of impulses, and the like.\* All are agreed that the axone—the axis cylinder of the nerve fibre—with its endings, is active in the conduction of impulses, but concerning the nerve function of the cell body and of the dendrites there has been much controversy. Recalling for a moment what was said at the beginning of these remarks regarding the position assumed by Golgi as to a diffuse nerve network, it will be remembered that he excluded in the spinal cord the dendrites and the cell body from the reflex arc. The sensory impulses, he thought, passed from the sensory fibres directly through the fibril reticulum out along the side fibrils to the axones of the motor fibres, and thence along them to the muscles. Accordingly, he doubted the possession of nerve function by the cell body and dendrites, and assumed that they were set apart to act solely as nutritive structures. That the cell bodies themselves are concerned directly in the nerve function can now scarcely be doubted by any one, hardly even by Golgi and Nansen, since the intimate

---

\* Irritability and conductivity, as has long been known, are not equivalent terms.

relation of axone and terminals to the protoplasm has been clearly demonstrated in certain instances. The origin of the idea of the non-participation of the cell body in the propagation of nerve impulses can be accounted for by the apparent existence of mechanisms for excluding it from the direct path of the current. A pregnant example offered was the arrangement in the spinal ganglion cell. For a long time it was held by many that the T-shaped process which brought the peripheral into a direct line with the central axone was for the purpose of cutting off the cell body from the conduction path. This idea was negatived by the demonstration of Wundt\* of a delay in the passage of the impulse corresponding to its passage through the spinal ganglion of 0.003 of a second, a result which has been confirmed and extended by the experiments of Gad and Joseph upon the vagus of rabbits. Moreover, the relations of the processes to the cell body in the cochlear and vestibular ganglia of human beings, as well as those in all the sensory ganglia of fishes, necessitates the passage of the impulses directly through the cell bodies. And, lastly, the physiologists who have studied such centres, as, for example, that governing respiration in the medulla, and who assume that excitation of this centre can result from the direct chemical action of gases in the blood, will not permit us to believe that the group of cell bodies making up the centre is unconcerned in nervous mechanisms.

There has been much controversial writing upon the functions of the dendrites. The arguments in favor of the different views have been ably marshaled and criticised by both von Kölliker† and von Lenhossék.‡ On account of the fundamental importance of the topic it will be necessary to consider briefly the main points bearing upon it.

A mainstay of the Golgi school was the supposed direct attachment of the ends of the dendrites to the glia cells and to walls of the blood-vessels. The supporters of the "nutrition" view held that the dendrites through their apical attachments represent the direct paths for the introduction of food materials

---

\* Wundt, W. *Untersuchungen zur Mechanik der Nerven und Nerven-centren*, 8vo, Stuttgart, 1871-'76.

† Von Kölliker. *Handbuch der Gewebelehre des Menschen*, Bd. ii, S. 58, 111-115, 126-128, 683, 684.

‡ *Op. cit.*, S. 135-143.

from the blood-vessels into the nerve cells. Now, while the direct attachment of many of the processes of glia cells to the walls of the blood-vessels appears to have been definitely proved, there is no evidence at all that any such arrangement commonly exists for the dendrites of the nerve cells. According to von Kölliker, the only attempt to picture such a relation is that of Sala.\* This example of failure of the dendrites to end free must be looked upon as an unusual observation. Even if it be confirmed, the experience of every one who works with the silver method must convince him that such a relation is highly exceptional. Moreover, studies upon the histogenesis of the nerve centres reveal no distinct reciprocal relations between the blood-vessels and the dendrites.

This connection with the blood-vessels was thought by Golgi to be the true explanation for the existence of the forests of dendrites which pass out toward the surface of the cerebellum and cerebral cortex, and of the dendrites which in the spinal cord run out in no inconsiderable numbers into the white matter for some distance, and in some animals (for example, certain reptiles) even to the surface, forming a matted feltwork upon the exterior of the cord. Could any more plausible explanation be given than that they, like the roots of trees drawing juices from a distance, pass outward to obtain nutriment from the blood-vessels of the pia?

That adendritic cells exist, has been adduced as an argument against the nervous function of the dendrites and in favor of their nutritive function. So obvious a fallacy is hardly worthy of consideration.

Some histologists, who concede that many of the dendrites have to do with both nervous and nutritive activities, believe that dendrites may exist which possess only one class of these functions. Thus, von Kölliker, while he inclines to the view that many of the dendrites are concerned in conduction,† is by no means willing to deny that there are some of them which do not play such a part, but which serve only to aid in the nutrition of the cell. He emphasizes the statement that all the

---

\* Sala, L. Zur feineren Anatomie des grossen Seepferdefusses. *Ztschr. f. wissenschaft. Zool.*, Münch. u. Leipz., Bd. lii, Taf. v, Fig. 6.

† "Fassen wir alles zusammen, so scheint, wie die Sachen jetzt liegen, die Wageschale doch in hohem Grade zu Gunsten der nervösen Natur der Dendriten sich zu neigen." *Handbuch der Gewebelehre*, Bd. ii, S. 113.

physiological functions of the spinal cord can be entirely satisfactorily explained without calling in the aid of the dendrites.\*

There is some force in the objection that there are dendrites so situated in the nervous system that they apparently can not come into conduction-relation with structures belonging to other neurones. Many of the examples which have been brought forward to illustrate this point have not, however, stood the test of investigation. Thus, Ramón y Cajal and C. L. Sala have demonstrated in batrachians collaterals from the fibres of the white funiculi in the spinal cord which run out toward the periphery and even to the surface of the spinal cord to mingle with the plexus of dendrites in that situation. In the olfactory bulb, however, and in Ammon's horn and the fascia dentata, there are dendrites which appear to have no direct relations to the terminals of collaterals or axones of other neurones. At any rate, such relations have not yet been proved. Even von Lenhossék, who along with van Gehuchten and Ramón y Cajal is one of the strongest supporters of the view that many of the dendrites are conductors, grants † that to assert that the disposition of the dendrites in the nerve centres depends entirely upon the establishment of functional relations among different neurones is going too far. He argues that if this were the sole determining factor the organism could have gotten along with much simpler arrangements than those to be met with in many parts of the central nervous system—for example, in the molecular layer of the cerebellar cortex. He would rather assume that the excitations occurring within nerve cells are in some way favored by the fact that the protoplasm of the cell is split up into a number of fine processes—the dendrites.

Let us turn now to the data which favor the assumption that the dendrites are concerned in nerve function as well as in aiding in caring for the nutrition of the neurone. The most convincing evidence of nerve function in dendrites is that offered by the structure of those curious bodies, the olfactory glomeruli. The view advanced by Owsiannikow ‡ and by

---

\* *Op. cit.*, S. 126.

† *Op. cit.*, S. 142.

‡ Owsiannikow, P. Ueber die feinere Structur der Lobi olfactorii der Säugethiere. Arch. f. Anat., Physiol. u. wissenschaft. Med., Leipz. (1860), S. 469-477.



Walter,\* that the fibres of the olfactory nerve on entering the bulb from the regio olfactoria become directly continuous with the processes of the large and small nerve cells of the gray matter of the olfactory lobe, was sharply contested by Golgi,† who asserted that between the fine fibrils into which the olfactory nerve fibres break up on entering the glomeruli and the beginnings of the protoplasmic processes of the cells of the gray matter no union can be demonstrated; nay, since sometimes the protoplasmic processes stain when the axis-cylinder processes fail to take the dye, and *vice versa*, probably a chemical difference between the two sets of fibrils exists.

Ramón y Cajal,‡ from a careful study of the glomeruli with the osmo-bichromate method, came to the conclusion that the only possible path for the olfactory nerve impulses is from the terminals of the olfactory fibres in the glomeruli to the dendrites of the mitral cells, and along these to the cells whence they follow their axones into the olfactory tract (Fig. 157).\* These observations and views were confirmed in a large number of animals by van Gehuchten and Martin,|| as well as by von Kölliker.<sup>^</sup> The last states emphatically (1) that the dendrites can assume the conduction of nerve impulses and (2) that the transference of nerve impulses from one neurone to another can take place directly from fibre to fibre, a direct influence of cell body upon fibres or of fibres upon cell bodies not being essential.

The existence of anatomical relations which render necessary the assumption of a conducting capacity for the dendrites has been further demonstrated in the cerebellar cortex by

\* Walter, G. Ueber den feineren Bau des Bulbus olfactorius. Arch. f. path. Anat., etc., Berl., Bd. xxii (1861), S. 241-259.

† Golgi, C. Sulla fina struttura dei bulbi olfattorii. Riv. sper. di freni-at., Reggio-Emilia (1875), vol. i, pp. 405-425.

‡ Ramón y Cajal, S. Origen y terminación de las fibras nerviosas olfactorias. Gac. san. de Barcel., vol. iii, 1890; also El eneefalo de los reptiles Barcelona, 1891.

\* Golgi's observation of fine axones entering the olfactory glomeruli, other than those of the nervi olfactorii, has not, so far as I know, been confirmed by others.

|| van Gehuchten, A., et Martin, J. Le bulbe olfactif chez quelques mammifères. La cellule, Louvain, t. vii, fasc. 2, pp. 205-237.

<sup>^</sup> von Kölliker, A. Ueber den feineren Bau des Bulbus olfactorius. Sitzungsab. d. phys.-med. Gesellsch. zu Würzb., Jahrg. (1892), No. 1, S. 1-5.

Ramón y Cajal; \* in the optic lobe of birds (Fig. 158) by van Gehuchten; † in the distribution of the axones of the mitral

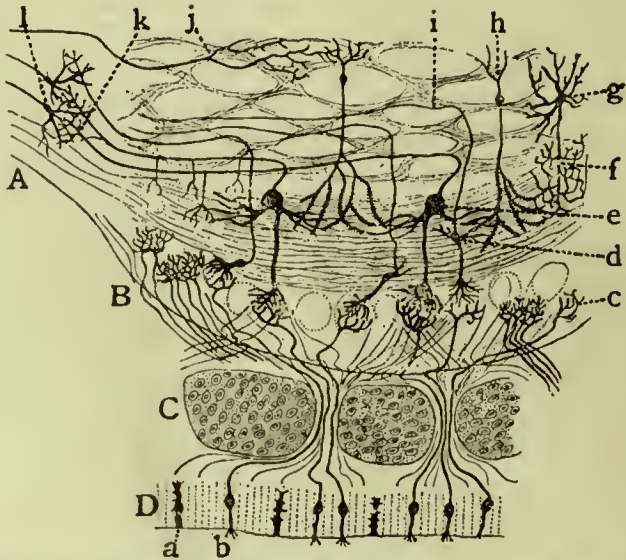


FIG. 157.—Scheme of the olfactory apparatus of mammals. *A*, the olfactory lobe; *B*, olfactory bulb; *C*, cartilage of the embryonic cribriform plate; *D*, nasal mucosa; *a*, supporting cell; *b*, peripheral olfactory neurone; *c*, arborization of an olfactory nerve fibre in the glomerulus of the olfactory bulb; *d*, small nerve cell; *e*, mitral cell; *h*, so-called "grannule"; *g*, large stellate cell with short axone (*f*) terminating in the molecular layer; *j*, arborization of fibres of central origin. (After Ramón y Cajal.)

cells of the olfactory lobe by Calleja; † and in the retina by Dogiel.\* There can, therefore, be no doubt that certain of the dendrites are capable at least of receiving excitations and of playing a part in their further propagation. Ramón y Cajal, van Gehuchten, Retzius, and von Lenhossék have therefore endeavored to extend the view so as to make it hold in general for all dendrites, and have assumed that the most common mode

\* Ramón y Cajal, S. Significaeión fisiológica de las expansiones protoplasmáticas y nervosias de las células de la sustancia gris. *Rev. de cien. méd. de Barcel.* (1891), Año xvii, p. 673.

† van Gehuchten, A. La structure des lobes optiques chez l'embryon de poulet. *Cellule, Lierre et Louvain*, t. viii (1892), fase. i, pp. 1-43.

‡ Calleja, C. La región olfactoria del cerebro, Madrid, 1893.

\* Dogiel, A. S. Ein besonderer Typus von Nervenzellen in der mittleren gangliösen Schicht der Vogel-Retina. *Anat. Anz., Jena*, Bd. x (1895), No. 23, S. 750-760.

of transference of a nerve excitation from one neurone to a second is by means of the contact of the terminals of an axone of the former with the dendrites of the latter, a conclusion which would seem to be scarcely warranted by the facts at pres-

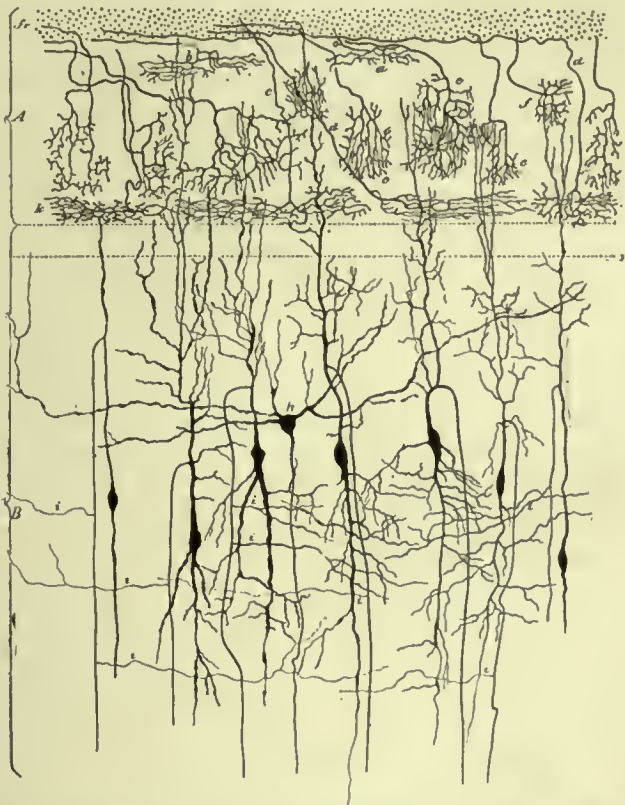


FIG. 158.—Section through the optic lobe of the embryo chick. (After A. van Gehuchten. *Cellule*, Liège et Louvain, t. viii, 1892, Pl. i, Fig. 1.) In the external layer *A* are represented the terminals of the fibres of retinal origin; in the layer *B* are shown several nerve cells of the middle zone of the optic lobe; *fr*, zone of peripheral nerve fibres; *a* and *b*, superficial arborizations; *c* and *d*, deep arborizations; *e*, rectangular arborizations; *f*, cuboidal arborizations. The nerve cells show internal dendrites manifoldly branched, and a large peripheral dendrite which terminates at different levels in the outer layer, sometimes (*k*) by a horizontal arborization at the level of the deep retinal arborization. The axone arises from the peripheral dendrite and runs through the middle layer, giving off numerous collaterals, *i*.

ent established. That it is one method of transference is certain; but that there are others, for example, through direct

contact or concrescence of axone terminals with the protoplasm of the cell body, all grant.

It may be worth while to point out just here a certain fallacy of generalization to which, curiously enough, attention appears not to have been called. Evidence has been adduced which demonstrates indubitably that in certain parts of the nervous system the anatomical relations are such that a conducting function for the dendrites must be admitted. This proof was brought forward as one of the means of demonstrating the nervous function of the dendrites. But some writers appear to take it for granted as a necessary sequence that dendrites for which no such anatomical relations are demonstrable possess no nerve function. If this were sound reasoning, we should have to assume that the transference of impulses from one neurone to another made up the sum total of the nervous functions, an absurdity too obvious to need further discussion. We have not the right to draw our deductions from any one factor to the exclusion of all other coexisting influences. It is surely easy to conceive of a participation of the dendrites in the nerve functions of the neurone, even if they stand in no direct relation either of receiving or discharging to another neurone or set of neurones. Indeed, granted that one portion of a single cell, as we believe a whole neurone to be, possesses nerve function, the onus of proof upon the question of the nature of another portion of this cell—for example, the dendrites—lies with those who deny the nervous function, not with those who maintain it.

Now that the cell body of the neurone is known to possess nerve function, the fact that the axone often comes off from a dendrite instead of from the cell body is further evidence in favor of the identity or at least similarity of function of cell body and dendrites. This conclusion would agree strikingly with the morphological resemblances revealed by the method of Nissl. Further, if anaxones are to be regarded as nerve cells, as seems almost certain, the dendrites must surely possess nerve function.

That the axones are concerned in the nerve function of the neurone has, so far as I know, never been questioned. It is generally believed that in the conduction of the excitations there can be no transference from one neurone to another except in those parts in which the myelin sheath is not present—that is, for the majority of neurones, so far as the axone is concerned, only in the region of its terminals and possibly in the short non-medullated portion immediately adjacent to the



nerve cell. This statement is equally true of the collaterals, for, as Flechsig\* has shown, these branches, at least in the cerebral cortex, are, like the main axones, provided with medullary sheaths. We have indubitable evidence, too, that the majority, if not all, of the collaterals of the dorsal root fibres within the spinal cord are medullated. The side fibrils of Golgi are non-medullated, and from the studies of von Lenhossék, Apáthy, Held, and Bethe may probably be important agents in the transference of impulses from neurone to neurone. The relation in which the side fibrils stand to the neuropilum in invertebrates has already been referred to.

---

\* Flechsig, P. Ueber eine neue Färbungsmethode des centralen Nervensystems und deren Ergebnisse bezüglich des Zusammenhanges von Ganglienzellen und Nervenfasern. *Arch. f. Anat. u. Physiol., Leipz., Physiol. Abth.* (1889), S. 537.

## CHAPTER XXIII.

### ON THE DIRECTION OF CONDUCTION IN THE NEURONES AND THE THEORY OF THEIR DYNAMIC POLARITY.

Direction followed by nerve impulses in their passage through neurones—  
Cellulipetal and cellulifugal conduction—Theory of the dynamic polarity of the nerve elements—Question of possibility of conduction in both directions in axones and dendrites.

WE have now to deal with the question of the direction followed by a nerve impulse in its passage through a neurone, and have to consider the evidence for and against the view that the impulses in a given variety of cell processes take always the same direction. The hypothesis that in the neurone the dendrites represent the apparatus for receiving nerve impulses, conducting always in the direction of the cell body (cellulipetal conduction), the axones being the discharging processes conducting always in a direction away from the cell body (cellulifugal conduction), advanced first, I believe, by van Gehuechten in April, 1891,\* has been strongly advocated also by Ramón y Cajal† in an article in which he deals with “the theory of the dynamic polarity of the nerve elements.” Retzius‡ has declared also in favor of this view, and it has been adopted, though in a somewhat modified form, by von Kölliker, Waldeyer, von Lenhossék, and others. In the embryological considerations of His and of Mall it met with approbation, since *a priori* nothing could be more natural than that the processes developed upon the end of the cell originally directed toward the outside of the body

---

\* van Gehuechten, A. La structure des centres nerveux. La moelle épinière et le cervelet. Cellule, Liège et Louvain, t. vii (1891), p. 101.

† Ramón y Cajal, S. Significación fisiológica de las expansiones protoplasmáticas y nerviosas de las células de la sustancia gris. Rev. de cien. méd. de Barcel., vol. xvii (1891), p. 673.

‡ Retzius. Ueber die neueren Prinzipien in der Lehre von der Einrichtung des sensiblen Nervensystems. Biol. Untersuch., Stockholm, n. F., Bd. iv, 1892.

should serve for the reception of stimuli.\* The actual proof of cellulipetal conduction in dendrites is established by the observations previously mentioned, which demonstrate their conducting capacity; above all, by those bearing upon the structure of the mitral cells and the relation of their dendrites to the olfactory glomeruli. The galvanometric experiments of Mislawsky† have led him to support the doctrine of cellulipetal conduction in dendrites.

That the axones, at least when engaged in those of their functions with which we are acquainted, conduct, as a rule, cellulifugally is immediately apparent. Among other examples we have the passage of impulses along the pyramidal tracts or along the motor nerves from the ventral horns to the muscles, or, again, in the dorsal funiculi of the spinal cord or in the optic nerve. From the nature of things in motor neurones the cellulifugal impulses passing along the axones are also centrifugal impulses; while in the sensory neurones within the central nervous system the cellulifugal impulses in the axones are, as a rule, centripetal. This is not, however, tantamount to saying that centripetal impulses are always descending, and that centripetal impulses are always ascending, although this holds as a general rule. An example of an exception is to be found in the descending limb of the Y-shaped divided dorsal root fibre which passes downward to terminate in the gray matter of a lower level and is undoubtedly a centripetal fibre.

Are there exceptions to the law of cellulipetal conduction in dendrites and of cellulifugal conduction in axones? This question, according to our present knowledge, must be answered in the affirmative. In those dendrites from which occasionally an axone takes its origin it is obvious that the conduction in the portion of the dendrites between the general cell body and the axone hillock must be cellulifugal, not cellulipetal, a difficulty of nomenclature which can be obviated by adopting the suggestion of von Lenhossék, who recommends describing the impulses in dendrites as being *axopetal* rather than cellulipetal. But in this way we are thrown on the other horn of the

---

\* Cf. Mall, F. P. Histogenesis of the Retina in *Amblystoma* and *Necturus*. J. Morphol., Bost., vol. viii (1893), pp. 415-432.

† Mislawsky, N. Sur le rôle physiologique des dendrites. Compt. rend. Soc. de biol., Par. (1895), 10. s., t. ii, p. 488.

dilemma when we consider the direction of conduction in the dendrites of an anaxone—for example, in the amacrine cells of the retina. Where there is no axone it would be absurd to speak of axopetal impulses. The argument that there are dendrites which stand in no relation with processes of other neurones which would permit of any transference of impulses makes against the doctrine of the universal cellulipetal conduction of dendrites. Further, if there is ever a transference of impulses from one neurone to another by means of the interwoven dendrites of two neurones, a view which von Beehterew strongly supports, it is obvious that with a given impulse the direction of the conduction in one of the sets of dendrites must be cellulifugal and axofugal. Von Beehterew, in corroboration of his hypothesis, describes the intimate relations of certain dendrites of the two halves of the cord in the ventral commissure, and of those of the anaxones in the olfactory lobe with those of the mitral cells; further, he adduces as instances the dendrites in the molecular layer of the cerebral cortex, and especially those of the nuclear layer of the cerebellum. Interesting as the hypothesis is, there is, as yet, no proof of its truth.

Nearly all writers have agreed that in vertebrates in the typical monaxones the conduction along the axones is cellulifugal. In the diaxones, however, the same rule need not hold. If we look upon the spinal ganglion cells as diaxones, then, ob-

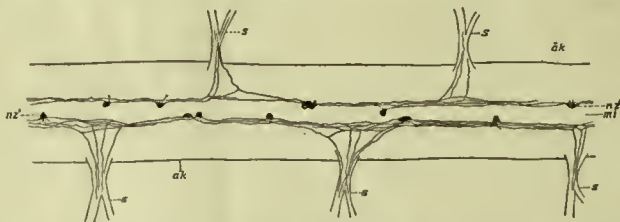


FIG. 159.—Spinal cord of amphioxus. (After Retzius.) *ak*, outer angle of spinal cord; *mi*, median line; *s*, sensory nerve roots; *nz'*, bipolar ganglion cells, the main processes of which run longitudinally and divide dichotomously (T-shaped), sending one branch into a sensory root.

viously, the direction of the conduction of the sensory impulses in the peripheral axone is cellulipetal; in the central axone, cellulifugal. Those who have committed themselves to the doctrine of universal cellulifugal conduction in axones have denied that the axis cylinder of the peripheral sensory nerve fibres is really an axone, assuming it to be rather dendritic in



nature.\* The fact, too, that the axis cylinder of the peripheral fibre is, as a rule, of thicker calibre than that of the central fibre has been thought to favor the view that it is a protoplasmic process; but, as has been stated, this would appear to be entirely referable to the differences in distance between the cell body and the end of the axis cylinder, since for the ordinary ganglion

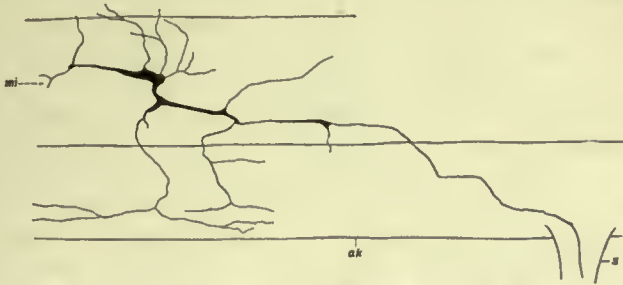


FIG. 160.—Spinal cord of amphioxus. (After Retzius.) *mi*, median line; *ak*, outer angle of spinal cord; *s*, sensory root. A rather large multipolar cell is shown, the axone of which enters into a sensory root.

the peripheral fibre is, as a rule, longer than the central; for the cochlear and vestibular ganglia the peripheral fibre is the shorter, and here the process passing to the periphery is of smaller calibre than that of the central fibre. I take it that we must acknowledge that, though embryologically a dendrite, the peripheral sensory fibre in the adult is histologically an axone, and the passage of impulses from the periphery to the centres must be granted as an example of cellulipetal conduction in an axone. In amphioxus, an animal which possesses no spinal ganglia, Retzius† has shown that the sensory impulses are received by the telodendrions of axones and conveyed along axones cellulipetally to the nerve centres, a form of sensory apparatus very commonly met with in invertebrates. In amphioxus two varieties of cells send axones into the sensory roots, bipolar cells (Fig. 159, *n z'*) and multipolar cells (Fig. 160) (Smirnow, Retzius, von Lenhossék).

\* The suggestion that the peripheral sensory fibre is a dendrite was, I believe, first made by Ramón y Cajal, in 1889, in an article entitled *Conexion general de los elementos nerviosos*, which appeared in *La medicina práctica*, Madrid, in October of that year.

† Retzius, G. Zur Kenntniss des centralen Nervensystems von *Amphioxus lanceolatus*. *Biol. Untersuch.*, Stockholm, n. F., Bd. ii (1891), p. 29.

The fact that the optic nerve contains axones whose cells of origin are situated not in the retina but in the brain (*corpora quadrigemina*) is not, as some think, proof of cellulipetal conduction in axones. I can see no reason for not believing that centrifugal impulses pass from the brain to the retina. Indeed, now that we know what an enormous number of neurones are situated within the retina, it would be surprising were its elements not in some way under the control of a governing centre in the central nervous system; and *a priori* the centre most likely to possess the power would be one of the three which first receive the centripetal impulses from the retina, namely, that which we know to be also the local seat of government for the movements of the eye muscles—the superior colliculi of the *corpora quadrigemina*. That these centrifugal fibres of the optic nerve represent the apparatus concerned in the objectivization of received sensations—*i. e.*, in their projection outward—an idea suggested by von Bechterew, does not seem to me to be probable.

The arguments for cellulifugal conduction in axones hold also for their medullated collaterals. The hypothesis has been put forward by von Lenhossék\* that Golgi's distinction between non-medullated side fibrils and true medullated collaterals is of definite physiological significance. He thinks it very probable that the side fibrils act as axopetal conductors, the true collaterals alone being cellulifugal as regards direction of conduction. He advances as examples the relations of the side fibrils on the axones of the ventral horn cells of the cord, the Purkinje cells of the cerebellum, and those described by Ramón y Cajal and van Gehuchten on the axones of the olfactory mitral cells. He would designate the side fibrils then as axodendrites (to distinguish them from cytodendrites), and the true collaterals as paraxones. Von Lenhossék's personal studies, particularly those dealing with the relations in rodents (Fig. 161) of the sensory collaterals to the side fibrils given off from the axones of the ventral horn cells, are indeed strikingly suggestive of the exercise by the side fibrils of a receptive function for impulses. As a result of his own studies van Gehuchten† has opposed this theory, and I must agree with von Kölliker that up to the present time a cellulipetal conduction in the col-

---

\* *Op. cit.*, S. 129-134.† *Cellule*, t. xi.

laterals (side fibrils) is no better proved than is cellulifugal conduction in the dendrites.

If the studies of Apáthy and Bethe be confirmed, and it be true that the fibrils demonstrable by their methods be especially differentiated for the purpose of conducting impulses, a participation of all parts of the neurone in the phenomena of conduc-

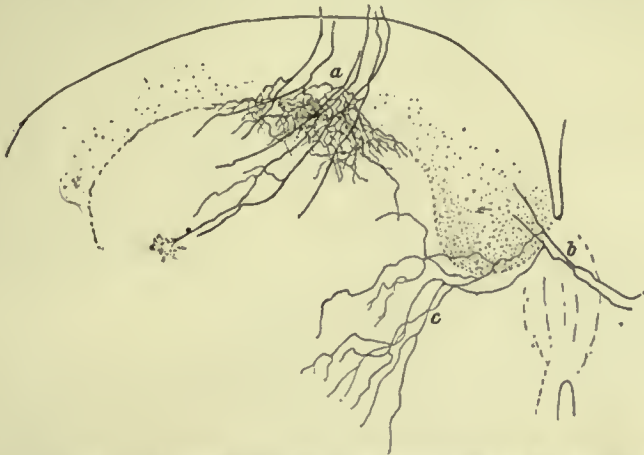

FIG. 161 —Portion of spinal cord of new-born rabbit stained by the chrome-silver method. *a*, fine plexus formed of Golgi's side fibrils from the axones of ventral horn cells at the ventral margin of the ventral horn; *b*, commissural axone with long side fibrils, *c*. (After M. von Lenhossék, *Der feinere Bau des Nervensystems*, etc., 11 Aufl., 1895, S. 257, Fig. 38.)

tion must be granted, for these fibrils are limited to no single portion of the neurone. Moreover, since the same fibril can sometimes be followed running cellulipetally in one branch of a dendrite and cellulifugally in another branch of the same dendrite (Bethe), it is obvious that, if the fibril conducts, the dendrites must carry both cellulipetal and cellulifugal impulses.

A most interesting and difficult experiment performed by Bethe\* must here be referred to. This investigator, working at Naples in November, 1896, isolated the neuropil of the second antenna of *Carcinus*—in other words, he removed the ganglion cells of the neurones supplying the antenna, but left their processes and side branches. He proved that, even in the ab-

\* Bethe, A. *Das Centralnervensystem von Carcinus Maenas*. Ein anatomisch-physiologischer Versuch. I. Theil, 2. Mittheilung. *Arch. f. mikr. Anat.*, Bonn, Bd. I, S. 589-639.

sence of the perikaryons of the neurones, flexion and extension can be reflexly produced—apparently an absolute demonstration that neurones can temporarily continue to function in the entire absence of their cell bodies. In a still later article,\* as a result of his studies of the primitive fibrils (Apáthy), Bethe concludes that the explanation of his fundamental reflex experiment is to be found in the relations which the fibrils bear to the mechanism. These relations are illustrated in Fig. 162. When Bethe

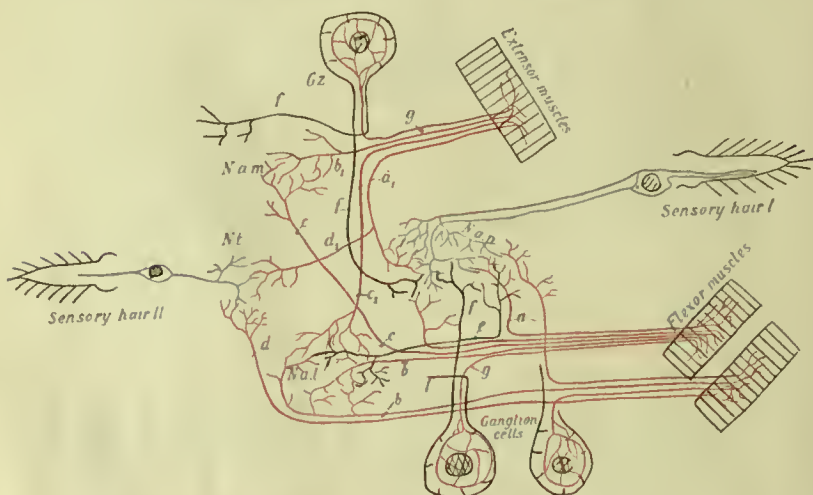


FIG. 162.—Schematic drawing to illustrate the course of the primitive fibrils of the receptive and motor elements of the second antenna of *Carcinus Maenas*. (After A. Bethe, Arch. f. mikr. Anat., Bonn, Bd. li, 1898, Taf. xvii, Fig. 3.) Blue—primitive fibrils coming from the "reception hairs" on the surface of the body to the central organ. Red—the primitive fibrils going to the nucleus. Black—other fibrils.

*N. a. p.*, neuropilum antennarii posterius; *N. t.*, neuropilum tegumentarii; *N. a. l.*, neuropilum antennarii laterale; *N. a. m.*, neuropilum antennarii mediale; *a*, motor primitive fibrils to flexor muscles from *N. a. p.*; *b*, motor fibrils from *N. a. l.* to flexors; *b'*, motor fibrils from *N. a. m.* to extensors; *c*, motor fibril from *N. a. m.* to flexors; *c'*, motor fibril from *N. a. l.* to extensors; *d* and *d'*, fibrils throwing antenna muscles under influence of *N. t.*; *e*, fibril connecting *N. a. l.* with *N. a. p.*; *f*, fibril throwing cell body under influence of neuropil; *g*, motor fibrils extending from cell body to muscles.

removes all the ganglion cells from the neuropils of the second antenna of *Carcinus* and separates them from the whole of the rest of the nervous system by a circular cut and section of the

\* Bethe, A. Das Centralnervensystem von *Carcinus Maenas*. Ein anatomisch-physiologischer Versuch. II. Theil (3. Mittheilung). Arch. f. mikr. Anat., Bonn, Bd. li, S. 382-452.



oesophageal commissure, so that the nerve of the second antenna is connected with end stations (neuropilum antennarii II mediale, laterale et posterius) entirely deprived of ganglion-cell connection, this second antenna still retains its tonus and its reflex excitability. This proves that the reflex arch does not (or at least *need not*) include the cell bodies of the neurones. Since primitive fibrils (Apáthy) can be followed directly from the neuropils into the motor axones without going through ganglion cells, Bethe believes that the reflex path goes by way of the centripetal (receptive fibres) to the neuropil and thence directly (without passage through the perikaryon of the motor neurone) into the centrifugal motor fibres. Thus, on the whole, Bethe's studies afford a strong and most important confirmation of the views of Apáthy, the main difference between the conceptions of the two observers lying in the fact that whereas Apáthy believes that the *Elementargitter* (neuropil of His, Punktsubstanz of Leydig) is "diffuse," Bethe is confident that this is not so. That the conceptions concerning simple contact-relation between the processes of the neurones previously held must accordingly be modified there can be no doubt, though that the doctrine of the morphological and physiological independence of the neurones is invalidated but few will be willing to grant. Bethe himself retains the term neurone as a designation for all the parts easily demonstrable as standing in connection with one ganglion-cell body.

To epitomize our actual knowledge then of the direction of the conduction of impulses in neurones, it may be said that axopetal conduction has been proved for the dendrites of many neurones, and that cellulifugal conduction can be asserted for the majority of axones, although cellulipetal conduction certainly occurs in some. Here our certain knowledge stops, yet the evidence for cellulifugal conduction in many dendrites is very strong, and it is not lacking for cellulipetal conduction in the side fibrils. Nevertheless, it would seem very unwise at present to state positively that nerve impulses may not pass in both directions in all neurones. There is certainly no apparent reason why they should not; indeed, just as we have peristalsis and antiperistalsis in tubes covered by smooth muscle, and just as electrical currents may pass in both directions along a piece of copper wire, it would not be at all improbable in such eminently irritable structures as the nerve cells that the stimula-

tion of either pole or of the terminals of any one of its processes may lead to alterations in the energy conditions of the whole neurone.

That at present we are well acquainted with the evidence for the passage of impulses in the neurones in one direction only does not exclude the possibility that we may at some later time become cognizant of facts which may demonstrate the conduction of impulses of some sort in the opposite direction; especially as physiological experiment has shown that impulses artificially excited in nerve fibres travel in both directions from the point of stimulation. Though the researches of Gotch and Horsley \* make it appear that on artificial stimulation of a motor nerve, while impulses may pass into the cell bodies of the neurones to which these fibres belong, there is no evidence that they pass out of the neurones immediately affected into those related to them anatomically. But the question of cellulipetal and cellulifugal conduction must be solved first for single neurones before the transference of impulses from neurone to neurone can be settled, and the evidence as yet will not permit us to deny the passage of impulses in both directions. The changes in the cell body in the neighborhood of the axone hillock occurring after section of the corresponding axone may not be dependent entirely upon alteration in the character of cellulifugal processes in the cell, but may be influenced in part possibly by cellulipetal influences coming from the point of section. In attempting to explain the phenomena of tetanus, a similar possibility should be borne in mind. The impulses passing in one direction could be of an entirely different nature or quality from those passing in the other. The whole question must be for the present left open. The danger of the ancient mode of induction described by Bacon as "*inductio per enumerationem simplicem, ubi non reperitur instantia contradictaria*," is one against which the scientist must ever be on his guard.

---

\* Gotch, F., and V. Horsley. On the Mammalian Nervous System, its Functions, and their Localization determined by an Electrical Method. Phil. Tr., 1891, Lond. (1892), vol. clxxxii (B.), pp. 267-526.

## CHAPTER XXIV.

### THE RELATIONS OF TROPHIC TO NERVOUS FUNCTIONS IN THE NEURONE.

The relations of trophic changes to nervous functions—Influence of repose and activity upon the neurones—Studies of Hodge upon the histology of fatigue—Studies of Vas, Mann, Lugaro, and others—Investigation of hibernating animals—Method of indirect electrical stimulation of neurones.

WE may now perhaps most suitably turn to a brief consideration of the mutual relations and interdependence of the trophic functions and those which have to do with the manifestations of irritability. In this connection the influence of the repose and of the activity of the neurones upon their nutrition is of especial importance. Intimately associated with this topic of repose and activity is the question of physiological rhythms so ably dealt with by Donaldson.\* Into a discussion of the subject from this standpoint it is not my purpose to enter, and my remarks will be confined to certain more striking histological relations. As has been said above, *a priori* there is in the neurones, as in everything that lives, no such thing as absolute repose, since at no time during life is complete cessation of activity possible. Repose and activity are here, therefore, merely relative terms, and are used throughout in this restricted sense.

The pioneer in the investigation of the histology of fatigue is undoubtedly the American investigator Hodge.†

---

\* *Op. cit.*, p. 293.

† Hodge, C. F. Some Effects of Stimulating Ganglion Cells. *Am. J. Psychol.*, Balt., vol. i (1887-'88), pp. 479-486; Some Effects of Electrically Stimulating Ganglion Cells. *Am. J. Psychol.*, Balt., vol. ii (1888-'89), pp. 376-402; The Process of Recovery from the Fatigue occasioned by the Electrical Stimulation of Cells of the Spinal Ganglia. *Am. J. Psychol.*, Worcester, vol. iii (1890), pp. 530-543; A Microscopical Study of Changes due to Functional Activity in Nerve Cells. *J. Morphol.*, Bost., vol. vii (1892-'93),

In a series of brilliant experimental researches he has established the existence of definite morphological alterations in the cell bodies of neurones accompanying the excessive exercise of their physiological function. He found that prolonged faradic stimulation of a peripheral sensory nerve in the cat led to distinct alterations in the cells of the corresponding spinal ganglion (Figs. 163, 164), and later he was able to demonstrate similar changes in the nerve cells of animals after a long day's exercise (English sparrows, swallows, pigeons [Figs. 165, 166], and honey-bees). On comparison of the non-

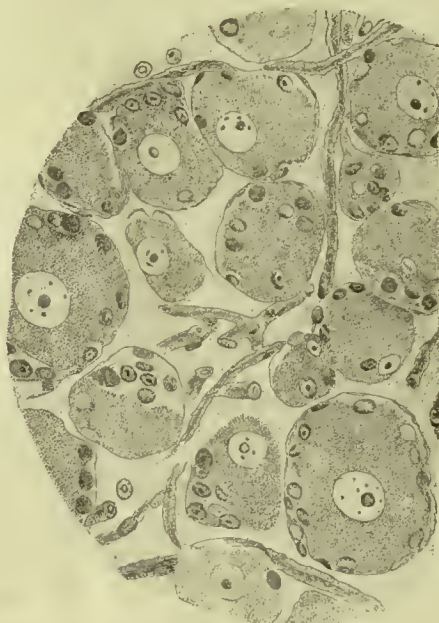


FIG. 163.—Section through ganglion on dorsal root of first thoracic nerve of cat. Osmic acid. Unstimulated. (After Hodge.)

fatigued cells (in case of faradic stimulation, the cells of the spinal ganglia on the side not stimulated; in the other instances, the cells of animals captured in the morning) with

---

pp. 95-168; *Die Nervenzelle bei der Geburt und beim Tode an Alterschwäche*. *Anat. Anz.*, Jena, Bd. ix (1894), S. 706-710; *Changes in Ganglion Cells from Birth to Senile Death; Observations on Man and Honey-Bee*. *J. Physiol.*, Cambridge, vol. xvii (1894), pp. 129-134; *A Microscopical Study of the Nerve Cell during Electrical Stimulation*. *J. Morphol.*, Bost., vol. ix (1894), pp. 449-463.



those artificially or normally fatigued, Hodge found alterations in the latter both in the protoplasm and in the nucleus. The

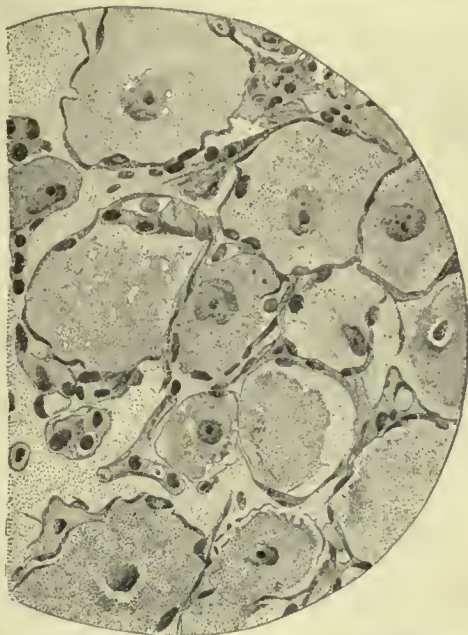


FIG. 164.—Section through ganglion on dorsal root of first thoracic nerve of cat after intermittent electrical stimulation during five hours. Osmic acid. (After Hodge.) The nuclei are darker, shrunken and irregular in outline, and the protoplasm is somewhat vacuolated.

nuclei of the tired cells were diminished in size; they presented zigzag borders and stained more intensely than did normal nuclei; the protoplasm was often shrunken, and stained more feebly than in the cells not fatigued. The alterations disappeared within about twenty-five hours after cessation of the electrical stimulation,\* which had lasted five hours, and in the case of the working animals after a night's rest.

Certain of his experiments in which he stimulated living sympathetic cells where they could be watched directly through the microscope and compared in appearance with others not

---

\* The objection has been quite properly raised by van Gehuchten and by Goldscheider and Flatau that the results obtained from electrical stimulation can scarcely be looked upon as equivalent to those dependent upon normal fatigue. Electricity can not of course be regarded as an "adequate" stimulus.

stimulated, are most convincing. Drawings at intervals show very clearly the gradual alterations which occur.

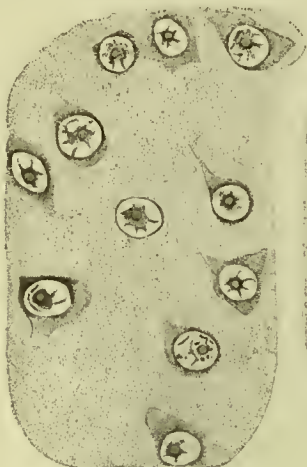


FIG. 165.

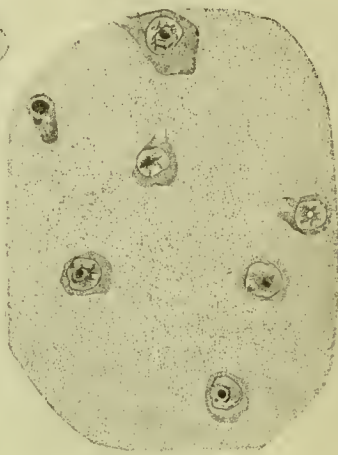

FIG. 166.

FIG. 165.—Camera-lucida drawing of occipital cortex of pigeon killed at 5.30 A.M., to show rested nerve cells. Corrosive sublimate for four hours; Gaule's staining. (After Hodge.)

FIG. 166.—Camera-lucida drawing of cortex of pigeon killed at 7.30 P.M., to show changes in cells indicating normal daily fatigue. (After Hodge.)

Experiments along similar lines have been made by Vas (Fig. 167),\* Lambert,† Mann (Fig. 168),‡ recently by Lugaro,§ Pognat,|| and by Eve.<sup>Δ</sup> Mann and Vas, while essentially con-

\* Vas, F. Studien über den Bau des Chromatins in der sympathischen Ganglienzelle. *Arch. f. mikr. Anat.*, Bonn, Bd. xl (1892), S. 375-389.

† Lambert, M. Note sur les modifications produites par l'excitation électrique dans les cellules nerveuses des ganglions sympathiques. *Compt. rend. Soc. de biol., Par.*, 9. s., t. v (1893), pp. 879-881.

‡ Mann, G. Histological Changes induced in Sympathetic, Motor and Sensory Nerve Cells by Functional Activity. *J. Anat. and Physiol.*, Lond., vol. xxix (1895), p. 100.

§ Lugaro, E. Sur les modifications des cellules nerveuses dans les divers états fonctionnels. *Arch. ital. de biol.*, Turin, t. xxiv (1895-'96), pp. 258-281; also *Sperimentale. Sez. biol.*, Firenze, An. xlix (1895), pp. 159-193.

|| Pognat, C. A. Sur les modifications histologiques des cellules nerveuses dans l'état de fatigue. *Compt. rend. Acad. d. sc., Par.*, t. cxxx (1897), pp. 736-738.

<sup>Δ</sup> Eve, F. C. Sympathetic Nerve Cells and their Basophile Constituent in Prolonged Activity and Repose. *J. Physiol.*, Cambridge, vol. xx (1896), pp. 334-353.

firming the researches of Hodge, have described an enlargement of both cell body and nucleus after brief stimulation; other authors (Swierczowsky and Tomsa) have noticed active movements of the nucleoli during excitation, and Magiui has described a displacement of these structures in a direction toward the axone hillock. Lugaro, who thinks that insufficient attention has been paid to the distinction between signs of cellular activity and those of fatigue, has made an exhaustive series of experiments from which he concludes that the activity of nerve cells is accompanied by a state of turgescence in the protoplasm of the cell body; fatigue, on the other hand, producing progressive diminution in the size of the cell body. He finds that with moderate degrees of activity, which correspond to swelling of the cell body, the nucleus undergoes no alterations in size; but if the activity is prolonged to fatigue it slowly becomes smaller. The stainable substance of Nissl, Lugaro believes, undergoes a slow increase in amount in the earlier phases of activity, while later, when the cell becomes fatigued, it is diminished and is more diffusely distributed throughout the cell body.

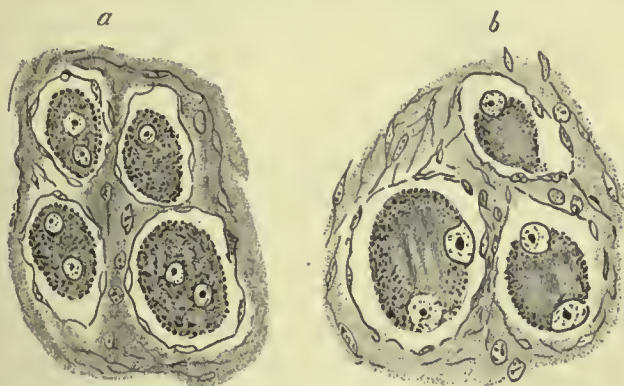

FIG. 167.—Sections through the superior cervical ganglion of the rabbit stained by Nissl's method. (After Vas.)  $\times 1,000$  diameters. *a*, section through normal ganglion; *b*, section through ganglion after stimulation of sympathetic trunk for fifteen minutes with faradic current.

Eve could find as the only change resulting from protracted activity the occurrence of a slight diffuse blue stain in the cell substance (Nissl's method). His idea that this is due to formation of acid by the cell with consequent slight solution and diffusion of the material which stains blue will, considering

what is now known of the Nissl bodies, doubtless meet with opposition.

Studies of the nervous system of hibernating animals have been undertaken by Jacobsohn.\* He found, however, no discernible alteration in the motor cells of the ventral horns.

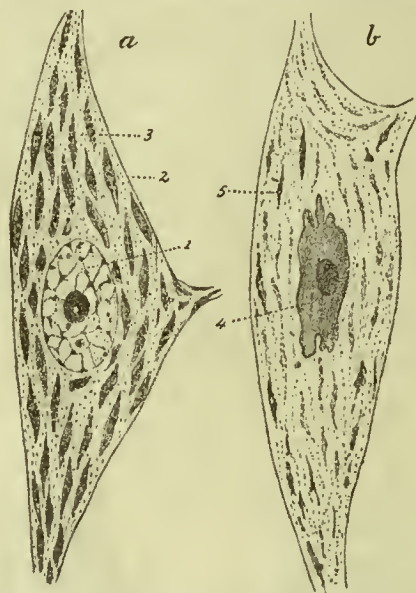


FIG. 168.—Two motor cells from lumbar region of spinal cord of dog fixed in sublimate and stained in toluidin blue. *a*, from the fresh dog: 1, pale nucleus; 2, dark Nissl spindles; 3, bundles of nerve fibrils. *b*, from the fatigued dog: 4, dark shriveled nucleus; 5, pale spindles. (After Mann.)

The influence of prolonged illumination upon the retina has been studied by Pergens.†

A very ingenious suggestion in order to do away with direct traumatic influence or direct physical or chemical influence by an electric current upon the neurone has been made by Goldscheider and Flatau.‡ They suggest that one stimulate the

\* Jacobsohn, L. Ueber das Aussehen der motorischen Zellen im Vorderhorn des Rückenmarks nach Ruhe und Hunger. *Neurol. Centralbl.*, Leipz., Bd. xvi (1897), S. 946-948.

† Pergens, E. Action de la lumière sur la rétine. *Ann. soc. roy. d. sc. méd. et nat. de Brux.*, t. v (1896), pp. 389-421.

‡ Goldscheider, A., und E. Flatau. Normale und pathologische Anatomie der Nervenzellen auf Grund der neueren Forschungen. Berlin (1898), S. 35.



motor region of the cerebral cortex and then examine the cell bodies of the corresponding lower motor neurones (ventral horn cells). In the same way the lower motor neurones could be indirectly stimulated by way of the peripheral sensory neurones (spinal ganglion cells, dorsal roots of spinal nerves), after which the morphological appearances of the ventral horn cells could be compared with the normal. In such an event, as they emphasize, it would be important not to confine one's self to the use of Nissl's method, which gives definite results only with regard to the tigroid masses, but in addition other methods, like those of Flemming, Held, and M. Heidenhain, which demonstrate more particularly the structure of the ground substance, should be employed.

While it is evident that additional research is still urgently called for, it will be seen that enough has already been done to supply us with some direct microscopic evidence for the intimate relations existing between the state of nutrition of the cell and the manifestation of functional activity. In substantiation of these results there exists a considerable amount of pathological and pharmacological evidence, some examples of which will be considered in the following chapter.

## CHAPTER XXV.

### ON THE HISTOLOGICAL ALTERATIONS IN NEURONES DUE TO THE ACTION OF POISONS, AND A COMPARISON OF THESE WITH THE EFFECTS OF TRAUMATISM.

Changes in the neurones in intoxications and infections—Comparison of primary lesions in the cell bodies of neurones with those secondary to lesions of axones—Theories concerning trophicity.

WE are in possession now of a large series of studies by Nissl's and other methods which have been undertaken to investigate the effects of poisonous substances upon the neurones. It would be impossible to even refer to all of these, but a few at least may be mentioned.

Nissl \* has demonstrated definite lesions in the large motor cells of the ventral horns of the rabbit after poisoning with strychnine, veratrin, alcohol, phosphorus, the toxins of tetanus, and trional. He has also shown the alterations produced in the Purkinje cells and spinal ganglion cells of the rabbit after lead poisoning, and the changes in the cortical cells after poisoning with alcohol, morphine, and lead. Nissl has emphasized the differences of the alterations produced in the same group of cells by the action of different poisons, and has further demonstrated that the same poison can lead to entirely different results in different types of cells in the same animal. He has referred not only to the changes in the chromatic and achromatic substance, but also to the nuclear alterations in such intoxications.

Nissl has investigated the nerve cells in acute, subacute, and chronic forms of poisoning, since he finds that the effects of poisoning vary very much according to the time during which the intoxication has been active. Especially interesting are the

---

\* Nissl, F. Ueber die Veränderungen der Nervenzellen nach experimentell erzeugter Vergiftung. Neurol. Centralbl., Leipz., Bd. xv (1896), S. 9; Allg. Ztschr. f. Psychiat., etc., Berl., Bd. liv (1897), S. 1-107.

results which he has obtained in his so-called "subacute maximal intoxications," in which the animal under experiment receives daily an amount of poison just short of the lethal dose until death occurs (after from a few days to several months). The alterations in arsenical poisoning are well shown in Fig. 169. The whole nerve cell is swollen, there is marked diminu-



FIG. 169.—Effects of arsenic upon the nerve cell. (After F. Nissl, *Allg. Ztschr. f. Psychiat.*, etc., Berl., Bd. liv., 1897.) The cell to the left of the figure is normal; that to the right from an animal poisoned by arsenic.

tion in the amount of tigroid substance, so that it is often impossible to distinguish the chromatic from the non-chromatic portion of the cell. Alterations in the nucleus can also be made out.

In his studies of phosphorus poisoning Nissl found very profound alterations in the nerve cell—alterations which tend at the beginning to affect often one portion of the cell in preference to others, although no definite rule as to the exact portion likely to be affected in a given instance could be laid down. In advanced stages of the poisoning the cell is remarkably diminished in size and the nucleus smaller than normal. The architecture of the cell becomes completely obscured, the only trace of tigroid remaining being a few dustlike particles and irregular granular masses. The cells may even go on to complete atrophy, and eventually entirely disappear (Fig. 170).

The effects of veratrin poisoning are somewhat different. Here and there in the cell body of the neurone, tigroid masses disappear, leaving small cavities in the ground substance.

Whereas certain of the tigroid masses undergo this change, others remain apparently entirely unaffected, or are at most but slightly altered. In prolonged poisoning the ground substance




FIG. 170.—The effects of phosphorus poisoning upon the neurones. (After F. Nissl, *Allg. Ztschr. f. Psychiat.*, etc., Berl., Bd. liv, 1897.) The cell in the upper right-hand corner is normal; all the other cells show the effects of phosphorus poisoning.

may be involved, and the nucleus of the cell diminishes in size. Many of the cells present a diffuse staining, the limits of the Nissl bodies being but very indistinctly visible (Fig. 171).

For Nissl's findings in poisoning by silver, strychnine, morphine, tetanus, lead, and alcohol, the original publications of that author may be consulted.

Inasmuch as different poisons act upon the same variety of cell in a different way, and as the same poison can influence different types of cells in different ways, Nissl believes that we are thus afforded a new and important means of analyzing the functional activities of the different groups of cells inside the central nervous system. By administering elective poisons and comparing the clinical and psychological manifestations during life with the alterations in the cells after death, it may be possible to establish the function of the individual cell varieties and along with these the function of the various localities in which they are situated.



These views of Nissl are supported in the main by Lugaro, who has studied the alterations in the nerve cells after lead and arsenic poisoning.\* It is Lugaro's idea that the chromatic portion of the cell (Fig. 172) is the first to be affected by poisons, and that the alterations of the achromatic substance follow with a rapidity which depends upon the kind of poison and the type of cell concerned. Alterations of the chromatic part are reparable, but he doubts if this be true for the achromatic portion. The alterations in the periphery of the cell come on earliest; changes in the nucleus occur last, when the resistance of the cell has been exhausted. Changes in the dendrites he thinks succeed those in the cell body, a point of view in opposition to the position taken by Monti and Berkley. The changes in the spinal ganglion cells in arsenic intoxications, described by Lugaro, are pictured in Fig. 172.

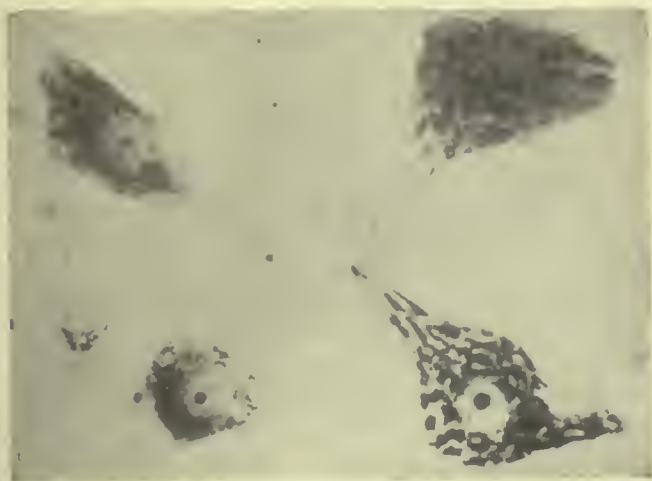


FIG. 171.—The effects of veratrin poisoning upon the neurones. (After F. Nissl, *Allg. Ztschr. f. Psychiat.*, etc., Berl., Bd. liv, 1897.) The cell in the lower right-hand corner is normal; the others show the effect of veratrin poisoning.

The effect of strychnine upon the lower motor neurones has been studied by Nissl, by Goldscheider and Flatau, and others. The changes are closely allied to those which are found in

\* Lugaro, E. Sulle alterazioni degli elementi nervosi negli avvelenamenti per arsenico e per piombo. *Riv. di patol. nerv.*, Firenze (1897), vol. ii, pp. 49-64.

tetanus poisoning. They may develop very quickly after the injection of the alkaloid, even as early as three minutes after subcutaneous injection. Alterations in the nucleoli precede those in the tigroid masses, according to Goldscheider and

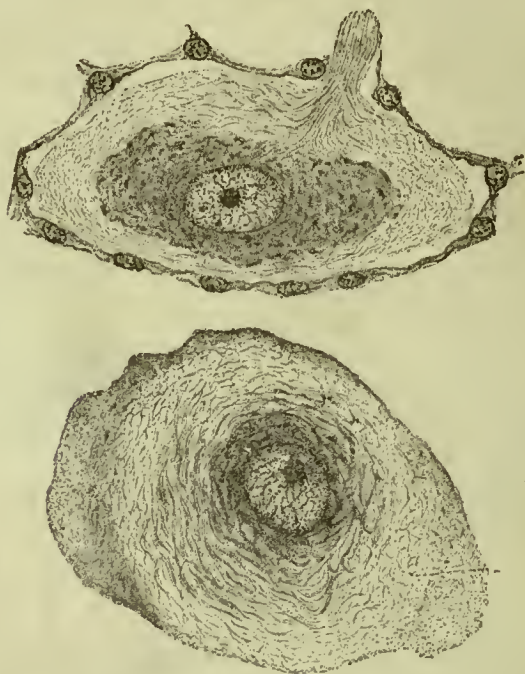

FIG. 172.—Two spinal ganglion cells showing peripheral chromatolysis in arsenical poisoning. (After E. Lugaro, *Riv. di patol. nerv.*, Firenze, vol. ii, 1897, p. 53, Figs. 2 and 3.) Sublimate fixation; hæmatoxylin staining.

Flatau. No distinct proportion could be established between the morphological alteration and the amount of functional disturbance. Functional disturbances were recovered from some time before the histological appearances had again become normal.

This absence of any strict proportionality between the visible morphological changes and the degree of functional disturbance is of the highest importance, and such incongruity should hold in check those zealous investigators who, without adequate data, are ready to interpret every histological finding in terms of the clinical symptomatology. As a matter of fact,

the alterations in the cells in acute and chronic poisoning, so far as they have been studied up to the present time, can scarcely be brought into relation with the clinical symptoms. The occurrence of Nissl's "acute cell disease" (*vide infra*) in a whole series of entirely different disease-pictures is further evidence of our lack of information with regard to the correspondence of the *demonstrable* histological alterations in the neurones and the symptoms met with during life. That the histological alterations have functional equivalents, however, no one can doubt, and other investigators have gone too far in denying the existence of any relation between the nerve-cell changes demonstrable in poisoning and the nervous disturbances met with during life. All that we can say at present is that the appearance and disappearance of the majority of the clinical symptoms are independent of the relatively gross intraneuronal structural alterations thus far described. The correspondence in all probability lies in the finer structural alterations indiscoverable by our present methods of examination, and will first be ascertainable when advances in technique permit of the application of procedures which reveal such finer changes.

Very important from a therapeutic standpoint are the investigations of Bräuer.\* This investigator studied the cell bodies of the neurones in the central nervous system of some twenty-three rabbits poisoned by mercury. Some of the animals were subjected to acute, others to subacute, still others to chronic poisoning with this metal. The poison was given by the mouth, subcutaneously and intravenously. In addition to the marked alterations in the kidneys and intestines distinct paralytic phenomena on the part of the nervous system soon became manifest. The paralysis gradually increased as the poisoning continued, the reflexes were exaggerated, and the animals exhibited an outspoken ataxia. Sections of the nervous system studied with Nissl's method showed large numbers of altered cells in the ventral horns. Among the altered cells there remained a considerable number which did not appear to be affected, although the relative proportions varied much in different animals. Very frequently Bräuer met with localized

---

\* Bräuer, L. Der Einfluss des Quecksilbers auf das Nervensystem des Kaninchens. Deutsche Ztschr. f. Nervenhe., Leipz., Bd. xii (1897), S. 1-67.

areas in individual cells in which tigroid bodies were beginning to break up. The fine particles became scattered through the ground substance, and the cell contents often presented a dust-like appearance. The bearing of such observations upon the treatment of syphilis is obvious.

It would take too long to consider all the reports of studies of intoxication even if only

those made recently were referred to.

Among the recent researches, those of Sarbó\* on anæmic alterations, Vas on

nicotine poisoning, Dehio on strychnine poisoning, Manersi on strychnine and chloroform poisoning, Berkley on alcoholic and ricin intoxications, Masetti† on antipyrine intoxication, of Pándi‡ on bromine, cocaine, nicotine, and antipyrine poisoning, Laslett and Warrington# on lead poisoning, Wright|| on bromide poisoning, Mourek and

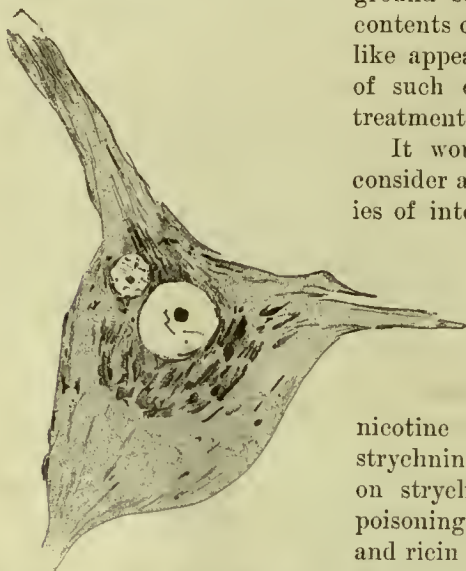


FIG. 173.—A nerve cell from a part of the spinal cord deprived of blood for six hours through ligature of the abdominal aorta. (After G. Marinesco, *La Presse médicale*, Par., 1897, p. 45, Pl. V.) The peripheral portion of the cytoplasm contains only a few tigroid masses, although the latter are still numerous near the nucleus.

\* Sarbó, A. Ueber die Rückenmarksveränderungen nach zeitweiliger Verschlussung der Bauchaorta; ein Beitrag zur Pathologie des Ganglionzellkerne. *Neurol. Centralbl.*, Leipz., Bd. xix (1894), S. 664-671.

† Masetti, E. Le alterazioni del midollo spinale nell'avvelenamento cronico sperimentale per antipirina. *Riv. sper. di freniat.*, Reggio-Emilia, vol. xxi (1895), pp. 668-677.

‡ Pándi, K. Ueber die Veränderungen des Centralnervensystems nach chronischer Vergiftung mit Brom, Kokain, Nikotin und Antipyrin. *Ungar. Arch. f. Med.*, Wiesb., Bd. ii (1893-'94), S. 257-284.

# Laslett, E. E., and W. B. Warrington. The Morbid Anatomy of a Case of Lead Paralysis. Condition of the Nerves, Muscles, Spindles, and Spinal Cord. *Brain*, Lond., vol. xxi (1898), pp. 224-231.

|| Wright, H. K. The Cerebral Cortical Cell under the Influence of Poisonous Doses of Potassii Bromidum. *Brain*, Lond., vol. xxi (1898), pp. 186-223.



Hess\* on the effects of various poisons, should be mentioned. The effect of cutting off the blood supply to the neurones is illustrated in Fig. 173.

There exists also a series of researches upon acute and chronic infectious processes, those experimentally produced and those occurring in nature. Among these may be mentioned the studies of Babes,† Beck,‡ Dejerine,\* Ewing,|| Goldscheider and Brasch,^ Goldscheider and Flatau,◇ Lugaro,‡ Nicholls,‡ Sabrazes and Cabannes,‡ Marinesco.\*\*

A beginning has been made in the study of acute and chronic degenerative processes in human beings and in animals, some of known and some of doubtful origin: The researches of Acquisti and Pusateri,†† Ballet,‡‡ Ballet and

---

\* Mourek, J., et P. Hess. Lésions fines des cellules motrices de la moelle épinière dans les divers états d'empoisonnement. *Rev. neurol., Par.*, t. v. (1897), No. 23.

† Babes, V. Ueber den Einfluss der verschiedenen Infectionen auf die Nervenzellen des Rückenmarks. *Berl. klin. Wehnschr.*, Bd. xxxv (1898), S. 6; 36: 56.

‡ Beck, A. Die Veränderungen der Nervenzellen beim experimentellen Tetanus. *Orvosi hetil.*, Budapest, vol. xxxvii (1893), No. 32. Ref. in *Neurol. Centralbl.*, Leipz., Bd. xiii (1894), No. 24.

\* Dejerine, J. Sur la chromatolyse de la cellule nerveuse au cours des infections avec hyperthermie. *Compt. rend. Soc. de biol., Par.*, 10. s., t. iv (1897), p. 728.

| Ewing, J. Studies on Ganglion Cells; a Preliminary Communication. *Med. Rec.*, N. Y., vol. liii (1898), pp. 513-517.

^ Goldscheider, A., und F. Brasch. Ueber die Veränderung menschlicher Nervenzellen beim Fieber. *Fortschr. d. Med.*, Berl., Bd. xvi (1898), S. 126-128.

◇ Goldscheider, A., und E. Flatau. Normale und pathologische Anatomie der Nervenzellen auf Grund der neueren Forschungen. Berlin (1898).

‡ Lugaro, E. Alterazioni delle cellule nervose nella peste bubbonica sperimentale. *Riv. di patol. nerv.*, Firenze, vol. ii (1897), pp. 241-244.

‡ Nicholls, J. Studies of Typhoid Fever. *J. Exper. Med.*, N. Y., vol. iv (1899).

‡ Sabrazès, J., et C. Cabannes. Note sur les lésions des cellules nerveuses de la moelle dans la rage humaine. *N. iconog. de la Salpêtrière*, Par., t. x (1897), pp. 155-165.

\*\* Marinesco, G. Sur les lésions du système nerveux central au cours des maladies infectieuses. *Compt. rend. Soc. de biol., Par.*, 10. s., t. iv (1897), pp. 795-798.

†† Acquisti, V., ed. E. Pusateri. Sull' anatomia patologia degli elementi nervosi nell' uremia acuta sperimentale. *Riv. di patol. nerv.*, Firenze, vol. i (1896), pp. 377-385.

‡‡ Ballet, G. Les lésions cérébrales de la paralysie générale étudiées par la méthode de Nissl. *Ann. méd.-psychol.*, Par., 8. s., t. vii (1898), pp. 448-459.

Dutil,\* Boedeker and Juliusburger,† Cramer,‡ Dejerine and Thomas,# Friedmann,|| Marinresco,^ Monti,◇ Popoff,‡ Hoch,‡ Quervain,‡ Sacerdotti and Ottolenghi,\*\* Schaffer,†† Lugaro and Chiozzi,‡‡ Soukhanoff,\*\* and Stroebe.||||

\* Ballet et Dutil. Sur quelques lésions expérimentales de la cellule nerveuse. XIIth Internat. medic. Congr. zu Moskau. Neurolog. Centralbl., Leipz., Bd. xvi (1897), S. 915-916.

† Boedeker und Juliusburger. Anatomische Befunde bei Dementia paralytica. Neurol. Centralbl., Leipz., Bd. xvi (1897), S. 774-779.

‡ Cramer, A. Pathologisch-anatomischer Befund in einem acuten Falle der Paranoiegruppe. Arch. f. Psychiat. u. Nervenkr., Berl., Bd. xxix (1896), S. 1-24.

# Dejerine et Thomas. Sur l'absence d'altérations des cellules nerveuses de la moelle épinière dans un cas de paralysie alcoolique. Compt. rend. Soc. de biol., Par., 10 s. (1897).

|| Friedmann, M. Ueber progressive Veränderungen der Ganglienzellen bei Entzündungen, nebst einem Anhang über active Veränderungen der Axencylinder. Arch. f. Psychiat., etc., Berl., Bd. xix (1887), S. 244-268.

^ Marinresco. Pathologie de la cellule nerveuse. Rapport présenté au congrès international de médecine à Moscou. Paris (1897).

◇ Monti, A. Sur l'anatomie pathologique des éléments nerveux dans les processus provenant d'embolisme cérébral; considérations sur la signification physiologique des prolongements protoplasmiques des cellules nerveuses. Arch. ital. de biol., Turin, t. xxiv (1895-'96), pp. 20-33.

‡ Popow, N. Arch. f. path. Anat., etc., Berl., Bd. xciii (1883), S. 351-366.

‡ Hoch, A. On Changes in the Nerve Cells of the Cortex in a Case of Acute Delirium and a Case of Delirium Tremens. Am. J. Insan., Balt., vol. liv (1897), pp. 589-606.

‡ de Quervain, F. Ueber die Veränderungen des Centralnervensystems bei experimenteller Kachexia thyreopriva der Thiere. Arch. f. path. Anat., etc., Berl., Bd. exxxiii (1893), S. 481-550.

\*\* Sacerdotti, C., e D. Ottolenghi. Sulle alterazioni degli elementi nervosi nella diserasia uremica sperimentale. Riv. di patol. nerv., Firenze, vol. ii (1897), S. 1-8.

†† Schaffer, K. Ueber Nervenzellveränderungen während der Inanition. Neurol. Centralbl., Leipz., Bd. xvi (1897), S. 832-837; also Das Verhalten der Spinalganglienzellen bei Tabes auf Grund Nissl's Färbung. Neurol. Centralbl., Leipz., Bd. xvii (1898), S. 2-7; also Ueber Nervenzellenveränderungen des Vorderhorns bei Tabes. Ein Beitrag zur Pathogenese der trophischen Störungen der Tabes. Monatschr. f. Psychiat. u. Neurol., Berl., Bd. iii (1898), S. 64-98.

‡‡ Lugaro, E., e L. Chiozzi. Sulle alterazioni degli elementi nervosi nell' inanizione. Riv. di patol. nerv., Firenze, vol. ii (1897), pp. 394-400.

\*\* Soukhanoff, S. Sur l'histologie pathologique de la polynévrite dans ses rapports avec les lésions de la cellule nerveuse. N. iconog. de la Salpêtrière, Par., t. x (1897), pp. 347-354.

|| Stroebe, H. Ueber Veränderungen der Spinalganglien bei Tabes dorsalis. Centralbl. f. allg. Path. und path. Anat., Jena, Bd. v (1894), S. 853-855.

In the investigation into the changes in the human cerebral cortex no one has thus far had so much experience as Franz Nissl. In a recent paper\* he distinguishes seven forms of alterations in the cells of the human cortex: (1) Acute cell disease; (2) chronic cell disease; (3) severe cell disease; (4) combined disease forms; (5) vanishing of cell; (6) simple rarefaction; (7) granular breaking up of the cell.†

Nissl lays much emphasis upon the first of these forms, the so-called acute cell disease. According to him it runs the same course in every instance, having always the same termination, and when it has once appeared it involves all the cells of the cortex without exception. The changes are so characteristic that, after once seeing them, one can make a positive diagnosis without difficulty. The disease does not affect a part of the cell only but involves the whole neurone, the stainable as well as the unstainable substance, the nucleus as well as the cell body, the axone as well as the dendrites, all parts being involved apparently in the same degree. In this form of neurone change the unstainable substances are so altered that they become stainable, a fact which makes Nissl think that his "unstable substance" consists not only of a fibrillary constituent, but, in addition, of one or several other substances.

Nissl finds this acute cell disease not only in acute paralyses but in a great variety of psychoses, and also in patients who have not been the subjects of mental disease in the ordinary sense, but who, succumbing to various disorders, have before death been partly delirious, partly somnolent. The involvement of all the cells in the cortex is an exceedingly interesting feature, and one met with rarely in any other form of disease.

An instructive paper dealing with the alterations discoverable by Nissl's method in the human cortex is that of August Hoch,‡ of the McLean Hospital, Waverly, Mass. Working in

\* Nissl, F. Nervenzellen und graue Substanz. Münch. med. Wehnschr., Bd. xlv (1898), S. 988; 1023; 1060.

† In this country Hoch (Hoch, A. On Changes in the Nerve Cells of the Cortex in a Case of Acute Delirium and a Case of Delirium Tremens. Am. J. Insan., Balt., vol. liv (1897), pp. 589-606) has described one case in which the "acute cell disease" (*acute Veränderung*) and another in which the "severe cell disease" (*schwere Veränderung*) of Nissl existed. His descriptions of the changes are the fullest and most accurate in the English language.

‡ Hoch, A. Nerve-Cell Changes in Somatic Diseases. A Preliminary Communication. Am. J. Insan., Balt., vol. lv (1898), pp. 231-240.

Nissl's laboratory at Heidelberg, Hoch had been impressed with the frequency with which changes were found in the cortical nerve cells in individuals dead of diseases of different kinds. Recognizing the importance of a thorough knowledge of the possible changes in the cells in somatic disease for the interpretation of the pathological alterations met with in the brains of the insane, Hoch directed his especial attention toward these. In the paper mentioned he deals with a particular cell alteration, which he designates "cell shrinkage." He has studied this change in human beings, in whom it occurs in the most diverse diseases, and also in experimental animals.

This alteration in the cells, as he describes it, is found chiefly in the medium-sized and smallest pyramids, as well as in the cells of the fifth layer. The contour of the neurone is distorted and shrunken, and there may be much retraction of the borders of the cell body between the processes, so that a part of the cell body may, at first sight, look like part of a cell process. A well-marked honeycomb structure is visible in the cell body, and is sometimes indicated in the processes. The nucleus is darkly stained, diminished in size, and often distorted. In Nissl preparations it looks homogeneous; the nucleolus is often oval in shape, and may be paler than normal, but never shows a purplish hue. Instead of the honeycomb appearance, the protoplasm may be "crumbly-looking."

While these changes occur in the smaller pyramids and the cells in the fifth layer and in a few of the larger pyramids, Hoch finds a very different appearance in most of the larger pyramidal cells and especially in the largest pyramids (not the motor or Betz cells). There may be but little alteration in the external form of the cell body, but there is marked change in the distribution of the stainable substance throughout the cell. The stainable substance is seen at the base and at the sides of the pyramid, sometimes forming a rim around the periphery of the cell; often this rim is not continuous but consists of a number of separate "crumbly" portions. The basal processes are much more altered than the large apical dendrite, especially in the larger cells. The alterations in the nucleus are very characteristic. No nuclear membrane can be demonstrated, and the interior of the nucleus shows no trace of a sharp design, in Nissl preparations frequently looking entirely homogeneous. The nucleolus is, however, unaltered. The change just described



Hoch designates "alteration with rarefaction around the nucleus."

As a rule the large motor cells look entirely normal.

In two of his cases Hoch met with an alteration in which the cells may be compared to vesicles. Around the nucleus he found a narrow rim of "crumbly-looking" substance, then a clear area, and at the periphery of the cell body another accumulation of "crumbly-looking" substance. There may be a marked accumulation of the stainable substance at the site of origin of a basal process. The nucleus in such cells varies much in appearance; sometimes it may be homogeneous; it may be pale; it may be indistinctly spotted, or sometimes it may look almost normal. The feature common to these cells is the vesicular, balloonlike appearance of the defective cell body. The cells exhibiting this alteration were met with only in the upper layers of the cerebral cortex.

It struck Hoch that the vesicles may be due to œdema, and he accordingly experimented on the cortex of the rabbit. A piece of a rabbit's brain immediately after decapitation was placed in distilled water for from twelve to twenty-four hours and then hardened in alcohol. Another piece was treated with normal salt solution and subsequently hardened in alcohol. The cortex treated with water showed by Nissl's method typical "vesicular cells," while the cortex treated with normal salt solution showed cells which corresponded in every detail with the typical "cell-shrinkage." Experiments on the human cortex obtained from healthy individuals at autopsy, so far as they went, confirmed the results obtained in the rabbit. Hoch was not able to produce experimentally his "alteration with rarefaction around the nucleus."

Hoch concludes that œdema is an important factor in the production of vesicular cells. He points out in his article the importance, however, of bearing in mind the possible appearance of artefacts due to the action of alcohol upon the tissues. It may be that the modification of Nissl's method recommended by Lord \* will be of service in the exclusion of such artefacts,

---

\* Lord, J. R. A New Nissl Method; Normal Cell Structure and the Cytological Changes terminating in Fatty Degeneration; some Remarks on Cell Physiology and its Relation to Insanity; a Note on the Use of Picroformal Generally, and in Bevan Lewis's Fresh Method. *J. Ment. Se., Lond.*, vol. xliv (1898), pp. 693-700.

since in his procedure, as in that of Bevan Lewis, frozen sections are employed and alcohol fixation is avoided.

There would appear to be some ground for believing that a study of the changes in the nerve cells enables us to distinguish between the microscopie picture of the cell body of a neurone after a lesion to its axone and that which results from the direct action of toxic substances upon the cell body of the neurone.

We now know very well the appearances of the corresponding ventral horn cells of the spinal cord and medulla after sec-

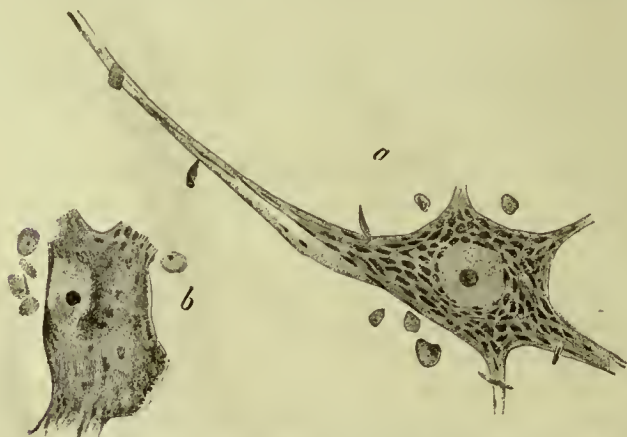


FIG. 174.—Cells from the nuclei of the oculomotorius nerves of the cat thirteen days after section of the root fibres of the nerve on one side. (After E. Flatau, *Fortschr. d. Med.*, Berl., Bd. xiv, 1896, Taf. i, Figs. 3 and 4.) *a*, cell from nucleus of side not operated upon, showing typical stichochrome arrangement of Nissl bodies; *b*, cell from nucleus of side operated upon. The homogeneous dustlike appearance is represented. Here and there single larger irregular Nissl bodies are visible. The nucleus is displaced to the side of the cell.

tion of the axones of a motor nerve (*vide supra*). After a short time the cell bodies of the group of neurones concerned appear somewhat swollen and there are marked changes in the appearance of the protoplasm, most advanced near the axone hillock. These changes consist, as has already been stated, in a breaking up into fine granules of the tigroid masses with diffuse staining of the achromatic substance of the cell. If the changes be very marked, as is often the case in young animals, the tigroid masses may disappear from a large portion of the cell body and the nucleus may be displaced to the side of the cell. As a

result, the typical stichochrome arrangement of the tigroid aggregations inside the body of the cell is entirely lost, in late stages in the dendrites also, and what stainable substance is left appears in the form of fine dustlike particles or as a diffuse blue stain (Fig. 174). These secondary changes in the cell bodies of neurones, the evidence of "reaction at a distance," may lead to the death of the cell in case the peripheral connection can not be again made, although more often after a certain length of time there is a gradual restitution of the normal appearances, due, Nissl thinks, to the formation of new connections. According to Marinesco, there occurs during the process of repair progressive hypertrophy of the nerve cell up to a period as late as ninety days after the operation. He believes that this increase in size of the nerve cell is for the purpose of assisting in the repair of the lesions in the divided nerve, and that complete return of function occurs only after the anatomical continuity of the peripheral nerve has been re-established.

The changes in the cell bodies following the direct action of toxic substances upon them differ, as a rule, markedly from those just described. Without going into a detailed description here it may be pointed out that the chromatolysis under these circumstances begins, as a rule, not inside the cell but rather at the periphery of the cell body and in the dendrites, extending gradually toward the nucleus. Marinesco\* has laid great stress upon this point, and has brought forward in evidence the changes which occur in experimental anæmia after ligation of the aorta (Fig. 173, *vide supra*), in hydrophobia, in acute experimental uræmia, and in other conditions. He states also that in addition to peripheral chromatolysis in primary lesions of the nerve cell, instances are met with in which the chromatolysis is diffuse and others in which it is perinuclear.

My own studies, made on several forms of intoxication with mineral poisons, on cerebro-spinal meningitis (Fig. 175), and, in conjunction with J. Erlanger, on the facial nucleus of rabbits after section of the facial nerve (Fig. 176), and on the motor cells in the ventral horns of the spinal cord after extirpation of the biceps muscle, so far as they have gone, support these views,

---

\* Marinesco, G. Pathologie générale de la cellule nerveuse; lésions secondaires et primitives. Presse méd., Par. (1897). pp. 41-47.

although with certain modifications and reservations. The main emphasis in the "secondary" lesion is to be laid upon the fact that the process begins near the axone hillock. Less importance is to be attributed to the peripheral chromatolysis in the

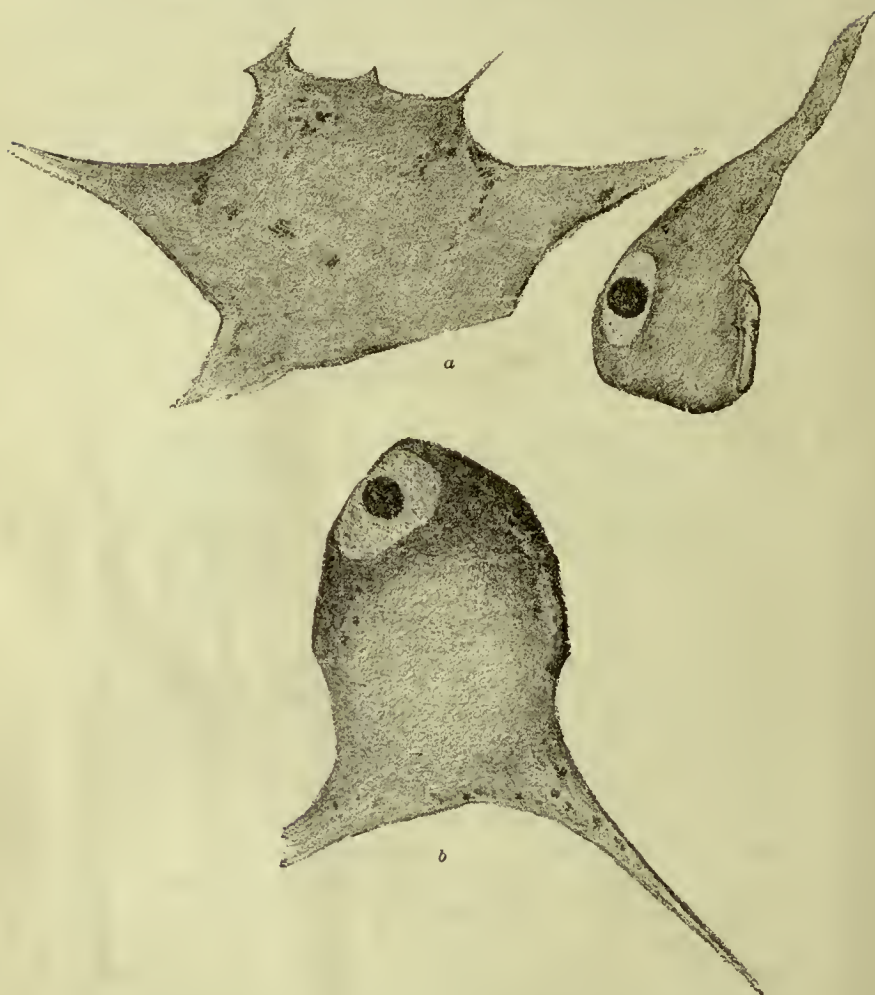


FIG. 175.—Cells from the human spinal cord in epidemic cerebro-spinal meningitis. *a*, two cells from the ventral horn. The nucleus of one of them is not visible; that of the other is displaced to the side of the cell. Marked disorganization of the stainable substance of Nissl, the secondary result of the involvement of the ventral roots by the meningeal inflammation. *b*, cell from the nucleus dorsalis showing alterations which result from a lesion of the axone of the cell.



“primary” lesion, since in ricin poisoning,\* for example, changes may have occurred in the Nissl bodies throughout the cell body at a very early period, even before there is actual chromatolysis. In the study of the pathological anatomy of human cases the

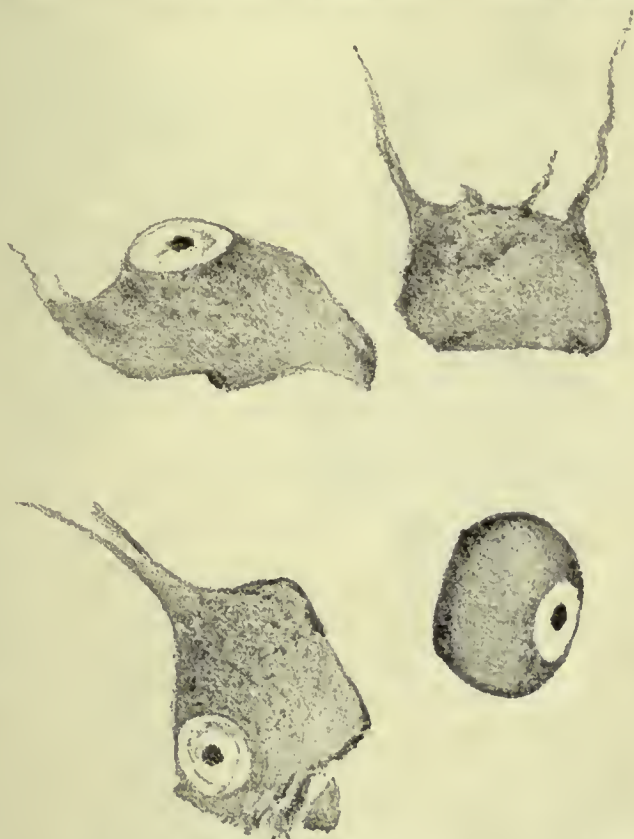


FIG. 176.—Four nerve cells from the nucleus nervi facialis of a rabbit fifteen days after section of the nerve root. Drawing made from one of J. Erlanger's preparations.

results of such investigations should at all events be borne carefully in mind, and it will be the duty of the pathologist to endeavor to distinguish in the various forms of nerve lesion the alterations which depend upon “reaction at a distance” from

---

\* Studied in tissues of experimental animals kindly supplied by my colleague, Dr. S. Flexner.

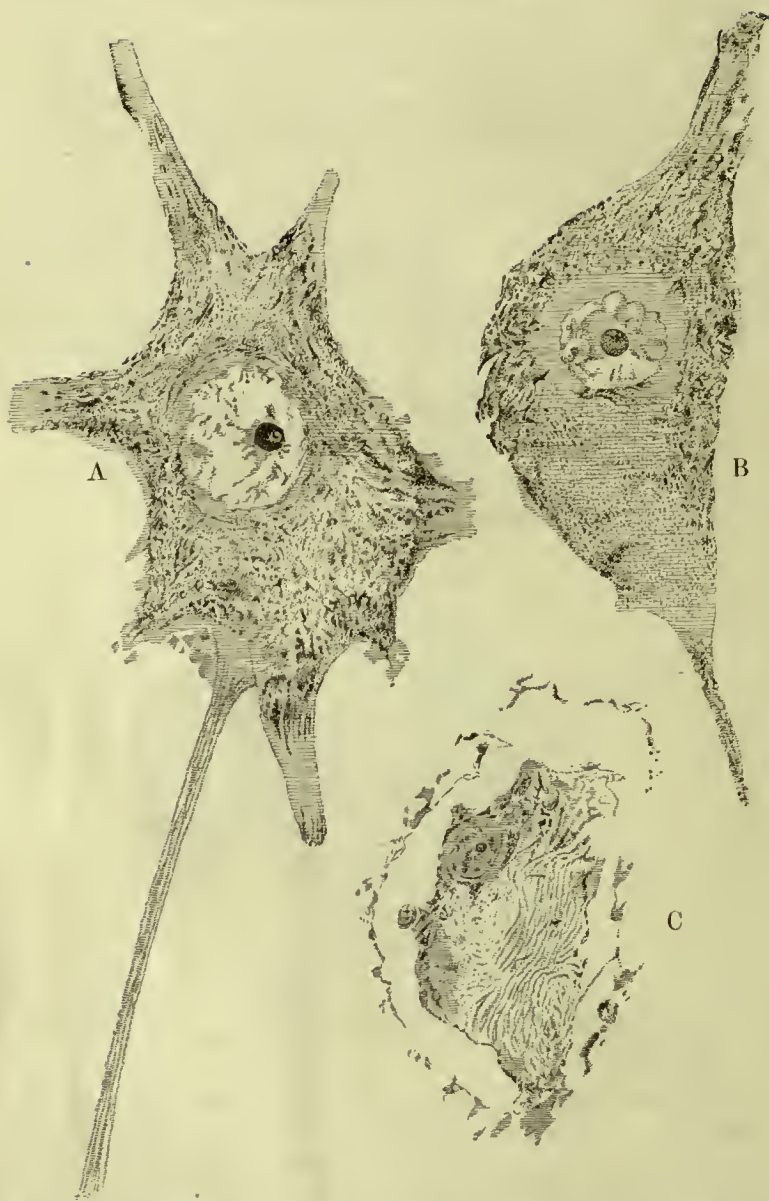


FIG. 177.—Similarity of changes produced in cell bodies of lower motor neurones (1) by cutting the axone and (2) by cutting the corresponding dorsal roots. (After W. B. Warrington, *J. Physiol.*, Cambr., vol. xxiii, 1898, pl. i, Figs. 1, 2, and 3.) A, a normal cell of the ventral horn; B, ventral horn cell fourteen days after section of corresponding ventral root; C, cell from dorso-lateral group of ventral horn twenty-three days after section of several dorsal roots of the cauda equina.

those which are the result of the direct action of noxæ in solution in the blood and lymph upon the cell bodies and dendrites of the neurones. In certain pathological conditions the neurone may doubtless be affected in both ways simultaneously. I have found this to be true in epidemic cerebro-spinal meningitis.

The lesions in this disease in the cells of the ventral horns are in part those of reaction at a distance, in part those of primary intoxication of the nerve cell. I am of the opinion that the former set of lesions which by the way are by far the more pronounced are the result of injury to the motor roots by the meningeal inflammation, the latter to the general toxic effect of the poisons produced by the bacteria which cause the disease.

Highly interesting in this connection are the results obtained by Warrington,\* of Liverpool. He has cut the dorsal roots of spinal nerves from the fifth to the ninth thoracic inclusive, and studied sections of the various segments of the cord by Nissl's method. He found alterations in a large number of cells in the seventh and eighth segments, especially in the dorso-lateral group of cells in those segments. In the monkey a great many cells are found altered on the opposite side. The alterations, as will be seen in Fig. 177, are similar to the changes which result when the axones of these cells are cut. Warrington attributes the change to the withdrawal of the afferent impulses which normally impinge on the cornual cells, and compares his results with those obtained from the well-known experiments of Mott and Sherrington,† by which it was shown that section of the dorsal roots leads to pronounced loss of muscular tone, ataxia, and marked impairment of voluntary movement. These studies of Warrington, taken with those of Marinesco and van Gehuchten,‡ should make us keep in view the possibility that the lesion hitherto supposed to be typical of

---

\* Warrington, W. B. On the Structural Alterations observed in Nerve Cells. *J. Physiol.*, Cambridge, vol. xxiii (1898), pp. 112-129.

† Mott, P. W., and C. S. Sherrington. Experiments upon the Influence of Sensory Nerves upon Movement and Nutrition of the Limbs. *Proc. Roy. Soc. Lond.*, vol. lvii (1895), pp. 345-481.

‡ Van Gehuchten, A. L'anatomie fine de la cellule nerveuse. XIIth Congrès international de médecine à Moscou 1897. Refer. in *Neurol. Centralbl.*, Leipz., Bd. xvi (1897), No. 19.

a reaction at a distance due to lesion of an axone may depend upon an entirely different cause—namely, the removal of afferent impulses from the dendrites and cell bodies of the neurones concerned.

An interesting problem for research in connection with intoxications has probably already suggested itself to the minds of many. If soluble toxic substances are capable of producing within a comparatively short period of time alterations within the neurones which are histologically recognizable, the question arises, What will be the effect of administering a specific antitoxine at the same time as, or subsequently to, the introduction of

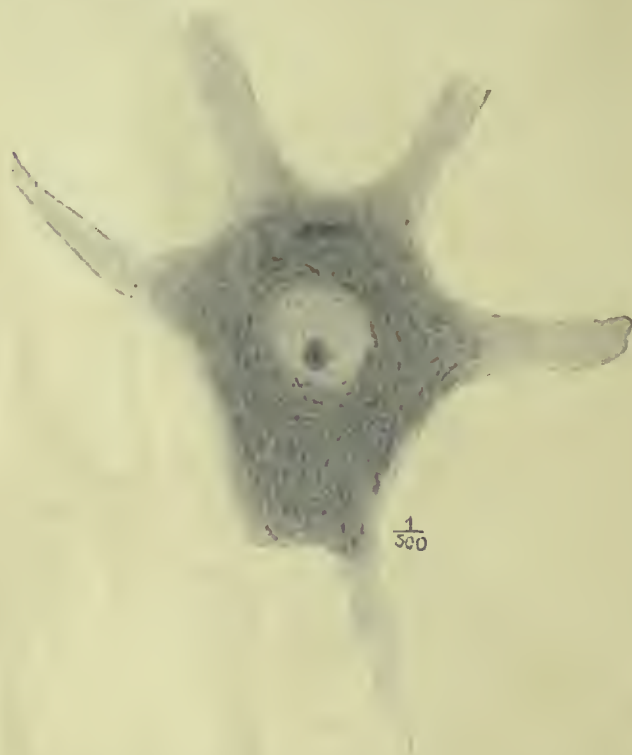

FIG. 178.—Effects of poisoning with malon-nitril. (After A. Goldscheider u. E. Flatau, *Normale und pathologische Anatomie der Nervenzellen*, etc., Berl., 1898, Taf. iv, Fig. 1.)

the toxic substance? At the date of writing only a few researches which have a direct bearing upon this topic have been made—



namely, those of Goldscheider and Flatau\* upon poisoning with malon-nitril and upon tetanus poisoning, those of Mari-



FIG. 179.—Effects of artificial increase of body temperature. (After A. Goldscheider u. E. Flatau, *Normale und pathologische Anatomie der Nervenzellen*, etc., Berl., 1898, Taf. iv, Fig. 2.) A ventral horn cell of the lateral group is shown.

nesco and Chantemesse † upon tetanus toxine and antitoxine, and of Kempner and Pollack ‡ on botulismus poisoning. It is

\* Goldscheider, A. und E. Flatau. Kenntniss der Structur der Ganglienzellen (Vortrag von Goldscheider), Verein für innere Medecin. Berl. klin. Wehnschr. (1897), S. 237. Also, *Normale und pathologische Anatomie der Nervenzellen*, Berlin, 1898.

† Chantemesse et Marinesco. Des lésions histologiques fixes de la cellule nerveuse dans leurs rapports avec le développement du tétanos et l'immunité anti-tétanique [Abstr.]. Bull. et mém. Soc. méd. d. hôp. de Par., 3. s., t. xv (1898), pp. 96–104.

‡ Kempner, W. und B. Pollack. Die Wirkung des Botulismustoxins (Fleischgiftes) und seines specifischen Antitoxins auf die Nervenzellen. Deutsche med. Wehnschr., Leipz. u. Berl., Bd. xxiii (1897), S. 505–507.

known that if malon-nitril be injected into a rabbit, hydrocyanic poisoning quickly results, leading to the death of the animal, after from twenty to thirty minutes, with paralytic and dyspnoic phenomena. If, however, the animal has been injected a few minutes before with a solution of hyposulphite of soda it quickly stirs about and recovers. It is supposed that the sodic salt acts as an antidote by giving off sulphur which unites with the cyanogen radicle. In animals killed with malon-nitril distinct alterations in the Nissl bodies can be made out (Fig. 178). In animals treated with the two substances and killed after nineteen hours certain alterations in structure are still apparent, though after seventy-one hours the cells are again normal. Goldscheider and Flatau have compared the findings in such instances with those resulting from the artificial heating of animals in the thermostat up to  $43^{\circ}$  or  $44^{\circ}$ . If the animal be taken out before death it is flaccid and incapable of moving. The ventral horn cells of the cord examined at this period are seen to have lost their normal structure; the tigroid bodies are replaced by light-brown opaque masses and by single granules, the whole cell being enlarged and the dendrites swollen (Fig. 179). If the overheated animals be removed from the thermostat and kept alive, gradual restitution of the normal structure can be made out after several hours (Fig. 180), though the repair in the cells is not so rapid as the reappearance of function would lead one to believe. While the animals appear to recover very quickly from the symptoms, the regeneration of the cells after the nutritive disturbance requires for completion at least several days. It is evident, therefore, that changes in the chromatic substance alone, as many have long suspected, do not suffice to account for the clinical phenomena associated with them. All the evidence goes to prove that the function of the cell, as has already been pointed out in Section III, must be intimately associated with the integrity of what we call the achromatic substance.

Marinesco and Chantemesse have studied guinea-pigs injected with tetanus toxine with the object of investigating the relation of immunity to histological alterations in the cells. After injection of the toxine alone they found typical alterations in the cells of the ventral horns, quite like those which have been described by Nissl, Goldscheider and Flatau, and others (Figs. 181, 182). After injection of tetanus toxine and antitoxine they could find no alterations in the cells after three days, but if the anti-

toxic serum were not injected until twenty-four hours after the injection of toxine, distinct alterations in the cell bodies of the neurones could still be made out, although it is stated that these were less marked than when the toxine alone had been injected.

The various changes in the nucleus and nucleoli, to which considerable attention has been already directed by a number of investigators, afford, to a certain extent, valuable information concerning the state of nutrition of the cell, but they must here be passed over without further comment.

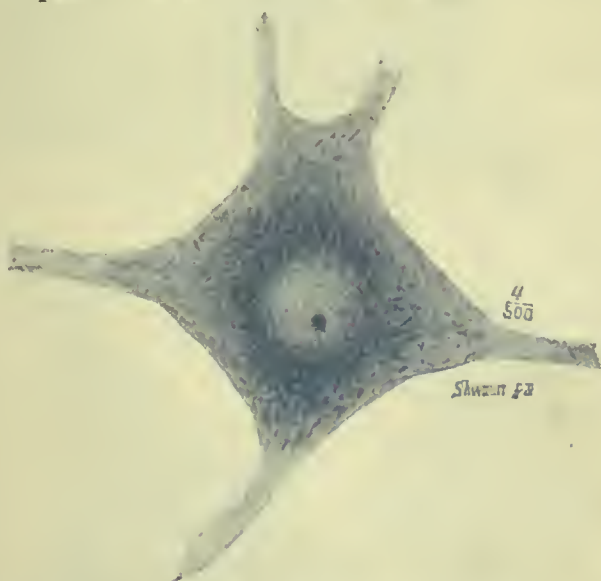

FIG. 180.—Recovery of ventral horn cell from changes produced by artificial increase of body temperature. (After Goldscheider and Flatau, *Normale und pathologische Anatomie der Nervenzellen*, etc., Berl., 1898, Taf. v, Fig. 2.) The figure shows a ventral horn cell of the lateral group after eight hours and a half of restitution.

A warning concerning the necessity for obtaining very fresh material when Nissl's method is to be employed for studying pathological alterations may not be superfluous. Not only may lesions in nerve cells change in appearance in pathological cases a short time after death (Marinesco), but normal cells may by post-mortem alterations come to resemble those altered as the result of disease. We have to thank Neppi,\* of Tram-

\* Neppi, A. Sulle alterazioni cadaveriche delle cellule nervose rilevabili col metodo di Nissl. *Riv. di patol. nerv.*, Firenze, vol. ii (1897), pp. 152-155.

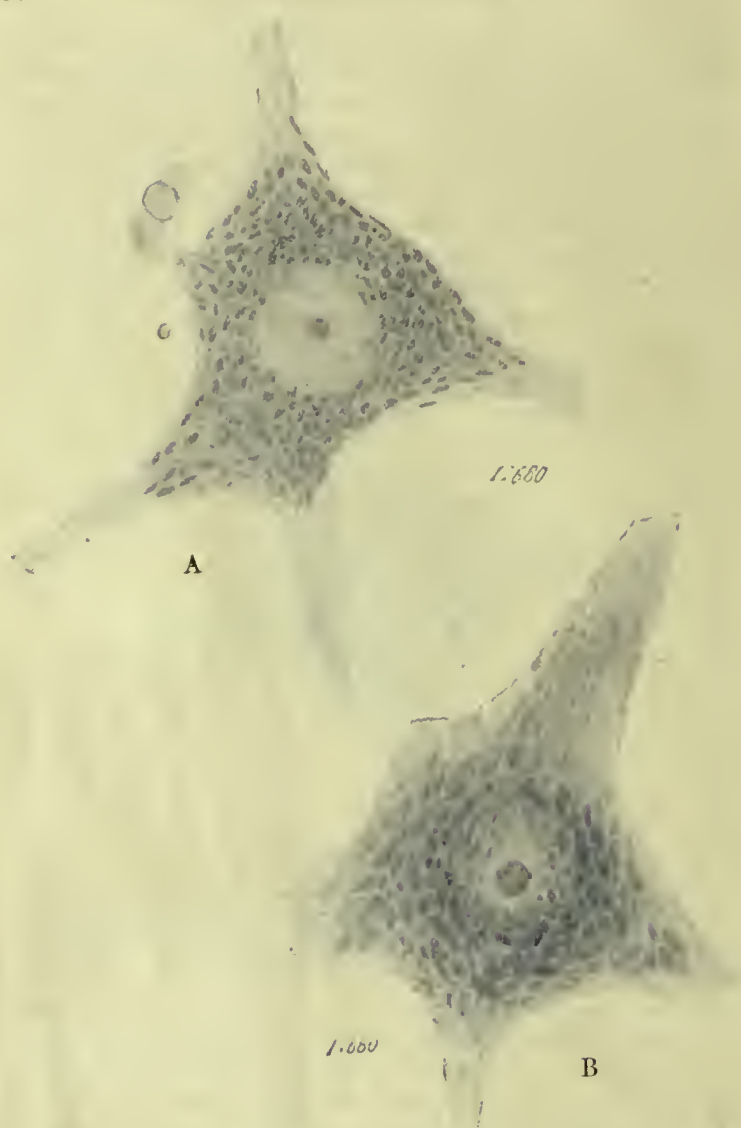

FIG. 181.—Effects of tetanus toxin upon the lower motor neurones. (After Goldscheider and Flatau, *Normale und pathologische Anatomie der Nervenzellen*, etc., Berl., 1898, Taf. vi, Figs. 1 and 2.) A, normal motor ventral horn cell of the rabbit, showing typical structure as demonstrated by Nissl's method. B, ventral horn cell two hours after intravenous injection of 0.04 (1 cm., 4-per-cent. solution) tetanus toxin. The nucleolus is swollen and of a lighter color than normal. The tigroid masses are swollen and somewhat pale, though the arrangement is well preserved.



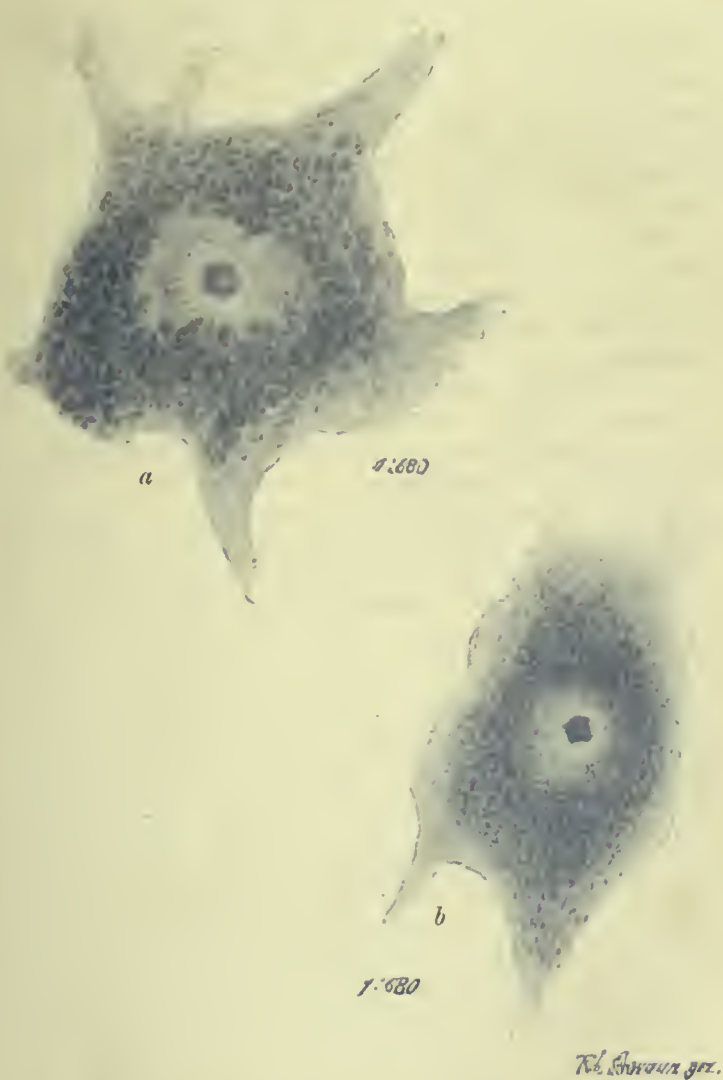


FIG. 182.—More advanced stages of poisoning with tetanus toxine. (After Goldscheider and Flatau, *Normale und pathologische Anatomie der Nervenzellen*, etc., Berl., 1898, Taf. vii, Figs. 1 and 2.) *a*, nerve cell from an animal five days after an injection of 0.0016 (1 cem., solution 1:600) tetanus toxine. The nucleolus is markedly swollen; the tigroid bodies are also much swollen, and are manifestly breaking up and are becoming intermingled. *b*, nerve cell from an animal twenty-one hours and a quarter after injection of 0.04 (1 cem., 4-per-cent. solution) tetanus toxine. The nucleolus is deformed. The tigroid masses show the finely granular disintegration.

busti's laboratory, for a report on the changes, revealed by Nissl's method, which take place post mortem in normal nerve cells.

Since Neppi's article another on the same subject has appeared by Barbacci and Campacci.\* A. Hoch states that the Betz cells of the paracentral lobule are very resistant to post-mortem alteration.

None of the methods at present at our disposal suffice, however, for more than the discovery of what must be relatively extremely gross alterations in the structure of the nerve cells, and we can only hope that ere long advances in cytological technique will permit a deeper penetration into the mysteries of nerve-cell organization.

These considerations bearing upon the physiology and pathology of the neurone have led me further than I had intended; they must now be brought to a close. A series of phenomena have been touched upon, all too briefly, I fear, to do justice to them—Wallerian and Türck's degeneration, the changes in the nerve centres following amputations, the experiments of von Gudden, Bregman, Darkschewitsch, Nissl, and Flatau, the effects of injury to the nerve centres through cutting off of the blood supply, the effects of acute and chronic poisonings of the neurones, the phenomena of regeneration, the incessant activity of the nervous structures, the absence of proof of any actual spontaneity in the elements, the doctrine of the specific energies of nerves, the unity of nerve functions in the neurones, the direction in which impulses are transmitted, and the influence of activity, fatigue, repose, poisoning, etc., upon the structure of the nerve-cell protoplasm. This cursory glance, however, over many phases of the metabolic and nervous activities of the neurones may have sufficed, I hope, to throw the essential points concerning the nutrition of neurones into relief. The changes characteristic of the degenerations of Waller and of Türck prove to us that no matter how important the medullary sheath may be in the integrity of the neurone for the nutrition of the axone inside it, it is certain that this influence alone or together with that of the nutrient supplies arriving through the nodes of Ranvier can not suffice for the maintenance of the

---

\* Barbacci, O., e G. Campacci. Sulle lesioni cadaveriche delle cellule nervose. Riv. di patol. nerv., Firenze, vol. ii (1897), pp. 337-347.

health of the nerve fibre. There is not a little evidence, indeed, favoring the view that the medullary sheath depends for its nourishment upon the axone, rather than that the axone is nourished from the medullary sheath. Some influence or influences from the rest of the neurone, particularly from the cell body, are essential to the well-being of the nerve fibres. What is the nature of this influence or of these influences? Does the axone actually receive all its nutrient material from the ganglion cell, or does it depend, as would seem *a priori* much more likely, for the most part upon autochthonous metabolism, needing only the influence of the cell to which it is connected to govern the assimilation? These are questions for which the data at command do not permit as full answers as we could wish. Every one must grant that the peripheral nerve fibre takes care in large part of its own nutrition; the presence of vasa nervorum affords sufficient warrant for this belief. Further, the evidence for its subordination to local processes of diffusion is to be found in the local injuries to peripheral nerves resulting from the circulation in the blood of soluble substances of a toxic nature—as, for example, in diphtheria. The key to the whole problem undoubtedly lies, as the neurone concept teaches, in the fact that the axone in all its parts, no matter how far removed from the cell body, is an integral part of a single cell. To explain the influence of the cell body upon the fibre, Goldscheider has advanced a very ingenious hypothesis. He suggests that it is most probable that there is an actual transport of a material, perhaps a fermentlike substance, from the cell along the whole course of the axone to its extremity, and that first through the influence of this chemical body the axone is enabled to make use for its nutrition of the material placed at its disposal in its anatomical course. Schäfer sees in the loss of the influence of the nucleus the important factor in cellulifugal degeneration of a severed nerve fibre, but attempts no explanation of the nature of the nuclear power exerted.\* Personally, I rather favor the view advocated by von Lenhossék,

---

\* To gain an idea of the recent conceptions concerning the relation of the nucleus to nutritive processes in the cell the article of Haberlandt (Ueber die Beziehungen zwischen Function und Lage des Zellkerns bei den Pflanzen, Jena, 1887) and that of Korschelt (Beiträge zur Morphologie und Physiologie des Zellkernes, Zool. Jahrb., Abth. f. Anat., Bd. xxvi, 1886) may be consulted.

that instead of assuming an actual transportation of a chemical substance we can very well conceive of a variety of excitation which, starting from the cell, perhaps even from the nucleus, streams constantly through the axone, and in it in some way, perhaps by a process comparable to electrolysis, maintains the chemical conditions suitable for the assimilation of the nutritive juices, a view entirely compatible with the fact that the trophic action of the cell body appears to be least active in the parts of the axone most distant from it. Goldscheider has argued that since peripheral sensory fibres (in which presumably the impulses are, in the main at least, centripetal) degenerate completely when cut through, just as do divided motor fibres in which the impulses are centrifugal, the influence of the ganglion cell presiding over the assimilation is not identical with the functional excitation, an idea which Rumpf\* had as early as 1882 satisfactorily stated. In view of what I have said before concerning the possibility of functional excitation in either direction in a neurone, this argument would lose something of its force; but, granting that it is well based, it need not militate against von Lenhossék's hypothesis, inasmuch as in the absence of the passage of genuine nerve impulses cellulifugally in the peripheral sensory fibres the transmission of the excitations essential to nutrition would still be conceivable, and would certainly be no more difficult to conceive of than the actual cellulifugal transport of a chemical substance in a direction opposite to that followed by the functional excitation. The more thought one gives to the subject, the more he will find in the trophic relations of the neurones to make him hesitate before he denies the possibility of the conduction of impulses or influences in either direction throughout the neurone.

But hypotheses such as have just been considered will not suffice for the interpretation of the findings in the main body of the neurone after division of its axone—those included in the delicate experiments of Nissl, Flatau, Marinesco, Erlanger, and others, as well as those in the earlier studies of von Gudden and his pupils, and in the observations upon the nervous system after amputations. We have seen that these observations have, partially at least, annulled the validity of Wal-

---

\* Rumpf, Th. Zur Degeneration durchschnittener Nerven. Untersuch. a. d. physiol. Inst. d. Univ. Heidelb., Bd. iv (1882).



ler's doctrine of the trophic relations of the nerve cells, for after injury to an axone, in addition to the degeneration in the axone peripheral to the lesion, there are demonstrable alterations in the cytoproximal end of the axone and especially in the cell body of the neurone itself.

Marinesco, in his careful study of the nervous system after amputations, attempted to account for the discrepancy. Although up to this time the spontaneity of nerve function had scarcely been questioned, this author threw doubt upon the automatic activity of the nerve cell. It was his idea rather that the functional activity of a nerve cell was entirely dependent upon stimuli reaching it from the outside, and that in the absence of the advent of external stimuli the spinal ganglion cells, for example, can not retain their nutritive functions. He was more cautious in his explanation of the atrophy of the ventral horn cells, but suggested that in case a limb was amputated, even though the path carrying voluntary impulses to the motor cells in the ventral horns remained intact, the one which brought the sensory impulses concerned in reflex activities was interfered with, and the diminution in impulses reaching the ventral horn cells thus brought about could, he thought, result in a marked depreciation of their vitality. Goldscheider, in his article dealing with the doctrine of the trophic centres, accepts fully this hypothesis of Marinesco and in a way extends it.\* Von Lenhossék, who is favorably impressed by it, does not believe, however, that the loss of centripetal stimuli reaching the corresponding segment of the spinal cord by way of the sensory fibres coming from the muscles, tendons, etc., after injury to a motor nerve,† will suffice to explain the alteration in the cells of origin of the fibres cut through. While I cannot agree with von Lenhossék that there is no physiological basis for the view that these stimuli influence the motor cells which lie in the same segment of the spinal cord, or that no reason for such a relation is visible, it must nevertheless be granted that in his attempt to offer a suitable explanation he has called attention to another possible factor which may be of decided import as regards nutrition. He finds the simplest ex-

---

\* Strong confirmatory evidence has since been adduced by Warrington and van Gehuchten. *Vide supra*.

† Cf. Nissl's experiments.

planation of the degenerative phenomena in question in the assumption that for every nerve cell a necessary condition of existence is its normal connection with its end organ by means of its axone—for example, in the case of a cell of the ventral horn with its corresponding muscle. In the cutting through of a motor axone it is, according to him, not the loss by the motor cell of the few centripetal stimuli which this might occasion, but rather the impossibility of a normal discharge of energy, the nerve cell being, as it were, embarrassed by the storm of excitations reaching it by way of the reflex collaterals, fibrils of the pyramidal tracts, or other connections. Flatau, in his discussion of the subject, takes a midway position, believing that the nutrition of the ganglion cell may be affected either by diminution in the number of impulses which it receives or by the consequent impossibility of the giving off of stimuli to muscles or to other neurones. This certainly is a very rational position



FIG. 183.—Spinal ganglion cell showing marked alterations following section of the sciatic nerve. Sublimate fixation; thionin staining. (After Lugaro.)

to take, inasmuch as in a society of cells, just as in any other community, if one member be deprived of the influences of its fellows, or, although receiving such influences, become glutted with them, owing to inability to discharge its own functions, that member must necessarily suffer.

Still another hypothesis has been advanced by Lugaro,\* who has studied the alterations in the spinal ganglion cells after section of their peripheral (Fig. 183) and central (Fig. 184) axones. He points out that the motor axone and the peripheral prolongations of spinal ganglion cells differ in that they are placed at the opposite extremities of nerve elements. This very position he suggests may be of especial influence as regards

\* Lugaro, E. Sulle alterazioni delle cellule nervose dei gangli spinali, in seguito al taglio della branca periferica o centrale del loro prolungamento. Riv. di patol. nerv., Firenze, vol. i (1896), pp. 457-470; also, Sul comportamento delle cellule nervose dei gangli spinali in seguito al taglio della branca centrale de loro prolungamento. *Ibid.*, vol. ii (1897), pp. 540-543.

disturbances of nutrition. He thinks that either suppression of the stimuli normally arriving in the group of nerve elements or impediment to the discharge of energy from a group acts by disturbing the normal action of the metabolic cycle and can lead to degeneration of the neurones. He finds, however, that while after section of the peripheral axone of the spinal ganglion cell there are marked nutritive disturbances to be made out in the cell bodies inside the spinal ganglia, after section of the fibres of the dorsal root of a spinal nerve or its intramedullary prolongations only insignificant changes or none at all are

to be found in the cells. In order to explain this apparent paradox he suggests that the various elements of the nervous system offer varying resistance to nutritive disturbances. He can imagine that the sensory elements suffer more especially from the suppression of external stimuli, while on the other hand the motor elements suffer mainly as a result of hindrance to the discharge of energy elaborated within them, and which, under normal circumstances, is removed immediately from the centre where this work is done. It is Lugaro's opinion further that the recovery of certain cells in the spinal ganglia and the permanent alterations or complete disintegration of others is to be explained by the assumption of variations in native regenerative capacity in different cells.

That the injury resulting from whatever cause, if only temporary, need not be fatal to the neurone concerned, is fully indicated by the general work which has been done on regeneration of peripheral nerves. Even though the preliminary signs of neurone decay can be demonstrated by the method of Nissl, the trophic function is not at first lost, inasmuch as strenuous efforts toward repair are made,\* and should the axone




FIG. 184.—Spinal ganglion cell forty days after section of corresponding dorsal root. Sublimite fixation; thionin staining. (After Lugaro.)

---

\* This is apparently true even inside the central nervous system. Cf. Worcester, W. L., *On Regeneration of Nerve Fibres inside the Central Nervous System*. J. Nerv. and Ment. Dis., N. Y., vol. xxv (1898), p. 698.

happily succeed in re-establishing its terminal relations there is gradually a complete restitution to the normal condition. Only when on account of some obstacles in the way, or through some other cause, this re-establishment of the former or other conduction relations of the neurone is rendered impossible, do complete degeneration and disappearance of the neurone occur after section of the axone. With the peripheral sensory axones the trophic effort manifested is often extreme, as many unfortunate individuals have found to their discomfort in the appearance of the so-called amputation neuromata.



## SECTION VI.

### ON THE GROUPING AND CHAINING TOGETHER OF NEURONES IN A COMPLEX NERVOUS SYSTEM LIKE THAT OF MAN AND MAMMALS.

---

INTRODUCTION. Chap. XXVI.

SUBSECTION I. Neurones connecting the sense organs of the body with the central nervous system (peripheral centripetal neurones; sensory neurones of the first order; sensory protoneurones).

Classification of sensory impressions. The neural segment. Physiological and clinical studies. Chap. XXVII.

A. Centripetal neurones of the first order collecting bodily impressions: 1. Those connected with the spinal cord, Chaps. XXVIII to XXXIV; 2. Those connected with the rhombencephalon, Chap. XXXV.

B. Centripetal neurones of the first order collecting impressions of special sense: 1. Peripheral gustatory neurones; 2. Peripheral olfactory neurones, Chap. XXXVI; 3. Peripheral visual neurones, Chap. XXXVII; 4. Peripheral auditory neurones, Chap. XXXVIII.

SUBSECTION II. Neurones within the central nervous system connecting the end-stations (nuclei terminales) of the axones of the peripheral centripetal neurones with other portions of the central nervous system (sensory neurones of the second and of higher orders).

A. Central neurones of sensory conduction paths other than those corresponding to the organs of special sense: 1. Those pertaining to the spinal peripheral sensory neurones—(a) Neurones the cell bodies of which are situated in the nuclei funiculi gracilis et cuneati, Chap. XXXIX; (b) neurones the cell bodies of which are situated in the nucleus dorsalis, Chap. XL; (c) neurones the cell bodies of which are situated in the gray matter of the cord, the axones going to the fasciculus ventro-lateralis Gowersi, Chap. XLI; (d) neurones the cell bodies of which are situated in the gray matter of the cord, the axones going to the fasciculi proprii, Chap. XLII. 2. Those pertaining to the cerebral peripheral sensory neurones—(a) Neurones the cell bodies of which are situated in

the nuclei terminales of the N. vagus, N. glossopharyngeus, and N. intermedius, Chap. XLIII; (*b*) neurones the cell bodies of which are situated in the nuclei terminales of the N. vestibuli, Chap. XLIV; (*c*) neurones the cell bodies of which are situated in the nuclei terminales of the N. trigeminus, Chap. XLV. 3. Neurones the cell bodies of which are situated in the cerebellum, the axones of which run cerebralward, and possibly represent an indirect central sensory conduction path, Chap. XLVI. 4. Central sensory axones passing into or through the cerebral peduncle and the terminations of such axones—(*a*) The lemniscus or fillet, Chap. XLVII; (*b*) the fasciculus longitudinalis medialis, Chap. XLVIII; (*c*) the formatio reticularis alba, Chap. XLIX; (*d*) certain fibres of the brachium conjunctivum and the radiations of the nucleus ruber, Chap. L. 5. Central sensory axones passing through the internal capsule (corticopetal projection neurones of the general sensory path)—(*a*) Embryological system No. 1; (*b*) embryological system No. 2; (*c*) embryological system No. 3, Chap. LI.

- B. Central neurones of conduction paths corresponding to the organs of special sense: 1. Central neurones of the gustatory conduction path; 2. Central neurones of the olfactory conduction path, Chap. LII; 3. Central neurones of the visual conduction path, Chap. LIII; 4. Central neurones of the auditory conduction path, Chap. LIV.

SUBSECTION III. Neurones directly connecting the central nervous system with the voluntary muscles of the body (lower motor neurones).

- A. Those pertaining to the spinal cord, Chap. LV.  
 B. Those pertaining to the rhombencephalon, isthmus, and mesencephalon—1. Those, the axones of which belong to the N. hypoglossus; 2. Those, the axones of which belong to the N. accessorius; 3. Those, the axones of which belong to the N. vagus et glossopharyngeus; 4. Those, the axones of which belong to the N. facialis; 5. Those, the axones of which belong to the N. abducens; 6. Those, the axones of which belong to the N. trigeminus; 7. Those, the axones of which belong to the N. trochlearis; 8. Those, the axones of which belong to the N. oculomotorius, Chap. LVI.

SUBSECTION IV. Neurones which enter into conduction relation with the lower motor neurones and throw the latter under the influence of other centres (intermediary and upper motor neurones).

- A. Those, the axones of which help to make up the fasciculi proprii of the spinal cord, Chap. LVII.  
 B. Those, the axones of which run in the fasciculus longitudinalis medialis and in the formatio reticularis alba of the rhombencephalon, Chap. LVIII.  
 C. Those, the cell bodies of which are situated in the cerebellum, Chap. LIX.

- D. Those, the cell bodies of which are situated in the mesencephalon and diencephalon, Chap. LX.
- E. Those, the cell bodies of which are situated in the telencephalon (pallium and rhinencephalon)—1. Those, the axones of which correspond to the fasciculi cerebrospinales or pyramidal tract, Chap. LXI; 2. Those, the axones of which run to the motor nuclei of the cerebral nerves, Chap. LXII; 3. Those, the axones of which correspond to the frontal cerebrocorticopontal path, Chap. LXIII; 4. Those, the axones of which correspond to the temporal cerebrocorticopontal path; 5. Those, the axones of which connect the lobus occipitalis with the nuclei governing the movements of the eyes; 6. Those, the axones of which connect the rhinencephalon with the lower motor neurones, Chap. LXIV.

SUBSECTION V. Projection neurones, commissural neurones, and association neurones of the telencephalon.

- A. Projection neurones, Chap. LXV.
- B. Commissural neurones: 1. Those, the medullated axones of which correspond to the fibres of the corpus callosum; 2. Those, the medullated axones of which correspond to the commissura anterior cerebri; 3. Those, the medullated axones of which correspond to the fibres of the commissura hippocampi, Chap. LXVI.
- C. Association neurones: 1. Those with short axones; 2. Those with long axones, Chap. LXVII; 3. Localization of association neurones in the cerebral cortex. Flechsig's doctrine of "association centres," Chap. LXVIII.

## CHAPTER XXVI.

### INTRODUCTORY.

Methods of description—Classification to be followed—Architectonics of the nervous system—Neurone systems—Conduction paths.

ONE would like to be able to describe the structure of the human nervous system according to the arrangement of the neurones underlying the various functional nervous processes. Unfortunately, the limited knowledge we have at present suffices only for a beginning of such a description. We have gained, it is true, important clues concerning the individuality of mechanisms, the successive complication of nervous phenomena, and their structural basis from comparative anatomy

and from studies in ontogeny. Thus, Edinger\* in the last edition of his text-book has given us for the first time a view of the successive increase in complexity characterizing the nervous systems belonging to a large series of animals, and the physiological studies of Jacques Loeb, J. Steiner, and A. Bethe give us a glimpse of what we can hope from the study of the functions in lower forms. Flechsig's method permits us also to form some idea of the mechanisms underlying the simplest nerve functions in human beings and those concerned in the performance of the more complex ones up to at least the fifth month of extrauterine life. But none of these methods furnishes us with more than a beginning on the lines indicated.

In the description to be given here of the grouping of the neurones no attempt will be made to describe the groups according to the sequence met with in the development of function, but instead, inasmuch as for practical purposes this seems at the moment to be more important, some of the main groups of neurones with which we are fairly well acquainted and of the functions of which we have a relatively extended knowledge, especially as they appear in the new-born babe and in the adult, will be dealt with.

The central cerebrospinal nervous system is ordinarily described as being connected with the other organs of the body and with the external world by means of nerves. These nerves contain fibres of one or both of two sorts, afferent or centripetal, and efferent or centrifugal. By means of the former the neurones within the central system are capable of being influenced from without; through the latter they exert an influence upon other parts of the body. To borrow an illustration from von Lenhossék, the peripheral nerves care for the "import" and "export" relations of the central nervous system, while the neurones inside look after "home" relations. In the following account, therefore, it will be necessary to consider the structural relations of the neurones which connect the sense organs of the body with the central nervous system (including the afferent nerves), of those connecting the central nervous system with the muscles of the body (including the efferent

---

\* Edinger, L. *Vorlesungen ueber den Bau der nervösen Centralorgane des Menschen und der Thiere für Aerzte und Studirende.* 5. Aufl., Leipzig, 1896, 398 pp., 8vo.



nerves), and of those of the collections of neurones inside the central nervous system. The different groups may be conveniently discussed under the following headings:

I. Neurones connecting the sense organs of the body with the central nervous system (peripheral centripetal neurones; sensory neurones of the first order; sensory protoneurones). Chaps. XXVII to XXXVIII.

II. Neurones within the central nervous system connecting the end-stations of the axones of the peripheral centripetal neurones with other portions of the central nervous system, and neurones which in turn connect the end-stations of the latter with still higher portions of the central system (sensory neurones of the second order and of higher orders). Chaps. XXXIX to LIV.

III. Neurones connecting the central nervous system with the voluntary muscles of the body (lower motor neurones). Chaps. LV and LVI.

IV. Neurones within the central nervous system which enter into conduction relation with the lower motor neurones and throw the latter under the influence of other centres. Neurones connecting the pallium, cerebellum, etc., with the lower motor neurones. Chaps. LVII to LXIV.

V. Projection, commissural, and association neurones of the telencephalon. Chaps. LXV to LXVIII.

An idea of the tectonics or architecture of the nervous system, considering the neurones as the architectural units, can be gained only when we form spatial conceptions of the distribution of the various neurones and their processes in the central and peripheral nerve organs. Such spatial conceptions are obtainable only by combining in the mind the results of a whole series of studies—embryological, histological, physiological, and pathological. A careful study of the topographical relations in faultless sets of serial sections through various degenerated nervous systems, or through the foetal central organs at various stages in the process of myelinization, together with the study of Golgi preparations, permits one to make mental fusions of the single pictures, and so to obtain an idea of the distribution in space of the various fibre bundles, and the cells of which they represent the medullated axones. A much more accurate method is that of graphic reconstruction from serial sections (W. His), or plastic reconstruction by

means of wax plates (G. Born). The advantages of the latter method are illustrated in the model of the rhombencephalon and mesencephalon constructed by Miss Florence Sabin, to which references are occasionally made in the following chapters. If he has not obtained "ideas in three dimensions" of the groups of neurones and their interrelations inside the central nervous organs, the student will find himself entirely at sea when he attempts the explanation of the results of pathological lesions.

The term "system" is employed often by neurological writers, and unfortunately not always in the same way. It would seem desirable,\* in accordance with recent German writers, to limit the use of the term "neurone system" to an aggregate of homologous axones, and to restrict the use of the term "fibre system" to a group of medullated axones of homologous origin and homologous distribution (as regards their collaterals, subdivisions, and terminals). Thus, for example, the neurones, the cell bodies of which are situated in the spinal ganglia, the central axones of which enter the dorsal funiculi of the spinal cord and terminate in its gray matter or in the nuclei of the medulla oblongata, together represent a great "system" of peripheral spinal centripetal neurones. This *system* is in turn divisible into *sub-systems*—(1) on the ground of myelinization; and (2) according to the particular nuclei in which a given set of fibres terminate. The fibres of the pyramidal tract represent a "fibre system," since (1) they are the axones of homologous cells in the cerebral cortex, and (2) they terminate in homologous regions in the spinal cord.

Topographical study teaches that there may be a "mixing of systems" in given areas of a cross section. A given topical area in a microscopic section seldom represents an entirely pure "fibre system." It is legitimate, however, in topographical descriptions, to give names *à fortiori* to the various areas. Thus we speak of the "area of the lateral pyramidal tract" in a cross section of the spinal cord, although we know that in this area a few fibres other than those of the pyramidal tract

---

\* Cf. Tschermak, A. Ueber den centralen Verlauf der aufsteigenden Hinterstrangbahnen und deren Beziehungen zu den Bahnen im Vorderseitenstrang. Arch. f. Anat. u. Physiol., Anat. Abth., Leipz. (1898), S. 291-400.

exist; and again we call a certain bundle in the dorso-lateral periphery of the cord the fasciculus cerebellospinalis, or the dorso-lateral spino-cerebellar system, though we have good evidence that the fibres of this fasciculus are mixed, in places at least, with fibres not homologous with the spino-cerebellar fibres.

A chain or series of neurone systems, constituting a functional unit of a higher order, may be designated a "conduction path"—the Germans call it a *Leitungsbahn*.<sup>\*</sup> Thus the several "systems" following upon one another in a given "conduction path" may be spoken of as primary systems, secondary systems, tertiary systems, etc. In the general *centripetal* conduction path from the muscles to the cerebral cortex the peripheral centripetal neurones corresponding to the spinal ganglion cells represent a "primary system"; the neurones of the next higher order (whose perikaryons and dendrites are in the nucleus funicularis externus (or nucleus funiculi gracilis) and whose axones run as internal arcuate fibres across the raphe into the opposite interolivary layer, and on through the medial lemniscus to terminate in the ventro-lateral part of the thalamus) represent a "secondary system"; while the neurones connecting the ventro-lateral part of the thalamus with the somæsthetic area of the cerebral cortex represent a tertiary system. This sensory "conduction path" would consist, then, of three superimposed sets of "neurone systems." As we shall see, in the "afferent" or "centripetal" conduction paths the perikaryons and dendrites of a given "neurone system" are, as a rule, situated *below* and the axones *ascend* toward the perikaryons and dendrites of the next neurone system. On the other hand, in the "efferent" or "centrifugal" conduction paths the perikaryons and dendrites of a given neurone system are situated, as a rule, *above*, and the axones *descend* toward the perikaryons and dendrites of the neurone system of the next order. To use a nomenclature suggested by Tschermak, the efferent conduction path is composed of "distal-axone" systems, and the afferent conduction path of "central-axone" systems. The "distal-axone" systems are in the main motor or reflex, the "central-axone" systems, in the main, sensory.

---

<sup>\*</sup> Cf. Held, H. Arch. f. Anat. u. Physiol., Anat. Abth., Leipz. (1893), S. 436. Also the numerous publications of Paul Flechsig and of W. von Bechterew.

In a given conduction path, composed of several superimposed or subimposed neurone systems, the primary, secondary, and other systems need not necessarily contain the same total number of neurones; indeed, as we have seen already, and shall see further on, a single neurone of one system is often, by virtue of a number of end-ramifications, able to enter into conduction relations with a number of neurones in a neurone system of the next higher order (e. g., terminals of N. trigeminus in the substantia gelatinosa, terminals of tractus opticus in the colliculus superior); in other instances, on the contrary, the terminals of a large number of axones of one neurone system may be so arranged that they can influence only a smaller number of neurones of a neurone system of the next order (e. g., Nn. olfactorii, terminating in the olfactory glomeruli). In the one case there is a "multiplication of elements" in the direction of the conducting path, in the other a "reduction of elements." \*

To a description of the various neurone systems, at least those that are best known, we may now conveniently proceed.

---

\* For further interesting considerations of a similar nature with regard to neurone systems and conduction paths, especially with reference to the *divergence* and *confluence* of paths, the reader may turn with advantage to the article of Tschermak above cited.



## SUBSECTION I.

**Neurones Connecting the Sense Organs of the Body with the Central Nervous System (Peripheral Centripetal Neurones; Sensory Neurones of the First Order; Sensory Protoneurones).**

## CHAPTER XXVII.

ON THE CLASSIFICATION OF SENSORY IMPRESSIONS AND THE RELATION OF THE CENTRIPETAL NEURONES TO THE SEGMENTATION OF THE BODY.

Neurones collecting bodily impressions—Neurones collecting impressions from the external world—Externalization of impressions—The neural segment or neurotome—Nn. spinales—Radix ventralis—Radix dorsalis—Ganglion spinale—Peripheral nerves—Rami communicantes, etc.—Plexus cervico-brachialis—Plexus lumbo-sacralis—Cutaneous distribution of peripheral sensory nerves—Cutaneous distribution of dorsal root fibres—Experimental studies in animals—Overlapping—Clinical studies on human beings—Surface areas of the topographical anatomists.

THE peripheral centripetal neurones are those through which the central nervous system is affected, (*a*) by changes taking place in the body itself (outside the central nervous system and organs of special sense), and (*b*) by physical and chemical influences exerted from the environment of the individual.\* This classification of sensory neurones conforms to the custom of dividing the impulses which pass into the central nervous system into (A) impressions which concern the body itself, and (B) impressions which concern the external

---

\* In this connection it must not be forgotten that the neurones within the nerve centres can be and often are very significantly affected by influences dependent upon alterations in the blood and lymph. It would be a grave error to assume that all the phenomena in the central neurones are dependent upon reactions called forth by impulses coming in through the peripheral centripetal fibres. The respiratory mechanism, for example, is largely of a chemical character. This, however, is so obvious when one's attention is directed toward it that further discussion here is unnecessary.

world, the former including what has ordinarily been known as "common sensation," the latter embracing the "special senses." The tendency of the mind is to refer the sensations which may result in consciousness from the former set of impulses to changes in the body itself, and to project those which result from the latter set of impulses into the external world; that is to say, while the former are, as a rule, not "objectivisable," or "externalizable," the latter are always or nearly always "objectivisable." In the latter set of impressions an element of externality seems to be inherent.

Such a distinction, while convenient for purposes of description, is not wholly free from objection. In the skin, for example, one meets with a sensory surface which concerns not only the body itself, but also the external world. And even impressions brought into the nervous system through the muscle sense are probably, to a certain extent, objectivisable. For the sake of convenience, however, and with this preliminary qualification, the neurones may be considered under these headings, the first group (*a*) bringing impulses into the nerve centres from the skin, mucous membranes, muscles, semicircular canals, bones, tendons, joints, sexual organs, and internal viscera; the second group (*b*) bringing impressions into the central nervous system from the organs of special sense; namely, from (1) the gustatory organs; (2) the olfactory organs; (3) the visual organs; (4) the auditory organs.

The relations of the sensory nerve to the so-called *neurotome* or *neural segment* are shown in the accompanying figure (Fig. 185). If the student grasp clearly the idea of the neural segment (cf. Chapter XVIII) he will have much less difficulty in understanding the architecture of the nervous system in general. In the illustration the *motor ventral root* (*radix ventralis*) is seen coming out of the ventro-lateral surface of the spinal cord, being formed by the union of a number of *fila radicularia*. It turns dorsalward where it is joined by the *dorsal sensory root* (3) or *radix dorsalis*, in the course of which is seen a nodular swelling, the *ganglion spinale* (4). The ventral root forms no definite union with the dorsal root, but simply lies beside it, the combined roots forming the *common* or *mixed nerve stem* (5). This common stem of a spinal nerve divides into two main trunks, the *ramus dorsalis* (6), which runs dorsalward to supply the musculature and skin of the back, and a *ramus ventralis* (7),

which turns ventralward into the parietes to supply the musculature and skin of this region, including the musculature and skin of the extremities. This ventral ramus in typical instances gives off (*a*) a lateral branch, the so-called *ramus cutaneus*

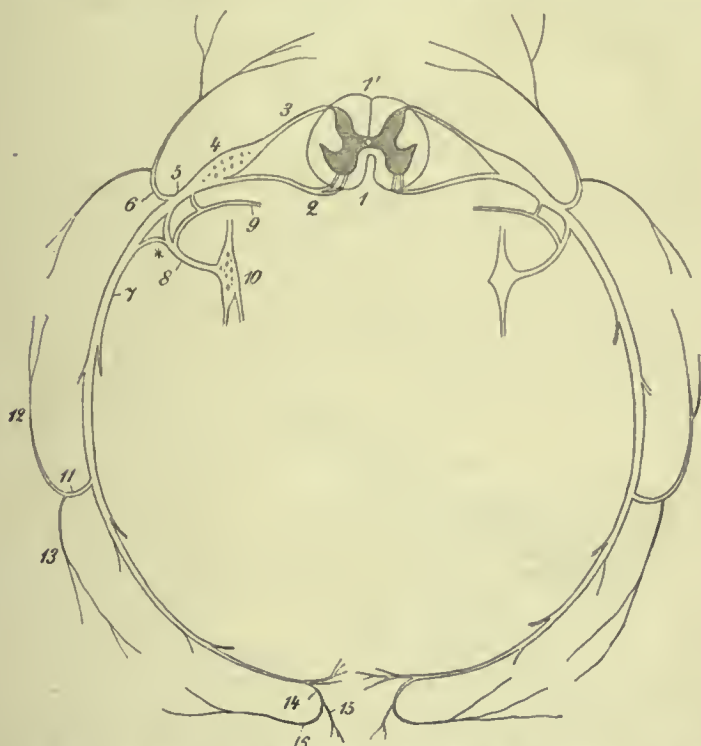


FIG. 185.—Cross section of the central and peripheral nervous system of a man, illustrating the neural segment. (After A. Küber, *Lehrbuch der Anatomie des Menschen*, V. Aufl., Leipz., 1898, Bd. ii, S. 265, Fig. 233.) 1, fissura mediana ventralis of the spinal cord; 1', sulcus medianus dorsalis; 2, radix ventralis (motor); 3, radix dorsalis (sensory); 4, ganglion spinale; 5, nervus spinalis (common trunk); 6, ramus dorsalis; 7, ramus ventralis; 8, ramus communicans; 9, ramus meningeus; 10, ganglion sympathicum; 11, ramus cutaneus lateralis; 12, dorsal limb, 13, ventral limb of 11; 14, ramus cutaneus ventralis dividing into a medial limb 15 and a lateral limb 16. The cross section of the spinal cord shows the H-shaped substantia grisea with the canalis centralis in the commissura grisea. About the substantia grisea lies the white mantle formed by the substantia alba.

lateralis (11) (which in turn divides into a dorsal (12) and a ventral (13) limb), and (*b*) a more ventral branch, the *ramus cutaneus ventralis* (14), which (dividing into a medial (15) and a lateral (16) limb) innervates the skin on the ventral surface





other rami are given off from this mixed trunk, namely, the *ramus communicans* (8), containing both sensory and motor fibres destined for the viscera and blood-vessels by way of the sympathetic nervous system (10), and a *ramus meningeus* (9), which runs back through the foramen intervertebrale to enter the vertebral canal, there to break up into fibres, which are distributed to the spinal cord, its sheaths, and the walls of the vertebral canal.

It would be a mistake, however, to leave the impression that in each *peripheral nerve* there are sensory and motor fibres corresponding only to one common stem derived from a single neural segment. While this would be true, or nearly true, for the thoracic region, it would not hold for the cervical, lumbar, and sacral regions. In these regions the *rami ventrales* form anastomoses and plexiform unions, so that the derivatives of neighboring neural segments become incorporated in common bundles. It is customary to describe two large nerve plexuses: a superior—the so-called *plexus cervico-brachialis*; and an inferior—the so-called *plexus lumbo-sacralis*.

The *plexus cervico-brachialis* (Fig. 186) arises from the anastomoses formed by the *rami ventrales* of the cervical and first two thoracic nerves. It is subdivided into the (1) *plexus cervicalis* and (2) the *plexus brachialis*, the latter being further subdivided into (a) a *pars supraclavicularis* and (b) a *pars infraclavicularis*.

The *plexus lumbo-sacralis* (Fig. 187) can be subdivided into (1) the *plexus lumbalis*, (2) the *plexus sacralis*, and (3) the *plexus pudendo-caudalis*, the latter being further subdivisible into (a) the *plexus pudendus* and (b) the *plexus coccygens*. The *plexus lumbalis* is composed of the ventral rami derived from the mixed stems of the four upper Nn. lumbales, while the *plexus sacralis* has its origin in the ventral rami, derived from the fifth N. lumbalis and the first and second Nn. sacrales.

The *plexus pudendus* is formed by the ventral rami derived from the mixed stems of the third and fourth Nn. sacrales, the *plexus coccygens* from the ventral rami of the fifth N. sacralis and the first N. coccygens.

As a result of the anatomical conditions just referred to, it must be obvious that the clinical symptoms dependent upon lesions of the peripheral sensory neurones will vary widely according to the situation of the lesion.

Thus, the distribution of the disturbances of cutaneous sensibility will be very different in a case in which a nerve is




FIG. 187.—Plexus lumbosacralis, including the plexus lumbalis, the plexus sacralis, and the plexus pudendus. Ventral aspect. (After P. Eisler, taken from Rauber's *Lehrbuch der Anatomie des Menschen*.) *rl*, ramus cutaneus lateralis of the N. subcostalis; *ih*, N. iliohypogastricus; *ri*, its ramus iliacus; *ii*, N. ilioinguinalis; *ql*, Nerve for quadratus lumborum; *se*, N. spermaticus externus; *li*, N. lumboinguinalis; *p*, ramus muscularis to M. psoas; *cl*, N. cutaneus femoris lateralis; *i*, ramus muscularis to M. iliacus; *ip*, ramus muscularis to M. iliopsoas; *Cr*, N. femoralis; *oa*, N. obturatorius accessorius; *o*, N. obturatorius; *gs*, N. glutæus superior; *pl*, ramus muscularis to M. piriformis; *Pe*, N. peronæus; *gi*, N. glutæus inferior; *Ti*, N. tibialis; *fi*, rami musculares to Mm. flexores cruris; *q*, ramus muscularis to M. quadratus femoris and M. gemellus inferior; *oi*, ramus muscularis to M. obturator internus and M. gemellus superior; *cp*, N. cutaneus femoris posterior; *cm*, N. cut. elun. inf. medialis (N. perforans lig. tuberoso-sacrum); *pu*, N. pudendus; *h*, N. hæmorrhoidalis ext.; *l*, ramus muscularis to M. levator ani; *c*, ramus muscularis to M. coccygeus; *a*, *b*, Nn. anococcygei.

injured near the periphery, from that to be made out in a case in which one of the strands of a nerve plexus is involved, and the distribution in both these instances will again be quite different from that met with in lesions of a dorsal root of a spinal nerve. Finally, lesions of the intramedullary continuations of the dorsal roots, owing to deviations in the paths followed by individual bundles arising from a given root, will yield disturbances in sensation quite different in distribution, and probably also in the qualities of sensation interfered with, from those met with in any extramedullary lesion.

The cutaneous distribution of the peripheral sensory nerves has been tolerably carefully worked out by means of (1) dis-

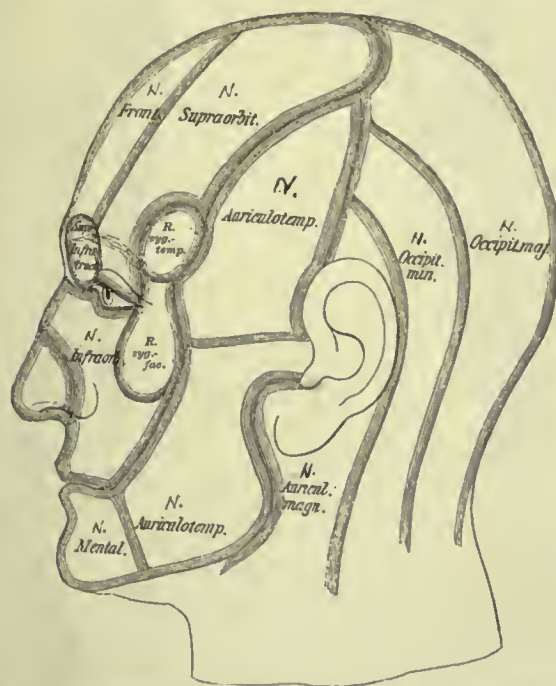


FIG. 188.—The areas supplied by the cutaneous nerves of the head. (After F. Merkel, taken from Rauber's text-book.)

sections on the dead, (2) experiments on living animals, and (3) clinical observations on diseased human beings followed by careful post-mortem examination. In Figs. 188–190 the main

results of these studies are illustrated. For further details the valuable atlas of Hasse\* may be consulted. Now that we

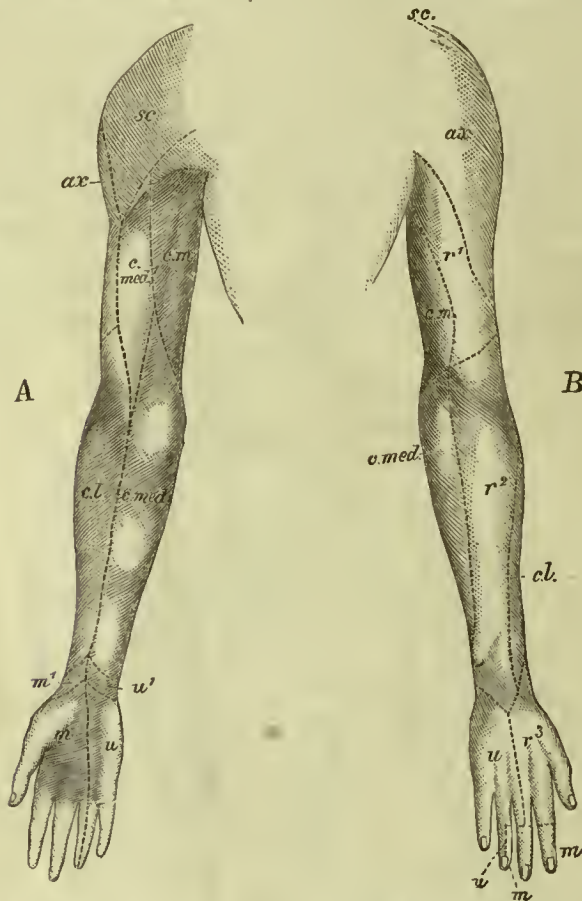


FIG. 189.—Areas supplied by the cutaneous nerves of the upper extremity. (After A. Rauher, *Lehrbuch der Anatomie des Menschen*, V. Aufl., Leipz., 1898, Bd. ii, S. 631, Fig. 549.) A, volar surface; B, dorsal surface. *sc.*, Nu. supraclaviculares; *ax.*, N. axillaris; *c.m.*, N. cutaneus brachii medialis; *c.med.*, N. cutaneus antibrachii medialis; *c.med'*, area of upper arm supplied by fore-going nerve; *cl.*, N. cutaneus antibrachii lateralis, a branch of the N. musculocutaneus; *r¹*, N. cutaneus brachii posterior (branch of N. radialis); *r²*, N. cutaneus antibrachii dorsalis (branch of N. radialis); *r³*, branch of N. radialis on the back of the hand; *u.*, N. ulnaris (ramus dorsalis manus and ramus volaris manus) in the hand; *u¹*, ramus cutaneus palmaris of N. ulnaris; *m.*, N. medianus in the hand; *m¹*, its ramus palmaris.

\* Hasse, C. *Hand-Atlas der sensiblen und motorischen Gebiete des Hirn- und Rückenmarksnerven* (36 Tafeln). Zum Gebrauch für practische Aerzte und Studierende. Wiesbaden (1895), 8vo.



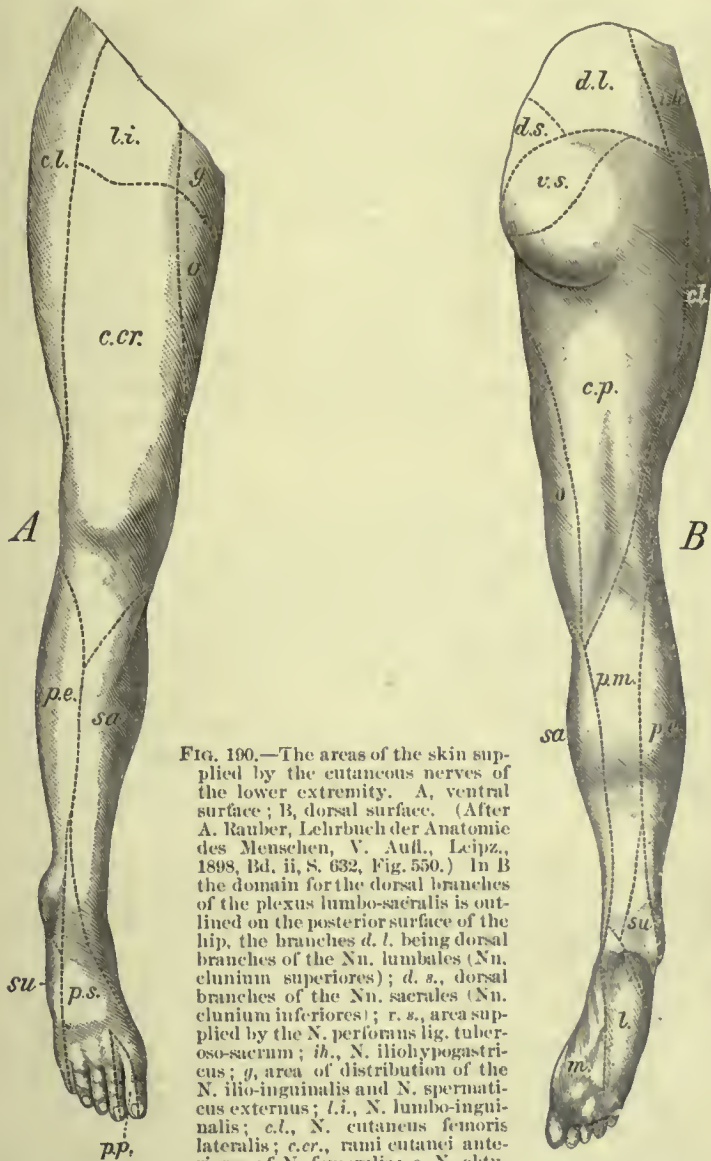


FIG. 190.—The areas of the skin supplied by the cutaneous nerves of the lower extremity. A, ventral surface; B, dorsal surface. (After A. Rauber, *Lehrbuch der Anatomie des Menschen*, V. Aufl., Leipz., 1898, Bd. ii, S. 632, Fig. 550.) In B the domain for the dorsal branches of the plexus lumbo-sacralis is outlined on the posterior surface of the hip, the branches *d. l.* being dorsal branches of the Nn. lumbales (Nn. clunium superiores); *d. s.*, dorsal branches of the Nn. sacrales (Nn. clunium inferiores); *v. s.*, area supplied by the N. peroneus lig. tuberoso-sacrum; *ih.*, N. iliohypogastricus; *g.*, area of distribution of the N. ilio-inguinalis and N. spermaticus externus; *l. i.*, N. lumbo-inguinalis; *c. l.*, N. cutaneus femoris lateralis; *c. cr.*, rami cutanei anteriores of N. femoralis; *o.*, N. obturatorius; *c. p.*, N. cutaneus femoris posterior; *sa.*, N. suphenus; *p. e.*, lateral, *p. m.*, posterior branch of N. peroneus to the leg; *su.*, N. suralis; *p. s.*, N. peroneus superficialis (N. cutaneus dorsalis medialis et N. cutaneus dorsalis intermedius et Nn. digitales dorsales pedis); *p. p.*, N. peroneus profundus (Nn. digitales dorsales hallucis lateralis et digiti secundi medialis); *m.*, N. plantaris medialis; *l.*, N. plantaris lateralis.

*su.*, N. suralis; *p. s.*, N. peroneus superficialis (N. cutaneus dorsalis medialis et N. cutaneus dorsalis intermedius et Nn. digitales dorsales pedis); *p. p.*, N. peroneus profundus (Nn. digitales dorsales hallucis lateralis et digiti secundi medialis); *m.*, N. plantaris medialis; *l.*, N. plantaris lateralis.

know from the studies of Blix,\* Goldscheider,† von Frey,‡ and V. Henri that at least four qualities of sensation—cold, warmth, touch, and pain—are mediated by the skin and apparently by means of specific sense organs, it is important that the surface of the body be reworked to determine whether or not the peripheral areas are identical for the different sense qualities. As we shall see in a few moments, the segmental areas at least appear to be somewhat different for the different qualities of entaneous sensation.

The study of the sensory areas of the surface corresponding to the dorsal roots of the spinal nerves, in addition to its high clinical importance, has excited so much interest and has been prosecuted in so many ingenious ways that a brief synopsis of the researches and a statement of the present status of knowledge and belief in this connection may not be out of place.

As early as 1849 Eckhard\* stated as a result of a few experiments that the field of skin to which a sensory root goes is not exactly that which overlies the muscles which are supplied by the corresponding motor root. This research was soon followed by another from the same laboratory, this time from Peyer.¶ This investigator sectioned all mixed nerve stems except the one which he was studying, and then applied mechanical and thermal stimuli to the skin. He came to the conclusion that in the skin of the fore-limb the fields of the individual spinal nerve roots more or less overlap one

\* Blix, M. Experimentelle Beiträge zur Lösung der Frage ueber die spezifische Energie der Hautnerven. *Ztschr. f. Biol.*, Bd. xx (1884), S. 141.

† Goldscheider, A. Gesammelte Abhandlungen ueber die Physiologie des Muskelsinnes. Leipzig. (1898).

‡ von Frey, M. Beiträge zur Sinnesphysiologie der Haut, i, ii, iii, iv, Leipzig. (1894-'97). Aus den Berichten der math.-phys. Cl. d. k. Sachs. Gesellsch. der Wissensch., July 2 and Dec. 3, 1894, March 4, 1895, and Aug. 2, 1897. Also, Untersuchungen ueber die Sinnesfunctionen der menschlichen Haut. Erste Abhandlung. Druckempfindung und Schmerz. Abhandl. d. math.-phys. Cl. der k. Sachs. Gesellsch. d. Wissensch., Leipzig., Bd. xxiii (1896), No. iii, S. 175-266.

\* Eckhard, C. Ueber Reflexbewegungen der vier letzten Nervenpaare des Frosches. *Ztschr. f. rat. Med.*, Heidelberg., Bd. vii (1849), S. 281-310.

¶ Peyer, J. Ueber die peripherischen Endigungen der motorischen und sensiblen Fasern der in den Plexus brachialis des Kaninchens eintretenden Nervenwurzeln. *Ztschr. f. rat. Med.*, Heidelberg., 2 R., Bd. iv (1854), S. 52-77.

another. He believed, however, that the territory innervated by a sensory dorsal root corresponds approximately to the skin which covers the muscles innervated by the corresponding motor ventral root.

The admirable researches of Krause\* show how much can be done by simple dissection and dissociation. Krause also used the so-called reflex method and followed besides the degeneration of nerve fibres after section of the nerves. His studies are of great importance in the history of localization, and must be carefully considered by every one investigating in this field. His conclusions regarding the fifth, sixth, seventh, and eighth cervical roots in the main still hold.

A very important contribution to knowledge is to be found in the research of Türek,† who worked out in detail the areas

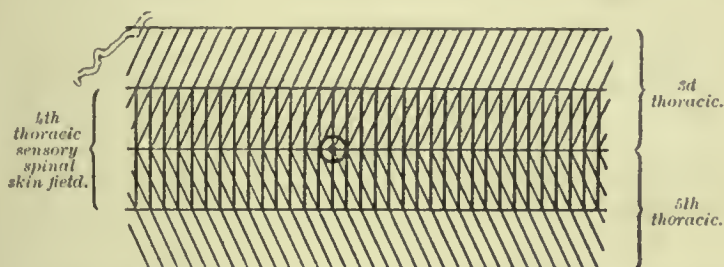


FIG. 191.—Diagram of the position of the nipple in the sensory skin fields of the 4th, 3d, and 5th thoracic spinal roots. The overlapping of the cutaneous areas is represented. (After C. S. Sherrington, *Phil. Tr., Lond., B.*, 1893, vol. clxxxiv, 1894, p. 737.)

for the spinal nerves in the dog from the level of the fourth cervical to that of the fourth sacral. His results are very nearly in accord with those of the more recent studies, and it is rather curious that they have not attracted the attention of anatomists in general. This appears to be due in large part,

\* Krause, W. Beiträge zur systematischen Neurologie des menschlichen Armes. *Arch. f. Anat., Physiol. u. wissenschaft. Med.*, Leipz. (1864), S. 349–357.—Beiträge zur Neurologie der oberen Extremität 4<sup>o</sup>, Leipz. u. Heidelb. (1865).—Die Anatomie des Kaninchen, in topographischer und operativer Rücksicht bearbeitet. 2. Aufl., Leipz. (1884), 8vo.

† Türek, L. Vorläufige Ergebnisse von Experimental-Untersuchungen zur Ermittlung der Haut-Sensibilitätsbezirke der einzelnen Rückenmarks-Nervenpaare. *Sitzungsb. d. k. Akad. d. Wissensch. Math.-naturw. Cl.*, Wien (1856), S. 3; also *Denkschr. d. Wiener Akad.*, Bd. xxxix (1869).

as Sherrington points out, to the difficulty of understanding the experimental notes and drawings left by Türek, and published posthumously. Türek made out distinctly the bandlike areas of distribution, but probably went too far in stating that each spinal nerve has an area of skin belonging to it, which is supplied by it exclusively. He recognized, however, that many of the spinal nerves have a field which they supply in common with some other spinal nerves, and he even made out that the nerves of the upper and lower extremity have no exclusive areas but only common ones.

Of the recent studies may be mentioned those of Walsh,\* Herringham,† Paterson,‡ Sherrington,\* and others.

Sherrington's studies are most painstaking and elaborate, and include experiments upon a large number of frogs, cats, and monkeys. He proceeded as follows: Finding that section of a single root did not cause complete anæsthesia anywhere, but only a diminution of sensation, in order to determine the exact peripheral area of distribution of the dorsal root of a given spinal nerve he cut two or three roots above and below the root in which he was interested. Thus, to determine the area of distribution of the fourth thoracic root he would cut the second and third thoracic roots and the fifth and sixth thoracic roots, while to determine the area of distribution of the third thoracic root he would cut the first and second thoracic roots and the fourth and fifth thoracic roots, and so on. The zone in which sensation still existed could be determined by testing for reflex response. He found that the field of skin belonging to each sensory spinal nerve root overlaps the skin fields of the neighboring spinal nerve roots to a remarkable extent. "The disposition is such that the field laps to a certain extent over the field of the root or roots immediately in front

---

\* Walsh, J. The Anatomy of the Brachial Plexus. *Am. J. M. Sc., Phila., n. s.*, vol. lxxiv (1877), p. 387-399.

† Herringham, W. P. The Minute Anatomy of the Brachial Plexus. *Proc. Roy. Soc. Lond.*, vol. xli (1886), pp. 423-441; also *Phil. Tr. Lond.*, clxxvii (1887).

‡ Paterson, A. M. The Origin and Distribution of the Nerves to the Lower Limb. *J. Anat. and Physiol., Lond.*, vol. xxviii (1893-'94), pp. 24; 169.

\* Sherrington, C. S. Experiments in Examination of the Peripheral Distribution of the Fibres of the Posterior Roots of some Spinal Nerves. *Phil. Tr. Lond. (B) for the Year 1893*, vol. clxxxiv, *Lond. (1894)*, pp. 641-763.



of it, and to a certain extent over the field of the sensory roots immediately behind it. These two overlaps may be termed respectively the *anterior overlap* and the *posterior overlap* of a sensory root field" (Fig. 191).

Sherrington further finds that although in a plexus each spinal nerve root affords separate contributions to several nerve trunks, the cutaneous distribution of the root is composed not of disjoint patches but of patches so connected with one another that the distribution of the entire root forms a continuous field.

When at its simplest, as in the thoracic region, the shape of the cutaneous field of a dorsal root is that of a horizontal band with almost parallel edges, wrapping half way around the body between the mid-dorsal and mid-ventral lines (Figs. 192, 193). This simple zonal shape is departed from in many places, owing probably to the modification which the body segments have individually undergone in the development of the configuration of the animal. This deviation from the simple and regular figure is due in vertebrate forms largely to the outgrowth of the limbs, but with care the root fields can be tolerably accurately defined in the upper and lower extremity. Here the zones run approximately parallel to the long axis of the limb, which is not surprising when the mode of origin of the limb in the embryo is considered.

Reflex reaction is much less easily elicited near the edge of a field, in Sherrington's experiment, than in other parts of each spinal field.

In addition to the *anterior overlap* of a sensory spinal skin field into segmental fields anterior to it, and the posterior overlap into fields posterior already mentioned, each one of these fields has *crossed overlaps* passing into the fellow field of the opposite half of the body, both at the mid-dorsal and at the mid-ventral line. Since the fore and aft overlaps are very marked, Sherrington concludes that each point of skin throughout the body is supplied by at least two sensory spinal roots, in some regions by three. Sherrington denies that the cutaneous fields of the sensory spinal roots correspond closely with the fields of distribution of the motor roots in the skeletal muscles. He states further that the sensory spinal fields do not correspond with the fields of cutaneous distribution of the motor root as judged of by the pilo-motor fibres of those roots. On

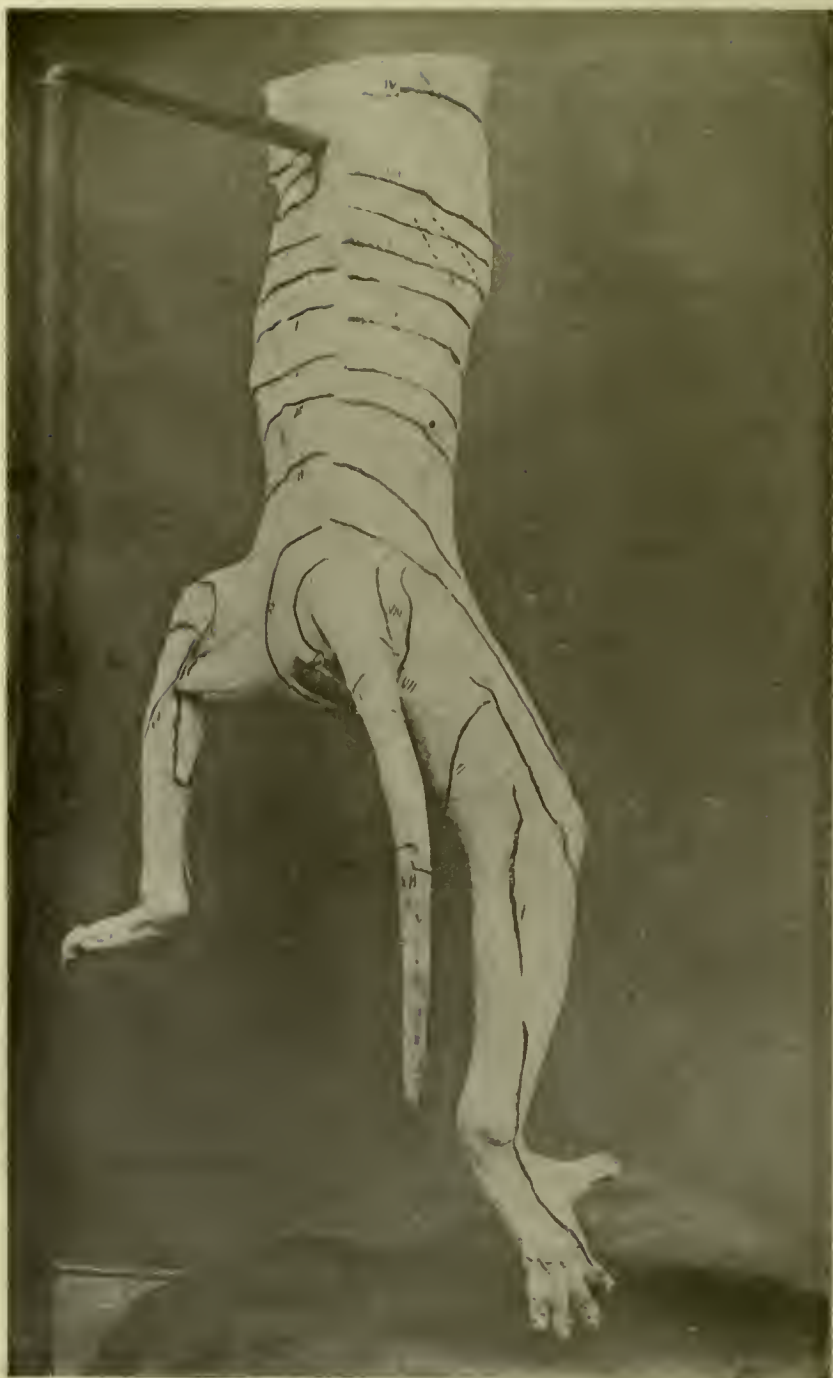

FIG. 192.—Cutaneous fields of dorsal roots of spinal nerves of monkey. Dorsal view. The anterior borders of the skin fields are marked on the left half of the casts, the posterior borders on the right half. (After C. S. Sherrington, *Phil. Tr., Lond.*, 1894, vol. clxxxiv, Pl. 50.)



FIG. 193.—Cutaneous fields of dorsal roots of spinal nerves of monkey. Ventro-lateral view.  
(After C. S. Sherrington, *Phil. Tr., Lond.*, 1894, vol. clxxxiv, Pl. 50.)

the other hand, the pilo-motor fields of the sympathetic ganglia and the cutaneous sensory fields do correspond.

A more recent and apparently very extensive paper by Sherrington I have thus far been able to consult only in abstract.\* In this article Sherrington discusses, in addition to his experi-

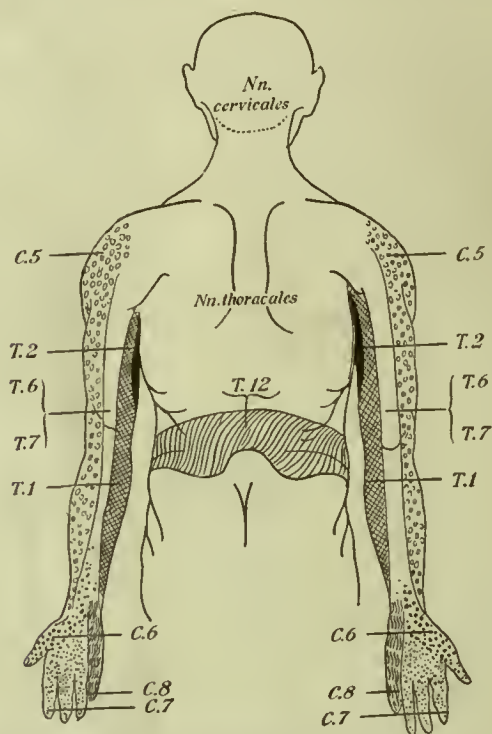


FIG. 194.—Mode of distribution of the dorsal root fibres of the lower cervical and thoracic nerves. (After W. Thorburn, from A. van Gehuchten's *Anatomic du système nerveux*, etc.)

mental studies of the distribution in the skin and muscles of the *Nn. cervicales* and upper *Nn. thoracales* of monkeys, the results of some investigations which concern the *N. trigeminus* and also the behavior of the spinal reflexes in total transverse

\* Sherrington, C. S. Experiments in Examination of the Peripheral Distribution of the Fibres of the Posterior Roots of some Spinal Nerves. Part II. *Phil. Tr. Lond.*, B. (1898), vol. cxc, pp. 45-186. Abstr. by L. Bruns in *Neurol. Centralbl.*, Leipz., Bd. xvii (1898), S. 1041-1046.



lesion. Sherrington has employed largely his method of "remaining anæsthesia" in order to avoid the confusion resulting from "overlapping." Electrical stimulation and studies of degenerated fibres by osmium blackening were also made:

So far as the subject now being considered is concerned, the second chapter of his article interests us most—that dealing with the relation of segmentation to the innervation of the extremities. On superficial examination one might be led to believe that considerable differences exist as regards the limbs in the areas of distribution of the motor and sensory roots of given spinal nerves. The areas of motor distribution form con-

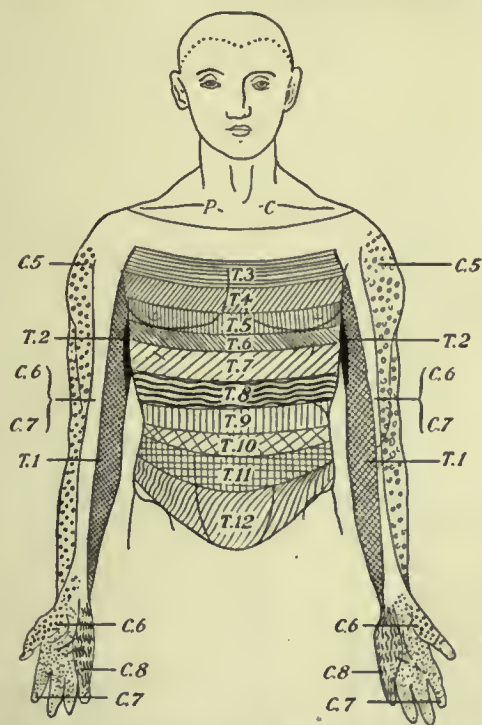


FIG. 185.—Mode of distribution of the dorsal root fibres of the lower cervical nerves and of the thoracic nerves. (After W. Thorburn, from A. van Gehuchten's text-book.)

tinuous zones, all beginning at the middle line of the trunk and extending for a longer or shorter distance into the extremities—that is to say, the same ventral roots of spinal nerves

which innervate muscles at the tips of the extremities also innervate some muscles of the trunk. The areas of distribution of the dorsal roots (sensory) appear, on the contrary, to be separated entirely from the trunk; thus the cutaneous areas supplied by the seventh and eighth cervical roots and by the first thoracic root, for example, nowhere reach the trunk. Sherrington proves, however, that this difference exists only between *skin* nerves and motor nerves, not between sensory nerves in general and motor nerves, for though the sensory dorsal roots above referred to supply no portion of the *skin* of the trunk, they do send sensory branches to the muscles and other subcutaneous structures there. Thus the areas of sensory distribution also form continuous zones involving both trunk and extremity. The sensory nerves for given muscles always originate in the spinal ganglia of the segments which correspond to the motor nerves to the same muscles. Sherrington, with Mall, is of the opinion that the best guide to the understanding of the structural relations in an extremity (arm or leg) is to be found in the neural distribution. His studies show the following: (1) The degree of overlapping of cutaneous areas of individual dorsal roots varies greatly, being much more marked in the extremities than in the trunk. (2) The intermixing of the fields of dorsal roots is very much greater than that of the peripheral nerve trunks, even in the hand and foot. Thus, while there is very little overlapping of the areas supplied by the N. medianus, N. ulnaris, and N. radialis, yet when the innervation of the hand by dorsal roots is examined it is found that a large middle area of the hand and fingers is supplied by all three of the seventh and eighth cervical and first thoracic dorsal roots. (3) A certain parallelism between the overlapping of the skin areas of the various dorsal roots and the anastomoses between the derivatives of different roots in single muscles is recognizable. Thus, in the extremities very few muscles are monomeric (unisegmental), the majority being polymeric (two, three, or four segments). The intercostal muscles are monomeric. The muscles of the hand and foot, on the contrary, exhibit the most marked mixing of motor roots from different segments. (4) As regards the functional significance of the overlapping, Sherrington thinks there is none; the anastomoses have, on the contrary, a morphological basis.

In this connection it is interesting to compare with the results of experiments on animals the findings of clinicians in pathological human cases. We refer to the researches of Thorburn,\* Ross,† Dana,‡ Starr,\* Mackenzie,|| Head,<sup>^</sup> Kocher,<sup>^</sup> and Cushing.‡

Thorburn's studies refer mainly to the peripheral distribution in human beings of the fibres of the dorsal roots of the plexus cervicalis and of the plexus lumbo-sacralis and their corresponding segments in the spinal cord. His studies are based mainly upon cases of traumatic injury to the spinal cord, and his results are illustrated in the accompanying figures. Starr's valuable analysis of a vast amount of clinical material is epitomized in the table, introduced in Chapter LV, in which the lower motor neurones are discussed.

\* Thorburn, W. Cases of Injury to the Cervical Region of the Spinal Cord. *Brain*, Lond., vol. ix (1886-'87), pp. 510-543.—On Injuries of the Cauda Equina. *Brain*, Lond., vol. x (1887-'88), pp. 381-407.—Spinal Localizations as indicated by Spinal Injuries. *Brain*, Lond., vol. xi (1888-'89), pp. 289-324.—The Distribution of Paralysis and Anæsthesia in Injuries of the Cervical Region of the Spinal Cord. *Brit. M. J.*, Lond. (1888), vol. ii, pp. 1382-1385.—A Contribution to the Surgery of the Spinal Cord. Philadelphia (1889).

† Ross, James. On the Segmental Distribution of Sensory Disorders. *Brain*, Lond., vol. x (1887-'88), pp. 333-361.

‡ Dana, C. L. A Clinical Study of Neuralgias, and of the Origin of Reflex or Transferred Pains. *N. Y. Med. J.*, vol. xvi (1887), pp. 121-127.

\* Starr, M. Allen. Local Anæsthesia as a Guide in the Diagnosis of Lesions of the Lower Spinal Cord. *Am. J. Med. Sc.*, Phila., n. s., vol. civ (1892), pp. 15-35; and Local Anæsthesia as a Guide in the Diagnosis of Lesions of the Upper Portion of the Spinal Cord. *Brain*, Lond., vol. xvii (1894), pp. 481-512.

|| Mackenzie, J. Contribution to the Study of Sensory Symptoms Associated with Visceral Disease. *Med. Chron.*, Manchester, vol. xvi (1892), pp. 293-322.

<sup>^</sup> Head, H. On Disturbances of Sensation with Especial Reference to the Pain of Visceral Disease. *Brain*, Lond., vol. xvi (1893), pp. 1-133; *ibid.*, vol. xvii (1894), Part III, pp. 339-480; and *ibid.*, vol. xix (1896), pp. 153-276.

<sup>^</sup> Kocher, T. Die Verletzungen der Wirbelsäule zugleich als Beitrag zur Physiologie des menschlichen Rückenmarks. *Mitt. a. d. Grenzgeb. d. Med. u. Chir.*, Jena, Bd. i (1896), S. 415-480.—Die Läsionen des Rückenmarks bei Verletzungen der Wirbelsäule. *Ibid.*, S. 481-660.

‡ Cushing, Harvey W. Hæmatomyelia from Gunshot Wounds of the Spine. *Am. J. M. Sc.*, Phila., vol. cxii (June, 1898).

The paper of Ross is brimful of suggestiveness, and should be read by every one who wishes to enter at all thoroughly

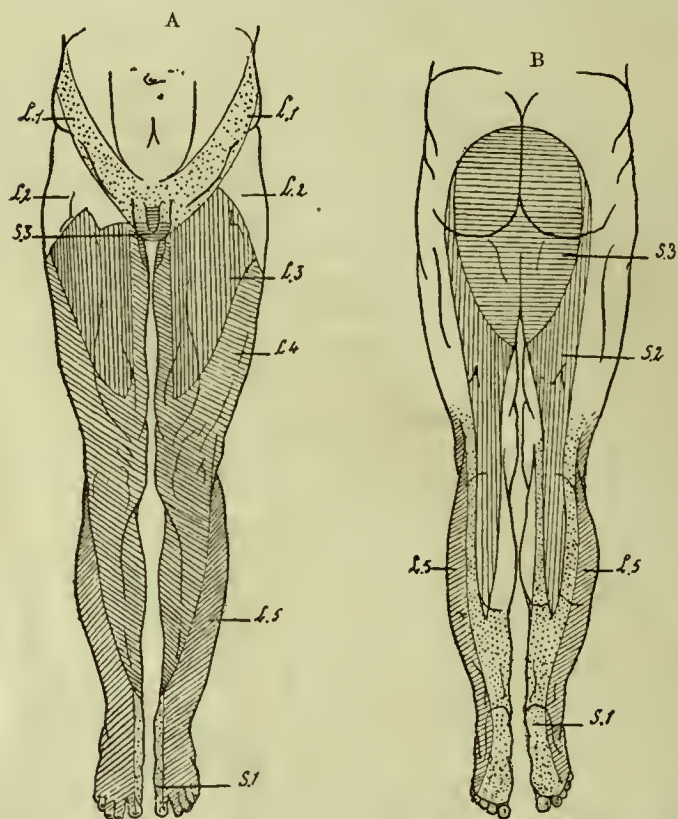


FIG. 196.—Mode of distribution of the dorsal root fibres of the lumbar and sacral nerves. (After W. Thorburn, from A. van Gehuchten's text-book.) A, ventral aspect; B, dorsal aspect.

into the bibliography of sensory localization. Scarcely less interesting are the accurate observations of Dana with regard to the pain accompanying visceral disease, and Starr is right in his complaint that too little attention has been paid to Dana's studies in subsequent investigations upon the same subject. A comparison of Dana's diagrams (Figs. 197, 198) with those of Head, Thorburn, Starr, and others, show how closely the ideas of a later date correspond with those advanced by him in 1887.



The extended studies of Head are very ingenious, and have attracted widespread attention. He, like Clifford Allbutt, Ross, Dana, and others, had noticed that the cutaneous tenderness (pathological associated sensations) accompanying certain disorders of the stomach tend to occupy definite tracts of skin with definite borders. This led him to investigate the pain and accompanying tenderness consequent upon disturbances of other organs, and he found that these sensory disturbances also followed definite lines. Stimulated by the suggestive papers of Ross, he thought it probable that these areas might bear some definite relation to nerve distribution, and with this in view studied the distribution of a large number of cases of herpes zoster, hoping that they might throw some light upon the significance of the tender areas in visceral disease. To his surprise he found that the areas occupied by herpes zoster corresponded exactly to those with which he was familiar in visceral disturbances. Further study showed that the areas represented the distribution of either a single nerve root or a segment of the spinal cord.

Head inclines to the view that the distribution of the nerve roots is somewhat different from the distribution for the segments inside the spinal cord. His reasons for thinking so are briefly these: Whereas Sherrington found that the areas of cutaneous supply from any two roots definitely overlapped, Head states that his areas do not overlap at all, or if so, only very inconsiderably. Sherrington's areas, it is true, apparently represent the root supply for the sensation of touch, while Head's areas correspond rather to pain sensations and trophic sensations. It might be assumed that whereas the distribution of the fibres for the sensation of touch in the various dorsal roots overlap considerably, those for pain do not overlap. Sherrington, however, states expressly that he used touch and pain stimuli indifferently as a test for the presence or absence of sensation, and Head feels sure from his observations in five instances of surgical division of a single dorsal root in man that not only was there absence of anaesthesia to touch after division, but in most instances the sensation of heat, pain, and cold was also not materially disturbed. Head believes, therefore, that whereas Sherrington's areas represent the true root supply, his areas correspond to the supply, not of roots, but of segments of the spinal cord from which the roots in part arise. He believes

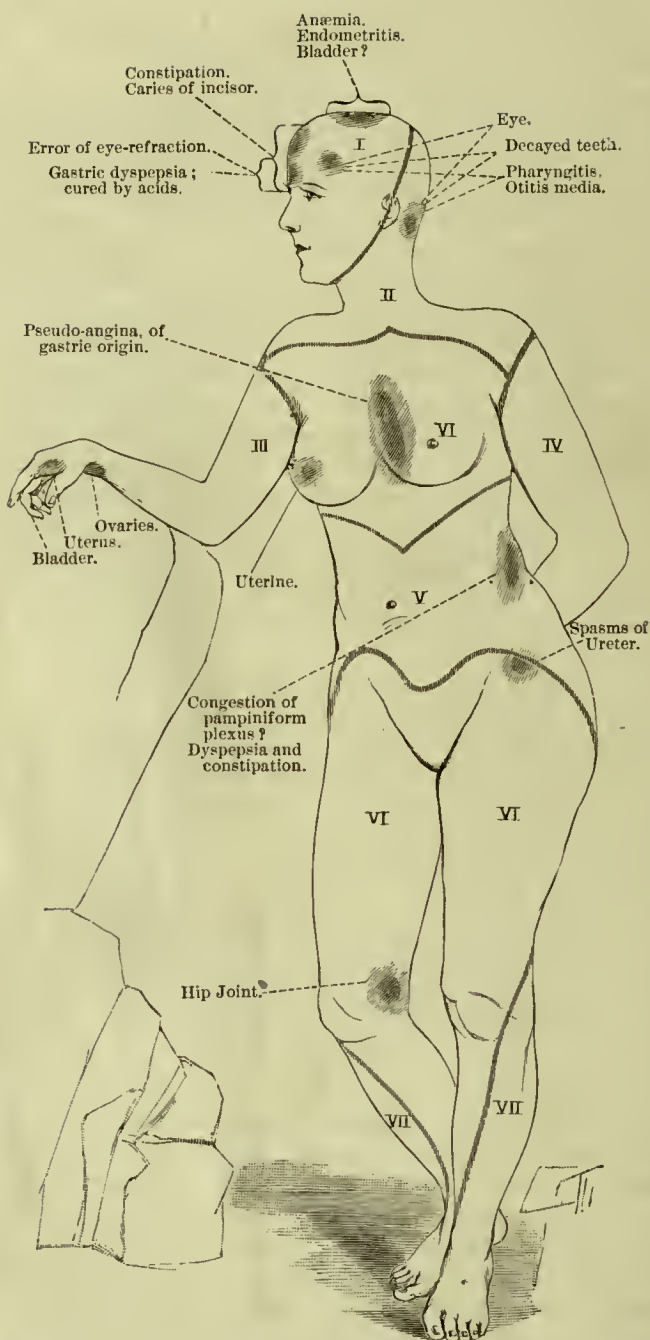


FIG. 197.—Referred pain in visceral disturbances. (After C. L. Dana, N. Y. Med. Jour. for July 30, 1887, p. 125.)

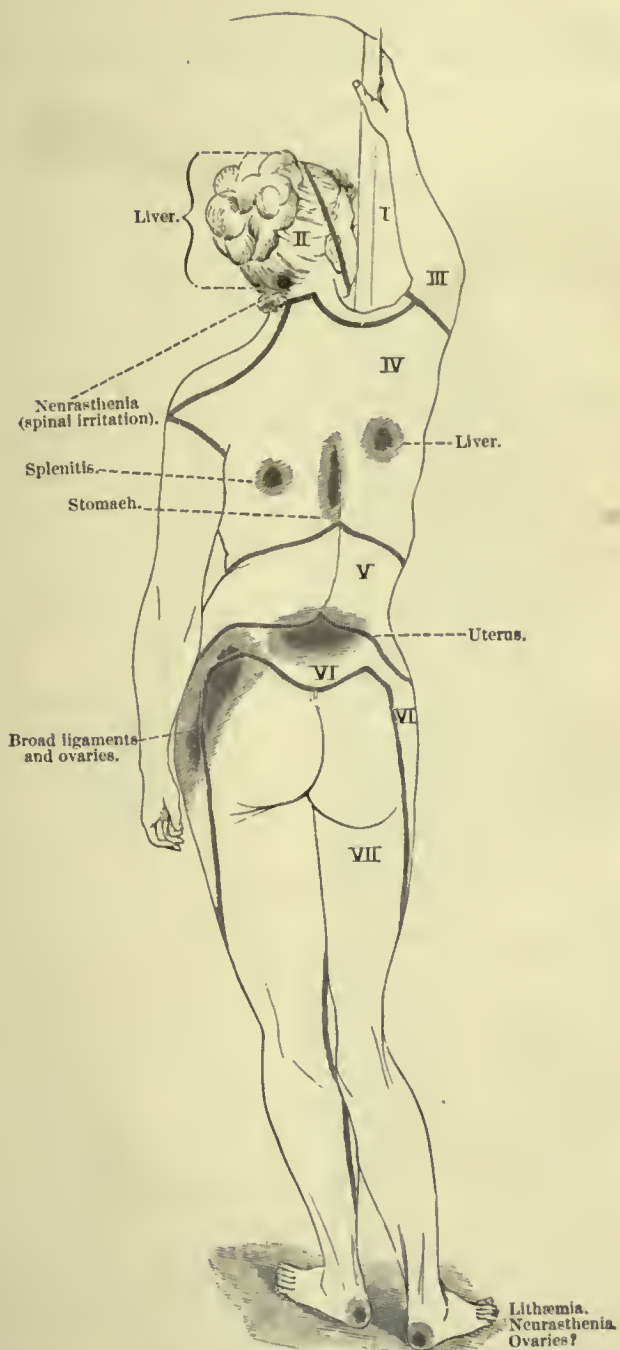


FIG. 198.—Referred pain in visceral disturbances. (After C. L. Dana, N. Y. Med. Jour. for July 30, 1887, p. 125.)

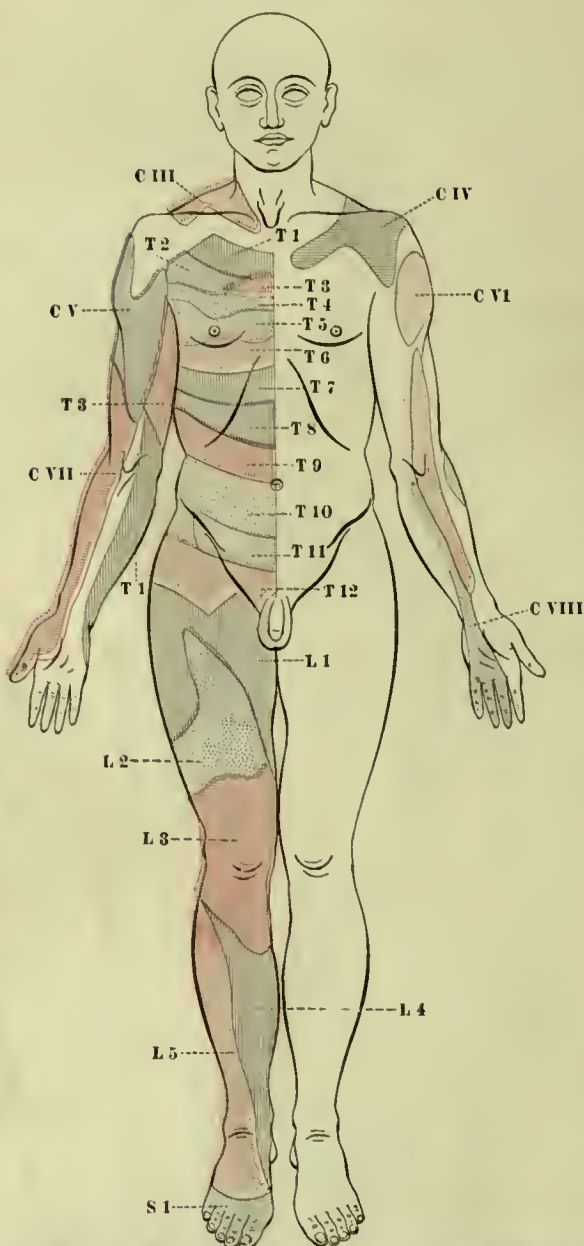


FIG. 199.—Areas of pain sensation in visceral disease. (After H. Head, taken from W. Osler, *The Principles and Practice of Medicine*, 3d ed., N. Y., 1898, p. 919, Fig. 7.)



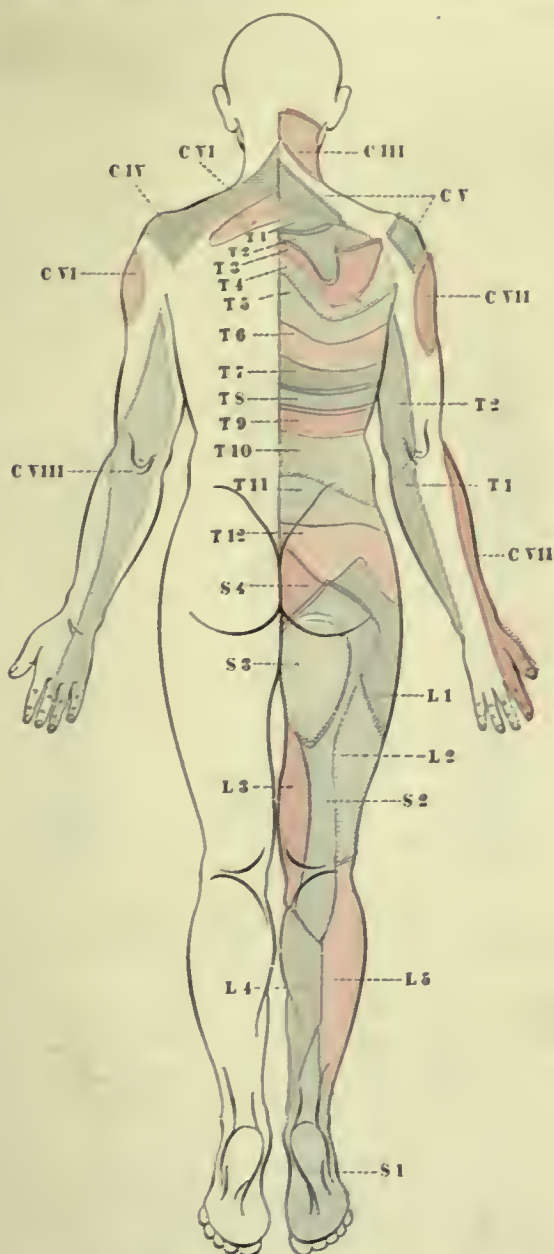


FIG. 200.—Areas of pain sensation in visceral disease. (After H. Head, taken from W. Osler, *The Principles and Practice of Medicine*, 3d ed., N. Y., 1899, p. 911, Fig. 8.)

that the mechanism for the sensation of touch in the various spinal segments must overlap, while that for the sensations of pain, heat, and cold does not overlap, at any rate to the same extent. The areas as outlined by Head are indicated in the accompanying diagrams (Figs. 199, 200).

The localization within the spinal cord can not, however, be said to be satisfactorily settled, and much research is still necessary.\* The clinicians often have considerable difficulty

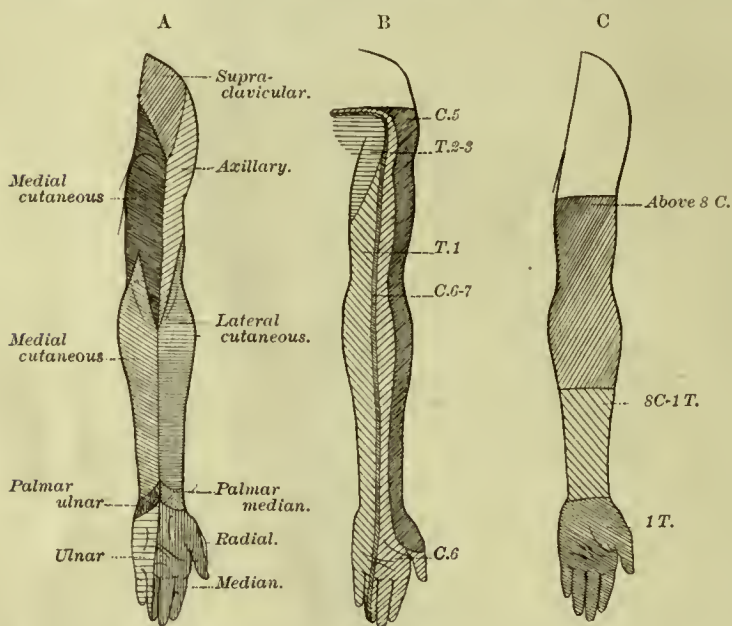


FIG. 201.—Types of anæsthesia. A, peripheral (from Hasse); B, spinal, root type of Chipault (from Kocher); C, cerebral, medullary type of Chipault (from Brissaud). (After P. C. Knapp, *Tr. Amer. Neurol. Assoc.*, 1897.)

in deciding as to the site of a lesion which causes disturbances of sensation. These difficulties have recently been discussed in an instructive paper by Knapp.† It is especially in cases of syringomyelia that the findings may be puzzling. In the dia-

\* An interesting recent paper is that of C. E. Beevor, *The Distribution of Motor and Sensory Symptoms from Injury to the Roots of the Braehial Plexus*. *Tr. M. Soc., Lond.*, vol. xix (1896), pp. 72-79.

† Knapp, P. C. *Anæsthesia in Diseases of the Spinal Cord*. *Tr. Am. Neurol. Ass. for 1897*. New York (1898), p. 81.



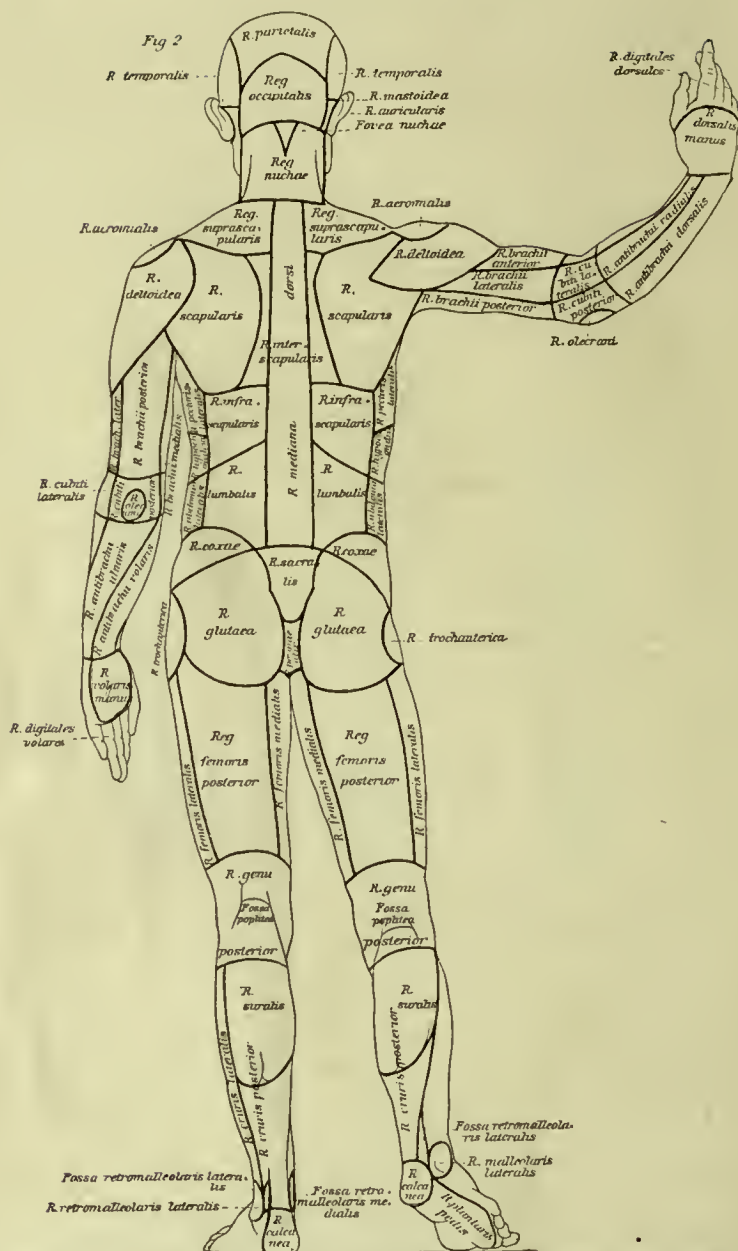


FIG. 203.—Regiones corporis humani. (After W. His, Die anatomische Nomenclatur, Leipz., 1895, Taf. ii.)



gram (Fig. 201), combined by Knapp from various sources, the so-called peripheral, spinal, and cerebral types of anæsthesia in the left arm are indicated. A lesion of the cerebral type can be due not only to diseases of the cerebrum, but to lesions inside the spinal cord.

That the areas of cutaneous sensory disturbance do not correspond to the regions on the surface of the body which have been defined by the topographical anatomists will be clear from the accompanying diagrams, which are here introduced for convenience of reference (Figs. 202, 203).

(A) Centripetal Neurones of the First Order collecting Bodily Impressions.

CHAPTER XXVIII.

PERIPHERAL CENTRIPETAL NEURONES.

Relations of peripheral centripetal neurones to the central nervous system—  
The sensory spinal nerves—The sensory cerebral nerves.

THE neurones collecting bodily impressions will first be described. Part of them are connected with the spinal cord, the remainder with the rhombencephalon. There are, as every one knows, thirty-one pairs of spinal nerves, including eight cervical, twelve thoracic, five lumbar, five sacral, and one coccygeal (Fig. 204). If we include the two rudimentary coccygeal nerves, which Rauber has described, the total number is increased to thirty-three. All of the spinal nerves have ganglia upon their dorsal roots (Fig. 205). It is in these ganglia that the cell bodies of the spinal peripheral sensory neurones are situated. Of the cerebral nerves not all possess sensory functions; outside of the organs of special sense only those which are provided with ganglia in their course are known to carry centripetal impulses. Excluding the nerves of special sense—that is, the olfactory, optic, and cochlear nerves, and the nerves concerned in the sense of taste (portions of the glossopharyngeal, trigeminus, and nervus intermedius)—we have left as sensory cerebral nerves the sensory portion of the nervus trigeminus with its ganglion semilunare (Gasseri), the nervus intermedius of Wrisberg with its geniculate ganglion, the nervus vestibuli with its ganglion vestibuli, the nervus vagus with its ganglion jugulare and ganglion nodosum, the nervus glossopharyngeus with its two ganglia (ganglion superius and ganglion petrosus), and occasionally, perhaps, a portion of the hypoglossus nerve, since in the embryo at any rate it is sometimes provided with a sensory ganglion (Froriep). In these various ganglia are situated the cell bodies

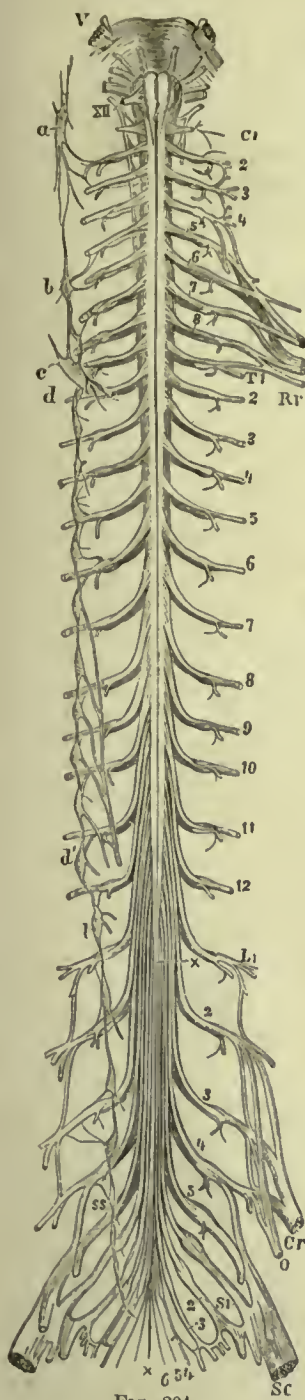


FIG. 204.

FIG. 204.—Spinal cord in connection above with the medulla oblongata and pons. (After A. Rauber, *Lehrbuch der Anatomie des Menschen*, V. Aufl., Leipz., 1898, Bd. ii, S. 504, Fig. 485.) *V*, Nervus trigeminus; *XII*, nervus hypoglossus; *C*<sub>1</sub>, first cervical nerve; *C*<sub>2-8</sub>, second to eighth cervical nerve; *T*<sub>1-12</sub>, first to twelfth thoracic nerve; *L*<sub>1-5</sub>, first to fifth lumbar nerve; *S*<sub>1-5</sub>, first to fifth sacral nerve; *C*, Nervus coccygeus; *x, x*, filum terminale of the spinal cord. From the root marked *L*<sub>1</sub> to *x*, cauda equina; *Rr*, plexus brachialis; *Cr*, Nervus femoralis; *Sc*, Nervus ischiadicus; *O*, Nervus obturatorius; the enlargements opposite *L*<sub>3</sub>, *4*, and *5* represent the spinal ganglia on the dorsal roots. On the left side of the figure the sympathetic trunk is shown. *a* to *ss* are ganglia; *a*, ganglion cervicale superius; *b* and *c*, ganglion cervicale medium et inferius; *d*, first thoracic ganglion; *d'*, last thoracic ganglion; *l*, first lumbar ganglion; *ss*, first sacral ganglion.

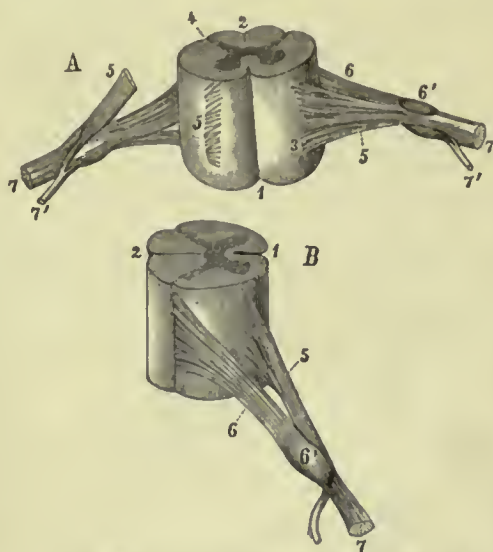


FIG. 205.—Portions of the pars cervicalis of the spinal cord with nerve roots. (After A. Rauber, *Lehrbuch der Anatomie des Menschen*, V. Aufl., Leipz., 1898, Bd. ii, S. 283, Fig. 248.) *A*, spinal cord seen from the ventral surface. On the right side the ventral fila radicularia have been cut through. *B*, spinal cord seen from the lateral surface.—*1*, ventral median fissure; *2*, dorsal median sulcus; *3*, sulcus lateralis ventralis, whence the ventral fila radicularia emerge; *4*, sulci laterales dorsales through which the dorsal root fibres enter the spinal cord; *5*, radix ventralis going past spinal ganglion cut through on the right side in Fig. *A*; *6*, radix dorsalis emerging from the ganglion spinale (*6'*); *7*, *N. spinalis* immediately after its formation through the union of the radix ventralis and dorsalis dividing into *7*, a ramus ventralis, and *7'*, a ramus dorsalis. The ramus communicans and the ramus meningeus are not shown in this figure.

of the peripheral sensory neurones, of the variety under discussion, pertaining to the rhombencephalon.

It is especially to be noted that, if we leave out those gathered from the viscera by means of the sympathetic nerves, all the impressions collected at the periphery of the body and

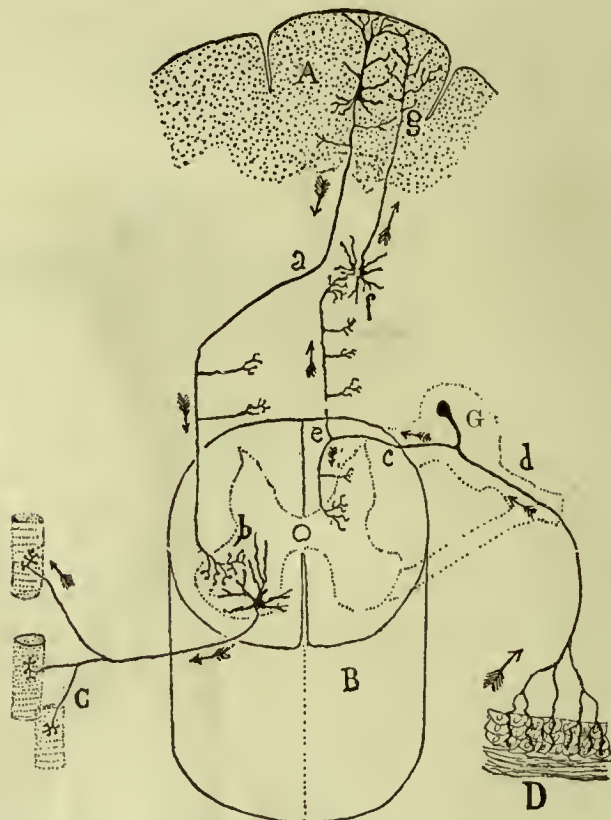


FIG. 206.—Scheme of peripheral spinal sensory neurone showing the peripheral process, *d*, extending to a peripheral sensory surface *D* and a central axone *c*, entering the spinal cord through the dorsal root of a spinal nerve there bifurcating at *e* into an ascending and a descending limb which give off numerous collaterals. The cell body is shown in the spinal ganglion *G*. Other neurones are schematically shown, but need not be considered here. (After S. Ramón y Cajal, *Les nouvelles idées*, etc. Translated by Azoulay, Paris, 1894, p. 25, Fig. 6.)

from the internal organs are carried into the central nervous system (spinal cord and brain stem) by means of one set of neurones (Fig. 206). The total number of individual neurones



concerned is enormous, but there is no superimposition of neurones in the mechanism here described. A centripetal impulse originating at the periphery reaches the primary end-station of the sensory neurones inside the central nervous system after having passed through only one neurone. Although for the origin of any given sensation centripetal impulses start at the periphery, usually in a considerable number of different neurones, each of these extends as far as some primary end-station inside the central nervous system, not requiring to pass through any secondary neurone on the way.\*

---

\* This is in all probability not true of the sensory impulses collected by means of the neurones of the sympathetic system; these impulses, it is probable, pass through a chain or series of individual neurones before arriving in the cerebrospinal system. They are carried by means of the rami communicantes into the dorsal roots of the spinal nerves. Their further fate is not yet clear. Some of the sympathetic axones end within the spinal ganglia about the bodies of spinal ganglion cells, and the centripetal impulses which they carry could then be taken into the spinal cord by means of the central prolongations of the spinal ganglion cells. It has been asserted by some investigators that a certain number of sympathetic axones pass from the rami communicantes directly through the ganglia, or past them into the dorsal roots and so into the spinal cord without interruption. More research is needed before entirely satisfactory statements can be made regarding these points.

## CHAPTER XXIX.

### GENERAL DESCRIPTION.

The spinal ganglia—Bipolar cells in embryo—Unipolar cells in adult—Peripheral sensory fibres—Central axones to dorsal funiculi—Fibres exogènes of P. Marie—Nuclei terminales—Phylogenetic studies—The structure of human spinal ganglion cells—Studies of von Lenhossék, Lugaro, and Nissl.

#### 1. Centripetal Neurones of the First Order (collecting Bodily Impressions) connected with the Spinal Cord.

THE perikaryons of all the sensory neurones that we are describing are situated outside the central nervous system (in human beings) in marked contrast to the cell bodies of the peripheral motor neurones, which are situated within the columnæ griseæ of the spinal cord. In Section IV the embryological origin of these neurones has been described. It will be recalled that in the human embryo they appear near the spinal cord and soon come to occupy positions lateral from it. At a very early period the distal and central processes of the spinal ganglion cells are recognizable. It has also been pointed out that there is a gradual transition in the embryo from the bipolar condition of the cells to the unipolar condition which is characteristic of the adult. In considering the anatomical distribution and physiological function of these peripheral sensory neurones their bipolar nature has ever to be borne in mind, the unipolar condition of the adult being the result simply of an attenuation of a portion of the cell body, doubtless an example of adaptation to environment, but whether for economy of room or for improvement of nutritive relations we do not know. It has been stated that the distal process of the spinal ganglion cell grows to the periphery and becomes the axone of a peripheral sensory nerve fibre, or, since it often divides, it may take part in the formation of many peripheral sensory nerve fibres.

The central prolongation of the spinal ganglion cell grows directly into the spinal cord. The total mass of central prolongations from a single ganglion forms the dorsal root of one spinal nerve (Fig. 207). The dorsal fasciculi of white matter within the spinal cord are built up in the main of the intramed-

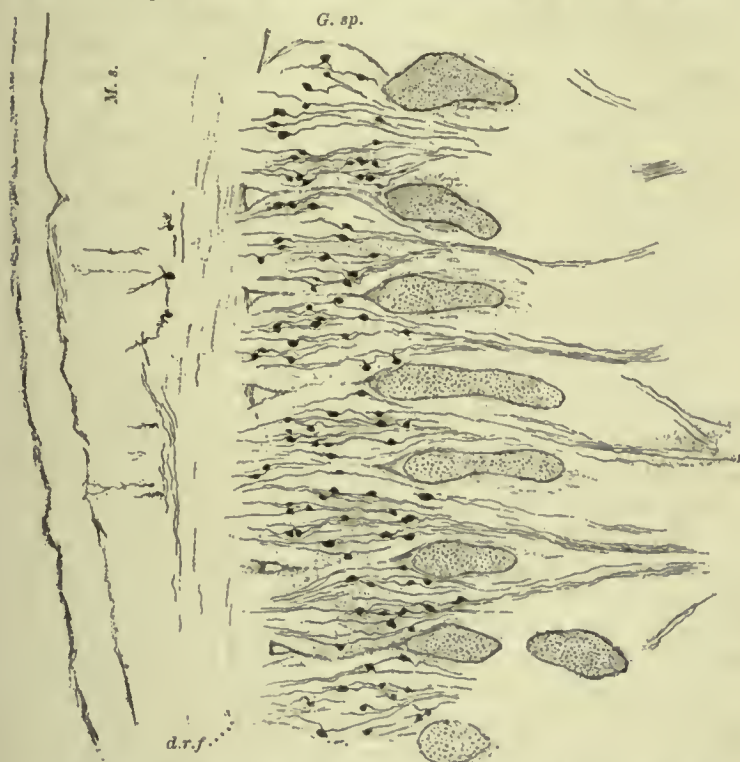


FIG. 207.—Sagittal section through seven spinal ganglia of embryo mouse, 10 mm. long. Cervical region. Method of Golgi-Ramón, double impregnation. Preparation and drawing by C. H. Bunting. *d. r. f.*, dorsal root fibres; *G. sp.*, ganglion spinale; *M. s.*, medulla spinalis.

ullary prolongations of the dorsal root fibres. They are thus formed chiefly of fibres extrinsic or exogenous to the cord (*fibres exogènes* of P. Marie). These dorsal root fibres somewhere in the cord, medulla, or cerebellum end by ramifying among and upon the cell bodies (perikaryons) and dendrites of other neurones in what we now call the *nuclei terminales*, or the “primary end-stations of the sensory conduction paths.”

This description holds good for the peripheral sensory neu-

rones of the cerebrum as well as for those of the cord. There too the cell bodies are situated outside the brain in the ganglia on the cerebral nerves, the peripheral prolongations run to the surface of the body as medullated fibres, the medullated central prolongations run into the nerve centres to end in the primary end-stations or nuclei of termination of the cerebral nerves. In the last are situated the cell bodies and dendrites of other neurones (of the second order) which can take up the impulses and carry them further.

While it is true that nearly all the embryonic bipolar cells of the spinal and cerebral sensory ganglia become later unipolar in human beings, in many of the lower forms, for example in the fish, they remain bipolar throughout life. It is interesting to remember that in the ganglion vestibuli of human beings (as well as in the ganglion cochleæ) the bipolar condition is retained throughout life just as in the fish.

Phylogenetic studies have excited a great deal of interest in connection with the original position of these peripheral sensory neurones.\* In some animals like *Lumbricus* the cell bodies of the sensory neurones are situated in the epithelial surfaces of the animal (Fig. 208), the short peripheral process or dendrite passing between the other epithelial cells toward the surface, the central prolongation running from the skin into the nerve centres. Other animals (like *Nereis*) possess neurones in which the cell body is no longer located in the peripheral epithelial surface, but is situated near it, or at various points between it and the central organ. The further the cell body from the epithelium, the greater of course is the length of its distal process. In human beings, as has been stated, and in other mammals the cell body is almost as far distant as possible from the peripheral surface, inasmuch as the spinal ganglia are very close to the central cerebrospinal nervous system and very far removed from the peripheral sensory surfaces. One vertebrate, amphioxus, is peculiar in that its bipolar sensory neurones are situated within the spinal cord (Retzius). There are animals—as, for example, *Pterotrachea*—which in a comparatively limited space show a whole number of transitional stages be-

---

\* Cf. Retzius, G. Ueber die neuen Prinzipien in der Lehre von der Einrichtung des sensiblen Nervensystems. Biol. Untersuch., Stockholm, n. F., Bd. iv (1829), S. 49–56.



tween the peripheral position of the cell body and the central (Edinger). It is of the greatest interest to find that in human beings we have one instance (in the domain of the special senses, however) in which the cell body of a peripheral sensory neurone is situated among the epithelial cells of a sensory surface. I refer to the cell bodies of the peripheral olfactory neurones (Fig. 157, *vide supra*, p. 262).

The ganglion spirale and ganglion vestibulare in human beings present stages transitional between the peripheral olfactory neurone and the ordinary peripheral spinal neurone, since

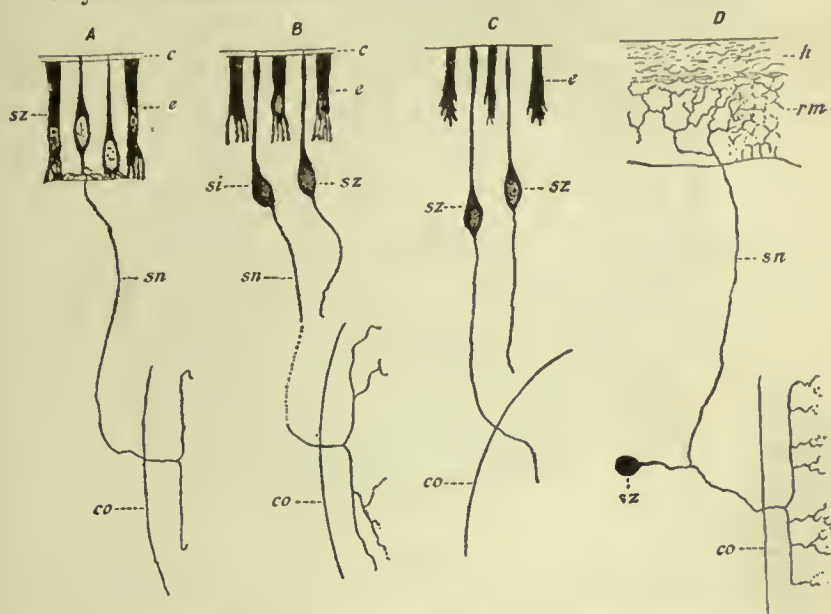


FIG. 208.—Peripheral centripetal neurones of various animals. (After G. Retzius, *Biol. Untersuch.*, Stockholm, Bd. iv, 1892, S. 56, Figs. 1, 2, 3, and 4.) *A*, oligochaete worms (*Lumbricus*); *B*, polychaete worms (*Nereis*); *C*, molluscs (*Limax*); *D*, vertebrates. The gradual change in the position of the perikaryon in the phylogenetic series is interesting. *e*, epithelial cells of sensory surface; *c*, cuticle; *sz*, perikaryon of peripheral centripetal neurone; *rm*, rete Malpighii of epidermis; *sn*, axone; *co*, central nervous system.

the cell bodies of the neurones in these ganglia are situated out near the sensory surfaces, whence they collect impressions, though not actually in them.

The structure of the cell bodies situated within the spinal ganglia has been described at some length in Section III and

need not be discussed again here. In Fig. 209 is shown a large type of cell from the human spinal ganglion taken from von Lenhossék's recent article, and in Fig. 210 certain other types.\* For accurate measurements of the dimensions of the spinal ganglion cells of different animals, adult and embryonic, the reader is referred to the article of Cavazzani.†

The medullated peripheral prolongations of the spinal ganglion cells run, along with the medullated motor axones, out into the peripheral nerves (Fig. 205 ; *vide supra*).

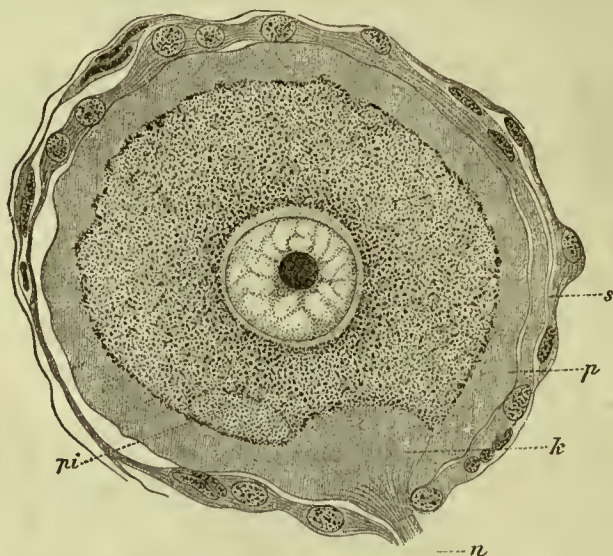


FIG. 209.—Large spinal ganglion cell from a healthy man with connective-tissue capsule. (After M. von Lenhossék, 1896, taken from A. Rauber's text-book.) Staining with toluidin blue and eosin. *s*, endothelial sheath ; *p*, peripheral clear zone of the protoplasm ; *k*, axone hillock ; *pi*, pigment.

In the dog five distinct types of cells in the spinal ganglia have been described by Lugaro.‡ The types to be found in the rabbit have been carefully studied and described by Nissl.

After dividing a variable number of times, these medullated

\* von Lenhossék, M. Ueber den Bau der Spinalganglienzellen des Menschen. Arch. f. Psychiat. u. Nervenkr., Berl., Bd. xxix (1896-'97), S. 346-380.

† Cavazzani, E. Intorno ai gangli spinali. Arch. ital. di clin. med., Milano, vol. xxxvi (1897), pp. 41-53.

‡ Lugaro, E. Sulle alterazioni delle cellule nervose dei ganglia spinali. Riv. di patol. nerv. e ment., Firenze, vol. i (1896), Nos. 8 and 12.

axones reach the peripheral organs, whence they collect cellulipetal impulses. All of these peripheral fibres end free; at any rate, we have as yet no evidence of connection *by continuity* of the termination of one of these fibres with any other cell. That

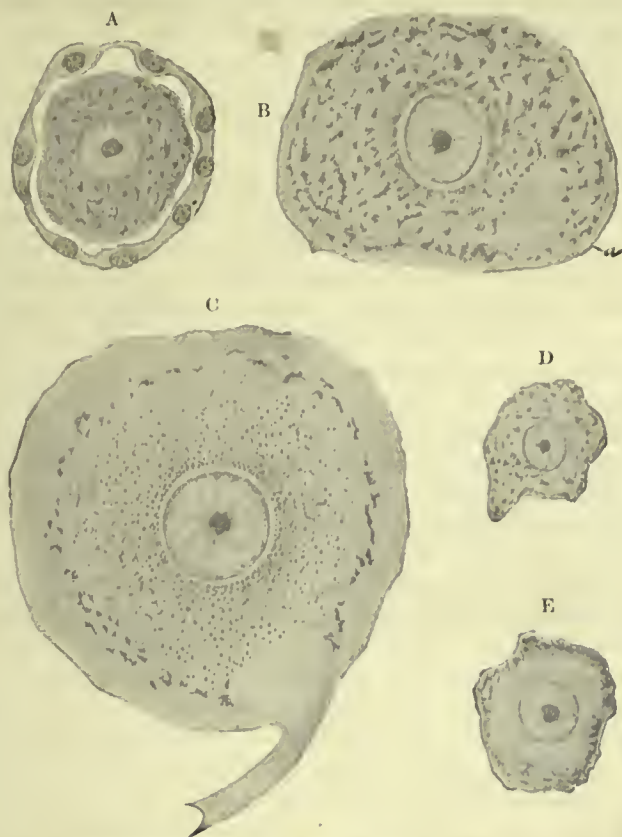


FIG. 210.—Several types of spinal ganglion cells. (After M. von Lenhossék, Arch. f. Psychiat., Bd. xxix, 1896-97.) A and D, small chromophile spinal ganglion cells, somewhat shrunken; B, medium-sized spinal ganglion cell with coarse tigroid masses; a, pigment; C, large pale cell, peripheral garland of tigroid evident; E, small chromophile spinal ganglion cell, interior of cell presents a homogeneous appearance, garland of tigroid masses at the periphery.

the peripheral endings may actually penetrate into epithelial or other cells seems likely from the studies of Engelmann, Apáthy, and others. The modes of ending in the peripheral organs are, however, very variable.

It was long thought that ganglion cells were situated in Meissner's corpuscles in the skin, in the so-called *Tastzellen* of Merkel, and in other peripheral end organs, and that these send their axis-cylinder processes into the nerve centres. But this view has been shown to be false. The peripheral prolongations of spinal ganglion cells end free in the shape of disklike expansions in these structures.

On account of their functional relations the so-called sensory nerve endings might be, perhaps, better called peripheral nerve beginnings.

No less than one hundred and eighty-five articles concerning the endings of sensory nerves in vertebrates have recently been collected and reviewed by Kallius, of Göttingen.\* As this author states, the different varieties of nerve endings may be classified in different ways, either according to the endings themselves or to the tissues in which they are situated. They may terminate independently of any special end organ, or the free endings of the fibres may be inclosed in certain definite, specially differentiated, terminal corpuscles. The most convenient method of describing them is as (1) those incident to epiblastic and hypoblastic structures, and (2) those incident to mesoblastic structures.

---

\* Kallius, E. Endigungen sensibler Nerven bei Wirbeltieren. Merkel Bonnet's Ergebn. d. Anat. u. Entwicklungsgesch., Bd. v. (1895), Wiesbaden, 1896, S. 55-94.



## CHAPTER XXX.

### THE MEDULLATED PERIPHERAL AXONES OF THE PERIPHERAL CENTRIPETAL NEURONES AND THEIR TERMINAL APPARATUS.

Centripetal nerve endings or beginnings—Classification—Nerve beginnings in epiblastic and hypoblastic tissues—Naked beginnings in epithelium—Epidermis—Mucous membranes—End-platelets—Merkel's Tastzellen and Tastmenisci—Grandry's corpuseles—Nerve beginnings on hairs, hair follicles, and teeth—Nerve beginnings in lung, liver, pancreas, stomach, and intestine—Nerve beginnings in mammary gland. .

#### *Sensory Nerve Beginnings in Epiblastic and Hypoblastic Tissues.*

IN the skin the fibres representing divisions of peripheral prolongations of spinal ganglion cells lose their myelin sheaths before entering the epithelium. Once inside the epidermis, they branch typically, giving off first tangential branches, from which secondary finer divisions pass through the stratum germinativum into the upper layers. The individual fibrils can pass upward or downward, but always, or nearly always, end in the epithelium itself. At the tips of the individual fibres very fine bulblike processes are often seen. Many believe that the nerve fibrils end inside the epithelial cells. Certain it is that the nodules can be seen pressing into the surface of the cell, but that they actually are to be considered as intracellular nerve endings is at present doubtful. The weight of evidence is, on the whole, against this view.

In mucous membranes covered by squamous lamellated epithelium—for example, the tongue and œsophagus (Fig. 211)—the relations are similar to those in the epidermis. Retzius\* has pointed out a peculiarity of the terminals of the nerves in

---

\* Retzius, G. Ueber die sensiblen Nervenendigungen in den Epithelien bei den Wirbelthieren. Biol. Untersuch., Stockholm, n. F., Bd. iv (1892), S. 37-44.—Einige Beiträge zur Kenntniss der intraepithelialen Endigungsweise der Nervenfasern. Biol. Untersuch., Stockholm (1894), n. F., Bd. vi, S. 62-64.

the epithelium lining the urinary passages. Thus, in the bladder, for example, the sensory nerve fibres run tangentially for long distances, making marked curves about the cells. The

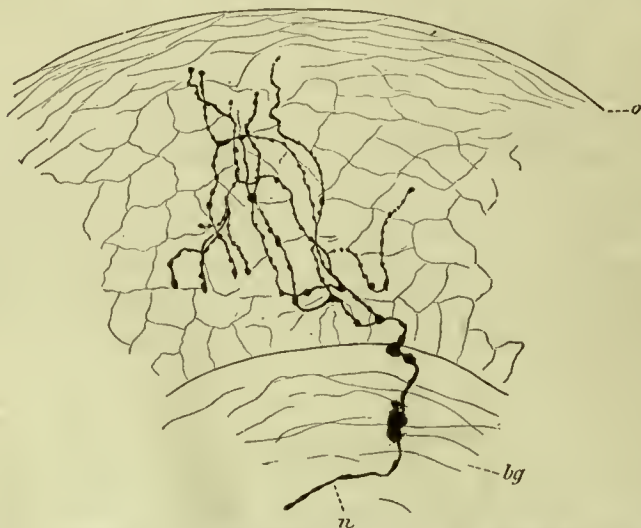

FIG. 211.—Nerve fibrils in the epithelial lining of the œsophagus; method of Golgi. (After G. Retzius, *Biol. Untersuch.*, Stockholm, n. F., Bd. iv, 1892, Taf. xiv, Fig. 2.) *o*, surface of epithelium; *bg*, subepithelial connective tissue; *n*, nerve fibre.

actual terminations, however, appear never to lie in the superficial layers of the epithelium, but the branches, having passed out near the surface, turn backward to end free near the junction of the epithelium with its connective-tissue support (Fig. 212). Whether or not this behavior depends upon the variations in the distention of the bladder wall, or represents a mechanism for the purpose of avoiding a possible harmful influence of the urine upon the nerve endings, is not known.

The mucous membranes covered by ciliated epithelium also receive nerve fibres which end free in among and upon the cells (Fig. 213).

The number of nerve fibrils present in ordinary epithelial surfaces is remarkable; even the gold method, by means of which Cohnheim\* discovered the free intercellular endings in

\* Cohnheim, J. Ueber die Endigung der sensiblen Nerven in der Hornhaut. *Arch. f. path. Anat.*, etc., Berl., Bd. xxxviii (1867), S. 343-386.

the epithelial layer of the cornea (Fig. 214), shows in successful preparations a large number of fine fibrils. But the nigro-

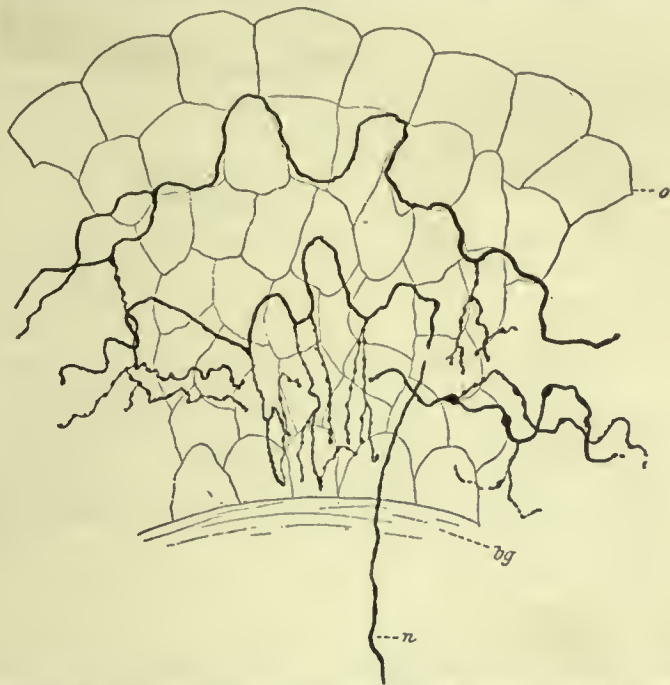

FIG. 212.—Nerve fibrils in the epithelium of a vertical section of the rabbit's bladder. Method of Golgi. (After G. Retzius, *Biol. Untersuch.*, Stockholm, n. F., Bd. iv, 1892, Taf. xiv, Fig. 4.) *o*, superficial layer of epithelial cells; *bg*, subepithelial connective tissue; *n*, nerve fibre passing from connective tissue into the epithelium.

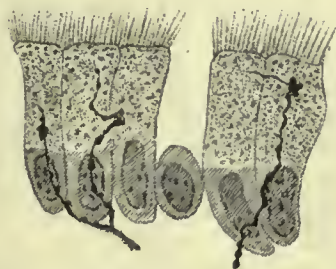


FIG. 213.—Termination in the form of trefoil end platelets on the ciliated cells of the frog's palate. Sagittal section; vital staining with methylene blue; alum cochineal used as a counterstain. (After A. Bethe, *Arch. f. mikr. Anat.*, Bonn, Bd. xlv, 1894, Taf. xii, Fig. 6.)

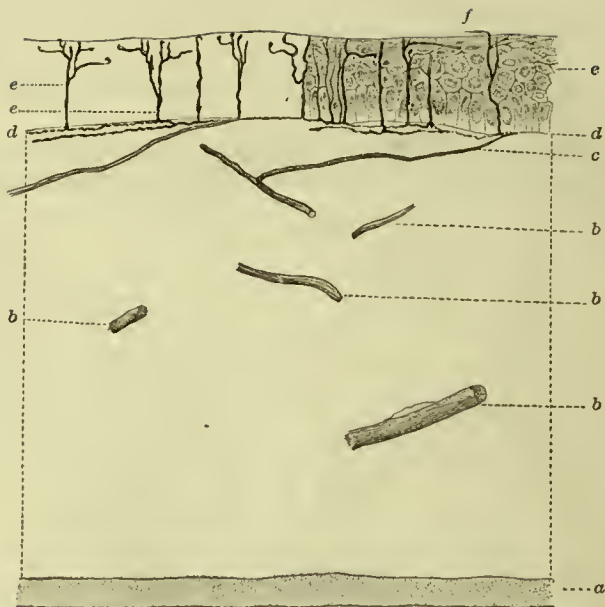


FIG. 214.—Vertical section through the cornea. (After J. Cohnheim, Arch. f. path. Anat., etc., Berl., Bd. xxxviii, 1867, Taf. xii, Fig. 8.) The corneal corpuscles and the cells of Descemet's membrane are left out of the drawing; the anterior epithelium has been drawn in only in part. *a*, Descemet's membrane; *b*, nerves from the plexuses; *c*, branches going to the epithelium, here ascending by accident very obliquely; *d*, fibres of the subepithelial layer; *e*, vertical end threads with horizontal outrunners; end nodules can be seen; *f*, an undoubted præcorneal horizontal fibre.

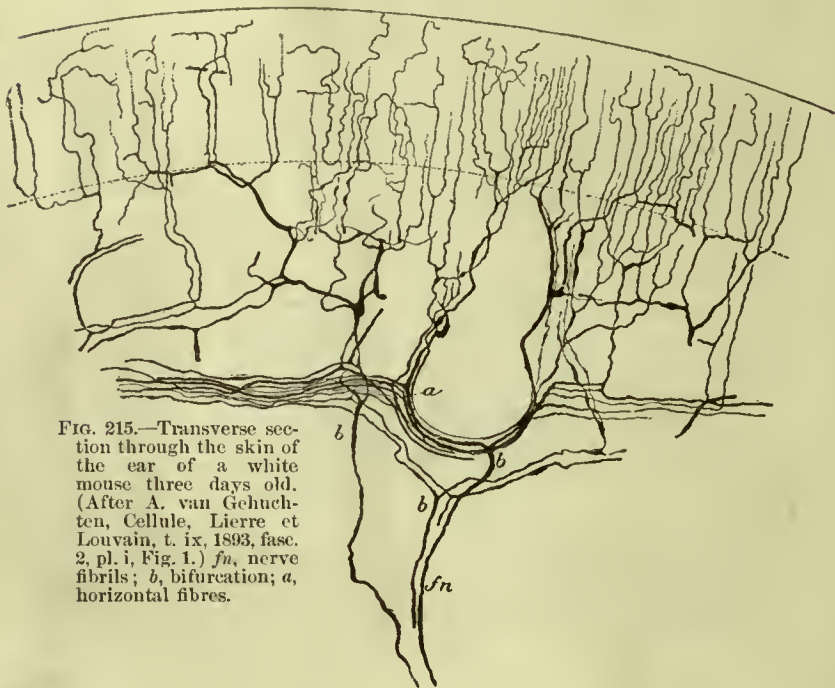


FIG. 215.—Transverse section through the skin of the ear of a white mouse three days old. (After A. van Gehuchten, Cellule, Liège et Louvain, t. ix, 1893, fasc. 2, pl. i, Fig. 1.) *fn*, nerve fibrils; *b*, bifurcation; *a*, horizontal fibres.



sine and safranin staining of Macallum,\* and the method of Golgi applied by F. E. Schulze,† van Gehuchten,‡ and others, has shown us the really enormous number of nerve fibrils that are present in such structures (Fig. 215). The method of Ehrlich, applied to the skin and mucous membrane by Eberth, Szymonowicz,\* Bethe, Dogiel (Figs. 216-218), and others, has revealed even more. It would appear that almost every epithelial cell stands in contact relation with one or more nerve fibrils. And perhaps this may be true of all epithelial cells.

While the majority of the fibrils in the skin and in the epithelium of the mucous membranes end free, often with formation of slight varicosities, others of them terminate in definitely differentiated end platelets. As an example of these may be mentioned the so-called trefoil-shaped platelets which Bethe|| has described as occurring on the nerve fibrils in contact with the cylindrical cells in the epithelium of the frog's tongue and palate, and the round end plates which he finds on the rod cells, the forked cells, and the deep cylindrical cells in the same organ. These end plates (Fig. 219) are to be looked upon as expansions of the distal end of the nerve fibril. The nerve fibril is attached to the end plate very much as the stem is to a leaf. Several of them may belong to a single nerve fibril, and, what is more important, the same nerve fibre can be connected with the simple free nerve endings as well as with these endings in platelets. The epithelial cells in contact with these platelets can often be differentiated from the other epithelial cells by their behavior toward alum cochineal. Niemaek describes in the frog's tongue cells almost completely surrounded by a mantle of nerve substance arising as an expansion of a terminal

---

\* Macallum, A. B. The Nerve Terminations in the Cutaneous Epithelium of the Tadpole. *Quart. J. Micr. Sc.*, Lond., n. s., vol. xxvi, pp. 53-70.

† Schulze, F. E. Freie Nervenenden in der Epidermis der Knochenfische. *Sitzungsb. d. k. Preuss. Akad. d. Wissensch.*, phys.-math. Cl. (1892), No. viii, S. 87, 88.

‡ van Gehuchten, A. Les terminaisons nerveuses intra-épidermiques chez quelques mammifères. *Cellule, Liège et Louvain*, t. ix (1893), fasc. 2, pp. 301-331.

\* Szymonowicz, W. Beiträge zur Kenntniss der Nervenendigungen in Hautgebilden. *Arch. f. mikr. Anat.*, Bonn, Bd. xlv (1895), S. 624-654.

|| Bethe, A. Die Nervenendigungen im Gaumen und in der Zunge des Frosches. *Arch. f. mikr. Anat.*, Bonn, Bd. xlv (1894), S. 185-206.

fibril; Bethe could not, however, find such structures in tissues fixed by his method.

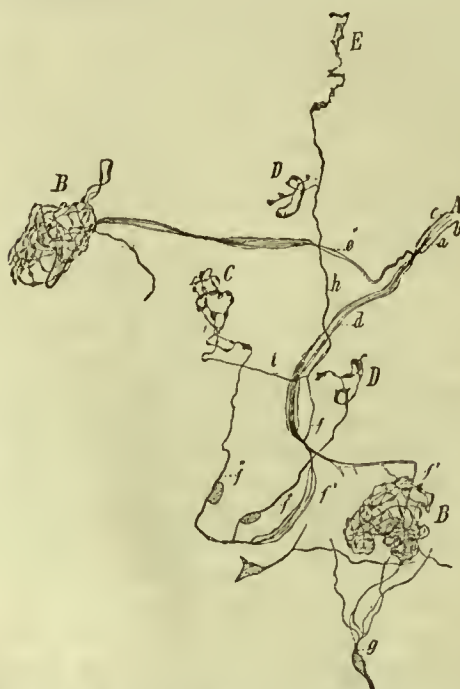

FIG. 216.—Nerves and nerve endings from the human cornea. (After A. S. Dogiel, *Anat. Anz.*, Jena, Bd. v, 1890, S. 483, Fig. 5.) *A*, medullated nerve fibre which divides into two, *d* and *e*, of which one, *e*, ends in a compound skein, *B*; the other, *d*, breaks up into three branches *f*, *f'*, *f''*. The branch *f* divides into two threads, *h* and *i*; the thread *h* ends in a loop, *D*, and in a hooklet, *E*, but the thread *i* helps to form the simple skein *C*; the branch *f'* enters the complex skein, *B*; the branch *f''* finally breaks up into the threads *f'''* and *f'''*, of which the former ends in a loop, *D*, while the other goes into the skein *C*. The branch *f'''* is surrounded for a certain distance by myelin; nuclei are, however, immediately adjacent to the threads *f'''* and *f'''*. *g*, branch of a medullated fibre (not shown in the figure) which breaks up into threads which go over into the compound skein, *B*; *a*, central fibre; *b*, peripheral part of axone; *c*, myelin.

Another form of end platelet with which histologists have become familiar since Merkel's\* descriptions is that to be met

\* Merkel, Fr. Ueber die Endigung der sensiblen Nerven in der Haut. *Nachr. v. d. k. Gesellsch. der Wissensch. a. d. Georg-Aug.-Univ., Göttingen* (1875), S. 123–128.—Tastzellen und Tastkörperchen bei den Hausthieren und beim Menschen. *Arch. f. mikr. Anat.*, Bonn, Bd. xi (1875), S. 636–652.—Ueber die Endigungen der sensiblen Nerven in der Haut der Wirbeltiere. 4to. Rostock (1880).

with adjacent to the well-known *Tastzellen* of this author. The epithelial cell (*Tastzelle* of Merkel) adjacent to the tactile meniscus is of different shape, and possesses entirely different staining reactions from those of the other cells, so that when one is once familiar with its appearance he can recognize it in sections which have not been stained especially to show the nerve endings. In the skin, Merkel's *Tastzellen* are

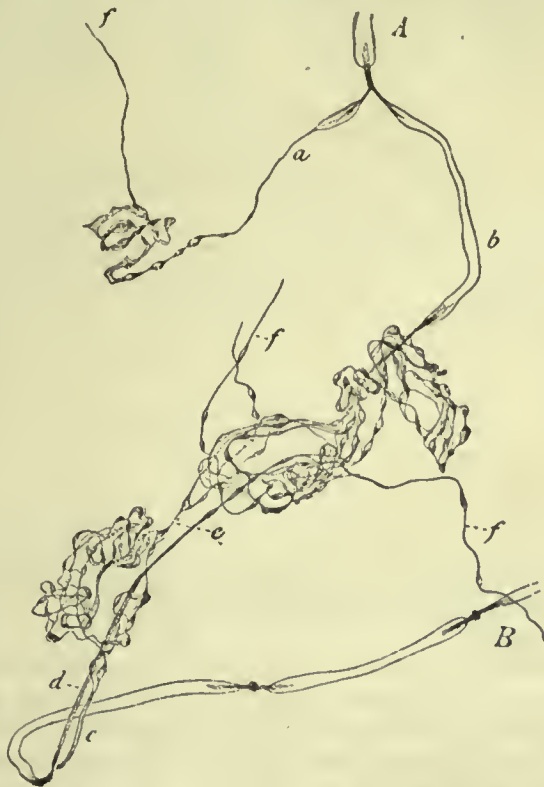

FIG. 217.—Nerves and nerve endings in human cornea. (After A. S. Dogiel, *Anat. Anz.*, Jena, Bd. v, 1890, Fig. 6.) *A* and *B*, two medullated fibres, each of which divides forklike into two branches (*a*, *b* and *c*, *d*); the branch, *a*, forms a simple skein, the others form compound skeins; *e*, a varicose thread which unites two end skeins; *f*, threads which have arisen by division of the axone of the medullated fibres.

most numerous in the interpapillary processes of epithelium. They are easily demonstrable in the adult (Fig. 220) and embryo (Fig. 221) pig by means of the vital staining with

methylen-blue, as Szymonowicz\* has shown. I have stained them by the same method in the pig's snout, and also in human skin obtained from the surgical operating room. With the aid of Bethe's fixing method one can obtain beautiful pictures by counter-staining the sections with Czokor's alum cochineal. In a successful preparation the expansions of the ends of the nerve fibrils—the tactile menisci—are stained deep blue, the *Tastzellen* of Merkel dark red, and other epithelial cells pale pink.

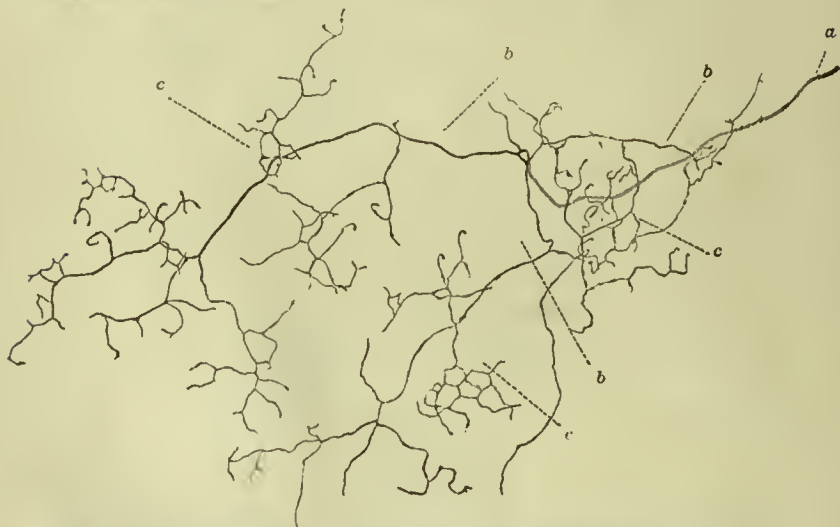


FIG. 218.—Medullated nerve fibre from the conjunctiva of man. (After A. S. Dogiel, Arch. f. mikr. Anat., Bonn, Bd. xlv, 1894-'95, Taf. iii, Fig. 5.) The medullated fibre (a) breaks up into single branches (b) and smaller divisions still (c), which form a plexus beneath the epithelium.

Merkel thought at first that the *Tastzellen* were actually ganglion cells. Now we know them to be simply modified epithelial cells in contact with special disklike expansions of the nerve fibrils. The structures have been aptly compared to an acorn, the differentiated cell corresponding to the nut, the meniscus to the cup in which the nut sits, and the nerve fibril to the stem of the cup. Kallius looks upon Bethe's end platelets, described above, as transition forms between the simple free inter-

\* Szymonowicz, W. Beiträge zur Kenntniss der Nervenendigungen in Hautgebilden. Ueber Bau und Entwicklung der Nervenendigungen in der Schnauze des Schweines. Arch. f. mikr. Anat., Bonn, Bd. xlv (1895), S. 634-635.



cellular nerve endings and the ending in menisci on Merkel's *Tastzellen*.

A comprehensive series of researches on the so-called Grandry's \* corpuscles, which are found in the duck's bill (Fig. 222),

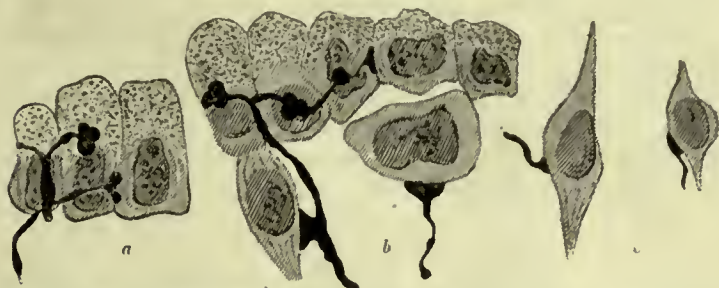


FIG. 219.—Nerve endings in epithelium of frog's palate. (After A. Bethe, Arch. f. mikr. Anat., Bonn, Bd. xliv, 1894-'95, Taf. xii, Figs. 2, 3, and 4.) Vital staining with methylene blue. Fixation by Bethe's method; counterstaining with alum cochineal. *a*, two endings with trefoil end plates, one of the endings being seen from the side; *b*, upper border of a sensory hillock teased out of a sagittal section, nerve endings with trefoil plate on four cylindrical cells (one of them seen from the side), also nerve termination in the form of a round plate on a round cell and on one cylindrical cell in the depth; *c*, two isolated rod cells with end plates and nerve fibrils from a teased preparation.

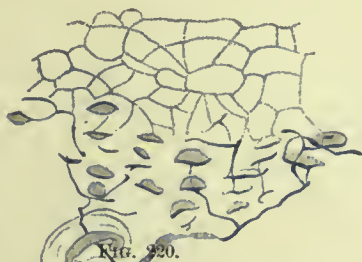

FIG. 220.

FIG. 220.—A perpendicular section of the lower part of the epidermis between two papillae which shows a large group of Merkel's *Tastzellen*. Above, one sees the limits of the epithelial cells indicated, below two nerve fibres entering the epithelium. On the left side probably a part of an end bulb. (After W. Szymonowicz, Arch. f. mikr. Anat., Bonn, Bd. xlv, 1895, Taf. xxxiii, Fig. 6.)




FIG. 221.

FIG. 221.—A perpendicular section through the lower part of the epidermis between two papillae, from a fetus 30 cm. long, to show the development of the nerve endings about Merkel's *Tastzellen*. (After W. Szymonowicz, Arch. f. mikr. Anat., Bonn, Bd. xlv, 1895, Taf. xxxiii, Fig. 9.)

\* Grandry. Recherches sur les corpuscles de Pacini. J. de l'anat. et physiol., etc., Par. (1869).

make it appear that these structures also represent groups of epithelial cells between which nerve fibrils end free by means of terminal end plates. Dogiel\* has studied them with the methylene-blue method and has convinced himself that there are disks inside them which are continuous with nerve fibres lying between the cells of the corpusele. The finer structure has been studied also by Geberg† with both Golgi's method and the methylene-blue stain (Fig. 223). Geberg believes that the nerve fibre breaks up in the disk into a number of very fine fibrils which run in directions through the disk

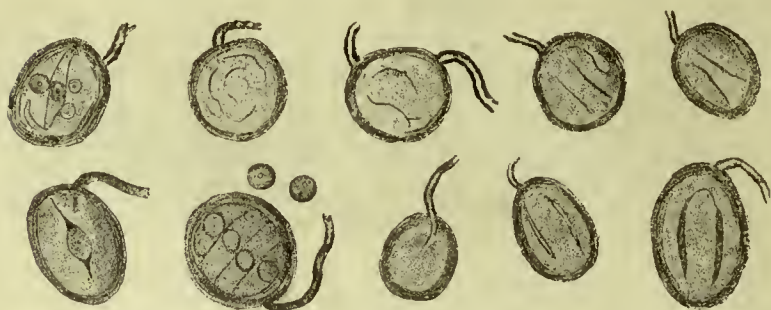

FIG. 222.—Grandry's terminal nerve corpuseles from the duck's bill. (After M. Grandry, *J. de l'anat. et physiol.*, Par., t. vi, 1869, pl. xv. Fig. 10.)

(Fig. 224), while Dogiel thinks that the axis cylinder breaks up into two bundles of fibres which run around the border in a ringlike way, leaving the centre of the disk free from actual nerve fibrils. It is rather interesting to note that Grandry's corpuseles are classed among the epithelial structures, despite the fact that they are situated in the subepithelial tissues and are inclosed in a definite connective-tissue sheath. The study of the ontogeny of the cells, however, is said to have established their epithelial origin.

The nerve endings in the hairs have naturally attracted a great deal of attention inasmuch as these structures have long been known to be very delicately responsive tactile organs. As

\* Dogiel, A. S. Die Nervenendigungen in Tastkörperchen. *Arch. f. Anat. u. Physiol., Anat., Abth.*, Leipz., Jahrg. (1891), S. 182-192.

† Geberg, A. Ueber die Innervation der Gaumenhaut bei Schwimmvögeln. *Internat. Monatsehr. f. Anat. u. Physiol.*, Leipz., Bd. x (1893), S. 205-240.

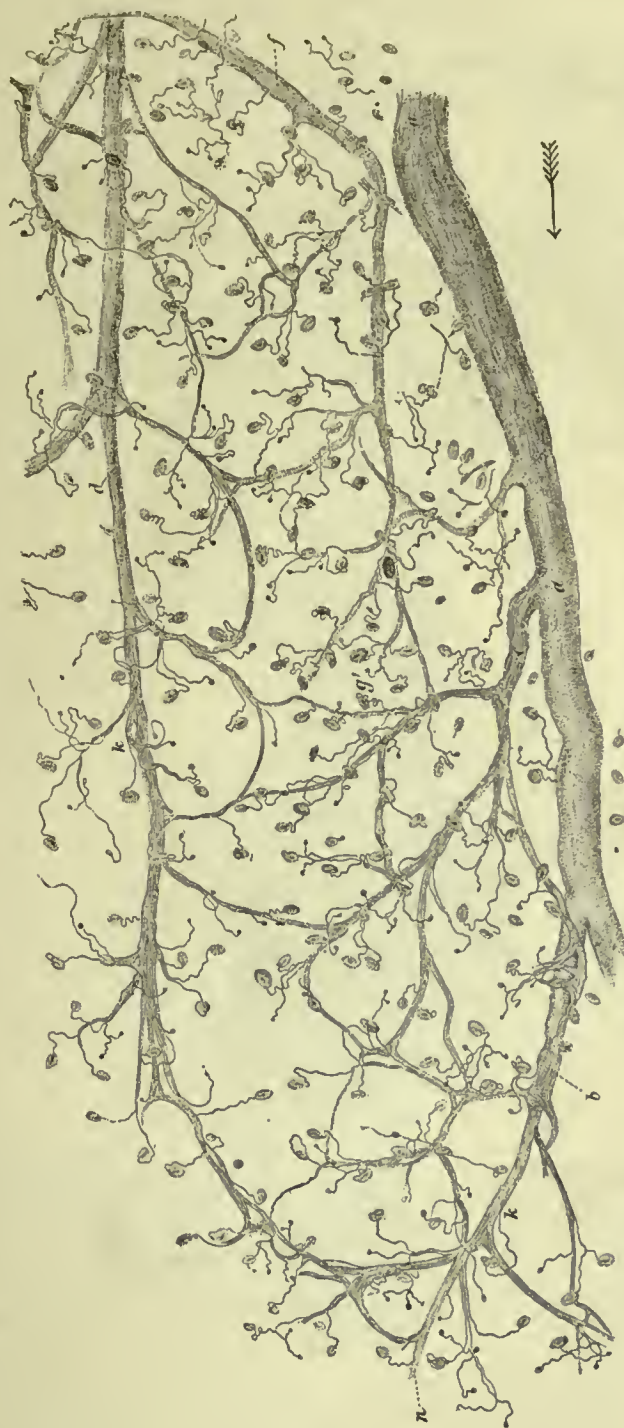

FIG. 223.—Flat preparation from the mucous membrane of the palate of a duck, showing nerve fibres and nerve endings. Treatment with acetic acid and osmium. (After A. Geberg, Internat. Monatschr. f. Anat. u. Physiol., Leipzig, Bd. x, 1883, Taf. ix, Fig. 1.) *a*, a large branch of the palatal nerve arising from the second division of the N. trigeminus (one sees its branches *b* and *c* along with the plexuses which they help to form); *d*, a branch of the palatal nerve from which, at *k*, one sees small bundles of fibres arise, which break up into single nerve fibres and go directly to tactile corpuscles without entering into the nerve plexuses; *g'*, medullated fibre undergoing fork-shaped bifurcation. Of its limbs of division, one ends in a Grandry's corpuscle, the other in a corpuscle of Herbst.

von Frey \* puts it, "Every hair is a lever whose short arm is in the skin, while the long arm serves for the reception of the




FIG. 224.—Tactile discs from two Grandry's corpuscles in connection with the axis cylinders (*nn*) of the nerve fibres connected with them. Methylene-blue staining. (After A. Geberg, *Internat. Monatschr. f. Anat. u. Physiol.*, Leipz., Bd. x, 1893, Taf. ix, Figs. 6 and 6b.) One sees the axis cylinders go over into the tactile disc, where the stained fibrils or bundles of fibrils of the axis cylinder break up into delicate threads which pass in different directions, but mainly to the border of the terminal disc. In A, a network like union of the threads can be made out among the fibrils of the tactile disc in places, although it is not very marked; *k*, nucleus of the connective-tissue sheath of the corpuscle.

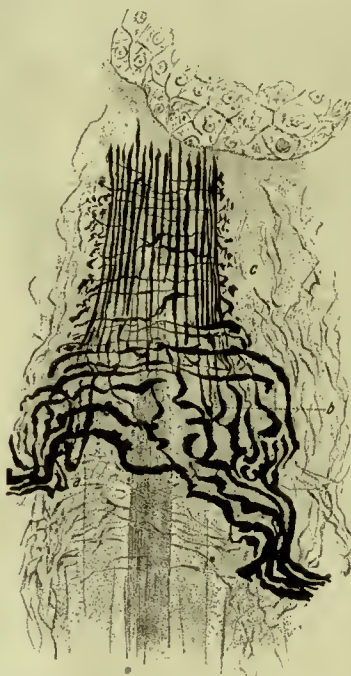


FIG. 225.—Nerve endings about a large hair from the dog. (After R. Bonnet, *Morphol. Jahrb.*, Leipz., Bd. iv, 1878, Taf. xvii, Fig. 4.) Gold preparation. The entering nerves partly form loops, which often grow suddenly more delicate, as at *a*; at *b* one can make out the origin of the straight terminal fibres going forklike from the medullated fibres; *c*, circular terminal fibres practically in cross section, visible external to the straight fibres.

\* von Frey, M. Beiträge zur Physiologie des Schmerzsinner. Ber. d. math.-phys. Cl. der K. Sächs. Gesellsch. d. Wissensch., Leipz., Sitz. vom 2. Juli, 1894, S. 188.



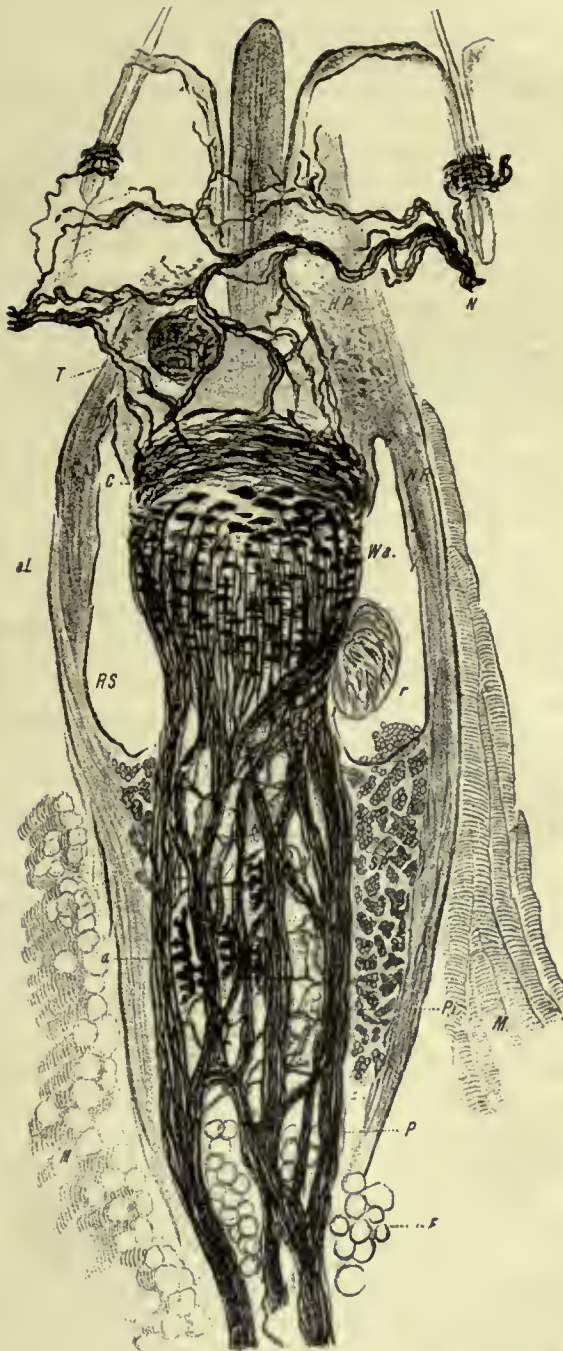


FIG. 226.—Erectile body of a hair of the rat. (After R. Bonnet, *Morphol. Jahrb.*, Leipz., Bd. iv, 1878, Taf. xix, Fig. 13.) Gold preparation. *P*, deep layer of the intrafollicular plexus; *Wa*, swelling on root sheath showing nerve end buds; *a*, peculiar jagged nerve terminals in the deep-lying nerve plexuses; *N*, branch of cutaneous nerve which forms the plexus of the neck of the hair follicle, *H P*, and the nerve ring, *NR*; *RS*, circular sinus; *SP*, spongy body; *r*, circular ridge; *M*, muscle of the follicle; *F*, fat.

stimulus." The earlier studies of Bonnet,\* Merkel,† and Arnstein‡ showed the intimate relation of medullated nerve fibres to the hairs, and indeed to a particular part of the hair (Figs. 225, 226). Just below the spot where the sebaceous gland opens into it the hair follicle shows a furrow about it, beneath which is a projecting ridge. The nerves connected with the hair follicle approach this ridge and penetrate the sheath, losing on entrance their medullated coverings. The further fate of the nerve fibrils was for some time not clear, though Bonnet by means of chloride of gold staining showed the existence of horizontal branches running about the hair. These branches gave off ascending twigs which appeared to lie upon the glassy membrane of the hair follicle imbedded in longitudinal folds in this structure. There seemed to be some doubt whether or not the fibres went through the glassy membrane; many believed that they did not perforate it but simply lay upon it. The method of Golgi in the hands of van Gehuchten\* and Retzius‡ has shown the general characteristics of the endings about the hairs in the mouse, rat, and man very clearly and satisfactorily (Fig. 227). In the mouse and rat each hair receives one nerve fibre which has its origin not in the deep nerves of the skin, but as a branch of a neighboring fibre which is destined to innervate also a portion of the epidermis. This fact is of great interest inasmuch as it proves that either the hairs and these portions of the epidermis have to do with the origin of the same quality of sensations, or if they mediate different sense-modalities then the same neurone must be capable of transmitting from the periphery to the centres impulses con-

\* Bonnet, R. Studien ueber die Innervation der Haarbälge der Haustiere. *Morphol. Jahrb.*, Leipz., Bd. iv (1878), S. 329-398.

† Merkel, Fr. Tastzellen und Tastkörperchen bei den Haustieren und beim Menschen. *Arch. f. mikr. Anat.*, Bonn, Bd. xi (1876).

‡ Arnstein, C. Die Nerven der behaarten Haut. *Sitzungsber. d. k. Akad. d. Wissensch. Math.-naturw. Cl.*, Wien, III. Abt., Oktober, 1876.

\* Van Gehuchten, A. Les nerfs des poils. *Bull. Acad. roy. de sc. de Belg.*, Brux., 3 s., t. xxv (1893), pp. 230-232.—Les nerfs des poils. *Mém. de l'Acad. roy. de Belg.*, Brux., t. xlix, 1893.—Contributions à l'étude de l'innervation des poils. *Anat. Anz.*, Jena, Bd. vii (1892), S. 341-348.

‡ Retzius, G. Ueber die Nervenendigungen an den Haaren. *Biol. Untersuch.*, Stockholm, n. F., Bd. iv (1892), S. 45-48.—Ueber die Endigungsweise der Nerven an den Haaren des Menschen. *Biol. Untersuch.*, Stockholm, n. F., Bd. vi, S. 61-62.

cerned in the production of more than one sense-quality. The nerve fibre having reached the hair follicle, divides into two branches which run horizontally about the hair almost at right angles to its course, one division running in front, the other behind the hair. These may meet or they may run only part

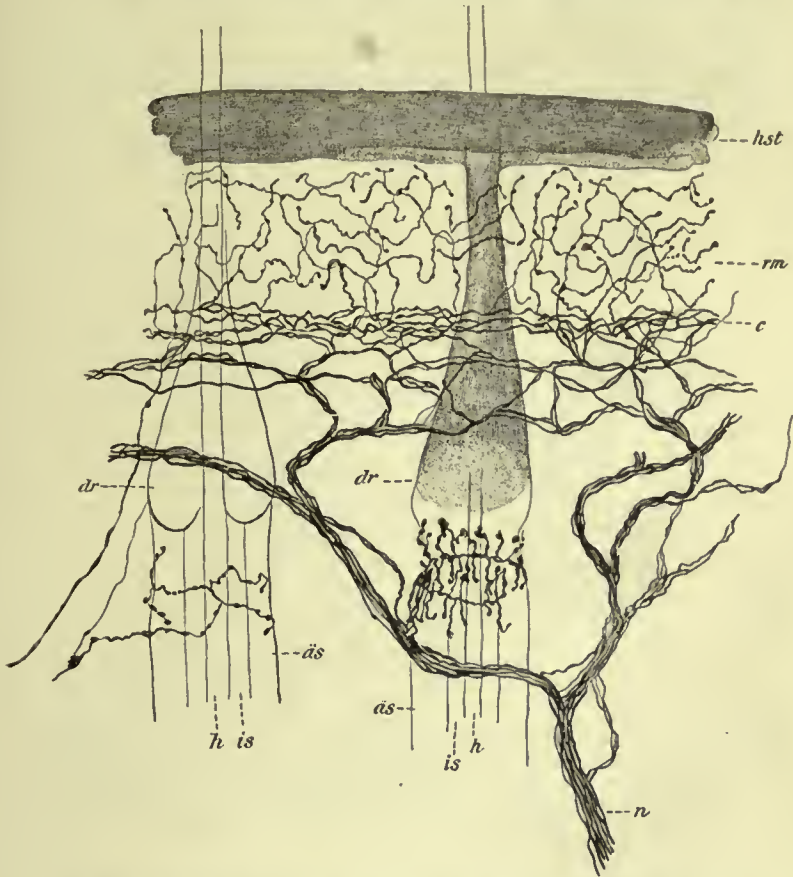


FIG. 227.—Nerves and nerve endings in the skin and hair follicles. (After G. Retzius, *Biol. Untersuch.*, Stockholm, Bd. iv, 1892, Taf. xv, Fig. 4.) *hst*, stratum corneum; *rm*, stratum germinativum Malpighii; *c*, most superficial nerve-fibre plexus in the cutis; *n*, cutaneous nerve; *is*, inner root sheath of hair; *as*, outer root sheath; *h*, the hair itself; *dr*, glandulæ sebacæ.

of the way around, thus forming an incomplete ring. Small ascending twigs run up from these horizontal branches parallel to the direction of the hair to terminate, according to van Ge-

huchten, in small end nodules. A few branches run perpendicularly downward. Retzius, by means of Golgi's method, has made out very similar relations in the human embryo.




FIG. 228.

FIG. 228.—Nerve endings in the form of tactile discs beneath the glassy membrane of the hairs. (After P. Ostromow, *Anat. Anz.*, Jena, Bd. x, 1895, S. 783, Figs. 2 and 4.) A. Tactile discs beneath the glassy membrane of a cat's hair. The tactile discs are connected with perforating nerve fibres and with one another. Teased preparation. B. Nerve endings of the hair of a pig. *a*, tactile discs beneath the glassy membrane; *b*, straight terminal fibres external to the glassy membrane which run out into spoon-shaped or hatchet-shaped endings.

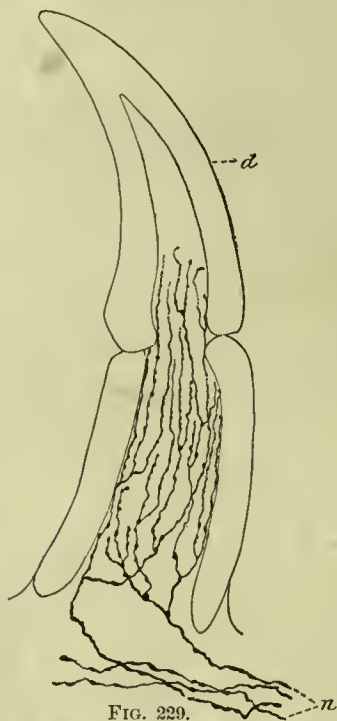


FIG. 229.

FIG. 229.—Longitudinal view of tooth of *Gobius*, showing nerve terminals. (After G. Retzius, *Biolog. Untersuch.*, Stockholm, n. F., Bd. iv, 1892, Taf. xvii, Fig. 7.) *d*, dentine; *n*, nerve fibres ascending close to inner surface of dentine and ending free.

Whether or not the nerves found by Orru\* and by Retzius in the papillæ of the hair actually run into the follicle and correspond to constant nerve endings in the adult must as yet remain undecided.

\* Orru, E. La terminazione nervosa nei peli. *Boll. R. accad. di Roma*, Anno xix (1892-1893), Fse. 7, pp. 762-767.



Very complicated nerve endings have been described on the so-called sinus hairs by a number of observers. The most complete description is that of Ostroumow,\* who worked with methylene blue (Fig. 228). I have found in the embryo pig by means of the methylene-blue method nerve endings connected with definite *Tastzellen* (of Merkel) inside the hair follicles just as Ostroumow has described them. The "nerve end buds" pictured by Bonnet in 1878 are probably the same endings about *Tastzellen* (cf. Fig. 226, *vide supra*).

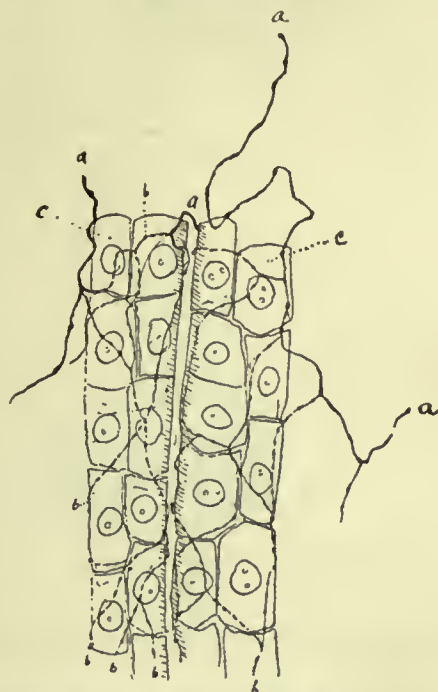


FIG. 230.—Nerve endings in the liver. (After P. Korolkow, *Anat. Anz.*, Jena, Bd. viii, 1893, S. 753, Fig. 2.) *a*, axis cylinder of the plexus extending between the rows of liver cells; *b*, fibrils which form a network over the cells; *c*, rows of liver cells.

That the teeth are sensitive to touch, and more especially to pain, is a matter of general knowledge. It has been disputed whether or not besides the nerve endings in the pulp there

\* Ostroumow, P. Die Nerven der Sinushaare, mitgeteilt v. Prof. Arnstein. *Anat. Anz.*, Jena, Bd. x (1895), S. 781-790.

were also nerve endings in the solid portion of the tooth; while some have believed that the nerve fibrils end only among the bodies of the odontoblasts at the periphery of the pulp, others think that they may actually penetrate the dentine itself, inasmuch as it is known that if the gum be re-

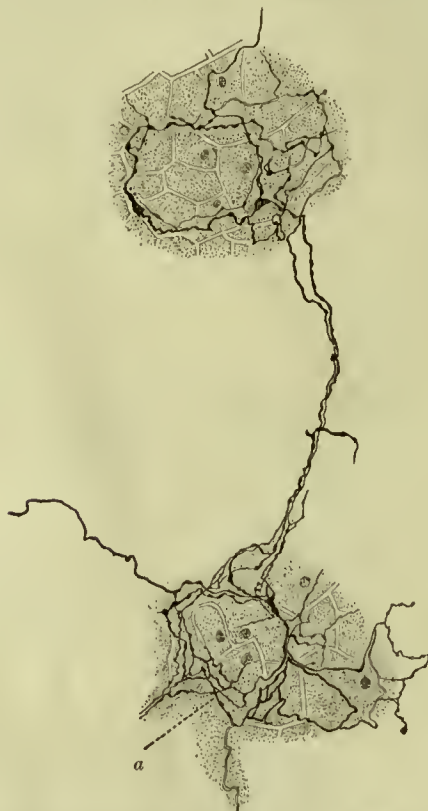

FIG. 231.—Periacinous plexus (*a*) of nerve fibrils in the pancreas. (After E. Müller, *Arch. f. mikr. Anat.*, Bonn, Bd. xl, 1892, Taf. xxii, Fig. 16.)

tracted the dentine is sensitive at the margin of the enamel. Retzius\* has applied Golgi's method to the teeth of many ani-

\* Retzius, G. Zur Kenntniss der Nervenendigungen in den Zähnen, *Kleinere Mittheil. aus dem Gebiete der Nervenhistologie*. Biol. Untersuch., Stockholm, n. F., Bd. iv (1892), S. 65-66.—Ueber die Nervenendigungen in den Zähnen bei Amphibien. Biol. Untersuch., Stockholm, n. F., Bd. v, S. 40-41.—Zur Kenntniss der Endigungsweise der Nerven in den Zähnen der Säugetiere. Biol. Untersuch., Stockholm, n. F., Bd. vi, S. 54.

mals, and has succeeded in staining the nerves (Fig. 229). He finds that the nerve fibres of the pulp branch manifoldly and

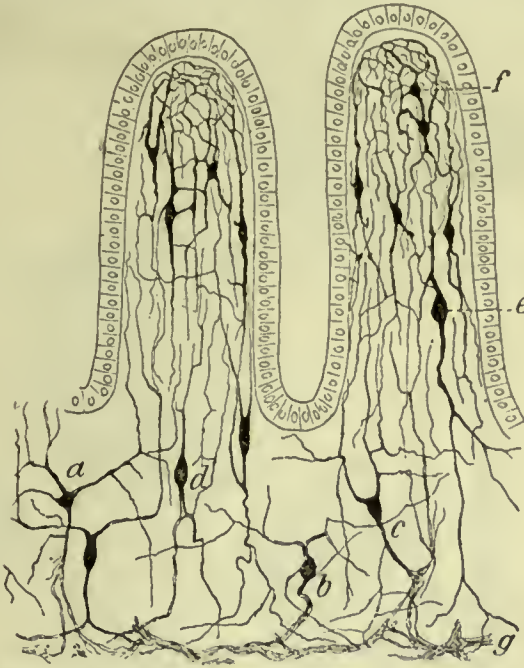


FIG. 232.—Nerve cells and nerve fibres in the villi and among the glands of the *intestinum tenue* of the guinea-pig. (After S. Ramón y Cajal, taken from A. Oppel's text-book.) *a, b, c, d*, perikaryons of different shapes among *glandulae intestinales* (Lieberkuehni); *e, f*, perikaryons situated in the villi *intestinales*; the plexus formed by their processes is shown.

are distributed between the odontoblasts ending close or near the inner surface of the dentine. He was never able, however, to follow nerve fibrils into the dentinal tubules. Subsequently the subject has been submitted to especial research by Morgenstern,\* who has obtained very remarkable results. He describes different sorts of endings not only in the dentine itself but also even in the enamel. These findings have been disputed by

\* Morgenstern, M. Ueber das Vorkommen von Nerven in den harten Zahnsubstanzen. *Deutsche Monatsschr. f. Zahnh.*, Leipz., Jahrg. x (1892), Oktober, S. 436-437.—Weiteres ueber Vorkommen von Nerven in den harten Zahnsubstanzen und ueber eine Methode sie aufzufinden und zu konservieren. *Ibid.*, Jahrg. xiii, S. 111-114.

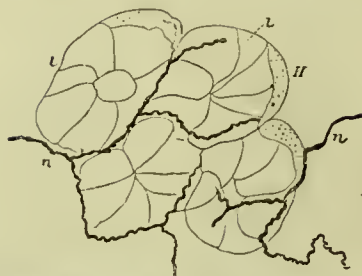

FIG. 233.—Nerve endings in the salivary glands. (After G. Retzius, *Biol. Untersuch.*, 1890, taken from Rauber's text-book.) *l, l*, sections of acini; *H*, crescent; *n, n*, nerve fibres.

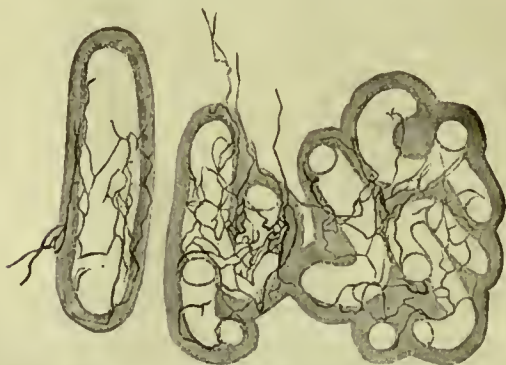

FIG. 234.—Section through the caput epididymidis of a young tomtat. (After D. Timofeev, from Rauber's text-book.)

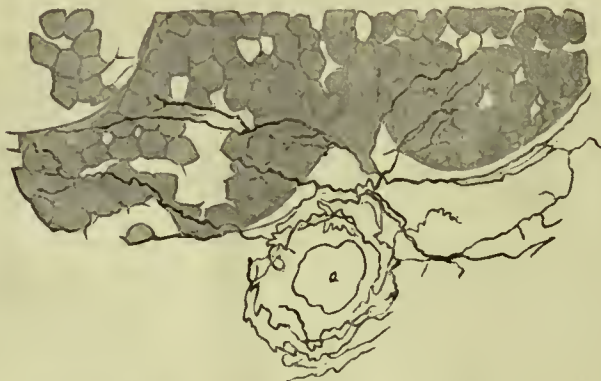


FIG. 235.—Nerve terminals in transverse section of the tubuli seminiferi of the rabbit. *a*, blood-vessel. (After G. Slavunos, from Rauber's text-book.)



Röse,\* who thinks that Morgenstern had to deal with precipitates in the dentinal tubules and on the processes of the odontoblasts. For the present, then, we must await patiently the results of further research in this direction.

As to the beginnings of centripetally conducting fibres in the organs of hypoblastic origin, exclusive of the mucous membranes, comparatively little is known. Cuccati † and Berkley

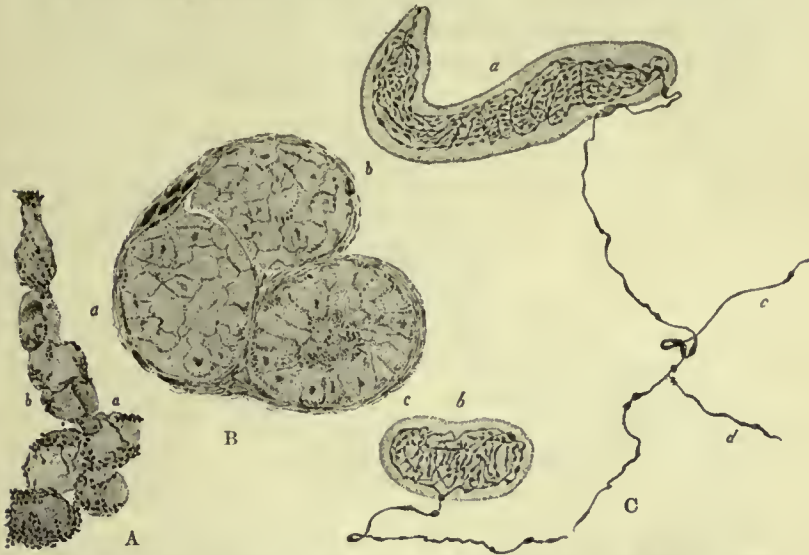


FIG. 236.—Nerve endings in the mammary gland. (After Dmitrijewski, Kasan, 1894.)

have described the nerve endings in the lung, and Berkley † and Korolkow \* have followed the fine nerve fibrils throughout the

\* Röse, C. Ueber die Nervenendigungen in den Zähnen. Deutsche Monatsschr. f. Zahnk., Leipz., Jahrg. xi, S. 58-60.

† Cuccati, G. Nervi del polmoni. Nota preventiva, presentata alla reale Accad. di Bologna nella Sessione del 15 Gennaio, 1888.—Sopra il distribuirlo e la terminazione delle fibre nervose nei polmoni della rana temporaria. Internat. Monatsschr. f. Anat. u. Physiol., Leipz., Bd. v (1888), S. 194-203.—Intorno al modo onde i nervi si distribuiscono e terminano nei polmoni e nei muscoli addominali del Triton cristatus. Internat. Monatsschr. f. Anat. u. Physiol., Leipz., Bd. vi (1889), S. 237-249.

‡ Berkley, H. J. Studies in the Liver. Intrinsic Nerves. Johns Hopkins Hosp. Rep., Balt. (1894).

\* Korolkow, P. Ueber die Nervenendigungen in der Leber. Anat. Anz., Jena, Bd. viii (1893), S. 751-753.

liver substance (Fig. 230). The pancreas (Fig. 231) as well as the stomach and intestine (Fig. 232) have been studied by Erik Müller,\* and by Ramón y Cajal, and the salivary glands (Fig. 233) and the thyroid have also been investigated by several observers. The endings in the epididymis have been studied by Timofeew (Fig. 234), those in the testicle by Sclavunos (Fig. 235). The sensory as well as the motor and secretory nerve endings in the mammary gland (Fig. 236) have

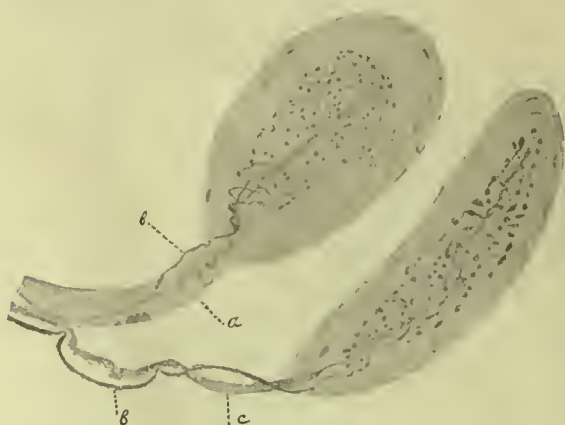

FIG. 237.—Two corpuscles containing nerve endings from the external connective-tissue sheath of the dog's prostate. (After Timofeew, 1895, from Rauber's text-book.) *a*, thick medullated nerve fibre which runs out into the band-shaped axis cylinder; *b*, delicate medullated nerve fibre which forms the terminal apparatus; methylene-blue staining.

lately been studied by Dmitrijewski.† Two corpuscles from the prostate are shown in Fig. 237. Without going into a detailed description of the findings in these various organs it may be stated that every one has been surprised at their enormous richness in nerve fibrils.

\* Müller, E. Zur Kenntniss der Ausbreitung und Endigungsweise der Magen-, Darm- und Pankreasnerven. *Arch. f. mikr. Anat.*, Bonn, Bd. xl, S. 390-409.

† Dmitrijewski, P. Ueber die Nerven des Milchdrüsen. *Diss. Kasan*, 1894, abstracted by Stieda in *Merkel-Bonnet's Ergebn. der Anat.*, Bd. v (1895), Wiesb., 1896.

## CHAPTER XXXI.

### THE MEDULLATED PERIPHERAL AXONES OF THE PERIPHERAL CENTRIPETAL NEURONES AND THEIR TERMINAL APPARATUS—(*Continued*).

Sensory nerve beginnings in mesoblastic tissues—Corium and tela subcutanea—Tunicæ mucosæ and tæla submucosæ—Meninges—Tendons—Connective tissue of organs—Voluntary, cardiac and smooth muscle—Nerve terminals in pathological growths.

#### *Sensory Nerve Beginnings in Mesoblastic Tissues.*

WE next have to consider the distribution of the peripheral extremities of the centripetal nerves in the various mesoblastic structures including the corium and tela subcutanea of the skin, the connective tissue of mucous membranes, the meninges of the brain, the tendinous structures of the body, the capsules and interstitial connective tissue of the solid organs, and the muscles, including voluntary, cardiac, and smooth muscular tissue. Here also it has been found that the nerve fibrils may terminate as free endings either in the form of delicate varicosities or end-platelets, or they may be inclosed in encapsulated end-organs of specific structure (*corpuscula nervorum terminalia*).



FIG. 238.—Free nerve endings on the basal membrane at the junction of the epidermis with the subcutaneous tissue. (After W. Szymonowicz, *Arch. f. mikr. Anat.*, Bonn, Bd. xlv, Taf. xxxiii, Fig. 5.) One sees a nerve fibre enter from below on each side and break up to form an end plexus. Szymonowicz thinks that this ending is identical with the *terminaison hédériforme* of Ranvier.

In the skin at the junction of the corium with the epidermis Ranvier has described what he calls *terminaisons hédériformes*. These have subsequently been studied by the methylene-blue method by Szymonowicz \* in the snout of the pig (Fig. 238).

\* *Op. cit.*

They consist of axis cylinders which divide manifoldly and form irregular dendritic end-branchings and end-plexuses, the fibres often showing varicosities in their course. According to Szymonowicz, they are more developed in the parts of the skin

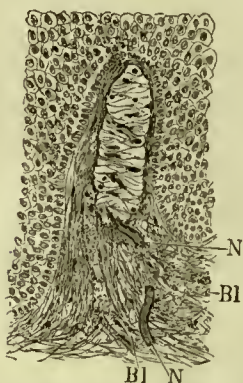


FIG. 239.—Tactile corpuscle of Meissner from a section through the skin of the human toe. Fixation with osmic acid. *Bl*, blood-vessel; *N*, medullated nerve fibre. (After P. Schiefferdecker, *Gewebelehre*, Braunschweig, 1891, S. 221, Fig. 141.)

in which Merkel's *Tastzellen* in the epidermis are absent or present only in small numbers. They often lie immediately upon the basal membrane, following exactly the indentations and irregularities of the junction of the epidermis with the corium. Szymonowicz could not make out, however, that any branches ever passed into the epidermis to run among the epithelial cells.

The endings lying upon the glassy membrane of the hair follicles also represent free nerve endings in the connective tissue.

Of the special end-organs occurring in the connective tissue of the skin several interesting forms have been described. First of all the tactile corpuscle described long ago by Wagner and Meissner\* is familiar to every one (Fig. 239). A section made through the skin of the pulp of the finger shows numbers of these in the papillæ of the corium. Sometimes the corpuscles are simple, but they may consist of several lobules with a common base. One or more nerve fibres enter the lobule at or near its base; after taking a somewhat tortuous course each plunges into the corpuscle, loses its myelin sheath, and divides repeatedly with formation of a definite end arborization inside the corpuscle. Each terminal branch runs out to end free, usually as a

\* Wagner, R., und G. Meissner. Ueber das Vorhandensein bisher unbekannter eigenthümlicher Tastkörperchen (*Corpuscula tactus*) in den Gefühlswärzchen der menschlichen Haut und neber die Endausbreitung sensativer Nerven. *Nachr. v. d. k. Gesellsch. d. Wissensch. n. d. Georg-Aug.-Univ. Götting.*, 1852, S. 17-32. Also Meissner, G. *Beiträge zur Anatomie und Physiologie der Haut*. Leipzig, 1853.—Zur Lehre vom Tastsinn. *Ztschr. f. rat. med.*, Heidelb., n. F., Bd. iv (1854), S. 260-280.—*Untersuchungen neber den Tastsinn*. *Ibid.*, 3 R., Bd. vii (1859), S. 92-118.



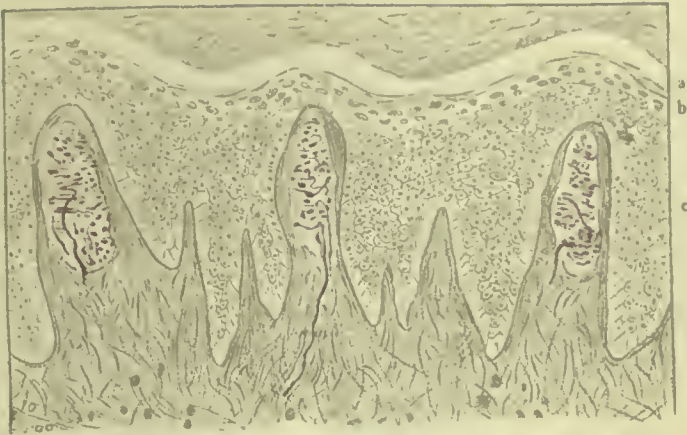


FIG. 240.—Section through the skin of the toe. In three papillae Meissner's corpuscles with stained nerve fibres are visible. *a*, stratum lucidum; *b*, stratum granulosum; *c*, stratum Malpighi. (After A. S. Dogiel, *Internat. Monatsschr. f. Anat. u. Physiol.*, Leipz., Bd. ix, 1892, Taf. v, Fig. 1.)

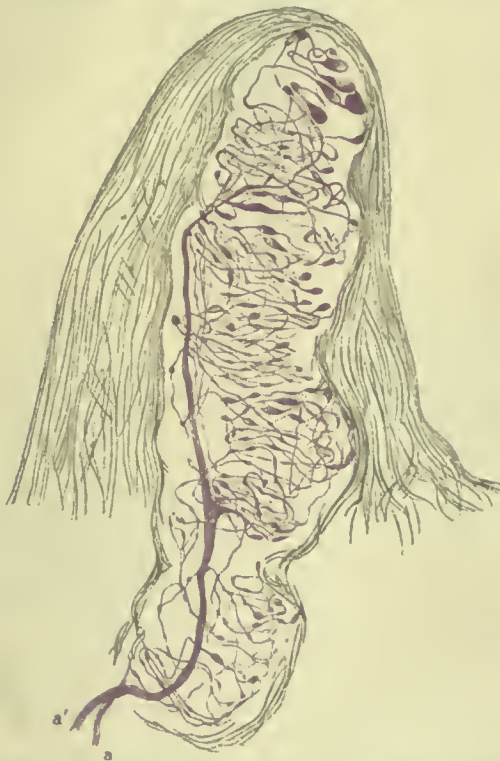

FIG. 241.—Meissner's corpuscle. *a* and *a'*, axis cylinders of nerve fibres, which enter the corpuscle and break up into branches and threads, out of which the nerve skein arises. (After A. S. Dogiel, *Internat. Monatsschr. f. Anat. u. Physiol.*, Leipz., Bd. ix, 1892, Taf. v, Fig. 2.)

somewhat flattened plate in among the flat or wedge-shaped cells (*Kolbenzellen* of Krause)\* of the corpuscles. These corpuscles of Meissner are abundant in non-hairy parts where tactile sense is acute. They have been carefully studied by means of the methylene-blue method by Dogiel.† He has described at length the formation of a system of loops resulting from the spiral-like curvings, manifold divisions, and crossings of the fibres inside the corpuscles (Figs. 240, 241). Dogiel believes that a network is formed of these divisions, a view shared by Smirnow,‡

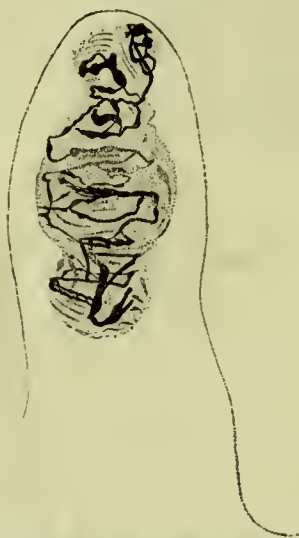

FIG. 242.—Tactile corpuscle from the skin of the volar surface of the index finger of a man twenty-five years old. Method of Golgi. (After A. Smirnow, *Internat. Monatschr. f. Anat. u. Physiol.*, Leipz., Bd. x, 1893, Taf. xi, Fig. 5.)

who has studied Meissner's corpuscles in the skin with gold chloride, with Golgi's method, and also with methylene blue in

\* Krause, W. *Die terminalen Körperchen der einfach sensiblen Nerven*. Hanover, 8vo, 1860.—*Die Nervenendigung in den Tastkörperchen*. *Arch. f. mikr. Anat.*, Bonn, Bd. xx (1881-'82), S. 212-221.

† Dogiel, A. S. *Die Nervenendigungen in Tastkörperchen*. *Arch. f. Anat. u. Physiol.*, Anat. Abth., Leipz., 1891, S. 181-192.—*Die Nervenendigungen in Meissner'schen Tastkörperchen*. *Internat. Monatschr. f. Anat. u. Physiol.*, Leipz., Bd. ix (1892), S. 76-85.

‡ Smirnow, A. *Ueber Endkolben in der Haut der Planta pedis und ueber die Nervenendigungen in den Tastkörperchen des Menschen*. *Internat. Monatschr. f. Anat. u. Physiol.*, Leipz., Bd. x (1893), S. 241-247.



FIG. 243.—Peripheral part of conjunctiva palpebrarum of man. *a*, papilla with terminal nerve corpuscle inside; *b*, layer of epithelial cells on the surface of papilla. Vital staining with methylene blue. (After A. S. Dogiel, *Arch. f. mikr. Anat.*, Bonn, Bd. xlv, 1894-'95, Taf. iii, Fig. 1.)

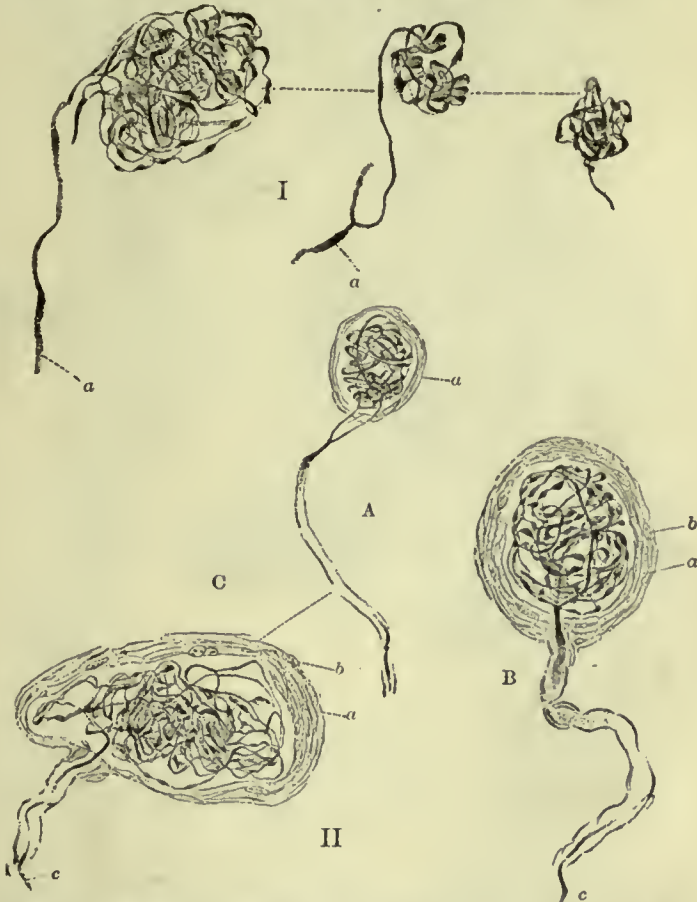

FIG. 244.—Terminal nerve corpuscles in the eyelids of man. (After A. S. Dogiel, *Arch. f. mikr. Anat.*, Bonn, Bd. xlv, 1894-'95, Taf. iii, Figs. 2 and 4.) I. Terminal nerve corpuscles from the papillae of the margin of the lid; *a*, medullated nerve fibres. II. *A*, *B*, *C*, terminal nerve corpuscles of different forms from the pars orbitalis conjunctivae; *a*, the sheath; *b*, nuclei of flat cells of the sheath; *c*, medullated nerve fibres.

perfectly fresh tissue removed at operation (Fig. 242). The latter staining showed exquisitely the ramification and division of the fibres inside the corpuscles. Methylene-blue preparations

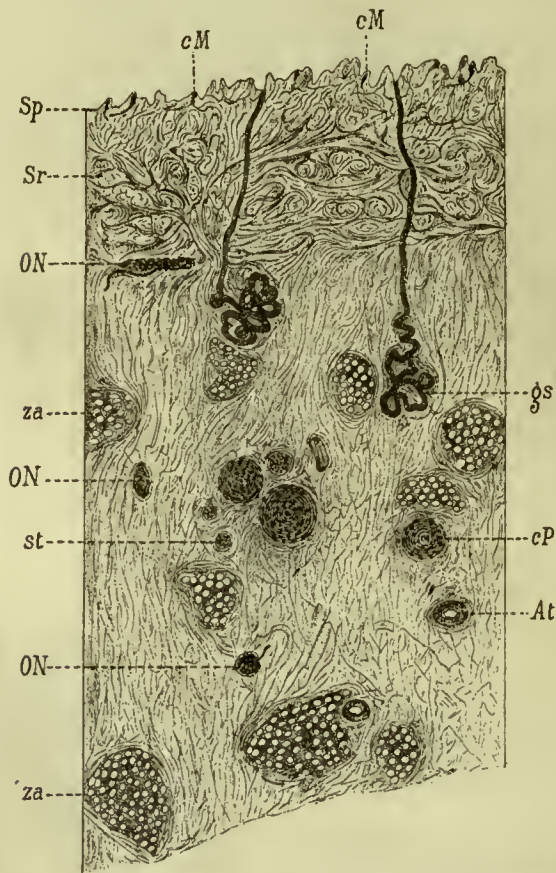


FIG. 245.—Semi-schematic section of the skin of the pulp of the fingers in order to demonstrate the topography of the "terminal nervous organs" (ON) described by Ruffini. (After A. Ruffini, Arch. ital. de biol., Turin, t. xxi, 1894, pl. iii, Fig. 13.) Chloride-of-gold preparation. At, arteriole; cM, Meissner's corpuscles; cP, transverse sections of Pacinian corpuscles; gs, sudoriparous glands; ON, Ruffini's endings; Sp, papillary layer of the skin; Sr, reticular layer of the skin; za, fat.

show that the same nerve fibre may be connected with more than one tactile corpuscle, and Dogiel states that he has seen fibres enter the corpuscle, pass again out of it, and enter the epithelium to terminate there. End corpuscles (Figs. 243, 244)



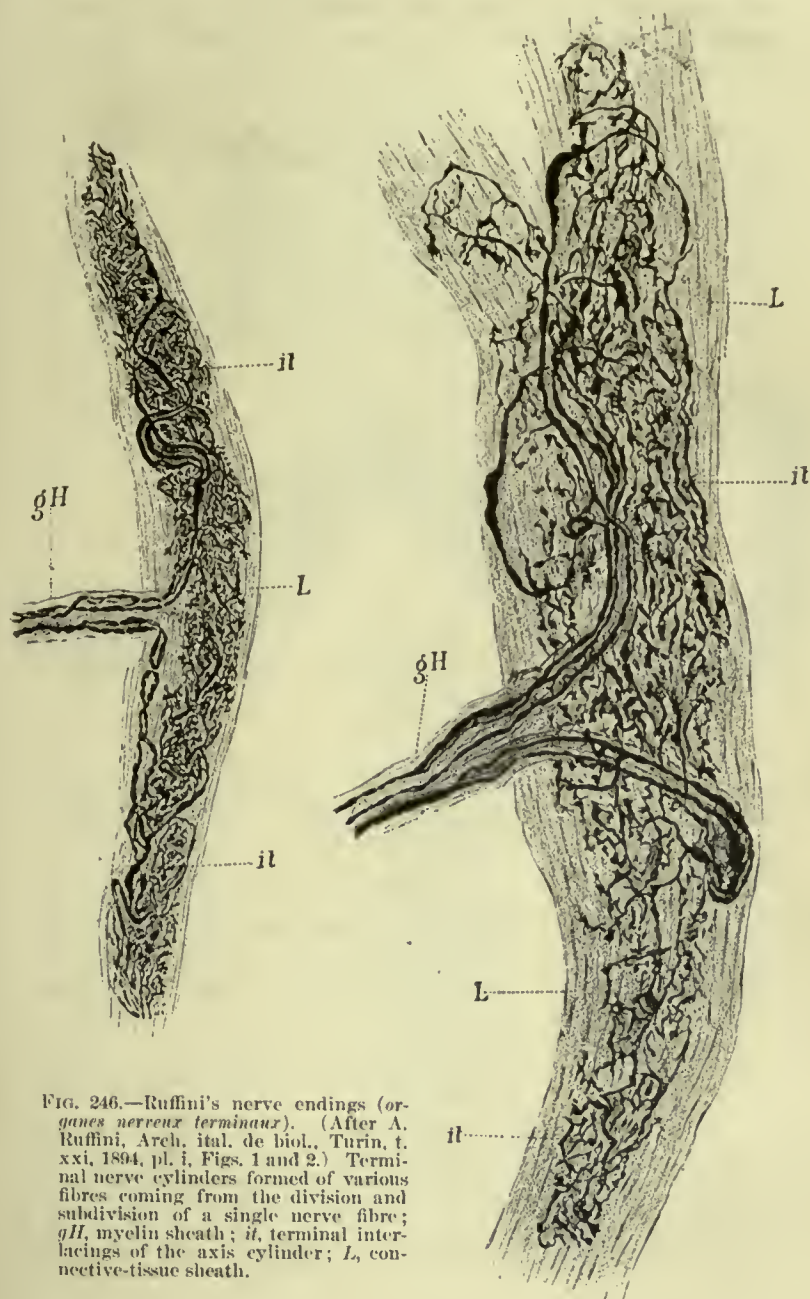


FIG. 246.—Ruffini's nerve endings (*organes nerveux terminaux*). (After A. Ruffini, *Arch. ital. de biol.*, Turin, t. xxi, 1894, pl. i, Figs. 1 and 2.) Terminal nerve cylinders formed of various fibres coming from the division and subdivision of a single nerve fibre; *gH*, myelin sheath; *it*, terminal interlacings of the axis cylinder; *L*, connective-tissue sheath.

somewhat similar to Meissner's corpuscles, but much simpler, have been described in the conjunctiva of human beings by Dogiel.\*

A special variety of terminal corpuscle has been described in the subcutaneous tissue of the human finger by Ruffini. These bodies, which are oval in shape and about as numerous as the corpuscles of Pacini, lie at the junction of the corium and tela subcutanea, and often, according to Ruffini,† in the connective tissue septa which separate the masses of fat in the latter (Fig. 245). These corpuscles, which he names *organes nerveux terminaux*, are ordinarily known in the bibliography as

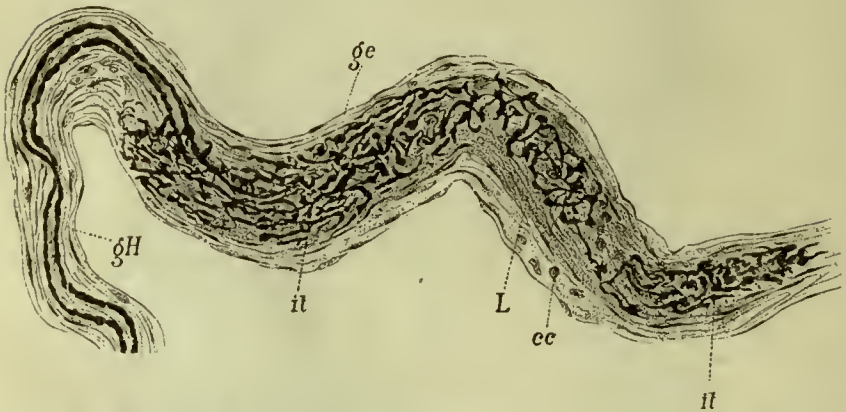


FIG. 247.—Terminal nerve corpuscle of Ruffini. The nerve fibres enter by one of the extremities of the corpuscle. It is easy to make out that Henle's sheath goes to form the capsule of the corpuscle. (After A. Ruffini, Arch. ital. de biol., Turin, t. xxi, 1894, pl. 1, Fig. 4.)

"Ruffini's endings." They receive their nerve fibres from the side (Fig. 246), or more rarely from one end (Fig. 247). The nerve fibre, when once inside the strong connective-tissue sheath, divides into numerous branches which show varicosities

\* Dogiel, A. S. Die Nervenendigungen im Lidrande und in der Conjunctiva palpbr. des Menschen. Arch. f. mikr. Anat., Bonn, Bd. xlv (1894-'95), S. 15-25.

† Ruffini, A. Di un nuovo organo nervoso terminale e sulla presenza dei corpuscoli Golgi-Mazzoni nel connettivo sottocutaneo dei polpastrelli delle dita dell' uomo. Mem. d. R. accad. d. Lincei, Anno cclxxvii (1893).—Sur un nouvel Organe nerveux terminal et sur la présence des corpuscules Golgi-Mazzoni dans le conjonctif sous-cutané de la pulpe des doigts de l'homme. Arch. ital. de biol., Turin, t. xxi (1894), pp. 249-265.

in their course and end in small free end knobs. Ruffini believes that they form actual anastomoses before terminating. The Ruffini ending is seen in cross-section in Fig. 248, and in

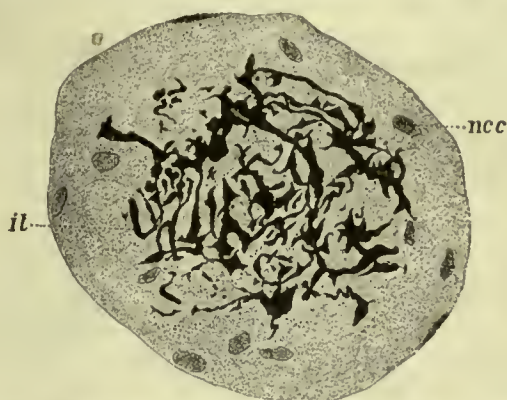


FIG. 248.—Transverse section of Ruffini's terminal corpuscle. (After A. Ruffini, *Arch. ital. de biol.*, Turin, t. xxi, 1894, pl. ii, Fig. 12.)

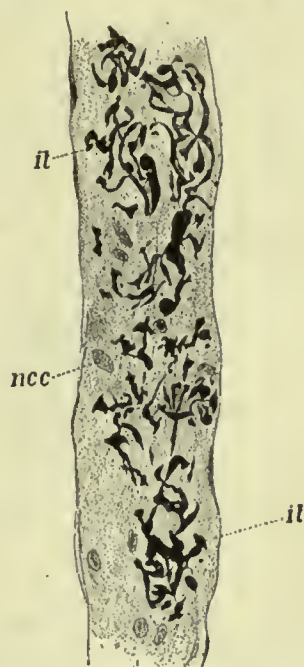

FIG. 249.—Oblique section of a terminal nerve corpuscle of Ruffini. (After A. Ruffini, *Arch. ital. de biol.*, Turin, t. xxi, 1894, Fig. 11.)

oblique section in Fig. 249. Ruffini's findings have been confirmed by Sfameni\* and by von Frey. That a number of end-

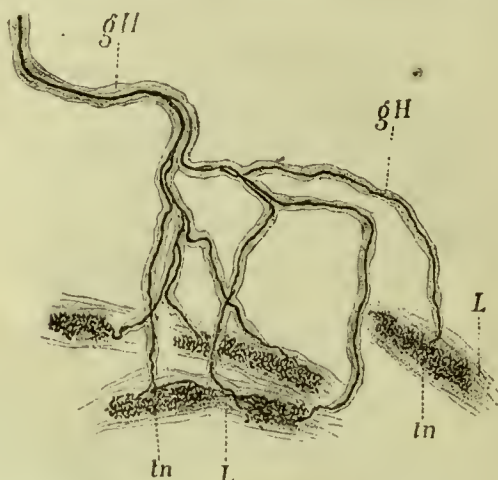


FIG. 250.—A nerve fibre is shown dividing into seven secondary fibres to which are attached five *organes nerveux terminaux* of Ruffini. (After A. Ruffini, Arch. ital. de biol., Turin, t. xxi, 1894, pl. ii, Fig. 10.)

ings may be attached to the subdivisions of one nerve fibre is well shown in Fig. 250. These corpuscles of Ruffini while they resemble the corpuscles of Golgi and Mazzoni, are really different from the latter.

A somewhat simpler structure than Meissner's corpuscles is met with in the so-called end bulbs of Krause,† which occur in the skin and in greater numbers in the conjunctiva. Each corpuscle consists of a sheath made up of flat connective-tissue cells continuous with the perineurium inside which is the so-called inner bulb, a finely granular mass which shows sometimes a concentric lamellation. In the centre of the inner bulb is the axis cylinder, the myelin sheath having been lost at its entrance into the organ. The axone runs out to end quite free at the upper end of the bulb, usually terminating in a slight button-shaped thickening. These structures have been studied also by Szymonowicz with the methylene-blue method.

\* Sfameni, P. Recherches comparatives sur les organes nerveux terminaux de Ruffini. Anat. Anz., Jena, Bd. ix (1894), S. 671-676.

† Krause, W. Die terminalen Körperchen der einfach sensiblen Nerven. Hanover (1860), 8vo.



His findings are well illustrated in Fig. 251. The end-bulbs in the conjunctiva where Krause first discovered them have been described by Dogiel (Fig. 252).

Not unlike these simple cylindrical end-bulbs of Krause, and differing from them in reality mainly in the complexity of the capsule, are the peculiar corpuseles variously known as the corpuseles of Vater, of Pacini, and of Herbst.\* The general appearance of the Pacinian corpusele from the cat's mesentery is well known to every medical student, since it forms a standard

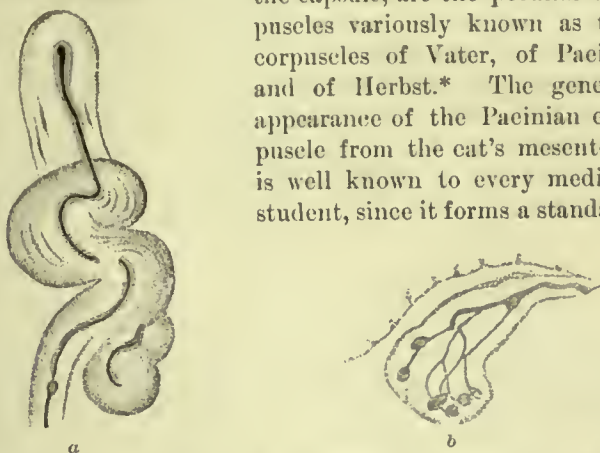


FIG. 251.—End bulbs stained by the methylene-blue method. (After W. Szymonowicz, *Arch. f. mikr. Anat.*, Bonn, Bd. xlv, 1895, Taf. xxxiii, Figs. 1 and 3.) *a*, spirally twisted end bulb; the axis cylinder, the inner bulb, and the connective-tissue layers can be seen; the small piece on the right-hand side below probably belongs to a second end bulb. *b*, terminal corpusele composed of several end bulbs.

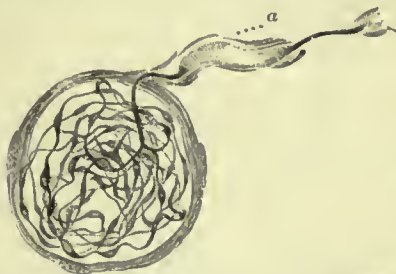

FIG. 252.—Terminal corpusele from the edge of the conjunctiva bulb. (After A. S. Dogiel, *Arch. f. mikr. Anat.*, Bonn, Bd. xxxvii, 1891, Taf. xxxiii, Fig. 3.) *a*, medullated nerve fibre, the axis cylinder of which goes over into a dense end skein.

object for study in every histological course. The corpusele, large enough to be visible to the naked eye, has a translucent

\* Herbst, G. *Die Pacinischen Körper und ihre Bedeutung. Ein Beitrag zur Kenntniss der Nervenprimitivfasern.* Göttingen, 1848, 8vo.

appearance. The fibrous sheath of the nerve is continuous with the connective-tissue sheath of the corpuscle, the latter consisting of from twelve to fifteen or more concentric lamellæ. The myelin sheath passes for some distance into the organ, but as soon as the nerve fibre has reached the inner bulb the myelin sheath disappears and the axis cylinder runs naked in the centre of the inner bulb. At the apex of the bulb the nerve fibre often divides into several processes, all of which run out to end free in the granular substance of the bulb. Ehrlich's method is very suitable for the study of these structures, as Dogiel \* and Kallius † have shown, inasmuch as the nerve fibre stains of an intense blue or purplish color, while the granular substance of the inner bulb stains only feebly (Fig. 253). Retzius ‡ has

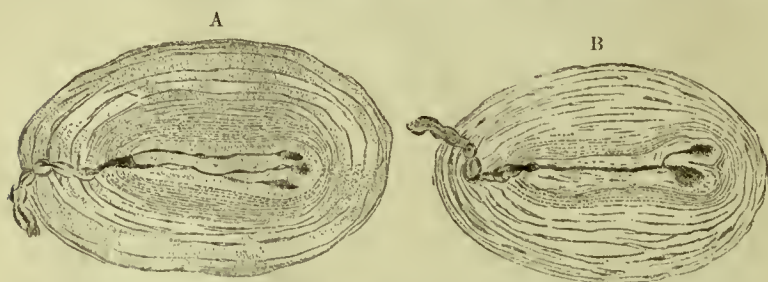

FIG. 253.—Herbst's corpuscles. Methylene-blue staining. (After A. S. Dogiel, *Arch. f. Anat. u. Physiol.*, Leipz., 1891, Anat. Abth., Taf. xi, Fig. 11.) The axis cylinder entering the corpuscle A breaks up inside the inner bulb into three branches, each of which terminates in an end knob; in the corpuscle B a side twig is given off in the inner bulb from the main fibre, also terminating in an end knob.

studied them also by using Golgi's method. The surface of the terminal fibre shows many black prickly projections. Simple treatment of Pacinian corpuscles with dilute acetic acid, however, shows practically all the details of the structure (Fig. 254). Pacinian corpuscles occur in the skin of human beings in the connective tissue near joints, in periosteum, on tendons, and in the connective tissue of the serous membranes, pericardium, pleura, and peritonæum.

\* Dogiel, A. Die Nervenendigungen in Tastkörperchen. *Arch. f. Anat. u. Physiol.*, Anat. Abth., Leipz., Jahrg. (1891), S. 181-192.

† *Op. cit.*

‡ Retzius, G. Die Pacinischen Körperchen in Golgischer Färbung. *Biol. Untersuch.*, Stockholm, n. F., Bd. vi (1894), S. 65.

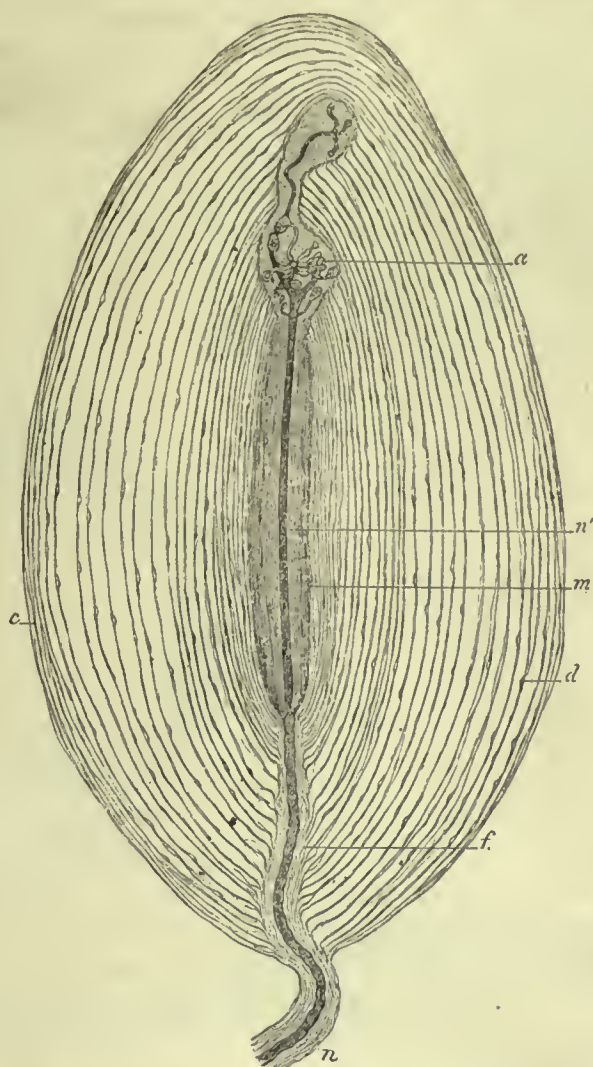


FIG. 254.—Corpuscle of Pacini of the mesentery of an adult cat; studied fresh without addition of any reagent. *c*, capsules; *d*, endothelial rows separating the corpuseles; *n*, nerve fibre leaving corpusele; *f*, perineurial sheath; *m*, central mass or so-called inner bulb; *n'*, terminal fibre; *a*, point where one of the branches of the terminal fibre divides into a large number of branches which go to form numerous terminal bulgings. (After L. Ranvier, *Traité technique d'histologie*, Paris, 1875, p. 923, Fig. 309.)

Ruffini\* describes a modified form of Vater's corpuscle in different parts of the body, which he designates the "Golgi-Mazzoni corpuscle." It is in reality the same corpuscle described by Golgi in tendons (*vide infra*). He finds that the nerve fibres inside these bodies divide oftener than in typical Pacinian corpuscles, although they always end free in flat bulb-like expansions. Ruffini finds them not only on tendons but in the subcutaneous connective tissue of the finger tip (Fig. 255). It is evident that Krause's bulbs, the Vater-Pacinian corpuscles, the tendon-corpuscle of Golgi, the terminal corpuscle of Mazzoni,† and the Golgi-Mazzoni corpuscle of Ruffini are closely allied varieties of nerve endings. In the same group are probably also to be placed some of the so-called genital corpuscles.‡ They have been carefully studied with the methylene-blue method by Retzius.\* The main difference between them and the Pacinian corpuscle lies in the fact that the genital corpuscle has fewer lamellæ in its connective-tissue sheath (*vide* Figs. 256-258). These bodies have been studied in human beings and in the mouse by Dogiel || (Figs. 259-261).

---

\* Ruffini, A. Di una particolare reticella nervosa e di alcuni corpuscoli del Pacini che si trovano in concessione cogli organi muscolo tendinei del gatto. Atti d. r. Accad. d. Lincei, An. cclxxxix (1892). Serie II. Rendic. Cl. di sc. fis., mat. e nat., Roma, vol. i, fase. 13, 1 Semestr. (1892), pp. 542-646.—Sur un réticule nerveux spécial et sur quelques corpuscles de Pacini qui se trouvent en connexion avec les organes musculo-tendineux du chat. Arch. ital. de biol., Turin, t. xviii (1892), pp. 101-105.—Also, Sur un nouvel organe nerveux terminal et sur la présence des corpuscles Golgi-Mazzoni dans le conjonctiv sous-cutané de la pulpe des doigts de l'homme. Arch. ital. de biol., Turin, t. xxi (1894), pp. 249-265.—Sopra dui speciali modi d'innervazione degli organi muscolo-tendinei di Golgi con riguardo speciale alla struttura del tendinetto del organo muscolo-tendineo ed alla maniera di comportarsi delle fibre nervose vasomotorie nel perimio del gatto. Monitore zool. ital., Firenze, vol. viii (1897), pp. 101-105.

† Mazzoni. Osservazioni microscopiche sopra i cosiddetti corpuscoli terminali dei tendini dell' uomo e sopra alcune particolari piastre nervose superficiali che si trovano nei medesimi tendini. Mem. Accad. d. sc. d. Ist. di Bologna, S. 6, vol. 1 (1891).

‡ *Wollustkörperchen* of the Germans.

\* Retzius, G. Ueber die Endigungsweise der Nerven in den Genitalnervenkörperchen der Kaninchen. Internat. Monatsehr. f. Anat. u. Physiol., Leipz., Bd. vii (1890), S. 323-333.

|| Dogiel, A. S. Die Nervenendigungen in der Haut der äusseren Genitalorgane des Menschen. Arch. f. mikr. Anat., Bonn, Bd. xli (1893), S. 588-612.



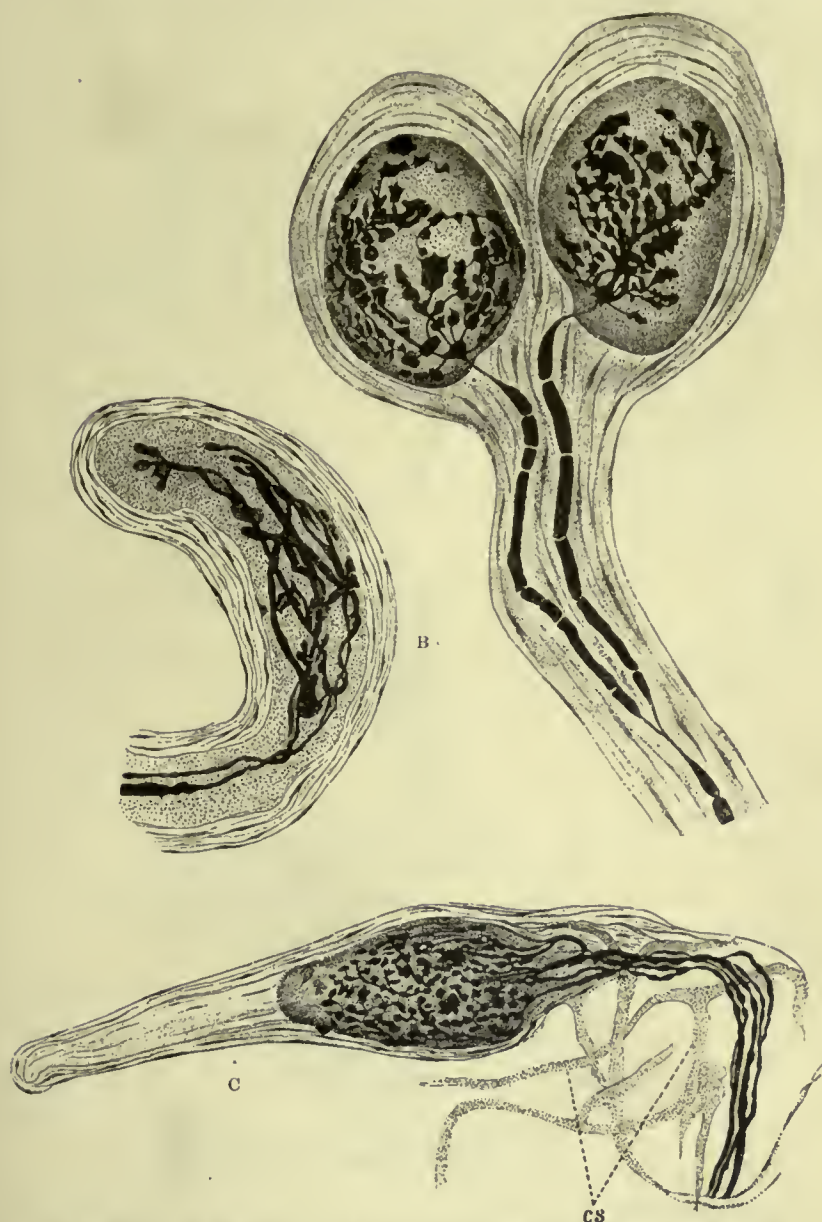

FIG. 255.—Golgi-Mazzoni corpuscles found by Ruffini in the subcutaneous connective tissue of the pulp of the finger. (After A. Ruffini, *Arch. ital. de biol.*, Turin, t. xxi, 1894, pl. iii, Figs. 14, 15, and 16.)

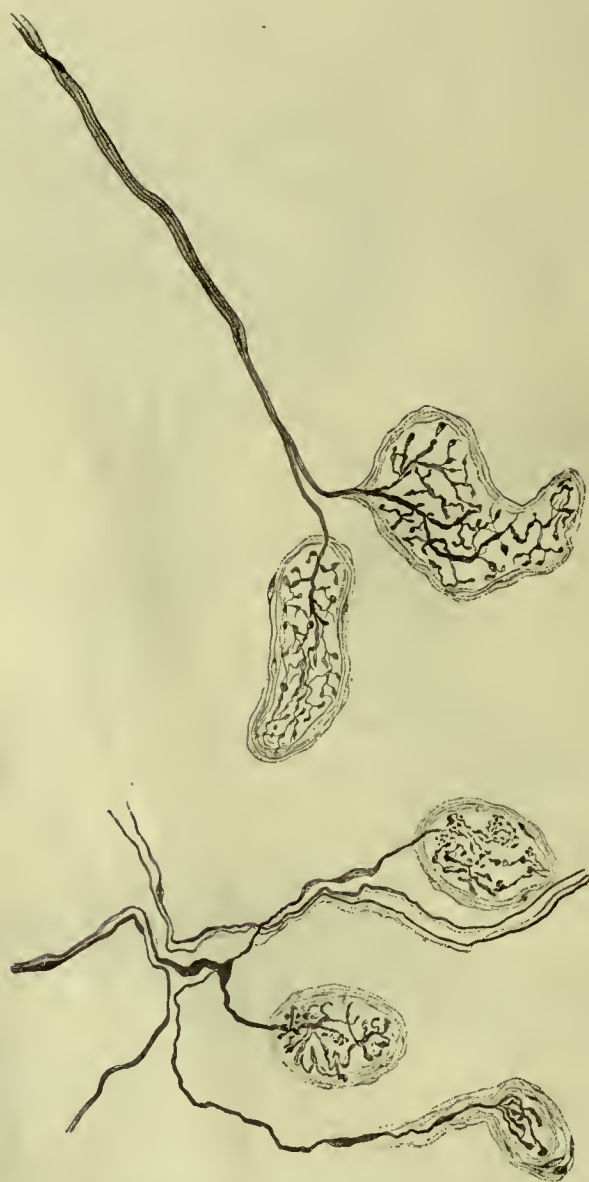

FIG. 256.—Genital nerve corpuscles from the mucous membrane of the clitoris of the rabbit. Methylene-blue staining. (After G. Retzius, *Internat. Monatsschr. f. Anat. u. Physiol.*, Leipz., Bd. vii, 1890, Taf. xiv, Figs. 1 and 2.)

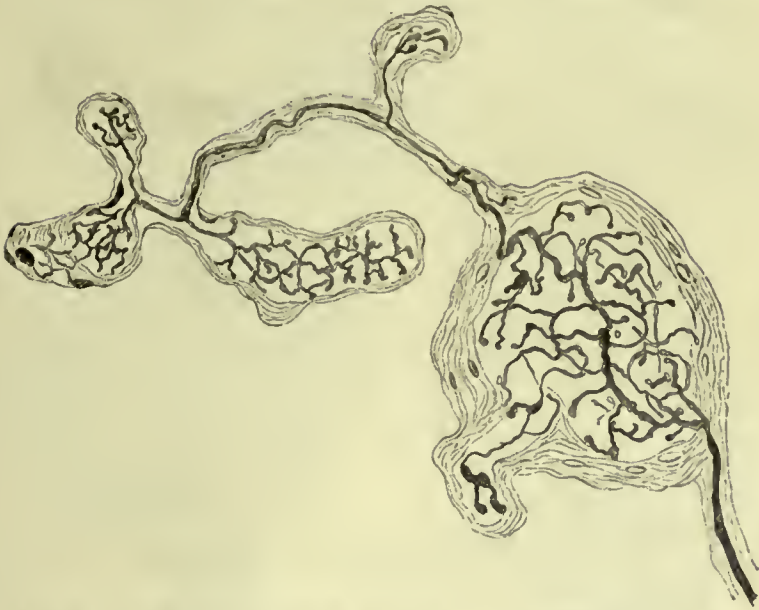


FIG. 257.—Genital nerve corpuscles from the mucous membrane of the glans penis of the rabbit. Methylene-blue staining. (After G. Retzius, *Internat. Monatsschr. f. Anat. u. Physiol.*, Leipz., Bd. vii, 1890, Taf. xv, Fig. 15.)

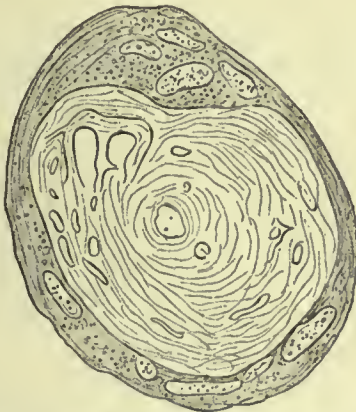

FIG. 258.—Cross section of genital nerve corpuscle from the clitoris of the rabbit. Fixation with Flemming's fluid; hematoxylin staining. (After G. Retzius, *Internat. Monatsschr. f. Anat. u. Physiol.*, Leipz., Bd. vii, 1890, Taf. xv, Fig. 16.)

A peculiar form of nerve ending hitherto undescribed has been found by Dogiel\* in the connective tissue of the cornea. He has made out in this situation peculiar free terminals in the form of definite end-platelets. He describes nerve branches which run more or less parallel to the margin of the cornea, sometimes in radial directions toward the centre of this structure. At their extremities are found flat quadrangular or

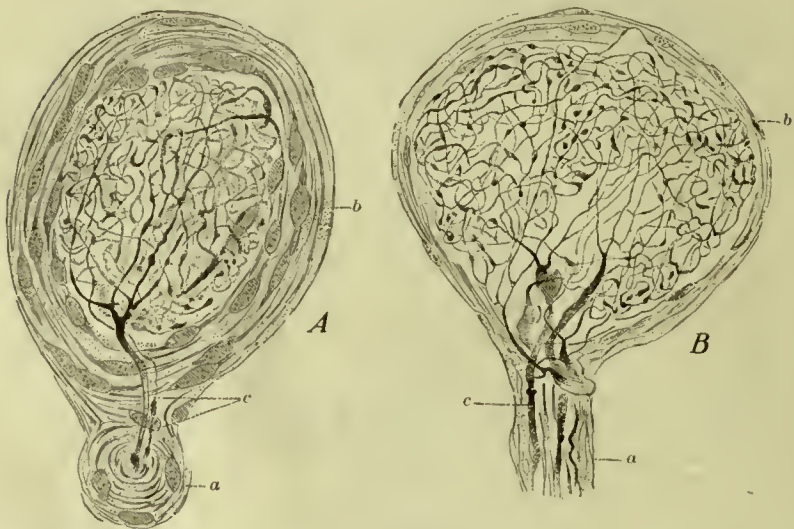


FIG. 259.—Genital nerve corpuscles from human glans penis. *a*, sheath of a nerve stem; *b*, sheath of corpuscle with nuclei of flat cells in same; *c*, axis cylinders of nerve fibres which branch inside the inner bulb of the corpuscle. (After A. S. Dogiel, *Arch. f. mikr. Anat.*, Bonn, Bd. xli, 1893, Taf. xxxii, Figs. 2 and 3.)

irregularly rounded end-platelets, some of which show concavities and indentations, with uneven and jagged borders (Fig. 262). The size of the individual platelets varies much. They never contain nuclei, and they sometimes resemble closely the corneal cells, but in reality have no connection with the latter. It is not impossible, as Kallius points out, that the older ideas of Kühne, Waldeyer, Izquierdo, and others, concerning the im-

\* Dogiel, A. S. *Die Nerven der Cornea des Menschen.* *Anat. Anz.*, Jena, Bd. v (1890), S. 483-494.—*Die Nervenendkörperchen (Endkolben, W. Krause) in der Cornea und Conjunctiva bulbi des Menschen.* *Arch. f. mikr. Anat.*, Bonn, Bd. xxxvii (1891), S. 602-619.



mediate connection between nerves and the protoplasm of the connective-tissue cells of the cornea, may thus be explained.

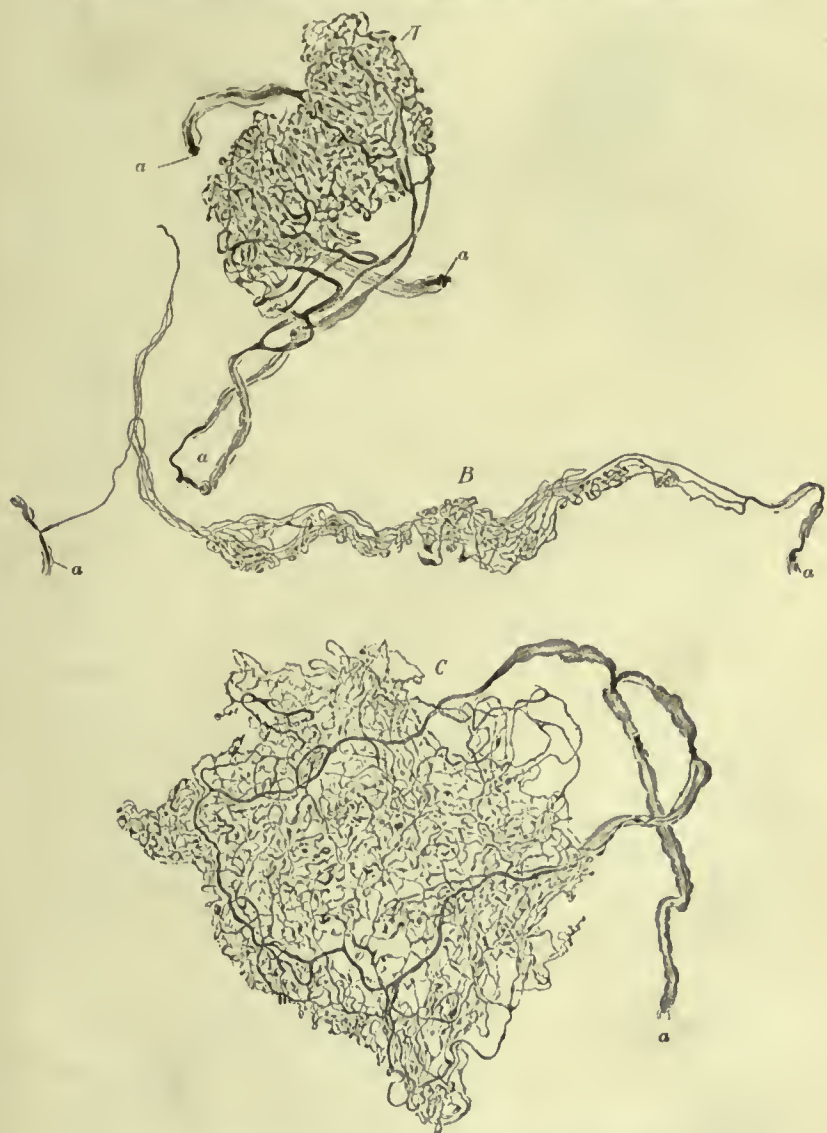


FIG. 200.—Genital nerve corpuscles of different forms from the human glans penis. (After A. S. Dogiel, Arch. f. mikr. Anat., Bonn, Bd. xli, 1893, Taf. xxxii, Figs. 6 and 7, and Taf. xxxiii, Fig. 8.) *a*, medullated nerve fibres.

The enormous number of nerve fibres which have been described in the connective tissue of the mucous membrane of the stomach and intestine by Erik Müller, Berkley, Ramón y Cajal, and others, are thought by many to be mainly motor for the innervation of smooth muscle, and secretory for the innervation of glands. There can be but little doubt, however, that among these are many fibres which carry centripetal impulses. They have been studied with the method of Golgi, and also with the method of Ehrlich.

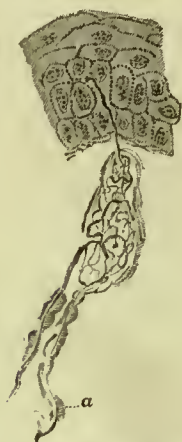

FIG. 261.—End bulb from glans penis of a white mouse. *a*, medullated nerve fibres, the axis cylinders of which end in a nerveskein. From the skein a fine nerve fibre can be seen going out to end among the epithelial cells. (After A. S. Dogiel, *Arch. f. mikr. Anat.*, Bonn, Bd. xli, 1893, Taf. xxxiii, Fig. 18.)

The nerve endings in the meninges of the brain in animals have been investigated recently by D'Abundo \* and Jacques,† who find that both the spinal and cerebral dura mater is rich in nerves, particularly in non-medullated fibres. With the methylene-blue method free end-arborizations and pencil-like nerve endings are to be made out inside the bundles of connective tissue. Acquisto and Pusateri ‡ have since studied the endings in the human cerebral dura mater, and describe and figure, in addition to vaso-motor filaments, endings which are probably those of centripetally conducting nerves. They suggest the hypothesis that variations in the pressure of the cerebrospinal fluid may by means of these lead to reflex vaso-motor phenomena. If this idea be found later to correspond with the facts, the nerve endings of the dura mater must subserve physiological functions of no mean significance.

\* D'Abundo. La innervazione della dura madre cerebrale. Comunicazione fatta alla società. *Riforma med.*, Anno x, No. 42 (1884).

† Jacques, P. Note sur l'innervation de la dure-mère cérébrospinale chez les mammifères. *J. de l'anat. et physiol.* [etc.], Par., t. xxxi (1895), pp. 596-609.

‡ Acquisto, V., ed E. Pusateri. Sulle terminazioni nervose nella dura madre cerebrale dell' uomo. *Riv. di patol. nerv.*, Firenze, vol. i (1896), pp. 267-270.

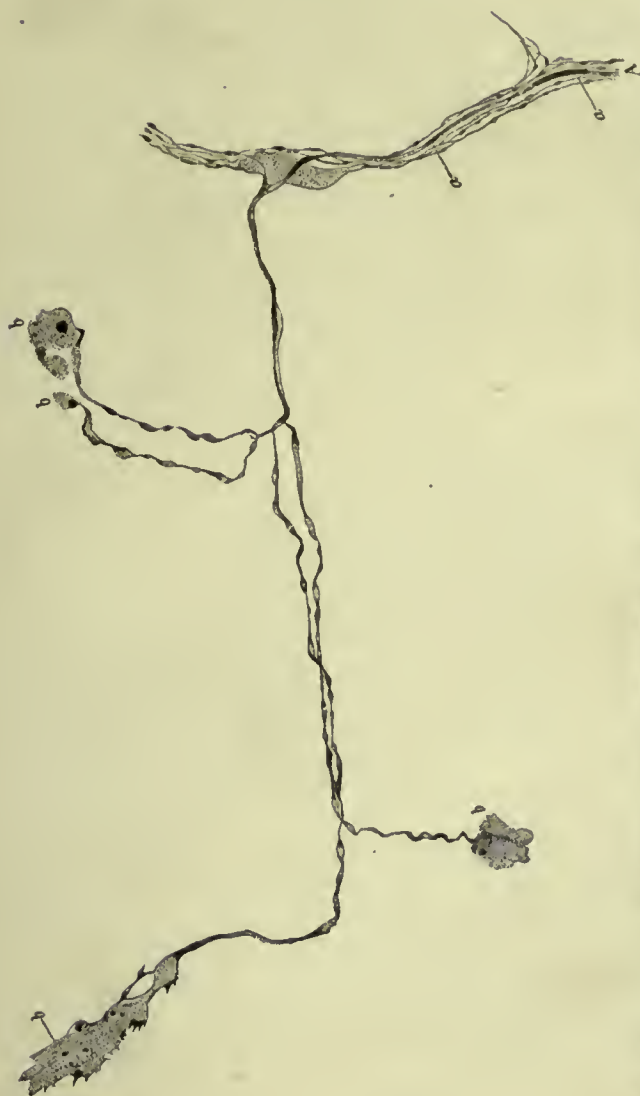

FIG. 262.—A, branch of one of the anterior nerve fibres of the cornea; a, axone of a medullated nerve fibre; this breaks up into delicate branches which run out to end plates (b) in the connective tissue. (After A. S. Dogiel, Arch. f. mikr. Anat., Bonn, Bd. xxxvii, 1891, Taf. xxxiv, Fig. 11.)

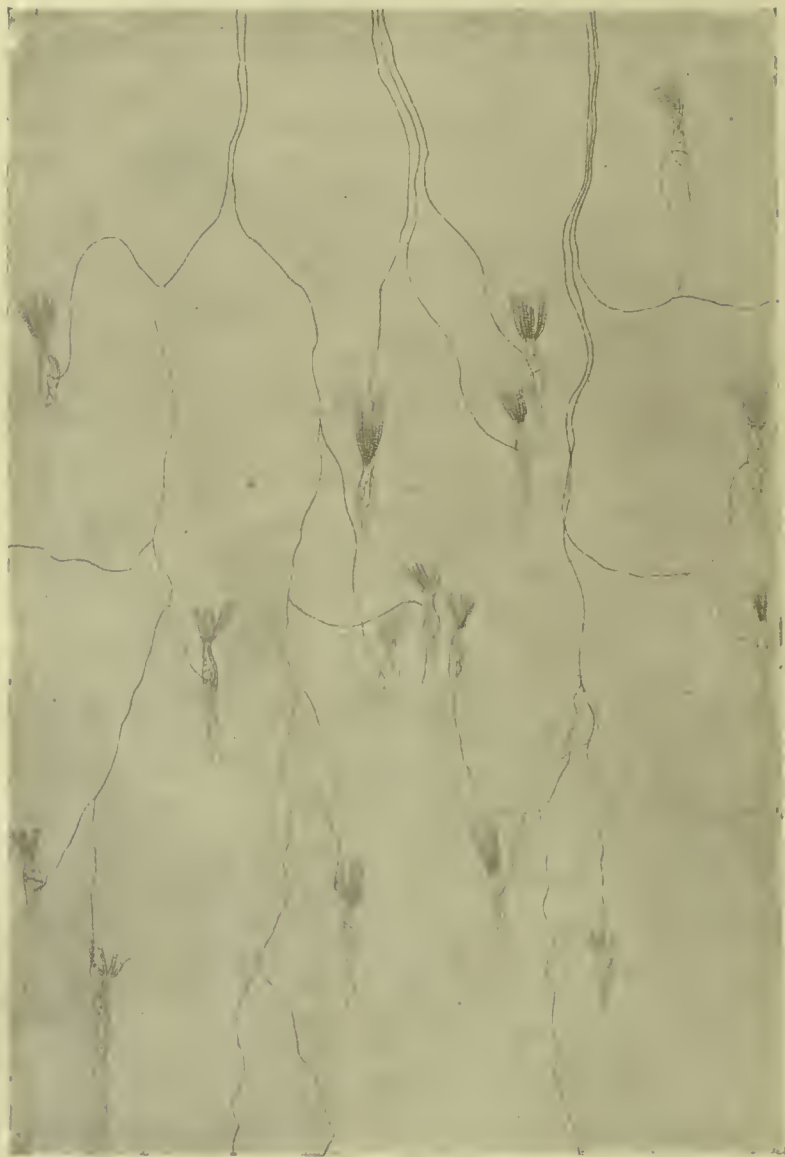

FIG. 263.—Musculo-tendinous nerve ending of Golgi. The drawing shows the distribution of the musculo-tendinous organs in a piece of the upper part of the tendon plate which belongs to the muscles of the back of the rabbit. From the upper part of the plate there come three nerve bundles which give off numerous fibres, each going to a musculo-tendinous end organ. (After C. Golgi, 1880, *Gesammelte Untersuchungen*, Jena, 1894, Taf. xxix, Fig. 4.)



The sensory nerve endings in tendons since they were described by Golgi\* in 1878 have been the object of many researches. According to Golgi, they form true terminal plaques, from two to thirty of these plaques making up a single corpuscle (Fig. 263). He found them in voluntary muscles located at the junction of the muscle fibres with the tendon. The whole corpuscle, as described by Golgi, is fusiform, and is situated on the surface of the tendon, being formed of granular substance, and possessing an envelope of several hyaline concentric layers, in which are imbedded a certain number of nuclei. The nerve fibres on entering the corpuscle lose their neurilemma, but at first retain their myelin sheaths, dividing into two or three medullated fibres, each of which then gives rise to a true end-arborization of naked nerve fibrils. Each corpuscle receives at least one nerve fibre, though usually at least four or five pass to it.

Very extensive studies of the endings of nerves in tendons have been made since by Ciaccio.† He has examined the tendons in several classes of vertebrates as well as in human beings, and finds similar relations in all (Figs. 264-267). The nerves entering the tendons divide, according to Ciaccio, into several branches, the individual fibres running in between the tendon bundles. On their way they lose their myelin sheaths, and the connective-tissue sheaths fuse with the connective tissue of the tendon bundles. As the fibres pass on, they divide repeatedly, and finally end free with small varicose bulgings, surrounding the tendon bundles, in the form of spirals or rings. The structures described by many as nuclei in these endings, Ciaccio feels sure, are nothing more than peculiar nodosities of

\* Golgi, C. Ueber die Nerven der Sehnen des Menschen und anderer Wirbeltiere und ueber ein neues nervöses musculo-tendinöses Endorgan. Untersuchungen ueber den feineren Bau des centralen und peripherischen Nervensystems. Uebers. v. R. Teuscher., Jena (1894), S. 203-216.

† Ciaccio, G. V. Intorno alle piastre nervose finali ne'tendini de'Vertebrati; nuove investigazioni microscop. Mem. Accad. d. sc. d. Ist. di Bologna, 1889, 4 s., vol. x (1890), pp. 301-324.—Sur les plaques nerveuses finales dans les tendons des vertébrés. Nouvelles recherches microscopiques [Transl.]. J. de mierog., Par., t. xiv (1890), 172; 201; 234.—Nuove investigazioni microscopiche intorno alle piastre nervose finale sui tendini delle 5 classi di vertebrati. Rendic. Accad. d. sc. d. Ist. di Bologna (1890-'91), pp. 19-20.—Sur les plaques nerveuses finales dans les tendons des vertébrés. Arch. ital de biol., Turin, t. xiv (1890), pp. 31-57.

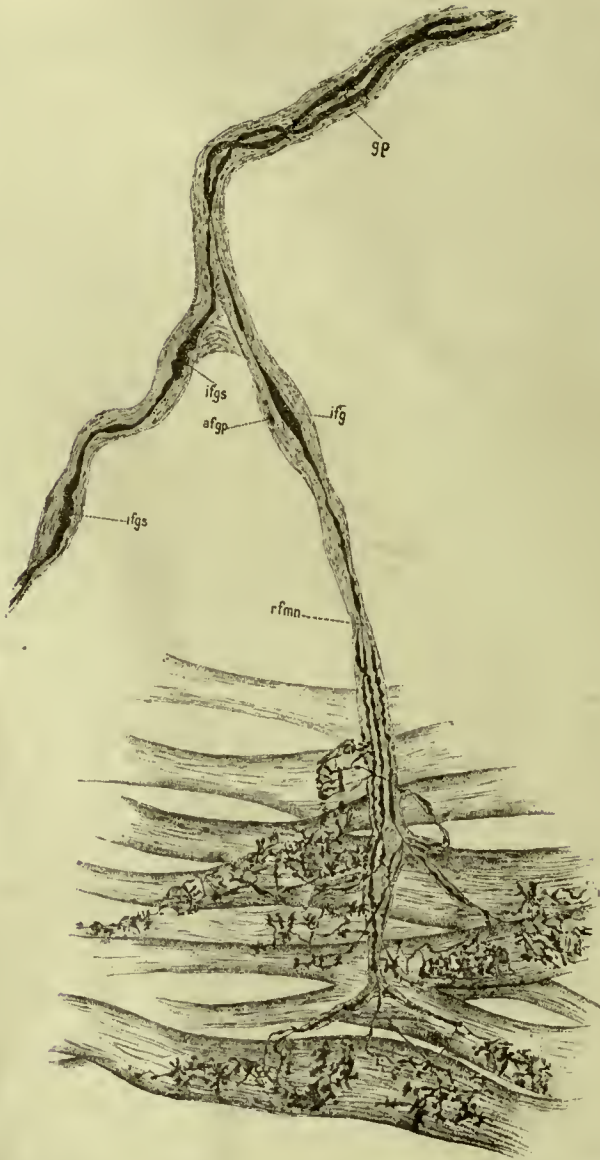


FIG. 264.—Tendinous expansion of one of the muscles of man. (After G. V. Ciaccio, Arch. ital. de biol., t. xiv, 1891, pl. i, Fig. 1.) Large terminal nerve plaque composed of several portions, equal in number to the branches into which the fibre which gives rise to the plaque divides. Loewit's gold method. *afgp*, fusiform thickening of the perineural sheath; *ifg*, fusiform thickening of the medullated nerve fibre inside; *ifgs*, slight sinuosity of fusiform thickening of nerve fibre; *gp*, perineural sheath; *rfma*, branching of the axis cylinder.

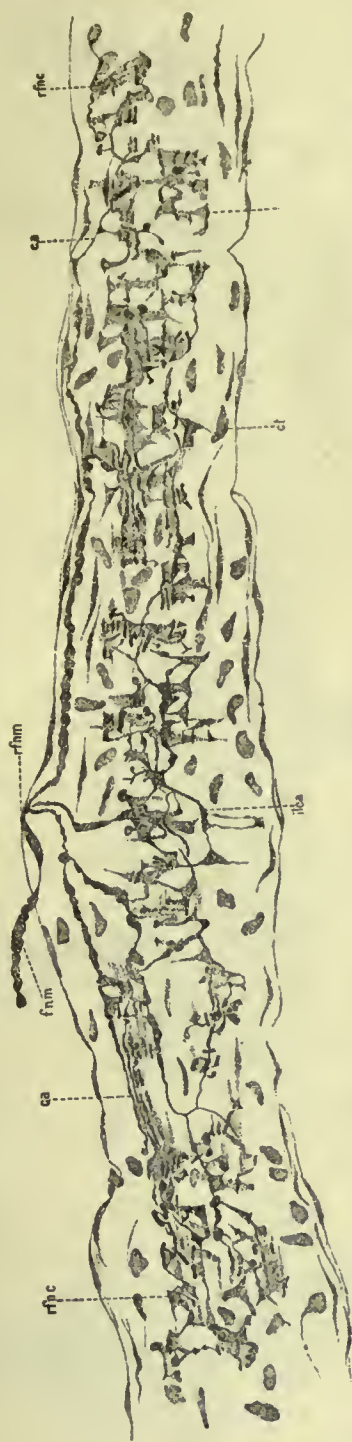

FIG. 265.—A terminal musculo-tendinous organ in which a terminal nerve plaque occupies nearly the length of the tendon. (After G. V. Ciaccio, Arch. ital. de biol., Turin, t. xiv, 1891, pl. i, Fig. 4.) *ca*, axis cylinders; *ct*, tendon corpuscle; *fnc*, medullated nerve fibre; *ilc*, thickening in the course of an axis cylinder; *rfnc*, ultimate ribbonlike ramifications of the axones; *rfnc*, ramifications of the medullated nerve fibre.

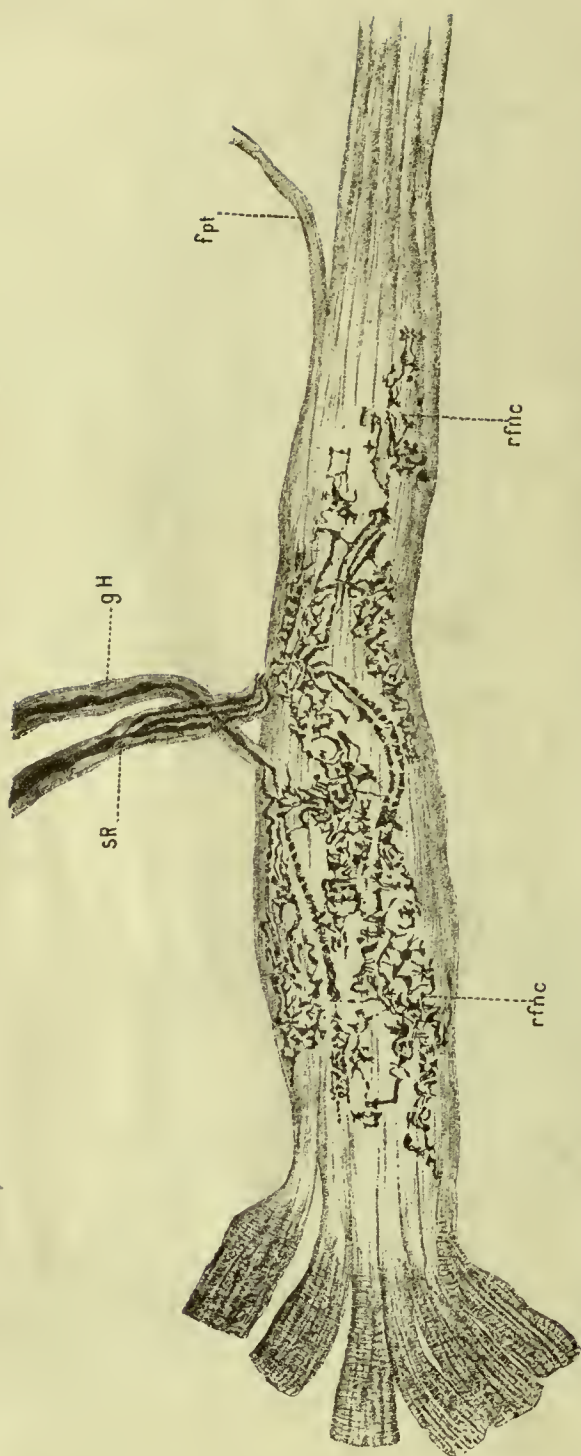


FIG. 206. — Human tendo calcaneus (Achillis); F, musculo-tendinous terminal organ with final nerve plaque in the same. (After G. V. Ciaccio, Arch. ital. de biol., Turin, t. xiv, 1894, pl. ii, Fig. 6.) *fpt*, primitive fibrillary bundles of the tendon; *gH*, Henle's sheath; *SR*, code of Ranvier; *rfnc*, ultimate ribbon-shaped ramifications of the axones.



the nerve fibres. He denies definite encapsulation with connective tissue, such as Golgi described, and further lays stress on the relation of the endings to the tendons proper, independent

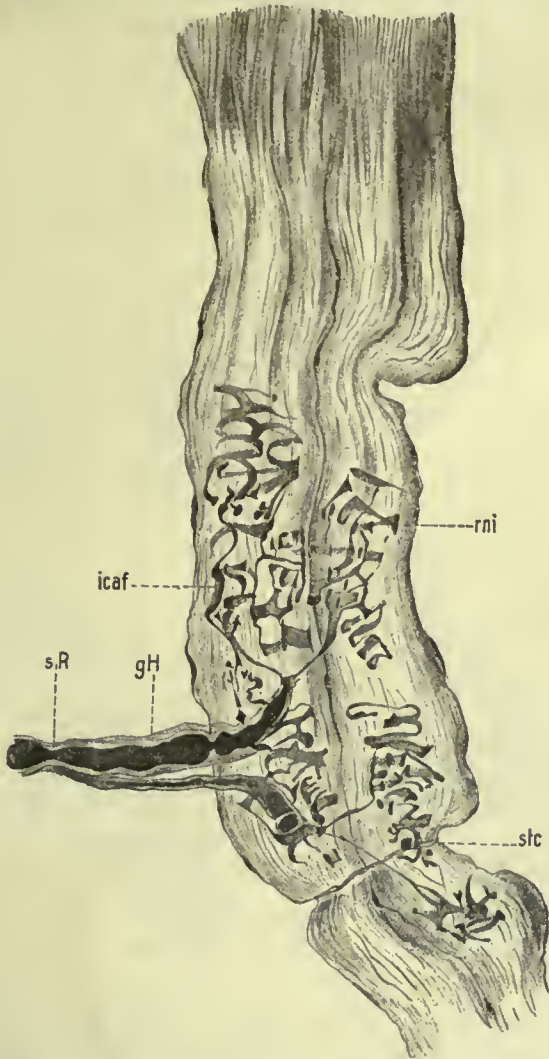


FIG. 267.—Tendinous expansion of one of the motor muscles of the eye of an ox. (After G. V. Ciaccio, *Arch. ital. de biol.*, t. xiv, 1891, pl. iv, Fig. 27.) Two musculo-tendinous organs of Golgi united with one another and compressed toward the lower extremity by a band of connective tissue. Each corpuscle of Golgi has its own ultimate nerve plaque. These two plaques show both the bushlike and ringlike endings.

of the muscles, a view again in contradiction to that of Golgi. The endings always lie inside the tendons, apparently never on

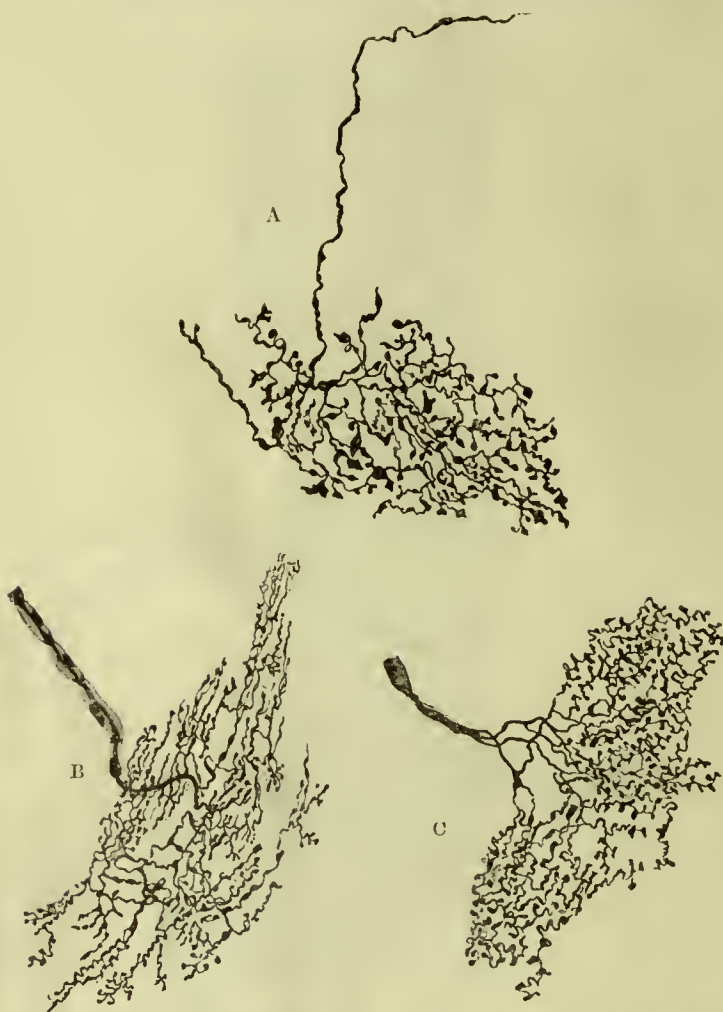


FIG. 268.—A, sensory nerve ending from exocardium of upper half of left atrium of the heart of the gray rat. B and C, sensory nerve endings from the endocardium of the dog. (After A. Smirnow, *Anat. Anz.*, Jena, Bd. x, 1895, S. 745, Figs. 3, 4, 5.)

their sheaths. Ciaccio calls them *plaques tendineuses avec terminaison buissonneuse des nerfs à spirals ou à anneaux*. As

we have said, these endings of Golgi, Ciaccio, and Mazzoni are probably closely allied to Pacinian corpuscles.

As to the endings of nerves inside the interstitial connective tissue of organs we have data concerning the heart, lungs, and certain parts of the eye. The sensory nerve endings in the endocardium of the auricles and ventricles, as well as the auriculo-ventricular valves and the chordæ tendineæ of amphibians and mammals, have been studied by Smirnow,\* who has also attempted to make out the alterations in the endings after section of the nerves to which they correspond (Fig. 268). The nerve endings in the lung have been examined by Berkley,

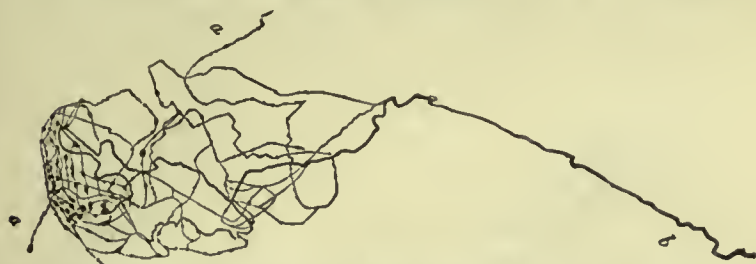

FIG. 269.—Nerve endings in the lung of the frog; large skein with entering medullated nerve fibre (*b*) and two threads leaving the skein *a*. (After A. Smirnow, *Anat. Anz.*, Jena, Bd. iii, 1888, S. 259, Fig. 2.)

Cuccati,† and Smirnow ‡ (Fig. 269). The endings here in the connective tissue are not unlike those found in that of the heart.

Melkich\* has studied the free endings of sensory nerves in the connective tissue in the iris of birds by Ehrlich's method and finds two varieties of nerve endings in this region: On the posterior surface of the iris a plexus of very fine nerve fibres which, after manifold division and interlacing, end free, never forming anastomoses. The other variety, situated near the

\* Smirnow, A. Ueber die sensiblen Nervenendigungen im Herzen bei Amphibien und Säugetieren. *Anat. Anz.*, Jena, Bd. x (1895), S. 733-749.

† Cuccati, G. Intorno al modo onde i nervi si distribuiscono e terminano nei polmoni e nei muscoli addominali del Triton cristatus. *Internat. Monatschr. f. Anat. u. Physiol.*, Leipz., Bd. vi (1889), S. 237-249. Also *Bull. d. sc. med. di Bologna*, 6. s., vol. xxiii (1889), pp. 304-307.

‡ Smirnow, A. Ueber Nervenendknäuel in der Froschlunge. *Anat. Anz.*, Jena, Bd. iii (1888), S. 258-261.

\* Melkich. Zur Kenntniss des Ciliarkörpers und der Iris bei Vögeln, mitgetheilt von Prof. Arnstein. *Anat. Anz.*, Jena, Bd. x (1895), S. 28-35.

muscle fibres of the iris, arises from the division of medullated nerve fibres which form free nerve endings after repeated dendritic subdivisions (Fig. 270). He does not think that they are motor fibres, but believes that they represent the sensory element in accommodation, the first variety, according to his

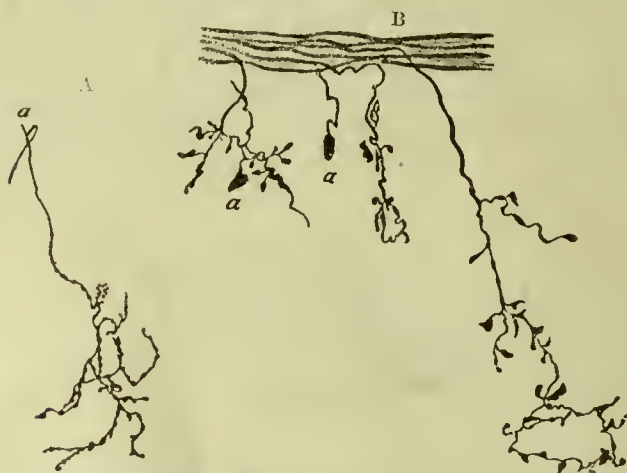


FIG. 270.—Sensory nerve endings in the ciliary body of birds. (After Melkisch, *Anat. Anz.*, Jena, Bd. x, 1895, S. 30, Figs. 2 and 3.) *A*, sensory end arborization from the ciliary body near the elastic ring; *a*, medullated nerve fibre; *B*, tendril-like nerve endings in connection with the medullated nerve fibre which arises directly from a nerve trunk. At *a* are seen some granular plates.

idea, carrying impulses concerned in pain sensations. Very similar nerve endings have been described in the connective tissue of the ciliary body in the eye of the cat and of man by Agababow\* (Fig. 271).

Turning now to the sensory nerve endings in voluntary, cardiac, and involuntary muscles, the former may first be described. In addition to Pacinian corpuscles and end bulbs, not unlike those described by Krause in the conjunctiva, which occur in considerable numbers in the muscles (Kerschner) and the *organi musculi-tendinei* of Golgi, above referred to, the principal ending believed to be sensory in voluntary muscle is the so-called muscle spindle (Kühne, Forster)† or neuro-mus-

\* Agababow, A. Die Innervation des Ciliarkörpers. *Anat. Anz.*, Jena, Bd. viii (1892-'93), S. 555-561.

† Forster, Laura. Zur Kenntniss der Muskelspindeln. *Arch. f. path. Anat.*, etc., Berl., Bd. cxxxvii (1894), S. 121-154.



cular bundle (Roth). These organs were first seen in the frog in 1861 by Weissmann, who thought them to be definite organs inside the muscle. They have since been studied and described by a whole series of observers in many different animals as well as in human beings. Kühne, who introduced the term "muscle spindle," described a special form of the structure in reptiles. Many authorities, among whom may be mentioned Eisenlohr, Babinski, and Fraenkel, have studied them in diseased muscle and thought them to be pathological phenomena. In 1878 Ranvier expressed the view that they represented an especial physiological mechanism standing in a definite relation to the nervous system, a view which has been accepted by Roth, Kersehnner,\* Christomanos and Strossner, Laura Forster, and in fact by the majority of recent investigators.

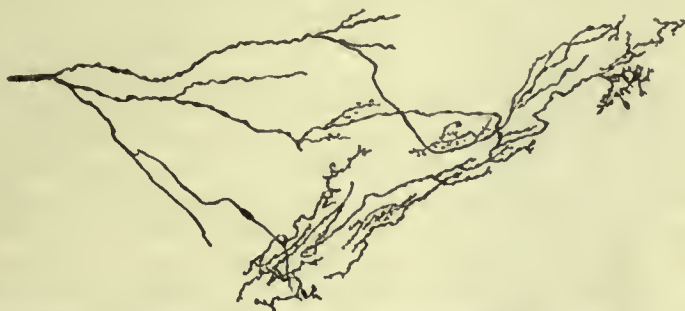

FIG. 271.—Nerve endings in ciliary body demonstrated by the method of Golgi. (After A. Agababow, *Anat. Anz.*, Jena, Bd. viii, 1893, S. 558, Fig. 2.) The figure shows a delicate nerve stem which breaks up into single nerve fibres, which in turn run out to form end arborizations which lie at different depths in the tissue.

The muscle spindles consist of long, narrow, hollow structures, containing within them striped muscle fibres, blood vessels, connective tissue, and medullated nerve fibres. The openings at the ends are partially closed by bundles of muscle fibres,

---

\* Kersehnner, L. Ueber Muskelspindeln. *Verhandl. d. anat. Gesellsch.*, Jena, Bd. vi (1892), S. 85-89.—Bemerkungen neber ein besonderes Muskelsystem im willkürlichen Muskel. *Anat. Anz.*, Jena, Bd. iii (1888), S. 126-132.—Beitrag zur Kenntniss der sensiblen Endorgane. *Anat. Anz.*, Jena, Bd. iii (1888), S. 288-296.—Ueber die Fortschritte in der Erkenntniss der Muskelspindeln. *Anat. Anz.*, Jena, Bd. viii (1892-'93), S. 449-458.—Bemerkungen zu Herrn Dr. Angelo Ruffini's Aufsatz: Considerazioni critiche sui recenti studi dell' apparato nervoso nei fusi muscolari. *Anat. Anz.*, Jena, Bd. ix (1893-'94), S. 553-562.

vessels, nerves, and connective tissue. The whole mass of structures inclosed in a common sheath is considerably wider in the middle than at the end. Lymph interspaces exist throughout the spindle, while through the centre of it runs a lymph space of considerable size. The sheath corresponds in character to the perineurium of a peripheral nerve. At the ends of the spindle it is thin, but it increases in thickness toward the widened parts. The number of striped muscle fibres present in a single spindle varies in its different parts. They are usually fewer at the ends, where the fibres are also finer, more numerous in the middle of the spindle, where the individual fibres are also thicker. The fibres are beautifully striated, as one can easily make out in longitudinal sections. The nerve fibres, like the muscle fibres, vary in numbers at different levels in the spindle. Forster\* found eleven muscle fibres and six nerve fibres in a cross section of one spindle, and in that of another ten muscle fibres and eight nerve fibres.

The nerves enter the spindle in different parts of its course, pene-

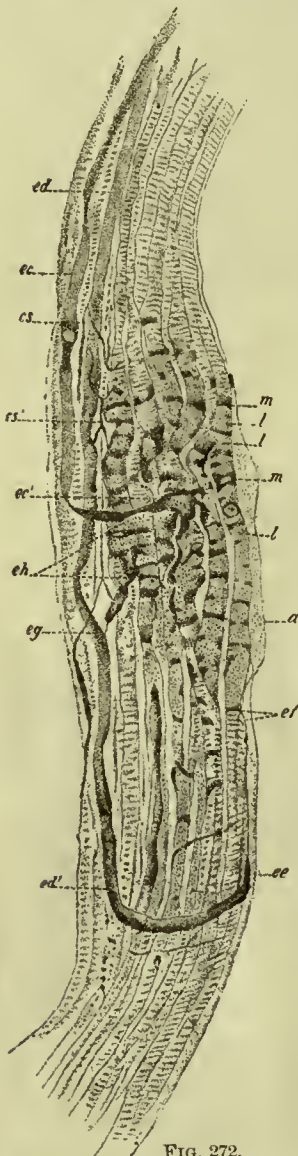


FIG. 272.

FIG. 272.—Muscular spindle from *myoxus avellanarius*. (After S. Trinchese, Mem. Accad. d. sc. d. Ist. di Bologna, 4. s., t. x, 1889-'90, Fig. 7.) *a*, sheath of the muscle spindle; *cs*, axis cylinder penetrating the internuclear protoplasm; *ec*, another axis cylinder entering the internuclear protoplasm; *ed*, *ef*, axis cylinder penetrating the internuclear protoplasm; *eh*, axis cylinder in various depths of the internuclear protoplasm; *l*, nuclei of the muscles.

\* *Op. cit.*

trating the sheath after running a short distance in it. They are often accompanied by blood vessels, which are present not only in the capsule, but also inside the neuro-muscular bundle. The muscle and nerve fibres inside are separated from one another by strands of white fibrous connective tissue. Between the sheath and its contents is situated a peripheral lymph space through which a few single fibres run.

The number of spindles in a single muscle is very large; as many as thirteen have been counted in one cross section through the genioglossus muscle. They may be situated in the various parts of the muscle itself, in the external perimysium, partly in the tendon and partly in the muscle, or they may be wholly surrounded by tendon. The bodies are especially easy to demonstrate in cases of muscular atrophy in human beings, and they have already been studied and described in a large number of such cases.\* Spiller† has recently reviewed the bibliography of the subject, and his paper is accompanied by an excellent illustration. As to the sensory nature of the spindles there can be no longer much doubt, for when the motor nerve fibres supplying the voluntary muscles have undergone almost complete degeneration as a result of disease of the lower motor neurones, the majority of the nerves in these structures may remain normal. Sherrington‡ proved by physiological experiment that the spindles are connected with the sensory roots of the nerves. While it is true that motor nerve terminals have been occasionally found in the muscle fibres inside these bodies,\* the majority of nerve endings which have been thus far demonstrated are of the sensory type. In 1889 Trinchese|| gave a good illus-

---

\* Horsley, V. Short Note on Sense Organs in Muscle and on the Preservation of Muscle Spindles in Conditions of Extreme Muscular Atrophy, following Section of the Motor Nerve. *Brain*, Lond., vol. xx (1897), p. 375.

† Spiller, W. G. The Neuro-Muscular Bundles (*Muskel-Knospen*, *Muskelspindeln*, *faisceaux neuro-musculaires*). *J. Nerv. and Ment. Dis.*, N. Y., vol. xxiv (1897), pp. 626-630.

‡ Sherrington, C. S. On the Anatomical Constitution of Nerves of Skeletal Muscles; with Remarks on Recurrent Fibres in the Ventral Spinal Nerve-Root. *J. Physiol.*, Cambridge, vol. xvii (1894), pp. 211-258.

\* Kerschner, L. *Op. cit.*, *Anat. Anz.*, Jena, 1888, S. 295.

|| Trinchese, S. Contribuzione alla conoscenza dei fusi muscolari. *Mem. r. Accad. d. sc., d. Ist. di Bologna*, 4. s., vol. x, 1889 [1890], pp. 715-725. Also *Transl.: Contribution à la connaissance des fuseaux musculaires. Arch. ital. de biol.*, Turin (1890-'91), t. xiv, pp. 221-230.

tration of these structures (Fig. 272). Excellent demonstrations have been given by Ruffini.\* He finds elaborate sensory endings resulting from the manifold subdivision of the axis cylinders of the nerve fibres inside the spindles. He distinguishes three varieties of these endings: *terminaisons à anneaux*, where the nerves surround the muscle fibres in rings; *terminaisons à spirales*, where they go around them in a spiral fashion; and *terminaisons à fleurs*, where they end upon them with complicated dendritic branchings (Figs. 273 and 274).




FIG. 273.—Middle third of a terminal plaque in the muscle spindle of an adult cat. (After A. Ruffini, *Arch. ital. de biol.*, Turin, t. xviii, 1893, p. 108, Fig. 1.) S, spirals; A, rings; F, dendritic branchings. Chloride-of-gold preparation.

Huber, of Ann Arbor, has recently studied these structures with the methylene-blue method, and has succeeded in obtaining exquisite pictures of the nerve endings even to their ulti-

\* Ruffini, A. Sulla terminazione nervosa nei fusi muscolari e sul loro significato fisiologico. Nota preventiva. *Atti d. r. Accad. d. Lincei. Cl. di sc. fis. mat. e nat.*, Roma, 2. s., vol. i, 1892.—Sur la termination nerveux dans les faisceaux musculaires et sur leur signification physiologique. *Arch. ital. de biol.*, Turin, t. xviii (1892), pp. 106-114.—Considerazioni critiche sui recenti studi dell'apparato nervoso nei fusi muscolari. *Anat. Anz.*, Jena, Bd. ix (1893-'94), S. 80-88.—Sulla fina anatomia dei fusi neuro-muscolari del gatto e sul loro significato fisiologico. *Monitore zool. ital.*, Firenze, vol. vii (1896), pp. 49-52.



mate termination (Fig. 275). Thanks to his courtesy, I have had the opportunity of examining his specimens, and have

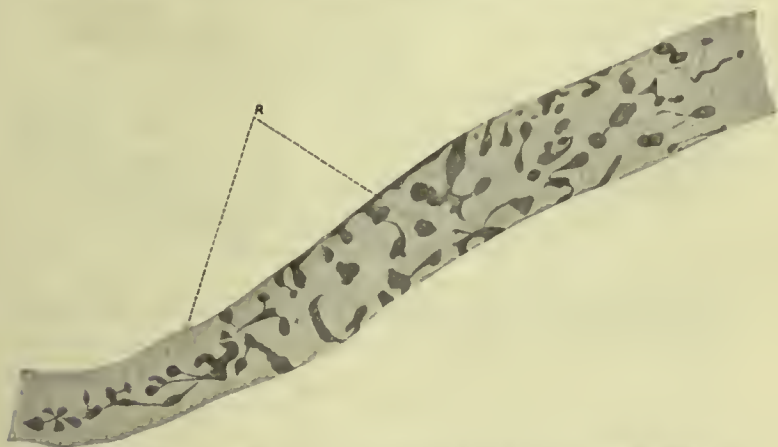


FIG. 274.—A striped muscle fibre in a human muscle spindle with *terminaisons à fleurs*. (After A. Ruffini, Arch. ital. de biol., Turin, t. xviii, 1893, p. 111, Fig. 2.) R, terminal enlargements of the axis cylinder. Chloride-of-gold preparation.

been much surprised at the complexity of the endings. His results, together with plates and a very complete bibliography, have been embodied in a recent paper by himself and Mrs. De Witt.\* The method of Sihler † is also of great service in demonstrating the muscle spindles. To succeed with the method some care has to be taken in teasing out the preparation. I have had the good fortune to see some of Sihler's preparations, and can speak in high terms of his method. The contrast between the large calibre of the sensory fibres going to these struc-

\* Huber, G. C., and Lydia M. A. De Witt. A Contribution on the Motor Nerve Endings and on the Nerve Endings in the Muscle Spindles. J. Comp. Neurol., Granville, vol. vii (1898), pp. 169-230.

† Sihler, C. Ueber eine leichte und sichere Methode die Nervenendigung an Muskelfasern und Gefässen nachzuweisen. Arch. f. Anat. u. Physiol., Physiol. Abth., Leipz. (1895), S. 202.—Ueber Muskelspindeln und intramuskuläre Nervenendigungen bei Schlangen und Fröschen. Arch. f. mikr. Anat., Bonn, Bd. xlv (1895), S. 709-723.—A description of a simple and reliable method to trace the nerves in the muscle. Cleveland M. Gaz., vol. x (1894-'95), pp. 255-264. Also, Am. Month. Micr. J., Wash., vol. xvi (1895), pp. 172-182.—The sensory end-organs of voluntary muscle. Cleveland M. Gaz., vol. xi (1895-'96), pp. 595-600.

tures and the much smaller calibre of the ordinary motor nerve fibres of muscle was very striking.

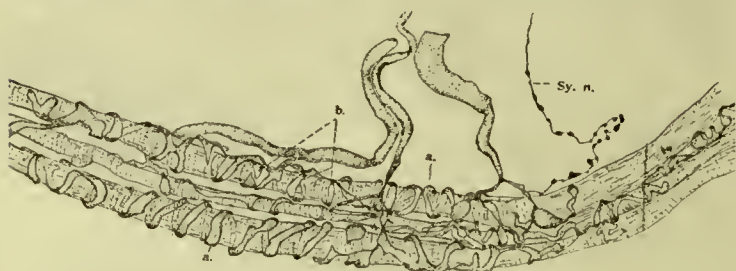


FIG. 275.—Muscle spindle from intrinsic plantar muscles of a dog. (After G. C. Huber and Lydia De Witt, *J. Comp. Neurol.*, Granville, vol. vii, 1898, pl. xvii, Fig. 38.) *Sy. n.*, sympathetic vasomotor fibre.

The whole make-up of the muscle spindle or neuro-muscular bundle impresses one as a structure especially adapted as a sense organ to give information concerning various states of tension in the muscle. Contraction of the muscles in which they are situated must necessarily lead to alterations in the pressure of the lymph inside them, and I am inclined to agree with those observers who assign to them an important function in connection with muscular sense. The subject is, however, still obscure, and the last word concerning them has by no means yet been said. Renewed attention is being paid to them just now by the neuro-pathologists. I need only refer to the careful studies of Batten\* and Grünbaum.†

The nerve endings in the heart muscle have been studied by Berkley,‡ Dogiel and Tumarzew,§ Heymans and Demoor,||

\* Batten, F. E. The Muscle Spindle under Pathological Conditions. *Brain*, Lond., vol. xx (1897), pp. 138-179.

† Grünbaum, A. S. Note on Muscle Spindles in Pseudo-Hypertrophic Paralysis. *Brain*, Lond., vol. xx (1897), pp. 365-367.

‡ Berkley, H. J. On Complex Nerve Terminations and Ganglion Cells in the Muscular Tissue of the Heart Ventricle. *Anat. Anz.*, Jena, Bd. ix (1893-'94), S. 33-42.

§ Dogiel, J., u. Tumarzew. Contribution to the Comparative Anatomy and Physiology of the Heart. (Russian) *Medycyna*, Kasan (1893), Nos. 46 and 47. Abstract in Merkel-Bonnet's *Ergebnisse der Anat.*, Bd. iv (1894), S. 299; also Dogiel, A. S. Die sensiblen Nervenendigungen im Herzen und in den Blutgefässen der Säugethiere. *Arch. f. mikr. Anat.*, Bonn, Bd. lii (1898), S. 44-70.

|| Heymans, J. F., et L. Demoor. Étude de l'innervation du cœur des

Jacques,\* and Huber and De Witt. Whether or not the complex feltwork of fibres which these investigators find throughout the organ have to do with the mediation of centripetal impulses or whether they are concerned wholly with the carrying of motor impulses to the heart muscle fibres has not yet been determined. The fibres in Fig. 276 are believed by Huber and De Witt to be motor.† Similar doubt exists concerning the nature of nerve endings in smooth muscle; enormous numbers of fine fibrils have been found in smooth muscle membranes, and their exact relation to the fibres has in some cases been carefully studied; but how many of these are motor and how many of them are sensory, remains for further investigation to determine. Certain it is that the walls of tubes which have smooth muscle coats are well supplied with sensory nerves. To make

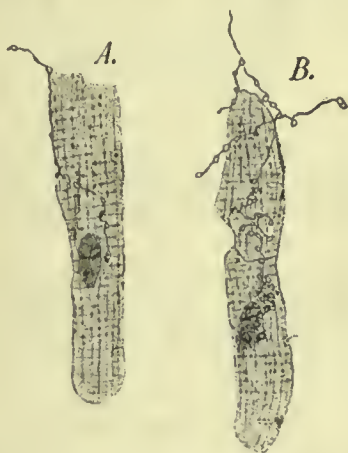


FIG. 276.—Surface view of cardiac muscle cells with nerve endings. (After G. C. Huber and Lydia De Witt, *J. Comp. Neurol.*, Granville, vol. vii, 1898, pl. xiv.)

this clear I have only to mention the intestine, the bile duct, the ureter, the bladder, the uterus, and the blood-vessels. Intestinal colic, biliary and renal colic, are accompanied by a vari-

---

vertébrés à l'aide de la méthode de Golgi. *Mém. couron. Acad. roy. de méd. de Belg.*, Brux., t. xiii (1894).

\* Jacques, P. *Recherches sur les nerfs du cœur chez la grenouille et les mammifères.* *J. de l'anat. et physiol.*, etc., Par., t. xxx (1894), pp. 622-648.

† The sensory nerve endings in the heart described by Smirnow are situated in the connective tissue, not in the muscle.

ety of pain, characteristic enough to be designated as "smooth muscle pain." The labor pains connected with contractions of the uterus are of a similar nature; the severe pain believed by

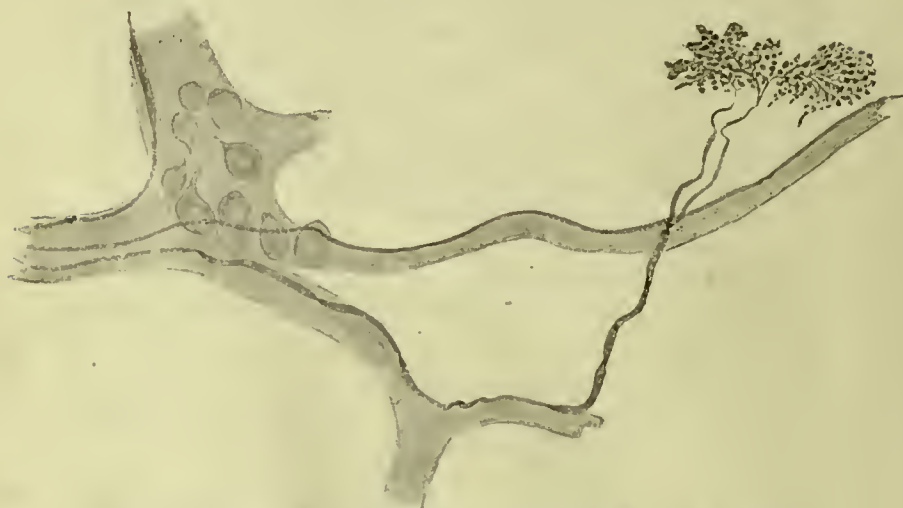

FIG. 277.—Intermuscular end arborization from the left wall of the trachea of the dog. The broad medullated nerve fibre belonging to it is visible for some distance. Methylene-blue preparation. (After A. Arnstein, from Rauber's text-book.)

many to be associated with spasmodic contraction of the blood-vessels (angina, migraine) may also be thought of here. But whether the pain in these cases is the result of stimulation of

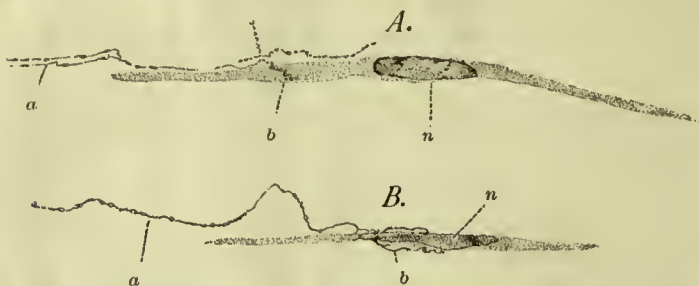


FIG. 278.—Longitudinal section of involuntary muscle showing nerve endings. (After G. C. Huber and Lydia De Witt, *J. Comp. Neurol.*, Grunville, vol. vii, 1898, pl. xiv, Figs. 22 and 23.) *a*, axis cylinder terminating; *b*, the termination itself; *n*, nucleus of the smooth muscle cell.

sensory nerve fibres beginning in the muscle itself or in the connective-tissue structures is not known. In the trachea inter-



muscular nerve-endings have been demonstrated by Arnstein (Fig. 277). The nerve endings described in connection with the smooth muscle of the iris and ciliary body are doubtless concerned in the mechanism of pupillary contraction and of accommodation reaction. In Fig. 278 the motor endings on the smooth muscle-cells of the intestine are illustrated. The findings of Retzius on the vasa afferentia in the glomeruli of the kidney are shown in Fig. 279. The nerve endings on the lymph vessels have recently been described by Dogiel.\*

Recently nerve endings have been found in certain pathological new growths. Thus Reisner† has found nerves in condylomata, and Vollmer‡ has also studied nerve endings in these growths. Young,\* in his study of nerves in tumors, has successfully demonstrated nerve fibres, both medullated and non-medullated, in a considerable number of these growths. He concludes that, in sarcomata at least, nerves are just as much an integral part of the tumor as are the sarcomatous blood-vessels. The nerves were not followed, however, to their ultimate terminations, and it must for the present remain doubtful whether they represent purely vaso-motor filaments or whether among them definite sensory fibres also exist.

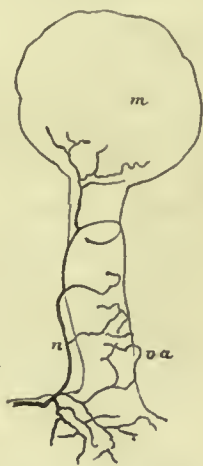

FIG. 279.—Nerve ending on the vas afferens in the cortex of the kidney. (After G. Retzius, Biol. Untersuch., Stockholm.) *m*, corpuscula renalis (Malpighi); *va*, vas afferens; *n*, nerve.

\* Dogiel, A. S. Die Nerven der Lymphgefässe. Arch. f. mikr. Anat., Bonn, Bd. xlix (1897), S. 791-797.

† Reisner, A. Ueber das Vorkommen von Nerven in spitzen Condylomen. Arch. f. Dermat. u. Syph., Wien u. Leipz., Bd. xxvii (1894), S. 385-396.

‡ Vollmer, E. Nerven und Nervenendigungen in spitzen Condylomen. Arch. f. Dermat. u. Syph., Wien u. Leipz., Bd. xxx (1895), S. 363-380.

\* *Op. cit.* Cf. Chap. IV, p. 37.

## CHAPTER XXXII.

### CENTRAL AXONES OF PERIPHERAL CENTRIPETAL NEURONES.

Fibres of dorsal roots—Origin, course, branching, and termination—Lateral and medial bundle of dorsal root—Entry zone—Methods of studying intramedullary continuations of dorsal root fibres—Myelinization of fibres—Studies of Flechsig, von Beehterew, Karasin, and Trepinski—Ventral, middle, and dorsal root zones—Flechsig's oval centre—Relations of myelinization sub-systems to function—Trepinski's four foetal sub-systems—Studies of tubes.

*Central Axones of Peripheral Centripetal Neurones.*—Having considered the medullated peripheral sensory nerve fibres (distal processes of the spinal ganglionic cells) it is next in order to consider the proximal processes of those cells, those which enter the central nervous system. The central prolongations of the spinal ganglion cells (which together make up in mammals almost the entire mass of fibres in the dorsal roots of the spinal nerves) approach the spinal cord and plunge into it at the dorsal lateral sulcus where the neurilemma of the individual fibres is lost. The fibres on entering the cord divide by Y-shaped division into an ascending and descending branch. Of these the former runs a shorter or longer distance before terminating in the gray matter of the cord or in the case of some fibres in the medulla oblongata or cerebellum; the descending limb terminates in the gray matter of the cord after running downward for a very short distance. On their way these axones before and after division give off numerous collaterals which also run into the gray matter to end free among the cells and dendrites of cells situated there. In this way the mechanism is supplied by means of which the impulses arriving by way of the peripheral sensory neurones can be transferred to motor neurones in the cord or to centripetal neurones of a higher order which in turn conduct impulses to higher regions of the nervous system. The regions of termination of the fibres are, it will be seen, of

very considerable extent, and include not only those of the terminations of the main fibres\* but also those of the terminations of the collaterals. Although an enormous amount of work has been done concerning the more exact distribution of the dorsal root fibres on their entrance into the cord and the course followed by their intramedullary prolongations, we are even now in the dark concerning many points. This fact will be evident from the following summary review of some of the principal contributions in this field.

It was early observed that each dorsal root of a spinal nerve on entering the cord consists of two more or less differentiated bundles, a lateral bundle consisting in the main of fine fibres, and a medial, much larger bundle, consisting of coarser fibres. Lissauer† showed that the fine root fibres become separated almost immediately after entrance into the cord from the coarser fibres and pass over directly into the perpendicular column which he termed the "marginal zone" (*Randzone*), now usually spoken of as Lissauer's fasciculus. The fibres of this fasciculus are easily recognizable by their small size. The rest of the fibres pass medialward, a large number of them running in for a long distance close to the dorso-medial surface of the dorsal horn of the gray matter. This zone is easily recognizable in well-stained Weigert preparations of the adult cord cut at suitable levels, and has been called by Strümpell and Westphal the "root zone" or "root entrance zone." It will be spoken of here simply as the *entry zone* of the dorsal roots. The further course of the fibres was for a long time disputed. Before the period of the newer investigations many authorities believed that the dorsal root fibres turned directly into the gray matter of the cord and were directly continuous either with cells there or with a network or felt-work. It is now known that relatively few dorsal root fibres enter the gray matter to terminate exactly at the level of their entrance. On the contrary, the majority of them run up and down in the white matter after bifurcation for some distance before entering the gray substance. When they do enter the gray matter they are not found to be the processes of cells situated there, but end by exhausting themselves by multiple sub-

---

\* *Stammfasern* of the Germans.

† Lissauer, H. Beitrag zum Faserverlauf im Hinterhorn des menschlichen Rückenmarks und zum Verhalten desselben bei Tabes dorsalis. Arch. f. Psychiat. u. Nervenkr., Berl., Bd. xvii (1886), S. 377-438.

division, coming into relation with other neurones only by contact or concrescence.

A knowledge of the intramedullary course of these medullated axones of the dorsal root fibres has been gained, aside from the simple topographical studies of serial sections, in the main through (1) the application of embryological methods; (2) the study of secondary degenerations, (*a*) experimentally produced, and (*b*) the result of disease in human beings; and (3) the chrome-silver method of Golgi.

His's researches showed that the dorsal fasciculi of the spinal cord are embryologically the result of ingrowth of the central processes of spinal ganglion cells. A comparison of the number of fibres in the dorsal fasciculi with the total number of those of the dorsal roots prevented many from believing, however, that the dorsal fasciculi were made up in the main of dorsal root fibres. At this time the Y-shaped division of the dorsal root fibres inside the spinal cord had not been discovered.

The myelinization of the various portions of the dorsal fasciculi has been carefully studied by Flechsig,\* von Bechterew,† and Karusin.‡

Flechsig's studies early convinced him that the fibres of the dorsal roots and of the dorsal funiculi do not become medullated all at once. On the contrary, definite groups receive their myelin at very different periods. A study of human fœtuses at different periods of development has established the sequence of medullation in the different bundles, and Flechsig's description of the dorsal funiculi is based upon the results of this developmental analysis, and largely upon preparations made by Trepinski in his laboratory. Each dorsal funiculus, exclusive of Goll's bundle (*fasciculus gracilis*), can, according to Flechsig, be divided into the following areas:

- (1) The ventral root zone (*vordere Wurzelzone*).

\* Flechsig, P. Die Leitungsbahnen im Gehirn und Rückenmark, Leipzig (1876), and especially in his article Ist die Tabes dorsalis eine "System-Erkrankung." Neurol. Centralbl., Leipz., Bd. ix (1890), S. 33; 72.

† Von Bechterew, W. Die Leitungsbahnen im Gehirn und Rückenmark, Leipzig (1894).

‡ Karusin, P. Das Fasersystem des Rückenmarks, entwickelungsgeschichtlich untersucht. Moskau (1894). Abstract by Stieda in Merkel-Bonnet's Ergebnisse der Anatomie u. Entwickl., Bd. v (1895), S. 445.



- (2) The middle root zone (*mittlere Wurzelzone*).
- (3) The dorsal root zone (*hintere Wurzelzone*).
- (4) The median zone (*mediane Zone der Hinterstränge*).

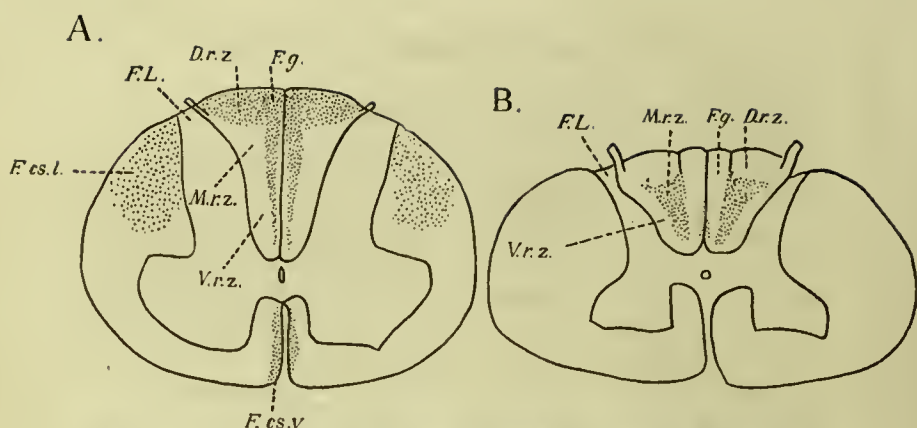
The median zones of the two sides make up in the lumbar region what is often spoken of as the *ovales Centrum* of Flechsig. The middle root zone develops in two parts (first and second systems of the middle root zone), as does also the dorsal root zone (medial and lateral portions of the dorsal root zone). The position of these various zones is clearly shown in the accompanying diagrams (Fig. 280). The sequence of medullation is as follows:

- (1) The ventral root zone (Fig. 280, *V.r.z.*).
- (2) The first system of the middle root zone (*M.r.z.*) and the median zone.
- (3) Goll's fasciculi, second system of middle root zone and the medial portion of the dorsal root zone (*D.r.z.*).
- (4) Last of all toward the end of foetal life the lateral portion of the dorsal root zone (Lissauer's marginal zone) (Fig. 280, *F.L.*).

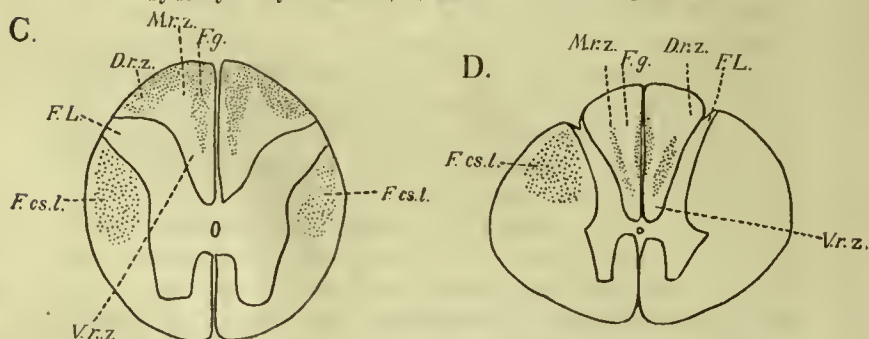
Of these the only bundle to increase steadily in cross section as one passes up the cord is Goll's fasciculus. All other regions show in the thoracic cord, especially in its middle parts, a considerably less area in cross section than they do in the enlargements.

As to the origin and termination of the nerve fibres contained in the different foetal zones, Flechsig, when he wrote in 1890, believed that the ventral root zone (*V.r.z.*) received very many, probably all, of its fibres direct from the dorsal roots of the spinal nerves; they went, he thought, into the dorsal horn after a longer or shorter course. In front of the dorsal horn they vanished, although he could not make out their exact termination. He felt sure that they have nothing to do with the nucleus dorsalis.

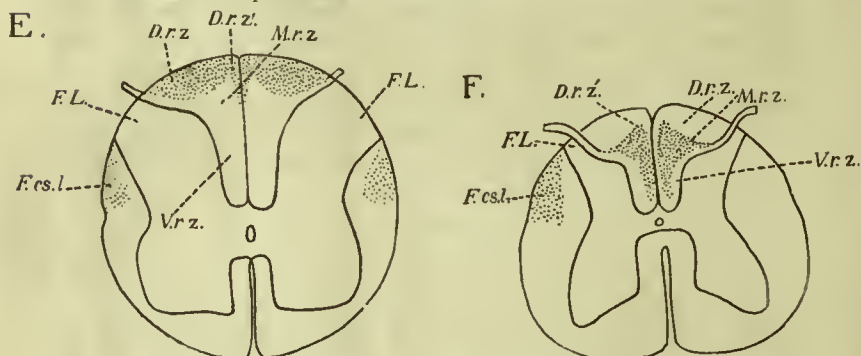
The fibres of the first system of the middle root zone he believed come entirely from the dorsal roots and end after a short course by turning into the nucleus dorsalis (Clarkii). As to the origin and termination of the fibres in the median zone he could make no statement. Concerning the fibres of Goll's fasciculus, Flechsig could give no direct proof from the study of the foetus that they have their origin in the dorsal roots. He could first certainly demonstrate them as compact bundles of fibres in the region of the tenth thoracic nerve. Further down



Middle of intumescentia cervicalis: A, memberment of dorsal funiculi as revealed by study of myelinization; B, lesion in a case of incipient tabes.



Pars thoracalis: C, section through mid-thoracic region illustrating myelinization memberment; D, section through upper thoracic region showing lesion in a case of incipient tabes.



Intumescentia lumbalis: E, memberment as revealed by study of myelinization; F, lesion in a case of incipient tabes.

FIG. 280.—Figures illustrating the dorsal funiculi in the cervical, thoracic, and lumbar regions of the spinal cord. Those on the left side illustrate the embryological memberment, those on the right side the lesions in cases of incipient tabes. (After P. Flechsig, Neurol. Centralbl., Leipz., Bd. ix, 1890, S. 73, Figs. 1, 2, 3, 4, 5, and 6.) Lettering explained in text.

the fibres appeared to be distributed over the whole cross section of the middle root zone.\*

The fibres of the medial portion of the dorsal root zone (*D.r.z.*) all come, according to Flechsig, from the dorsal roots. They leave the dorsal funiculi by three paths: (*a*) The fibres most medially laid run in part in the raphe forward to the dorsal commissure and then bend out toward the dorsal horn. These fibres have nothing to do with Goll's fasciculus. (*b*) The lateral fibres leave the dorsal fasciculi from the side, crossing the entering dorsal roots at an acute angle, and arrive at the dorsal horns, whence they run forward. (*c*) The main mass of fibres runs through the middle root zone to enter the dorsal horns midway between the dorsal commissure and the periphery of the cord. These bundles run forward as far as the periphery of the ventral horns, becoming lost between the fibres of the ventral roots and the large ganglion cells of the ventral horns.

The fibres of the lateral portion of the dorsal root zone (Lissauer's marginal zone) run, just as Lissauer described them, to the fine plexus of fibrils in front of the dorsal commissure and to the lateral limiting layer of the gray substance. All fibres of this zone, Flechsig believes, have their origin in the dorsal roots.†

This memberment of the dorsal funiculi does not correspond to that based upon secondary degeneration after lesion of dorsal roots (*vide infra*), and apparently the former, unlike the latter, does not correspond to the different length of the fibres. It is Flechsig's opinion that his areas correspond to specific sense qualities (muscle-sense, sense of touch, of pain and the like), the different systems having different peripheral connections. While the areas outlined by degeneration secondary to lesion of dorsal roots differ much from those which result from

---

\* Earlier, Flechsig believed that the fibres of Goll's fasciculus have their origin also in the dorsal zone, and perhaps even more widely. They are more numerous in the medial portion of the middle root zone than in the lateral portion. Flechsig believes, however, that the fibres of Goll's fasciculus really represent intramedullary continuations of dorsal root fibres, and urges against von Bechterew's objection that the dorsal roots are all medullated before Goll's fasciculus, that his own observations show that when the fibres of Goll's fasciculus receive their myelin sheaths there are still many fibres in the dorsal roots which are non-medullated.

† It will be noticed that this description belongs to the period preceding that in which collaterals were distinguished from terminals.

embryological analysis, Flechsig asserts that in locomotor ataxia the lesions in the dorsal funiculi conform to the latter

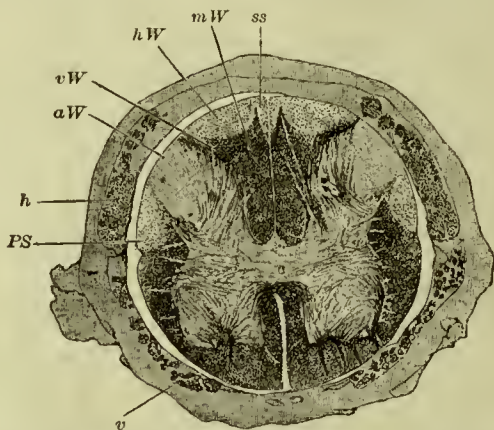


FIG. 281.—Upper half of lumbar enlargement of a fetus 35 cm. long; corresponds to Fig. 280, E. PS, lateral pyramidal tract; v, ventral roots medullated; h, dorsal roots partly medullated; vW, ventral root zone of dorsal funiculi; aW, dorsal root zone (lateral portion) of dorsal funiculi (Lissauer's fasciculus); hW, dorsal root zone (medial portion); ss, dorsal root zone (most median part of medial portion) of dorsal funiculi; mW, middle root zone. (After P. Flechsig, *Neurol. Centralbl.*, Leipz., Bd. ix, 1890, S. 78, Fig. 8.)

and not to the former. The degenerations in this disease so well worked out by Charcot and Pierret, Westphal, Strümpell, and others, Flechsig asserts on closer analysis show a very distinct parallelism with the areas outlined from the study of the foetus. In beginning tabes he finds that the disease is nearly always localized to the areas designated by him as the "middle root zone" and the "median zone" (these receive their myelin simultaneously, *vide supra*), all other regions remaining at first intact. A comparison of the two sides of Fig. 280, and of Fig. 281 (foetal markings) with Fig. 282 (degeneration in tabes) illustrates strikingly the parallelism. After tabes has passed the incipient stage the zones which develop later may be attacked in variable order, although, as a rule, the first to suffer is the lateral portion of the dorsal root zone, together with Goll's fasciculi, and later the medial portion of the dorsal root zone. The ventral root zone appears to be, without exception, the last to be attacked.

Von Bechterew agrees in the main with the views of Flechsig. He also divides the fasciculus cuneatus of Burdach into a ventral, a lateral, and a dorsal zone, but does not object to the insertion by



Flechsig of a middle zone between. In von Bechterew's book (1894) there is some stress laid upon differences in the time of medullation of certain portions of the fasciculus gracilis of Goll. The first portion of this fasciculus to become medullated, according to him, is that immediately adjacent to the median septum, an area which corresponds to Flechsig's *mediane Zone*. In addition to this, he distinguishes two other systems of fibres in the fasciculus gracilis: (1) An area, *gm*, taking in the major part of the fasciculus, and situated just external to the median zone; and (2) a narrow stripe, *gl*, lying between the area, *gm*, and the fasciculus cuneatus. The latter, von Bechterew states, is the portion of the dorsal fasciculi of the spinal

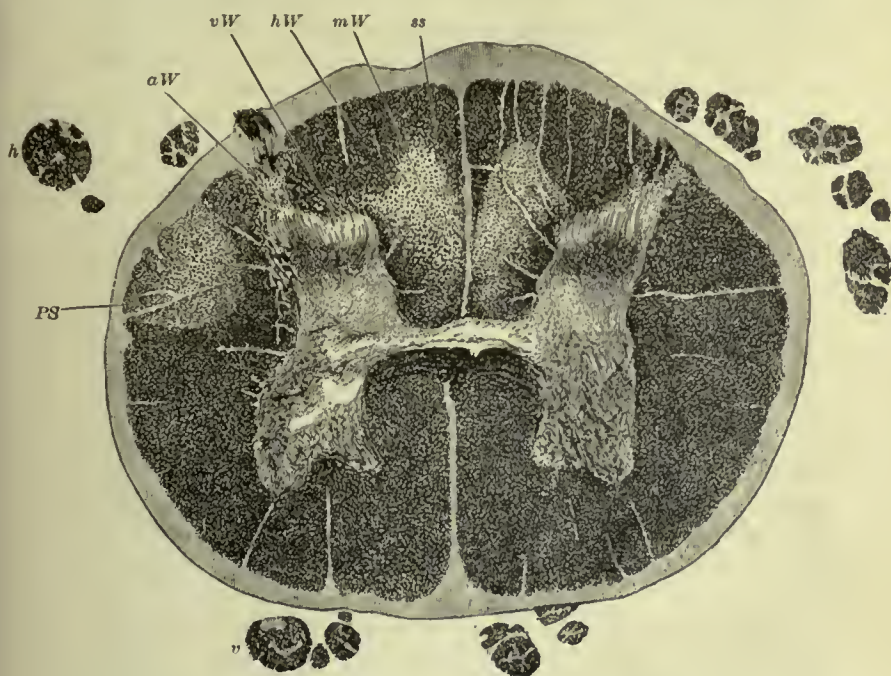


FIG. 282.—Cross section through the spinal cord at the level of the third lumbar nerve. *aW*, lateral dorsal root zone; *hW*, medial dorsal root zone; *ss*, median compartment of the latter; *mW*, middle root zone (degenerated), beginning tabes; *vW*, ventral root zone; *PS*, lateral pyramidal tract degenerated. (After P. Flechsig, Neurol. Centralbl., Leipz., Bd. ix, 1890, S. 77, Fig. 7.)

cord, the last to become medullated. He asserts with emphasis that the whole of Goll's fasciculus (with the exception of the "median zone," which he thinks has its origin in dorsal root fibres) is made up of medullated axones, which are processes of cells situated in

the dorsal horns of the gray matter of the spinal cord.\* This view is in direct contradiction to the results of the studies of secondary degenerations, and of those in which Golgi's method has been employed (*vide infra*). Von Bechterew further thinks that while a part of the fibres of Goll's bundle run all the way to the medulla oblongata without interruption, another portion is interrupted and continued upward only by the intercalation of other cellular elements situated in the dorsal horns.

Karusin, who has recently gone over this whole subject with the same method, having a large amount of material at his disposal, states emphatically that sharp limitations of single regions can not be made out. He holds that while it is true that the first well-developed fibres appear in the entry zone (*Einstrahlungszone* of von Lenhossék, or *ventrale Wurzelzone* of Flechsig), at later periods the process of myelinization occurs diffusely in all directions. He concludes that only three well-separated regions in the dorsal fasciculi are to be made out: (1) The fasciculus cuneatus, (2) the fasciculus gracilis, and (3) Lissauer's marginal zone. He insists that a connective-tissue sheath separates the fasciculus gracilis from the fasciculus cuneatus, a finding which he looks upon as a strong argument in favor of the anatomical individuality of the two fasciculi.†

As has been stated, Flechsig's publication in 1890 was based upon the study of sections made in his laboratory by Trepinski. Trepinski himself, now at Zoppot, has continued the studies, begun in Flechsig's laboratory, during the past eight years, and in 1898 has written a paper,‡ in which he comes to conclusions which differ materially from those of Flechsig. Leaving out of consideration the fibres of Lissauer's marginal zone, he states that, corresponding to the period of myelinization, there are four distinct fibre systems to be differentiated from one another in the dorsal funiculi of the human cord. These fibre systems, the areas of distribution of

---

\* As is pointed out further on, all the recent evidence is in exact opposition to this view of von Bechterew. The fibres of the fasciculus gracilis (Goll's) appear to be almost wholly intramedullary continuations of dorsal root fibres, while those in the median zone almost all represent medullated axones of neurones, the cell bodies of which are situated within the gray matter of the spinal cord itself.

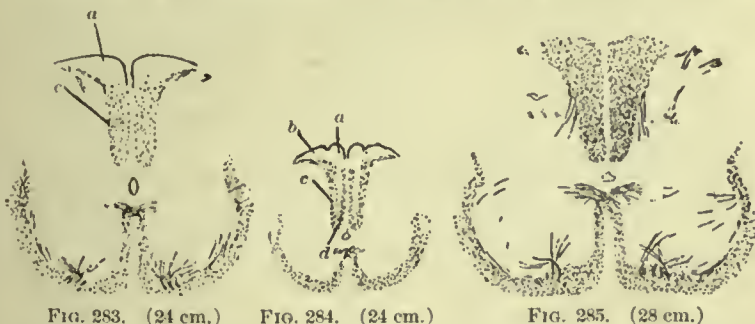† There is no getting around the fact, however, that the long fibres of the dorsal roots of the lower spinal nerves which enter the fasciculus cuneatus are continued upward in the fasciculus gracilis. Secondary degenerations prove this beyond the shadow of a doubt.

‡ Trepinski. Die embryonalen Fasersysteme in den Hintersträngen und ihre Degeneration bei der Tabes dorsalis. Arch. f. Psychiat. und Nervenkr., Berl., Bd. xxx (1897), S. 54-81.

which frequently overlap, attain to a ripe condition—that is, complete the process of medullation in foetuses 24 cm., 28 cm., 35 cm., and 42 cm. long, respectively. In foetuses of the last length the whole dorsal funiculus is fully medullated, although the fibres of Lissauer's marginal zone are then only beginning to receive their myelin sheaths. A number of the figures accompanying Trepinski's article are here reproduced (Figs. 283–291).

While it is true that the areas of distribution of the four fibre-systems overlap one another to a certain extent, these can be determined by an analysis of the varying appearances presented in the dorsal funiculi at different stages of development.

In the dorsal funiculus of foetuses 24 cm. long there are many medullated fibres present, but not everywhere in the cross section. The dorsal part of the dorsal funiculus (Fig. 283, *a*) in the lumbar



region is devoid of myelin; the more ventral parts (Fig. 283, *c*) are regularly studded with nerve fibres, but even here the individual fibres are separated from one another by considerable distances. In the thoracic and cervical cord there are no medullated fibres in the dorsal region of the dorsal funiculus (Fig. 284, *b*), nor are there any in the middle region of each dorsal funiculus (Fig. 284, *a*); the only medullated fibres present are situated in a narrow stripe near the median septum (Fig. 284, *d*), and in a somewhat broader stripe along the dorsal horn (Fig. 284, *c*). In the most ventral region of the funiculus these medullated areas go over into one another. The non-medullated regions are continuous with one another at the dorsal periphery.

In foetuses 28 cm. long the appearance of the dorsal funiculi in all regions is very different from the foregoing. In the lumbar cord, which has by this time grown to be considerably larger, not only is the dorsal portion, which before was non-medullated, now regularly studded with medullated fibres (Fig. 285), but the ventral portions have many more medullated fibres in them than before, the individual medullated fibres now standing much closer together



than in the foetus 24 cm. long, the new fibres evidently occupying the interspaces between the older ones. It is obvious, therefore, that this second system of fibres occupies the whole cross section of the lumbar portion of the dorsal funiculi, although Trepinski states that the dorsal region of the dorsal funiculus contains more of the fibres of the new system than does the ventral region, for in a foetus 28 cm. long, the dorsal region previously entirely non-medullated is almost as thickly studded with medullated fibres as is the ventral region.

In the thoracic cord and in the cervical cord there has also been a marked increase of medullated fibres when the foetus has attained a length of 28 cm. The regions of the dorsal funiculi, which in the foetus 24 cm. long were non-medullated, are now occupied by medullated fibres, and, further, even those regions which showed medullated fibres before now contain a greater number of them, for the individual fibres stand closer together. The distribution of the new fibres in the cross section is, however, not even, and the cross section shows light areas and dark areas in Weigert preparations, which are quite different in distribution from those characteristic of the previous period of development.

In the thoracic cord the lightest part of the cross section at this stage is the middle region of the dorsal funiculus (Fig. 286, *b*); it has the form of a stripe which goes from the dorsal periphery almost to the ventral extremity of the funiculus. The dorsal funiculus in the thoracic region thus becomes divided into a middle light part

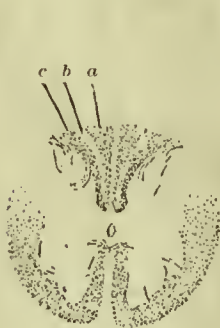

FIG. 286. (28 cm.)

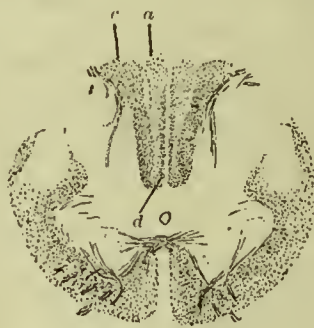

FIG. 287. (28 cm.)

(Fig. 286, *b*), a lateral dark part (Fig. 286, *c*), and a medial dark part (Fig. 286, *a*).

In the cervical cord in the foetus 28 cm. long the fasciculus gracilis (Fig. 287, *a*), owing to the small number of medullated fibres present in it, appears light, with the exception of a narrow stripe near the median septum (Fig. 287, *d*), a region which, it will be



recalled, contained some medullated fibres in the foetus 24 cm. long. The dark stripe of Goll's fasciculus passes over at the most ventral region of the dorsal funiculus into the medullated area which corresponds to the fasciculus cuneatus. The second system of fibres, therefore, in the cervical region is distributed over the whole cross section, but the fibres of the system are much more numerous in the narrow stripe occupying the medial portion of the fasciculus gracilis, and in the wide stripe corresponding to the fasciculus cuneatus. There are relatively few fibres of the system situated in the lateral portion of the fasciculus gracilis.

It is thus seen that the second system of fibres (foetus 28 cm. long) differs from the first system of fibres (foetus 24 cm. long) not only in the time of medullation,

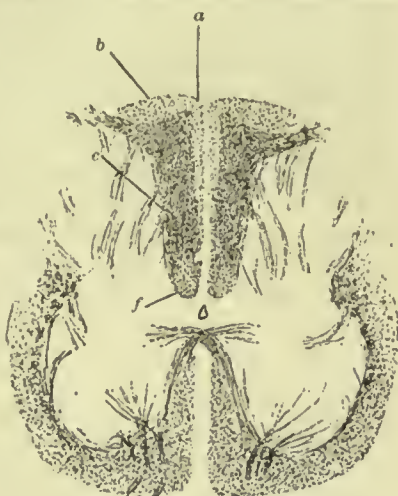


FIG. 288. (35 cm.)

but also in the arrangement of fibres as seen in the cross section. The mistake must not be made of thinking that all the fibres seen to be medullated in the foetus 28 cm. long belong to the second system; Trepinski's meaning, I take it, is that to the second system belong only those fibres which have received their myelin sheaths during the period of growth extending from the time when the foetus was 24 cm. long to the time when the foetus is 28 cm. long.

The third system of fibres in the dorsal funiculi, entirely non-medullated in the foetuses 28 cm. long, attains its full development in foetuses 35 cm. long. In the foetus 28 cm. long the cross section of the dorsal funiculus in the lumbar region was evenly studded with medullated fibres. In the foetus 35 cm. long there is seen to be one area which in Weigert preparations takes a very dark stain, while other parts are stained of a light color (Fig. 288). This is owing to the fact that in the dark region there has been a great increase in the number of medullated fibres. The new fibres (those of Trepinski's third system) occupy on the cross section stained by Weigert's method the greater part of the lumbar dorsal funiculus (Fig. 288, c). The area in which they are distributed is limited dorsally by a curved line, behind which the dorsal funiculus looks light (Fig. 288, b). Near the median septum too there is a light stripe (Fig. 288, a), which is continuous with the dorsal light region;

besides, the most ventral part of the lumbar dorsal funiculus (Fig. 288, *f*) looks light in comparison with the dark area, but here the demarcation is not sharp.

In the thoracic cord of a foetus 35 cm. long there is a memberment into light and dark areas, but this memberment, as Trepinski's drawings show, is quite different from that described in the foetus 28 cm. long (cf. Fig. 289 with Fig. 286). In the foetus 35 cm. long only the more ventral part of the lateral portion of the dorsal funiculus (Fig. 289, *c*) is dark; the dorsal portion of the lateral region (Fig. 289, *b*) appears now to be light, although in the foetus 28 cm. long it was just as dark as the ventral portion of this lateral region. Further, at this period (foetus 35 cm. long) the lateral dark region is considerably broader than it was at the earlier period



FIG. 289. (35 cm.)

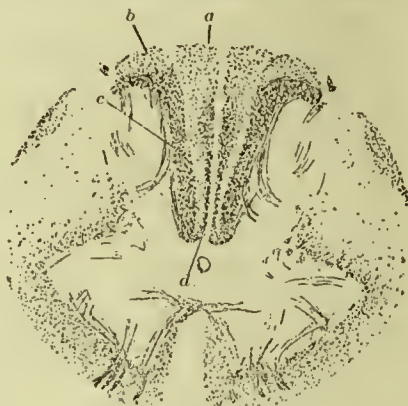

FIG. 290. (35 cm.)

(foetus 28 cm. long), so that the outer dark region now includes the middle light stripe of the earlier developmental stage. The medial dark part (Fig. 289, *d*) in foetuses 35 cm. long consists of a narrow stripe situated near the median septum, a stripe which at the ventral end of the dorsal funiculus goes over without limitation into the lateral dark area. The latter does not, however, reach the dorsal periphery. Owing to the narrow limits of the medial dark area there is a much more extensive light area (Fig. 289, *a*) in the thoracic cord of foetuses 35 cm. long than existed in foetuses 28 cm. long.

In the cervical cord of foetuses 35 cm. long the third system of fibres is distributed in the greater part of the fasciculus cuneatus (Fig. 290, *c*), only the small dorsal portion of the same (Fig. 290, *b*) showing no increase in fibres; this dorsal portion is now of a light color, although in foetuses 28 cm. long it was just as dark as the more ventral portions of the fasciculus cuneatus. The fibres of the

third system are distributed also in the medial portion of the fasciculus gracilis (Fig. 290, *d*), as is shown by an increase of the medullated fibres situated there at this developmental stage. This region of Goll's fasciculus is now closely studded with medullated fibres, and looks darker than the more lateral portions of this fasciculus (Fig. 290, *a*). On comparing the dark medial part of Goll's fasciculus in the foetus 35 cm. long with that of the foetus 28 cm. long, it will be seen that the region at the later period, though considerably larger, shows fibres standing much more closely together than in the earlier stage. The medial dark portion of the fasciculus gracilis is continuous with the dark portion of the fasciculus cuneatus at the ventral region of the dorsal funiculus.

The fourth system of fibres, according to Trepinski, has completed its development by the time the foetus has attained a length of 42 cm., for at this period, he states, all parts of the cross section of the dorsal funiculi are evenly studded with medullated nerve fibres. The change in the appearance of the cross section is evidently due to an increase of medullated fibres, which have come in to occupy the light regions between the fibres already present in them at earlier developmental stages. It is accordingly easy to define the areas of distribution of the fibres of the fourth system. Thus in the lumbar cord the nerve fibres of this system occupy the dorsal portion (Fig. 288, *b*), a medial region (Fig. 288, *a*), and a ventral field (Fig. 288, *f*) of the dorsal funiculi. In the thoracic cord they spread out in the dorsal region (Fig. 289, *b*) and the middle part (Fig. 289, *a*) of the dorsal funiculi. In the cervical cord they lie in the dorsal part of the fasciculus cuneatus (Fig. 290, *b*) and the lateral part of the fasciculus gracilis (Fig. 290, *a*). Later stages of development show, according to Trepinski, no alteration in the appearances of the dorsal funiculi, so that he assumes that all the fibre systems are present in foetuses 42 cm. long.

At this period Trepinski could make out medullated fibres for the first time in the region of Lissauer's marginal zone, an area which in reality belongs to the lateral funiculus of the cord. Even in foetuses 47 cm. long the myelin development in this region does not appear to be complete, for the medullated fibres stand much farther apart than in the adult individual.

Trepinski asserts, therefore, that, leaving out Lissauer's zone, it is easy to distinguish in the dorsal funiculi four embryonic systems of nerve fibres. The area of distribution in the cross section corresponding to each of these fibre systems can, he thinks, be established with exactness, in spite of the fact that the fibres of different systems mix up with one another, for each of the systems when it appears leads to an alteration in the appearance and membership of the dorsal funiculi. Each of the four systems lies, in the upper regions of the spinal cord, partly in the fasciculus cuneatus, partly in the

fasciculus gracilis, and since medullation is completed in the fasciculus gracilis at the same period as in the fasciculus cuneatus, it is obvious that from the study of development alone Goll's fasciculi are composed of the same embryonic fibre systems as are Burdach's fasciculi.

Trepinski, like Flechsig, believes that the distribution of the embryonic fibre systems affords the clew to the varying pictures met with in tabetic degeneration. In his article he gives a number of examples of cases of tabes illustrating his view. And it must be granted that if his drawings are objective, the parallelism between the tabetic degeneration and the stages of myelinization is remarkably striking. No student of tabes, at any rate, can afford to overlook these studies of Trepinski. It would lead us too far if we attempted to compare the findings in cases of tabes with the findings in the embryonic spinal cord. One example from Trepinski's article

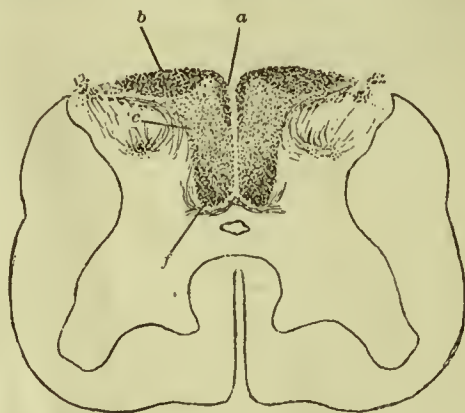

FIG. 291.

may, however, be given. In a case of beginning lumbar tabes Trepinski found, in addition to a degeneration of Lissauer's zone and of certain parts of the gray matter of the cord, a moderate degeneration in the middle region of the dorsal funiculi (Fig. 291, c). The dorsal parts of these funiculi (Fig. 291, b) look healthy, as do the medial regions connected with the dorsal parts and lying close to the median septum (Fig. 291, a) and a ventral field in the dorsal funiculi (Fig. 291, f). This distribution of degenerated fibres in the dorsal funiculi leads to a memberment, reminding one immediately of that met with in the spinal cord of a foetus 35 cm. long (cf. Fig. 288), with this difference, that the portions which were of a light color in the foetal dorsal funiculus appear dark in the diseased cord, and *vice versa*. It will be remembered that in the foetal dorsal funiculus this special appearance was brought about by the ripening of



the third system of fibres. Trepinski believes that the memberment in the diseased cord in this case must, therefore, be due to the degeneration and disappearance of that system of fibres which called forth the memberment in the spinal cord of the fœtus. He concludes, therefore, that in this case of tabes the degeneration has affected the third embryonic fibre system alone. That in the degenerated area many healthy nerve fibres remain is easily explained, for in among the fibres of the third system there exist fibres of the first and second system. If the fibres of the third system alone be diseased, then the fibres of the other system should remain over as healthy fibres in the degenerated region. He cites a series of interesting cases which he has met with, and illustrates them by drawings of the sections, but for these the reader must consult the original article.

## CHAPTER XXXIII.

### CENTRAL AXONES OF PERIPHERAL CENTRIPETAL NEURONES.

(Continued.)

Studies of secondary degenerations—Experimental investigations—Lesions of single dorsal roots in human beings—Studies of cases of transverse lesion of the spinal cord—*Fibres courtes, fibres longues et fibres moyennes* of P. Marie—Ascending degenerations in dorsal funiculi—Descending degenerations—The comma of Schultze—*Fibres endogènes* of P. Marie—*Triangle médian* of Gombault et Philippe—Flechsig's oval centre—Descending septo-marginal tract of Bruce and Muir—Descending limbs of dorsal root fibres—Axones of spinal cord cells entering dorsal funiculi—Excentric position of long fibres—Ascending endogenous fibres in dorsal funiculi—Anæmic necrosis following ligature of abdominal aorta—Fasciculus dorsalis proprius—Terminals of dorsal root fibres as studied by Marchi's method.

THE methods of studying secondary degeneration applied to the dorsal fasciculi have supplied us with a large number of facts of the highest degree of importance. In animals, if one or more dorsal roots be cut between the spinal ganglia and the spinal cord, the intramedullary continuations of these fibres undergo secondary degeneration, and can be studied later by Weigert's method or, better still in some cases, by the method of Marchi. In this way it is possible to determine the exact position in all parts of the spinal cord of the intramedullary continuations of any desired dorsal root. Without reviewing in detail all the individual researches made in this field, the results in general may be thus stated: After section of the dorsal root of a spinal nerve between the ganglion and the cord, both the lateral and medial bundle of fibres (seen just after entrance) undergo complete degeneration and can be easily studied. Immediately above the level of entrance of the nerve root concerned there is degeneration in the entry zone. If the lesion be situated low down in the spinal cord, an examination of transverse sections made at different levels up the cord shows two things: (1) A

progressive diminution in the number of degenerated fibres as the cord is ascended; (2) a gradual change in the position occupied by the degenerated fibres. The first observation proves that the fibres of a dorsal root which ascend in the cord stop at different levels; the second proves that fibres, which low down in the cord are situated near the gray matter in the entry zone, higher up come to occupy a position more dorsal and medial, gradually approaching Goll's fasciculus, and in the case of the sacral roots, for example, forming a part of it. All the evidence from the study of secondary degenerations goes to prove that the fibres of the fasciculus gracilis in the cervical region represent the long intramedullary continuations of dorsal root fibres which in the sacral and lumbar region were among the fibres of the fasciculus cuneatus. Each dorsal root as it enters the spinal cord pushes the fibres of Burdach's fasciculus in a dorsal and medial direction, so that the long ascending fibres are necessarily successively more and more displaced toward the dorsal median sulcus. These relations are beautifully illustrated by the experimental work of Singer,\* Kahler,† Tooth,‡ Singer and Münzer,\* and others.

Singer and Münzer cut the dorsal roots of the twenty-sixth, twenty-seventh, and twenty-eighth spinal nerves on one side, and also the dorsal roots of the twentieth, twenty-first, and twenty-second nerves of the same side. After the animal had lived long enough for degeneration to become marked, it was killed and the degenerations were studied in sections made at different levels (Fig. 292). A section made just above the entrance of the twenty-sixth root showed degenerated fibres in the white matter immediately adjacent to the dorso-medial

---

\* Singer, J. Ueber secundäre Degeneration im Rückenmark des Hundes. Sitzungsber. d. k. Akad. d. Wissensch., Math.-naturw. Cl., 3. Abth., Wien, Bd. lxxxiv (1882), S. 390-419.

† Kahler, O. Ueber die Veränderungen, welche sich im Rückenmarke in Folge einer geringgradigen Compression entwickeln; nebst einem die secundäre Degeneration im Rückenmarke des Hundes betreffenden Anhang. Ztschr. f. Heilk. Prag., Bd. iii (1882), S. 187-232.

‡ Tooth, H. H. The Goulstonian Lectures on Secondary Degeneration of the Spinal Cord. Brit. M. J., Lond. (1889), i, pp. 753; 825; 853. Also Reprint, London (J. A. Churchill), 1889.

\* Singer, J., und E. Münzer. Beiträge zur Anatomie des Centralnervensystems insbesondere des Rückenmarkes. Denkschr. der Wiener Akad., Bd. lvii (1890-'91), S. 569.

surface of the dorsal horn. At a little higher level below the entrance of the twenty-second dorsal root the diseased fibres were more separated from the dorsal horn and occupied a triangular area not so very far from the dorsal median sulcus (Fig. 292, *a*). These fibres were evidently those which represented continuations of the twenty-sixth, twenty-seventh, and twenty-eighth nerve roots which had been shoved dorsalward and medialward on account of the entrance in the interval of fibres from the twenty-fifth, twenty-fourth, and twenty-third spinal

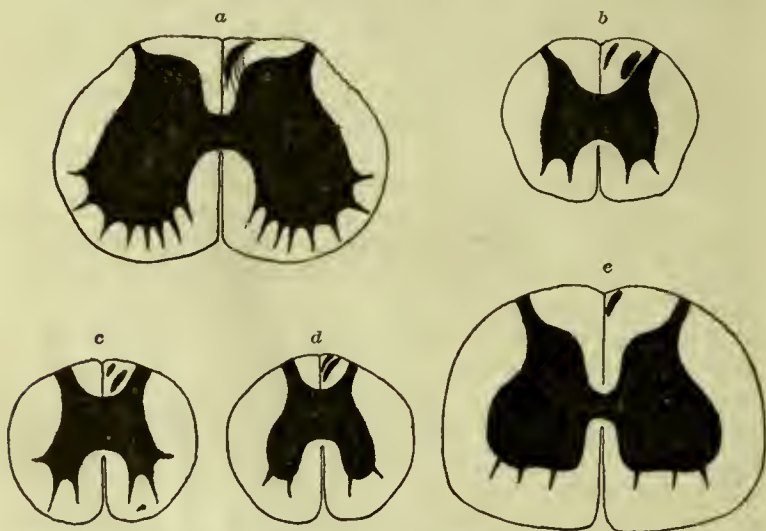


FIG. 292.—Secondary degenerations in the spinal cord after experimental section of dorsal roots. (After Singer and Münzer, from A. van Gehuchten, *Anatomie du système nerveux de l'homme*, Louvain, 1897, pp. 305 and 306, Figs. 208 to 212.) *a*, level of the twenty-second spinal nerve; *b*, cross section of the cord between the level of the twentieth and twenty-second spinal nerves; *c*, transverse section through the cord at the level of the eighteenth spinal nerve; *d*, transverse section of the cord in the thoracic region; *e*, transverse section of the cord at the level of the *intumescentia cervicalis*.

roots (not cut in the experiment). Sections made through the cord at any level between the entrance of the twentieth and twenty-second dorsal root showed the degenerated fibres of the twenty-sixth, twenty-seventh, and twenty-eighth still nearer the medial septum, and in addition new degenerated fibres of the twenty-second and twenty-first roots just dorso-medial to the dorsal horn of gray matter (Fig. 292, *b*). Higher up, at the level of the eighteenth spinal root, the degenerated fibres be-



longing to the dorsal roots which had been cut highest up were somewhat separated from the dorsal horns and had come to occupy the middle portion of the dorsal funiculus, although they were still separated by undegenerated fibres from the bundle of degenerated fibres near the median septum, the long continuations of the twenty-sixth, twenty-seventh, and twenty-eighth roots (Fig. 292, *c*). The lateral bundle decreased progressively in size in the sections taken from parts of the cord higher up. Sections made through the thoracic cord showed an ever-decreasing number of fibres in both bundles, which now began gradually to approach one another (Fig. 292, *d*). In the cervical cord the two bundles actually fused, and Singer and Münzer could see only a small triangular zone of degenerated fibres situated near the median septum (Fig. 292, *e*). Such an experiment would seem to be proof positive of the successive termination of the ascending continuations of dorsal root fibres at different levels of the cord and of the gradual and progressive displacement dorsalward and medialward of the longest fibres. Experiments of this type may be repeated at will, and they have been already made by numerous investigators, among them Oddi and Rossi,\* Berdez,† Mott,‡ Tooth and Horsley, Barbacci,\* and Langley and Anderson.¶

The study of secondary degenerations has led many to the view that in the fasciculus gracilis only the long intramedullary continuations of the sacral, or at most the lumbar dorsal roots are contained (Schiefferdecker, Singer). On the other hand,

---

\* Oddi, R., e U. Rossi. Sulle degenerazioni consecutive al taglio delle radici posteriori; contributo allo studio delle vie sensitive nel midollo spinale. *Monitore zool. ital.*, Siena, vol. i (1890), pp. 55-58; also Translation into French in *Arch. ital. de biol.*, Turin, t. xiii (1890), pp. 382-386.

† Berdez. Recherches expérimentales sur le trajet des fibres centripètes dans la moelle épinière. *Rev. méd. de la Suisse rom.*, Genève, t. xii (1892), pp. 300-316.

‡ Mott, F. W. Experimental Inquiry upon the Afferent Tracts of the Central Nervous System of the Monkey. *Brain*, Lond., vol. xviii (1895), pp. 1-20.

\* Barbacci, O. Die secundären, systematischen, aufsteigenden Degenerationen des Rückenmarks. *Centralbl. f. allg. Path. u. path. Anat.*, Jena, Bd. ii (1891), S. 353-365.

¶ Langley, J. N., and H. K. Anderson. Notes on Degeneration resulting from Section of Nerve Roots and Injury to the Spinal Cord. *Proc. of Physiol. Soc.*, Lond. (1894), p. xii.

Bastian, Schultze,\* Hofrichter,† Barbacci,‡ and Bruns believe that the dorsal roots of the thoracic nerves are also concerned in the formation of the fasciculus gracilis, Barbacci even going so far as to assert that the dorsal roots throughout the whole extent of the spinal cord help to build Goll's fasciculi.

We turn with interest to the examination of the relatively small number of cases in human beings in which there have been lesions (tumor, trauma) of one or more dorsal roots entirely or almost entirely without direct injury to the cord itself. Let us see in how far the results of study in such cases are in accordance with the findings in experimental animals. Such cases have been reported by Lange, Pfeiffer,\* Gombault,|| Sottas,<sup>Δ</sup> Mayer,<sup>◇</sup> Nageotte,<sup>‡</sup> Souques,<sup>‡</sup> Marguliés,<sup>‡</sup> and Dejerine and Thomas.\*\* These cases, though relatively few in

\* Schultze. Beiträge zur Lehre von dem sekundären Degeneration im Rückenmark des Menschen nebst Bemerkungen ueber die Anatomie der Tabes. Arch. f. Psychiat. u. Nervenkr., Berl., Bd. xiv (1883), S. 359-390.

† Hofrichter, E. Ueber aufsteigende Degenerationen des Rückenmarkes auf Grundlage pathologisch-anatomischer Untersuchung. Jena, 1883, 8vo.

‡ *Op. cit.*

\* Pfeiffer, R. Zwei Fälle von Lähmung der unteren Wurzeln des Plexus brachialis (Klumpke'sche Lähmung). Deutsche Ztschr. f. Nervenhe., Leipz., Bd. i (1891), S. 345-370.

|| Gombault, A. Bull. Soc. anat. de Par., t. lxvi, 1891.

<sup>Δ</sup> Sottas, J. Sur l'état de la moelle épinière dans deux cas de compression des racines postérieures. Compt. rend. Soc. de biol., Par., 9. s., t. v (1893), pp. 246-248.—Contribution à l'étude des dégénérescences de la moelle consécutives aux lésions des racines postérieures. Rev. de méd., Par., t. xiii (1893), pp. 290-313.

<sup>◇</sup> Mayer, C. Zur pathologischen Anatomie der Rückenmarkshinterstränge. Jahrb. f. Psychiat., Leipz. u. Wien, Bd. xiii (1894), S. 57-107.

<sup>‡</sup> Nageotte, J. Étude sur un cas de tabes uniradiculaire chez un paralytique général. Rev. neurol., Par., t. iii (1895), pp. 337; 369; 401.

<sup>‡</sup> Souques, A. Dégénération ascendante du faisceau de Burdach et du faisceau eunéiform, consécutive à l'atrophie d'une racine cervicale postérieure. Compt. rend. Soc. de biol., Par., 10. s., t. ii (1895), pp. 407-410.

<sup>‡</sup> Marguliés, A. Zur Lehre vom Verlaufe der hinteren Wurzeln beim Menschen. Neurol. Centralbl., Leipz., Bd. xv (1896), S. 347-351.

\*\* Dejerine J., et A. Thomas. Contribution à l'étude du trajet intra-médullaire des racines postérieures dans la région cervicale et dorsale supérieure de la moelle épinière; sur l'état de la moelle épinière dans un cas de paralysie radiale inférieure du plexus brachial d'origine syphilitique. Compt. rend. Soc. de biol., Par., 10. s., t. iii (1896), pp. 675-679.

number, have been very carefully studied, in two instances at least, by Marchi's method.\* The findings thus far in human cases prove that in man, as in experimental animals, the root fibres on entrance occupy a tolerably wide zone in the fasciculus cuneatus, just dorsal to the gray matter of the dorsal horn, as this is the area which is found degenerated at the level of a diseased dorsal root. In sections made at higher levels in the cord there is, as in animals, a gradual diminution in the number of degenerated fibres met with as the cord is ascended, proving that many of the root fibres terminate not only shortly after entrance, but also in different segments of the cord as they are passed. Each dorsal root, however, contains some very long fibres which ascend to high levels in the cord, and some to the medulla oblongata. The long fibres, as the study of the degenerated areas has demonstrated, are very gradually displaced from the region of the dorsal horn as the cord is ascended, owing to the entrance of new dorsal roots at each segment. As distinct a lamellation, however, corresponding to single roots, as would appear from Singer and Münzer's experiments to exist in the monkey, is not met with in the human cord; at any rate, in the midthoracic region there is in the fasciculus gracilis an intimate admixture of the long fibres of the lumbar and sacral roots (C. Meyer), and in the midcervical region the degenerated area corresponding to the sixth thoracic root (Margulíes' case) is practically identical with that for the third thoracic root (Nageotte's case) and with that for the first and second thoracic roots (Pfeiffer's cases). Still, speaking generally, it is true that *in the human cervical cord* in its upper part the portion of the fasciculus gracilis nearest the median septum represents the continuations of fibres in the sacral roots, the lateral portion of the fasciculus gracilis corresponds to the upper sacral, lumbar and, possibly, lower thoracic roots; the portion of the fasciculus cuneatus adjacent to the fasciculus gracilis contains the fibres from the thoracic roots, especially the upper, while the lateral portion of the fasciculus cuneatus consists mainly of fibres from the cervical roots. It is probable, how-

---

\* It is highly desirable that the spinal cord of any individual coming to autopsy with such a lesion should be removed carefully *in toto*, preserved in ten-per-cent formalin or fresh Müller's fluid, and handed over to a skilled neurologist for examination as soon as possible after its removal.

ever, that individual fibres may disobey this general law of distribution.\*

The change in the form of the degenerated area, as well as the alteration in position, is worthy of note. The case described by Marguliés may be chosen as typical of the class to which it belongs. If the accompanying figures (Fig. 293) and their legends be consulted, the relations at different levels above the site of lesion will be clearly understood. At the level of lesion (sixth thoracic root) the area corresponding to the entry zone shows degenerated fibres; the medial displacement with arrangement of the degenerated fibres in the form of an L is illustrated in the next section (level of first thoracic); still higher (level of seventh cervical root) the degenerated fibres, of which there are now many fewer, occupy a triangular area, and in the highest section figured (level of third cervical root) the typical narrow dorso-ventral band lying close to the paramedian septum is clearly visible.

Thus far in human cases, even in those studied by Marchi's method, continuations of dorsal root fibres into the opposite dorsal funiculus by way of the gray commissure have not been described, though some of those who have experimented upon animals assert that in them such fibres exist (Oddi and Rossi,† Loewenthal,‡ Paladino,\* and Pellizzi||). The very careful English investigator Mott, however, could not find such fibres in the monkey's cord.

The studies of secondary degenerations following *transverse lesion of the cord* from compression, trauma, and other causes, while of the greatest service for the information they have afforded concerning the tracts in general which ascend and de-

\* The studies of Schaffer with Marchi's method (Arch. f. mikr. Anat., Bonn, Bd. xliii) show this to be probable.

† *Op. cit.*

‡ Loewenthal, N. Neuer experimentell-anatomischer Beitrag zur Kenntniss einiger Bahnen im Gehirn und Rückenmark. Internat. Monatschr. f. Anat. u. Physiol., Leipz., Bd. x (1893), S. 168; 252; 269.

\* Paladino, G. Contribution aux connaissances sur le mode se comporter des racines dorsales dans la moelle épinière et sur les effets consécutifs à leur résection. Arch. ital. de biol., Turin, t. xxii (1894), pp. 53-59.

|| Pellizzi, G. B. Sur les dégénérescences secondaires dans le système nerveux central à la suite de lésions de la moelle et de la section de racines spinales; contribution à l'anatomie et à la physiologie des voies cérébelleuses. Arch. ital. de biol., Turin, t. xxiv (1895-'96), pp. 89-134.



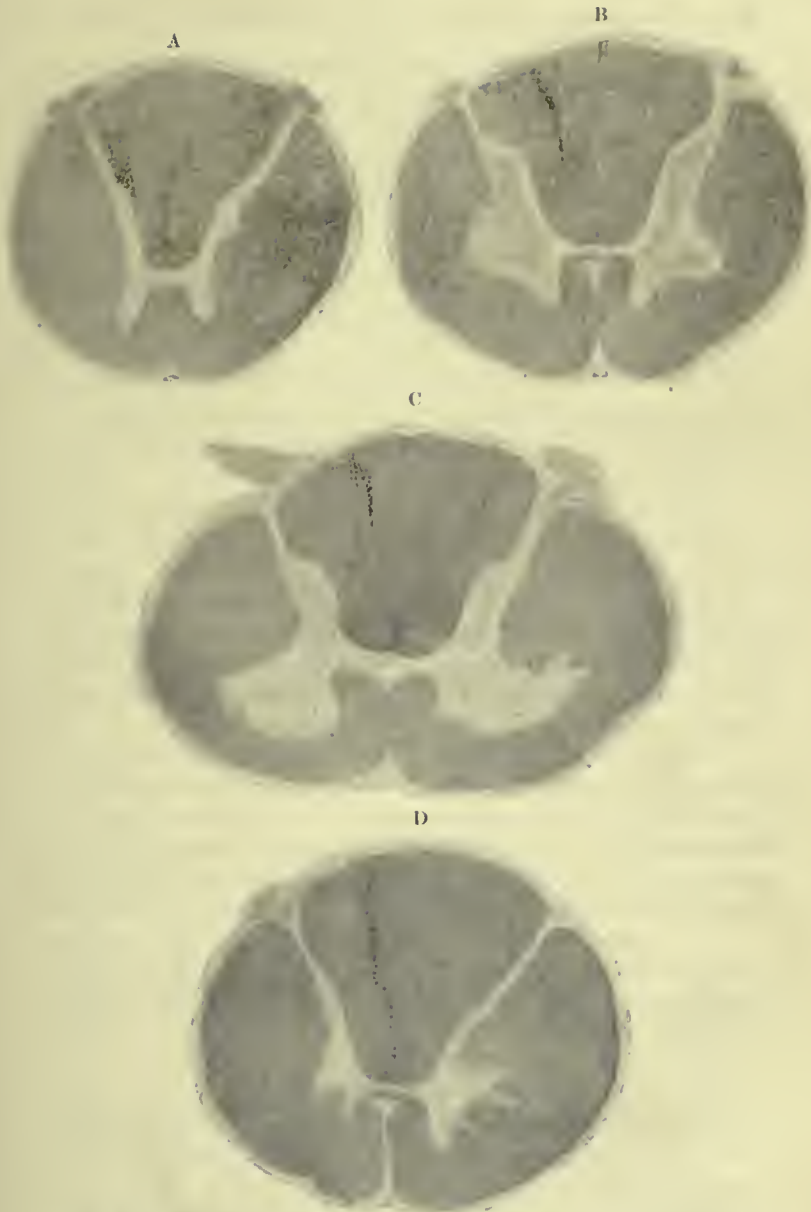


FIG. 293.—Transverse section of the human spinal cord showing secondary degenerations following isolated lesion of the sixth thoracic spinal nerve. (After A. Margulies, *Neurol. Centralbl.*, Leipz., Bd. xv, 1896, S. 348 and 349, Figs. 1-4.) A, transverse section at the level of the sixth thoracic root; B, transverse section at the level of the first thoracic root; C, transverse section at the level of the seventh cervical root; D, transverse section at the level of entrance of the third cervical root.

scend in the cord, naturally do not yield as satisfactory data for deductions concerning the intramedullary course of the dorsal root fibres as do the "purer" cases in which the root fibres alone are injured. Still they have supplied us with a mass of confirmatory evidence of very high value, and besides, in such cases certain features are met with which demand especial consideration.

Since the researches of Schiefferdecker \* an enormous number of cases have been studied by many different investigators. The individual researches which concern the dorsal funiculi need not be referred to here, since several excellent reviews of the status of this subject are extant—notably those of Tooth,† Barbacci,‡ Redlich,\* von Lenhossék,|| Schmaus,<sup>^</sup> and Philippe.◇

Leaving out of consideration here the degenerations in the ventral and lateral funiculi of the cord, the statement may be made that after total transverse lesion of the spinal cord the dorsal funiculi show, in addition to the changes which result locally from the direct insult (zone of traumatic degeneration of Schiefferdecker), certain secondary degenerations within them, mainly *above*, but to a less extent also *below* the level of the lesion.

The secondary degeneration in the dorsal funiculi *above* the level of the lesion (ascending secondary degeneration) varies according to the site of the injury. Thus, if it be situated in the lower parts of the spinal cord the dorsal funiculi will, just above the lesion, be degenerated over almost the whole of the transverse section of these funiculi. Sections a little higher,

\* Schiefferdecker, P. Ueber Regeneration, Degeneration und Architektur des Rückenmarkes. Arch. f. path. Anat., etc., Berl., Bd. lxxvii (1876), S. 542, and Bd. lxxix (1877), S. 321.

† Tooth, *op. cit.*

‡ *Op. cit.*

\* Redlich, E. Die hinteren Wurzeln des Rückenmarkes und die pathologische Anatomie der Tabes dorsalis. Arb. a. d. Inst. f. Anat. u. Physiol. d. Centralnervensyst. an d. Wien. Univ., Leipz. u. Wien. (1892), S. 1-52.

|| *Op. cit.*, S. 289.

<sup>^</sup> Schmaus, F. Sekundäre Degenerationen im Rückenmark. Article in Lubarsch-Ostertag's Ergebn. d. speziel. path. Morphol. u. Physiol. des Menschen und der Thiere. Wiesbaden (1896), S. 631.

◇ Philippe, Cl. Contribution à l'étude anatomique et clinique du tabes dorsalis. Paris, 1897.

after the entrance of dorsal roots above the lesion, show undegenerated fibres in the entry zone and lateral portion of the fasciculus cuneatus. The zone of undegenerated fibres increases progressively in size in sections cut at higher and higher levels, and the area occupied by the degenerated fibres as progressively decreases in size, and at the same time becomes more and more limited to the dorso-medial portions of the dorsal funiculi of the two sides. In the cervical region the degenerated fibres are entirely or almost entirely confined to the fasciculus gracilis, and if the lesions have been very low down (say below the level in which the fasciculus gracilis commences) they will occupy only that portion of the fasciculus gracilis adjacent to the dorso-medial septum. The degeneration in the fasciculus gracilis can be followed up to the nucleus funiculi gracilis in the medulla oblongata. Such findings prove the falsity of the doctrine of the absolute anatomical individuality of the fasciculus gracilis.

If the lesion, on the other hand, be situated in the upper thoracic region, in addition to the degeneration of the fasciculus gracilis, there may be found in specimens studied by Marchi's method, at a suitable period (death within three months) after the lesion, degenerated fibres also in the medial and dorsal portions of the fasciculus cuneatus, though the fibres are so few in number that in old cases studied by Weigert's method the fasciculus cuneatus on each side may appear almost or entirely normal. Transverse lesion of the cord in the cervical region always results in degenerations in the fasciculus cuneatus which, though diminishing in volume, may be followed up to the nucleus funiculi cuneati of the medulla oblongata.

Since each dorsal root, as is evident from the foregoing studies, contains fibres of very different lengths, we are justified in speaking of "short" dorsal root fibres, "long" dorsal root fibres, and dorsal root fibres of "intermediate" length (*fibres courtes, fibres longues, et fibres moyennes* of P. Marie, Fig. 294). The root fibres are distinguishable not only by their length, but also by their topographical relations in the dorsal funiculi, and their terminal distribution in the gray matter of the cord and medulla.

The areas of secondary degeneration in the dorsal funiculi below the level of a transverse lesion (descending secondary degeneration) also vary in form and extent according to the

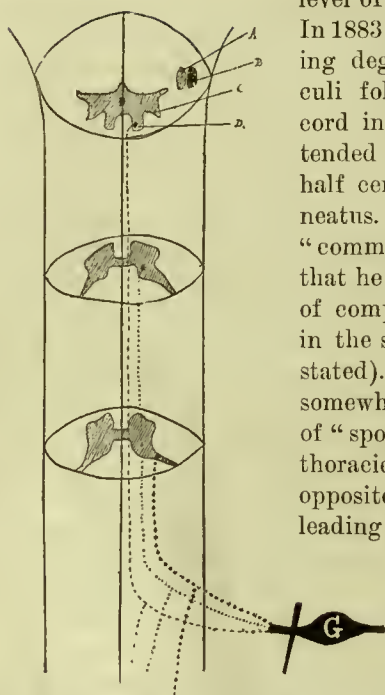


FIG. 294.—Scheme of the course and termination of the fibres of the dorsal roots. The black fusiform mass *G* represents a spinal ganglion; the line crossing it represents the site of section of the dorsal root arising from it. This dorsal root is divisible into three parts, each of which contains bifurcating fibres; +++++ "short fibres" terminating in dorsal horn; ..... "fibres of medium length" running in fasciculus cuneatus Burdachii to later plunge into gray matter at base of dorsal horn; ----- "long fibres" terminating in nucleus funiculi gracilis Golli (*D*) after having ascended within the fasciculus gracilis of the cord. The nucleus funiculi cuneati Burdachii is indicated at *C*. It receives the terminal of those "long fibres" and those "fibres of medium length" which come from the dorsal roots of the cervical portion of the spinal cord. (After P. Marie, *Leçons sur les maladies de la moelle*, Paris, 1892, p. 45, Fig. 48.)

level of the injury to the spinal cord. In 1883 Schultze\* described a descending degeneration in the dorsal funiculi following upon a lesion of the cord in the cervical region which extended downward about two and a half centimetres in the fasciculus cuneatus. He described it as a peculiar "commalike degeneration," and stated that he had found it also in two cases of compression of the thoracic cord in the same form (level of lesion not stated). He also met with it in a somewhat different form in one case of "spontaneous" myelitis of the mid-thoracic region. In a case of lesion opposite the ninth thoracic vertebra, leading to complete destruction of the

cord at this level, he found no such degeneration, the dorsal funiculi being entirely intact in the lumbar region. This peculiar degeneration which had been earlier (1880) observed by Westphal and by Strümpell, has been repeatedly found in similar cases by other investigators. In Fig. 295 is shown a degeneration of Schultze's comma in a case of compression myelitis which S. Rosenheim has recently studied.

The lesion was situated in the first, second, and third thoracic segments, being most marked at the

\* Schultze, F. Beiträge zur Lehre von der secundären Degeneration im Rückenmark des Menschen nebst Bemerkungen ueber die Anatomie der Tabes. Arch. f. Psychiat. u. Nervenkr., Berl., Bd. xiv (1883), S. 359-390.



level of the second segment. The figures show the degeneration in the dorsal funiculi at the level of the fourth, fifth, and

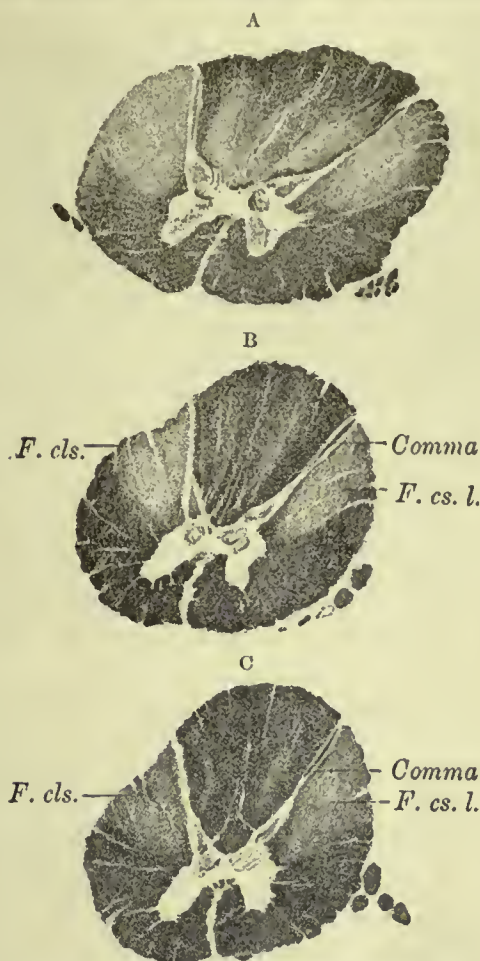


FIG. 295.—Secondary degeneration in the dorsal funiculi below a transverse lesion due to compression of the cord; Weigert-Pal preparation. (After S. Rosenheim, Johns Hopkins Hosp. Bull., vol. ix, anatomical number, Sept.-Oct., 1898.) A, level of the fourth thoracic segment; B, level of the fifth thoracic segment; C, level of the sixth thoracic segment. The position of the degenerating comma of Schultze is very evident. *Fcls*, fasciculus cerebrospinalis lateralis, also degenerated.

sixth thoracic segments. Below this level it could not be followed. The form and position of the comma in the fasciculus cuneatus parallel to the medial margin of the dorsal horn of

gray matter is well illustrated. The thicker head end of the comma is directed toward the gray matter, the thin tail toward the dorsal surface.

While some investigators (Schultze, Bruns, v. Lenhossék, Flatau, Giese) have held that the comma corresponds to descending fibres from dorsal roots, others (Tooth, Marie, Daxenberger, Gombault and Philippe, Dufour, Hoche) think that the medullated axones to which this area corresponds represent fibres entirely independent of the dorsal roots, and that they have their cells of origin in the gray matter of the spinal cord itself. The comma would, according to the latter view, represent a longitudinal association tract connecting different levels of the gray matter with one another. On this supposition its fibres would be intrinsic to the cord itself (*fibres endogènes* of P. Marie).\* The comma appears to have never been observed below the level of the ninth thoracic segment until the recent study of Hoche,† in which that observer, by means of Marchi's method in a case of compression at the level of the seventh thoracic segment, followed its fibres, though the commalike arrangement soon disappeared, as far as a point between the third and fourth lumbar segments. He was able, too, to determine by means of longitudinal sections what became of the fibres of the comma. They could be followed as fine dotted fibrils passing obliquely into the gray substance. In this, however, they must quickly change their plane, for Hoche could never follow a fibril to its exact termination. The long extent of these fibres in the dorsal funiculi (through at least eight segments of the spinal cord) is, as Hoche suggests, scarcely in accord with the idea that they represent descending branches of the dorsal roots. In the second case of compression at the junction of the cervical and thoracic cord, Hoche followed fibres from the comma as low as the level of the twelfth thoracic segment. Longitudinal sections in this case showed the degener-

---

\* Marie, P. *Leçons sur les maladies de la moelle*, 8°, Par. (1892), (G. Masson).—*De l'origine exogène ou endogène des lésions du cordon postérieur étudiées comparativement dans le tabes et dans le pellagre*. *Semaine méd.*, Par., t. xiv (1894), pp. 17-20.

† Hoche, A. *Ueber secundäre Degeneration, speciell des Gowers'schen Bündels nebst Bemerkungen ueber das Verhalten der Reflexe bei Compression des Rückenmarkes*. *Arch. f. Psychiat. u. Nervenkr.*, Berl., Bd. xxviii (1896), S. 510-543.

ated fibres running into the *nucleus dorsalis* (Fig. 296). Mann\* advances with much reserve the hypothesis that since it extends throughout the whole thoracic cord, diminishing progressively




FIG. 296.—Longitudinal section in an almost sagittal direction at the level of the eighth thoracic nerve showing degenerated fibres in the dorsal funiculi after transverse lesion. (After A. Hoche, *Arch. f. Psychiat.*, etc., Berl., Bd. xxviii, 1896, Taf. x, Fig. 8.) *a*, ventral funiculus; the degenerated fibres belong in part to the descending sulco-marginal degeneration, in part to short paths of the fasciculi proprii; *b*, substantia grisea containing the *nucleus dorsalis Clarkii*; *c*, dorsal funiculus. The degenerated fibres which lie on the right-hand side near the periphery belong to the path which lower down forms the oval field of Flechsig. The degenerated fibres going toward the substantia grisea form, on a corresponding cross section, the well-known comma-shaped degeneration figure. The comma is soon exhausted below this level, since all the fibres turn into the gray substance.

in volume as the cord is descended, it may have to do with the innervation of the intercostal muscles. As a matter of fact, at present its function is entirely unknown. In 1897, at the Moscow Congress, Obersteiner expressed the opinion that the fibres of the comma are exogenous, and in 1898 Zappert,† working in Obersteiner's laboratory, made a strong plea for the view that Schultz's comma, at least in part, is formed of descending limbs of dorsal root fibres of the upper parts of the spinal cord.

A set of fibres in the dorsal funiculi other than those concerned in the formation of Schultz's comma, though they have been confused with the latter, degenerate downward after transverse lesion of the cord. Thus in one of the cases studied by

\* Mann, L. *Klinische und anatomische Beiträge zur Lehre von der spinalen Hemiplegie.* Deutsche Ztschr. f. Nervenhe., Leipz., Bd. x (1896), S. 1-66.

† Zappert, J. *Beiträge zur absteigenden Hinterstrangsdegeneration.* Neurol. Centralbl., Leipz., Bd. xvii (1898), S. 102-107.

Barbacci, \* in which there was compression at the level of the sixth and seventh thoracic roots, followed by death at the end of forty days, he found just below the lesion a rather diffuse degeneration in the dorsal funiculi. Lower down he found in the transverse sections a stripe in the lateral part of the fasciculus cuneatus on each side, while much lower still the degeneration was limited to a narrow stripe along the dorsal median septum. Barbacci assumed (almost certainly erroneously, as will immediately be clear) that the degeneration below along the septum depended upon the wandering over toward the median line of a certain number of fibres from the comma higher up. The degeneration here mentioned as situated near the median septum has also been observed by Redlich † and by Daxenberger. ‡ The region concerned together with a peculiar triangular field carefully described by Gombault and Philippe # does not degenerate after injury to the dorsal roots, nor does it degenerate in an ascending direction after lesion of the gray substance below. Gombault and Philippe conclude from their studies that the fibres adjacent to the septum, the so-called *dorsomediales Sacralbündel* of Obersteiner (those of the two sides corresponding to the *centrum ovale* of Flechsig), form at the level of the lumbar enlargement and a little below this level an oval fasciculus; that lower down in the *conus medullaris* the same fibres are grouped in the form of a

---

\* *Op. cit.*

† Redlich, E. Zur Verwendung der Marchi'schen Färbung bei pathologischen Präparaten des Nervensystems. *Centralbl. f. Nervenl. u. Psychiat.*, Coblenz u. Leipz., n. F., Bd. iii (1892), S. 111-115. See also, Die hinteren Wurzeln des Rückenmarkes und die pathologische anatomie der *Tabes dorsalis*. *Jahrb. f. Psychiat.*, Leipz. u. Wien, Bd. xi (1892-'93), S. 1-52.

‡ Daxenberger, H. Ueber einen Fall von chronischer Compression des Halsmarks mit besonderer Berücksichtigung der secundären absteigenden Degenerationen. *Deutsche Ztschr. f. Nervenl.*, Leipz., Bd. iv (1893-'94), S. 136-150.

# Gombault, A., et C. Philippe. Contribution à l'étude des lésions systématisées dans les cordons blanc de la moelle épinière. *Arch. de méd. expér. et d'anat. path.*, Par., t. vi (1894), pp. 365; 538.—Note relative à la signification de la sclérose descendante dans le cordon postérieur et aux relations qu'elle affecte avec le centre ovale de Flechsig. *Progrès méd.*, Par., 2 s., t. xix (1894), pp. 255-257.—État actuel de nos connaissances sur la systématisation des cordons postérieurs de la moelle épinière. *Semaine méd.*, Par., t. xv (1895), pp. 161-166. Also Eng. Transl. in *Med. Week*, Par., vol. iii (1895), pp. 433-439.



triangular area (*triangle médian* of Gombault and Philippe); and that they belong to the association systems of the dorsal funiculi, and do not represent continuations of dorsal root fibres.

Hoche's study\* of two cases of compression (one at the level of the seventh thoracic, the other at the level of the eighth cervical segment) has gone far to render our knowledge of the fibres under consideration more satisfactory. By Marchi's method he has been able to follow the degenerated fibres in both instances throughout the whole thoracic cord into the filum terminale. In his second case degenerated fibres of this group could be followed through no less than twenty-three segments of the spinal cord. These cases are so important that they merit consideration in some detail.

In Hoche's first case (compression at the level of the seventh thoracic segment) the degenerated fibres belonging to the system under discussion, even just below the lesion, are situated on the dorsal periphery of the cord and are entirely distinct from those of the comma (Fig. 297). A little lower they approach the dorsal median septum (without, however, leaving the dorsal periphery), which they reach at the level of the eleventh thoracic segment. The fibres lower down begin to be arranged along the median septum, part of them remaining at the dorsal periphery, however, immediately adjacent to the septum until the level of the second lumbar is reached. From the level of the third to that of the fifth lumbar they no longer reach the dorsal periphery. But from the level of the fifth lumbar downward as far as the filum terminale the degenerated fibres of the two sides form a small triangle, the narrow base of which corresponds to the dorsal periphery of the cord. Throughout, the comma and the fibres of this bundle are entirely separate and distinct. They have, Hoche emphasizes, nothing to do with one another. It will be noticed that the degenerated fibres from the third to the fifth lumbar segment correspond exactly to Flechsig's *centrum ovale*, and that from the third to the

---

\* Hoche, A. Ueber Verlauf und Endigungsweise der Fasern des ovalen Hinterstrangfeldes im Lendenmarke. Neurol. Centralbl., Leipz., Bd. xv (1896), S. 154-156.—Ueber secundäre Degeneration speciell des Gowers'schen Bündels, nebst Bemerkungen ueber das Verhalten der Reflexe bei Compression des Rückenmarkes. Arch. f. Psychiat. u. Nervenkr., Berl., Bd. xxviii (1896), S. 510-543.

fifth sacral segment they correspond precisely to the *triangle médian* of Gombault and Philippe.

In Hoche's second case (compression at the level of the eighth cervical) it was found that the fibres of the tail of the comma in the upper part of the thoracic cord are intermingled

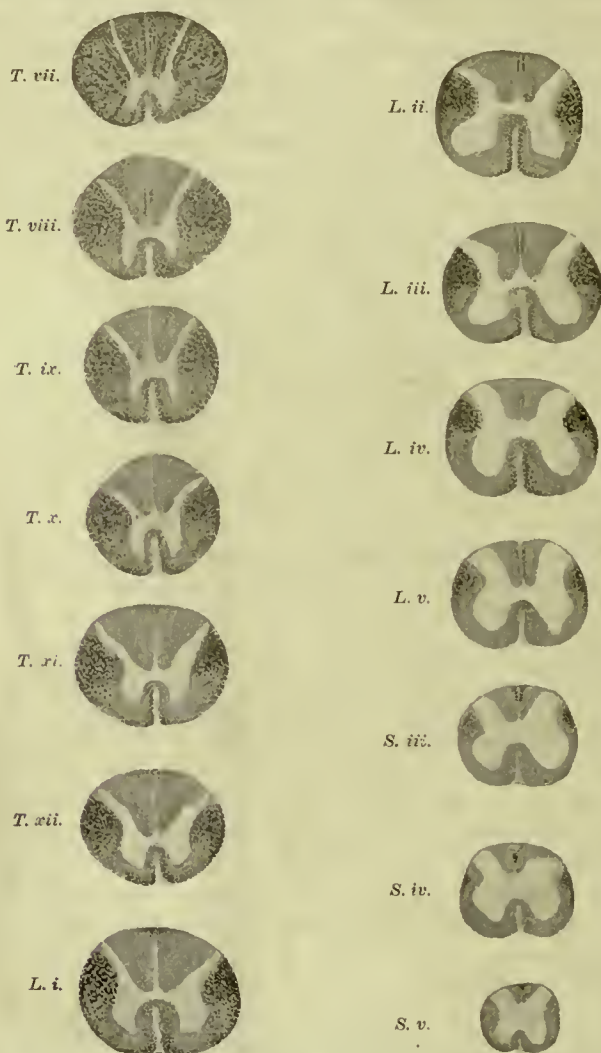


FIG. 297.—Descending degeneration below a transverse lesion at the level of the seventh thoracic segment. Method of Marchi. (After A. Hoche, Arch. f. Psychiat., etc., Berl., Bd. xxviii, 1896, Taf. ix, Fig. 1.)

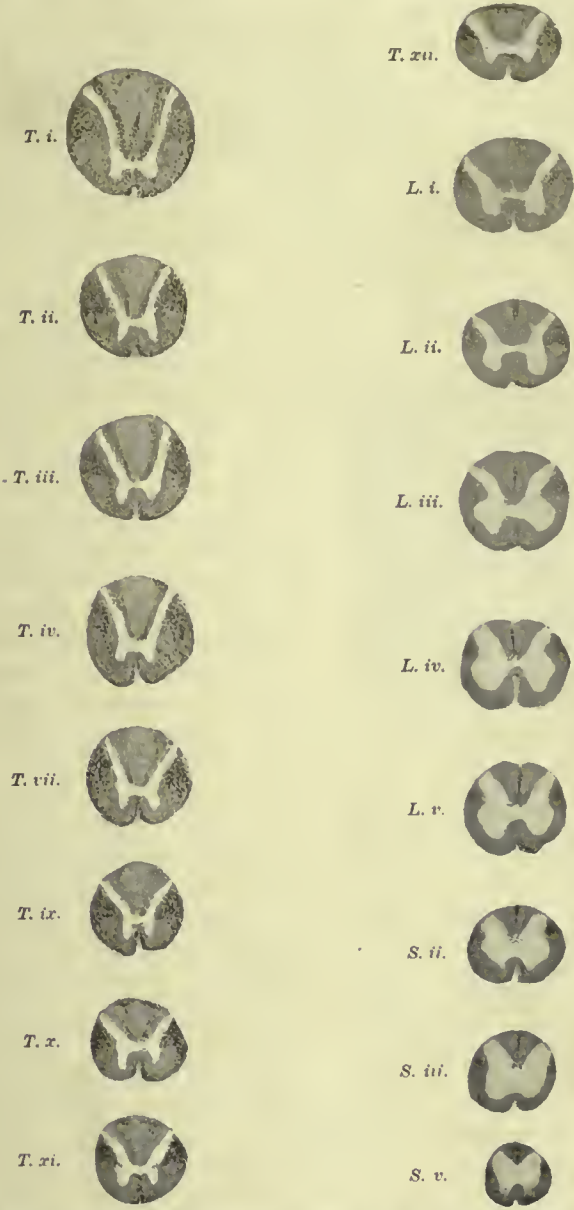


FIG. 298.—Descending degenerations below a lesion (compression) of the spinal cord at the level of the eighth cervical nerve. Method of Marchi. (After A. Hoche, Arch. f. Psychiat., etc., Berl., Bd. xxviii, 1896, Taf. x, Fig. 1.)

with the most ventral of the group of fibres, which lower down are confined to the dorsal periphery of the cord, the *centrum ovale* of Flechsig, and the *triangle médian* of Gombault and Philippe (Fig. 298). Though there is a certain degree of intermingling, the fibres appear to represent entirely distinct bundles, inasmuch as longitudinal sections prove that the fibres of the comma passing more and more ventralward finally terminate by bending into the gray substance. They do not wander backward into the dorsal bundle.

The fibres of the dorsal bundle terminate at different levels, but apparently in greatest numbers in the lower lumbar region,



FIG. 299.—Sagittal longitudinal section at the level of the fifth sacral nerve from a case of compression of the cord at the level of C. viii. Degenerated fibres stained by the method of Marchi. (After A. Hoche, Arch. f. Psychiat. u. Nervenkr., Berl., Bd. xxviii, 1896, Taf. x, Fig. 7.) *a*, ventral column, free from degeneration at this level; *b*, substantia grisea, showing the cells of the central canal; no ganglion cells in this region; *c*, dorsal funiculi close to the middle line, some of the vessels near the middle line being struck. The fibres of the triangular field (in corresponding cross section) of this level are bending around in a slightly curved direction into the gray substance. The field soon becomes exhausted.

inasmuch as at the level of the fourth lumbar segment there are as many as 350 or 400 degenerated fibres (lesion at level of eighth cervical), whereas at the level of the third sacral the number has been reduced to 130 or 140, at the level of the fifth sacral to 30 or 35, while below this only isolated fibres were found (Hoche). The ending of these fibres in the gray substance is clearly shown in Fig. 299.

A very valuable confirmation of the views above presented is to be found in a case of fracture of the twelfth thoracic vertebra, with complete crushing of the cord for a length of some 2 cm. in the lumbar region, studied by Bruce and Muir, of Edinburgh.\* As the patient died about five weeks after the injury,

the case was a very favorable one for studying the degeneration by the method of Marchi. Bruce and Muir describe

\* Bruce, A., and R. Muir. On a Descending Degeneration in the Posterior Columns in the Lumbar-Sacral Region of the Spinal Cord. Brain, Lond., vol. xix (1896), pp. 333-345.



and figure accurately the course and termination of the descending degenerated fibres with especial reference to the bundle here under discussion. They suggest that the bundle be called the "descending septo-marginal tract."

Besides the two distinct and now fairly sharply defined descending tracts which have just been described, there is a third group of fibres in the dorsal funiculi which degenerate downward, which should not be passed over unmentioned. In Fig. 297, at the level of the eighth thoracic segment (first segment below the lesion in Hoche's first case), is seen a small group of fibres in the form of a stripe along the dorsal septum in its ventral half. This does not reach the gray matter. It has already vanished in the section through the ninth thoracic segment. In Fig. 298 the same fibres, though in greater number, are seen in Hoche's second case at the level of the first thoracic segment, forming a field on each side of the median line converging toward the septum. They also have vanished at the level of the second thoracic segment (second segment below the lesion). These fibres evidently are extremely short (length of one or two segments).

Finally, immediately below a transverse lesion a few fibres degenerate diffusely over almost the whole of the transverse section, extending, however, rarely beyond one segment, an area usually spoken of as being within the limits of "traumatic degeneration."

The question now arises, What is the origin of these various descending tracts? We know from studies made by Golgi's method (*vide infra*) that fibres of two sorts descend in the dorsal funiculi—(1) the descending limbs of bifurcation of the fibres of the dorsal roots, and (2) the medullated axones of cells situated within the gray matter of the cord. What is the relation of each of these varieties of fibres to the different groups of descending fibres determined by the study of secondary degenerations? It must be confessed that at present we do not know for certain. Dufour\* supports the view of Tooth and Marie. Studying a case of compression of the lumbo-sacral nerve roots, he found in the lower part of the cord the two

---

\* Dufour. Quelques considérations sur le groupement des fibres endogènes dans les cordons postérieurs de la moelle, à propos d'un cas de compression des nerfs de la queue de cheval. *Compt. rend. Soc. de biol. Par.*, 10, s., t. iii (1896), p. 449.

bundles (comma, septo-marginal bundle) entirely free from degeneration, and believes, therefore, that the fibres entering into the dorsal roots play no part in their formation. He believes that each of these descending tracts represents an association bundle (endogenous fibres) of varying appearance, according to the level at which one observes it, the one being represented by the comma of Schultze in the upper part of the cord, by "cornu-commissural" fibres in the lumbar and upper sacral regions, and below the fourth sacral level by fibres which he terms the *faisceau sulco-commissural postérieur*. The second bundle, consisting in the main of longer association fibres, is situated in the thoracic cord in the dorso-lateral zone of the dorsal funiculus; at the level of the twelfth thoracic and first lumbar segment it reaches the dorso-medial angle of each dorsal funiculus. At the level of the third lumbar root it corresponds to the *Centrum ovale* of Flechsig, while at the fifth sacral it becomes the *triangle médian* of Gombault and Philippe. It is obvious that the consensus of opinion at present is in favor of the endogenous nature of the fibres of these two bundles.\* The idea of Hoche that the shorter longitudinal association fibres tend to run in the more ventral bundle, the longer in the dorsal bundle, is very attractive and entirely in accord with the general law of the tendency of the longer fibres to be situated near the periphery of the white matter. This law, though generally recognized, has been recently very definitely formulated by Flatau.†

---

\* It must be pointed out, however, that such reliable observers as Dejerine and Spiller (Dejerine, J., et W. G. Spiller. Contribution à l'étude de la texture des cordons postérieurs de la moelle épinière; du trajet intramédullaire des racines postérieures sacrées et lombaires inférieures. Comp. rend. Soc. de biol., Par., 10. s., t. ii (1895), pp. 622-628) contest the extension of endogenous fibres into the *triangle médian*, and von Lenhossék (*op. cit.*, S. 293) believed (in 1895) that the middle part of the fasciculus cuneatus, about the region of Schultze's comma, and perhaps also the field on the dorsal periphery, are the areas in which the descending limbs of the dorsal root fibres run longitudinally. Whether or not, in view of the findings of Hoche, Bruce and Muir, and Dufour in human cases studied since 1895, these observers have altered the opinions then expressed, I do not know. The carefully studied case of K. Schaffer (*op. cit.*) showed no degenerated fibres in the median zone of Flechsig, but this, as Hoche suggests, may be due to the fact that four months after the lesion is too late for satisfactory study by Marchi's method.

† Flatau, E. Das Gesetz der excentrischen Lagerung der langen Bahnen im Rückenmark. Ztschr. f. klin. Med., Berl., Bd., xxxiii (1897), S. 55-152.

The descending limbs of the fibres of the dorsal roots must, however, occupy some position in the cord. Whether they are diffusely distributed over the fasciculus cuneatus or are limited to the region of the entry-zone or to the third group of descending fibres (very short fibres) described above, or finally are intermixed with the endogenous descending fibres, we do not know. Serial sections in the next human case of pure lesion of a dorsal root, coming to autopsy at a period suitable for study by the method of Marchi, should settle this much-vexed question.

In view, then, of the extreme probability that descending endogenous fibres really exist in that part of the cord, the question naturally arises, Are there not also ascending endogenous fibres in the dorsal funiculi? Such a question could scarcely be answered by the study of degenerations following either lesion of the roots or compression of the cord. It could be more satisfactorily attacked by Golgi's method, and Ramón y Cajal\* and v. Lenhossék† have described the cell bodies of neurones situated in the dorsal horns whose axones enter the dorsal white funiculi. Von Lenhossék states that the axones may be mixed with ascending and descending limbs of sensory fibres. The number and course of the ascending endogenous axones in the cord of the rabbit can be exquisitely established by utilizing the experiment of Ehrlich and Brieger.‡ Münzer and Wiener\* have demonstrated in the rabbit by this method (tying the abdominal aorta and thus causing anæmic necrosis of the gray matter of the lumbar spinal cord) the course of the ascending endogenous fibres of lumbar origin (Fig. 300). While the results of such an animal experiment may not of course be directly transferred to the human cord, still it is in the highest degree suggestive and should put us on the alert for the isolation of these fibres in human beings. It is of no inconsiderable interest to note that the ascending bundle in the rabbit occupies a region in the upper part of the cord

---

\* Ramón y Cajal, S. Nuevas observaciones sobre la estructura de la médula espinal de los mamíferos. Barcelona (1890).

† *Op. cit.*, S. 354-356.

‡ Ehrlich und Brieger. Ueber die Ausschaltung des Lendenmarkgraues. Ztschr. f. klin. Med., Berl., Bd. vii, Suppl.-Hft. (1883-'84), S. 155-164.

\* Münzer, E., und H. Wiener. Beiträge zur Anatomie u. Physiologie des Centralnervensystems. Erste Mitth. Ueber die Ausschaltung des Lendenmarkgraues. Arch. f. exper. Path. u. Pharmacol., Leipzig, Bd. xxxv (1895), S. 113.

along the median septum, reminding one very much of the position taken by the descending bundle of endogenous fibres in the lumbar cord of human beings.\*

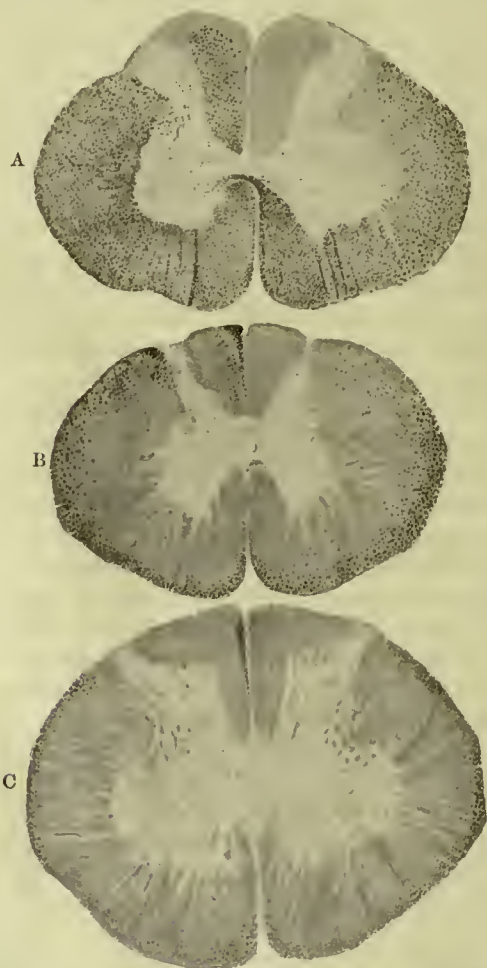

FIG. 300.—Cross sections through the spinal cord of a rabbit eleven days after compression of the aorta for one hour. Degenerated fibres stained by the method of Marchi. (After Münzer and Wiener, *Arch. f. exper. Pathol. u. Pharmacol.*, Leipz., Bd. xxxv, 1895, Taf. ii, Figs. 8, 9, and 10.) A, cross section through the lumbar cord at the level of the twenty-fifth root; B, cross section through the lower thoracic cord at the level of the twentieth root; C, cross section through the cervical cord at the level of the seventh root.

\* The possibility of injury to the nutrition of exogenous fibres by the conditions of the experiment must here not be lost sight of.



To conclude this part of our subject, therefore, it may be stated that secondary degenerations prove that the dorsal funiculi are composed of two distinct sets of elements—(1) intramedullary continuations of dorsal root fibres (central prolongations of spinal ganglion cells) and (2) medullated axones of neurones whose cell bodies are situated in the gray matter of the cord. The former (extrinsic or exogenous fibres) make up the main bulk of these funiculi, the latter (intrinsic or endogenous fibres) partly descending, partly in all probability ascending, make up a small portion of certain fairly definitely defined regions. The position of the ascending limbs of the bifurcated exogenous fibres corresponding to dorsal roots of different levels have been tolerably well established; the topographical relations of the descending limbs have not yet been satisfactorily made out. I venture to suggest that all of the fibres of the dorsal funiculi whose cells of origin are situated within the spinal cord itself be included under the term “fasciculus dorsalis proprius.” This would bring the dorsal funiculi into agreement with the ventral and lateral funiculi where the fasciculus ventralis proprius and the fasciculus lateralis proprius contain respectively both ascending and descending intersegmental fibres of varying length. The fasciculus dorsalis proprius would then be divisible into a ventral portion (fibres of the comma, etc.) and a dorsal portion (Bruce and Muir’s dorsal septo-marginal bundle, Obersteiner’s *dorsomediales Sacralbündel*, fibres of the *Centrum ovale* of Flechsig, of the median triangle of Gombault and Philippe, etc.).

The fibres of the dorsal roots terminating at different levels in the cord and medulla have been followed into the gray matter by means of Marchi’s method, though their exact terminal relations can be made out only with the aid of the method of Golgi (*vide infra*). The majority of fibres of the fasciculus gracilis which reach the medulla oblongata turn in to end in the nucleus funiculi gracilis, those of the fasciculus cuneatus to end in the nucleus funiculi cuneati. Marchi’s method, however, shows that in cases of compression of the cord not all the fibres of the dorsal funiculi which reach the medulla end in the gray matter of the nuclei graciles et cuneati. A certain number of those which ascend in the fasciculus gracilis are continued on as *fibræ arcuatae externæ dorsales* into the corpus restiforme and terminate first in the cerebellum, while a cer-

tain number are continued as fibræ arcuatæ internæ and can be seen decussating in the raphe (Fig. 301). Many of the fibres of the fasciculus cuneatus too do not terminate in the nuclei of the medulla (K. Schaffer, Hoche). In Fig. 302 degenerated

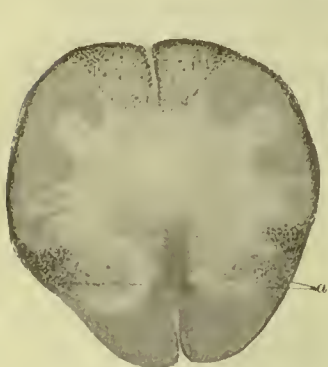


FIG. 301.

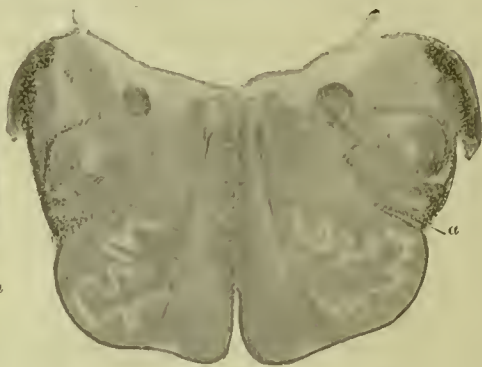


FIG. 302.

FIG. 301.—Transverse section through the medulla oblongata in the region of the decussatio lemniscorum (After A. Hoche, Arch. f. Psychiat. u. Nervenkr., Berl., Bd. xxviii, 1896, Taf. ix, Fig. 4.) Ascending degeneration following lesion at the level of the seventh thoracic segment. The degenerated fibres are stained black by Marchi's method. *a*, fasciculus ventrolateralis superficialis Gowersi. Degenerated fibres from the dorsal funiculi are seen among the fibræ arcuatæ internæ.

FIG. 302.—Cross section through the medulla oblongata at the level of the lower half of the nucleus olivaris inferior from the same case as the preceding figure. *a*, Gowers' bundle. (After A. Hoche, Arch. f. Psychiat. u. Nervenkr., Berl., Bd. xxviii, 1896, Taf. ix, Fig. 5.)

fibres coming from the area representing the uppermost end of the nucleus fasciculi cuneati can be seen forming two bands, one turning dorsal, the other ventral to the substantia gelatinosa and tractus spinalis nervi trigemini to enter the corpus restiforme through which the cerebellum is reached.\*

---

\* This path to the cerebellum apparently corresponds to v. Kölliker's *Hinterstrangkelnirnbahn*. The uncrossed path from the dorsal funiculi direct to the cerebellum is designated by some of the German writers a *directes ungekreuztes Hinterstrangkelnirnsystem*. In 1893 Hugh T. Patrick, of Chicago (Ueber aufsteigende Degeneration nach totaler Quetschung des Rückenmarkes, Arch. f. Psychiat. u. Nervenkr., Berl., Bd. xxv (1893), S. 831-844), described atrophy of fibres in the dorsal part of the corpus restiforme following upon transverse lesion at junction of the pars cervicalis with the pars thoracalis of the spinal cord. Fibres from the fasciculus gracilis to the lateral part of the corpus restiforme were found by Marehi's method to be degenerated in a case of compression of the cauda equina by A. Souques and G. Marinesco (Dégénération ascendante de la moelle; destruction par compression lente de la queue de cheval et du cône terminal.

The study of Weigert preparations in longitudinal and transverse section has shown the existence of many bundles of medullated nerve fibres extending between the white matter of the dorsal funiculi and the gray matter of the cord. When these were first observed they were believed to be medullated fibres having their origin in cells of the cord, and passing from it into the dorsal white funiculi. But after the study of secondary degenerations which proved that the majority of the white fibres of the dorsal fasciculi are in reality continuations of dorsal root fibres, the belief became current that the medullated fibres now under consideration represent mainly the terminals of the dorsal root fibres themselves, running in to end in the gray matter of the spinal cord. Exhaustive and exact descriptions of these medullated fibres were given by various investigators who studied Weigert specimens; the course of the bundles, their arrangement in groups, and the relative size of the individual bundles have been known for a long time. Even more had been made out. Gerlach, for example, had mentioned the entrance of bundles of fibres from the dorsal funiculi into the ventral horns, an observation which was confirmed by Waldeyer, Flechsig, and others. Von K  lliker described the termination of many fibres from the dorsal funiculi in the *nucleus dorsalis* (Clarke's gray column), and von Lenhoss  k had called attention to the relation of the dorsal root fibres to the dorsal white commissure. As we shall see, these descriptions, so far as they were purely objective, still have their value. They contain, however,

---

Presse m  d., Par. (1895), pp. 75-78. See also the interesting case recorded by F. v. S  lder, *Neurol. Centralbl.*, Leipz., Bd. xvi (1897), S. 308). Edinger as early as 1885 (*Zur Kenntnis des Verlaufes der Hinterstrangfasern in der Medulla oblongata und im unteren Kleinhirnschenkel*, *Neurol. Centralbl.*, Leipz., Bd. iii (1885), S. 73-76) had stated that a few fibres pass directly from the *fasciculus gracilis* around the periphery of the cord as *fibre arcuatae externae dorsales* to enter the *corpus restiforme*. The direct termination of axones of dorsal root fibres in the cerebellum of the same side seems to be better established for man than for animals. The study of experimental degenerations by Marchi's method in animals by such careful observers as Sherrington and Mott failed to reveal blackened fibres beyond the nuclei in the medulla. (See Sherrington, C. S. *Note on the Spinal Portion of some Ascending Degenerations*. *J. Physiol.*, Cambridge, vol. xiv (1893), pp. 255-302; and Mott, F. W. *Experimental Inquiry upon the Afferent Tracts of the Central Nervous System of the Monkey*. *Brain*, Lond., vol. xviii (1895), pp. 1-20.)

where objectivity was neglected, many grave errors which had to be corrected by means of studies made after the method of Golgi. In the light of the newer results, however, these older descriptions are by no means devoid of value. They can now be correctly interpreted, and indeed a combination of the results of studies by Golgi's method with those belonging to the older technique alone permit us to understand satisfactorily the anatomical relations of this portion of the spinal cord.



## CHAPTER XXXIV.

### CENTRAL AXONES OF PERIPHERAL CENTRIPETAL NEURONES. (*Continued.*)

The dorsal root fibres as studied by Golgi's method—Y-shaped bifurcation—  
Ascending limbs and descending limbs—Collaterals and terminals.

NOWHERE, perhaps, in the nervous system has the application of Golgi's method been of greater service than in the study of the spinal cord itself. Golgi's \* early studies of the cord, which are of the very highest importance, were soon followed by the epoch-making contributions of Ramón y Cajal, † von Kölliker, ‡ von Gehuchten, § von Lenhossék, || and Retzius. ^ An excellent epitome of the newer work on the spinal cord is to be found in the thorough article of Peláez. ¶

The chief results afforded by the study of Golgi pictures of the intramedullary continuations of the dorsal root fibres may briefly be summed up as follows:

(1) The fact has been completely demonstrated, by way of direct observation, that the majority of the fibres of the dorsal funiculi represent continuations of dorsal root fibres—that is, of the central prolongations of spinal ganglion cells.

---

\* Golgi, C. Studi istologici sul midollo spinale. Arch. ital. per le mal. nerv., Milano, vol. xviii (1881), pp. 155-165.

† Ramón y Cajal, S. Contribución al estudio de la estructura de la médula espinal. Rev. trimest. de histol. (1889), No. 3 y 4.

‡ von Kölliker, A. Ueber den feineren Bau des Rückenmarks Sitzungsber. d. phys.-med. Gesellsch. zu Würzb., 1890, S. 44-56.

§ von Gehuchten, A. La moelle épinière et le cerveau. Cellule, Liège et Louvain (1891).

|| von Lenhossék, M. *Op. cit.*

^ Retzius, G. Biol. Untersuch., Stockholm, n. F. (1891 and 1893).

¶ Peláez, P. L. Anatomía normal de la médula espinal humana y algunas indicaciones de anatomía comparada sobre el mismo órgano. Madrid (1897), 569 pp., 12mo.

(2) The dorsal root fibre has been shown to divide by Y-shaped division soon after entrance into the cord into an ascending and a descending limb.

(3) The limbs soon assume a perpendicular direction, the descending one terminating, after a short course, in the gray matter of the cord, the ascending limb running usually for a much longer distance in the white matter before terminating in the gray matter of the central system.

(4) In its course each fibre gives off a large number of collaterals, so that each central prolongation of the spinal ganglion cells comes into conduction relation with neurones of the cord, not only in the region where its fibre terminates, but at many levels in the cord where its collaterals end.

(5) The majority of the medullated fibres seen in Weigert specimens entering the gray matter from the dorsal funiculi represent, not the terminals of the dorsal root fibres, but collaterals given off by the ascending and descending limbs during their course.

(6) The terminals and collaterals of the dorsal root fibres which enter the gray matter end there among or upon the cell bodies and dendrites of the neurones of the cord. They are never connected otherwise than secondarily with cells, or with dendrites, or with collaterals or side fibrils, or with the branches of axones of cell type II.\*

(7) The number of collaterals given off by different portions of the continuations of the dorsal root fibres varies, and as a result the different areas in the dorsal funiculi do not agree as regards their richness in collaterals.

(8) Greater precision has been reached in determining the exact conduction relations of the various groups of fibres in the dorsal fasciculi to definite groups of neurones within the spinal cord. (Ventral horn cells; cells of nucleus dorsalis, etc.)

Golgi preparations show that on their entrance into the cord at the dorso-lateral sulcus the dorsal root fibres plunge in directly medial to the marginal zone of Lissauer, where the axones are seen to be grouped into two more or less definite portions, a lateral group of delicate axones and a medial group of much coarser axones. Very soon after entrance each fibre divides by means

---

\* The few centrifugal fibres of dorsal roots met with in many animals form an exception to this rule. They have their origin in cells in the cord.

of a forklike, Y-shaped division at an angle between  $150^{\circ}$  and  $160^{\circ}$  into two divisions, an ascending and a descending branch. While Golgi asserts that Y-shaped division is the exception, not the rule, Ramón y Cajal, von Kölliker, von Lenhossék, and van Gehuchten have never met with fibres which do not bifurcate. A successful Golgi preparation studied in longitudinal section through the zone of entrance is very convincing (Fig. 303). The fine fibres of the lateral bundles undergo Y-shaped

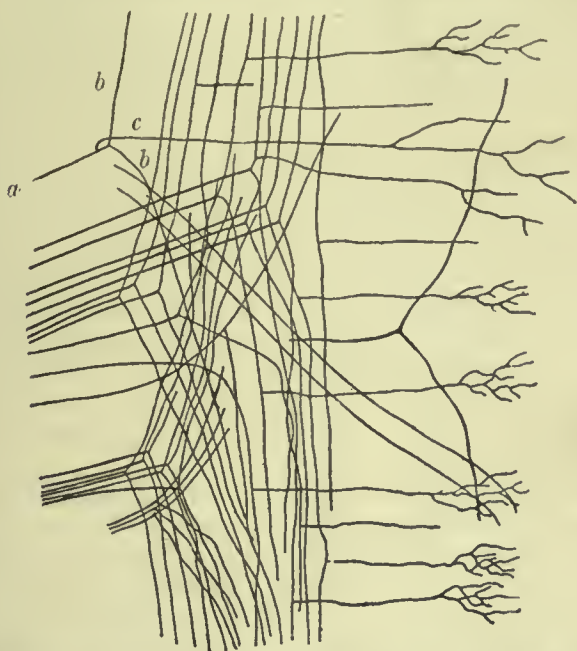


FIG. 303.—Entrance of the fibres of the dorsal roots into the dorsal funiculus of the spinal cord of an embryo calf. (After A. van Gehuchten, *Anatomie du système nerveux de l'homme*, Louv., 2. ed., 1897, p. 302, Fig. 205.) A stem fibre, *a*, is seen dividing into two branches, *b*, *b*, the ascending and descending limbs of bifurcation. From the stem fibre, *a*, a collateral, *c*, is seen to arise. A number of collaterals arising from the limbs of bifurcation of other fibres are illustrated.

division nearly all at the same spot, but the coarse fibres of the medial bundle undergo division in very different parts of the entry-zone. In the human embryo many of the fibres of the lateral portion divide first after entrance into the substantia gelatinosa, and these divisions in part pass backward out of the substantia gelatinosa into the dorsal funiculi again; certain others of the

divisions run up and down perpendicularly in the so-called longitudinal bundle of the dorsal horn. As regards calibre, the ascending limbs and descending limbs differ much. Von Lenhossék describes the ascending limb as being often coarse and thick, while the descending limb may be very delicate, sometimes resembling a collateral branch. Von Kölliker, on the contrary, could not convince himself of any constant difference in the calibre of the two limbs. Studies with the method of vital staining with methylene blue have taught Ramón y Cajal that as a rule the two limbs are of equal thickness, but that in from ten to fifteen per cent. of the fibres the size differs essentially, and then, as a rule, it is the descending limb that is the finer.

As regards the course of the ascending and descending limbs after division, this differs according as a fibre belongs to the lateral bundle or to the medial bundle, and indeed varies for the fibres of the same bundle. The ascending limb of a lateral fibre runs upward in the marginal zone of Lissauer for a greater or less distance. All the fibres in Lissauer's fasciculus are, however, relatively short. Some of the fibres, as mentioned above, run upward in the white matter of the dorsal horn. The descending limb of the lateral fibre runs only a short distance below the point of bifurcation before terminating in the gray matter.

The ascending limb of a fibre of the medial bundle runs upward in the cuneate fasciculus of Burdach; it may be short, running in to terminate soon in the gray matter; or it may be longer, passing up many segments of the cord before terminating; again, it may, if it form one of the longest fibres, reach even the medulla oblongata to terminate in the nuclei of the dorsal funiculi situated there (Fig. 304); or it may even go past these nuclei without stopping to enter the cerebellum by way of the corpus restiforme. Unfortunately, thus far it has been impossible to follow in sections prepared by Golgi's method a given fibre for a distance of more than a few segments of the cord, but in view of the combined results obtained with Golgi's method and from secondary degeneration this statement must be held to be correct.

The termination of the fibres has been studied very carefully. They bend in at various levels at right angles to enter the substantia gelatinosa beyond which they divide into a number of



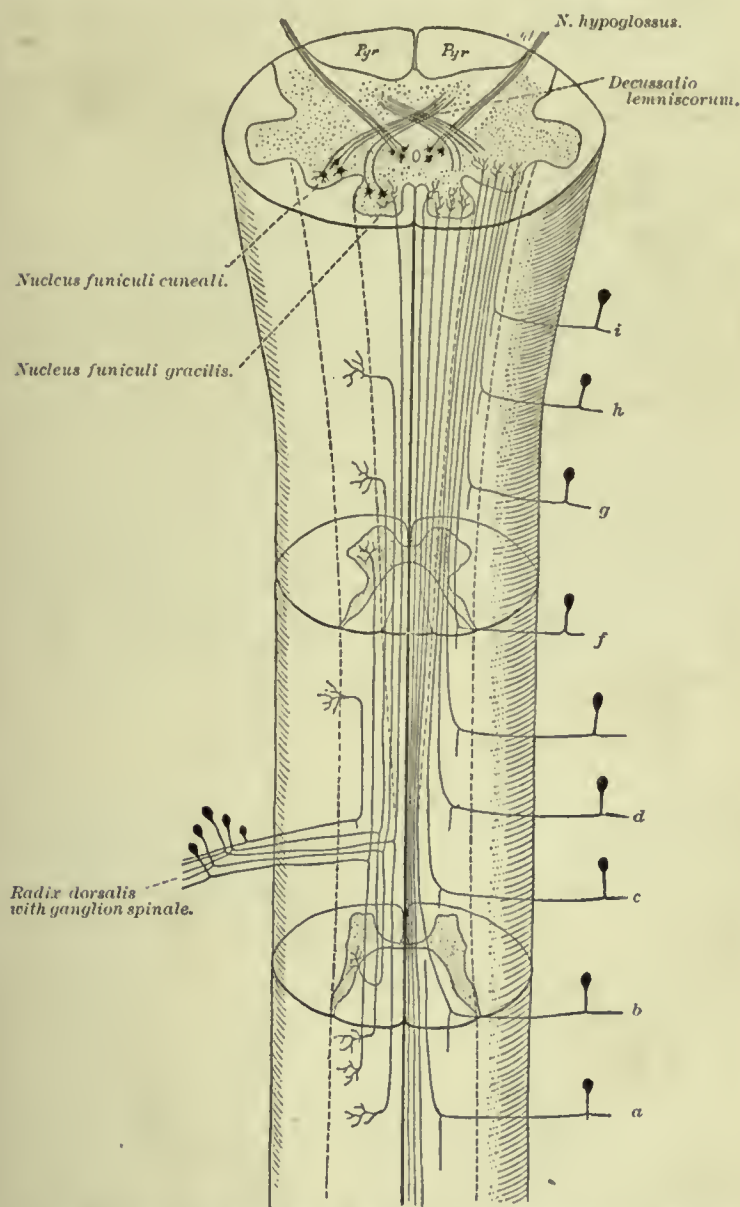


FIG. 304.—Scheme indicating the course followed by the central axones of the peripheral spinal centripetal neurones in the dorsal funiculi of the spinal cord. (After A. van Gehuchten, *Anatomie du système nerveux de l'homme*, 2. éd., Louv., 1897, p. 303, Fig. 206.) On the left side of the figure are shown shorter and longer axones of a single dorsal root; on the right side the relative positions of the long fibres from a whole series of dorsal roots (*a, b, c, d, . . . i*) are indicated; only a single cell of each ganglion is drawn.

fine branches which run ventralward, exhausting themselves by multiple division and ending, just as do the collaterals, in various regions of the gray matter of the cord. Those that run as far as the medulla before terminating end in the same way in the nucleus funiculi gracilis or nucleus funiculi cuneati. Those entering the cerebellum are believed to follow the general course of the fibres of the corpus restiforme.

The form, course, grouping, and terminal distribution of the collaterals (since their discovery in 1881 by Golgi and the demonstration of their large number and great significance by Ramón y Cajal) have been studied by nearly all investigators who have worked with Golgi's method (Fig. 305). As a result we have now very definite information concerning these fine branches. They are best studied in longitudinal sections where they can be seen arising by little wedge-shaped processes, sometimes from the main axone of the spinal ganglion cell before its bifurcation, but more often from the ascending and descending limbs which result from the Y-shaped division. In the medullated fibre the origin of the collateral appears to correspond always to a node of Ranvier. Not only do the fibres of the dorsal roots always bifurcate at a node of Ranvier, but the collaterals are always given off at such nodes. It is interesting to note that the collaterals have recently been demonstrated in the spinal cord by Ramón y Cajal \* with the methylene-blue method.

The total number of collaterals given off from a single dorsal root fibre is unknown, but may probably be very large. In calibre each collateral is much finer than the axone from which it has its origin unless we except the ultimate terminal branch of the axone which, as von Lenhossék suggests, may not improperly be looked upon as the last collateral given off by an axone. The collateral runs, as a rule, almost at right angles to the fibre from which it arises, passing straight or in a curved direction ventralward into the gray matter. That the cytoproximal portion of the fibre possesses many more collaterals than the cytodistal portion, at least as far as the ascending limb is concerned, is made very probable by von Lenhossék's studies, since he has

---

\* Ramón y Cajal, S. Los colaterales y bifurcaciones de las raíces posteriores de la médula espinal, demostradas con el azul de metileno. Rev. de clín., terap. y farm., Madrid, t. x (1896-'97), pp. 3-8; also, El azul de metileno en los centros nerviosos. Rev. trimest. microg., Madrid, vol. i, pp. 151-203.

never been able to discover collaterals coming off from the fibres constituting the fasciculus gracilis.\* This inequality of differ-

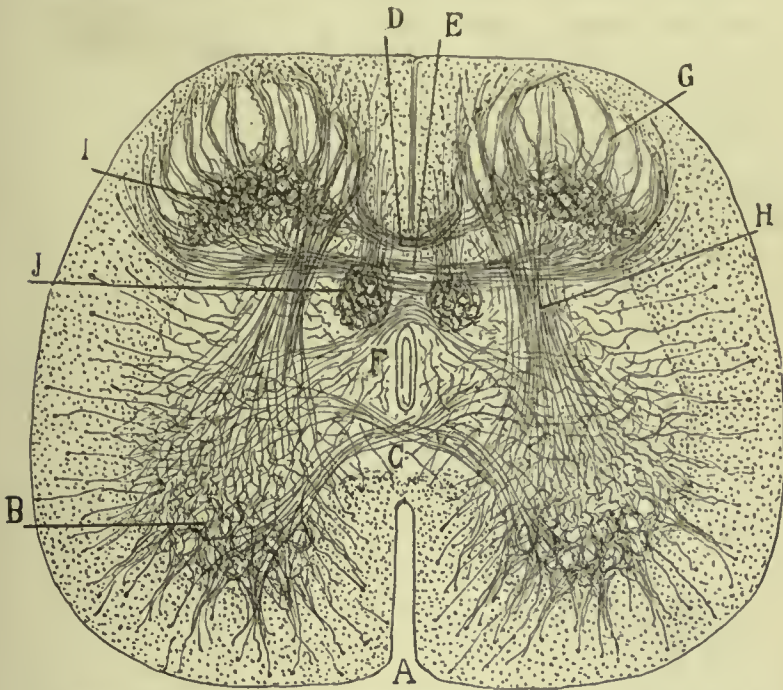


FIG. 305.—Cross section through the spinal cord of a newborn babe, to show the collaterals. (After S. Ramón y Cajal, Arch. f. Anat. u. Physiol., Anat. Abth., 1893, S. 328, Fig. 3.) A, sulcus ventralis; B, pericellular branches of the collaterals from the ventral funiculus; C, collaterals of the ventral commissure; D, dorsal bundle of the dorsal commissure; E, middle bundle of the dorsal commissure; F, ventral bundle of the dorsal commissure; G, fibril bundles of the dorsal funiculus which arise from its summit; H, sensorimotor or reflex collaterals; I, Waldeyer's "nucleus" of the dorsal horn; J, nucleus dorsalis Clarkii receiving a distinct group of collaterals.

ent portions of the fibre as regards the origin of collaterals in all probability explains the varying richness of the different re-

\* In contrast with von Lenhossék's statements may be mentioned the findings of Schaffer (Beitrag zur Histologie der secundären Degeneration; zugleich ein Beitrag zur Rückenmarksanatomie. Arch. f. mikr. Anat., Bonn, Bd. xliii (1894), S. 252-266), who found by Marchi's method degenerated fibres extending from the level of the lower thoracic cord all the way up to the medulla in the fasciculus cuneatus giving off at all levels degenerated collaterals which radiated into the ventral horns. It is perhaps possible that he has mistaken terminals for collaterals.

gions of the dorsal funiculi in collaterals which is shown in both transverse and longitudinal sections. The grouping of the collaterals in animals shows some minor differences from those found in human specimens. According to von Lenhossék, whose

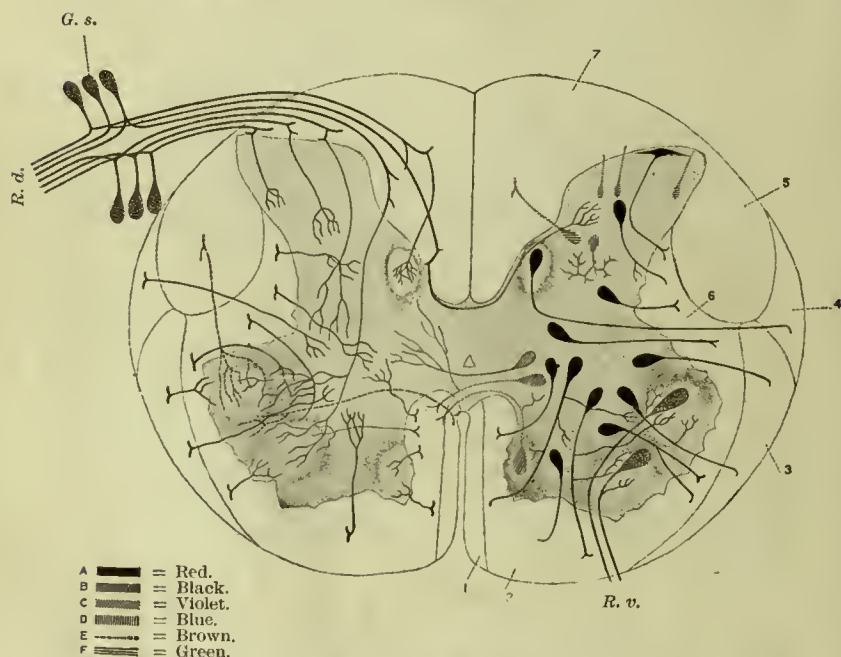


FIG. 306.—Scheme of the structure of the spinal cord; nerve cells in the left half of the cord; collaterals shown in the right half of the cord. (After M. von Lenhossék, *Der feinere Bau des Nervensystems*, etc., 2. Aufl., Berl., 1895, Taf. vi.) Left half of the cord, black cells are motor; side fibrils are seen arising from their axones; red cells are tautomer neurons, the axones going to the ventral and lateral funiculi. Among these are the cells in the nucleus dorsalis and some cells in the substantia gelatinosa of Rolando; collaterals are coming off from the axones. Violet cells are commissural cells or heteromeric neurones; one is seen sending its axone into the gray substance of the other side; the others send their axones to the white matter of the opposite side. The green cells send their axones to the dorsal funiculi. In blue is seen represented a Golgi cell of Type II, or dendraxone. In the right half of the cord the black cells represent the cell bodies of peripheral sensory neurones situated in the ganglion spinale; their central prolongations are shown entering the spinal cord as dorsal-root fibres, which bifurcate and send collaterals to terminate in various parts of the substantia grisea. Thus the reflex collaterals are seen going to the ventral horn; other collaterals enter the nucleus dorsalis; some pass through the dorsal commissure to the dorsal horn of the opposite side. The red collaterals come from the white fibres in the ventral and lateral funiculi; the lilac collaterals belong to the axones of heteromeric neurones; the brown collaterals and terminals represent fibres from the fasciculi cerebrospinales or pyramidal tract. 1, fasciculus cerebrospinalis ventralis; 2, fasciculus ventralis proprius; 3, fasciculus ventrolateralis Gowersi; 4, fasciculus cerebellospinalis; 5, fasciculus cerebrospinalis lateralis; 6, fasciculus lateralis proprius; 7, funiculus dorsalis; *R. v.*, radix ventralis; *R. d.*, radix dorsalis; *G. s.*, ganglion spinale.



careful studies of the cord have furnished us with a wealth of data concerning them, the collaterals in human beings may be classified as follows (Fig. 306):

*Collaterals ending in Dorsal Horns and Middle Part of Substantia Grisea.*—(a) Meridian bundles passing through Rolando's substance (not including those which are most medially placed and which are reflex collaterals). These give rise in the gray matter to that fine complex of delicate medullated fibres known in the bibliography as "Waldeyer's nucleus of the dorsal horn." They probably stand in conduction relation to the small nerve cells situated there.

(b) Collaterals arising from the fasciculus cuneatus medial to Rolando's substance from the same area which gives rise to the reflex collaterals (*vide infra*), although much less numerous than these. They turn transversely lateralward to terminate in end-arborizations among the cells of the central part of the dorsal horn.

(c) Collaterals from the most ventral part of the fasciculus cuneatus passing into the dorsal horns. These stain brown with Golgi's method, quite differently from the other groups of collaterals. They go past the nucleus dorsalis but enter into no relation with its cells.

(d) Collaterals which end in the substantia gelatinosa of Rolando, few in number and extremely fine. Origin not clear.

*Collaterals ending in Ventral Horns of Gray Matter.*—This group includes the majority of those irregular bundles seen in Weigert sections passing in from the cuneate fasciculus of Burdach partly ventro-medial to the substance of Rolando, partly through the medial half of this substance, forming S-shaped curves in the gray substance and passing ventralward directly into the ventral horns (*Ab schnürungs bündel* of Schwalbe, *Bogen bündel* of Redlich). These bundles are largest in the intumescensæ of the cervical and lumbar regions. They arise always in the sickle-shaped field of the fasciculus cuneatus in the region before spoken of as the "entry-zone."\* The collaterals of this group are the largest in the human cord. They can be divided into two sub-groups: (1) The main mass passing in fanlike convergence from the fasciculus cuneatus into the gray substance through the narrow space just ventro-medial to the medial angle of the substantia gelatinosa of Rolando, immediately behind the point of bending of the margin of the dorsal horn. They are joined here by the second group, (2)

---

\* Pierret's *Bandelettes externes*; Strümpell's *Wurzelzone*; Westphal's *Wurzeleintrittszone*; von Bechterew's *Grundbündeln der Hinterstränge*; Flechsig's *vordere Wurzelzone*; von Lenhossék's *Einstrahlungszone* or *Reflexkollateralenzone*.

consisting of a number of bundles less closely arranged which arise nearer the point of entrance of the dorsal roots into the cord in the lateral region of the fasciculus cuneatus dorsal to Rolando's substance. They have to penetrate the substantia gelatinosa before uniting with the main group ventral to this substance. All these collaterals (*Reflexkollateralen* of von Kölliker, *Manejo sensitivo-motor* of Ramón y Cajal) spread out into the ventral horn, calyx fashion, and exhaust themselves by multiple division in among the cell bodies, dendrites, and side fibrils of the lower motor neurones. On their way forward they give off side twigs which come in contact with cells of the dorsal horns. The curious behavior of these collaterals in the mouse and rabbit where the contact relations are mainly with the side fibrils of ventral horn cells has been referred to above (Section V). Bethe's "fundamental experiment" (see page 272) is also interesting in this connection.

*Collaterals ending in the Nucleus Dorsalis (Clarkii, Stillin-  
gi).*—This very important group of collaterals has its origin exclusively in the middle area of the fasciculus cuneatus, never from the fasciculus gracilis. The dark color of Clarke's nucleus in Weigert specimens is due to the presence in it of large numbers of medullated collaterals (and terminals) of dorsal root fibres. The bundles of collaterals pass into the gray matter and reach the dorsal side of the nucleus, where they split into two divisions, one of which passes to each side of the nucleus, so that in cross sections the nucleus reminds one of a berry on a stem or, if one will think of the structure in three dimensions, the long nucleus dorsalis can be thought of as a log lying in a trough. They form by their multiple divisions baskets about the individual cells of the nucleus, each fibre coming into contact with the bodies and dendrites of several cells. In beginning tabes, specimens stained by Weigert's method often show that these fine feltworks of medullated collaterals in the nucleus dorsalis are, along with Lissauer's marginal zone, the first elements to disappear.

*Collaterals going into the Dorsal Commissure of the Spinal Cord.*—The dorsal commissure in most animals is made up mainly of sensory collaterals. Von Lenhossék states that in human beings it is composed exclusively of such fibres. They have their origin in the most ventral part of the fasciculus cuneatus on the dorsal border of the gray commissure. They appear to end in the opposite dorsal horn, spreading out in a bushlike fashion ventral to the medial portion of Rolando's substance, where they break up into end arborizations.

No collaterals from the dorsal root fibres or dorsal fasciculi have

been traced through the ventral commissure.\* Whatever *direct* decussation occurs in the domain of the peripheral sensory neurone is accounted for, therefore, by the sensory collaterals forming the dorsal commissure. That such a feeble mass of fibres can account for the sensory decussations of the physiologists no one can suppose. This sensory decussation must much rather be explained, therefore, by the assumption of crossing of the axones of centripetal neurones of the second order or of higher orders (*vide infra*).

As to the actual *terminals of the axones* of the dorsal root fibres, they behave just as do the collaterals running in to end in the different portions of the gray matter of the cord and medulla. There is an important gap in our knowledge in one particular. We do not certainly know as yet whether or not the terminals of fibres of different length have specific, that is to say non-homologous, end stations. Should the affirmative be proved, the importance of such a fact for physiology and pathology is obvious.

We have now described the spinal peripheral sensory neurones as far as they are known in their entirety, including the bodies of the spinal ganglion cells, their peripheral prolongation, the nerve endings on the surface of the body and in the organs, and finally the central prolongations of the spinal ganglion cells, their Y-shaped divisions, the course and termination of the ascending and descending limbs, as well as the origin and distribution of the collaterals given off from their various parts. When we think of individual neurones of this group, for example, a neurone corresponding to one of the sacral roots whose peripheral process collects through a large number of divisions impressions from the lower extremity, perhaps even from the sole of the foot, while its central prolongation, leaving the spinal ganglion and entering the spinal cord in the lumbar region, gives off collateral branches to the nerve cells in the cord of that region, while its main ascending division passes up through the whole length of the spinal cord to terminate in the nucleus funiculi gracilis of the medulla oblongata,† giving

---

\* Mingazzini (Sulla fina struttura del midollo spinale dell' uomo. Riv. sper. di freniat., Reggio-Emilia, vol. xviii (1892), fasc. ii, Fig. i) has pictured collaterals which he assumes to be sensory passing through the ventral commissure; but v. Lenhossék denies the existence of any such fibres, and v. Kölliker agrees with him.

† Possibly even in the cortex of the cerebellum.

off on its way very many collaterals to very different segments of the cord, we see at a glance the marvellous distribution of which an individual cell is capable. It is doubtful if anywhere else in the animal kingdom a greater extension or a more manifold contact relationship is met with in any cell. Each spinal neurone may be thought of with the spinal ganglion cell as its centre, having a fanlike distribution of each process, the peripheral fan collecting impressions, the central fan giving off impulses to the various sensory end stations with which the fibre, by means of its terminals and collaterals, comes into conduction relation. The sum total of all the sensory end stations in the spinal cord and medulla, as has been seen, includes practically all regions of the gray matter.\*

---

\* In one sense the so-called motor areas of the cord are also in part the primary end stations of the peripheral centripetal conduction paths. The efforts which have constantly been made to separate centripetal from centrifugal paths have nearly always gone too far. Centripetal and centrifugal paths form parts of units of which the centripetal path is one limb, while the centrifugal path is the other. As far as present knowledge warrants, this relation holds good not only for the lowest centres, but also, though in more complex form, throughout the whole nervous system.



## CHAPTER XXXV.

### PERIPHERAL CEREBRAL CENTRIPETAL NEURONES COLLECTING BODILY IMPRESSIONS.

Those pertaining to the nervus vagus and nervus glossopharyngeus—Those pertaining to the nervus vestibuli—Those pertaining to the nervus intermedius—Those pertaining to the nervus trigeminus.

#### 2. Centripetal Neurones of the First Order (collecting Bodily Impressions) connected with the Rhombencephalon.

THE peripheral centripetal or sensory neurones of the cerebral nerves collecting impressions from the head and neck and from some of the internal organs, agree in general in their form and relations with what has been described as characteristic of the peripheral spinal centripetal neurones. The cell bodies of these cerebral peripheral sensory neurones are situated in the ganglia on the cerebral nerves. Their peripheral prolongations pass to the surface of the body and to the organs with which these nerves are connected, where they also exhibit the various nerve endings (*corpuscula nervorum terminalia*) mentioned before. The central prolongations pass into the brain stem, and, as von K  lliker showed, bifurcate, afterward running out into their terminals in the gray matter very much as do the dorsal root fibres on entrance into the cord. We have here to consider the sensory portions of the nervus vagus, nervus glossopharyngeus, nervus vestibuli, nervus intermedius, and nervus trigeminus. In their development the cerebral peripheral sensory neurones resemble closely the spinal sensory neurones of the first order (Fig. 307).

In order to make clear the relations of these nerves to their nuclei terminales in the central nervous system, there are introduced here a number of sections taken at various levels from two unbroken sets of serial sections of the brain stem of a new-

born babe (Figs. 308-324). The central prolongations of the unipolar ganglion cells of the *nervus vagus* (ganglion jugulare and ganglion nodosum), together with those of the ganglion cells of the *nervus glossopharyngeus* (ganglion superius and ganglion petrosum), enter the medulla oblongata mixed with

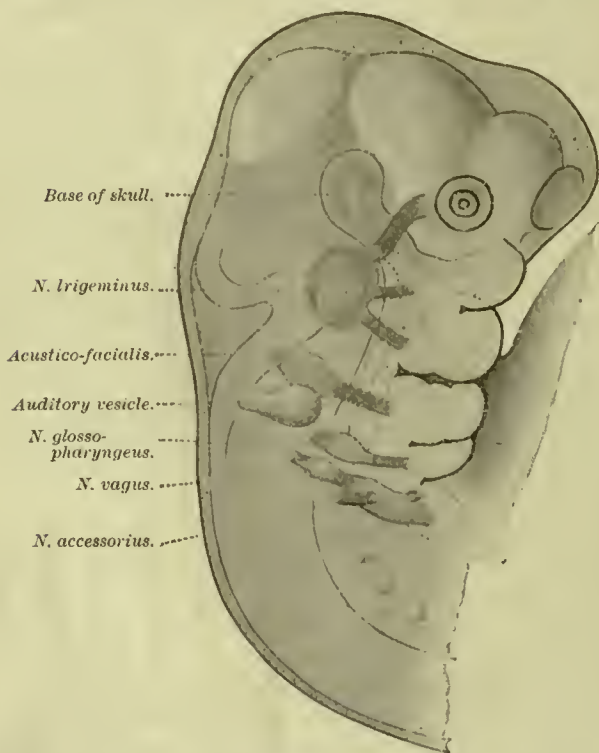


FIG. 307.—The developing cerebral nerves; head of a human embryo 10 mm. long. (After W. His, from Kollmann's text-book.)

the motor fibres of these nerves, just making their exit, at the dorso-lateral sulcus (sulcus lateralis dorsalis). The sensory root fibres of these nerves do not all enter at one spot in a compact mass, but make a number of small bundles which pass into the central system at several points along the sulcus (Figs. 320 and 321). In the new-born child the linear extent of entrance measures about .6 cm. (Fig. 325). The medullated fibres plunge through the tractus spinalis nervi trigemini and the adjacent substantia gelatinosa, going obliquely in the dorso-medial direction

toward the nuclei of reception (nucleus alae cinereae and nucleus tractus solitarii) of these nerves near the floor of the fourth ventricle. There is no bifurcation of the sensory fibres immediately

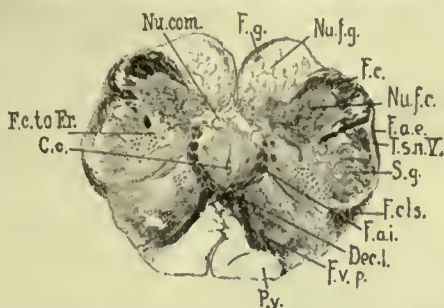


FIG. 308.—Transverse section through medulla oblongata of newborn child at level of decussation lemniscorum. (Series ii, section No. 50.) *C.c.*, canalis centralis; *Dec.l.*, decussatio lemniscorum; *F.a.i.*, fibrae arcuatae internae; *F.a.e.*, fibrae arcuatae externae; *F.c.*, fasciculus cuneatus Burdachi; *F.c.to Er.*, bundles from fasciculus cuneatus to formatio reticularis; *F.cls.*, fasciculus cerebellospinalis or direct cerebellar tract; *F.g.*, fasciculus gracilis Golli; *F.r.p.*, fasciculus ventralis proprius; *Nu.com.*, nucleus commissuralis; *Nu.f.c.*, nucleus funiculi cuneati et gracilis; *Nu.f.g.*, nucleus funiculi gracilis; *Py.*, pyramis; *T.s.n.V.*, tractus spinalis N. trigemini; *S.g.*, substantia gelatinosa [Rolandi]. (Weigert-Pal preparation by Dr. John Hewetson.)

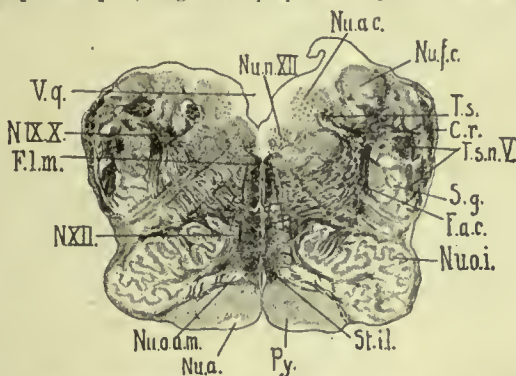


FIG. 309.—Transverse section of medulla oblongata of newborn child passing through the nucleus olivaris inferior. (Series ii, section No. 102.) *C.r.*, corpus restiforme; *F.a.e.*, fibrae arcuatae externae from the anterior half of the nucleus funiculi cuneati; *F.l.m.*, fasciculus longitudinalis medialis; *N.IX.X.*, N. glossopharyngeus et vagus; *N.XII.*, N. hypoglossus; *Nu.a.*, nucleus arcuatus; *Nu.a.c.*, nucleus alae cinereae; *Nu.f.c.*, nucleus funiculi cuneati; *Nu.o.a.m.*, nucleus olivaris accessorius medialis; *Nu.o.i.*, nucleus olivaris inferior; *Nu.n.XII.*, nucleus N. hypoglossi; *Py.*, pyramis (non-medullated); *S.g.*, substantia gelatinosa Rolandi; *St.il.*, stratum interolivare lemnisci; *T.s.*, tractus solitarius; *T.s.n.V.*, tractus spinalis N. trigemini; *V.q.*, ventriculus quartus. (Weigert-Pal preparation by Dr. John Hewetson.)

after entrance, a fact which is not surprising when the histogenetic relations discussed in Section IV are recalled. The bifurca-





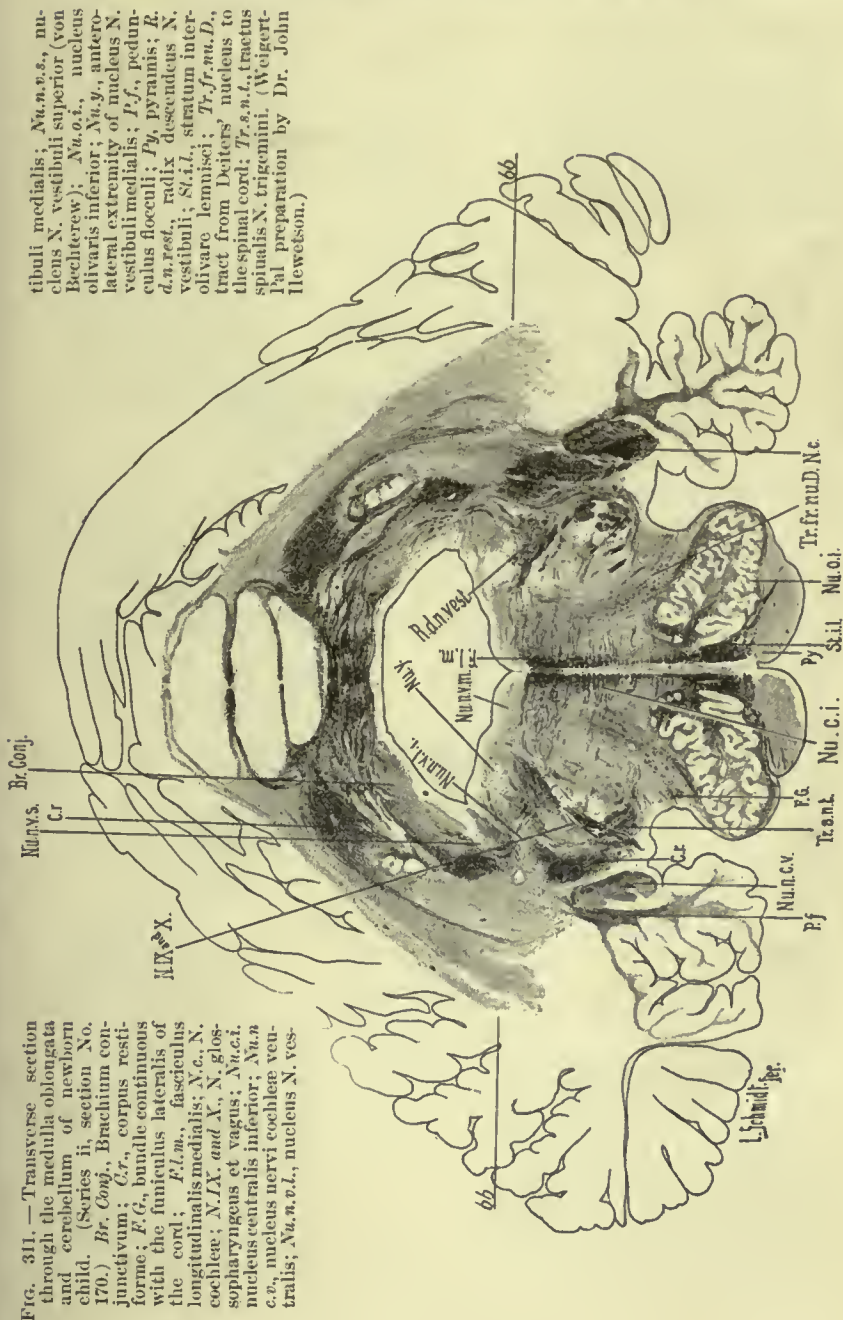


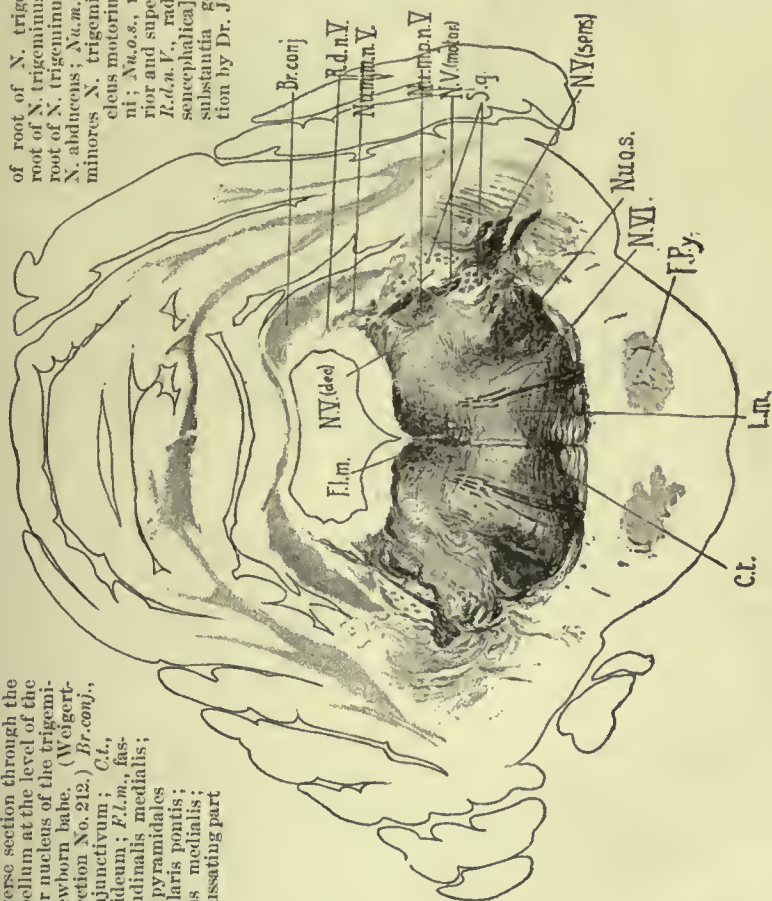FIG. 311. — Transverse section through the medulla oblongata and cerebellum of newborn child. (Series ii, section No. 170.) *Br. Conj.*, Brachium conjunctivum; *C.r.*, corpus restiforme; *F. G.*, bundle continuous with the funiculus lateralis of the cord; *F. L. m.*, fasciculus longitudinalis medialis; *N. c.*, N. cochleæ; *N. L. X.* and *X.*, N. glossopharyngeus et vagus; *Nu. c. i.*, nucleus centralis inferior; *Nu. n. c. v.*, nucleus nervi cochleæ ventralis; *Nu. n. v. l.*, nucleus N. ves-

tibuli medialis; *Nu. n. v. s.*, nucleus N. vestibuli superior (von Bechterew); *Nu. o. i.*, nucleus olivaris inferior; *Nu. y.*, anterolateral extremity of nucleus N. vestibuli medialis; *P. f.*, pedunculus flocculi; *Py.*, pyramis; *R. du. ves.*, radix descendens N. vestibuli; *St. il.*, stratum interolivare lemnisci; *Tr. fr. ru. D.*, tract from Deiters' nucleus to the spinal cord; *Tr. s. n. l.*, tractus spinalis N. trigemini. (Weigert-Pal preparation by Dr. John Hlewson.)



FIG. 313.—Transverse section through the pons and cerebellum at the level of the principal motor nucleus of the trigeminal nerve. Newborn babe. (Weigert-Pal, series ii, section No. 212.) *Br.conj.*, brachium conjunctivum; *Cl.*, corpus trapezoidale; *F.L.m.*, fasciculus longitudinalis medialis; *F.Py.*, fasciculi pyramidales in the pars basilaris pontis; *L.m.*, lemniscus medialis; *N.V.(dec.)*, decussating part

of root of *N. trigeminus*; *N.V.(motor)*, root of *N. trigeminus*; *N.V.(sens.)*, sensory root of *N. trigeminus*; *N.V.L.*, root fibres of *N. abducens*; *Nu.m.a.n.V.*, nuclei motorii minores *N. trigemini*; *Nu.m.p.a.V.*, nucleus motorius princeps *N. trigemini*; *Nu.o.s.*, nucleus olivaris superior and superior olivary complex; *R.d.a.V.*, radix descendens [mesencephalica] *N. trigemini*; *S.g.*, substantia gelatinosa. (Preparation by Dr. John Hewetson.)



alæ cinereæ divide in the bundles near this nucleus, the rest of the fibres inside it. The fibres entering the tractus solitarius undergo division, but not all at the same level.

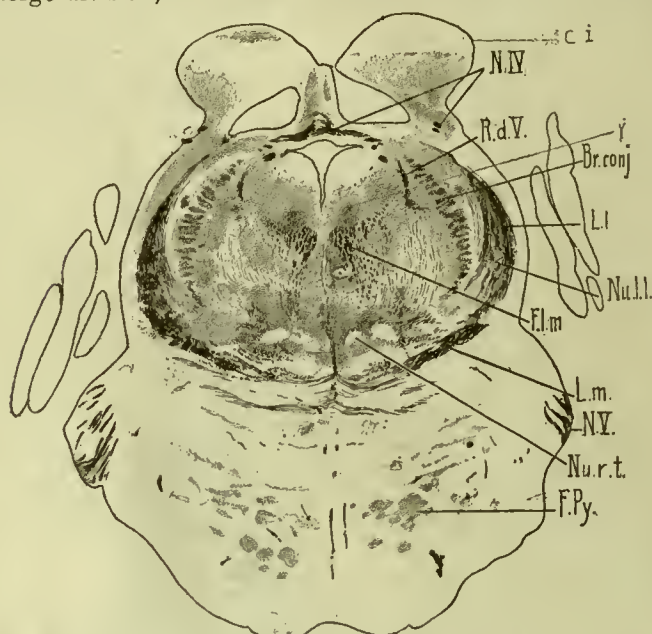


FIG. 314.—Transverse section through isthmus rhombencephali of newborn babe. (Weigert-Pal, series ii, section No. 268.) *Br.conj.*, brachium conjunctivum; *C.i.*, colliculus inferior; *γ*, nucleus described by Westphal\* as probably concerned in the origin of the N. trochlearis; *F.l.m.*, fasciculus longitudinalis medialis; *F.Py.*, fasciculi longitudinales [pyramidales]; *L.l.*, lemniscus lateralis; *L.m.*, lemniscus medialis; *N.IV.*, decussatio nervorum trochlearium; *N.V.*, N. trigeminus; *Nu.l.l.*, nucleus lemnisci lateralis; *Nu.r.t.*, nucleus reticularis tegmenti pontis; *R.d.V.*, radix descendens [mesencephalica] nervi trigemini. (Preparation by Dr. John Hewetson.)

The figure copied from Held (Fig. 326) shows root fibres dividing, one branch passing to the nucleus alæ cinereæ, the other descending in the tractus solitarius. These descending fibres give off collaterals (Fig. 327) and terminals, to end in the adjacent gray matter (nucleus tractus solitarii). Ramón y Cajal denies the existence of typical bifurcations (at least for the majority of root fibres of N. IX and N. X), and thinks that

\* Westphal, C. Ueber einen Fall von chronischer progressiver Lähmung der Augenmuskeln (Ophthalmoplegia externa) nebst Beschreibung von Ganglienzellengruppen im Bereiche des Oculomotoriuskerns. *Arch. f. Psychiat. und Nervenkr.*, Berl., Bd. xviii (1887), S. 858.



these fibres, disobeying the general law of dichotomy, are devoid of ascending limbs, all the fibres turning down in the tractus solitarius. The fibres entering the nucleus alæ cinereæ, which in the mouse is continuous with the nucleus tractus solitarii, he looks upon as collaterals. The general course of the tractus solitarius is best studied in horizontal sections of the baby's medulla stained by the Weigert-Pal method (Fig. 328). In its

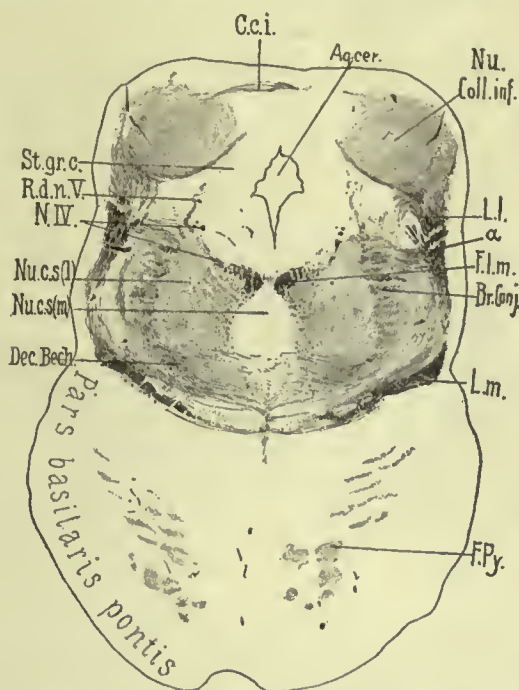


FIG. 315.—Transverse section through brain of newborn babe. Level of colliculi inferiores corpora quadrigemina. (Weigert-Pal, series ii, section No. 290.) *Aq.cer.*, aqueductus cerebri;  $\alpha$ , fibres running from lateral lemniscus toward dorsal border of brachium conjunctivum; *Br. Conj.*, brachium conjunctivum; *C.c.i.*, commissure between the colliculi inferiores; *Dec.Bech.*, ventral portion of brachium conjunctivum, which in reality forms a commissure between the superior nuclei of the vestibular nerves of the two sides; *F.l.m.*, fasciculus longitudinalis medialis; *F.Py.*, fasciculi longitudinales pontis (pyramidales); *L.I.*, lemniscus lateralis in large part terminating in the nucleus of the colliculus inferior; *L.m.*, lemniscus medialis; *N.IV.*, N. trochlearis; *Nu.Coll.inf.*, nucleus colliculi inferioris; *Nu.cs.(l)*, nucleus centralis superior, pars lateralis; *Nu.cs.(m)*, nucleus centralis superior, pars medialis; *R.d.n.V.*, radix descendens [mesencephalica] N. trigemini; *St.gr.c.*, stratum griseum centrale. (Preparation by Dr. John Hewetson.)

passage spinalward it gradually approaches the median line, lying in its lower part medial to the nucleus funiculi gracilis. Its fibres

can be seen terminating at different levels in the nucleus tractus solitarii which accompanies it. The gray matter of this nucleus more or less surrounds the tract, being better developed in some places than in others. At the cephalic extremity of the tractus solitarius a mass of gray matter can be seen passing headward for a distance of 1 or 2 mm. (*Nu.tr.sol.*, Fig. 328). From the general appearance of this mass, and the character of the cells within it,

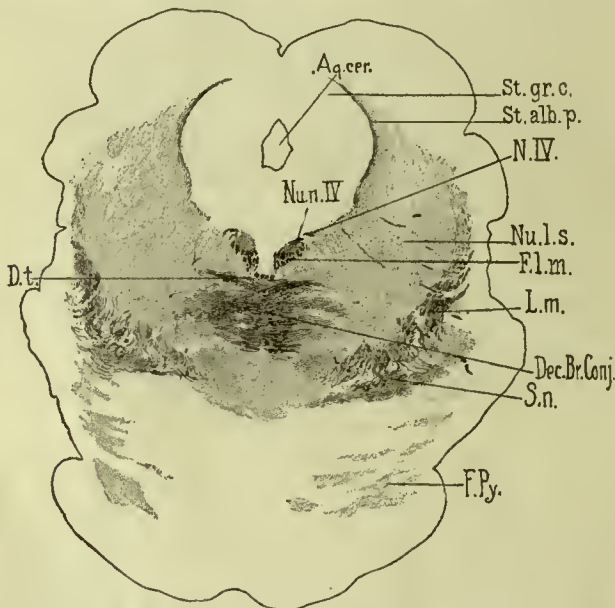


FIG. 316.—Transverse section through mesencephalon of newborn babe. Level of colliculi superiores of corpora quadrigemina. (Weigert-Pal, series ii, section No. 338.) *Aq.cer.*, aqueductus cerebri; *Dec.Br.Conj.*, decussatio brachii conjunctivi; *D.t.*, decussatio tegmenti ventralis (*ventrale Haubenkreuzung* of Forel); *F.l.m.*, fasciculus longitudinalis medialis; *F.py.*, fasciculi pyramidales in the pars basilaris pontis; *L.m.*, lemniscus medialis; *N.IV.*, N. trochlearis; *Nu.l.s.*, nucleus lateralis superior of Flechsig; *Nu.n.IV.*, nucleus N. trochlearis; *St.alb.p.*, stratum album profundum; *St.gr.c.*, stratum griseum centrale; *S.n.*, substantia nigra. (Preparation by Dr. John Hewetson.)

it is probably to be regarded as an upward continuation of the nucleus tractus solitarii. The maintenance of the general calibre of the tractus solitarius as it passes spinalward renders probable the view that the majority of the stem fibres pass for a long distance spinalward, chiefly collaterals being given off in the course of the tract. In sections of the baby's medulla, at the spinal end of the tractus solitarius, there is to be made out on each side of the middle line a distinct mass of cells, evidently

connected with the tractus solitarius (*Nu.com.*, Fig. 308). It is not impossible that this corresponds to the *ganglion commissurale*, which has been described by Ramón y Cajal in the medulla of the mouse. According to him, in the mouse this nucleus forms an oval mass of cells, which extends bridgelike just dorsal to the central canal (between the ependymal cells and the gray commissure of the cervical cord). In it terminate a large number of the fibres (according to Ramón y Cajal, no less than three fourths of them) of the tractus solitarius of the opposite side, so that we have to do here with a true terminal *decussatio tractus solitarii*. The fibrils branch manifoldly, and are so numerous that the plexus formed by them is one of the most complicated met with inside the central nervous system (Fig. 329).

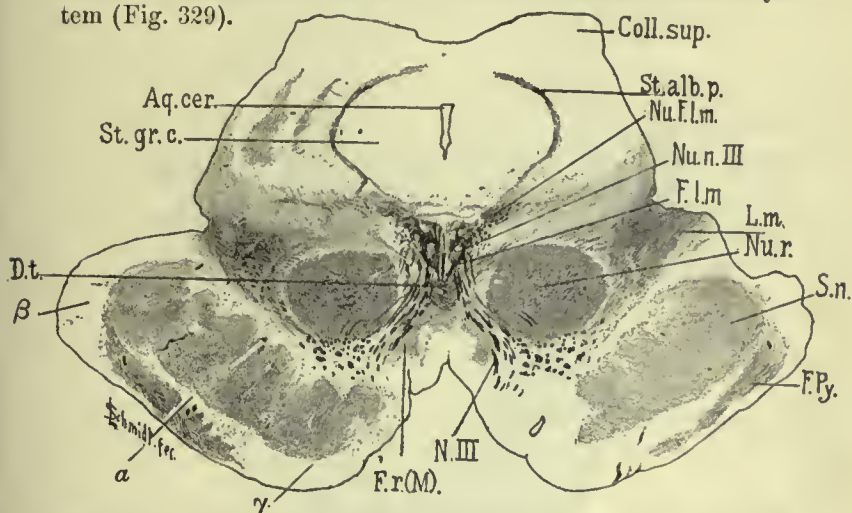


FIG. 317.—Transverse section through mesencephalon, colliculi superiores of corpora quadrigemina and cerebral peduncle of newborn baboon. (Weigert-Pal, series ii, section No. 384.) *Aq.cer.*, aqueductus cerebri; *Coll.sup.*, colliculus superior; *D.t.*, decussatio tegmenti dorsalis (*fontaineartige Haubenkreuzung* of Meynert); *F.l.m.*, fasciculus longitudinalis medialis; *F.Py.*, fasciculi pyramidales in the basis pedunculi; *Fr.(M)*, fasciculus retroflexus Meynerti; *L.m.*, lemniscus medialis; *Nu.F.l.m.*, nucleus fasciculi longitudinalis medialis or nucleus commissure posterioris (*oberer Oculomotoriuskern* of Darkschewitsch); *Nu.n.III*, nucleus N. oculomotorii; *Nu.r.*, nucleus ruber; *N.III*, N. oculomotorius; *St.alb.p.*, stratum album profundum; *St.gr.c.*, stratum griseum centrale; *S.n.*, substantia nigra; *α*, region of Flechsig's *Funnelschleife*; *β*, temporo-occipital tract to pons; *γ*, frontal tract from pallium to pons. (Preparation by Dr. John Hewetson.)

Outside the central nervous system the nervus vagus forms numerous anastomoses with the sympathetic. The relations are well shown in Fig. 330.

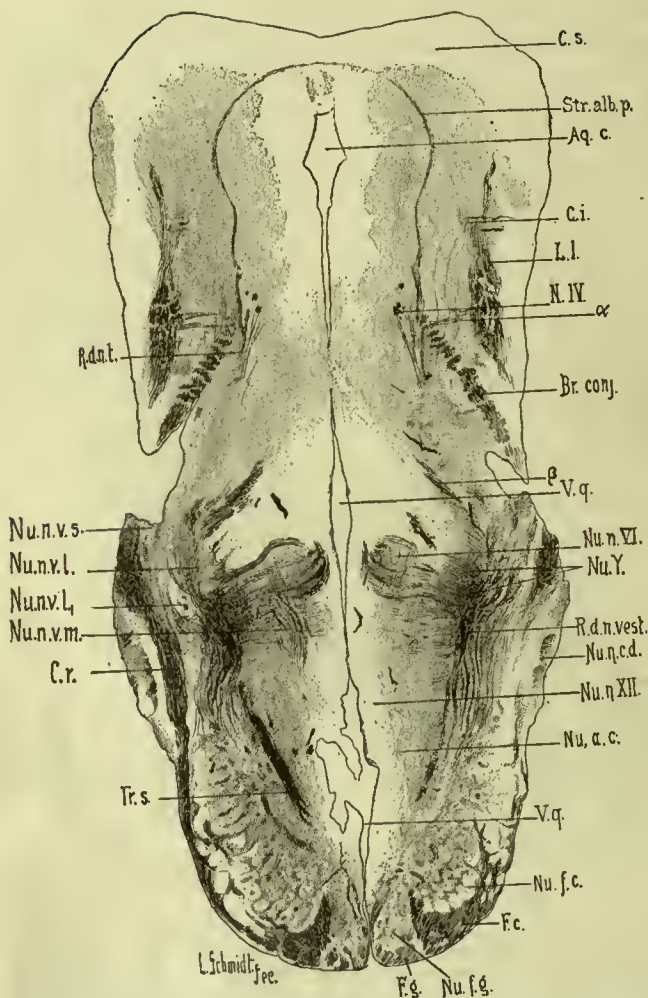


FIG. 318.—Horizontal section through the rhombencephalon and mesencephalon of a newborn babe. Level of nucleus nervi abducentis. (Weigert-Pal staining, series iii, section No. 66.) *a*, fibres running from region of lemniscus lateralis toward region of brachium conjunctivum; *Aq.c.*, aqueductus cerebri; *β*, decussating portion of root of N. trigeminus; *C.s.*, colliculus superior; *C.i.*, colliculus inferior; *Br.conj.*, brachium conjunctivum; *C.r.*, corpus restiforme; *F.c.*, fasciculus cuneatus; *F.g.*, fasciculus gracilis; *L.l.*, lemniscus lateralis; *N.IV.*, N. trochlearis; *Nu.a.c.*, nucleus alae cineræ; *Nu.f.c.*, nucleus funiculi cuneati; *Nu.f.g.*, nucleus funiculi gracilis; *Nu.n.c.d.*, nucleus N. coeblæ dorsalis; *Nu.n.VI.*, nucleus N. abducentis; *Nu.n.v.l.*, nucleus N. vestibuli lateralis (Deiters) pars medialis; *Nu.n.v.l.*, nucleus N. vestibuli lateralis (Deiters) pars lateralis; *Nu.n.v.m.*, nucleus N. vestibuli medialis (Schwalbe); *Nu.n.v.s.*, nucleus N. vestibuli superior (von Bechterew); *Nu.n.XII.*, nucleus N. hypoglossi; *Nu.Y.*, antero-lateral extremity of nucleus N. vestibuli medialis; *R.d.n.t.*, radix descendens [mesencephalica] nervi trigemini; *R.d.n.vest.*, radix descendens N. vestibuli; *Str.alb.p.*, stratum album profundum; *Tr.s.*, tractus solitarius; *V.q.*, ventriculus quartus. (Preparation by Dr. John Hewetson.)



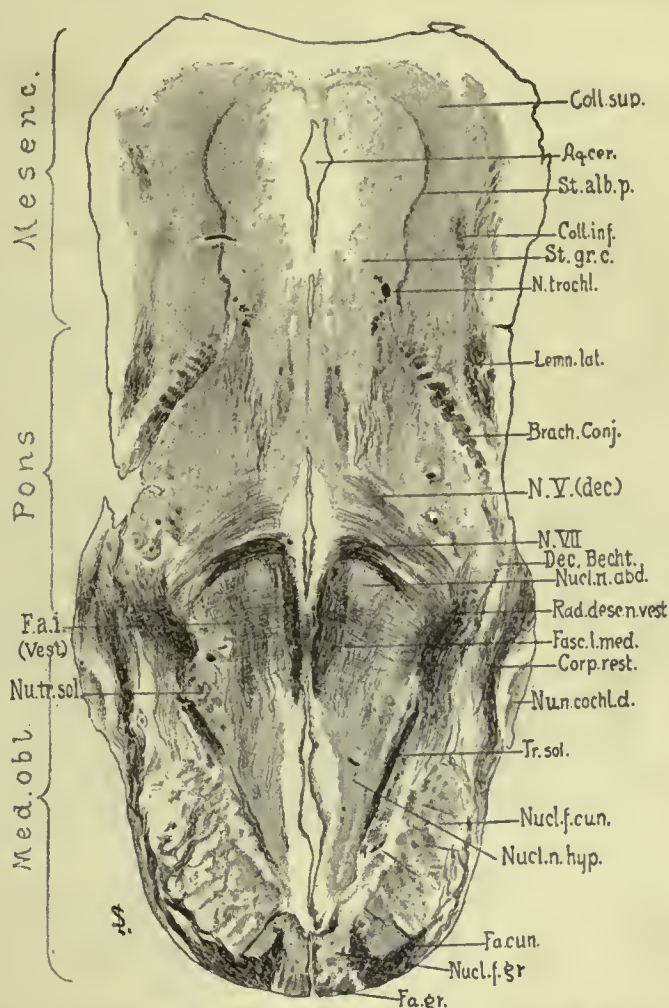


FIG. 319.—Horizontal section through the rhombencephalon and mesencephalon of a newborn babe. Weigert-Pal staining. Level of ventral part of nucleus nervi abducentis. (Series iii, section No. 72.) *Aq. cer.*, aqueductus cerebri; *Brach. Conj.*, brachium conjunctivum; *Coll. sup.*, colliculus superior; *Coll. inf.*, colliculus inferior; *Corp. rest.*, corpus restiforme; *Dec. Becht.*, fibres of ventral portion of brachium conjunctivum forming a commissure between the superior nuclei of termination of the vestibular nerves of the two sides; *Fa. cun.*, fasciculus cuneatus; *Fa. gr.*, fasciculus gracilis; *Fa. i. (Vest.)*, fibre arcuate pertaining to the central vestibular paths; *Fasc. l. med.*, fasciculus longitudinalis medialis; *Lemn. lat.*, lemniscus lateralis; *Med. obl.*, medulla oblongata; *Mesenc.*, mesencephalon; *N. trochl.*, N. trochlearis; *N. V. (dec.)*, decussating portion of the root of the N. trigeminus; *N. VII.*, radix N. facialis, pars secunda; *Nucl. f. cun.*, nucleus funiculi cuneati; *Nucl. f. gr.*, nucleus funiculi gracilis; *Nucl. n. abd.*, nucleus N. abducentis; *Nucl. n. cochl. d.*, nucleus N. cochleae dorsalis; *Nucl. n. hyp.*, nucleus N. hypoglossi; *Nutr. sol.*, nucleus tractus solitarii; *Rad. desc. n. vest.*, radix descendens N. vestibuli; *St. alb. p.*, stratum album profundum; *St. gr. c.*, stratum griseum centrale; *Tr. sol.*, tractus solitarius. (Preparation by Dr. John Howatson.)

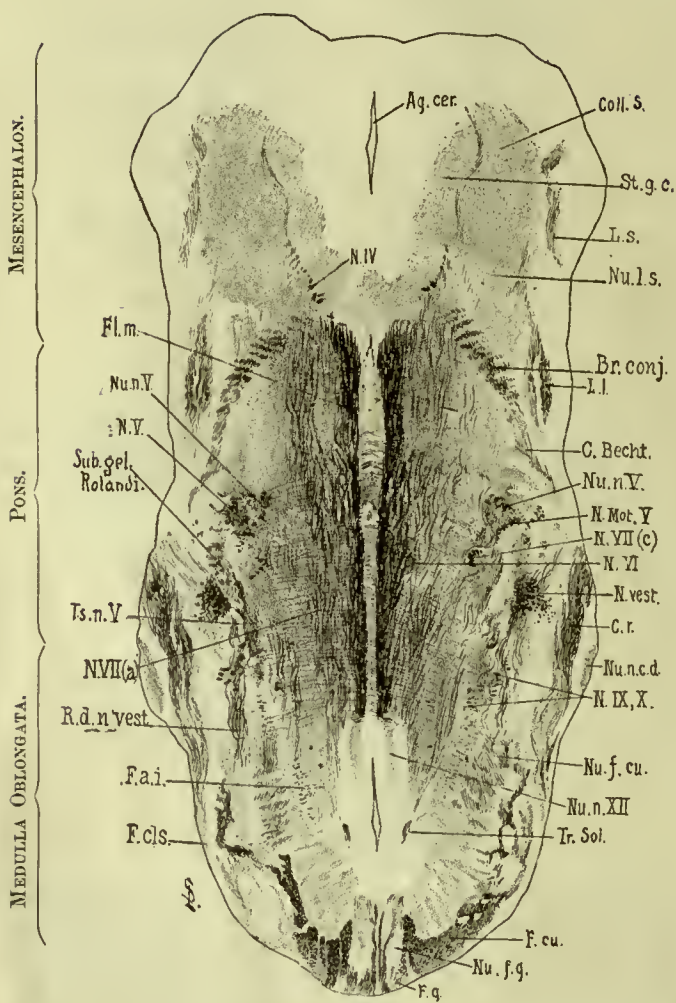


FIG. 320.

FIG. 320.—Horizontal section through the rhombencephalon and mesencephalon of the newborn babe. Weigert-Pal staining. Level of the fasciculus longitudinalis medialis. (Series iii, section No. 80.) *Aq.cer.*, aqueductus cerebri; *Br.conj.*, brachium conjunctivum; *C.Beht.*, commissure between Bechterew's nuclei of the two sides; *Coll.s.*, colliculus superior; *Cr.*, corpus restiforme; *F.a.i.*, fibre arcuata interna; *F.cls.*, fasciculus cerebellospinalis or direct cerebellar tract; *F.cu.*, fasciculus cuneatus; *F.g.*, fasciculus gracilis; *F.l.m.*, fasciculus longitudinalis medialis; *L.l.*, lemniscus lateralis; *L.s.*, lemniscus superior; *N.IV*, N. trochlearis; *N.Mot.V*, N. trigeminus, pars motorius; *N.V*, N. trigeminus; *N.VI*, radix N. abducentis; *N.VII(a)*, radix N. facialis, pars prima; *N.VII(c)*, radix N. facialis, pars secunda; *N.vest.*, N. vestibuli; *N.IX,X*, radices Nu. glossopharyngei et vagi; *Nu.f.cu.*, nucleus funiculi cuneati; *Nu.f.g.*, nucleus funiculi gracilis; *Nu.n.c.d.*, nucleus N. cochleæ dorsalis; *Nu.n.V*, nucleus N. trigemini; *Nu.n.XII*, nucleus N. hypoglossi; *Nu.l.s.*, nucleus lateralis superior of Flechsig; *R.d.n.rest.*, radix descendens N. vestibuli; *St.g.c.*, stratum griseum centrale; *Sub.gel.Rolandi*, substantia gelatinosa Rolandi; *Tr.sol.*, tractus solitarius; *T.s.n.V*, tractus spinalis N. trigemini. (Preparation by Dr. John Hewetson.)

FIG. 321.—Horizontal section through the medulla, pons, and midbrain of a newborn babe. Weigert-Pal staining. Level of nucleus nervi oculomotorii and nucleus nervi trochlearis. (Series iii, section No. 100.) *Aq. cer.*, aqueductus cerebri; *Br. conj.*, brachium conjunctivum; *Cp.*, commissura posterior cerebri; *C. Becht.*, commissure between Bechterew's nuclei of the two sides; *Cr.*, corpus restiforme; *Fl.m.*, fasciculus longitudinalis medialis; *F.c. to Fr.*, fibres from fasciculus cuneatus to formatio reticularis; *Fib. arc. int.*, fibre arcuate internæ; *F. cu.*, fasc. cuneatus; *Fr.a.*, formatio reticularis alba; *Mot. V.*, radix motorius N. trigemini; *N.V.*, radix N. abducentis; *N. rest.*, radix N. vestibuli; *N. VII(c.)*, radix N. facialis, pars secunda; *N. IX and X*, radices Nu. glossopharyngei et vagi; *N. XII*, radix N. hypoglossi; *Nu.cs.(m)*, nucleus centralis superior, pars medialis; *Nu.cs.(l)*, nucleus centralis superior, pars lateralis; *Nu.ll.*, nucleus lemnisci lateralis; *Nu.l.s.*, nucleus lateralis superior; *Nu.n. III.*, nucleus N. oculomotorii; *Nu.n. IV.*, nucleus N. trochlearis; *l.s.*, lemniscus superior; *Nu.f.g.*, nucleus funiculi gracilis; *Nu.n.cr.*, nucleus N. cochleæ ventralis; *Nu.n. VII.*, nucleus N. facialis; *S.g.*, substantia gelatinosa; *St.l.l.*, stratum interolivare lemnisci; *Sen. V.*, radix sensorius N. trigemini; *St.g.c.*, stratum griseum centrale; *Sub. gel.*, substantia gelatinosa near entrance of sensory part of N. trigeminus; *Tr.s.n.t.*, tractus spinalis N. trigemini; *Tr.fr.nu.D.*, tract from Deiters' nucleus to the spinal cord. (Preparation by Dr. John Hewetson.)



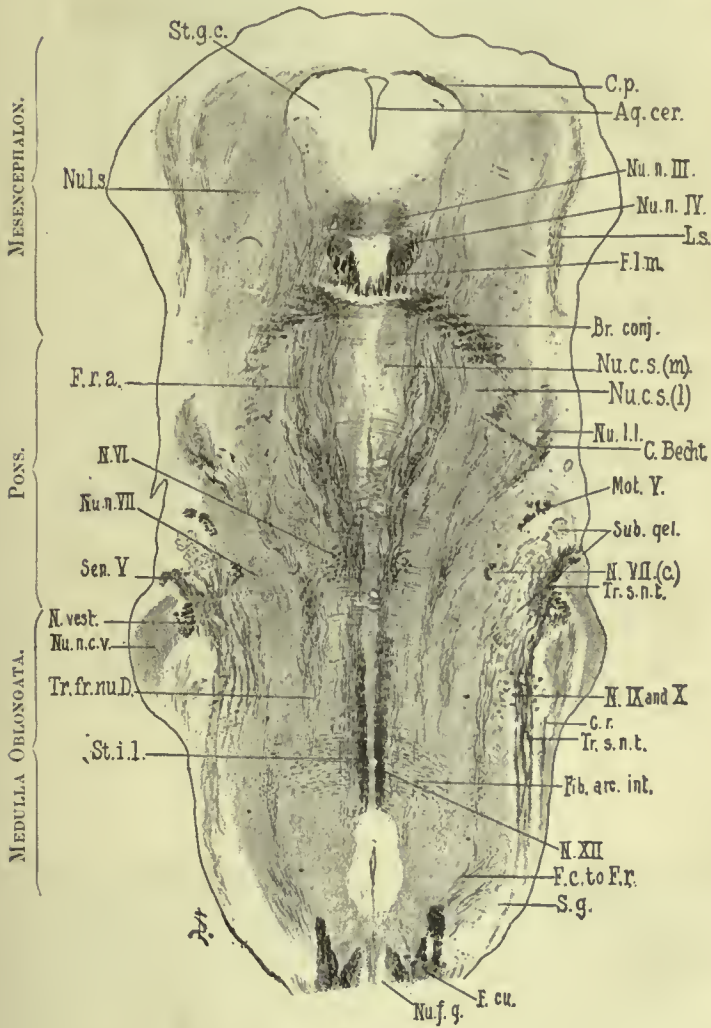


FIG. 321.

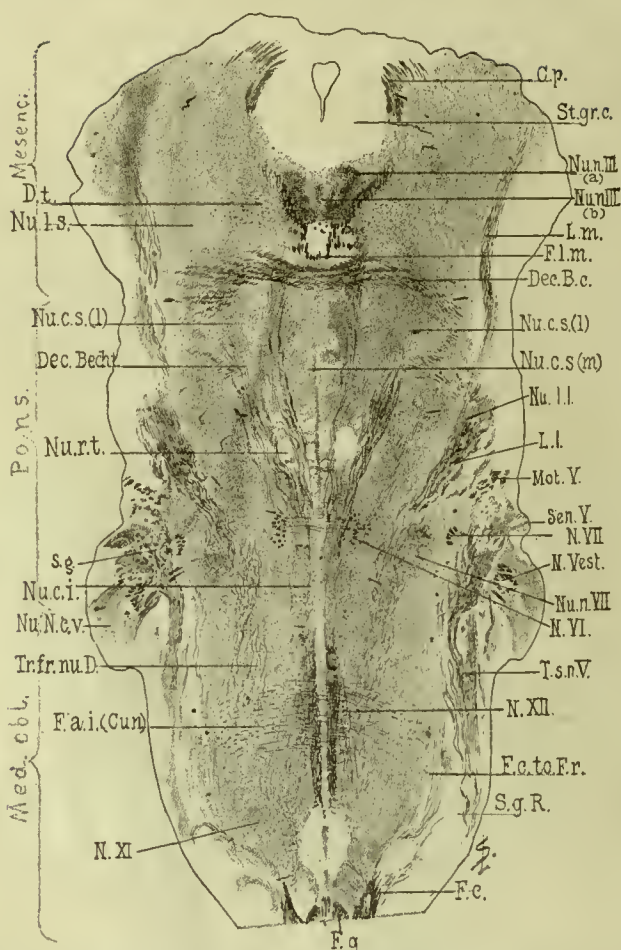


FIG. 322.—Horizontal section through the medulla, pons, and midbrain of a newborn babe. Weigert-Pal staining. Level of decussatio brachii conjunctivi and of nucleus reticularis tegmenti. (Series iii, section No. 108.) *C.p.*, commissura posterior cerebri; *Dec.B.c.*, decussatio brachii conjunctivi; *Dec.Becht.*, commissure between Bechterew's nuclei; *D.L.*, fibres to decussatio tegmenti; *F.a.i.(Cur)*, fibre arcuata interne from the nucleus funiculi cuneati; *F.e.*, fasciculus cuneatus; *F.c.to Fr.*, bundle from fasciculus cuneatus to formatio reticularis; *F.g.*, fasciculus gracilis; *F.l.m.*, fasciculus longitudinalis medialis; *L.m.*, lemniscus medialis; *L.l.*, lemniscus lateralis; *Mot.V.*, radix motorius N. trigemini; *N.VII.*, radix N. facialis, pars secunda; *N.vest.*, radix N. vestibuli; *N.VI.*, radix N. abducentis; *N.XII.*, radix N. hypoglossi; *N.XI.*, radix N. accessorii; *Nu.n.III.(a)*, nucleus N. oculomotorii, pars lateralis; *Nu.n.III.(b)*, nucleus N. oculomotorii, pars impar; *Nu.c.s.(l)*, nucleus centralis superior, pars lateralis; *Nu.c.s.(m)*, nucleus centralis superior, pars medialis; *Nu.l.l.*, nucleus lemnisci lateralis; *Nu.n.VII.*, nucleus N. facialis; *Nu.N.c.v.*, nucleus N. cochleae ventralis; *Nu.c.i.*, nucleus centralis inferior; *Nu.r.t.*, nucleus reticularis tegmenti; *Nu.l.s.*, nucleus lateralis superior; *St.gr.c.*, stratum griseum centrale; *Sen.V.*, sensory root of N. trigeminus; *S.g.*, substantia gelatinosa Rolandi; *Tr.fr.nu.D.*, tract from Deiters' nucleus to the spinal cord; *T.s.n.V.*, tractus spinalis N. trigemini. (Preparation by Dr. John Hewetson.)

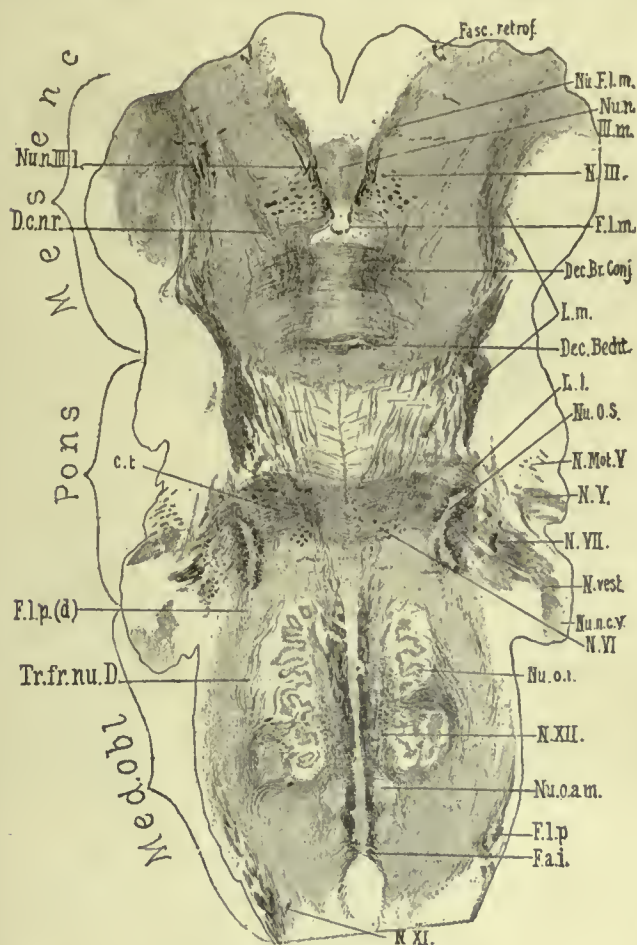


FIG. 323.—Horizontal section through the medulla, pons, and midbrain of a newborn babe. Weigert-Pal staining. Level of dorsal part of corpus trapezoidum and dorsal portion of nucleus olivaris inferior. (Series III, section No. 122.) *C.t.*, corpus trapezoidum; *Dec.Br.Conj.*, decussatio brachii conjunctivi; *Dec.Bcht.*, commissure between Bechterew's nuclei; *D.c.n.r.*, dorsal capsule of nucleus ruber; *F.a.i.*, fibre arcuatae internae; *Fasc. retrof.*, fasciculus retroflexus Meynerti; *F.l.m.*, fasciculus longitudinalis medialis; *F.l.p.*, bundle continuous with the fasciculus lateralis proprius of the cord; *F.l.p.(d)*, dorsal portion of bundle continuous with fasciculus lateralis proprius of the cord; *L.l.*, lemniscus lateralis; *L.m.*, lemniscus medialis; *N.III.*, radix N. oculomotorii; *N.Mot.V.*, motor root of N. trigeminus; *N.V.*, sensory root of N. trigeminus; *N.VI.*, radix N. abducens; *N.VII.*, radix N. facialis, pars secunda; *N.vest.*, radix N. vestibuli; *N.XI.*, radix N. accessorii; *N.XII.*, radix N. hypoglossi; *Nu.F.l.m.*, nucleus fasciculi longitudinalis medialis, or nucleus commissurae posterioris (*oberer Oculomotoriuskern* of Darkschewitsch); *Nun.III.m.*, pars impar of nucleus N. oculomotorii; *Nun.III.l.*, pars lateralis of nucleus N. oculomotorii; *Nu.o.s.*, nucleus olivaris superior; *Nun.c.V.*, nucleus N. cochleae ventralis; *Nu.o.i.*, nucleus olivaris inferior; *Nu.o.a.m.*, nucleus olivaris accessorius medialis; *Tr.fr.nu.D.*, tract from Deiters' nucleus to the spinal cord. (Preparation by Dr. John Hewetson.)

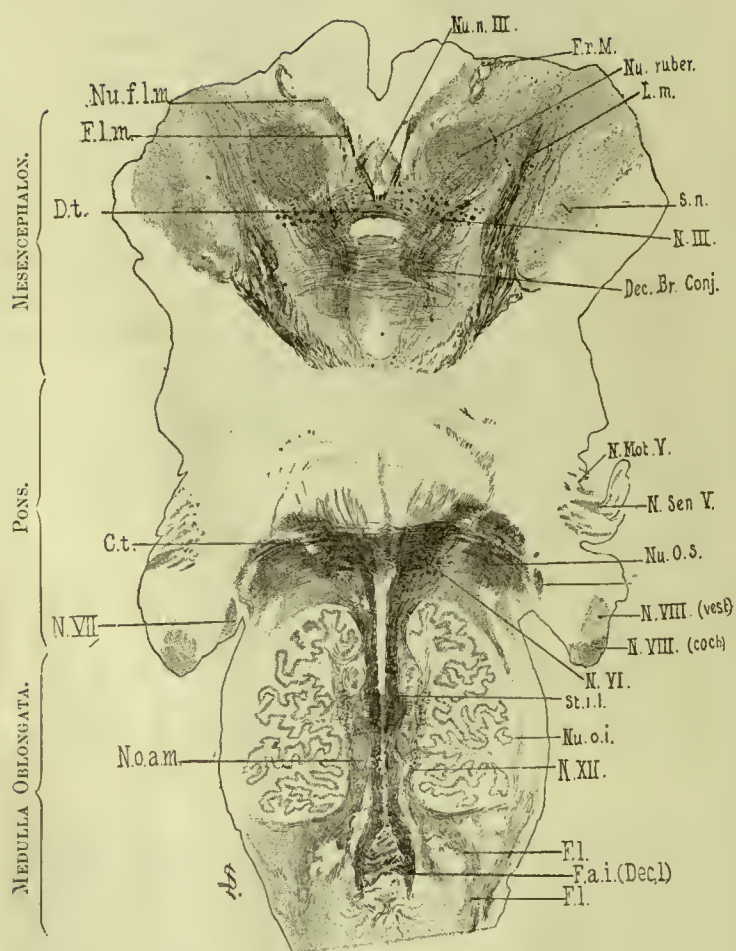


FIG. 324.



FIG. 324.—Horizontal section through the medulla, pons, and midbrain of new-born babe. Level of stratum interolivare lemnisei, corpus trapezoideum and nucleus ruber. Weigert-Pal staining. (Series III, section No. 136.) *C.t.*, corpus trapezoideum; *Dec.Br.Conj.*, decussatio brachii conjunctivi; *D.t.*, decussatio tegmenti ventralis (ventral tegmental decussation of Forel); *F.a.i.(Dec.l.)*, fibre arcuata internæ (decussatio lemniscorum); *F.l.*, fibres continuous with the funiculus lateralis of the spinal cord; *F.l.m.*, fasciculus longitudinalis medialis; *Fr.M.*, fasciculus retroflexus Meynerti; *L.m.*, lemniscus medialis; *N.III.*, radix N. oculomotorii; *N.Mot.V.*, motor root of N. trigeminus; *N.Sen.V.*, sensory root of N. trigeminus; *N.VIII.(coch.)*, radix N. cochleæ; *N.VIII.(vest.)*, radix N. vestibuli; *N.VI.*, radix N. abducens; *N.VII.*, radix N. facialis, pars secunda; *N.XII.*, radix N. hypoglossi; *Nu.fl.m.*, nucleus fasciculi longitudinalis medialis, or nucleus commissure posterioris (*oberer Oculomotoriuskern* of Darkschewitsch); *Nu.n.III.*, nucleus N. oculomotorii; *Nu.o.a.m.*, nucleus olivaris accessorius medialis; *Nu.o.i.*, nucleus olivaris inferior; *Nu.o.s.*, nucleus olivaris superior; *Nu.ruber*, nucleus ruber; *St.i.l.*, stratum interolivare lemnisei; *S.n.*, substantia nigra. (Preparation by Dr. John Hewetson.)

FIG. 325.—Diagram prepared by Miss F. Sabin from a series of sections through the brain of a new-born babe, showing the nuclei of the cerebral nerves and the area of exit and of entrance of the roots of the cerebral nerves in flat projection. *a*, line of lateral edge of fourth ventricle; *d, d, d*, fovea inferior; *e*, fovea superior; *g*, lateral surface of rhombencephalon; *III.*, area of exit of *N. oculomotorius*; *IV.*, area of exit of *N. trochlearis*; *V.*, area of exit and entrance of *N. trigeminus*; *VI.*, area of exit of *N. abducens*; *VII.*, area of exit of *N. facialis*; *VIII. (cochl.)*, area of entrance of *N. cochleæ*; *VIII. (vestib.)*, area of entrance of *N. vestibuli*; *IX. and X.*, area of entrance of *N. glossopharyngeus et vagus*; *XI.*, area of exit of *N. accessorius*; *XII.*, area of exit of *N. hypoglossus*; *Nu.n.III.*, nucleus *N. oculo-motorii*; *Nu.n.IV.*, nucleus *N. trochlearis*; *Nu.n.V. (m.p.)*, nucleus motorius princeps *N. trigemini*; *Nu.n.VI.*, nucleus *N. abducentis*; *Nu.n.VII.*, nucleus *N. facialis*; *Nu.a.*, nucleus ambiguus; *Nu.a.c.*, nucleus *ake cinereæ*; *Nu.n.v.m.*, nucleus *N. vestibuli medialis*; *Nu.n.v.s.*, nucleus *N. vestibuli superior*; *Nu.n.v.l.*, nucleus *N. vestibuli lateralis* (Deiters); *Nu.n.c.d.*, nucleus *N. cochleæ dorsalis*; *Nu.n.c.v.*, nucleus *N. cochleæ ventralis*; *Nu.n.XII.*, nucleus *N. hypoglossi*; *R.d.n.t.*, radix descendens [mesencephalica] *N. trigemini*; *R.d.n.v.*, radix descendens *N. vestibuli*; *S.g.*, substantia gelatinosa; *T. sol.*, tractus solitarius; *Tr.s.n.t.*, tractus spinalis *N. trigemini*; *Vent.*, ventral horn cells. The numbers to the left of the drawing indicate approximately the levels of the corresponding transverse sections represented by Figs. 308 to 317.

The plane of the sections from which this diagram was made is not quite transverse but somewhat oblique; the dorsal surface of the medulla has been struck by the knife more cerebralward than the ventral surface, the angle formed by the plane of the section with the longitudinal axis being approximately seventy degrees, as measured on the cerebral side. This accounts for the evident (slight) displacement cerebralward of the structures in the ventral portions of the sections as compared with those in the dorsal portions.

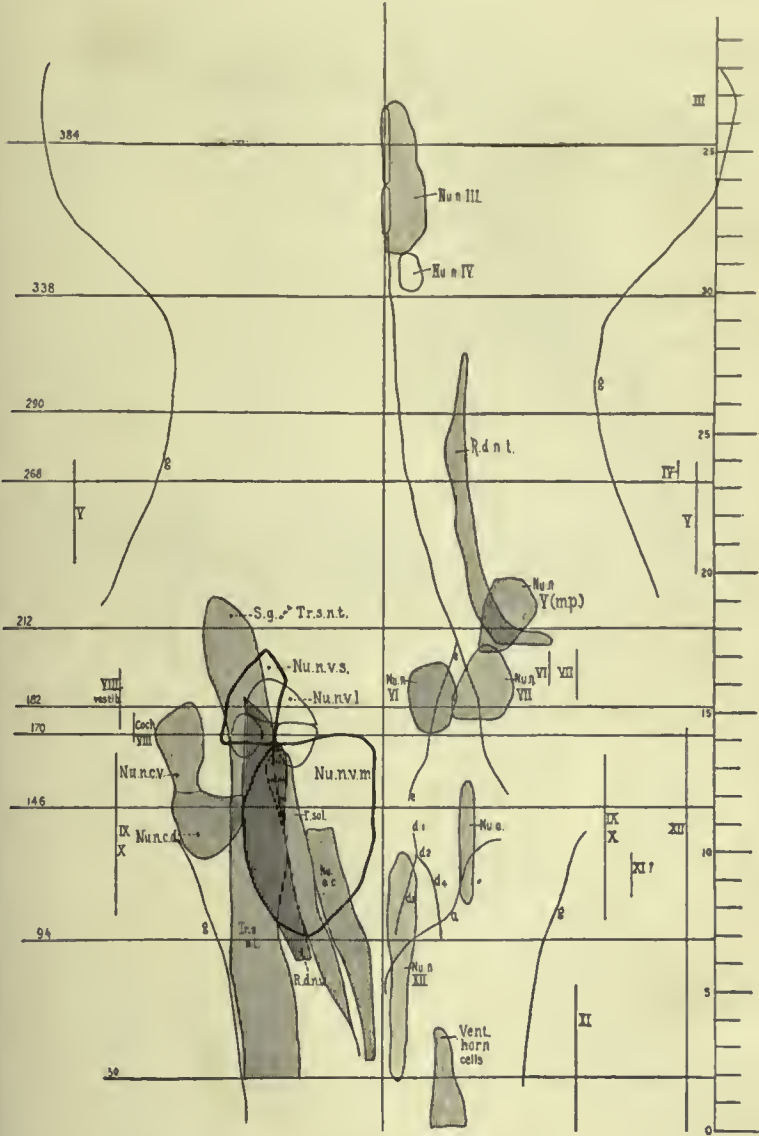


FIG. 325.



FIG. 326.—Endings of axones of *N. vagus* and *N. glossopharyngeus*. The fibres turning down into the tractus solitarius are well shown. (After H. Held, *Arch. f. Anat. u. Physiol., Anat. Abth., Leipz., 1892, Taf. i, Fig. 1.*)

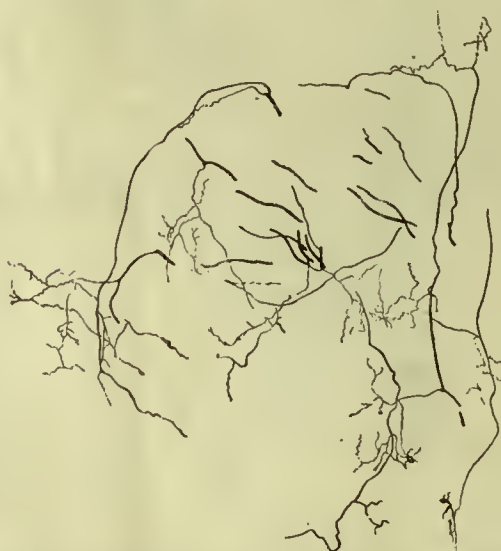

FIG. 327.—Tractus solitarius of a six-day-old cat. Delicate collaterals are seen coming from the main axones. (After H. Held, *Arch. f. Anat. u. Physiol., Anat. Abth., Leipz., 1892, Taf. i, Fig. 2.*)



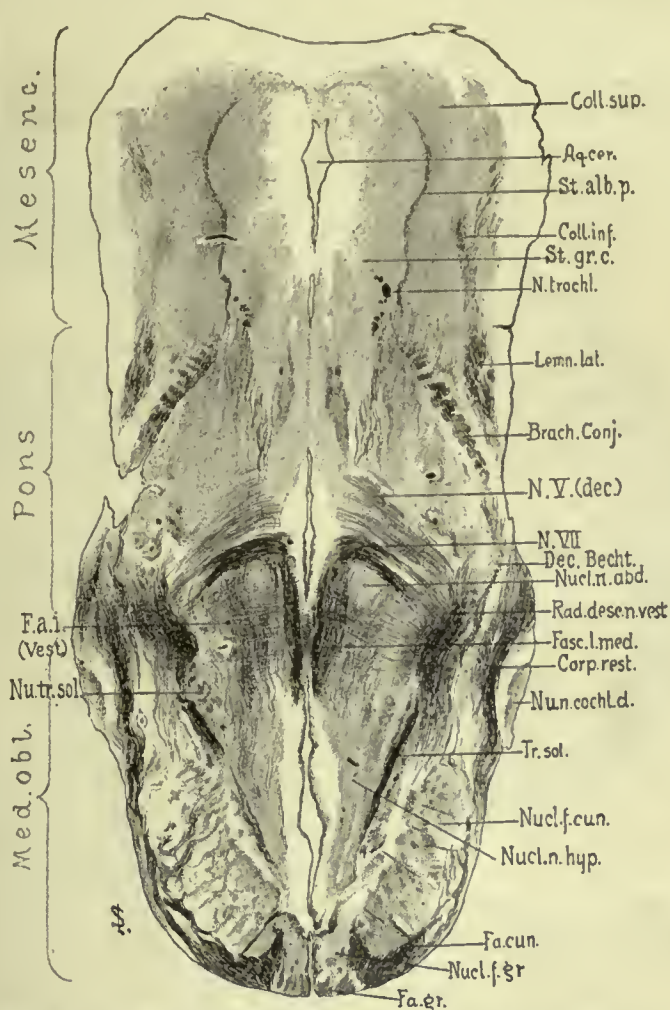


FIG. 328.—Horizontal section through the rhombencephalon and mesencephalon of a newborn babe. Weigert-Pal staining. Level of ventral part of nucleus nervi abducentis. (Series III, section No. 72.) *Aq.cer.*, aqueductus cerebri; *Brach.Conj.*, brachium conjunctivum; *Coll.sup.*, colliculus superior; *Coll.inf.*, colliculus inferior; *Corp.rest.*, corpus restiforme; *Dec.Becht.*, fibres of ventral portion of brachium conjunctivum forming a commissure between the superior nuclei of termination of the vestibular nerves of the two sides; *Fa.cun.*, fasciculus cuneatus; *Fa.gr.*, fasciculus gracilis; *F.a.i.(Vest.)*, fibre arcuatae pertaining to the central vestibular paths; *Fasc.l.med.*, fasciculus longitudinalis medialis; *Lemn.lat.*, lemniscus lateralis; *Med.obl.*, medulla oblongata; *Mesenc.*, mesencephalon; *N.trochl.*, N. trochlearis; *N.V.(dec.)*, decussating portion of the root of the N. trigeminus; *N.VIII.*, radix N. facialis, pars secunda; *Nucl.f.cun.*, nucleus funiculi cuneati; *Nucl.f.gr.*, nucleus funiculi gracilis; *Nucl.n.abd.*, nucleus N. abducentis; *Nu.n.cochl.d.*, nucleus N. cochleae dorsalis; *Nucl.n.hyp.*, nucleus N. hypoglossi; *Nu.tr.sol.*, nucleus tractus solitarius; *Rad.desc.n.vest.*, radix descendens N. vestibuli; *St.alb.p.*, stratum album profundum; *St.gr.c.*, stratum griseum centrale; *Tr.sol.*, tractus solitarius. (Preparation by Dr. John Hewetson.)



The cell bodies of the peripheral neurones corresponding to the *nervus vestibuli* are situated in the internal ear inside the ganglion vestibulare (Sarpa's ganglion, Fig. 331). These cells, which remain bipolar throughout life, send their peripheral

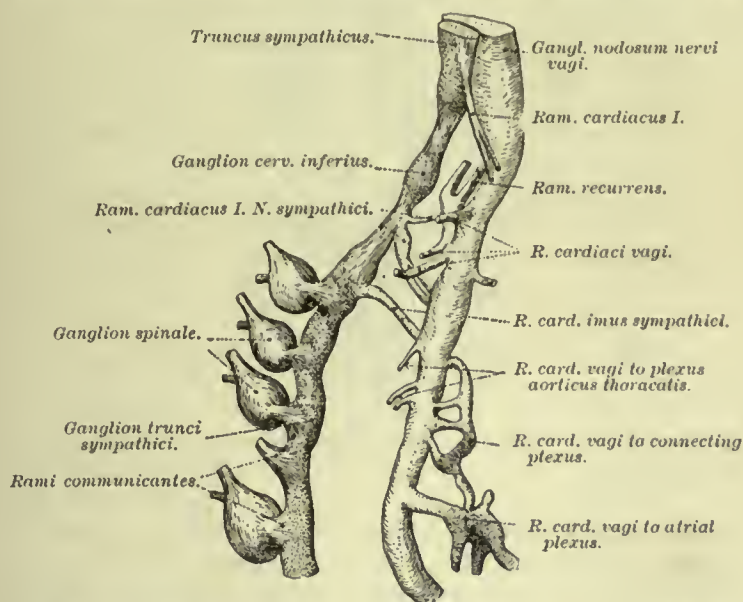


FIG. 330.—Sympathicus and N. vagus of a human embryo viewed from the right side. (After W. His, Junior, and J. Kollmann, from Kollmann's *Lehrbuch der Entwicklungsgeschichte des Menschen*, Jena, 1898, S. 560, Fig. 330.)

prolongations to the vestibule and semicircular canals, especially to the macula acustica utriculi and to the cristæ ampullares of the superior, posterior, and lateral membranous ampullæ (Fig. 332). These peripheral fibres, after repeated division, all end free\* in among the hair cells situated there, coming only into contact relation with these cells (Retzius, † van Gehuch-

\* The observations of H. Ayers—A Contribution to the Morphology of the Vertebrate Ear, with a Reconsideration of its Functions. *J. Morphol.*, Bost., vol. vi (1892), pp. 1-360: Ueber das peripherische Verhalten der Gehörnerven und den Wert der Haarzellen des Gehörorgans. *Anat. Anz.* Jena, Bd. viii (1892-93), S. 435-440—who formerly, at least, believed that acoustic nerve fibres arise directly from the hair cells, is in disagreement with the findings of other investigators.

† Retzius, G. Die Endigungsweise des Gehörnerven. *Biol. Untersuch.* Stockholm, n. F., Bd. iii (1892), S. 29-36.



ten,\* Ramón y Cajal,† von Lenhossék,‡ and Krause §). Inasmuch as the endings in the macula acustica sacculi (Fig. 333) correspond closely to those in the macula acustica utriculi, the

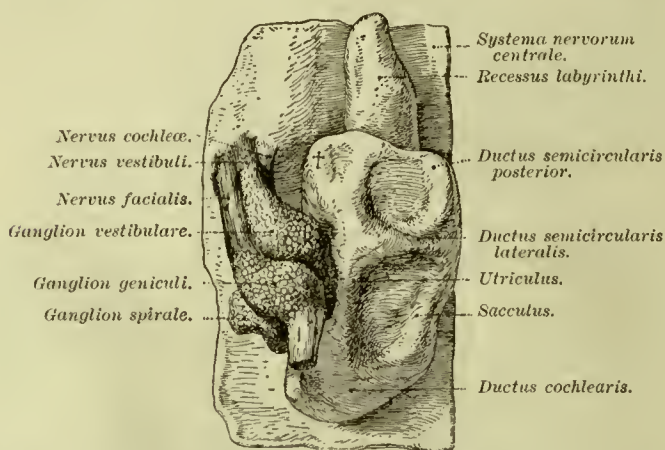


FIG. 331.—Left auditory vesicle with the acustico-facial complex of a human embryo at the fifth week. (After His, Junior, from Kollmann's text-book, S. 546, Fig. 333.)

question may naturally be raised as to whether the saccular branch of the nervus cochleæ really may not subservè the same functions as we now attribute to the branches of the nervus vestibuli. In the latter event it would perhaps be justifiable to remove the neurones corresponding to the nervus saccularis from the group of peripheral auditory neurones, and to include them with the group at present under consideration.

The central prolongations of the cells of the ganglion vestibulare, united into a compact mass as the nervus vestibuli, enter the central nervous system at the junction of the medulla and

\* van Gehuchten, A. Contributions à l'étude des ganglions cérébro-spinaux. Bull. Acad. roy. d. sc. de Belg., Brux., 3. s., t. xxiv (1892), pp. 117-154.

† Ramón y Cajal, S. El nuevo concepto de la histología de los centros nerviosos. Rev. de cien. méd. de Barcel., vol. xviii (1892), pp. 361-376; and pp. 457-476.

‡ von Lenhossék, M. Die Nervenendigungen in den Maculæ und Cristæ acusticæ. Anat. Hefte, Erste Abth.; Arb. aus anat. Instit., Bd. iii, Heft 9, S. 231.

§ Krause, R. Die Endigungsweise des Nerv. Acusticus im Gehörorgan. Verhandl. d. anat. Gesellsch., Jena, Bd. x (1896), S. 165-173.



the pons as the vestibular root of the acoustic nerve (*radix vestibularis N. acustici*). The demonstration by von Beehterew\* in 1885 of the existence and anatomical independence of two roots to the *nervus acusticus*, one (posterior and lateral) connected with the cochlea, the other (anterior and medial) connected with the vestibule and semicircular canals, formed the starting point of the series of investigations which have gradually solved the much-vexed questions concerning the origin and central connections of the "acoustic" or eighth nerve. Von Beehterew's researches found a most important confirmation and extension in the investigations of His.† This root enters at a point farther anterior (cerebralward) than does the cochlear root. It is also situated medial to the cochlear nerve, and after entrance passes obliquely, medial to the corpus restiforme (between it and the tractus spinalis nervi trigemini), in a dorsal and medial direction toward the floor of the fourth ventricle. A little lateral from a point midway between the median line of the medulla and the lateral margin of the corpus restiforme at this level, the root fibres, as von Kölliker and Held have shown, undergo bifurcation, dividing into a coarse descending and a more delicate ascending limb. This bifurca-

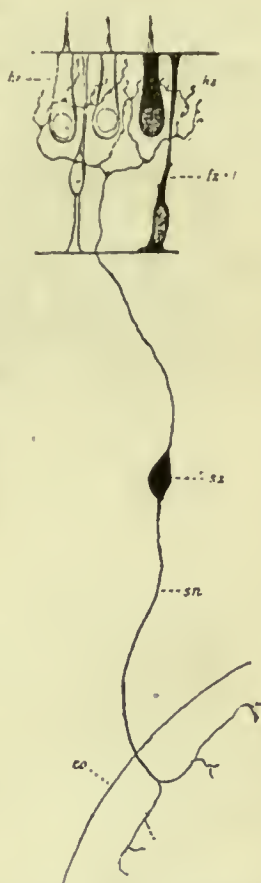

FIG. 332.—Scheme of peripheral termination of *N. vestibuli*. (After G. Retzius, *Biol. Untersuch.*, Stockholm, n. F., Bd. iv. 1892, p. 50, Fig. 7.) *co*, central nervous system; *fz*, delicate supporting cell; *hz*, hair cells; *m*, axon of *N. vestibuli*; *sz*, perikaryon of vestibular neurone in the ganglion vestibulare.

\* Beehterew, W. Ueber die innere Abtheilung des Striekkörpers und den achten Hirnnerven. *Neurol. Centralbl.*, Leipz., Bd. iv (1885), S. 145-147.

† His, W. Zur Geschichte des Gehirns sowie der centralen und peripherischen Nervenbahnen. *Abhandl. d. math.-phys. Cl. d. k. sächs. Gesellsch. d. Wissensch.*, Leipz., n. F. 135 (1888), Bd. xiv.

tion is exquisitely demonstrated in one of Ramón y Cajal's preparations (Fig. 334). The descending limbs of the vestibular fibres together make up the well-known *radix descendens nervi vestibuli*.\*

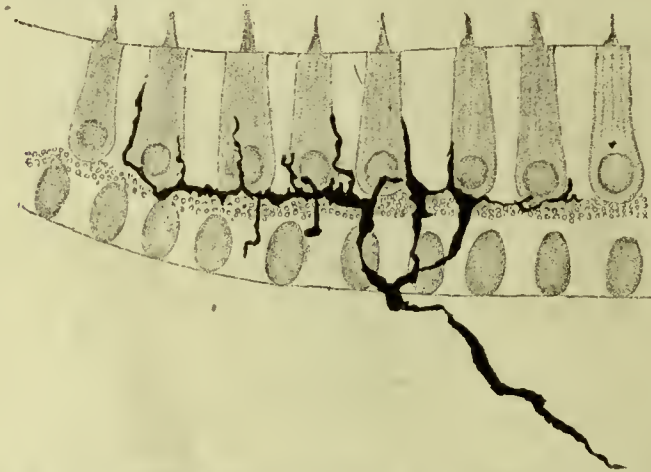


FIG. 333.—Isolated impregnated interepithelial end arborization from the macula acustica sacculi. Method of Golgi. (After M. von Lenhossék, *Anat. Hefte*, Wiesb., Bd. iii, Heft ix, 1893, Taf. xiii, Fig. 3.)

The root fibres of the nerve of the vestibule come into conduction relation by means of the collaterals and terminals of their axones with the so-called "nuclei of reception" or *nuclei terminales* (*Endkerne* of the Germans) of this nerve. In the descriptions of no part of the medulla has there been more confusion, perhaps, than in those of the region of the nuclei of termination of the acoustic nerve. The older literature, well epitomized by Onufrowicz,† is a mass of the most bewildering and contradictory statements, which, together with the varying,

\* This root, called by Meynert the *innere Abtheilung des Strickkörpers*, was carefully studied and described by C. F. W. Roller—*Eine aufsteigende Acusticuswurzel*. *Arch. f. mikr. Anat.*, Bonn, Bd. xviii (1880), S. 403-408; and *In Sachen der aufsteigenden Acusticuswurzel*. *Arch. f. Psychiat. u. Nervenkr.*, Berl., Bd. xiv (1883), S. 458-460—but was erroneously designated by him *aufsteigende Wurzel*. He believed that it had its origin in the fasciculus euneatus.

† Onufrowicz, B. *Experimenteller Beitrag zur Kenntniss des Ursprungs des Nervus acusticus des Kaninchens*. *Arch. f. Psychiat. u. Nervenkr.*, Berl., Bd. xvi (1885), S. 711-742.

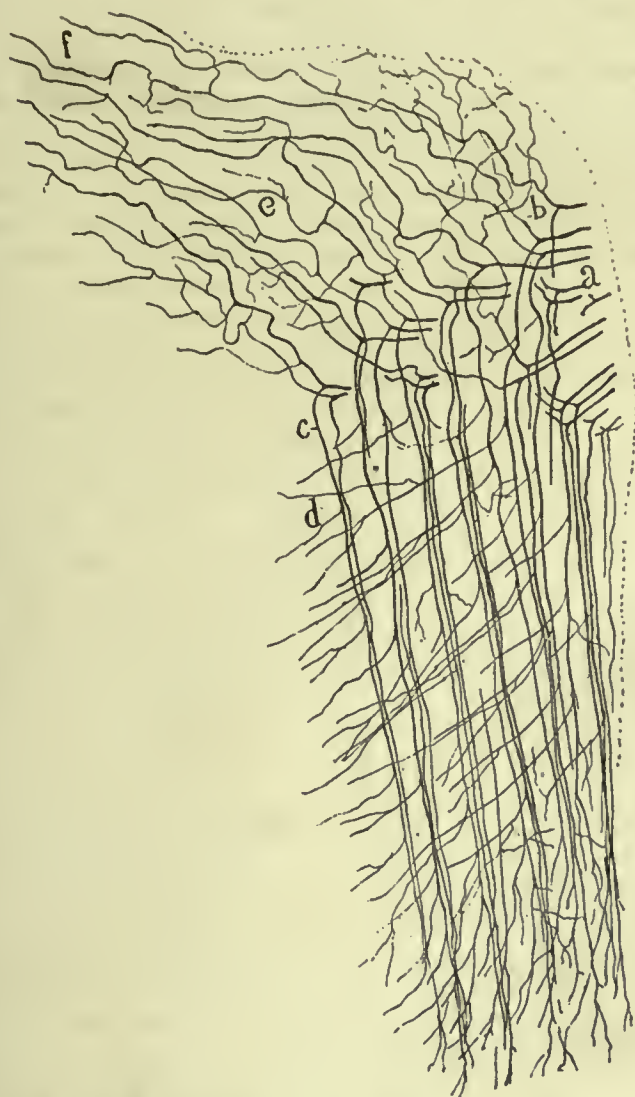

FIG. 334.—Lateral sagittal section through the rhombencephalon of a fetal mouse. (After S. Ramón y Cajal, *Beitrag zum Studium der Medulla Oblongata*, etc., Leipz., 1896, S. 63, Fig. 17.) The section is relatively thick and shows distinctly the bifurcation of the root fibres of the N. vestibuli. *a*, root fibres; *b*, ascending limbs; *f*, continuation of ascending limbs into nucleus N. vestibuli superior (Bechterew) and nucleus cerebelloacusticus; *c*, descending limb of large calibre; *d*, collaterals terminating in nucleus N. vestibuli spinalis.

overlapping, and inconsequent nomenclature employed, have made the older articles so puzzling as to render them almost worthless to the student of to-day.\* I shall not attempt, therefore, a tedious *résumé* of the bibliography, but shall state as simply as possible my own views regarding these nuclei, which have been formed after study of serial frontal, and horizontal sections through the medulla of the foetus and the adult with Miss Florence Sabin, and after a careful comparison of our findings with those of von Bechterew,† Flechsig,‡ Baginski,§ von Monakow,||

---

\* The extreme complexity of the parts and the limitations of technique of the period excuse the labyrinth of errors into which the older investigators were led. Amid the general confusion a reader of the older articles can not help being impressed with the careful objectivity of the descriptions of the great English neurologist, J. Lockhart Clarke (*Researches on the Intimate Structure of the Brain, Human and Comparative*, Phil. Tr., Lond., vol. cxlviii (1858), pp. 231-259.—*Researches on the Intimate Structure of the Brain, ibid.*, vol. cxlviii (1868), pp. 263-331). The publications of John Dean, of Boston (*The Gray Substance of the Medulla Oblongata and Trapezium*, 4to, Smithsonian Contributions to Knowledge, Washington, 1864), show excellent illustrations of the region in question. The original articles of O. F. C. Deiters (*Untersuchungen ueber Gehirn und Rückenmark des Menschen und der Säugethiere, nach dem Tode des Verfassers herausgegeben und bevorwortet von Max Schultze*, 8vo, Braunschweig, 1865) should be consulted by any one wishing to understand the position taken by this celebrated neurologist concerning the nuclei in question.

† von Bechterew, W. Ueber die innere Abtheilung des Strickkörpers und den achten Hirnnerven. *Neurol. Centralbl.*, Leipz., Bd. iv (1885), S. 145-147; [Origin and Course of *Stria medullaris s. acustica*.] *Med. Obozr.*, Mosk., vol. xxxvii (1892), pp. 470-478; also in *Neurol. Centralbl.*, Leipz., Bd. xi (1892), S. 297-305.—Der hintere Zweihügel als Centrum für das Gehör, die Stimme und die Reflexbewegungen. *Neurol. Centralbl.*, Leipz., Bd. xiv (1895), S. 706-712.

‡ Flechsig, P. Zur Lehre vom centralen Verlauf der Sinnesnerven. *Neurol. Centralbl.*, Leipz., Bd. v (1886), S. 545-551.—Weitere Mittheilungen über die Beziehungen des unteren Vierhügels zum Hörnerven. *Neurol. Centralbl.*, Leipz., Bd. ix (1890), S. 98-100.

§ Baginski, B. Ueber den Ursprung und den centralen Verlauf des Nervus acusticus des Kaninchens. *Arch. f. path. Anat.*, etc., Berl., Bd. cv (1886), S. 28-46.—Ueber den Ursprung und den centralen Verlauf des Nervus acusticus des Kaninchens und der Katze. *Arch. f. path. Anat.*, etc., Berl., Bd. cxix (1890), S. 81-93.

|| von Monakow, C. Ueber den Ursprung und den centralen Verlauf des Nervus acusticus. *Cor.-Bl. f. schweiz. Aerzte*, Bd. xvii, 1887, No. 5; abstract in *Neurol. Centralbl.*, Leipz., Bd. vi (1887), S. 201.



Sala,\* Held,† P. Martin,‡ Cramer,\* Ramón y Cajal,|| and others.

There are, in accordance with the views of the majority of recent investigators, at least four well-defined primary nuclei of termination in connection with the vestibular nerve: (1) The nucleus nervi vestibuli medialis (Schwalbe); (2) the nucleus nervi vestibuli spinalis (radix descendens); (3) the nucleus nervi vestibuli lateralis (Deiters); and (4) the nucleus nervi vestibuli superior (Flechsig, von Bechterew). In addition, the nervus vestibuli comes into direct conduction relation, (*a*) (probably chiefly by means of collaterals) with the nucleus nervi cochleæ ventralis; (*b*) (by means of ascending limbs of divided root fibres or collaterals from these) with the mass of nerve cells (Ramón y Cajal's *nucleus cerebello-acusticus*) in the lateral wall of the ventricle, dorsal to Bechterew's nucleus, and (*c*) with the nuclei of the roof of the fourth ventricle (nuclei fastigii) on both sides of the middle line, and (*d*) possibly, according to Ramón y Cajal, by means of a few fibres with the nucleus dentatus cerebelli and the cerebellar cortex.

Concerning the exact topographical relations of the four principal nuclei, the descriptions in the bibliography are not only very incomplete, but there is also considerable variance between the statements of different authors. Florence Sabin has made from serial sections a flat reconstruction of the exact limits of these nuclei as they exist in the new-born babe, and we

---

\* Sala, L. Sur l'origine du nerf acoustique. Arch. ital. de biol., Turin, t. xvi (1891-'92), pp. 196-207; also in *Monitore zool. ital.*, Firenze, vol. ii (1891), p. 219.

† Held, H. Die centralen Bahnen des Nervus acusticus bei der Katze. Arch. f. Anat. und Physiol., Anat. Abth., Leipz. (1891), S. 271-291.—Die Endigungsweise der sensiblen Nerven im Gehirn. Arch. f. Anat. u. Physiol., Anat. Abth., Leipz. (1892), S. 33-39.—Ueber eine directe acustische Rindenbahn und den Ursprung des Vorderseitenstranges beim Menschen. Arch. f. Anat. u. Physiol., Anat. Abth., Leipz. (1892), S. 257-264.—Die centrale Gehörleitung. Arch. f. Anat. u. Physiol., Anat. Abth., Leipz. (1893), S. 201-248.

‡ Martin, P. Zur Endigung des Nervus acusticus im Gehirn der Katze. Anat. Anz., Jena, Bd. ix (1893-'94), S. 181-184.

\* Cramer, A. Beiträge zum feineren Anatomie der Medulla oblongata und der Brücke mit besonderer Berücksichtigung des 3-12 Hirnnerven, Jena, 1894.

|| Ramón y Cajal, S. Beitrag zum Studium der Medulla oblongata, des Kleinhirns und des Ursprung der Gehirnnerven. Deutsche Uebersetz. vom Bresler, Leipzig, 1896.



are presented for the first time in her article\* with a diagram which shows clearly (at least in two dimensions) the size and relative positions of the nuclei. Miss Sabin's diagram is reproduced in Fig. 335.

It will be seen in the diagram (Areas M and Y) that the large nucleus nervi vestibuli medialis, beginning spinalward a little above the middle of the nucleus nervi hypoglossi, extends cerebralward to a level corresponding approximately to the spinal extremity of the nucleus nervi abducentis. Its medial border reaches almost to the median line of the floor of the ventricle, going over without sharp limit into the central gray matter, while laterally it fuses with and is with difficulty distinguishable from the nucleus nervi vestibuli spinalis (radix descendens). The latter nucleus is made up of great numbers of cells situated in the gray matter surrounding the descending root, and also of many cells interspersed among its fibres. The fibres of the descending root, as the cross section (Fig. 336) shows, are arranged in small bundles among which gray matter rich in cells is everywhere distributed. The nucleus of the descending root represents at least one of the principal, if not the principal, end-station of vestibular fibres.†

The antero-lateral extremity of the medial vestibular nucleus (Miss Sabin's nucleus Y) is undoubtedly the most important part of the medial nucleus. In transverse section, nucleus Y is triangular in shape with the apex ventralward, hence the name *nucleus triangularis* given to it by some authors. In it are situated an enormous number of cells closely crowded together, in among which ramify very many rather fine medullated fibres from the area in which the nervus vestibuli bifurcates. The nucleus Y tapers out posteriorly, and finally disappears anteriorly just medial to the wide part of the medial portion of

---

\* Sabin, Florence R. On the Anatomical Relations of the Nuclei of Reception of the Cochlear and Vestibular Nerves. Johns Hopkins Hosp. Bull., Balt., vol. viii, 1897, pp. 253-259.

† It is rather amusing to find that in the earlier history of the vestibular nuclei the medial nucleus was spoken of by Schwalbe as the *Hauptkern des Acusticus*. Later the superior nucleus (v. Beehterew) was described as the *Hauptkern des Acusticus*. It would be unfortunate if, in agreement with Ramón y Cajal and myself, still others, coming to the conclusion that the nucleus of the descending root is the principal nucleus, should introduce a third *Hauptkern des Acusticus*!

Deiters' nucleus as shown in the diagram (Fig. 335). Posterior to it (that is, spinalward from it) is situated the nucleus of the descending root, and the junction of the two nuclei is marked by a regular vortex of fine medullated fibres.\*

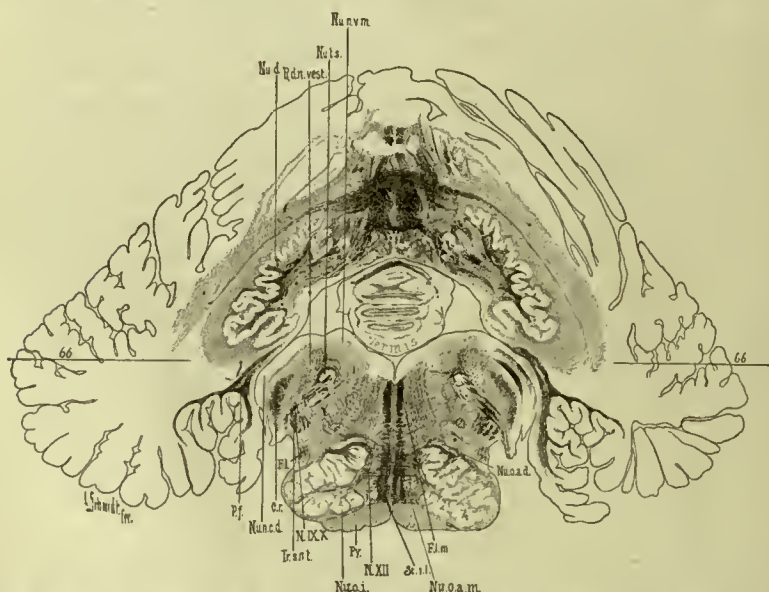


FIG. 336.—Transverse section of medulla oblongata and cerebellum of newborn child. (Series ii, section No. 146.) *C. r.*, corpus restiforme (the part medullated corresponds in the main to the direct cerebellar tract); *F. l.*, bundle continuous with the funiculus lateralis of the cord; *F. l. m.*, fasciculus longitudinalis medialis; *N. l. x. x.*, N. glossopharyngeus et vagus; *N. x. l.*, N. hypoglossus; *Nu. d.*, nucleus dentatus; *Nu. c. d.*, nucleus N. cochleæ dorsalis; *Nu. v. m.*, nucleus N. vestibuli medialis; *Nu. o. a. m.*, nucleus olivaris accessorius medialis; *Nu. o. i.*, nucleus olivaris inferior; *Nu. t. s.*, nucleus tractus solitarius; *P. f.*, pedunculus flocculi; *Py.*, pyramis; *R. d. n. vest.*, radix descendens N. vestibuli; *St. i. l.*, stratum interolivare lemnisci; *66*, plane of longitudinal section No. 66. [NOTE.—This figure has been disproportionately reduced in the reproduction.] (Weigert-Pal preparation by Dr. John Hewetson.)

\* Sabin, F. R. (*op. cit.*), has rightly laid emphasis upon the individuality of nucleus Y, adducing as her reasons (1) the size of the cells (larger than those of the rest of the medial nucleus, smaller than those of Deiters' nucleus); (2) the mode of staining of the nucleus (much darker than Deiters' nucleus proper in suitably differentiated Weigert-Pal preparations); (3) the distribution of the cells (closely packed together in Y, scattered and far fewer in number in Deiters' nucleus), and lastly, (4) its distinct demarkation from the adjoining gray masses. She does not assert its absolute morphological independence, but is content with outlining its position and calling attention to its characteristic features.



The nucleus nervi vestibuli superior (Flechsigs, v. Bechterew) is represented in the diagram by the area S, outlined by the very heavy black line. It begins posteriorly at a level somewhat behind that of the anterior end of the medial nucleus, but is placed much more laterally and dorsally, so that it lies in reality in the lateral wall of the fourth ventricle and in the ventro-lateral angle of this cavity rather than in its floor (Fig. 337). At the inferior end it is intimately connected with the fibres of the pedunculus flocculi; indeed, its lower limit is only with great difficulty determined, owing to the intimate admixture of fibres and cells. At its upper (anterior) extremity it tapers out into a narrow mass of cells which can be followed anteriorly as far as the level of the principal motor nucleus of the nervus trigeminus. The main mass of the superior nucleus of the N. vestibuli is ventral and medial to the ventral portion of the brachium conjunctivum. At its lower (posterior) extremity it is medial and dorsal to the corpus restiforme, where the latter turns up into the cerebellum. Just anterior to the point in which the connection of the pedunculus flocculi with Bechterew's nucleus is most apparent the nucleus lies ventral to the corpus dentatum and dorsal to the corpus restiforme, being intercalated, as it were, like a buffer between these two structures.

The nucleus nervi vestibuli lateralis (Deiters') is situated between the medial nucleus and Bechterew's nucleus, lateral to the former and ventral and somewhat medial to the latter (Fig. 337). Miss Sabin's diagram shows clearly its division into two parts, L and  $L_1$ . The portion L is situated in front of (anterior to) and medial to the portion  $L_1$ . I would suggest that these two portions of the nucleus nervi vestibuli lateralis be designated, temporarily at least, as the *Pars medialis* (L) and *Pars lateralis* ( $L_1$ ). I wish to lay stress, however, upon the fact that the subdivision of Deiters' nucleus here made, refers only to relatively gross relations, for microscopic examination shows that the two parts are in reality made continuous with one another by a few scattered cells which are interspersed among the root fibres of the nerve. The cells in L and  $L_1$  are very large multipolar ganglion cells, closely resembling the cell bodies of the lower motor neurones (cells of ventral horns in spinal cord, motor nuclei in medulla). The study of serial sections shows very clearly the remarkable relations of Deiters' nu-



cleus to the vestibular root fibres. The fibres entering as a tolerably compact bundle penetrate the medulla to the region of this nucleus, and then, suddenly stopping their dorso-medial course, bifurcate, the coarse descending limbs passing immediately downward after division in the *radix descendens nervi vestibuli*. The diagram (Fig. 335) shows how Deiters' nucleus ( $L_1$ ,  $L$ ) sits, as it were, like a cap upon the descending root. The medial portion of the nucleus  $L$  is separated from the lateral portion  $L_1$  by the entering root fibres.

Just how far down the fibres of the descending root go it is difficult to say. They can certainly be followed to a level posterior to the middle of the nucleus *nervi hypoglossi*. Ramón y Cajal has been able in the mouse to follow them below the ganglion commissurale of the *tractus solitarius*.

What is the fate of the ascending limbs of division of the axones of the *nervus vestibuli*? The careful studies of v. Kölliker, Held, and Ramón y Cajal with Golgi's method have determined their course. They pass in a dorsal and somewhat lateral direction, pursuing a tortuous and very irregular course into the nucleus *nervi vestibuli superior*, where all of them give off numerous collaterals and many of them end. The coarser fibres among them pass up medial to the *corpus restiforme* and terminate in the cerebellum in the nuclei of the roof of the fourth ventricle of the same and of the opposite side, and, according to Cajal, give off in passing collaterals to the little mass of nerve cells situated in their course (his *nucleus cerebello acusticus*). The fibres of the direct cerebellar bundle of the *nervus vestibuli* are doubtless among the bundles of medullated fibres seen in Fig. 337, extending between the region of Deiters' nucleus through Bechterew's nucleus and the *brachium conjunctivum* to the region of the nucleus *fastigii*, though they do not represent the majority of these fibres.\* It is impossible, however, from Weigert-Pal preparations to say in every instance in which direction the fibres are running—whether from the medulla to the cerebellum, or from the cerebellum to the medulla.

The connection of ascending limbs of vestibular fibres with the medial nucleus (its antero-lateral extremity, nucleus  $Y$ )

---

\* For a study of the nucleus *fastigii* by Golgi's method, see Ramón y Cajal. *Ganglions cérébelleux*. *Bibliogr. anat., Par.*, t. iii (1895), p. 33.

and with Deiters' nucleus appears to be mainly by means of collaterals. In Weigert-Pal preparations enormous numbers of fibres are seen to enter nucleus Y, but it is impossible to say

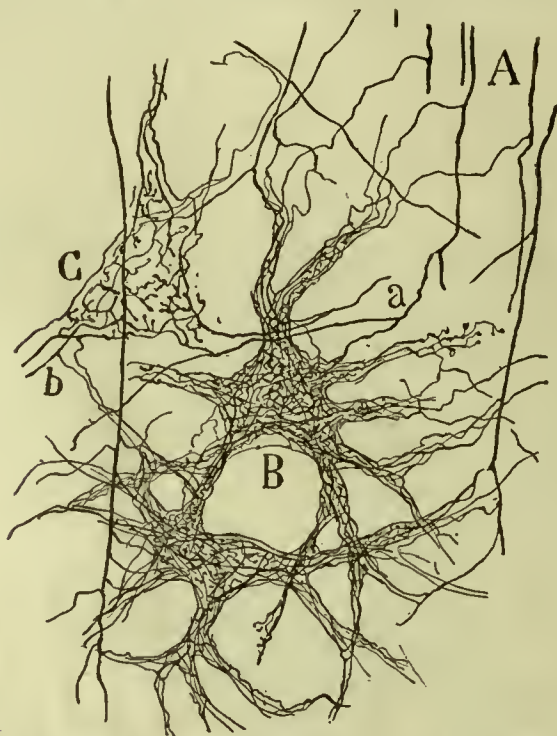


FIG. 338.—Pericellular endings of collaterals from the axones of the N. vestibuli in the nucleus N. vestibuli lateralis (Deiters') of a four-day-old cat. (After S. Ramón y Cajal, *Beitrag zum Studium der Medulla Oblongata*, etc., Leipz., 1896, S. 72, Fig. 19a.) A, descending limb of bifurcation of N. vestibuli; B, pericellular network; C, branches in which one can see the terminations of the ultimate fibrils; a, collateral which, entering into a network, sends another collateral (b) to neighboring ramifications.

whether these are collaterals or ascending limbs of divided root fibres. The lower portions of the medial nucleus receive numerous collaterals from the descending limbs running in the *radix descendens*. A great many collaterals from the fibres of the descending root end in Deiters' nucleus, where they form most complicated pericellular plexuses (Fig. 338). The majority of the collaterals and terminals of the descending limbs end, however, in the gray matter immediately adjacent—i. e., in the nucleus *nervi vestibuli spinalis*. Ramón y Cajal insists



that the innumerable collaterals of the descending root form without doubt the chief termination of the vestibular nerve.

A very welcome confirmation and extension of modern views concerning the distribution of the root fibres of the vestibular nerve has been furnished by Thomas.\* The reader is referred to his experiments in which he cut the root and subsequently studied the distribution of the fibres by means of the method of Marchi.

The student of the microscopic anatomy of the medulla oblongata can not fail to be impressed with the importance of these complex gray masses in connection with the collaterals and terminals of the axones of the peripheral vestibular neurones. Such an elaborate end-apparatus in a region where

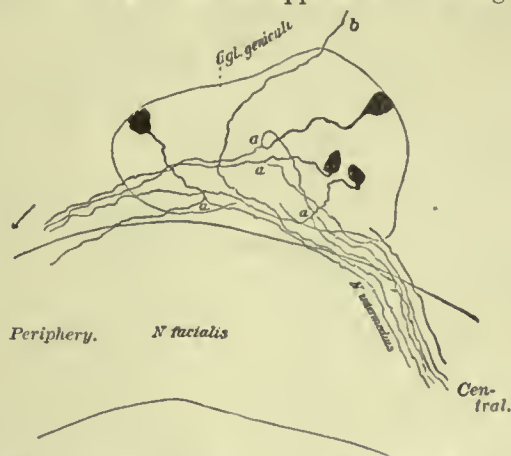


FIG. 339.—Ganglion geniculi of a newborn mouse. (After M. von Lenhossék.) Unipolar nerve cells giving off central axones to the N. intermedius; *a*, point of bifurcation; *b*, isolated fibre of the N. petrosus superficialis major.

space has been economized to the utmost must be of the highest physiological significance.

The central axones of the cells of the geniculate ganglion †

\* Thomas, A. Les terminaisons centrales de la racine labyrinthique. *Compt. rend. Soc. de biol., Par.*, 10. s., t. v (1898), pp. 183-185.

† This ganglion in early embryonic life is a portion of the general fan-shaped *Ganglion acusticofaciale* of His. The centripetal fibres arising from this ganglion decussate at the apex of the triangular ganglionic mass, and enter the medulla in the form of two bundles—a lateral and a medial. The peripheral fibres diverge as the cochlear and vestibular nerves. The motor facial nerve, whose cells of origin are inside the pons, breaks through this ganglionic mass, carrying with it the group of cells corresponding to the geniculate ganglion. Cf. His, W. *Die morphologische Betrachtung*

(*nervus intermedius*) join, in all probability, the intracentral prolongations of the *N. vagus* and *N. glossopharyngeus*. The peripheral axones accompany, in large part at least, the bundle of motor axones which constitutes the *N. facialis* (Fig. 339).

The cell bodies of the sensory neurones of the *nervus trigeminus* are situated in the ganglion semilunare (Gasseri) (Pl. I, Fig. 2). They are unipolar, like the cells of the spinal ganglia. Their medullated central axones form the portio major of the fifth cerebral nerve (Fig. 340). The peripheral processes of the ganglion cells are distributed to the skin of the face and the mucous membrane of the mouth. The central prolongations plunge through the substance of the pons into the region of their nuclei of reception (Fig. 341), where they bifurcate\* (Fig. 342), being thus distinguishable from the motor fibres of the fifth nerve, which do not bifurcate.† The descending limb of bifurcation is coarse; the ascending is fine, and terminates after rather a short course in that portion of the substantia gelatinosa often spoken of as the main nucleus of reception of the sensory portion of the trigeminus. In reality this is only the much expanded upper portion of the substantia gelatinosa. The descending limbs pass a long way down, the medullated axones forming the well-known tractus spinalis nervi trigemini,‡ which runs through the whole length of the

---

der Kopfnerven. Arch. f. Anat. u. Physiol., Anat. Abth., Leipz., 1887, S. 379-453; and Hiss, Jr., W. Zur Entwicklungsgeschichte des Acustico-Facialgebietes beim Menschen. Arch. f. Anat. u. Physiol., Anat. Abth., 1889, Suppl.-Bd., S. 1-28.

\* The bifurcation of the sensory axones of the *N. trigeminus* observed by Ramón y Cajal (Gac. san. de Barcel., 10 April, 1891) has been confirmed by von Kölliker, Held, and van Gehuchten.

† In Weigert-Pal preparations the sensory fibres of the *N. trigeminus* are of fine calibre, and stain of a brownish-black color; the motor axones are much coarser in calibre, and stain of a deep bluish-black color.

‡ Why even the first-class text-books persist in calling this spinal bundle the ascending root of the fifth (the Germans constantly referring to it as the *aufsteigende Wurzel*) I can not understand. This is a serious mistake, and nothing is more calculated to confuse the beginner than the continuance of such an erroneous nomenclature. The fibres *descend*; they are, in fact, the medullated descending limbs of the divided axones of cell bodies situated in the Gasserian ganglion. By naming it the "spinal tract of the trigeminus," or tractus spinalis nervi trigemini, we avoid the confusion with the radix descendens (mesencephalica) nervi trigemini, the medullated motor axones descending from the nuclei motorii minores nervi trigemini.

medulla, going even below the level of the decussation of the pyramids. These fibres on their way give off great numbers of collaterals and terminals, to end free in the neighboring

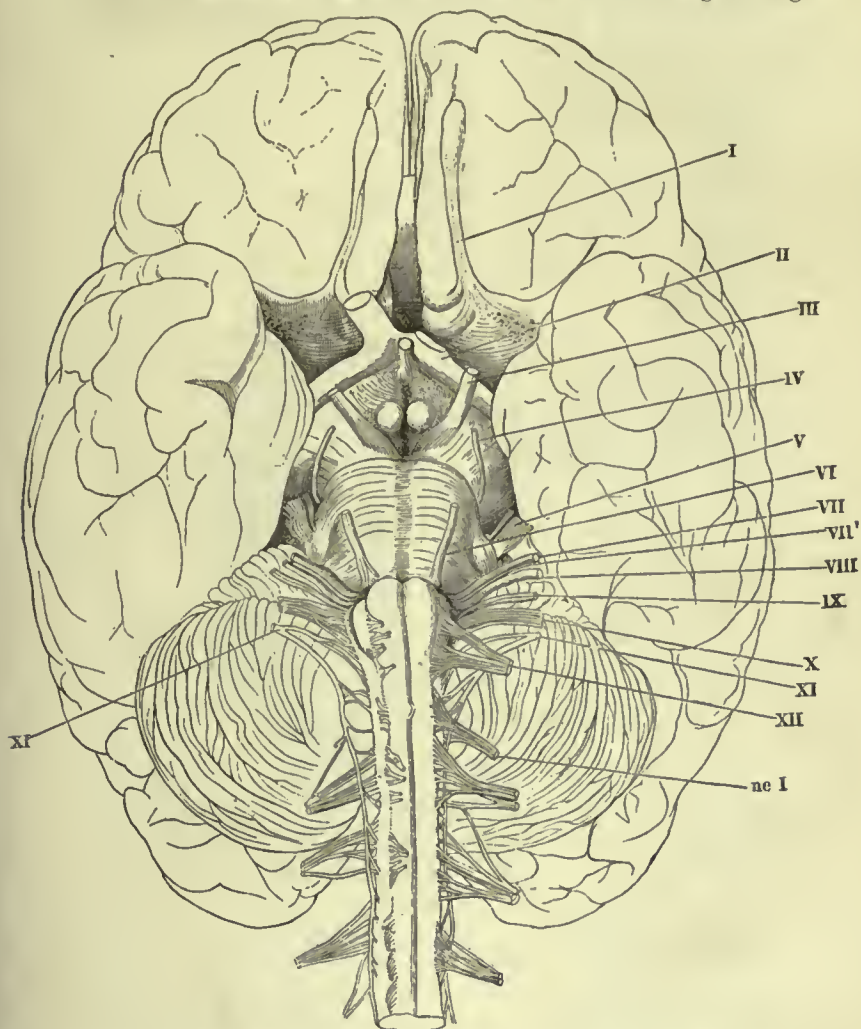
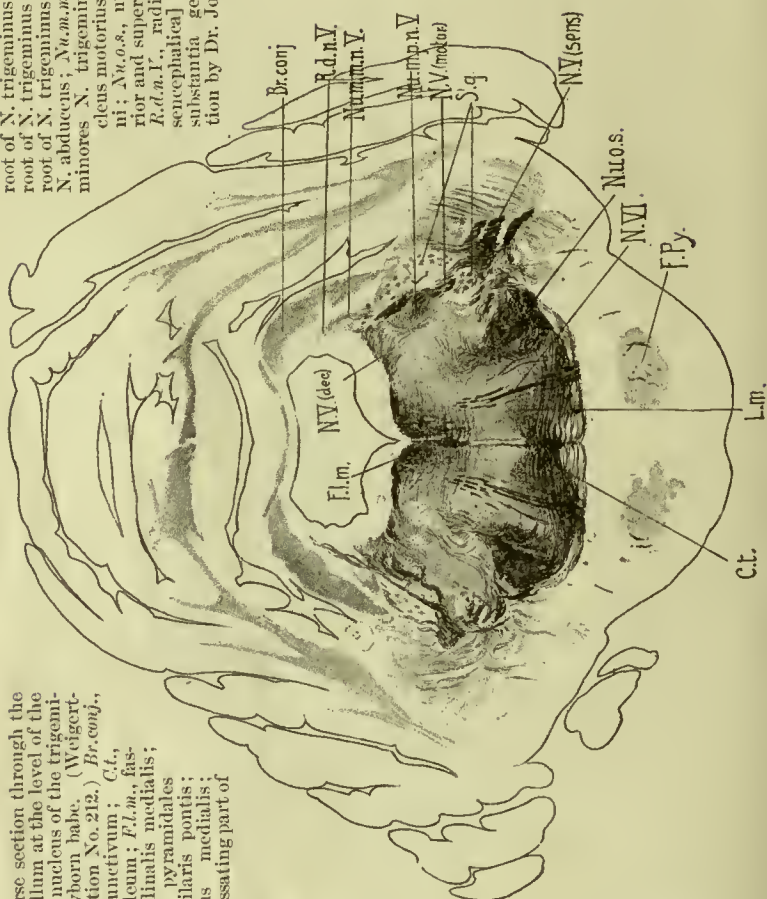


FIG. 340.—Cerebrum, with a portion of the spinal cord, viewed from the ventral surface. On the right-hand side the ventral roots are cut off short and turned medialward. (After Rüdinger and Henle, from A. Rauber's textbook.) I, tractus olfactorius; II, tractus opticus; III, N. oculomotorius; IV, N. trochlearis; V, N. trigeminus, portio major et portio minor; VI, N. abducens; VII, N. facialis; VII', N. intermedius; VIII, N. acusticus; IX, N. glossopharyngeus; X, N. vagus; XI, N. accessorius; XII, N. hypoglossus; ne I, N. cervicalis primus.

FIG. 341.—Transverse section through the pons and cerebellum at the level of the principal motor nucleus of the trigeminal nerve. Newborn babe. (Weigert-Pal, series II, section No. 212.) *Br.conj.*, brachium conjunctivum; *C.t.*, corpus trapezoidicum; *F.L.m.*, fasciculus longitudinalis medialis; *F.P.p.*, fasciculi pyramidales in the pars basilaris pontis; *L.m.*, lemniscus medialis; *N.V.(dec.)*, decussating part of

root of *N. trigeminus*; *N.V.(motor)*, motor root of *N. trigeminus*; *N.V.(sens.)*, sensory root of *N. trigeminus*; *N.V.L.*, root fibres of *N. abducens*; *Nu.m.m.n.V.*, nuclei motorii minores *N. trigemini*; *Nu.m.p.n.V.*, nucleus motorius princeps *N. trigemini*; *Nu.o.s.*, nucleus olivaris superior and superior olivary complex; *R.d.n.V.*, radix descendens [encephalical] *N. trigemini*; *S.g.*, substantia gelatinosa. (Preparation by Dr. John Hewetson.)





substantia gelatinosa, which in reality forms a continuous column of nuclei of reception for the fifth nerve, designated now as the *nuclei tractus spinalis nervi trigemini* (Fig. 343). The fibres of this tract are very characteristic in transverse sections stained by the Weigert-Pal method (Fig. 344). In the medulla

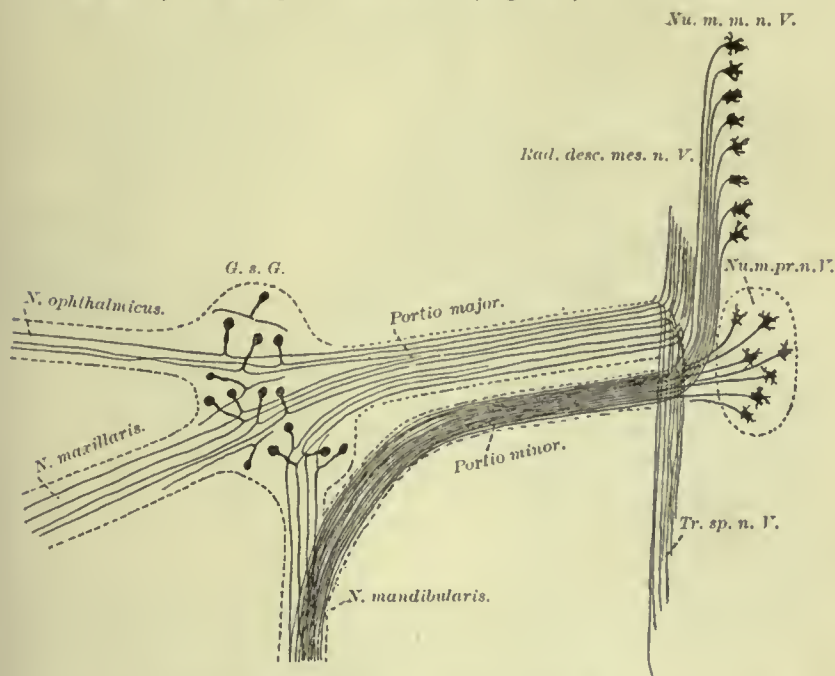


FIG. 342.—Scheme showing the motor and sensory neurones, the axones of which enter into the formation of the N. trigeminus. (After A. van Gehuechten, *Anatomie des système nerveux de l'homme*, Louvain, 1897, p. 543, Fig. 384.) *G. s. G.*, ganglion semilunare Gasseri; *Nu. m. m. n. V.*, nuclei motorii minores nervi trigemini; *Nu. m. pr. n. V.*, nucleus motorius princeps nervi trigemini; *Rad. desc. mes. n. V.*, radix descendens [mesencephalica] nervi trigemini; *Tr. sp. n. V.*, tractus spinalis nervi trigemini.

the bundle is traversed by the root bundles of the N. glosso-pharyngens and N. vagus (Fig. 344), and by some of the fibræ cerebello-olivares.

Just how far spinalward the tractus spinalis extends there seems to be a difference of opinion. According to Gudden,\* it probably reaches to the lowermost parts of the cervical cord.

\* Gudden, H. Beitrag zur Kenntniss der Wurzeln des Trigemiusnerven. *Allg. Ztschr. f. Psychiat.*, etc., Berl., Bd. xlviii (1891-'92), S. 16-33.

Obersteiner\* puts its lower limit at the level of the second cervical nerve, while von Kölliker† states that in the region of the uppermost cervical nerves there is no trace of the spinal

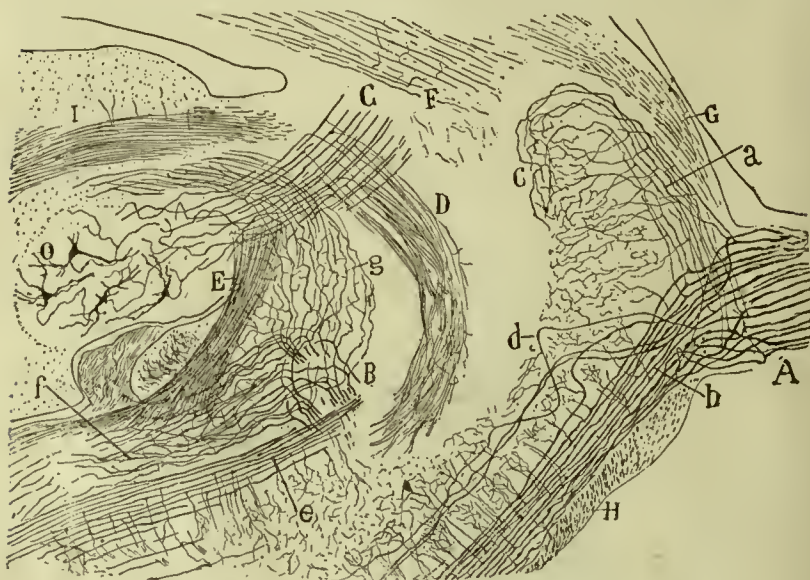


FIG. 343.—Lateral sagittal section through the pons and cerebellum of a fetal mouse, showing the sensory portion of the N. trigeminus. (After S. Ramón y Cajal, *Beitrag zum Studium der Medulla Oblongata*, etc., Leipz., 1896, S. 4, Fig. 1.) A, portio major or sensory root of N. trigeminus; the individual axones dividing into an ascending (a) and a descending limb (b); c, terminal branches of ascending limb; d, root fibres which sink into the depth; e, dorsal part of descending portion of sensory root; B, bifurcation of axones of N. vestibuli, the ascending limbs (g) going to the cerebellum, the descending limbs (f) going downward to the medulla oblongata; C, brachium conjunctivum; D, fasciculus cerebellaris descendens; E, corpus vestibiforme; F, lemniscus lateralis; H, corpus trapezoidinum; O, nucleus dentatus.

tract of the trigeminus. A little higher (about at the level at which the dorsal nuclei of the medulla begin) he finds the lower limit of the spinal tract. Cramer‡ traces it to the distal end of the pyramidal decussation.

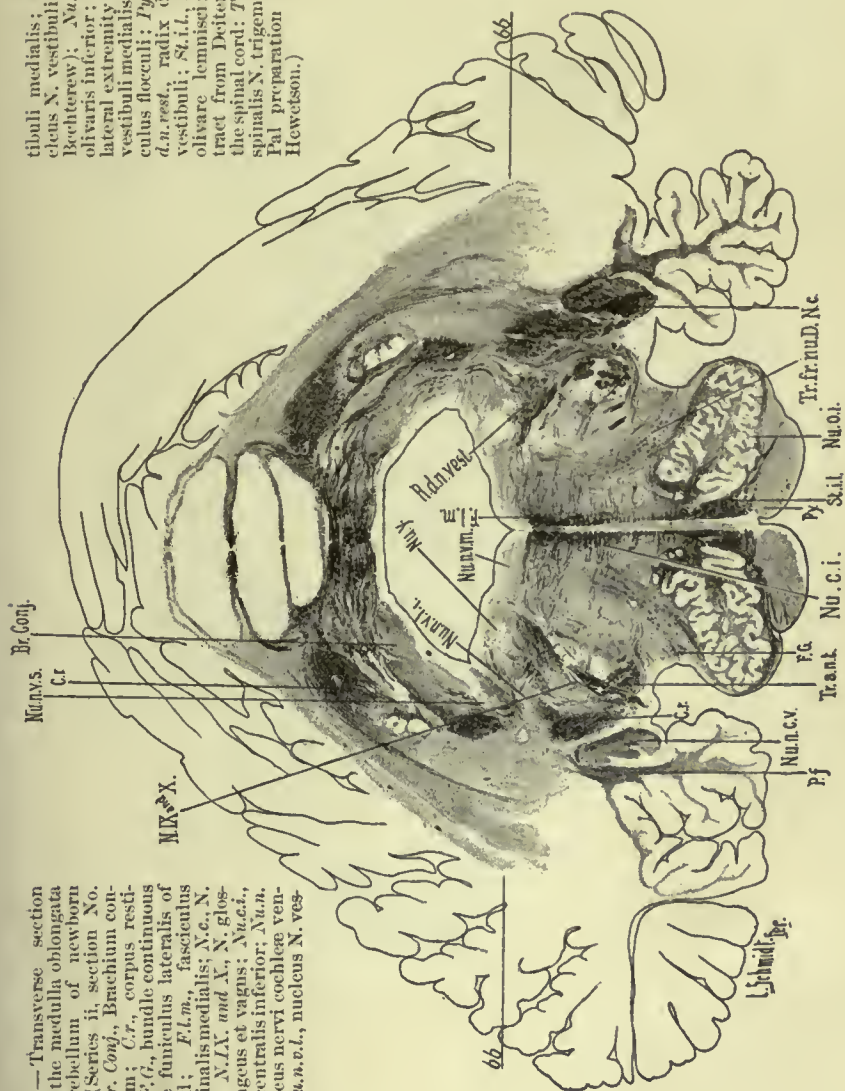
It has been shown by Golgi's method by Ramón y Cajal in sagittal sections that the two longitudinal layers of the tractus

\* Obersteiner, H. *Anleitung beim Studium des Baues der nervösen Central-Organen in gesunden u. kranken Zustände*. III Aufl., Leipzig (1896).

† *Op. cit.*, Bd. ii, S. 280.

‡ *Op. cit.*, S. 63.

tubuli medialis; *Nu.n.e.s.*, nu-  
 cleus N. vestibuli superior (von  
 Beyerew); *Nu.o.i.*, nucleus  
 olivaris inferior; *Nu.g.*, antero-  
 lateral extremity of nucleus N.  
 vestibuli medialis; *P.f.*, pedun-  
 culus flocculi; *Py*, pyramis; *R.*  
*d.n.rest.*, radix descendens N.  
 vestibuli; *St.i.l.*, stratum inter-  
 olivare lenseis; *Tr.fr.nu.D.*,  
 tract from Deiters' nucleus to  
 the spinal cord; *Tr.n.a.t.*, tractus  
 spinalis N. trigemini. (Weigert-  
 Pal preparation by Dr. John  
 Hewetson.)



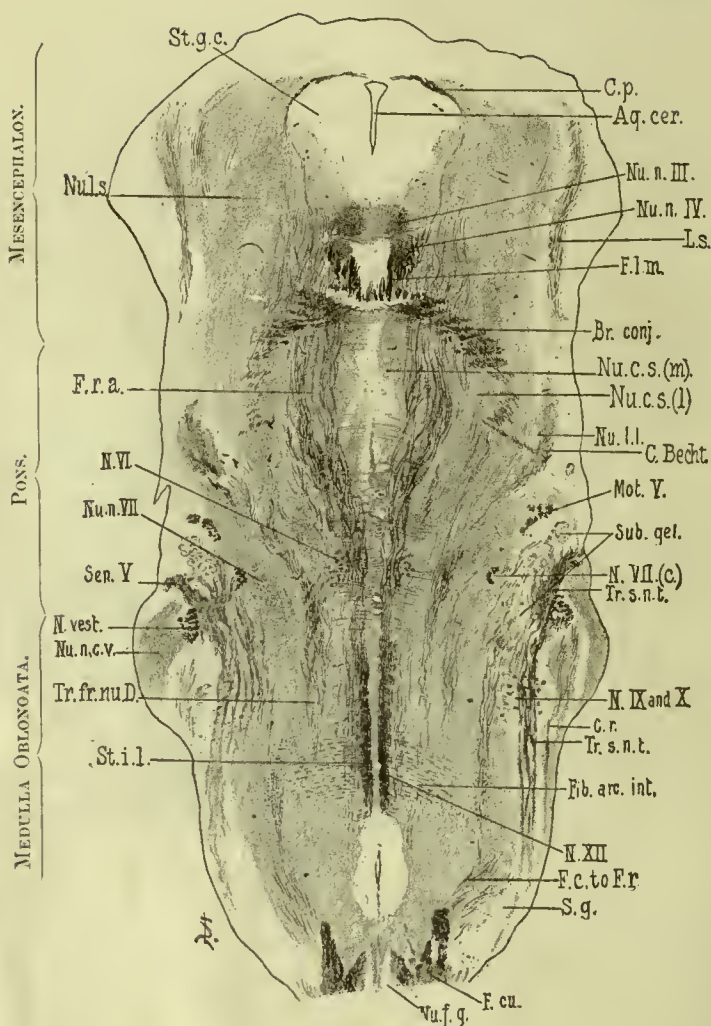


FIG. 345.



FIG. 345.—Horizontal section through the medulla, pons, and midbrain of a newborn babe. Weigert-Pal staining. Level of nucleus nervi oculomotorii and nucleus nervi trochlearis. (Series iii, section No. 100.) *Aq. cer.*, aqueductus cerebri; *Br. conj.*, brachium conjunctivum; *C.p.*, commissura posterior cerebri; *C. Becht.*, commissure between Bechterew's nuclei of the two sides; *Cl.r.*, corpus restiforme; *Fl.m.*, fasciculus longitudinalis medialis; *Fe. to Fr.*, fibres from fasciculus cuneatus to formatio reticularis; *Fib. arc. int.*, fibræ arcuatae intermæ; *F. cu.*, fasc. cuneatus; *Fr.a.*, formatio reticularis alba; *Mot. V.*, radix motorius N. trigemini; *N.VI.*, radix N. abducentis; *N. rest.*, radix N. vestibuli; *N. VII(c.)*, radix N. facialis, pars secunda; *N. IX and X*, radices Nu. glossopharyngei et vagi; *N. XII*, radix N. hypoglossi; *Nu.c.s.(m)*, nucleus centralis superior, pars medialis; *Nu.c.s.(l)*, nucleus centralis superior, pars lateralis; *Nu.l.l.*, nucleus lemnisci lateralis; *Nu.l.s.*, nucleus lateralis superior; *Nu.n. III.*, nucleus N. oculomotorii; *Nu.n. IV.*, nucleus N. trochlearis; *L.s.*, lemniscus superior; *Nu.f.g.*, nucleus funiculi gracilis; *Nu.n.er.*, nucleus N. cochleæ ventralis; *Nu.n. VII.*, nucleus N. facialis; *S.g.*, substantia gelatinosa; *St.l.l.*, stratum interolivare lemnisci; *Sen. V.*, radix sensorius N. trigemini; *St.g.c.*, stratum griseum centrale; *Sub. gel.*, substantia gelatinosa near entrance of sensory part of N. trigeminus; *Tr.s.n.t.*, tractus spinalis N. trigemini; *Tr.fr.nu.D.*, tract from Deiters' nucleus to the spinal cord. (Preparation by Dr. John Hewetson.)

FIG. 346.—Transverse section through the tractus spinalis N. trigemini and adjacent substantia gelatinosa of a newborn rabbit. (After S. Ramón y Cajal, *Beitrag zum Studium der Medulla Oblongata*, etc., Bresler, Leipz., 1896, S. 8, Fig. 2.) *A*, ventral part of tractus spinalis; *a*, interstitial cells; *c*, marginal cells; *d*, cell islands in substantia gelatinosa; *e*, small cells of these islands; *f*, stellate giant cells not arranged in islands; *g*, interinsular cells; *h*, a marginal cell, the axone of which appears to go into the white substance or into the tractus spinalis N. trigemini.

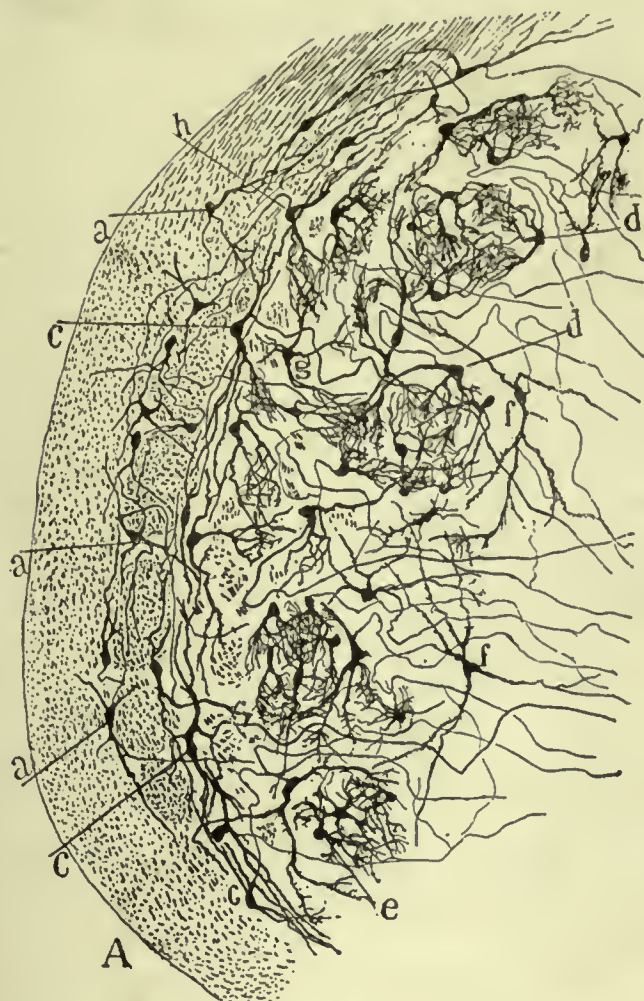

FIG. 346.

spinalis (one superficial and compact, the other deeper, and consisting of several bundles separated from one another by masses of gray matter) are formed by descending limbs of bifurcated root fibres (Fig. 343). The superficial and deeper layers of the tractus spinalis are easily demonstrable in horizontal sections of the rhombencephalon of the new-born babe, stained by the method of Weigert-Pal (Fig. 345).

The collaterals from the axones of the trigeminal fibres have been carefully studied and described by Ramón y Cajal. He divides them according to the region in which they are found into (1) interfascicular collaterals, (2) marginal collaterals, and (3) medial collaterals. The interfascicular collaterals ramify among the cell bodies lying medial to the superficial compact layer, and among the fasciculi of the deep layer of the tractus spinalis. The marginal collaterals, passing sometimes forward, sometimes backward, ramify among the peripherally placed spindle-shaped cell bodies (*Randzellen*) along the bundle of the deep layer. The medial collaterals unite to form small bundles which pass through the fibres of the deep layer, and form two or three layers of extremely dense end-plexuses in the substantia gelatinosa. Ramón y Cajal states that many of these collaterals, especially those arising from the dorsal part of the tractus spinalis, end in well-defined "cell islands" in the dorsal part of the substantia gelatinosa (Fig. 346).

The work of Bregman,\* in which the degenerations following section of the main branches of the trigeminus were studied, makes it seem certain that in the rabbit the fibres from the nervus ophthalmicus run in the ventral part of the tractus spinalis nervi trigemini, while those from the nervus maxillaris and from the nervus mandibularis run in the dorsal part of the tract. For important data regarding the functions of the tractus spinalis nervi trigemini, the case studied clinically by Hun† and pathologically by Ira van Gieson is referred to.

---

\* Bregman, E. Ueber experimentelle aufsteigende Degeneration motorischer und sensibler Hirnnerven. Arb. a. d. Inst. f. Anat. u. Physiol. d. Centralnervensyst. an d. Wien. Univ., Leipz. u. Wien (1892), S. 73-97.

† Hun, H. Analgesia, Thermic Anæsthesia, and Ataxia resulting from Fœci of Softening in the Medulla Oblongata and Cerebellum, due to Occlusion of the Left Inferior Posterior Cerebellar Artery. A Study of the Course of Sensory and Co-ordinating Tracts in the Medulla Oblongata. N. Y. M. J., vol. lxx (1897), pp. 513-519.



Van Gehuchten, in the first edition of his text-book,<sup>1</sup> described the ascending limbs of the fibres as passing up in the course of the descending mesencephalic motor root as far as the inferior colliculi of the corpora quadrigemina to the lateral region of the gray matter of the aqueduct. The studies of Lugaro,\* von Kölliker, and Ramón y Cajal, however, make it probable that the fibres of the descending mesencephalic root are chiefly, if not entirely, motor, and in the second edition of van Gehuchten's work these conclusions are agreed with.

Some authors describe sensory axones of the nervus trigeminus passing directly up into the cerebellum. The demonstration of the existence of such fibres would not be surprising, now that we know that certain of the axones of the dorsal funiculi and of the nervus vestibuli pass directly into the cerebellum without undergoing relay. Nevertheless, such a direct cerebellar tract for the nervus trigeminus has not yet been proved for human beings,† and its existence is vigorously opposed by von Beehterew‡ and Turner.\* The latter, a very careful observer, believes that what has been described as the "direct cerebellar root" || of the trigeminus corresponds to the fibres extending between the nuclei of the roof and Deiters' nucleus, and probably also to those connecting the superior olivary nuclei with the nuclei of the roof. Obersteiner,<sup>A</sup> in the last edition of his text-book, expresses the opinion that those who deny the direct relation of the nervus trigeminus to the cerebellum are in the wrong.

Centripetal impulses arriving along the fifth nerve can affect the motor nuclei in the medulla and upper cervical cord either by means of collaterals from the axones of the peripheral nerves

\* Lugaro, E. Sulle cellule d'origine della radice discendente del trigemino. Arch. di ottal., Palermo, vol. ii (1894-'95), pp. 116-119.

† van Gehuchten has followed in the embryo chick by Golgi's method trigeminal fibres directly into the cerebellum through the brachium pontis.

‡ von Beehterew, W. Ueber die Trigeminiwurzel. Neurol. Centralbl., Leipz., Bd. vi (1887), S. 289.

\* Turner, W. Aldren. The Central Connections and Relations of the Trigeminal, Vago-glossopharyngeal, Vago-accessory, and Hypoglossal Nerves. J. Anat. and Physiol., Lond., vol. xxix (1894-'95), pp. 1-15.

|| Edinger's *directe sensorische Kleinhirnbahn*.

<sup>A</sup> Obersteiner, H. Anleitung beim Studium des Baues der nervösen Centralorgane. III Aufl., Leipzig u. Wien (1896), S. 403.

themselves, or by means of collaterals or terminals of centripetal neurones of a higher order.

It will be seen that the central prolongations of the cell bodies of none of the peripheral sensory neurones collecting impressions from the body itself pass to the cerebral cortex directly. The centripetal impulses, therefore, which enter by means of these neurones into the nerve centres must be carried to the cerebral cortex through neurones with which these come in contact. But before describing these sensory neurones of a higher order it will be convenient to consider briefly the characters of the peripheral sensory neurones connecting the organs of special sense with the central nervous system.

(B) Centripetal Neurones of the First Order collecting Impressions of Special Sense (connecting Organs of Special Sense with the Central Nervous System).

Under this heading the gustatory, olfactory, visual, and auditory peripheral sensory neurones will be discussed.

## CHAPTER XXXVI.

### PERIPHERAL CENTRIPETAL NEURONES CONCERNED IN THE SENSE OF TASTE AND SMELL.

Peripheral centripetal neurones mediating taste impressions—*Nervus glossopharyngeus*—*Nervus trigeminus*—*Nervus intermedius*—Taste buds in tongue—Relation of nerve fibrils to taste bud—Intrageminal fibres—Intergeminal fibres—Specific taste qualities—Peripheral centripetal neurones mediating olfactory impressions—Perikaryons—Distal hair-like processes—Non-medullated axones—Termination in olfactory glomeruli—*Regio olfactoria* of nasal mucous membrane.

#### 1. Peripheral Gustatory Neurones.

*Gustatory Neurones.*—The peripheral sensory neurones mediating taste impressions consist of a portion of those of the *nervus glossopharyngeus* and probably also of the *nervus trigeminus* and *nervus intermedius*\* (Plate I, Fig. 2). In general, what has been said regarding the collection by the sensory neurones of the spinal and cerebral nerves of bodily impressions holds also for the nerves of taste. The peripheral branches of the ganglion cells concerned in collecting taste impressions come ultimately, however, into contact in the mouth and tongue with certain peculiar structures—the so-called taste buds.†

The structure of these bodies is well known and has been accurately described in the text-books. They are egg-shaped or barrel-shaped masses of epithelial cells situated mainly in the vallate papillæ and fimbriæ, though a few of them are scat-

---

\* In this connection the paper of A. F. Dixon—On the Course of the Taste Fibres, *Edinb. M. J.*, n. s., vol. i (1897), pp. 395–401—may be consulted with profit.

† These bodies appear to have been discovered independently by Loven and Schwalbe in 1867.

tered elsewhere over the tongue, in the soft palate, and on the epiglottis. Disse \* has recently described similar structures as

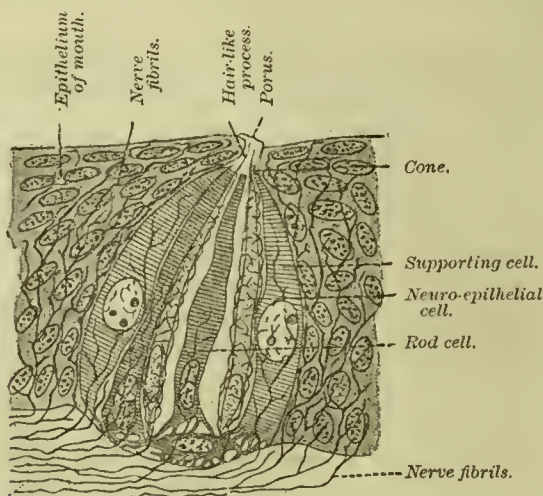


FIG. 347.—Schematic representation of a taste bud. (After Hermann, Sitzungsber. d. k.-bayer. Akad. d. Wissensch. zu München, 1888, as modified by Boehm und von Davidoff.)

occurring also in the nasal mucous membrane. They represent a differentiated portion of the epithelial part of the mucous membrane. At least two sorts of cells are present in each taste bud: (*a*) the supporting cells consisting of an outer layer with nuclei centrally placed, and an inner layer of very delicate cells with nuclei situated at the base; (*b*) the sensory cells, the so-called neuro-epithelial cells of the taste buds—delicate long-drawn-out cells which stain well by Golgi's method, and which send a hairlike process through the pore at the apex of the taste bud to the surface of the mucous membrane. It is probable that the flat cells at the base of the taste bud correspond to a special form of supporting cell (Fig. 347). The nerve fibres, as von Lenhossék † and Retzius ‡ have shown, end free in

\* Disse, J. Ueber Epithelknospen in der Regio olfactoria der Säuger. Nachr. v. d. k. Gesellsch. d. Wissensch., Götting. (1894), S. 66-71.

† von Lenhossék, M. Der feinere Bau und die Nervenendigungen der Geschmacksknospen. Anat. Anz., Jena, Bd. viii (1892-'93), S. 121-127.

‡ Retzius, G. Die Nervenendigungen in dem Geschmacksorgan der Säugetiere und Amphibien. Biol. Untersuch., Stockholm, n. F., Bd. iv (1892), S. 19-32.



among the cells of the taste bud. The old idea that the neuro-epithelial cells gave off axis-cylinder processes which ran to the nerve centres has been definitely disproved.

It is to be remembered that the mucous membrane of the tongue is supplied in general with nerve endings mediating the sensations of touch, pain, and temperature just as is ordinary skin. In addition it receives the nerve fibres which pass directly to the taste buds. The nerve fibres approaching the taste buds and becoming connected with them (intragemmal fibres of von Lenhossék) are distinguishable from the branches which terminate among the ordinary epithelial cells of the mucous membrane between the taste buds (intergemmal fibres). From two to five fibres approach the base of each taste bud, each of which on entering the bud breaks up into a fine end-arborization, the

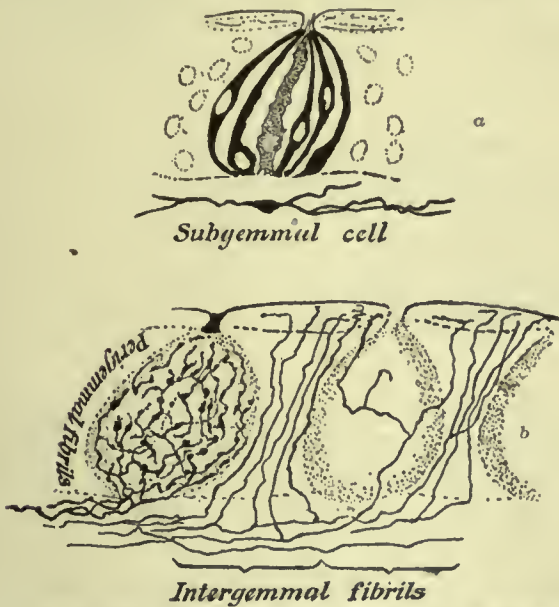


FIG. 348.—Taste buds (calyculi gustatorii) and peripheral extremities of peripheral processes of peripheral gustatory neurones, prepared by Golgi's method from the papilla foliata of the rabbit. (After M. von Lenhossék, *Anat. Anz.*, Jena, Bd. viii, 1893, S. 123, Fig. 1.) *a*, impregnated taste cells and a single supporting cell: below the taste bud a subgemmal cell is indicated; *b*, the beginnings of the nerve fibrils upon and between the taste buds.

individual fibres forming a complicated plexus about the constituent cells of the organ, though without entering into any



A general scheme of the taste conduction paths has been prepared by W. v. Bechterew. It is reproduced in Fig. 349.

## 2. Peripheral Olfactory Neurones.

The olfactory neurones of the first order extend from the mucous membrane of the nose to the olfactory bulb. The cell bodies of these neurones are, remarkable to state, situated actually in the mucous membrane of the nose itself, thus differing from all other peripheral sensory neurones (in human beings).\* It had long been known that in the olfactory region

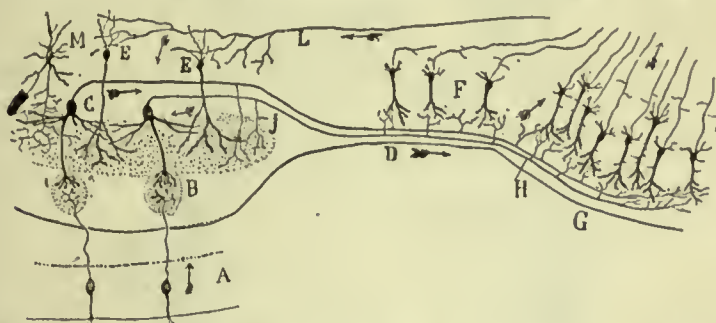


FIG. 350.—Scheme of the course followed by nerve impulses in the olfactory apparatus of mammals. (After S. Ramón y Cajal, *Les nouvelles idées*, etc., Transl. by Azoulay, Paris, 1894, p. 109, Fig. 26.) A, olfactory mucous membrane; B, olfactory glomerulus in bulb olfactorius; C, mitral cell; D, tractus olfactorius; E, olfactory "granules"; F, adjacent pyramidal cells; G, region of stria olfactoria lateralis; J, collaterals of the axones of the mitral cells in the olfactory bulb; H, collaterals of these same axones in the tractus olfactorius; I, collaterals of these same axones in the bulb olfactorius; L, centrifugal fibre terminating in the bulb olfactorius; M, Golgi cell of Type II or dendroaxone. The arrows show the direction of the impulses.

of the nasal mucous membrane cells of two kinds exist—supporting cells and sensory epithelial cells, the latter being delicate narrow cells provided with hairlike processes which project slightly upon the mucous surface. Max Schultze,† in 1862, dis-

\* It will thus be seen that in the nasal mucous membrane of human beings we meet with a sensory apparatus morphologically very similar to that which has been described in the epithelial surface of the fish worm.

† Schultze, M. Ueber die Endigungsweise der Geruchsnerven und der Epithelialgebilde der Nasenschleimhaut. *Ber. d. K. Preuss. Akad. d. Wissensch. zu Berlin* (1856), S. 504–514.—*Untersuchungen ueber den Bau der Nasenschleimhaut, namentlich die Structur und Endigungsweise der Geruchsnerven beim Menschen und den Wirbeltieren. Abhandl. d. Naturf. Gesellsch. zu Halle, Bd. vii* (1862).—*Das Epithelium der Riechschleimhaut des Menschen. Centralbl. f. d. med. Wissensch., Berl., Bd. ii* (1864), S. 385–390.

covered that from the proximal end of each olfactory cell an olfactory nerve fibre took its origin. The use of the methylene-blue method by Ehrlich \* and Arnstein † and of Golgi's method by Ramón y Cajal ‡ and van Gehuchten # has proved beyond

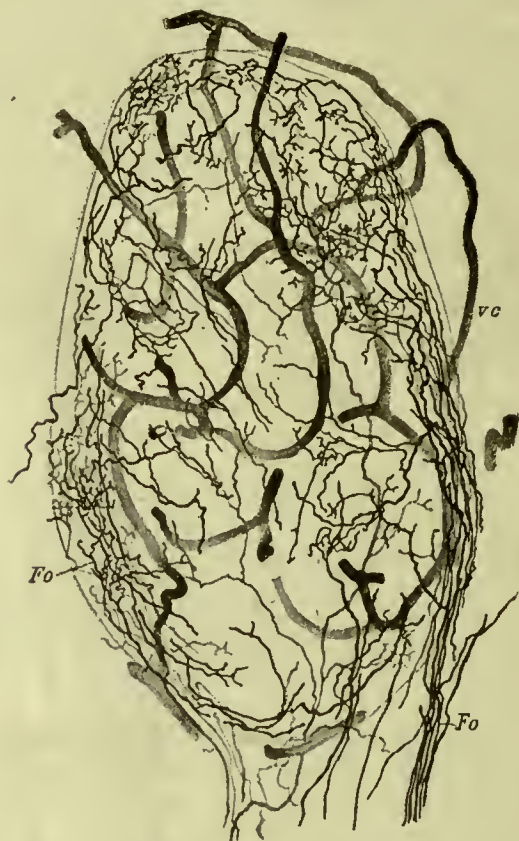

FIG. 351.—A glomerulus olfactorius from a young cat; method of Golgi. (After A. von Kölliker, *Handbuch der Gewebelehre des Menschen*, Bd. ii, Leipz., 1896, S. 701, Fig. 754). *Fo*, fila olfactoria breaking up into terminal branches inside the glomerulus; *vc*, capillary blood-vessels.

\* Ehrlich, P. *Op. cit.*

† Arnstein. Die Methylenblaufärbung als histologische Methode. *Anat. Anz.*, Jena, Bd. ii (1887), S. 125-135.

‡ Ramón y Cajal, S. Origen y terminación de las fibras nerviosas olfactorias. *Gac. san. de Barcel.* (1890).

# van Gehuchten, A. Contribution à l'étude de la muqueuse olfactive chez les mammifères. *Cellule*, Liège et Louvain (1891).



doubt that the olfactory nerve fibres really represent the axones of the cell bodies situated in the nasal mucons membrane. The short hairlike processes of these cells represent the dendrites (Fig. 350).

The nerve fibres which end free in the mucons membrane of the nose independent of olfactory epithelial cells probably belong to the nervus trigeminus, and have nothing directly to do with the carrying of olfactory impulses.

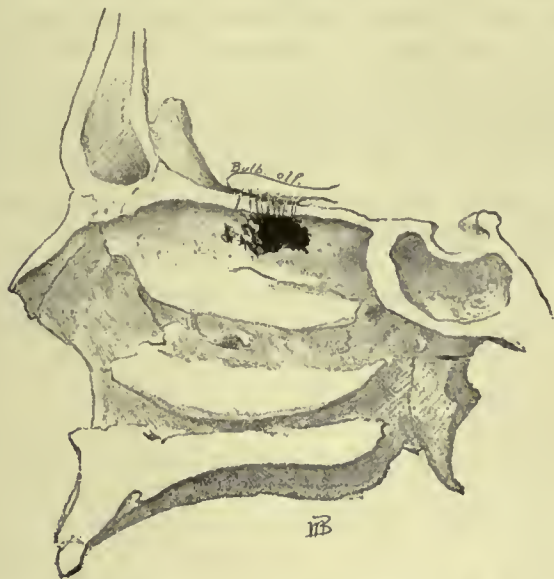


FIG. 352.—Area of nasal mucons membrane which, according to the researches of von Brunn, is innervated by Nn. olfactorii.

The axones of the olfactory neurones are non-medullated. They pass through the cribriform plate of the ethmoid bone in bundles (Nn. olfactorii) to the olfactory bulb which they enter.\* Here they terminate, as Golgi first proved, by free end-arborizations in the so-called olfactory glomeruli, coming into manifold contact inside them with the large dendrites of the mitral cells

\* For interesting data concerning accurate measurements in the domain of the bulbus and tractus olfactorius, the reader is referred to the article by H. H. Donaldson and T. L. Bolton, *The Size of Several Cranial Nerves in Man as Indicated by the Areas of their Cross Sections*. *Am. J. Psychol.*, Worcester, vol. iv (1891-'92), pp. 224-229.

of the olfactory bulb which are ultimately distributed in these structures. The mitral cells and brush cells of the olfactory bulb represent olfactory neurones of the second order and will be described subsequently. The endings of the Nn. olfactorii are well shown in Fig. 351. The dendrites of the mitral cells are not impregnated. The exact area of nasal mucous membrane concerned in the sense of smell is much smaller than many have believed. Thus, the studies of the late von Brunn\* have shown that the olfactory region is limited to a relatively small part of the superior turbinated bone and the adjacent region of the nasal septum. The area in each nostril situated at the very top probably does not exceed in extent more than two and a half square centimetres. Von Brunn in the course of his careful measurements found in one case that the olfactory epithelium extended in the right nasal cavity over a surface of 257 square millimetres. In a second case the distribution amounted to 238 millimetres (Fig. 352).

---

\* von Brunn, A. Beiträge zur mikroskopischen Anatomie der menschlichen Nasenhöhle. Arch. f. mikr. Anat., Bonn, Bd. xxxix (1892), S. 632-651.

### 3. Peripheral Visual Neurones.

## CHAPTER XXXVII.

### THE PERIPHERAL VISUAL NEURONES AND THE STRUCTURE OF THE RETINA.

Older studies of the retina—Its lamellation—Studies of Tartuferi, Ramón y Cajal, and Dogiel—Golgi preparations—The rod cells and cone cells—The bipolar cells—The ganglion cells and optic nerve fibres—Superimposition and interrelations of the retinal elements—Müller's fibres—The amacrine cells—The horizontal cells—Comparison of the peripheral visual neurones with other peripheral centripetal neurones—Von Lenhossék's study of the cephalopod eye—Reduction of elements in the visual conduction path.

*Visual Neurones.*—The peripheral sensory neurones concerned in the sense of sight are situated in the retina. The older ideas of the structure of the retina which most of us were taught in the medical schools were extremely complex, and the memorization of the exact position and appearance of the various layers of this membrane was by no means easy, since the intraretinal relations and connections of the elements were entirely obscure.

It will be recalled that externally next to (1) the layer of hexagonal pigment cells were situated (2) the layer of rods and cones. Then followed, passing inward, (3) the outer nuclear layer; (4) the outer molecular layer; (5) the inner nuclear layer; (6) the inner molecular layer; (7) the layer of nerve cells, and, lastly, (8) on the inner surface of the retina, the layer of nerve fibres. These various layers were easy to make out in preparations stained with ordinary nuclear dyes (Fig. 353), but as to what the individual layers meant, and to exactly what cells the various nuclei and processes belonged, there was much disagreement.

Instead of this unintelligible classification based simply upon staining appearances and without any rational interpretation as regards the internal connection of the elements, the newer studies

of Tartuferi,\* Ramón y Cajal,† Dogiel,‡ and others have taught us what these various layers mean. If one will compare Fig. 353 with the silver-picture of the retina (Fig. 354), the enormous simplification which has resulted from the application of Golgi's method to the study of this membrane will be immediately apparent. The silver chromate method shows that in the retina, in addition to certain more complex relations which exist, three very distinct sets of cells are superimposed: (1) The cells to which the rods and cones belong; (2) the bipolar cells; (3) the ganglion cells of the retina.\* Comparing the old classification with the present simple scheme, it will be seen that the outer

\* Tartuferi, F. *Sull' anatomia della retina*. Arch. per le sc. med., Torino, vol. xi (1887), pp. 335-358; and in the *Internat. Monatschr. f. Anat. u. Physiol.*, Leipz., Bd. iv (1887), S. 421-441.—*Sulla istologia della retina*. Ann. di ottal., Pavia, vol. xvi (1887-'88), pp. 474-476.

† Ramón y Cajal, S. *Estructura de la retina de las aves*. Rev. trimest. histol. norm., etc., Madrid, Nos. 1 y 2, Mayo, 1888.—*Sur la morphologie et les connexions des éléments de la rétine des oiseaux*. Anat. Anz., Jena, Bd. iv (1889), S. 111-121.—*Pequeñas contribuciones al conocimiento del sistema nervioso*. III. La retina de los batracios y reptiles, Agosto (1891).—*Notas preventivas sobre la retina y gran simpatico de los mamíferos*. Barcelona Dic., 1891.—*La retina de los Telosteos y algunas observaciones sobre la de los vertebrados superiores*, Madrid, 1892.—*El nuevo concepto de la histología de los centros nerviosos*. Rev. de cien. méd. de Barcel., vol. xviii (1892), pp. 361-376; 457-476, etc.—*La rétine des vertébrés*. Cellule, Lierre et Louvain, t. ix (1894), pp. 121-246.—*Neue Darstellung vom histologischen Bau des Centralnervensystems*. Arch. f. Anat. u. Physiol., Anat. Abth., Leipz. (1893), S. 319-428.—*Die Retina der Wirbelthiere*. Untersuchungen mit der Golgi-Cajal'schen Chromsilbermethode und der Ehrlich'schen Methylenblaufärbung. In Verbindung mit dem Verfasser zusammengestellt, uebersetzt, und mit Einleitung versehen von R. Greef, Wiesbaden (1894).

‡ Dogiel, A. S. *Ueber das Verhalten der nervösen Elemente in der Retina der Ganoiden, Reptilien, Vögel, und Säugethiere*. Anat. Anz., Jena, Bd. iii (1888), S. 133-143.—*Ueber die nervösen Elemente in der Netzhaut der Amphibien und Vögel*. Ibid., Bd. iii (1888), S. 342-347.—*Ueber die nervösen Elemente in der Retina des Menschen*. Arch. f. mikr. Anat., Bonn, Bd. xxxviii, S. 317-344.—*Ueber die nervösen Elemente in der Retina des Menschen*. Arch. f. mikr. Anat., Bonn, Bd. xl (1892), S. 29-38.—*Zur Frage ueber den Bau der Nervenzellen und ueber das Verhältniss ihres Achseneylinder-(Nerven)-Fortsatzes zu den Protoplasmafortsätzen (Dendriten)*. Arch. f. mikr. Anat., Bonn, Bd. xli (1893), S. 62-87.—*Neuroglia der Retina des Menschen*. Arch. f. mikr. Anat., Bonn, Bd. xli (1893), S. 612-623.—*Zur Frage ueber das Verhalten der Nervenzellen zu einander*. Arch. f. Anat. u. Physiol., Anat. Abth., Leipz. (1893), S. 429-434.

\* For one ganglion cell there are about one hundred rod and cone cells.



nuclear layer corresponds to the nuclei of the cells whose distal processes represent the rods and cones, while the inner nuclear

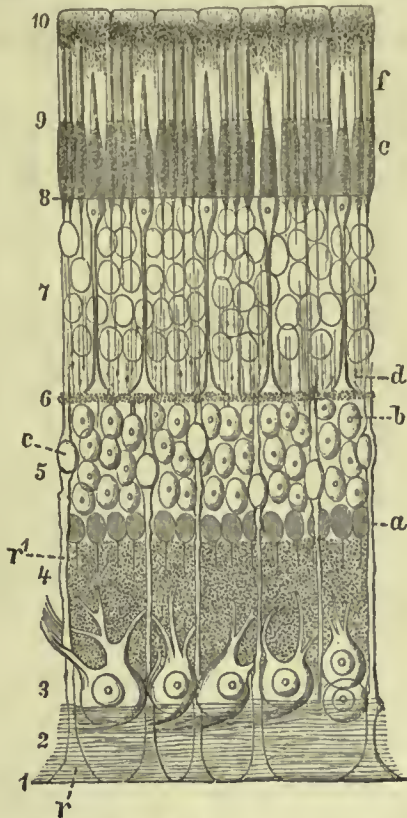


FIG. 353.—Transverse section through the retina of man. (Schematic, after M. Schultze, as modified by G. Schwalbe, *Lehrbuch der Anatomie der Sinnesorgane*, Erlangen, 1885, S. 98, Fig. 48.) 1, margo limitans internus; 2, layer of nerve fibres; 3, layer of ganglion cells; 4, internal reticular layer; 5, internal granular layer; a, spongioblasts; b, cells of the ganglion retine; c, nuclei of Müller's radial fibres; d, external reticular layer; e, layer of visual cells; 7, their nuclei (external granular layer); 8, membrana limitans externa; 9, rods and cones; d, zone of the external granular layer free from nuclei (Henle's external fibre layer); e, inner limbs of rods; f, outer limbs of rods; 10, pigment epithelium; r, wedge of Müller's fibres; r', Müller's fibre.

layer corresponds to the nuclei of the bipolar cells. The outer molecular layer represents the region of contact or conerescence relation between the proximal processes of the rod and cone cells and the distal processes of the bipolar cells, while the inner molecular layer corresponds to the region in which the ter-

minals of the proximal processes of the bipolar cells enter into contact or conereseence relation with the dendrites of the ganglion cells of the so-called "layer of nerve cells." The layer of nerve fibres represents the axones arising from the cell bodies

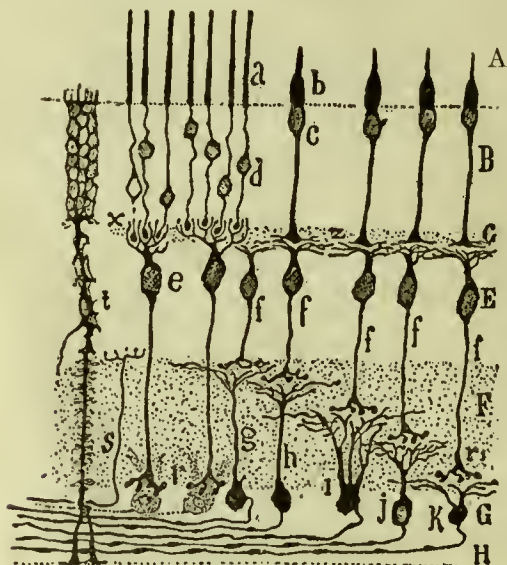


FIG. 354.—Scheme of the structure of the retina. (After S. Ramón y Cajal, *Die Retina der Wirbelthiere*, Uebersetz. v. Greiff, Wiesb., 1894, S. 17, Fig. 2.) A, layer of rods and cones; B, bodies of visual cells (external nuclear layer); C, external plexiform layer; E, layer of bipolar cells (internal nuclear layer); F, internal plexiform layer; G, layer of ganglion cells; H, layer of nerve fibres; a, rods; b, cones; c, bipolar (rod) cells; f, bipolar (cone) cells; r, lower branching of bipolar (rod) cells; r<sub>1</sub>, lower branching of bipolar (cone) cells; g, h, i, k, ganglion cells branching in different layers of the internal plexiform zone; x, contact between the rods and the bipolar (rod) cells; z, contact between the cones and the bipolar (cone) cells; t, Müller's cells; s, centrifugal nerve fibre.

in the "layer of nerve cells." These axones pass over the inner surface of the retina to reach the blind spot of the eye where they penetrate through the whole retina and make up the constituent fibres of the optic nerve. The nerve fibres of the optic nerve undergo partial decussation with those of the opposite side in the optic chiasm, and pass through the optic tracts to terminate in the corpora quadrigemina, lateral geniculate bodies, and pulvinar of the two sides (Fig. 355).

These three sets of elements—the rod and cone cells, the bipolar cells, and the ganglion cells—represent the principal

morphological constituents of the retina. There are, however, certain other elements present in this membrane which must be mentioned, though their relations to the principal elements, while they have been carefully studied, are not yet satisfactorily understood. These are (1) the so-called Müller's fibres (spongioblasts of His), which correspond to the ependymal framework of the spinal cord and brain; (2) the so-called amacrine\* cells of Ramón y Cajal (also sometimes called spongioblasts), which occur in the inner molecular layer, and which appear to be

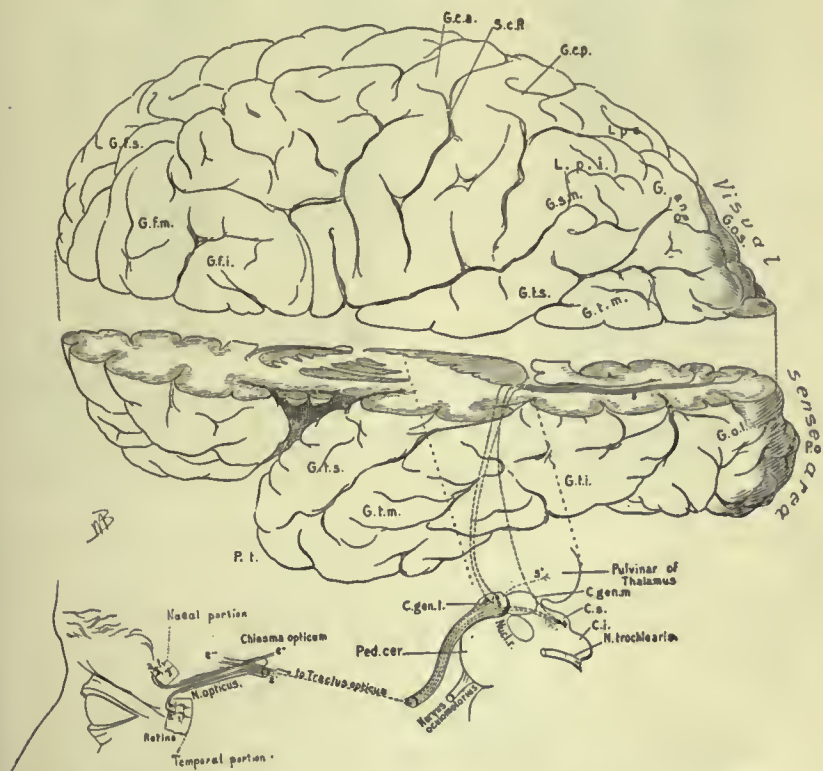


FIG. 355.—Scheme of visual conduction path. Lettering same as for Plate II, Fig. 1.

anaxones; and (3) the horizontal cells, outer and inner, of the outer molecular layer.

\* a privative, μακρος long, and ισος fibre.

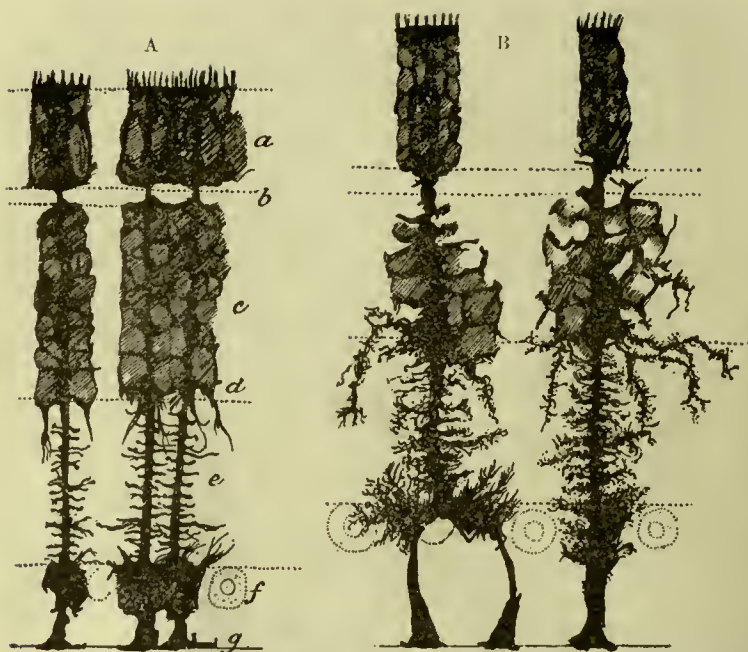


FIG. 356.—Epithelial cells (Müller's fibres) of the retina. (After S. Ramón y Cajal, *Die Retina der Wirbelthiere*, Uebersetz. v. Greeff, Wiesb., 1894, Taf. vi, Figs. 1 and 2.) A, Müller's fibres from the retina of the frog; a, external nuclear layer; b, external plexiform layer; c, internal nuclear layer; d, layer of spongioblasts; e, internal plexiform layer; f, layer of ganglion cells; g, basal layer or membrana limitans interna. B, Müller's fibres or epithelial cells from the retina of *Cyprinus carpio*.

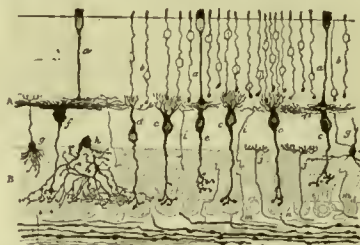


FIG. 357.—A section through the retina of an adult dog. (After S. Ramón y Cajal, *Die Retina der Wirbelthiere*, Uebersetz. v. Greeff, Wiesb., 1894, Taf. v, Fig. 2.) a, cone fibre; b, granule and fibre of a rod; c, bipolar cell with ascending end-brush belonging to the rods; d, bipolar cell with end-brush spread out flat belonging to the cones; e, giant bipolar cell with end-brush spread out flat; f, diffuse amacrine cell, the varicose branches of which lie for the most part directly upon the ganglion cells; g, ascending nerve fibres; h, centrifugal fibres; i and j, special cells which are very rarely impregnated; k, ganglion cell which receives the end-brush of a bipolar cell destined for the rods; l, nerve fibre which becomes lost in the internal plexiform layer; m, nerve fibre of the optic-fibre layer.



The shape of Müller's fibres is shown in the accompanying figure (Fig. 356). It is not improbable that they represent supporting cells.

The anaxones (amacrine cells) represent, in all probability, mechanisms for correlating the activities of the different neurones (bipolar cells and ganglion cells) with which they come into relation in the inner molecular layer. Since it is exactly

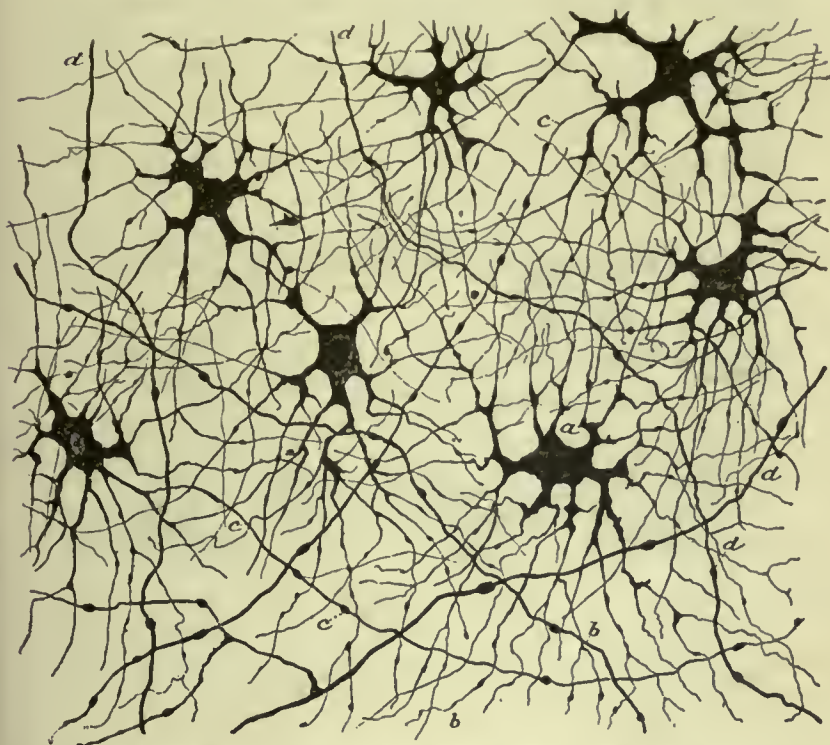


FIG. 358.—Nerve cells of the retina of the ox, stained with methylene blue; method of Ehrlich-Dogiel. (After S. Ramón y Cajal, *Die Retina der Wirbelthiere*, Uebersetz. v. Greeff, Wiesb., 1894, Taf. vii, Fig. 9.) This figure shows the external or small horizontal cells. *a*, cell body containing very intense blue spots; *b*, very fine and much-branched dendrites; *c*, axones without visible collaterals; *d*, single axis cylinders which often branch and which probably arise from the large or internal horizontal cells.

in their neighborhood in the retina that the few centrifugal fibres of the optic nerve terminate, it is not impossible that the influence exerted by the cerebral centres upon the retinal activities is mediated by these cells (Fig. 357).

The horizontal cells of the outer molecular layer can be divided into two groups—an external group (*cellule superficiali di grandezza media* of Tartuferi) and an internal set (large superficial cells of Tartuferi, large and small stellate cells of Dogiel).

The external horizontal cells are very numerous, and have long diverging dendrites, which spread out to form a thick plexus (Fig. 358). Their axones are extremely delicate and difficult to find, but are described by Ramón y Cajal as coming off usually from a dendrite. The axones and collaterals are distributed in the superficial portion of the outer molecular layer.

The inner horizontal cells (Fig. 359) are of two sorts: (*a*) Those with descending dendrites, and (*b*) those without de-




FIG. 359.—A perpendicular section through the retina of the ox. (After S. Ramón y Cajal, *Die Retina der Wirbelthiere*, Uebersetz. v. Greeff, Wiesb., 1894, Taf. vi, Fig. 12.) *a*, internal horizontal cell with descending process; *b*, another cell of the same sort without descending process; *c*, mitral-shaped amacrine cell with two branches which go in opposite directions; *d*, large amacrine cell for the fourth sub-layer; *e*, small ganglion cell which branches in the second sub-layer; *f*, *g*, *h*, *i*, *j*, different types of neuroglia cells; *k*, interstitial amacrine cell which branches chiefly in two sub-layers.

scending dendrites. The axones of the cells with descending dendrites are very thick and long and devoid of collaterals. According to Dogiel, these axones descend in order to enter the layer of optic nerve fibres, a view denied by Ramón y Cajal, who finds that they are distributed to the external molecular layer itself. The axones of the inner horizontal cells without descending dendrites are also thick and run horizontally for a considerable distance. It seems probable that the function of the horizontal cells of both sets (outer and inner) is to bring

into relation definite groups of rods with other definite groups lying at a distance.

The question at once arises, Which of the elements mentioned are to be looked upon as the peripheral visual neurones analogous to the peripheral spinal centripetal neurones and to the peripheral olfactory neurones? This question is not so easily decided, and is made more complicated by the fact that the whole retina arises embryologically (*vide* Section IV) from the central nerve tube, and not from a separate basis, as do the spinal and cerebral ganglia. I prefer, though this opinion may not be shared by all, to look upon the bipolar cells of the retina as the analogues of the spinal ganglion cells; their distal processes are then comparable to the afferent fibres in the peripheral spinal nerves, and their proximal processes to the axones of the fibres of the dorsal roots. The rods and cones would then correspond to differentiated epithelial ependymal cells\* with which the peripheral processes of the bipolar cells come in contact, just as the so-called neuro-epithelial cells of the taste buds in the tongue stand in contact relation to the peripheral fibres of the glossopharyngeal and other cerebral nerves, or as the *Tastzellen* of Merkel are related to the peripheral processes of spinal-ganglion cells. The axones of the bipolar cells would find their "nuclei of termination" in the outer molecular layer and in the ganglion cell layer of the retina; the latter would be analogous then to the gray matter of the spinal cord and medulla (of the general spinal sensory paths), to the nucleus alæ cinereæ and nucleus tractus solitarii (of the gustatory conduction path), and to the olfactory bulb (of the olfactory sensory conduction path). This would make the ganglion cell layer of the retina, the optic nerves, and the optic tracts parts of the central nervous system. The optic nerve is then, in a sense, not a peripheral nerve. Inasmuch, therefore, as we are here considering only the sensory neurones of the first order, the optic nerve and its course and termination will be described when the sensory neurones of higher orders are considered. It is only fair in conclusion to state that the recent studies of

---

\* This view is all the more enticing in that recent studies tend to show that the outer limbs of the rods and cones represent structures formed of the cilia of the ependymal cells coiled up and glued together. Cf. Krause, W. Uebersicht der Kenntnisse vom Bau der Retina im Jahre 1895. Schmidt's Jahrb., Leipz., Bd. cexlix (1896), S. 96; 201.



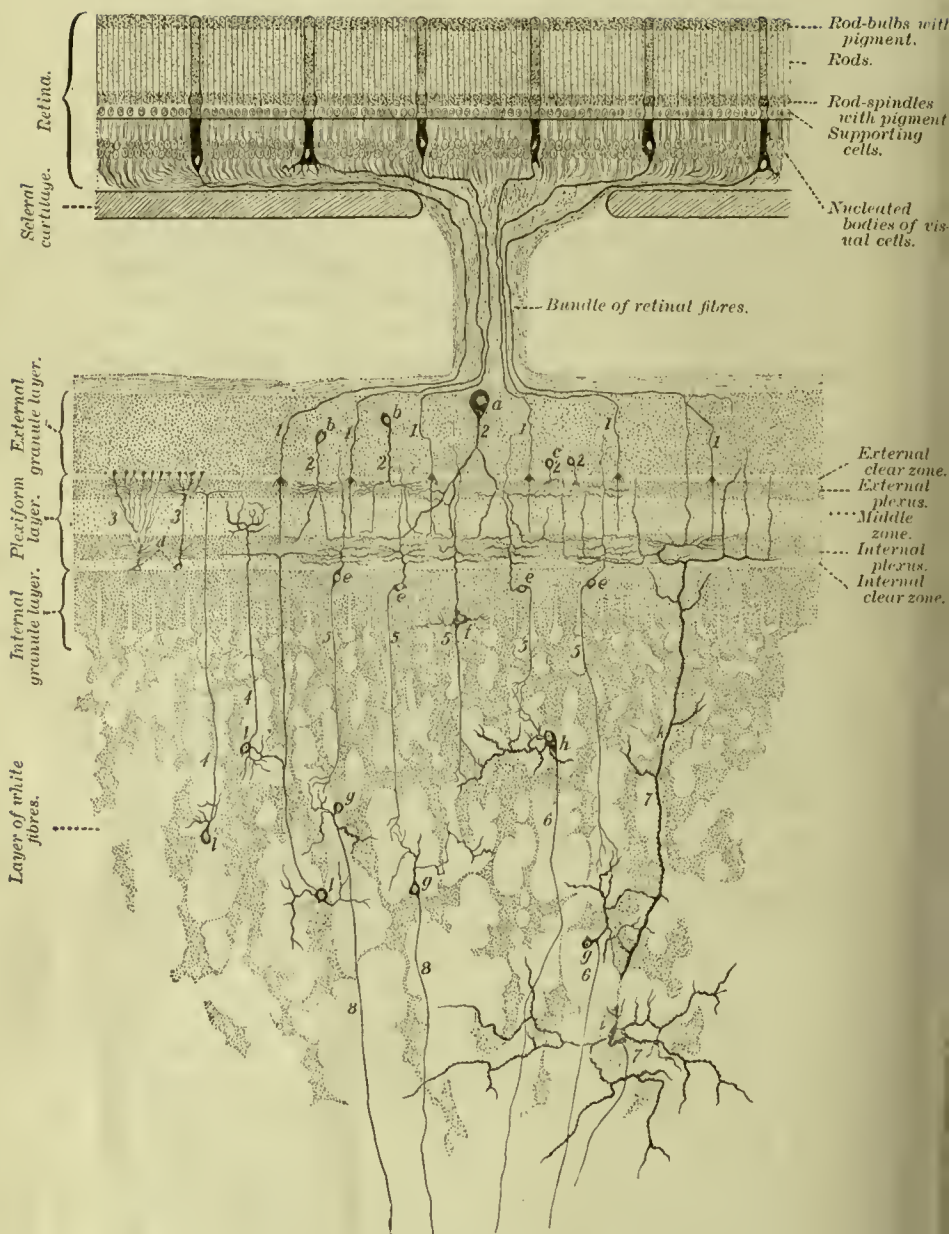


FIG. 360.



M. von Lenhossék\* make it extremely probable that the rod and cone cells in some animals are really true peripheral visual neurones (Fig. 360). If this be true, then the bipolar cells of the retina must in such animals be regarded as visual sensory neurones of the second order. There is no objection, so far as I know, to considering the rod cells and cone cells of the retina of human beings as actual *neurones*. No analogous cell is, however, existent in the olfactory mucous membrane.

In mammals two kinds of bipolar cells (*arbitrarily speaking*, optic neurones of the first order) occur: (1) bipolar cells for the rods, with vertical end-tufts, which enter into conduction relation with the terminal spherules of the rod cells, and (2) bipolar cells for the cones, the dendrites of which form end-tufts, which lie in a deeper plane than those for the rods; these end-tufts enter into conduction relation with the terminal bulgings and fibrillæ of the cone cells. The bipolar cells nearly always come into conduction relation with several of the rod cells, or of the cone cells. The number, however, varies; while one bipolar cell may stand in relation to only a few, another may be in a position to receive impulses from a great many. In the fovea centralis, where the number of cone cells is enormous, the individual cones are very delicate, and the basal swelling of each cone comes into contact exclusively with the dendritic tuft of a single bipolar cell.

---

\* von Lenhossék, M. Histologische Untersuchungen aus Schlappen der Cephalopoden. Arch. f. mikr. Anat., Bonn, Bd. xlvii (1896), S. 45-120.

---

FIG. 360.—Schematic representation of the structure of the retina and visual lobe of Eledone. (After M. von Lenhossék, Arch. f. mikr. Anat., Bonn, Bd. xlvii, 1896, Taf. viii.) In the retina only a few visual cells are represented. Such a cell consists of a distal prolongation, the "rod apparatus," and of the actual nucleated cell body. The latter gives off, at least in some cases, at its basal extremity some short protoplasmic fibrils. Every cell is continuous with a nerve fibre, which passes as a "retinal fibre" after perforating the cartilaginous sclera to the visual lobe. In the latter it ends in the region of the plexiform layer, partly in its external plexus with a delicate fibrillary arborization, partly through a descending branch on the external limit of the internal horizontal plexus. In the external granule layer there are three varieties of cells: The superficial large cells, 2 (*a*); the larger external granules, 2 (*b*); and the smaller external granules, 2 (*c*). In the plexiform layer, the autochthonous elements only, the glia cells, 3 (*d*), are represented. Of the elements of the internal granular layer (5, 5, 5), the cells 5 (*e*) correspond to the smaller, the cell 5 (*f*) to the larger variety of internal granule cells. Their axones go down into the medullated substance to end there with free ramifications (hypothetical). In the medullary layer the cells are of the ordinary type (6, 6, 6)—that is, cells with descending axones, of which there are smaller, 6 (*g*), and larger, 6 (*h*), examples. The cells, 4 (*i*), represent the rarer form—namely, the cells with ascending axones; finally, at the bottom, is shown a very large giant cell, 7 (*i*), which sends its axone, as do most of the cells in the medullary layer, into the peduncle.

## CHAPTER XXXVIII.

### THE PERIPHERAL AUDITORY NEURONES AND THE SPIRAL ORGAN OF CORTI.

The nervus cochleæ—Ganglion spirale—The cochlear root of the acoustic nerve—Peripheral processes and the organ of Corti—Central axones—Nuclei of termination—Bifurcation of axones—Terminals and collaterals.

#### 4. The Peripheral Auditory Neurones.

THE peripheral neurones of the auditory paths are those which enter into the formation of the radix cochlearis N.

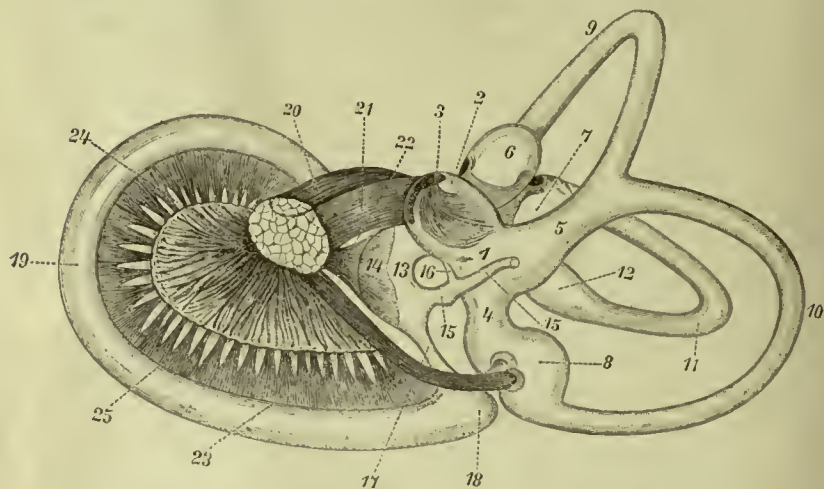


FIG. 361.—The labyrinth membranaceus of the right internal ear of a human embryo at the fifth month, seen from the medial side. (After G. Retzius, as slightly modified by A. Rauber.) 1-5, utricle; 2, recessus utriculi; 3, macula acustica utriculi; 4, sinus posterior; 5, sinus superior; 6, ampulla membranacea superior; 7, ampulla membranacea lateralis; 8, ampulla membranacea posterior; 9, ductus semicircularis superior; 10, ductus semicircularis posterior; 11, ductus semicircularis lateralis; 12, widened mouth of crus simplex of the lateral semicircular canal opening into the utricle; 13, sacculus; 14, macula acustica sacculi; 15, ductus endolymphaticus; 16, ductus utriculosaccularis; 17, ductus reuniens; 18, cæcum vestibulare of ductus cochlearis; 19, ductus cochlearis; 20, N. facialis; 21-24, N. acusticus; 21, N. vestibuli; 22, N. saccularis; 23, N. ampullaris inferior; 24, N. cochleæ; 25, distribution of N. cochleæ within the lamina spiralis ossea.

acustici, or so-called *nervus cochleæ*\* (Fig. 361). The cell bodies are situated in the ganglion spirale (ganglion of Corti) which lies in the bony cochlea† (Fig. 362). These cells remain

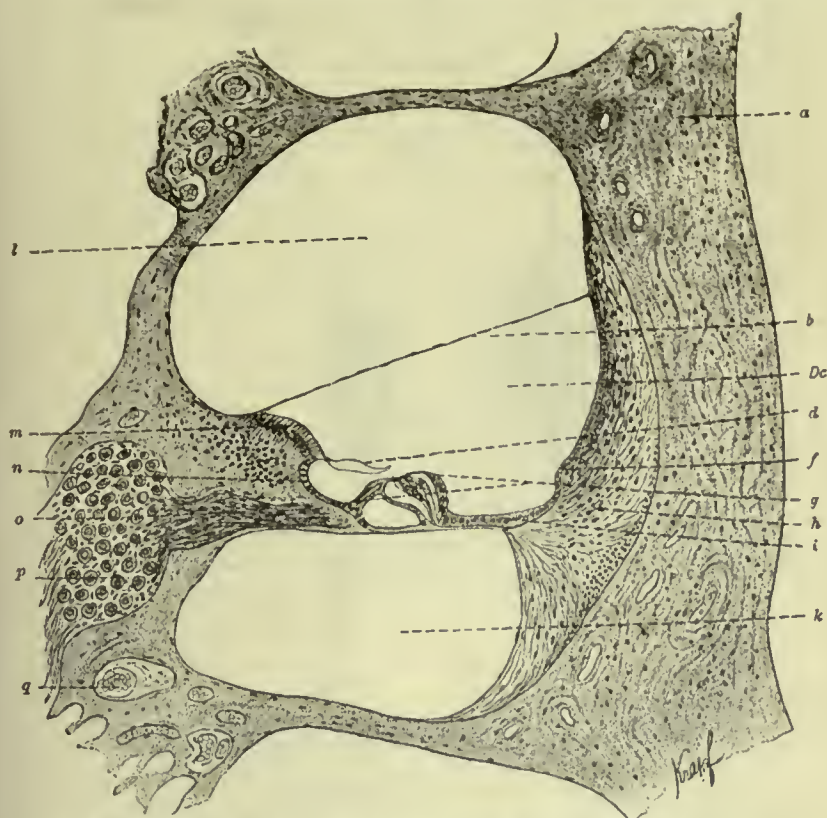


FIG. 362.—Section through the cochlear region of the labyrinth ossens et membranaceus of a guinea-pig. (After A. A. Boehm and M. von Davidoff, *Lehrbuch der Histologie des Menschen*, etc., Wiesb., 1895, S. 362, Fig. 243.) *l*, scala vestibuli; *m*, labium vestibulare of the limbus; *n*, sulcus spiralis; *o*, medullated peripheral fibres arising from cells in the ganglion spirale and being distributed to the organon spirale (Corti); *p*, perikaryons in the ganglion spirale; *q*, blood-vessel; *a*, bone; *b*, membrana vestibularis (Reissner); *Dc*, ductus cochlearis; *d*, Corti's membrane; *f*, prominentia spiralis; *h*, ligamentum spirale cochleæ; *i*, lamina basilaris; *k*, scala tympani.

\* There is no proof that in higher animals the neurones of the *nervus vestibuli* are concerned with impulses which have to do with the perception of sound.

† Sala, L. (Sur l'origine du nerf acoustique. *Arch. ital. de biol.*, Turin, t. xvi (1891-'92), pp. 196-207), believes, in agreement with Onufrowicz, that

bipolar (*vide supra*) throughout life (Fig. 363). The peripheral processes run out to end free without manifold branching in among the epithelial cells of the spiral organ of Corti (Ret-

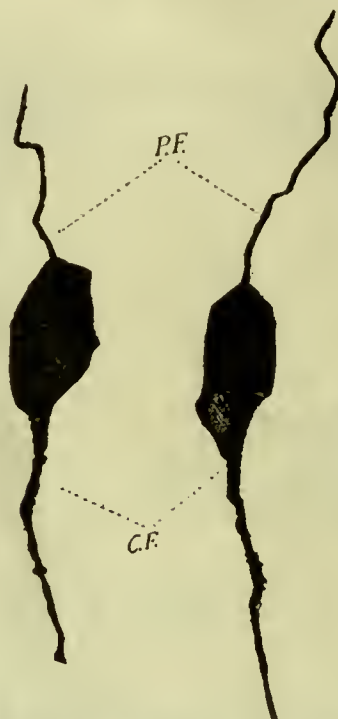

FIG. 363.—Two bipolar cells from the ganglion spirale cochleæ of a young mouse. Method of Golgi. (After M. von Lenhossék, *Anat. Hefte*, Wiesb., Bd. iii, H. ix, 1893, Taf. xiii, Fig. 1.) P.F., peripheral process; C.F., central axone.

zius,\* van Gehuchten †) inside the ductus cochleæ ‡ (Fig. 364). The medullated central prolongations or axones of these cells massed together make the nervus cochleæ (posterior lateral or

---

many of the cell bodies of the peripheral auditory neurones are situated in the ventral cochlear nucleus, but this view has not been supported by subsequent investigators.

\* Retzius, G. *Die Endigungsweise des Gehörnervens*. Biol. Untersuch., Stockholm, n. F., Bd. iii (1892), S. 29–36.

† van Gehuchten, A. *Contribution à l'étude des ganglions cérébro-spinaux*. Cellule, Liège et Louvain, t. viii (1892), p. 226.

‡ The nervus sacculi with peripheral distribution in the macula acustica sacculi is a branch of the nervus cochleæ.



cochlear root of the nervus acusticus). They pass into the central nervous system at the junction of the medulla with the pons, and enter into relation with definite masses (mainly the nucleus N. cochleæ ventralis, and the nucleus N. cochleæ dorsalis, nucleus tuberculi acustici) of gray matter in which are situated the cell bodies and dendrites of large numbers of sensory neurones of the second order.

The cochlear nerve as it enters the rhombencephalon passes dorsalward and spinalward lateral from the corpus restiforme into the medial side of the large nucleus nervi cochleæ ventralis, in which a large number of its fibres terminate (Fig. 365). A bundle of considerable size, however, can be followed in Weigert-Pal preparations as far as the nucleus nervi cochleæ

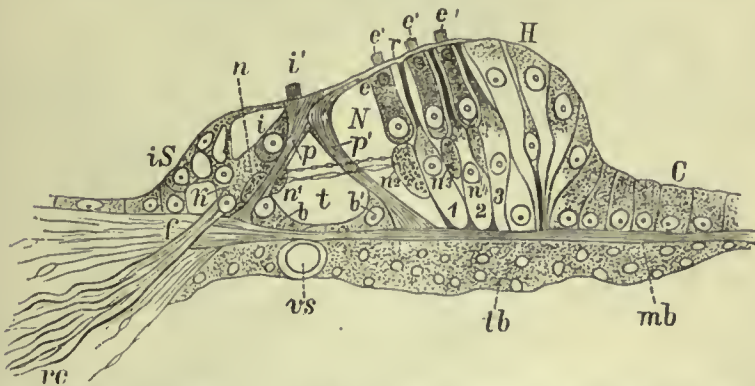
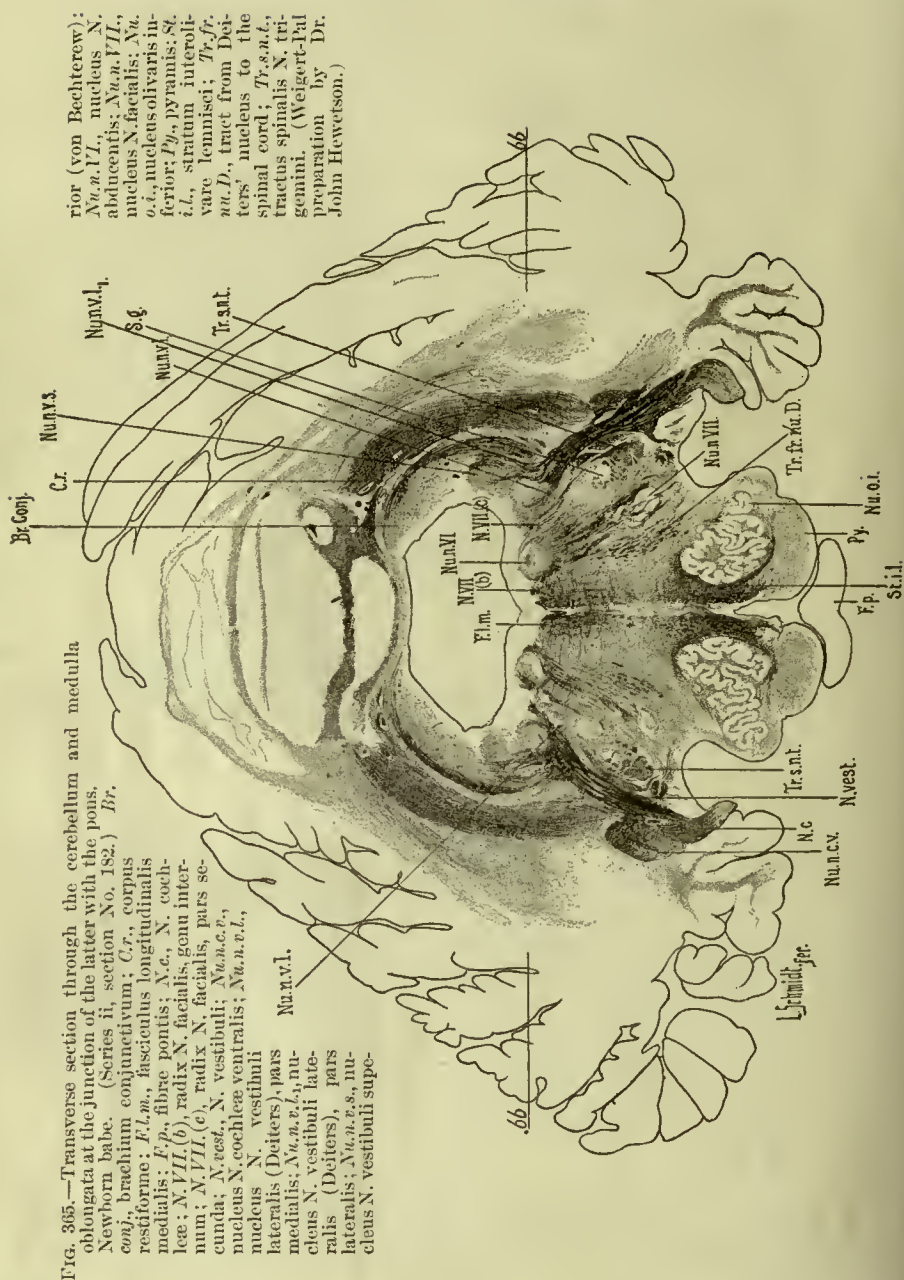


FIG. 364.—Spiral organ of Corti of the ductus cochlearis in transverse or radial section. (After G. Retzius, from A. Rauber's text-book, 1898, S. 818, Fig. 743.) *rc*, medullated distal processes of bipolar nerve cells in ganglion spirale; *f*, foramen nervosum in labium tympanicum giving passage to a bundle of the cochlear nerve fibres; *tb*, tympanic covering of lamina basilaris; *rs*, vas spirale; *iS*, internal supporting cells which on the left side are continuous with the epithelium of the sulcus spiralis; *p*, internal pillar with an inner basal cell (*b*) next to it; *p'*, external pillar with its external basal cell, *b'*; *1*, *2*, *3*, Deiters' supporting cells with phalangeal processes arriving at the surface of Corti's organ, there attached to the lamina reticularis, *r*; *H*, Hensen's supporting cells which diminish in height toward the right side of the figure and are continuous with *C*, the cells of Claudius; *k*, epithelial cells of the so-called "layer of granules"; *i*, internal hair cell, the upper end of which is hidden by the "head" of the internal pillar; *i'*, hairs of internal hair cell; *e*, external hair cell; *e'*, *e'*, *e'*, hairs of three external hair cells; *n*, *n*<sup>1</sup> to *n*<sup>4</sup>, various cross sections of the spiral cord of nerve distribution; the "tunnel cord" extends from *n*<sup>1</sup> to *n*<sup>4</sup> as a radial bundle; *t*, tunnel space; *N*, Nuel's space.

dorsalis, where the fibres appear to be continuous with the medullated fibres in the medial portion of this nucleus (Fig. 366, right side of figure). It is probable that the majority of the



fibres of this bundle terminate here, though some of them may pass directly through the dorsal cochlear nucleus to enter the striae medullares (sive acusticae), or, passing over the dorsal border of the corpus restiforme, plunge down to the region of the homolateral superior olivary complex and lateral lemniscus (Held). The position of the areas corresponding to the ven-

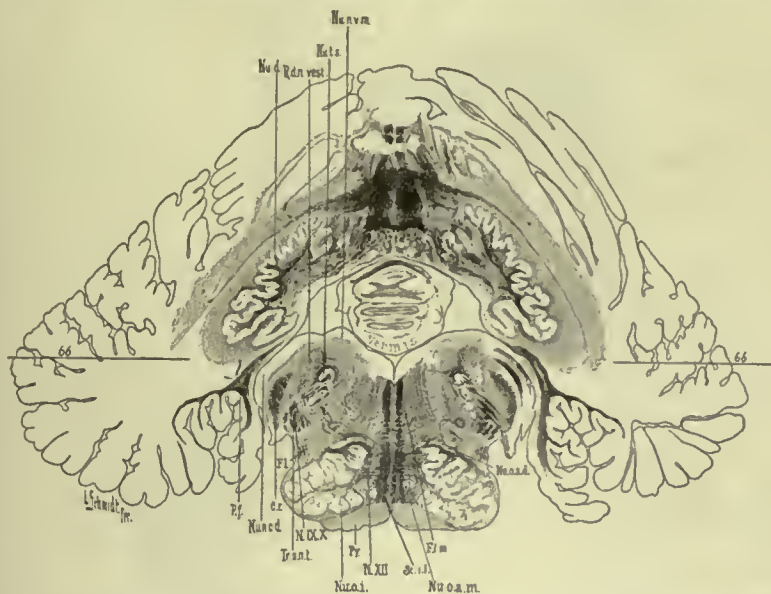


FIG. 366.—Transverse section of medulla oblongata and cerebellum of newborn child. (Series ii, section No. 146.) *C.r.*, corpus restiforme (the part medullated corresponds in the main to the direct cerebellar tract); *F.L.m.*, bundle continuous with the funiculus lateralis of the cord; *F.L.m.*, fasciculus longitudinalis medialis; *N.IX.X.*, N. glossopharyngeus et vagus; *N.XII.*, N. hypoglossus; *Nu.d.*, nucleus dentatus; *Nu.n.c.d.*, nucleus N. cochleae dorsalis shown more typically on opposite side of figure; *Nu.n.v.m.*, nucleus N. vestibuli medialis; *Nu.o.a.d.*, nucleus olivaris accessorius dorsalis; *Nu.o.a.m.*, nucleus olivaris accessorius medialis; *Nu.o.i.*, nucleus olivaris inferior; *Nu.t.s.*, nucleus tractus solitarii; *P.f.*, pedunculus flocculi; *Py.*, pyramis; *R.d.n.vest.*, radix descendens N. vestibuli; *St.i.l.*, stratum interolivare lemnisci; 66, plane of longitudinal section No. 66. [NOTE.—This figure has been disproportionately reduced in the reproduction.]

tral and dorsal cochlear nuclei, and the relation of these to the entering root bundle, and to the corpus trapezoidum, are well shown in Florence Sabin's second diagram (Fig. 367). The two nuclei, though practically continuous with one another, are fundamentally different in structure, and a very little study enables one, even with low powers of the microscope, to differen-

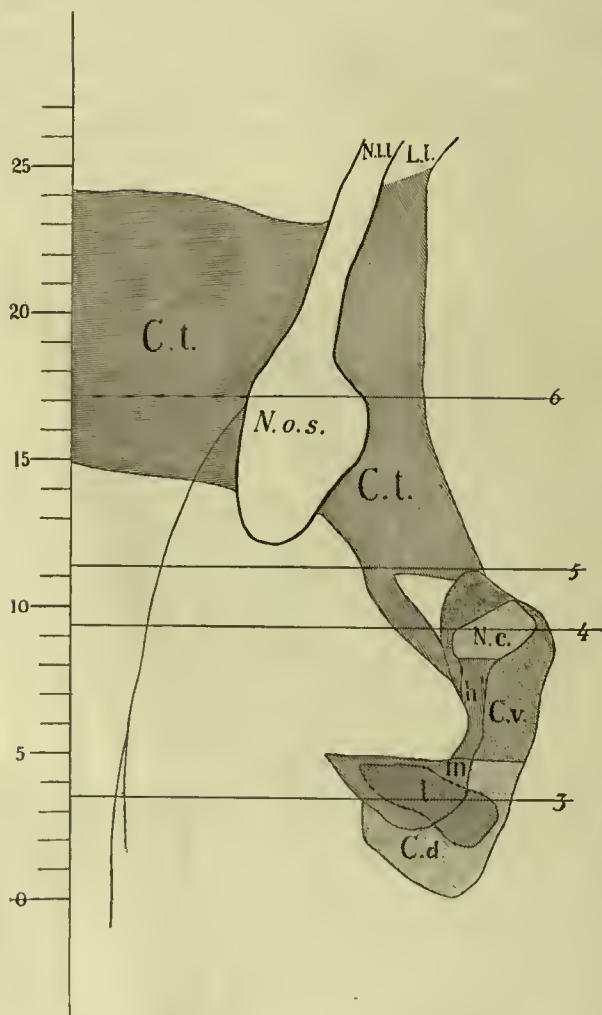


FIG. 367.—Diagram representing flat reconstruction (prepared from serial sections) of nuclei *N. cochleæ* and corpus trapezoideum. (After Florence R. Sabin, Johns Hopkins Hosp. Bull., 1897, No. 81, p. 258, Fig. 6.) *C.d.*, nucleus nervi cochleæ dorsalis; *C.t.*, corpus trapezoideum; *C.v.*, nucleus nervi cochleæ ventralis; *h*, portion of root bundle of cochlear nerve running past the ventral cochlear nucleus to the region of the dorsal cochlear nucleus; *l*, area occupied by medullated fibres of lateral portion of dorsal cochlear nucleus; *m*, area occupied by medullated fibres in the medial portion of the dorsal cochlear nucleus; *L.l.*, region of lemniscus lateralis; *N.e.*, nervus cochleæ; *N.o.s.*, complex of nucleus olivaris superior; *N.l.l.*, nucleus lemnisci lateralis.



tiate the two nuclei at a glance.\* A few of the fibres of the nervus cochleæ, according to Held,† go past the ventral nucleus without terminating in it, to enter the corpus trapezoidum

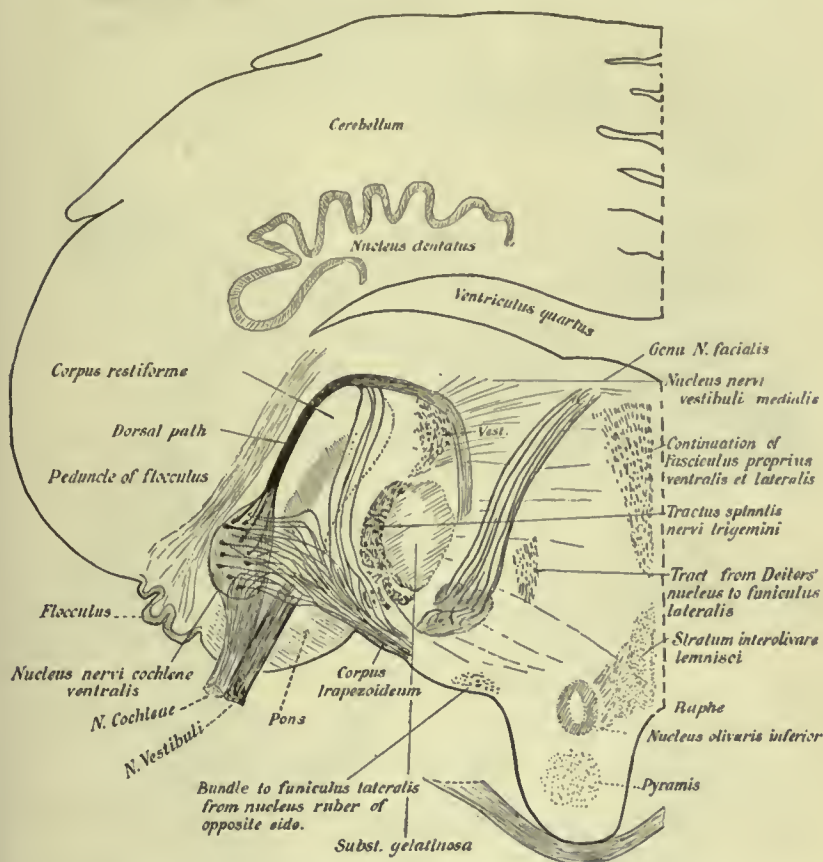


FIG. 368.—Entrance of N. cochleæ into the central nervous system; portions of the central auditory paths are also shown. Weigert preparation. Human fœtus, 32 cm. long. (After H. Held, Arch. f. Anat. u. Physiol., Anat. Abth., Leipz., 1893, S. 210, Fig. 5.) The figure is somewhat schematic.

\* The reader is advised here and in connection with other descriptions to refer frequently to the transverse and longitudinal sections pictured in Figs. 308 to 324.

† Held, H. Die centralen Bahnen des Nervus acusticus bei der Katze. Arch. f. Anat. u. Physiol., Anat. Abth., Leipz. (1891), S. 271-291.—Die centrale Gehörleitung. Arch. f. Anat. u. Physiol., Anat. Abth., Leipz. (1893), S. 201-248.

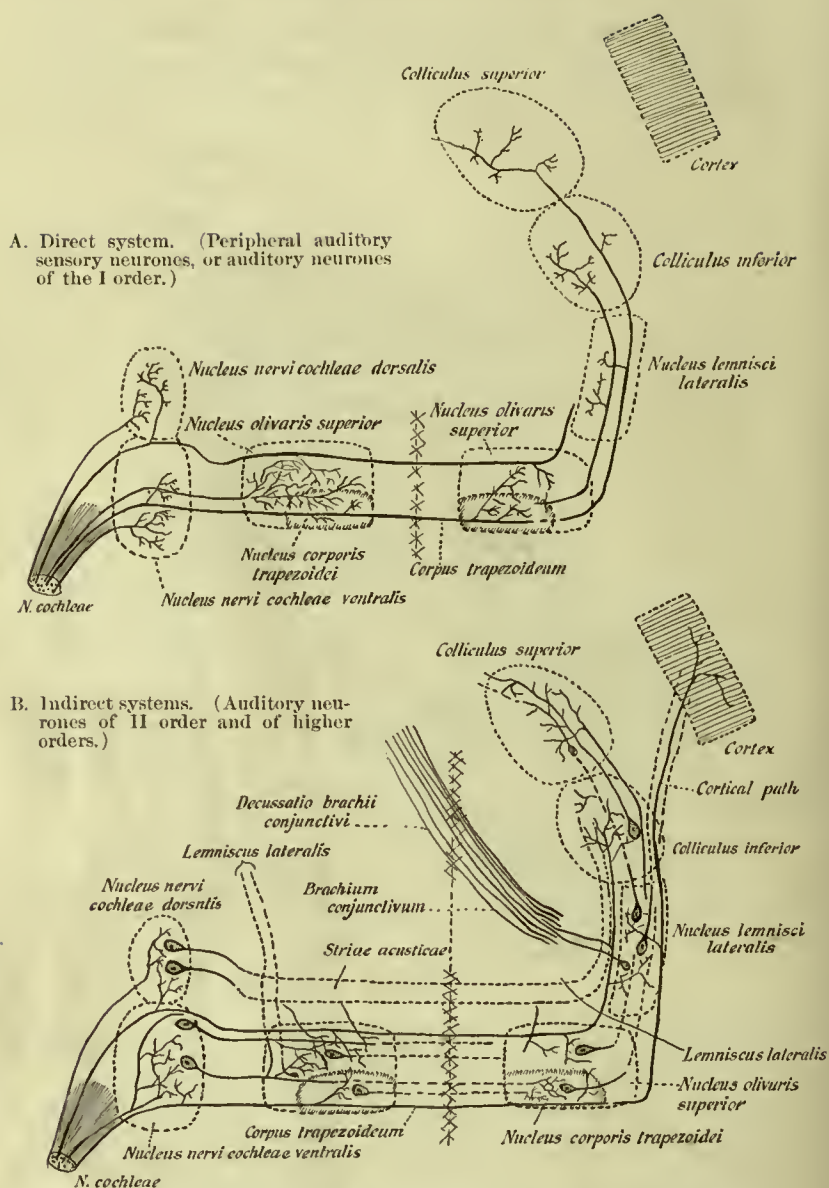


FIG. 369.—Schemes illustrating termination of axones of *N. cochleae* in the central nervous system, together with some of the central auditory neurones. (After H. Held, *Arch. f. Anat. u. Physiol., Anat. Abth.*, Leipz., 1893, S. 240. Fig. 15.)

(Fig. 368), and so come into relation with the superior olivary complex of the same or of the opposite side. Some root fibres may possibly, he thinks, go into the one or the other lateral lemniscus to terminate first in masses of gray matter situated even higher up in the cerebrospinal axis (Fig. 369). The studies of Thomas,\* by Marchi's method, also make it seem probable that root fibres of the cochlear nerve pass without interruption

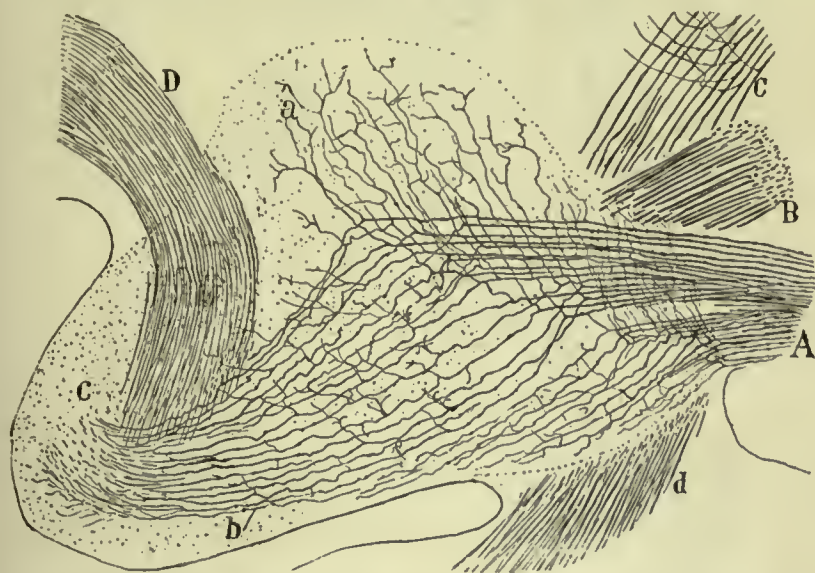


FIG. 370.—Sagittal markedly lateral section through the rhombencephalon of a fetal mouse, to show the entering N. cochleæ. (After S. Ramón y Cajal, *Beitrag zum Studium der Medulla Oblongata, etc.*, Bresler, Leipz., 1896, S. 79, Fig. 21.) A, N. cochleæ; B, N. vestibuli; C, sensory N. trigeminus; D, corpus restiforme; a, ascending limbs of bifurcation of axones of N. cochleæ; b, descending limbs; c, bundle of descending limbs which enters into the tail of the ventral nucleus and into the nucleus N. cochleæ dorsalis; d, descending limb of bifurcated axones of N. trigeminus (tractus spinalis N. trigemini) cut tangentially.

directly into the striæ acusticæ, corpus trapezoideum and lateral lemniscus. A point to be emphasized in connection with the nervus cochleæ is the absence of any evidence for the passage of any of its axones directly into the cerebellum. Thus the neurones of the first order as well as those of the second

\* Thomas, A. Les terminaisons centrales de la racine labyrinthique. *Compt. rend. Soc. de biol., Par.*, 10 s., t. v (1898), No. 6, p. 183.

order (*vide infra*) of the auditory conduction path are in marked contrast with those of the nervus vestibuli as regards their behavior toward the cerebellum.\*

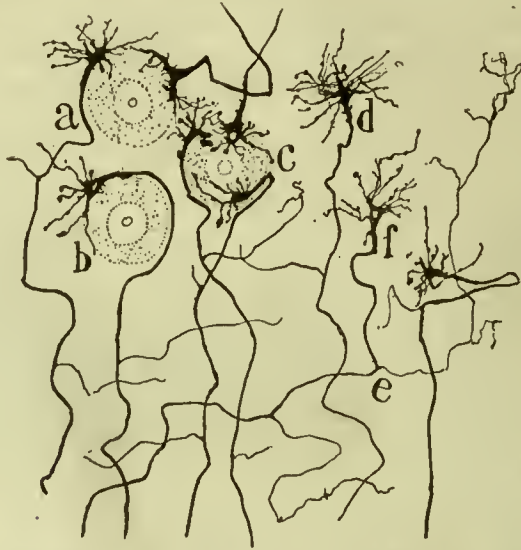

FIG. 371.—Mode of termination of the axones of the N. cochleæ in the nucleus N. cochleæ ventralis of a newborn cat. (After S. Ramón y Cajal, *Beitrag zum Studium der Medulla Oblongata*, etc., Bresler, Leipz., 1896, S. 77, Fig. 20a.) *a*, fibre ending in a conical bulb; *b*, fibre surrounding a cell; *c*, three end bulbs coming into contact with a single cell; *d*, stellate end bulb; *e*, delicate collaterals from a fibre connected with an end bulb; *f*, end bulb with a hole in it.

The axones of the cochlear nerve bifurcate on entering the ventral nucleus, dividing, as do the dorsal root fibres in the spinal cord, into an ascending and a descending limb, each of which gives off many collaterals (Fig. 370).

The ascending limb is short, and, passing dorsalward and backward, ends as a rule in the ventral cochlear nucleus. The descending limb is much longer. It runs posteriorly and enters the tail of the posterior part of the ventral nucleus and in many instances passes into the nucleus nervi cochleæ dorsalis.

The terminals and collaterals from the axones of the cochlear

---

\* It should be mentioned, however, that some investigators, among them Foster and Sherrington (Part III of Foster's *Text-book of Physiology*) and von Kölliker, maintain that the cochlear nerve is, by way of the striæ acusticæ and corpus restiforme, connected with the cerebellum.



nerve form curious end-arborizations which come into close contact with the cells of the nuclei terminales. They were first described by Held, and have also been pictured by Ramón y Cajal. They are well illustrated in the accompanying figure, which shows the terminals in the new-born cat (Fig. 371).

The course followed by the auditory impulses inside the central nervous system (auditory neurones of the second and of higher orders) will be considered in a subsequent chapter.

## SUBSECTION II.

**Neurones Within the Central Nervous System Connecting the End Stations (Nuclei Terminales) of the Axones of the Peripheral Centripetal Neurones with other Portions of the Central Nervous System (Centripetal Neurones of the Second Order and of Higher Orders; Central Neurones of the Sensory Conduction Paths).**

---

## CHAPTER XXXIX.

### CENTRIPETAL NEURONES INSIDE THE CENTRAL NERVOUS SYSTEM.

Classification—Those concerned in bodily sensations—Those pertaining to the spinal peripheral centripetal neurones—Groups of these—Those the cell bodies of which are situated in the nuclei of the funiculus gracilis and funiculus cuneatus of each side—*Fibræ areuatae internæ*—*Stratum interolivare lemnisei*—*Decussatio lemniscorum*—*Lemniscus medialis*—Nucleo-cerebellar systems.

HAVING considered the neurones collecting impulses from all parts of the body (including the organs of special sense) and carrying them into the nerve centres, it is necessary to examine briefly the main facts which have been ascertained concerning the neurones which are so disposed that they can take up the impulses, where they are left by the peripheral neurones, and carry them further. In this examination we shall follow the same plan as that adopted in our study of the peripheral centripetal neurones and consider (A) the paths concerned in the carrying of bodily impulses separately from (B) those whose function it is to forward the impressions derived from the organs of special sense.

(A) Central Neurones of Sensory Conduction Paths other than those corresponding to the Organs of Special Sense.

In considering the peripheral spinal neurones we have seen over how vast a territory the collaterals and terminals are distributed in the spinal cord and medulla. It is obvious that impulses arriving along a single peripheral spinal neurone can affect neurones of the second order by means of collaterals and terminals in very different portions of the gray matter of the

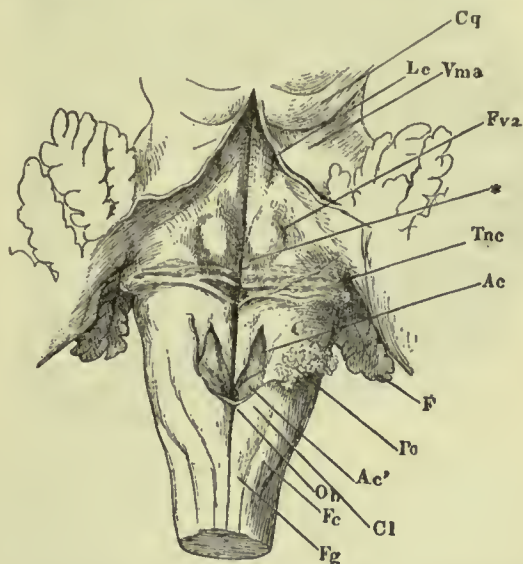


FIG. 372.—Floor of fourth ventricle and dorsal view of myelencephalon. (After J. Henle, *Handbuch der Nervenlehre des Menschen*, 11. Aufl., Braunschweig, 1879, Fig. 123, S. 206.) The cerebellum and velum medullare anterius have been cut through in the middle line and turned to the side. *Ac*, alae cineræ; *Ac'*, accessory nucleus of Stilling; *Cl*, clava; *Cq*, corpora quadrigemina; *F*, flocculus; *Fc*, funiculus cuneatus; *Fg*, funiculus gracilis; *Fva*, fovea superior; *Lc*, locus caeruleus; *Ob*, obex; *Po*, ponticulus (of tænia ventriculi quarti) laid to one side; *Tnc*, nucleus nervi cochleæ dorsalis and striae medullares; *Vma*, velum medullare anterius; the \* indicates the colliculus facialis.

spinal cord and medulla. An immense problem here lies before us. At present we can not speak with desired definiteness concerning all the neurones of the second order and of higher orders here concerned, but have to be content with describing the relations of certain great groups of neurones of the nuclei terminales as far as they have been made out. The lower motor neurones situated in the ventral horns are, as has been seen,

thrown under the influence of collaterals and terminals of peripheral sensory neurones, but in such an event the impulses can be carried, it is believed, to the muscles alone; the progress

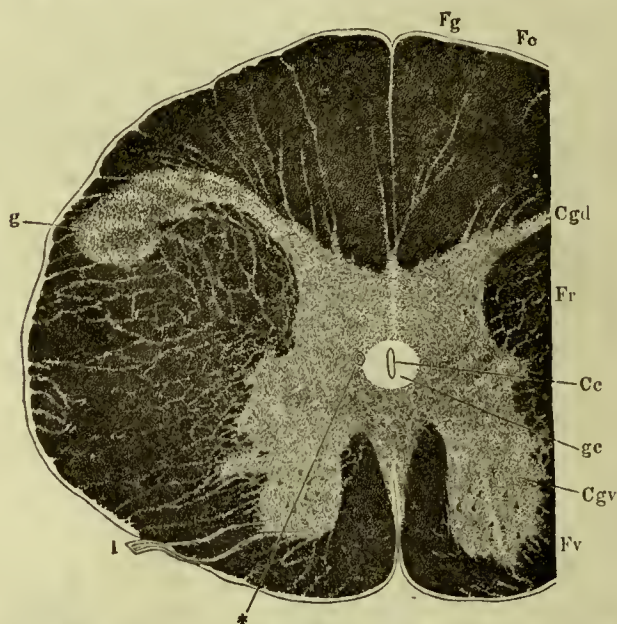


FIG. 373.—Transverse section at the junction of the medulla spinalis with the medulla oblongata. (After J. Henle, *Handbuch der Nervenlehre des Menschen*, Zweite Aufl., Braunschweig, 1879, S. 208, Fig. 124.) *Cc*, canalis centralis; *Cgd*, columna (grisea) dorsalis; *Cgv*, columna (grisea) ventralis; *Fr*, funiculus ventralis; *Fo*, fasciculus occipitalis; *Fg*, fasciculus gracilis; *g*, substantia gelatinosa Rolandi; *gc*, substantia gelatinosa centralis; *l*, ventral root of the first cervical nerve; the \* indicates a cross section of a blood-vessel; *Fr*, formatio reticularis. This section is below the level of the decussatio pyramidum.

of centripetal impulses toward higher centres would not be furthered. The neurones concerned in the latter function consist of at least several well-marked groups. It will be convenient to consider (1) the central neurones pertaining to the spinal sensory nerves more or less separately from (2) those which pertain to the cerebral nerves.

1. Central Neurones, the Perikaryons and Dendrites of which are Situated in the Nuclei Terminales of the Axones of the Spinal Peripheral Centripetal Neurones.

The neurones, the cell bodies and dendrites of which correspond to the nuclei terminales of the dorsal roots of the



spinal nerves may be considered under the following headings:

(a) Neurones the cell bodies of which are situated in the nucleus funiculi gracilis and nucleus funiculi cuneati of each side.

(b) Neurones the cell bodies of which are situated in the nucleus dorsalis of each side.

(c) Neurones the cell bodies of which are situated in the gray matter of the cord, their axones helping to form the fasciculus ventro-lateralis (Gowersi) of each side.

(d) Neurones the cell bodies of which are situated in the gray matter of the cord, their axones making up the fascicu-

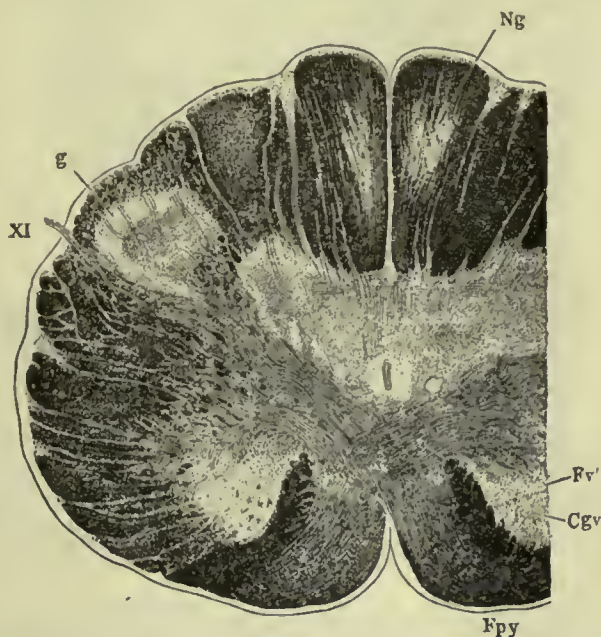


FIG. 374.—Transverse section through the medulla oblongata at the level of the decussatio pyramidum. (After J. Henle, *Handbuch der Nervenlehre des Menschen*, Zweite Aufl., Braunschweig, 1879, S. 211, Fig. 126.) *Cgr*, column (grisen) ventralis or ventral horn; *Fr'*, continuation in the medulla of the fasciculus ventralis proprius (*Forderstrangrest* of the Germans); *Fpy*, fasciculi cerebrospinales pyramidales undergoing decussation; *g*, substantia gelatinosa Rolandi; *Ng*, spinal extremity of nucleus funiculi gracilis; *XI*, nervus accessorius.

lus proprius (ground bundle) of the ventral, lateral, and dorsal funiculi of each side of the cord.

While these represent the chief nuclei terminales of the dorsal roots of the spinal nerves, it must be pointed out that a certain number of dorsal root fibres terminate first in the cere-

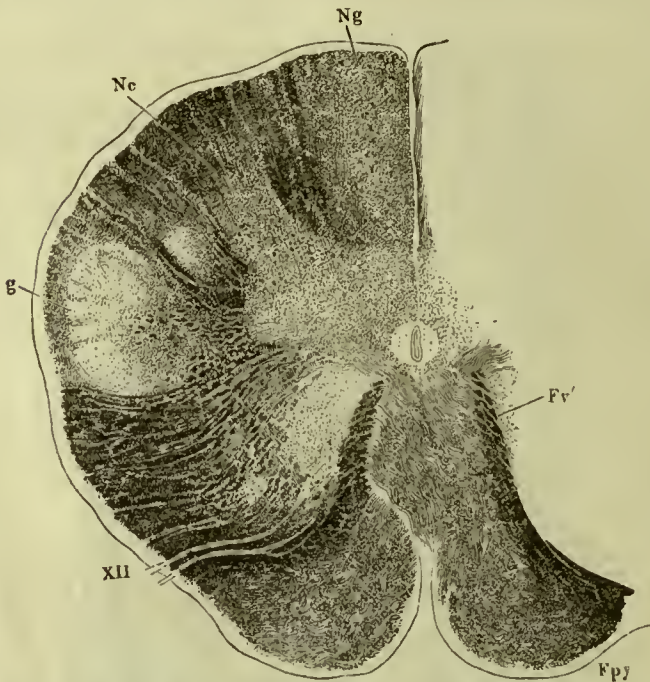


FIG. 375.—Transverse section through the medulla oblongata at the level of the most caudal fila radicularia of the nervus hypoglossus. (After J. Henle, *Handbuch der Nervenlehre des Menschen*, Zweite Aufl., Braunschweig, 1879, S. 213, Fig. 127.) *Fr'*, continuation in the medulla of the fasciculus ventralis proprius of the spinal cord; *Fpy*, pyramis (at uppermost level of decussatio pyramidum); *g*, substantia gelatinosa; *Nc*, nucleus funiculi cuneati (Burdachi); *Ng*, nucleus funiculi gracilis (Golli). The decussatio lemniscorum is not indicated in the figure, though it is to be seen at this level. Cf. Fig. 378.

bellum, and possibly also in the formatio reticularis grisea of the medulla oblongata (*vide infra*).

(*ad a*) The nuclei of the dorsal funiculi (nucleus funiculi gracilis and nucleus funiculi cuneati of each side) are situated in the medulla oblongata at its junction with the spinal cord. The swellings on the dorsal surface of the medulla, known on each side as the *clava* and the *tuberculum cuneatum*, are due to these nuclei (Fig 372). The *clava* corresponds to the *nucleus funiculi gracilis* and the *tuberculum cuneatum* to the

*nucleus funiculi cuneati*. A study of a series of sections (Figs. 373 to 377) through the upper portion of the cervical part of the spinal cord and the lower portion of the medulla reveals the general relation of the fibres of the dorsal funiculi

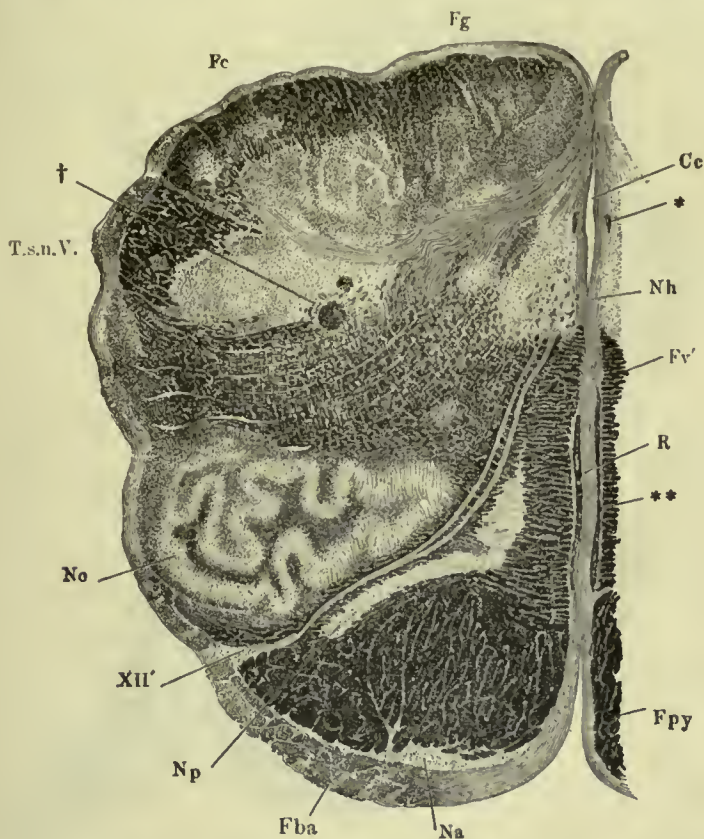


FIG. 376.—Transverse section of the medulla oblongata at the level of the caudal extremity of the nucleus olivaris inferior; potash preparation. (After J. Henle, *Handbuch der Nervenlehre des Menschen*, Zweite Aufl., Braunschweig, 1879, S. 220, Fig. 134.) Cc, canalis centralis; Fba, fibre arcuata externa ventrales; Fv', remains of ventral funiculus of the spinal cord; Fc, fasciculus cuneatus (Burdachi); Fg, fasciculus gracilis (Golli); Fpy, fasciculi cerebrospinales pyramidales above the level of the decussatio pyramidum; Na, nuclei arcuati; Nh, nucleus nervi hypoglossi; No, nucleus olivaris inferior; Np, nucleus olivaris accessorius medialis; R, raphe; T.s.n.V., tractus spinalis nervi trigemini; XII', radix nervi hypoglossi; \*, cross section of blood-vessel; \*\*, longitudinal section of blood-vessel; †, tractus solitarius.

to these nuclei. Passing from below upward, one makes out that as the masses of gray matter begin to appear, the volume



of the fasciculi of white fibres begins to diminish. In sections still higher up the nuclei are larger and the fasciculi grow pro-

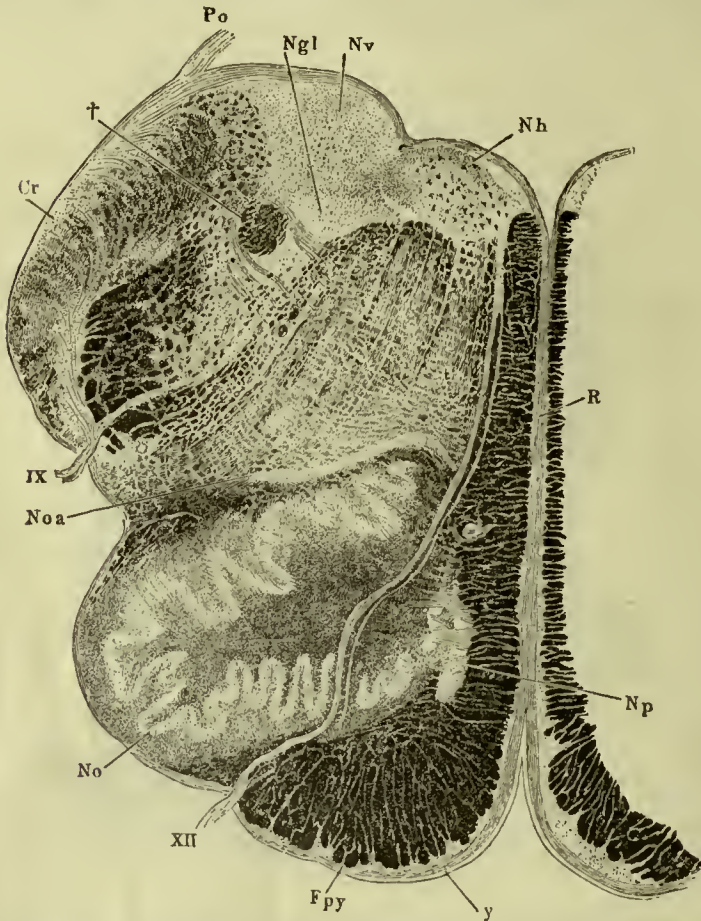


FIG. 377.—Transverse section of the medulla oblongata at the level of the middle of the nucleus olivaris inferior. (After J. Henle, *Handbuch der Nervenlehre des Menschen*, Zweite Aufl., Braunschweig, 1879, S. 227, Fig. 139.) *Cr.*, corpus restiforme; *Fpy*, fasciculi pyramidales; *Ngl*, nucleus (terminalis) nervi glossopharyngei; *Nh*, nucleus (originis) nervi hypoglossi; *No*, nucleus olivaris inferior; *Noa*, nucleus olivaris accessorius dorsalis; *Np*, nucleus olivaris accessorius medialis; *Nr*, nucleus alae cineræ (nucleus terminalis nervi vagi); *Po*, pontienus (of tænia ventriculi quarti); *R*, raphe; *IX*, radix nervi glossopharyngei; *XII*, radix nervi hypoglossi; *†*, tractus solitarius.

gressively smaller, until in the uppermost regions of the nuclei there are scarcely any white fibres intervening between the gray



masses and the dorsal surface, the white fibres having disappeared by running into the nuclei to terminate in them. The nucleus funiculi gracilis appears at a lower level than does the nucleus funiculi cuneati and it terminates at a lower level in the medulla than does its neighbor; the white fibres of the fasciculus gracilis have all disappeared at a level at which there is still a large mass of fibres in the fasciculus cuneatus running to higher levels.

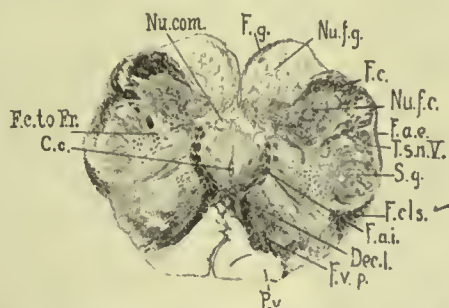


FIG. 378.—Transverse section through medulla oblongata of newborn child at level of decussatio lemniscorum. (Series ii, section No. 50.) C.e., canalis centralis; Dec.l., decussatio lemniscorum; F.a.i., fibre arcuate interna; F.a.e., fibre arcuate externa; F.c., fasciculus cuneatus Burdachii; F.c. to F.r., bundles from fasciculus cuneatus to formatio reticularis; F.c.s., fasciculus cerebellospinalis or direct cerebellar tract; F.g., fasciculus gracilis Golli; F.v.p., fasciculus ventralis proprius; Nu.com., nucleus commissuralis; Nu.f.c., nucleus funiculi cuneati; Nu.f.g., nucleus funiculi gracilis; Py., pyramis; T.s.n.V., tractus spinalis N. trigemini; S.g., substantia gelatinosa [Rolandi]. (Weigert-Pal preparation by Dr. John Hewetson.)

The fibres of the dorsal funiculi of the spinal cord terminating in the nuclei mentioned transfer the impulses which they carry to the dendrites and cell bodies of neurones situated there; the axones of these neurones carry the impulses farther. A large number of these axones appear as internal arcuate fibres which press in a curved direction to the raphe, decussate with corresponding internal arcuate fibres of the opposite side, forming the decussatio lemniscorum\* (Fig. 378), and then assume a longitudinal direction in the so-called interolivary layer of the lemniscus (*stratum interolivare lemnisci*) (Fig. 379). Farther head-

\* The nature of this decussation and its relation to the nuclei of the dorsal funiculi and to the lemniscus was long misunderstood. The myelinization studies of Flechsig first threw light on the subject. The Germans for a long time spoke of the decussation as the *obere Pyramidenkreuzung* to distinguish it from the motor decussation or *untere Pyramidenkreuzung*.

ward this interolivary layer is continuous with the *lemniscus medialis* which runs through the pons and midbrain toward the

higher centres terminating mainly in the ventro-lateral group of nuclei of the thalamus. Another portion of the axones from the nuclei of the dorsal funiculi pass through the corpus restiforme into the cerebellum.

The nucleus funiculi gracilis on each side receives the terminals of the majority of the axones which make up Goll's fasciculus of the same side of the cord, though it has lately been shown that a few terminals and collaterals cross the middle line to enter into the nucleus of the opposite side, forming in this way a terminal decussation of the axones of the peripheral centripetal neurone system (Ramón y Cajal's *entrecruzamiento terminal*).<sup>\*</sup> The cell bodies of the neurones situated in the nucleus funiculi gracilis are triangular or stellate, and richly provided with dendrites. A part of their axones pass at first lateralward, and then curving around become directed ventralward and medialward in order, as *fibræ arcuatæ in-*

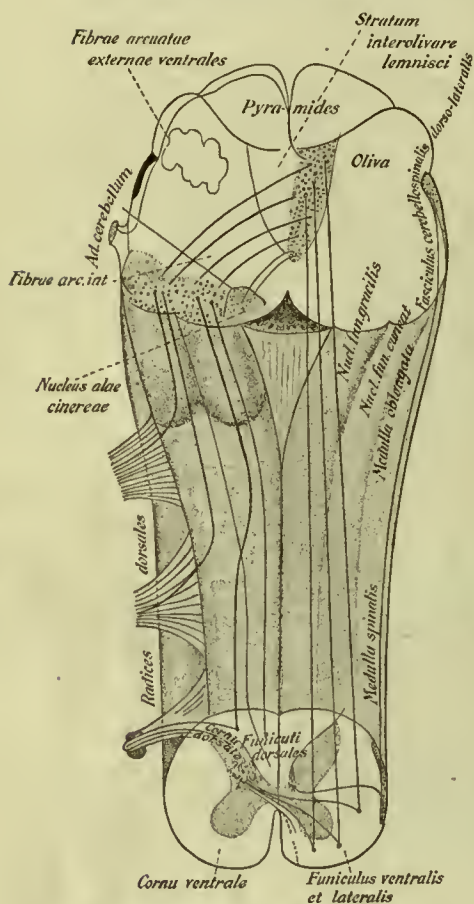


FIG. 379.—Scheme of the course of the sensory paths of the dorsal funiculi in the region of their nuclei in the medulla oblongata. (After L. Edinger, *Nervöse Centralorgane*, V. Aufl., Leipz., 1896, S. 343, Fig. 235.)

ternæ, to cross in the raphe and to enter into the opposite stratum interolivare lemnisci and thence into the medial part

<sup>\*</sup> Ramón y Cajal, S. Beitrag zum Studium der Medulla oblongata, des Kleinhirns und des Ursprungs der Gehirnnerven. Deutsch von Bresler, Leipz. (1896), S. 51.

of the lemniscus medialis. The course of these fibres and their terminations will be described in full further on. A certain number of the axones from this nucleus pass dorsalward to reach the surface of the medulla, and then run laterally as *fibræ arcuatæ externæ dorsales* to enter the cerebellum through the corpus restiforme (Edinger, Bruce, Ferrier and Turner). Further, some of the axones before mentioned as decussating at the raphe instead of running longitudinally in the stratum interolivare lemnisci, plunge ventrally through or around the pyramid to reach the lateral surface of the medulla and to enter the cerebellum through the corpus restiforme. It is believed by von Bechterew\* that a portion of these *fibræ arcuatæ externæ ventrales* undergo relay in the nuclei arcuati. At any rate it appears that of the external arcuate fibres having origin in the nucleus funiculi gracilis, the dorsal connect this nucleus with the cerebellum by means of the corpus restiforme of the same side (uncrossed gracilar nucleo-cerebellar neurone system), the ventral by means of the corpus restiforme of the opposite side (crossed gracilar nucleo-cerebellar neurone system).

The nucleus funiculi cuneati, or nucleus of Burdach's column (including the lateral [external] nucleus of Blumenau†), receives the majority of the terminals of the axones of the fasciculus cuneatus of the same side of the spinal cord, the terminal fibres breaking up into very complicated branchings in among the "islands" formed of the cell bodies and dendrites of this nucleus. The cell bodies in this nucleus are also rather small, triangular, or fusiform in shape. The majority of the axones of the cells in the pars medialis of the nucleus, like those of the cells in the nucleus funiculi gracilis, enter the medial lemniscus of the opposite side by way of the internal arcuate fibres and the stratum interolivare lemnisci. A considerable number of the medullated axones from this nucleus, however, again in agreement with the nucleus funiculi gracilis, enter the cerebellum of the same (uncrossed cuneate nucleo-cerebellar neurone system) and of the opposite (crossed cuneate nucleo-cerebellar neurone system) side by way of the *fibræ arcuatæ externæ dorsales et ventrales* and the corpora restiformia. The majority of the

\* von Bechterew, W. Die Leitungsbahnen im Gehirn und Rückenmark, Leipz. (1894), S. 90.

† Blumenau, L. Ueber den acusseren Kern des Keilstranges im verlängerten Mark. Neurol. Centralbl., Leipz., Bd. x (1891), S. 226-232.

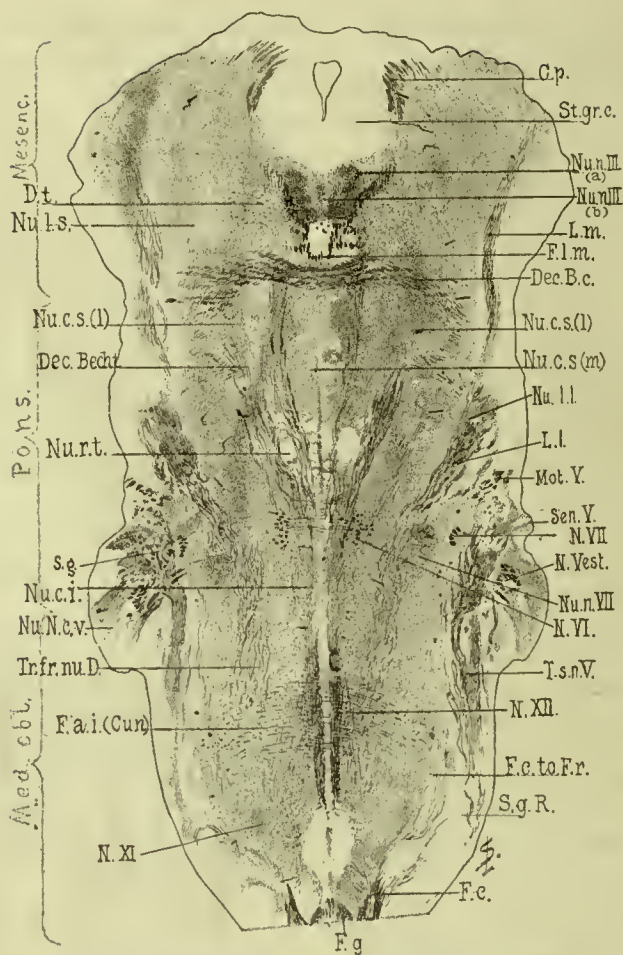


FIG 380.—Horizontal section through the medulla, pons, and midbrain of a newborn babe. Weigert-Pal staining. Level of decussatio brachii conjunctivi and of nucleus reticularis tegmenti. (Series iii, section No. 108.) (*C.p.*, commissura posterior cerebri; *Dec.B.c.*, decussatio brachii conjunctivi; *Dec.Becht.*, commissure between Bechterew's nuclei; *D.t.*, fibres to decussatio tegmenti; *F.a.i.(Cun.)*, fibrae arcuatae internae from the nucleus funiculi cuneati; *F.c.*, fasciculus cuneatus; *F.c.to.F.r.*, bundle from fasciculus cuneatus to formatio reticularis; *F.g.*, fasciculus gracilis; *Fl.m.*, fasciculus longitudinalis medialis; *L.m.*, lemniscus medialis; *L.l.*, lemniscus lateralis; *Mot.V.*, radix motorius N. trigemini; *N.VII.*, radix N. facialis, pars secunda; *N.vest.*, radix N. vestibuli; *N.VI.*, radix N. abducentis; *N.XII.*, radix N. hypoglossi; *N.XI.*, radix N. accessorii; *Nun.III.(a)*, nucleus N. oculomotorii, pars lateralis; *Nun.III.(b)*, nucleus N. oculomotorii, pars impar; *Nu.c.s.(l)*, nucleus centralis superior, pars lateralis; *Nu.c.s.(m)*, nucleus centralis superior, pars medialis; *Nu.l.l.*, nucleus lemnisci lateralis; *Nun.VII.*, nucleus N. facialis; *Nu.N.e.v.*, nucleus N. cochlear ventralis; *Nu.c.i.*, nucleus centralis inferior; *Nu.r.t.*, nucleus reticularis tegmenti; *Nul.s.*, nucleus lateralis superior; *St.gr.c.*, stratum griseum centrale; *Sen.V.*, sensory root of N. trigeminus; *S.g.*, substantia gelatinosa Rolandi; *Tr.fr.nu.D.*, tract from Deiters' nucleus to the spinal cord; *T.s.n.V.*, tractus spinalis N. trigemini. (Preparation by Dr. John Hewetson.)



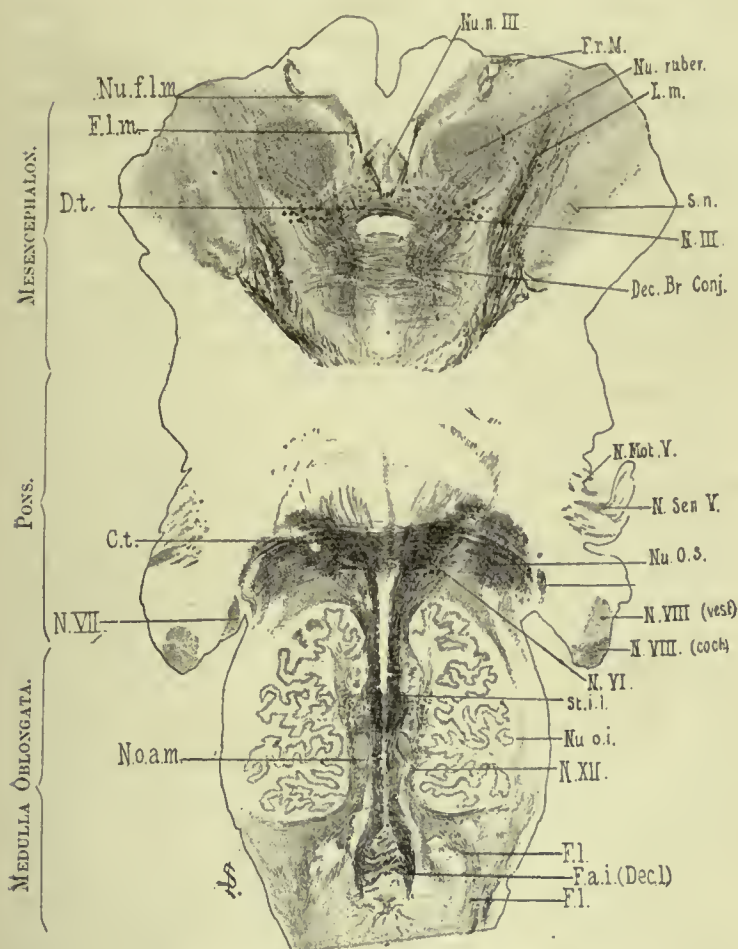


FIG. 381.—Horizontal section through the medulla, pons, and midbrain of newborn babe. Level of stratum interolivare lemnisci, corpus trapezoideum and nucleus ruber. Weigert-Pal staining. (Series III, section No. 136.) *C.t.*, corpus trapezoideum; *Dec.Br.Conj.*, decussatio brachii conjunctivi; *D.t.*, decussatio tegmenti ventralis (ventral tegmental decussation of Forel); *F.a.i.(Decl.)*, fibre arcuata interna (decussatio lemniscorum); *Fl.*, fibres continuous with the funiculus lateralis of the spinal cord; *Flm.*, fasciculus longitudinalis medialis; *Fr.M.*, fasciculus retroflexus Meynerti; *L.m.*, lemniscus medialis; *N.III.*, radix N. oculomotorii; *N.Mot.V.*, motor root of N. trigeminus; *N.Sen.V.*, sensory root of N. trigeminus; *N.VIII.(coch.)*, radix N. cochleae; *N.VIII.(vest.)*, radix N. vestibuli; *N.VI.*, radix N. abducentis; *N.VII.*, radix N. facialis, pars secunda; *N.XII.*, radix N. hypoglossi; *Nu.flm.*, nucleus Oculomotoriuskern of Darkschewitsch; *Nu.n.III.*, nucleus N. oculomotorii; *Nu.o.a.m.*, nucleus olivaris accessorius medialis; *Nu.o.i.*, nucleus olivaris inferior; *Nu.o.s.*, nucleus olivaris superior; *Nu.ruber.*, nucleus ruber; *St.i.l.*, stratum interolivare lemnisci; *S.n.*, substantia nigra. (Preparation by Dr. John Hewetson.)

axones from the cells in the *pars lateralis* or Blumenau's nucleus go to the cerebellum on the same side. In the cerebellum these fibres run as a compact bundle past the nucleus dentatus, through the more medial of the two bundles into which the corpus restiforme here divides (Tschermak), to end mainly in the cortex of the vermis inferior. On the way collaterals are given off to the nucleus *N. vestibuli lateralis* (Deiters), and to the cerebellar nuclei, especially to the nuclei *fastigii*.

As a result of the relative positions of the two nuclei, the internal arcuate fibres from the nucleus *funiculi gracilis* are to be found at levels farther spinalward than those containing the arcuate fibres from the nucleus *funiculi cuneati*, while, on the other hand, internal arcuate fibres from the nucleus *funiculi cuneati* can be seen at levels much higher up than those in which the last internal arcuate fibres from the nucleus *funiculi gracilis* are situated (Fig. 380). Miss Florence Sabin finds two main masses of arcuates connected with the nuclei *funiculi gracilis et cuneati*—(1) a lower mass probably common to the two nuclei, but mainly arising from the nucleus *funiculi gracilis*, the majority of which decussate in the raphe (Fig. 381), a distinct bundle, however, turning forward into the *stratum interolivare lemnisci* of the same side, and (2) an upper larger mass originating from the anterior half of the nucleus *funiculi cuneati*, apparently undergoing complete decussation in the raphe (Fig. 380). Between these two masses of arcuates is an area of considerable width, corresponding to the posterior half of the nucleus *funiculi cuneati*, in which no distinct bundles of arcuate fibres can be made out.

The developmental method has thrown much light upon the distribution of the axones from these two nuclei. The study of them is rendered easier by the fact that the axones from the nucleus *funiculi cuneati* become medullated some time before those from the nucleus *funiculi gracilis*. The former are already medullated in the human *fœtus* 30 cm. long, while the latter receive their myelin sheaths first when the *fœtus* has attained a length of from 35 to 38 cm. It is possible, therefore, to follow the course of the fibres upward separately. Without going into the details,\* it may be

---

\* For these the reader is referred to the large monograph on conduction paths published by P. Flechsig in 1876, to his *Plan des menschlichen Gehirns*, Leipz. (1883), and his articles in *Neurol. Centralbl.*, Leipz., Bd. iv (1885),

stated in general that these studies have shown that the internal arcuate fibres from the nucleus funiculi cuneati, after having crossed in the raphe, run cerebralward in the more dorsal portion of the stratum interolivare lemnisci to form in the pons the more lateral portions of the lemniscus medialis. A part of these fibres at the level of the inferior colliculus of the corpora quadrigemina pass dorsalward, according to von Bechterew, to enter the region which he designates as the corpus parabigeminum,\* some of them going on to the superior colliculus, apparently to terminate in these gray masses. The majority of the fibres, however, do not go so far dorsalward, but passing somewhat laterally, on account of the red nucleus, above this body, turn still more laterally to become connected, most probably, as we shall see later, mainly with the ventrolateral group of nuclei in the optic thalamus, but partly with the nucleus hypothalamicus (Luysi), and partly with the nucleus lentiformis of the same side and of the opposite side. The point of importance to remember at this stage in our description is that the majority of the fibres of this portion of the medial lemniscus extend through the cerebral peduncle, by way of the tegmentum, into the hypothalamic region.

The fibres from the nucleus funiculi gracilis occupy in the stratum interolivare lemnisci a region rather more medially

---

S. 97, and Bd. v (1886), S. 549; and also to the following publications by W. von Bechterew: (1) *Die Leitungsbahnen im Gehirn und Rückenmark*, Leipz. (1894), also II Aufl. (1899); (2) *Ueber die hinteren Wurzeln, den Ort ihrer Endigung in der grauen Rückenmarksubstanz und ihre centrale Fortsetzung*. Arch. f. Anat. u. Physiol., Anat. Abth., Leipz. (1887), S. 126-136. *Ueber die Schleifenschicht auf Grund der Resultate von nach der entwicklungsgeschichtlichen Methode ausgeführten Untersuchungen*. Arch. f. Anat. u. Physiol., Anat. Abth., Leipz. (1895), S. 379-395. The valuable studies of myelinization by L. Edinger: *Zur Kenntniss des Verlaufes der Hinterstrangfasern in der Medulla oblongata und im hinteren Kleinschenkel*. Neurol. Centralbl., Leipz., Bd. iii (1885), S. 73-76; of A. Bruce: *Illustrations of the Nerve Traets in the Mid- and Hind-Brain, etc.*, Edinb. and Lond. (1892); of L. O. Darksehewitseh and S. Freud: *Ueber die Beziehung des Striekkörpers zum Hinterstrang und Hinterstrangkern, nebst Bemerkungen ueber zwei Felder der Oblongata*. Neurol. Centralbl., Leipz., Bd. v (1886), S. 121-129; and of A. Cramer: *Beiträge zur feineren Anatomie der Medulla oblongata, der Brücke, etc.*, Jena, 1894, should also be consulted.

\* I have not been able to satisfactorily locate this body, notwithstanding careful study of the serial sections.

and ventrally situated than those from the nucleus funiculi cuneati, though it would appear that no sharp line of division can be drawn between them, the fibres of the two systems inter-mixing, especially at higher levels. A little higher up a portion of these fibres terminate apparently in the so-called "nuclei reticulares tegmenti pontis," those masses of gray matter situated near the raphe in the most ventral portions of the pars dorsalis pontis. The majority of the fibres, however, are continued through the pons as the more medial portions of the lemniscus medialis.\* In the tegmental portion of the cerebral peduncle these fibres lie medial and ventral to the bundle from the nucleus funiculi cuneati; the medial lemniscus, made up largely of the bundles from the two nuclei of the dorsal funiculi in this region, assumes, therefore, a sickle-shape. The fibres from the nucleus funiculi gracilis pass on through the tegmentum of the cerebral peduncle to the diencephalon, where, as will be pointed out later, the majority of them probably terminate by end-ramifications in the ventro-lateral regions of the thalamus. Von Bechterew's scheme of the axones passing out of the nuclei of the dorsal funiculi is reproduced in Fig. 382.

Studies by the method of Marchi, after destruction of the nuclei funiculi gracilis et cuneati in animals (Singer and Münzer, Ferrier and Turner, F. W. Mott, A. Tschermak), have shown that while the majority of the fibres extend forward as far as the thalamus, many of them terminate in the gray masses on the way (formatio reticularis grisea, nuclei pontis, colliculi of corpora quadrigemina).

Singer and Münzer,† experimenting upon cats, destroyed the spinal extremity of the nucleus funiculi cuneati on one side, and studied the ascending degeneration with the delicate method of Marchi. They found degeneration of the myelin sheaths of the fibræ arcuatæ internæ, corresponding to this part of Burdach's nucleus, and were able to follow the fibres across the raphe into the ventral part of the stratum inter-

---

\* The *most* medial bundles in the region of the lemniscus are made up in all probability not of centripetal but of centrifugal fibres. They become medullated much later than the rest of the fibres of the lemniscus. The nature of these fibres will be discussed in connection with those of the lemniscus medialis in general further on.

† Singer, J., u. E. Münzer. *Denkschr. d. Akad. d. Wissensch., Wien, Math.-naturw. Cl., Bd. lvii (1890), S. 569.*



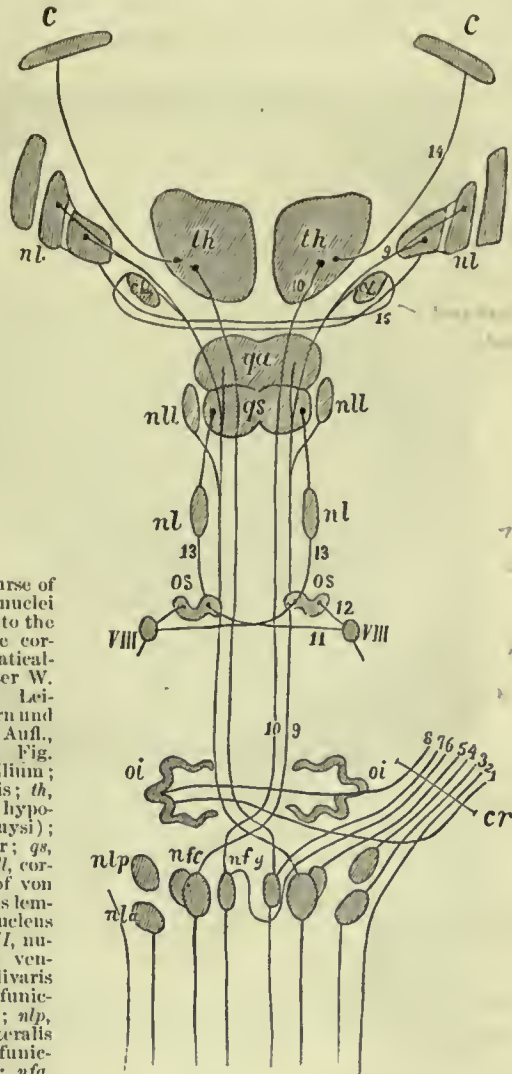


FIG. 382.—The course of the axones from the nuclei of the dorsal funiculi to the lemniscus and to the corpus restiforme, schematically represented. (After W. von Bechterew, *Die Leitungsbahnen im Gehirn und Rückenmark*, II. Aufl., Leipz., 1899, S. 252, Fig. 219.) *c*, cortex of pallium; *nl*, nucleus lentiformis; *th*, thalamus; *cl*, nucleus hypothalamicus (corpus Luysi); *qa*, colliculus superior; *qs*, colliculus inferior; *nll*, corpus parabigemini of von Bechterew; *nl*, nucleus lemnisci lateralis; *os*, nucleus olivaris superior; *VIII*, nucleus nervi cochleae ventralis; *oi*, nucleus olivaris inferior; *nla*, nucleus funiculi lateralis ventralis; *nlp*, nucleus funiculi lateralis dorsalis; *nfc*, nucleus funiculi cuneati Burdachi; *nfg*, nucleus funiculi gracilis

Golli; *cr*, corpus restiforme; 1 and 8, fibre cerebello-olivares; 2, fasciculus spino-cerebellaris dorso-lateralis (direct cerebellar tract of Flechsig); 3, fibre from the nucleus funiculi ventralis to the cerebellum; 4, fibre from the nucleus funiculi dorsalis to the cerebellum; 5, fibre from the nucleus funiculi cuneati to the cerebellum; 6 and 7, fibres from the nucleus funiculi gracilis of the two sides to the cerebellum; 9, lateral part of the lemniscus medialis formed by fibres from the contra-lateral nucleus funiculi cuneati; 10, medial part of the lemniscus medialis formed by fibres from the contra-lateral nucleus funiculi gracilis on their way to the thalamus; 14, axone of thalamocortical neurone or cortical lemniscus; 15, lemniscus fibres of Meynert's commissure.

olivare lemnisci of the opposite side. The fibres here assumed a longitudinal direction, and could be followed through the

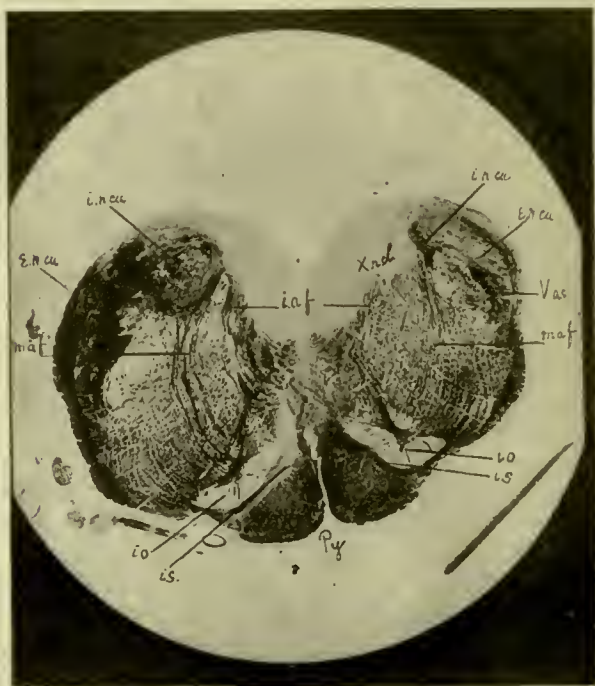


FIG. 383.—A transverse section of the medulla at the lower end of the nucleus olivaris inferior, showing the degeneration which follows destruction of the nucleus funiculi gracilis. (After Ferrier and Turner, *Phil. Tr., Lond.*, vol. clxxxv, 1894, B, pl. lxxviii, Fig. 5.) *X.n.cl.*, ventral extremity of the nucleus funiculi gracilis; *i.a.f.*, fibre arcuate internæ, degenerated on the side of the lesion; *i.s.*, stratum interolivare lemnisci; *i.n.eu.*, nucleus funiculi cuneati, pars medialis; *e.n.eu.*, nucleus funiculi cuneati, pars lateralis; *m.a.f.*, middle arcuate fibres in part degenerated on side of lesion; *i.o.*, nucleus olivaris inferior; *V.as.*, tractus spinalis N. trigemini; *Py*, pyramis.

lemniscus medialis as far as the hypothalamic region and ventro-lateral part of the thalamus. Farther than this they were unable to trace degenerated fibres.

Ferrier and Turner\* destroyed the nucleus funiculi gracilis,

\* Ferrier, D., and W. A. Turner. A Record of Experiments Illustrative of the Symptomatology and Degenerations following Lesions of the Cerebellum, etc. *Phil. Tr., Lond.*, vol. clxxxv for 1894 (B) (1895), pp. 755-761. —Also, An Experimental Research upon Cerebro-Cortical Afferent and Efferent Tracts. *Phil. Tr., Lond.*, vol. exe (1898), pp. 1-44.

or the *nucleus funiculi cuneati*, on one side, in the monkey, with the aid of the galvano-cautery, and studied the ascending degeneration with Marchi's method and Weigert's method. They obtained always degeneration in the *corpus restiforme* on the side of lesion, but failed to produce degeneration in the same bundle on the side opposite to the lesion. They studied also the degenerations in the *fibræ arcuatæ internæ* of the same side, and in the *lemniscus medialis* of the opposite side, and showed by the degeneration method that the fibres from the *nucleus funiculi gracilis* go to the ventral part of the opposite *lemniscus medialis* (Figs. 383 and 384), while those from the

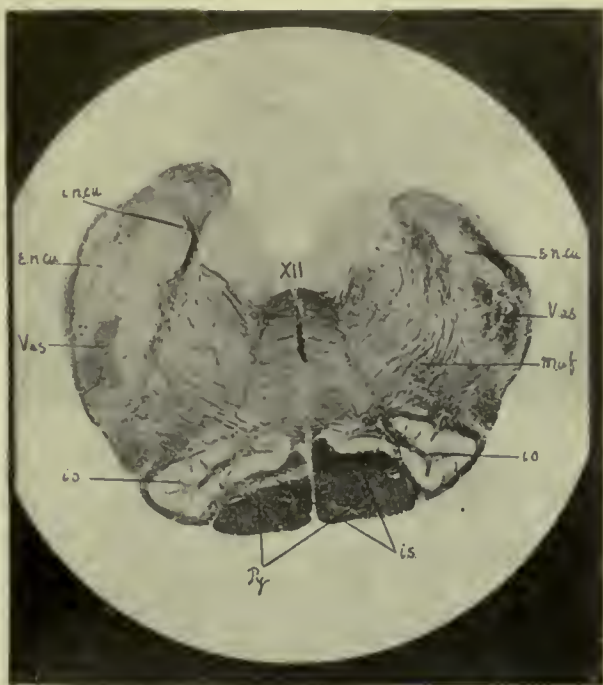


FIG. 384.—Transverse section of the medulla oblongata from the same case as the preceding somewhat higher up. (After Ferrier and Turner, *ibid.*, pl. lxxviii, Fig. 6.) Lettering as in the preceding figure.

*nucleus funiculi cuneati* go to the dorsal part of the same fibre-mass. The latter relation is well shown in Fig. 385, which represents a section stained by Weigert's method from a case in which Ferrier and Turner had cut the *corpus restiforme* and

destroyed the nucleus funiculi cuneati [Burdachi] on one side. They could not trace degenerated fibres beyond the thalamus.

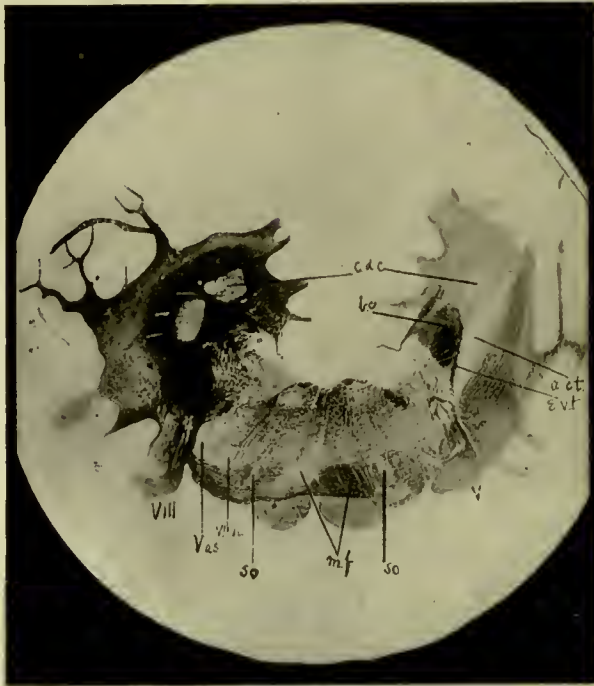

FIG. 385.—A frontal section through the rhombencephalon of a monkey after destruction of the nucleus funiculi cuneati and of the corpus restiforme. Staining by Weigert's method. (After Ferrier and Turner, *Phil. Tr., Lond.*, vol. clxxxv, 1894, B., pl. lxix, Fig. 5.) *mf*, lemniscus medialis; degeneration in its dorsal portion. In the cerebellum on the right side of the figure a large, fan-shaped sclerosed area (*a.c.t.*), formed chiefly by the direct fibres from the nucleus funiculi cuneati, is observable; owing to the fact that the restiform body was also destroyed, the sclerosed area contains in addition fibres from the nucleus funiculi gracilis and from the fasciculus cerebellospinalis. *e.v.t.*, tract between the cerebellum and Deiters' nucleus; *Vas*, tractus spinalis N. trigemini, degenerated on the left side owing to section of the nerve between the ganglion semilunare and the pons; *sa*, nucleus olivaris superior; *c.d.c.*, nucleus dentatus cerebelli; *V*, N. trigeminus; *VII*, nucleus N. facialis; *VIII*, N. vestibuli.

F. W. Mott,\* in a most convincing series of experiments, describes the course of the fibres from the nucleus funiculi gracilis et cuneati through the internal arcuates, decussation

\* Mott, F. W. *Experimental Enquiry upon the Afferent Tracts of the Central Nervous System of the Monkey*. *Brain, Lond.*, vol. xviii (1895), pp. 1-20.



of the lemniscus, interolivary layers, and medial lemniscus as far as the diencephalon. He followed degenerated fibres in the monkey as far as the ventro-lateral part of the thalamus, where the degeneration appeared to cease.

Tschermak\* has very recently attacked the problem again in Flechsig's laboratory at Leipzig. He destroyed the nuclei of the dorsal funiculi on one side in three cats, and studied the degenerations by the method of Marchi. He distinguishes four neurone systems, the perikaryons and dendrites of which are situated in the nuclei of the dorsal funiculi: (1) An uncrossed system from the nuclei of the dorsal funiculi to the cerebellum; (2) a crossing system from the nuclei of the dorsal funiculi to the cerebellum; (3) a crossing system from the nuclei of the dorsal funiculi to the thalamus; and (4) a crossing system from the nuclei of the dorsal funiculi to the cerebral cortex.†

The *first system* (uncrossed system from the nuclei of the dorsal funiculi to the cerebellum) originates mainly in the pars lateralis of the nucleus funiculi cuneati [Burdachi], the medullated axones passing partly as fibræ arcuatæ externæ dorsales into the corpus restiforme, partly directly from the anterior extremity of the nucleus into the corpus restiforme. Collaterals from these axones are given off to Deiters' nucleus in passing. Inside the cerebellum where the fibres of the corpus restiforme divide into two bundles—one lateral, the other medial—the fibres of the system under consideration enter the medial bundle and pass through it, giving off collaterals to the cerebellar nuclei, especially to the nucleus fastigii of both sides, finally terminating in the vermis inferior. This neurone system behaves much like the uncrossed dorso-lateral spino-cerebellar system (Flechsig's direct cerebellar tract, the fasciculus spino-cerebellaris dorso-lateralis), and

\* Tschermak, A. Ueber den centralen Verlauf der aufsteigenden Hinterstrangbahnen und deren Beziehungen zu den Bahnen im Vorderseitenstrang. Arch. f. Anat. u. Physiol., Anat. Abth., Leipz. (1898), S. 291-400.

† The German terms are: (1) *Das ungekreuzte Hinterstrangkern-Kleinhirnsystem* (*ungekreuzte dorsale Nucleo-Cerebellarsystem*); (2) *Das kreuzende Hinterstrangkern-Kleinhirnsystem* (*kreuzende dorsale Nucleo-Cerebellarsystem*); (3 u. 4) *Die beiden kreuzenden Hinterstrangkern-Grosshirnsysteme* (*Hinterstrangkern-Hauptschleifensysteme*); (3) = *Das Hinterstrangkern-Sehhügelsystem*; (4) = *Das Hinterstrangkern-Grosshirnrindensystem*.

accordingly the lateral part of Burdach's nucleus, or so-called nucleus of Blumenau, presents certain analogies with the nucleus dorsalis (Clarke's column) of the spinal cord, a point to which C. S. Sherrington, and also Blumenau, have already called attention.

The *second system* (crossing system from the nuclei of the dorsal funiculi to the cerebellum) originates mainly in the nucleus funiculi gracilis [Golli], but also in part from the pars medialis of the nucleus funiculi cuneati [Burdachi]. The medullated axones run as fibræ arcuatæ internæ to the raphe, mixed with similar arcuate fibres of the third and fourth systems. Having arrived in the stratum interolivare lemnisci of the opposite side, the medullated axones of the second system run between the pyramis and the nucleus olivaris inferior, thence along the ventro-lateral periphery of the medulla in the fibræ circum-olivares, partly around, and partly through the nuclei funiculi lateralis, to reach the area in which are situated the fibres of the fasciculus spino-cerebellaris dorso-lateralis (direct cerebellar tract). Mixed with the fibres of the latter, the fibres of the system we are considering enter the medial half of that bundle, lateral from the tractus spinalis nervi trigemini, which, headward, grows so rapidly in volume, and further on the fibres are situated in the medio-ventral part of the corpus restiforme. After giving off collaterals to Deiters' nucleus, the fibres of this system enter the lateral bundle (of the two fasciculi into which the corpus restiforme divides), give off collaterals to the nucleus dentatus, and ultimately terminate in the cortex of the vermis superior, chiefly on the corresponding side, but partly by way of the superior cerebellar decussation in the cerebellar cortex of the opposite side.

The *third system* (crossing system from the nuclei of the dorsal funiculi to the thalamus) and the *fourth system* (crossing system from the nuclei of the dorsal funiculi to the cerebral cortex), as described by Tschermak, will be considered a little further on, when the lemniscus medialis is discussed more in detail (Chap. XLVII). In the same place the results of the studies of human pathological cases will be taken up.

The method of Golgi has afforded interesting results, especially concerning the collaterals of the neurone systems originating in the nuclei of the dorsal funiculi. The work thus far with

this procedure has been done by Held,\* v. Kölliker,† Ramón y Cajal,‡ and Blumenau.\* The collaterals from the axones of the neurone systems on the way to the cerebellum have been referred to above. Still more interesting are the findings regarding the collaterals from the axones of the neurone systems pertaining to the lemniscus medialis. Thus from the *fibræ areolatae internæ*, before reaching the *decussatio lemniscorum*, there are collaterals given off to the nucleus N. hypoglossi, and to the *formatio reticularis grisea* (in this region represented by the nucleus centralis inferior Flechsigi and the nucleus lateralis inferior Flechsigi). On the far side of the raphe where the medullated axones run in the *stratum interolivare lemnisci*, long collaterals are given off which pass chiefly by way of the hilus into the cavity of the nucleus olivaris inferior to terminate in among the perikaryons and dendrites situated in the much wrinkled gray capsule which this body represents. Passing headward, the main axones enter the lemniscus medialis, arriving there by plunging through between the transverse fibres of the *corpus trapezoideum*, and then follow the course of the lemniscus, many fibres going as far as the diencephalon. In the pons where the lemniscus medialis forms the floor of the *pars dorsalis pontis*, large numbers of collaterals are given off to the adjacent masses of gray matter. Among these may be mentioned (1) collaterals to the nucleus centralis medius,|| especially to its ventral part; and (2) collaterals to the nuclei pontis, those large masses of *substantia grisea* situated among

---

\* Held, H. Beiträge zur feineren Anatomie des Kleinhirns und des Hirnstammes. Arch. f. Anat. u. Physiol., Anat. Abth., Leipz. (1893), S. 435-446.

† v. Kölliker, A. Handbuch der Gewebelehre des Menschen, 6. Aufl., Leipz. (1896).

‡ Ramón y Cajal, S. Beiträge zum Studium der Medulla oblongata, etc. Deutsche Uebersetz. von Bresler, Leipz. (1896).

\* Blumenau. Des noyaux du cordon postérieur et la substance de Rolando dans la bulbe. Neurol. Centralbl., Leipz., Bd. xv (1896), S. 1129.

|| This nucleus, so designated by P. Flechsig, appears to correspond to W. v. Bechterew's *Nucleus reticularis tegmenti pontis*; the latter author separates the ventral portion of the nucleus, that resting directly upon or even penetrating among the fibres of the medial lemniscus, from the main mass, and calls it the *medialer Schleifenkern*, to distinguish it from the more laterally placed nucleus lemnisci lateralis, or *lateral Schleifenkern*.



the fasciculi longitudinales and fibræ transversæ in the pars basilaris pontis (Fig. 386).

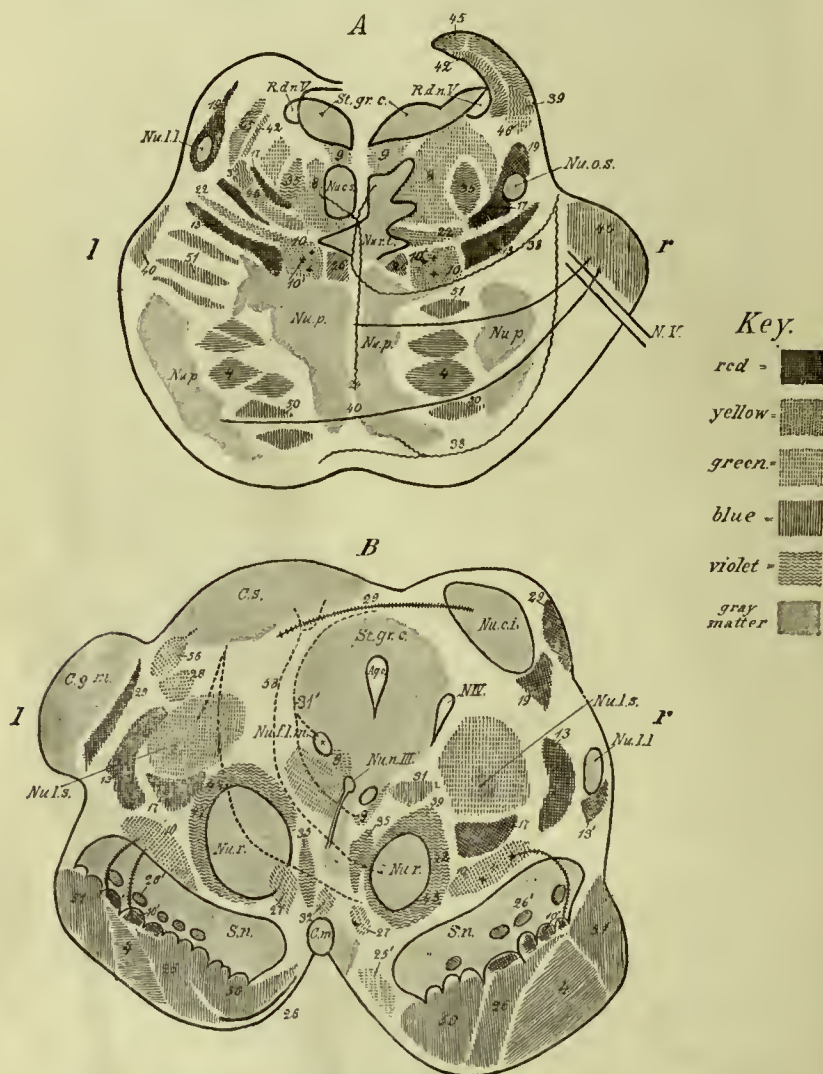


FIG. 386.—A, transverse section through the posterior half of the pons. The left half of the illustration corresponds to the anterior, the right half to the posterior portion of the pons. (After W. von Bechterew, 1894, somewhat modified.) *Nu.c.s.*, nucleus centralis superior; *Nu.l.l.*, nucleus lemnisci lateralis; *Nu.o.s.*, nucleus olivaris superior; *Nu.p.*, nuclei pontis; *Nu.r.t.*, nucleus reticularis tegmenti; *N.V.*, radix N. trigemini; *R.d.n.V.*, radix descendens



In the mesencephalon collateral branches (and possibly terminals of stem axones also) go from the axones of the lemniscus medialis to (1) the nucleus colliculi inferioris, (2) the strata grisea colliculi superioris, (3) the nucleus lateralis superior Flechsigi, (4) the nucleus centralis superior, (5) the nucleus commissurae posterioris (*obere Oculomotoriuskern* of Darkschewitsch), (6) the stratum griseum centrale (*centrale Höhlen-grau*), and (7) the substantia nigra.

(mesencephalica) nervi trigemini; *St.gr.c.*, stratum griseum centrale. *Red*—13, fibres of the lemniscus medialis pertaining to the nucleus funiculi cuneati; 10, scattered bundles in the lemniscus medialis; 17, region of scattered fibres which develop late in the lateral field of the formatio reticularis; 19, lemniscus lateralis. *Yellow*—10, fibres of lemniscus medialis originating in nucleus funiculi gracilis; 22, fibres from the region of the colliculus inferior to the nucleus reticularis tegmenti and to the pons. *Violet*—35, fibres of fasciculus centralis tegmenti (*centrale Haubenbahn*); 24, fibres passing by the raphe from the nuclei pontis to the formatio reticularis grisea; 33, fibres of the spinal bundle (von Bechterew) of the brachium pontis; 45, 39, 42, different bundles in the brachium conjunctivum. *Blue*—4, fasciculi longitudinales (pyramidales); 26, fibres of medial accessory bundle in lemniscus medialis (to motor nuclei of cerebral nerves); 46, fibres of cerebral bundle of brachium pontis; 50, frontal cerebrocortico-pontal path; 51, temporo-occipital cerebrocortico-pontal path. *Green*—9, fasciculus longitudinalis medialis; 8, fibres which represent the pontal continuation of the fasciculus lateralis proprius of the spinal cord; 46, commissural bundle lying ventralward from the brachium conjunctivum.

B, transverse section through the brain stem; level of pedunculi cerebri. The right half illustrates the level of the colliculus inferior, the left half that of the colliculus superior. (After W. von Bechterew, 1894, somewhat modified.) *Aq.c.*, aqueductus cerebri; *C.g.m.*, corpus geniculatum mediale; *C.m.*, corpus mamillare; *C.s.*, colliculus superior; *N.IV*, radix N. trochlearis; *Nu.c.i.*, nucleus colliculi inferioris; *Nu.f.l.m.*, nucleus fasciculi longitudinalis medialis or nucleus commissurae posterioris (*obere Oculomotoriuskern* of Darkschewitsch); *Nu.l.l.*, von Bechterew's *Corpus parabigeminum*; *Nu.l.s.*, nucleus lateralis superior of Flechsig (*nucleus innominatus* of von Bechterew); *Nu.n.III*, nucleus nervi oculomotorii; *Nu.r.*, nucleus ruber; *S.n.*, substantia nigra; *St.gr.c.*, stratum griseum centrale. *Red*—19, fibres of lemniscus lateralis which enter colliculus inferior; 29, fibres of brachium quadrigeminum inferius from the colliculus inferior of the same and of the opposite side; 13, fibres of the lemniscus medialis originating in the nucleus funiculi cuneati; 13', fibres of the lemniscus medialis going to the corpora quadrigemina; 10', scattered bundles of the lemniscus which go over into the basis pedunculi; 17, region of the scattered fibres (late to develop) of the formatio reticularis. *Yellow*—10, fibres of lemniscus medialis from the nucleus funiculi gracilis; 23, fibres from the nucleus colliculi inferioris to the thalamus (according to von Bechterew); 56, fibres from the colliculus superior to the cerebral cortex. *Violet*—39, 42, 45, fibres of the brachium conjunctivum before their entrance into the red nucleus; 47, 48, fibres from the red nucleus to the nucleus lentiformis, the thalamus, and the cerebral cortex (these are the radiations of the red nucleus); 35, fibres of the fasciculus centralis tegmenti (*centrale Haubenbahn*). *Green*—9, fasciculus longitudinalis medialis; 31, fibres of the dorsal part of the commissura posterior; 31', fibres of the ventral part of the commissura posterior; 27, fasciculus retroflexus Meynerti; 32, fasciculus thalamomammillaris (Vieq d'Azyri); 25', fasciculus pedunculomammillaris pars basilaris (pedunculus corporis mammillaris); 58, fibres from the substantia grisea of the colliculus superior to the region of the nucleus ruber of the opposite side. *Blue*—4, fasciculi longitudinales (pyramidales); 50, fibres of frontal cerebrocortico-pontal path (medial bundle in basis pedunculi); 51, fibres of occipito-temporal cerebrocortico-pontal path (lateral bundle in basis pedunculi); 26, fibres of the accessory bundle of the lemniscus; 26', fibres connecting the substantia nigra with the cerebral hemispheres.

Further on in the hypothalamic region of the diencephalon the studies with Golgi's method have thus far not yielded wholly satisfactory results, owing in large part to the complexity of the region and the paucity of our general knowledge concerning it. Held, however, observed with silver chromate impregnation large, coarse axones which enter the ventral part of the thalamus, where they divide manifoldly, and form thick feltworks of fine branchings extending for considerable distances. He made out that these axones come in part from the bands of white matter dorsal to the nucleus hypothalamicus, (corpus Luysii), and concluded that they correspond to the fibres of the sensory cerebral paths (both lemniscus medialis and brachium conjunctivum), and accordingly made the statement that at least a portion of these paths does not extend all the way without relay to the cerebral cortex, but that the neurone systems concerned terminate definitively in the thalamus. This observation is a pleasing confirmation of the views based upon the study of pathological degenerations in human beings with Weigert's method (von Monakow, Mahaim), and upon the examination of the central nervous systems of experimental animals (Singer and Münzer, F. W. Mott, Ferrier and Turner, Tschermak).

The studies of Blumenau with the method of Golgi proved that the axones of the cells of the nucleus funiculi gracilis, together with those from the pars medialis of the nucleus funiculi cuneati, pass chiefly in arches to the raphe, where they cross to the opposite side and assume a longitudinal direction in the stratum interolivare lemnisei. A number of these fibres bifurcate in the interolivary layer, one limb ascending, the other descending. He could follow the axones of the large perikaryons in the pars lateralis nucleï funiculi cuneati into the corpus restiforme.

It is obvious, therefore, that in addition to carrying impulses for long distances cerebralward, the neurone systems under consideration are well adapted for playing an important rôle in connection with the complicated reflex activities, the centres for which, it is believed, are situated in the medulla and pons.

## CHAPTER XL.

### THE NUCLEUS DORSALIS AND THE ASCENDING DORSO-LATERAL SPINO-CEREBELLAR NEURONE SYSTEM.

Clarke's column or the nucleus dorsalis—Perikaryons and dendrites—Axones of direct cerebellar tract—Myelinization—Relation to corpus restiforme—Terminations in cerebellum—Collaterals to nucleus dentatus.

(*ad b*) We have seen that collaterals and terminals from a certain definite region of the dorsal funiculi of the spinal cord, namely, those from the middle area of the fasciculus cuneatus (part of Fleschsig's middle root zone), enter and terminate in the nucleus dorsalis (Clarkii, Stillingi). This longitudinal column, described by Lockhart Clarke \* as the "posterior vesicular column," and called "Clarke's column" by von Kölliker, seen in cross section of the thoracic spinal cord on the medial side of the neck of the dorsal horn of gray matter on each side, extends uninterruptedly from the level of the third lumbar nerve below to that of the seventh cervical nerve above (Fig. 387, *C* and *D*). Corresponding masses, separated from the main column, are found in the sacral and cervical regions; that in the sacral cord is situated at the level of origin of the second and third sacral nerves, and is known as the "sacral nucleus" of Stilling.† The "cervical nucleus" is situated at the level of the third and fourth cervical nerves. In many respects the pars lateralis of the nucleus funiculi cuneati, or Blumenau's nucleus in the medulla, corresponds to the nucleus dorsalis of the spinal cord.

In the nucleus dorsalis are situated rather large multipolar cells with numerous much-branching dendrites (Fig.

---

\* Clarke, J. L. Phil. Tr., Lond. (1851), Pt. II.

† Stilling, B. Neue Untersuchungen ueber den feineren Bau des Rückenmarks. Cassel (1859), 4to.

388). Ramón y Cajal and von Lenhossék divide the cells in this nucleus, the majority of which are multipolar, into two groups—(1) stellate or polygonal; (2) spindle-shaped ele-

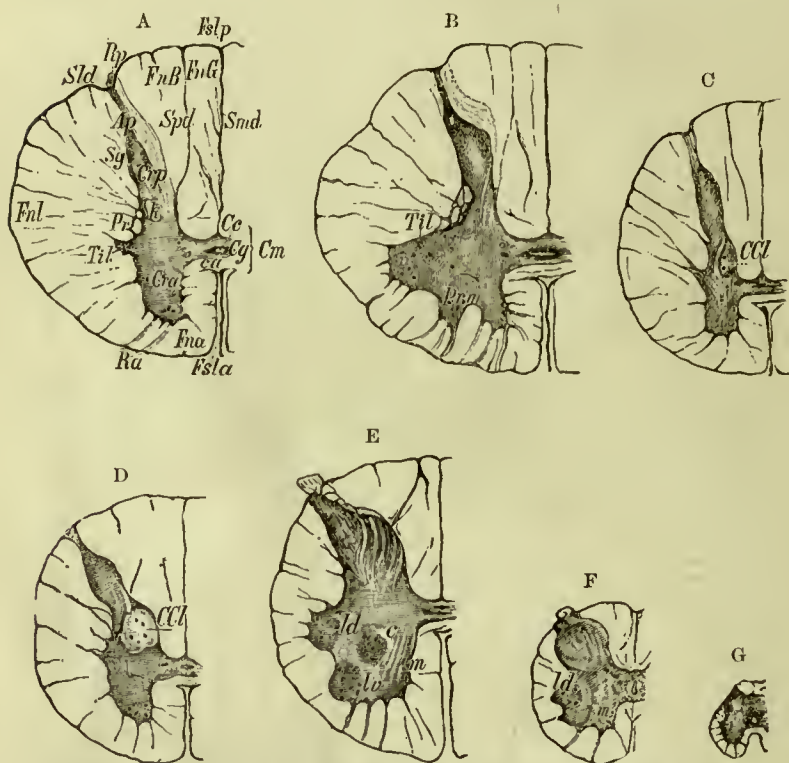


FIG. 387.—Cross sections through the human spinal cord, stained with carmine. (After H. Obersteiner, Anleitung beim Studium des Baues der nervösen Centralorgane im gesunden und kranken Zustande, III. Aufl., Leipz. u. Wien, 1896, S. 227, Figs. 96-102.) A, transverse section at the level of C iii; *Cg*, commissura grisea; *Ap*, apex columnæ dorsalis; *Ca*, commissura ventralis alba; *Cc*, canalis centralis; *Cm*, commissura medullæ spinalis; *Cra*, cornu ventralis; *Crp*, cornu dorsalis; *Fna*, funiculus ventralis; *Fnb*, fasciculus cuneatus Burdachi; *Fng*, fasciculus gracilis Golli; *Fnl*, funiculus lateralis; *Fsla*, fissura mediana ventralis; *Fslp*, sulcus medianus dorsalis; *k*, tractus solitarius; *Pr*, formatio reticularis; *Ra*, radix ventralis; *Rp*, radix dorsalis; *Sg*, substantia gelatinosa Rolandi; *Sld*, sulcus lateralis dorsalis; *Smd*, septum medianum dorsale; *Spd*, septum intermedium dorsale; *Til*, tractus intermedio-lateralis. B, transverse section at the level of C vi; *Prm*, processus cervicalis medius cornu ventralis; *Til*, columna intermedio-lateralis. C, transverse section at the level of T iii; *CCl*, nucleus dorsalis Clarkii. D, transverse section at the level of T xii; *CCl*, nucleus dorsalis. E, transverse section at the level of L v; *m*, medial cell group of the cornu ventralis; *lv*, lateral ventral, *ld*, lateral dorsal, and *c*, central cell group. F, transverse section at the level of S iii; *m*, medial, *ld*, lateral-dorsal cell group. G, transverse section through the lower part of the conus medullaris at the level of origin of the N. coccygeus.



ments. Mann\* has reconstructed examples of the nerve cells of this nucleus, one thousand times enlarged. He asserts that the cells are essentially bipolar (in agreement with Mott), and that they send one axis cylinder upward, the other downward.

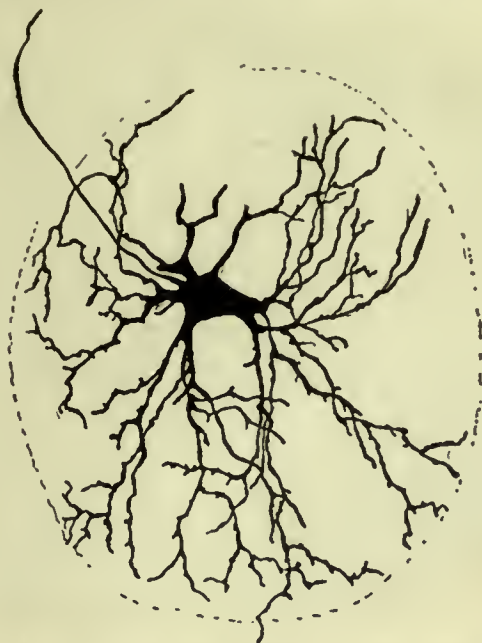

FIG. 388.—Nerve cell from the nucleus dorsalis of a human embryo 32 cm. long. Method of Golgi. (After M. von Lenhossék, *Der feinere Bau des Nervensystems*, etc., Berl., II. Aufl., 1895, S. 347, Fig. 53.) The axone of the cell shown at the upper left of figure becomes the axis cylinder of a medullated fibre of the fasciculus cerebello-spinalis (or direct cerebellar tract).

The axones of most of the cells situated here pass out, though sometimes rather indirectly, to the fasciculus cerebello-spinalis (direct cerebellar tract or *Kleinhirnseitenstrangbahn* of Flechsig) of the same side. Flechsig's† studies of myelination (Fig. 389), and those of Mott,‡ and especially of H. T.

\* Mann, G. Structure of Nerve Cells as shown by Wax Models. Report of the Sixty-sixth Meeting of the British Association for the Advancement of Science, held at Liverpool in 1896, pp. 980-981.

† Flechsig, P. *Die Leitungsbahnen im Gehirn und Rückenmark*. Leipz. (1876), S. 295.

‡ Mott, F. W. Microscopical Examination of Clarke's Column in Man, the Monkey, and the Dog. *J. Anat. and Physiol.*, Lond., vol. xxii (1887-'88),

Patrick\* on secondary degenerations, made it almost certain that the axones of the cells of the nucleus dorsalis pass upward in this tract. The actual proof of this has, it is said, been fur-

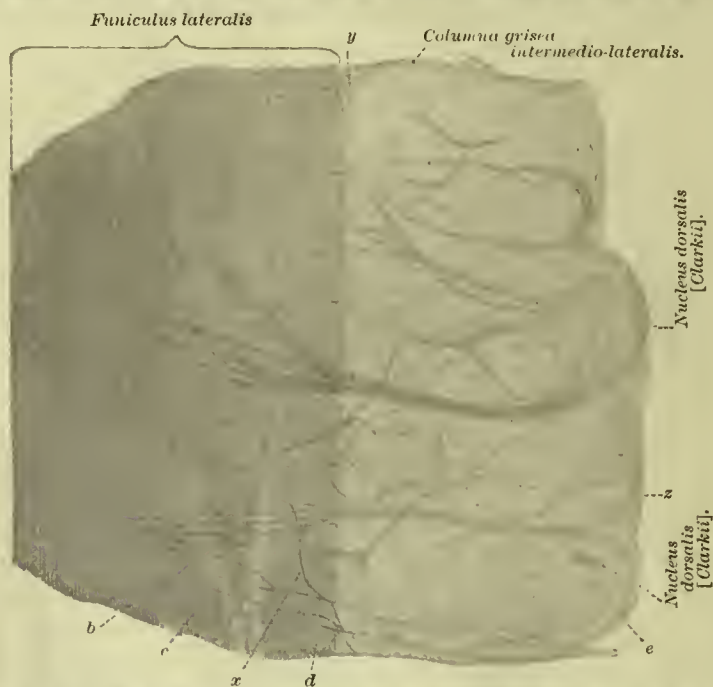

FIG. 389.—Frontal longitudinal section at the junction of the pars thoracalis and pars lumbalis of the spinal cord, illustrating the relation of the nucleus dorsalis to the fasciculus spino-cerebellaris dorso-lateralis. (After P. Flechsig, *Die Leitungsbahnen im Gehirn und Rückenmark des Menschen*, etc., Leipz., 1876, Taf. xviii, Fig. 2.) *b*, bundle from the nucleus dorsalis to the direct cerebellar tract, the horizontal direction being maintained until the compact part of the latter is reached; *c*, fasciculus cerebro-spinalis lateralis; *d*, substantia alba (limiting layer); *e*, medullated axones from nucleus dorsalis to fasciculus spino-cerebellaris dorso-lateralis (direct cerebellar tract); *x*, fibre taking a steplike course, doubtless belonging to the direct cerebellar tract; *z*, fibre bundle of unusual course near the nucleus dorsalis; *y*, fibre bundles which bend around out of the horizontal direction to descend longitudinally (nature doubtful).

nished by Laura. The axones are very long, running the whole length of the spinal cord to the medulla, whence they pass by way of the corpus restiforme into the cerebellum. The fibres

pp. 479-495.—The Bipolar Cells of the Spinal Cord and their Connections. Brain, Lond., vol. xiii (1890), pp. 433-448.

\* Patrick, H. T. On the Course and Destination of Gowers' Tract. J. Nerv. and Ment. Dis., N. Y., vol. xxiii (1896), pp. 85-107.

which in the adult are of a very large calibre become medullated at a later period in the embryo than those of the lateral ground bundle.

In the thoracic cord the medullated axones of the uncrossed dorso-lateral spino-cerebellar tract which we are here considering make up a rather narrow stripe at the periphery of the dorsal half of the lateral funiculus. They thus occupy the region between the lateral pyramidal tract and the surface of the cord, and are situated dorsally as regards Gowers' tract (Fig. 390). The fibres, corresponding to the location of their

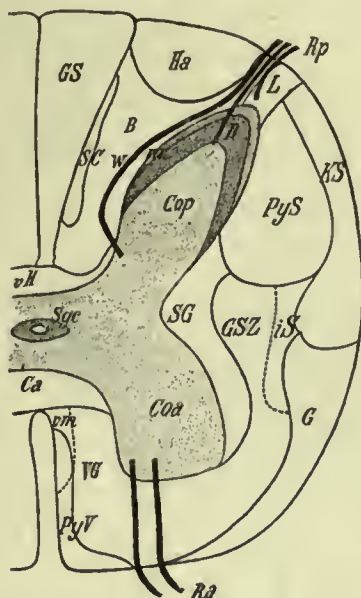


FIG. 390.—Schematic transverse section through the pars cervicalis of the medulla spinalis. (After H. Obersteiner, *Anleitung beim Studium des Baues der nervösen Centralorgane*, etc., III. Aufl., Leipz. u. Wien, 1896, S. 257, Fig. 113.) *B*, fasciculus cuneatus Burdachii; *Ca*, commissura ventralis; *Coa*, cornu ventralis; *Cop*, cornu dorsalis; *G*, fasciculus ventro-lateralis Gowersi; *GS*, fasciculus dorsalis Golli; *GSZ*, mixed bundle of funiculus lateralis; *Ha*, dorso-lateral field of funiculus dorsalis; *iS*, intermediary bundle of funiculus lateralis; *KS*, fasciculus cerebello-spinalis or direct cerebellar tract of Flechsig; *L*, Lissauer's fasciculus; *m*, marginal zone; *PyS*, fasciculus cerebro-spinalis lateralis or lateral pyramidal tract; *PyV*, fasciculus cerebro-spinalis ventralis or ventral pyramidal tract; *R*, substantia gelatinosa Rolandi; *Ra*, radix ventralis; *Rp*, radix dorsalis; *SC*, comma of Schultze; *SG*, lateral limiting layer; *Sgc*, substantia sulco-marginalis; *Vg*, fasciculus ventralis proprius; *vH*, ventral field of dorsal funiculi; *em*, fasciculus sulco-marginalis; *w*, dorsal root fibre.

cells of origin, appear first in the uppermost part of the lumbar cord, and gradually increase in mass as the cord is ascended,

owing to the continued accession of new fibres from the nucleus dorsalis at successive levels. At the junction of the cervical cord with the medulla oblongata this fasciculus cerebello-spinalis Flechsigi comes to occupy the angle between the gray matter of the dorsal horn and the lateral surface of the cord. The fibres become displaced dorsalward and help to build the corpus restiforme, being the earliest of the fibres of the latter bundle to become medullated (Fig. 391). The fibres of the

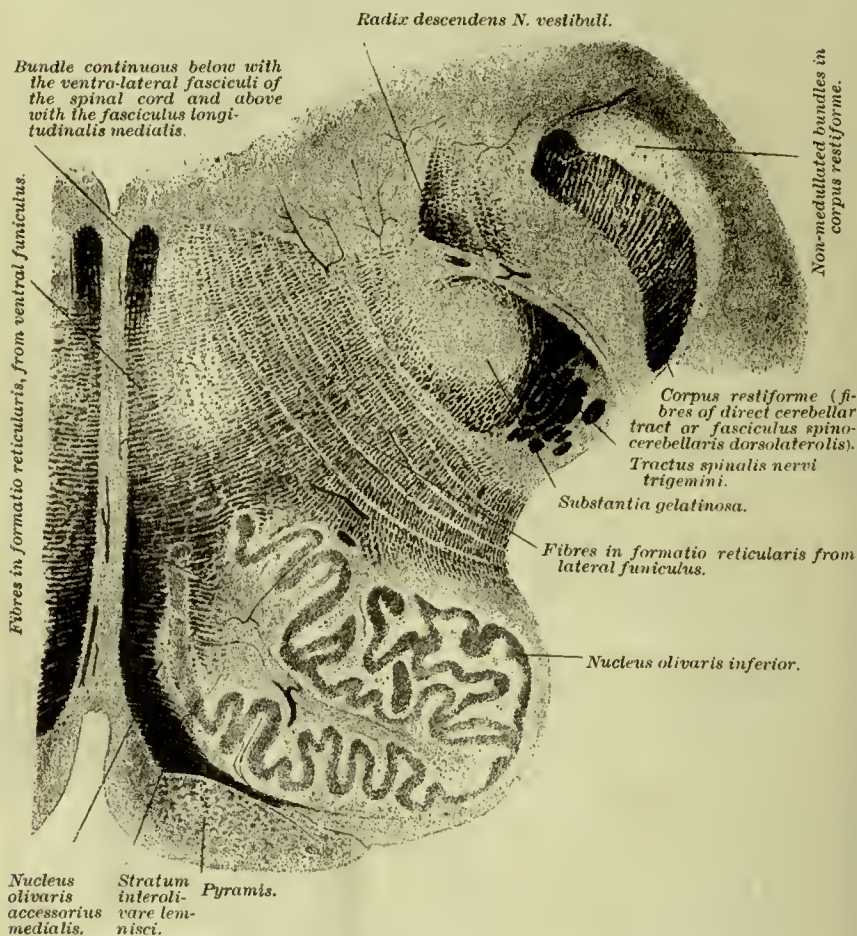


FIG. 391.—Transverse section through upper third of medulla oblongata of a fetus 40 cm. long. (After P. Flechsig, *Die Leitungsbahnen*, etc., Leipz., 1876, Taf. xi, Fig. 2.)



direct cerebellar tract are medullated at the fifth month of foetal life (Bruce). In foetuses from 25 to 27 cm. long, one can follow these medullated axones in serial sections up through the

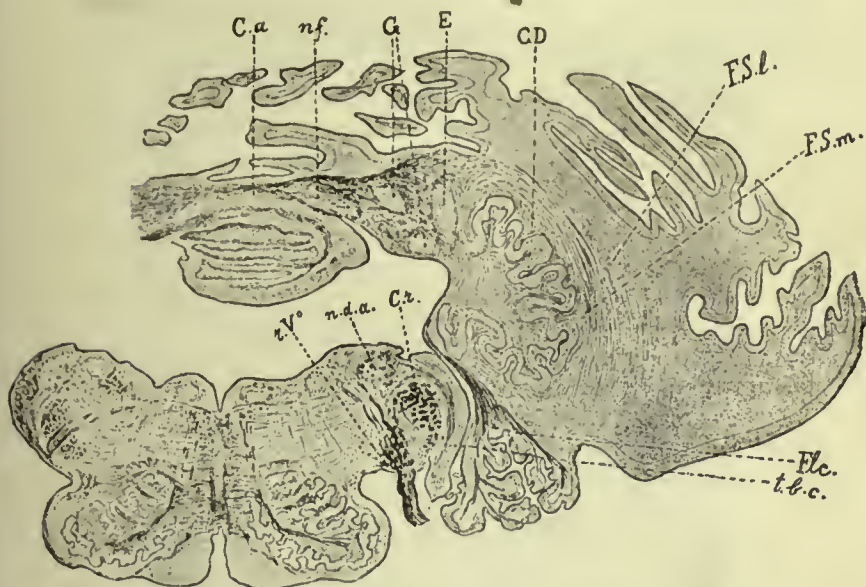


FIG. 392.—Frontal section of medulla oblongata and cerebellum of seven months' fetus at level of last (proximal) portion of nucleus fastigii. The nucleus globosus consists of several parts. (After Sancte de Sanctis, *Monatsschr. f. Psychiat. u. Neurol.*, Berl., Bd. iv, 1898, p. 276, Fig. 7.) *C.a.*, large anterior decussation commissure; *CD.*, corpus dentatum sen eiliarc; *Cr.*, corpus restiforme; *E.*, nucleus emboliformis; *Flc.*, flocculus, with its peduncle; *F.S.l.*, fibræ semicirculares laterales; *F.S.m.*, fibræ semicirculares mediales; *G.*, nucleus globosus; *n.d.a.*, nucleus nervi vestibuli; *nf.*, nucleus fastigii; *r.V°*, tractus spinalis nervi trigemini; *t.b.c.*, nucleus nervi cochleæ dorsalis.

corpus restiforme to their terminations in the vermis. They pass by the anterior part (giving off collaterals to it) of the corpus dentatum mainly on its lateral side to pass out to the cortex of the dorsal and proximo-ventral portion of the vermis, partly on the same side, but to a great extent by way of the large commissure (Figs. 392 and 393) also, on the opposite side, where the fibres enter the gray substance, lose their myelin sheaths, and terminate by end-ramifications in among the nerve cells and their processes situated there. Another smaller portion of the corpus restiforme, its so-called "medial bundle," passes, partly medially and ventrally as regards the cerebellar nuclei (nucleus dentatus, nucleus globosus, nucleus emboli-

formis, and nucleus fastigii), partly actually through these gray masses to terminate chiefly in the cortex of the vermis inferior. Some of the fibres, however, pass through the commissura cerebelli inferior, others through the interfastigial commissure. It is not surprising, therefore, that some time after section of the fasciculus in the upper cervical cord in young animals von Monakow should find that there had resulted atrophy of the corresponding half of the vermis. The area which is occupied by these fibres is shown in Fig. 394. The fact that the fasciculus cerebello-spinalis,\* all the way from the lower

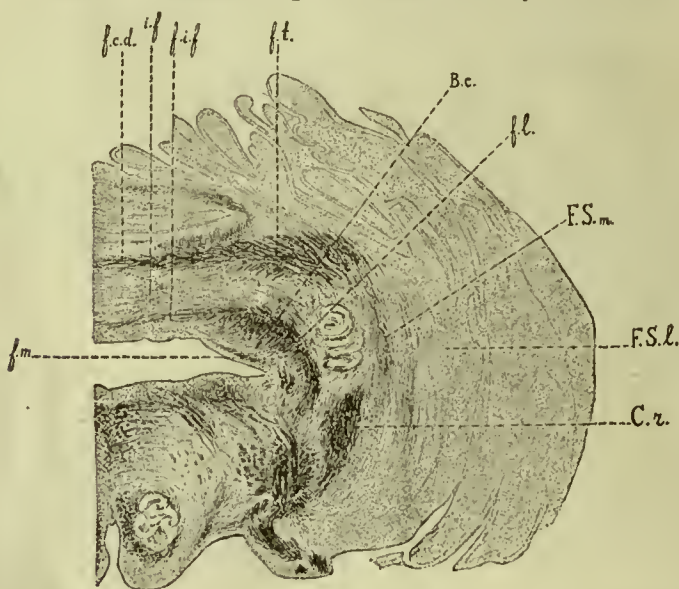


FIG. 393.—Frontal section of medulla oblongata and cerebellum of seven months' foetus at level of proximal extremity of nucleus fastigii and nucleus dentatus. (After Sancte de Sanctis, *Monatsschr. f. Psychiat. u. Neurol.*, Berl., Bd. iv, 1898, p. 277, Fig. 8.) *B.c.*, brachium conjunctivum; *C.r.*, corpus restiforme; *f.c.d.*, fibre commissurales dorsales; *f.i.f.*, fibre infrafastigiales; *f.l.*, fibres lying lateral from the brachium conjunctivum, which join the fibre infrafastigiales; *f.m.*, fibres lying medial to the brachium conjunctivum, related to Deiters' nucleus; *F.S.l.*, fibre semicirculares laterales; *F.S.m.*, fibre semicirculares mediales; *f.t.*, transverse fibres belonging to the large anterior commissure; *i.f.*, interfastigial decussation.

\* On account of the direction in which impulses are conducted by this tract it is unfortunate that it has been designated a *cerebello-spinal* fasciculus; it would be more appropriate to apply the term *spino-cerebellar* to the bundle. In a revision of the nomenclature, I would suggest that *fasciculus spino-cerebellaris dorso-lateralis* be considered as a suitable name for the tract.

thoracic region to the corpus restiforme in the medulla, is situated on the very surface of the cord explains why in diseases like cerebro-spinal meningitis it is especially exposed to injury.\*



FIG. 394.—Frontal section through rhombencephalon of monkey; destruction of nucleus funiculi euneati and corpus restiforme. Weigert's method. (After Ferrier and Turner, Phil. Tr., Lond., vol. clxxxv, 1894, B., pl. lxix, Fig. 5.) *mf*, lemniscus medialis; degeneration in its dorsal portion. In cerebellum on right side is a large, fan-shaped sclerosed area (*a.c.t.*), formed chiefly by direct fibres from the nucleus funiculi euneati; the sclerosed area contains in addition fibres from the nucleus funiculi gracilis and from the fasciculus cerebello-spinalis. *e.v.t.*, tract between the cerebellum and Deiters' nucleus; *f.us*, tractus spinalis N. trigemini, degenerated on the left side; *so*, nucleus olivaris superior; *c.d.c.*, nucleus dentatus cerebelli; *V*, N. trigeminus; *VIII*, nucleus N. facialis; *VIII*, N. vestibuli.

According to Patrick, whose studies are among the most careful we possess, a certain number of the fibres of the fasciculus do not enter the cerebellum through the corpus restiforme, but pass on further headward in company with the fibres of Gowers' tract.

\* Barker, L. F. On Certain Changes in the Cells of the Ventral Horns and of the Nucleus Dorsalis (Clarkii) in Epidemic Cerebro-spinal Meningitis. Brit. M. J., Lond. (1897), ii, pp. 1839-1841.

## CHAPTER XLI.

### ON GOWERS' TRACT AS A COMPLEX OF FIBRE-SYSTEMS.

The fasciculus ventro-lateralis superficialis (Gowersi)—Degenerations in the ventro-lateral region—Upward continuation of Gowers' tract—Studies of Loewenthal, Auerbach, Mott, Patriek, Hoche, and others—The ventro-lateral conjunctival spino-cerebellar neurone system—Sensory crossing of Edinger—The ventro-lateral superior spino-quadrigeminal neurone system—The ventro-lateral spino-thalamic system—Relations to the lemniscus lateralis—Rossolimo's studies—The inferior spino-quadrigeminal neurone system—The spino-peduncular neurone system (to the substantia nigra)—The spino-lentiformal neurone system—The ventro-lateral spino-cerebellar restiformal neurone system.

(*ad c*) The cell bodies of the neurones, the axones of which go to make the fasciculus ventro-lateralis superficialis (Gowersi), ordinarily known as Gowers' tract, are situated in the gray matter of the spinal cord, apparently, partly in the central portion of the ventral horns, partly in the middle zone of the gray substance (v. Lenhossék). The axones of the fasciculus come in part directly from the gray matter of the same side of the cord (axones of tautomeric neurones), in part indirectly from the gray matter of the opposite side\* of the cord by way of the ventral commissure (axones of heteromeric neurones). The corresponding bundle of medullated axones in the white matter, which bears the name of the distinguished English neurologist Gowers,† degenerates upward on transverse lesions of the cord,

---

\* Guarnieri, G., ed. A. Bignami. *Ricerchi sui centri nervosi di un amputato*. Boll. d. Soc. Lancisiana d. osp. di Roma, vol. viii (1888), p. 163. The reader is referred also to the researches of Edinger and of Mott.

† Gowers, W. R. *Diagnosis of the Diseases of the Spinal Cord*. London (1897).—*Bemerkungen ueber die antero-laterale aufsteigende Degeneration im Rückenmark*. Neurol. Centralbl., Leipz., Bd. v (1886), S. 97–99.—*Weitere Bemerkungen ueber den aufsteigenden antero-lateralen Strang*. Neurol. Centralbl., Leipz., Bd. v (1886), S. 150.—*On the Antero-lateral Ascending Tract of the Spinal Cord*. Lancet, Lond. (1886), i, p. 1153; also in *Asclepiad*, Lond., vol. iii (1886), pp. 278–281.



a fact determined by Gowers himself, and confirmed by Tooth, Francotte, Barbacci, and others. The size and position of the degenerated area varies according to the position of the lesion, owing to the circumstance that the tract is made up of fibres which enter it at various segments of the cord. The tract first becomes visible in the uppermost region of the lumbar cord, being situated on the surface of the lateral funiculus ventrally and laterally as regards the lateral pyramidal tract; it increases notably in volume as the cord is ascended. Higher up in the thoracic region the fibres form a stripe along the ventro-lateral

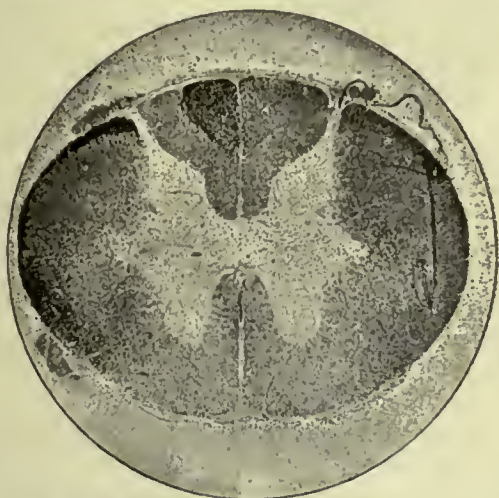

FIG. 395.—Transverse section of spinal cord at level of the fourth cervical segment to show ascending degeneration of Gowers' tract. (After F. W. Mott, *Brain*, Lond., vol. xv, 1892, p. 228, Fig. 1.) The degenerated fibres are stained black in the fasciculus gracilis, in the fasciculus spino-cerebellaris dorso-lateralis, and in the fasciculus ventro-lateralis superficialis. The degeneration resulted from hemisection on the right side, at the level of T i and T ii.

aspect of the cord in front of the fasciculus cerebello-spinalis Flechsigi, but among them are mixed many fibres of the fasciculus ventralis et lateralis proprius. In the cervical cord Gowers' bundle forms a more extensive and more compact mass, extending from the direct cerebellar tract of Flechsig behind to the ventral roots in front (Fig. 395). It would appear that many of the fibres in the tract under consideration continue up for only a short distance when they turn in to end in the gray matter of the cord, thus representing shorter and longer longitudinal association tracts between the spinal segments. Thus,

in human cases, where a spinal lesion has existed low down in the cord the main mass of the ascending degeneration in Gowers' tract can be followed as a rule no farther up than the cervical cord. In the case described by Gowers, of lesion in the upper part of the lumbar enlargement, it was impossible to follow the degeneration above the upper part of the cervical enlargement, and in a case of lumbar paraplegia, studied by Schaffer\* with Marchi's method, it was not possible to follow degenerated fibres in Gowers' bundle above the level of the root of the second cervical nerve. Moreover, in lesions at any level, the number of fibres degenerated decreases progressively as successive sections in an ascending direction are studied. According to the observations of Barbacci and others, the longest fibres of this fasciculus run in the parts of the tract situated nearest to the periphery of the cord.

The upward continuation in the medulla of Gowers' tract has been the topic of much discussion. A number of investigators believe that a portion of it at least is continued directly or by relay into the medial lemniscus. Von Beechterew, who independently isolated the fasciculus as a separate tract by the embryological method of Flechsig, states that it is medullated at the beginning of the eighth month of foetal life. He followed it into the medulla as far as the region of the nuclei laterales, where it lies close to the periphery of the ventro-lateral surface. He inclined to the view that the fibres of Gowers' bundle terminate in the more ventral of the two nuclei laterales. It was early shown, however, by the experiments of Loewenthal,† that destruction of the left lateral funiculus in the dog was followed by a degeneration of the fasciculus ventro-lateralis superficialis which could be followed up to the uppermost part of the pons, where it turns dorsalward in order to pass near the brachium conjunctivum through the velum medullare anterius into the cerebellum. At that time Loewenthal named this fasciculus the "ventral cerebellar path." Similar experiments were made

---

\* Schaffer, K. Beitrag zur Histologie der secundären Degeneration; zugleich ein Beitrag zur Rückenmarksanatomie. Arch. f. mikr. Anat., Bonn, Bd. xliii (1894), S. 252-266.

† Loewenthal, N. Dégénérations secondaires ascendantes dans le bulbe rachidien, dans le pont et dans l'étage supérieur de l'isthme. Rev. méd. de la Suisse rom., Genève, t. v (1885), pp. 511-533.

by Auerbach\* with the aid of Marchi's method; he was able to follow the degenerated fibres to their termination in the ventral parts of the superior vermis. He found three fasciculi extending from the cord to the cerebellum: (1) a dorsal cerebellar tract

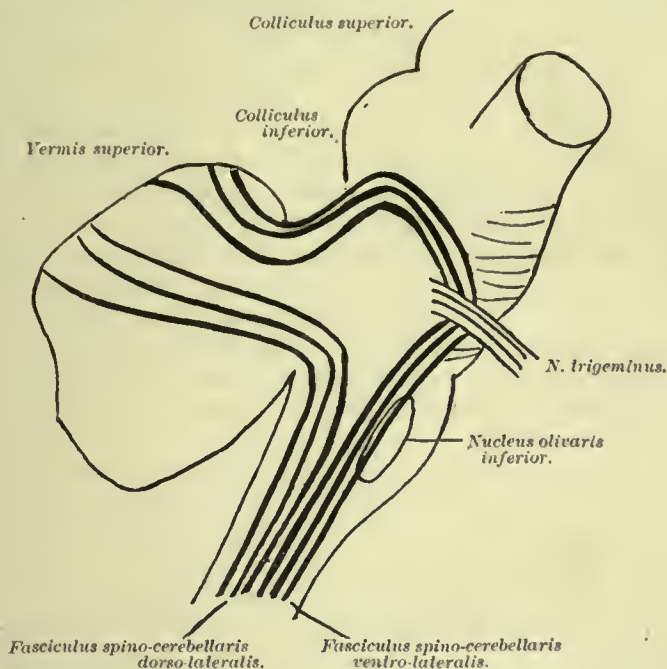


FIG. 396.—Diagrammatic representation of the course of the fibres of the two principal tracts ascending from the spinal cord to the cerebellum. (After F. W. Mott, *Brain*, Lond., vol. xv, 1892, p. 219, Fig. 1.) The fasciculus spino-cerebellaris ventro-lateralis Gowersi and the fasciculus spino-cerebellaris dorso-lateralis are united in the cord and in the lower part of the medulla. The latter passes into the corpus restiforme and terminates in the dorsal portion of the superior vermis. The former remains ventrally situated until it reaches the level of the N. trigeminus; passing beyond this it forms a loop backward to reach the dorso-lateral surface of the brachium conjunctivum. The fibres then course backward and sweep round into the anterior portion of the superior vermis.

(Flechsig's tract) ending in the dorsal part of the vermis superior; (2) a ventral cerebellar tract (Gowers' tract) ending in the ventral parts of the vermis; and (3) a third smaller bundle arising in the

\* Auerbach, L. Zur Anatomie der aufsteigend degenerierenden Systeme des Rückenmarks. *Anat. Anz*, Jena, Bd. v (1890), S. 214-216.—Zur Anatomie der Vorderseitenstrangreste. *Arch. f. path. Anat.*, etc., Berl., Bd. exxi (1890), S. 199-209.

lumbar cord and accompanying Gowers' tract as far as the level of exit of the nervus trigeminus, where it left the latter to pass through the corpus restiforme into the cerebellum toward the nucleus dentatus. The exact course of the fibres has also been very carefully worked out by Mott\* and by Schaefer in monkeys by means of experimental section and subsequent study by Marchi's method. The English neurologists find that in the pons the fibres "leave their ventral situation, forming a loop over the fifth nerve; they are then directed obliquely upward and backward, to the surface of the superior peduncle, forming a layer of fibres continuous with the valve of Vieussens and separated from the peduncle by a thin layer of gray matter; they then run downward on the posterior surface of the peduncle as far as its junction with the cerebellum at the isthmus, where these degenerated fibres can be seen streaming inward to the superior vermis." The accompanying diagram shows in general the course of the two principal tracts which ascend from the spinal cord to the cerebellum (Fig. 396).

In human beings, however, the upward continuation of Gowers' tract above the medulla was first followed by Patrick† as far as the region of the corpora quadrigemina (Fig. 397).

He found along with the degeneration of the ventro-lateral spino-cerebellar bundle marked degeneration in the lateral lemniscus. In 1896 he published in this country the results of his experiments on cats with the aid of the method of Marchi. He found after hemisection or total transverse lesion of the spinal cord ascending degeneration in the region of Gowers' tract as far as the cerebellar worm, and stated that whereas the dorso-lateral spino-cerebellar tract terminates in the dorsal and proximo-ventral portions of the vermis, the fibres of the ventro-lateral spino-cerebellar tract are ultimately distributed in the ventral and distal dorsal parts of the vermis as well as to the lateral lobe.

\* Mott, F. W. Ascending Degenerations resulting from Lesions of the Spinal Cord in Monkeys. *Brain*, Lond., vol. xv (1892), pp. 215-229.

† Patrick, Hugh T. Ueber aufsteigende Degeneration nach totaler Quetschung des Rückenmarkes (Anhang zu dem Aufsätze von Dr. Bruns: Ueber einen Fall von totaler traumatischer Zerstörung des Rückenmarkes, etc.). *Arch. f. Psychiat. u. Nervenkr.*, Berl., Bd. xxv (1893), S. 831-844; also *J. Nerv. and Ment. Dis.*, N. Y., vol. xxiii (1896), pp. 85-107.



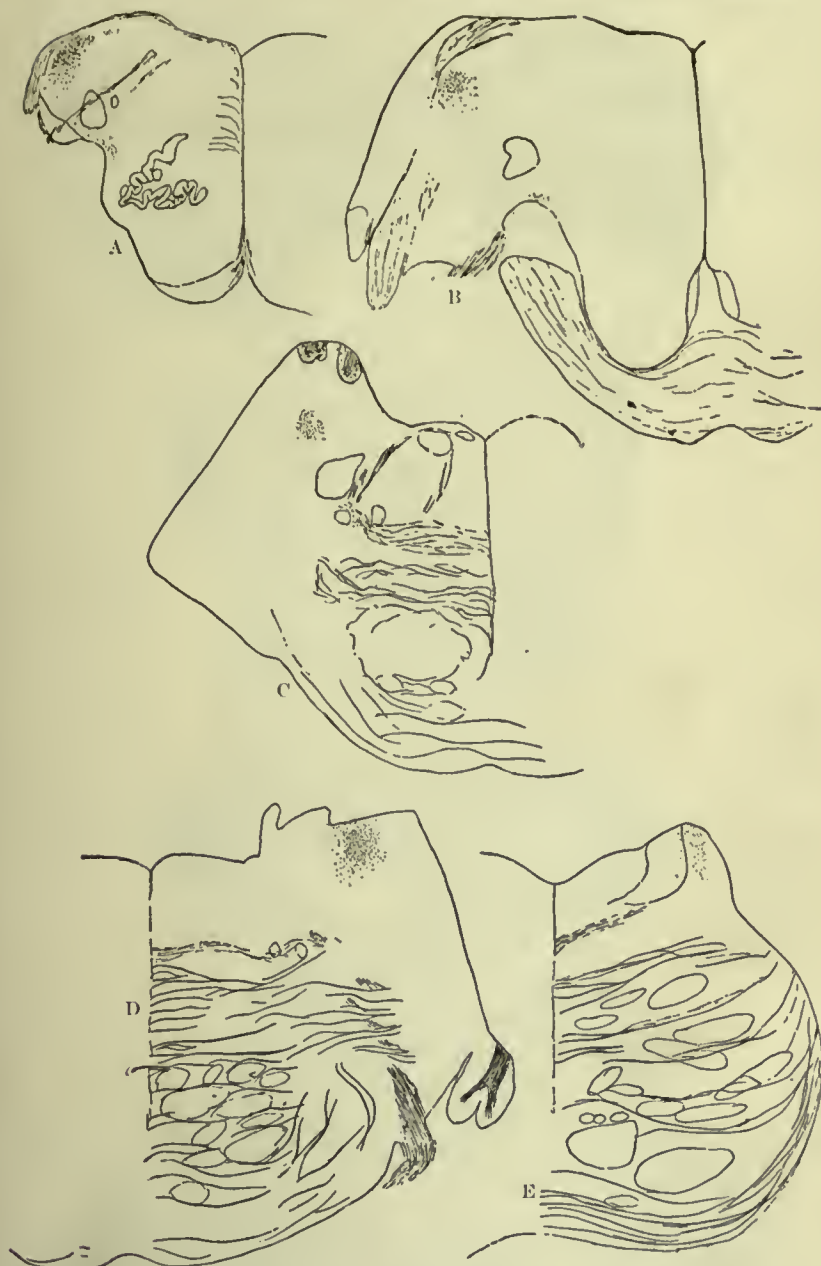

FIG. 397.—Degeneration of Gowers' tract above the medulla oblongata. (After H. T. Patriek, *Arch. f. Psychiat., Berl.*, Bd. xxv, 1893, S. 834 *et seq.*)

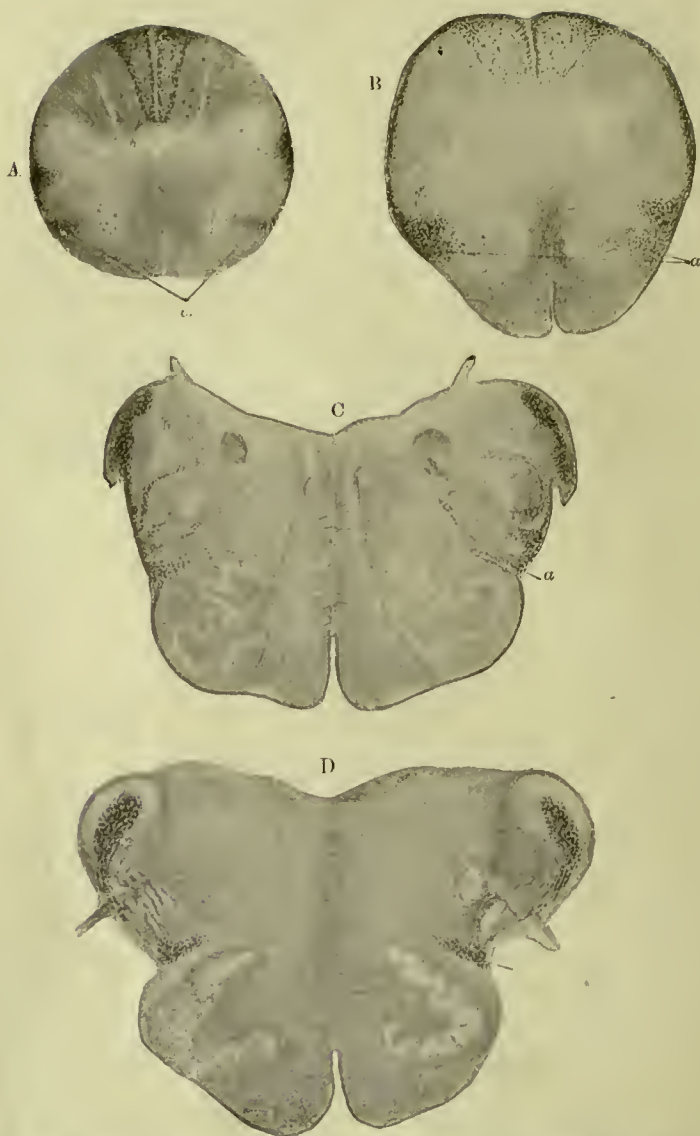
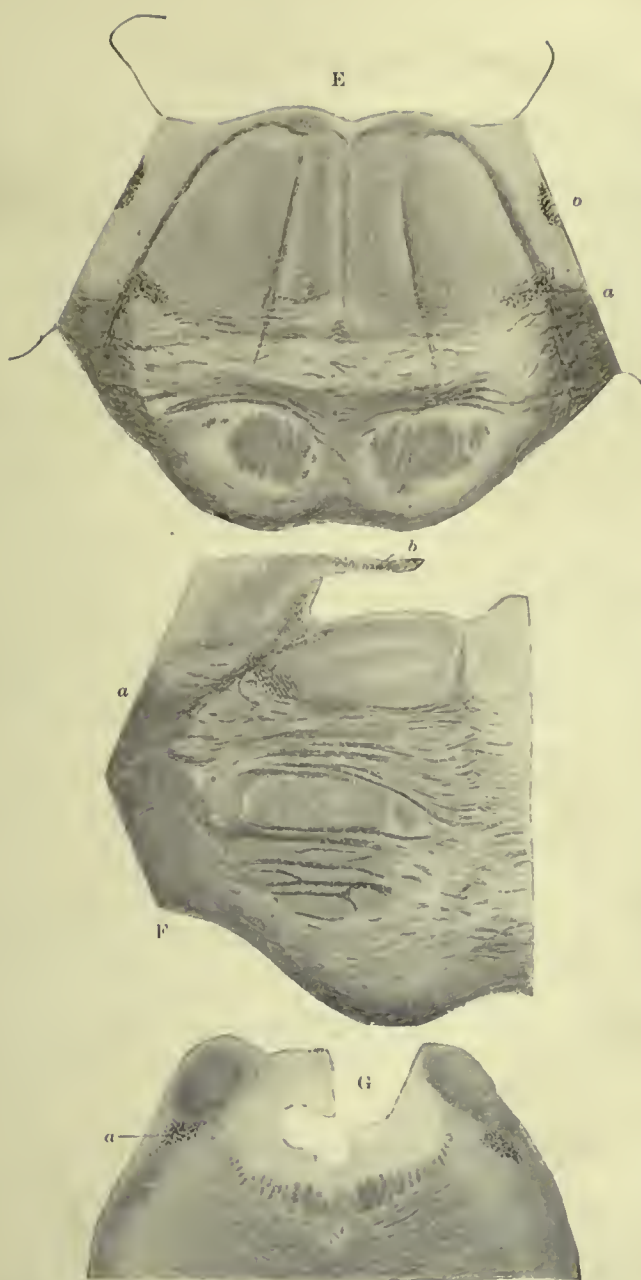

FIG. 398.—Ascending degeneration of the fasciculus ventro-lateralis Gowersi after transverse lesion of the human cord at the level of T VII. Method of Marchi. (After A. Hoche, *Arch. f. Psychiat. u. Nervenkr.*, Ber., Bd. xxviii, 1896, Taf. ix, Figs. 3-9.) A, level of decussatio pyramidum; a, Gowers' bundle. B, level of decussatio lemniscorum; a, Gowers' tract. C, level of the inferior half of the nucleus olivaris inferior. D, level of the superior half of the nucleus olivaris inferior. E, level of the genu internum radialis N. facialis; a, Gowers' tract; b, degenerated area in corpus restiforme.



forme. F, transverse section at the level of the radix N. trigemini; *a*, Gowers' bundle bending around into the hook; *b*, Gowers' bundle after the hook formation, running back into the cerebellum. G, transverse section at the level of the inferior colliculus; *a*, the portion of Gowers' bundle which, according to Hoche, extends farthest cerebralward.

Risien Russell \* finds that in man the fibres of Gowers' tract begin as far down as the third or fourth lumbar segment. He insists further that though there is marked "overlapping" or "mixing" of the efferent with the afferent tracts in the ventro-lateral region of the cord, the main representation of the afferent tract is internal to that of the efferent tract, that is to say, Gowers' tract is separated from the periphery of the cord by efferent fibres.

In 1896, Hoche † was able in two human cases to follow the tract through various levels of the cord, medulla, pons, and midbrain, and thence back through the brachium conjunctivum or medullare anterius into the cerebellum. The findings in one of his cases are well illustrated in Fig. 398. In the second of his cases he thought he could make out a decussation of the fibres in the roof of the fourth ventricle. It is evident, therefore, that Testut, Edinger, and Mott are correct in assuming the existence of two direct tracts from the spinal cord to the cerebellum, and it seems likely that, in the future, Flechsig's tract will be known as the fasciculus spino-cerebellaris dorsalis (or dorso-lateralis), and Gowers' tract as the fasciculus spino-cerebellaris ventralis (or ventro-lateralis).

The cerebellar termination of Gowers' tract has been made out also in human cases with Marchi's method by v. Sölder ‡ and by Worotynski.\*

The newer investigations make it appear that what we have designated above as Gowers' tract consists of at least several distinct neurone systems. The principal mass is the fasciculus spino-cerebellaris ventro-lateralis, which goes through the brachium conjunctivum or velum medullare anterius to terminate in the cerebellum. This corresponds to the ventro-lateral conjunctival spino-cerebellar system of the Swiss and Germans, and

\* Russell, J. S. R. Contributions to the Study of Some of the Afferent and Efferent Tracts in the Spinal Cord. Brain, Lond., vol. xxi (1898), pp. 145-179.

† Hoche, A. Ueber secundäre Degeneration, speciell des Gowers'schen Bündels, nebst Bemerkungen ueber das Verhalten der Reflexe bei Compression des Rückenmarkes. Arch. f. Psychiat. u. Nervenkr., Berl., Bd. xxviii (1896), S. 510-543.

‡ v. Sölder, F. Degenerirte Bahnen im Hirnstamme bei Läsion des unteren Cervicalmarks. Neurol. Centralbl., Leipz., Bd. xvi (1897), S. 308-312.

\* Worotynski, B. Zur Lehre von den secundären Degenerationen im Rückenmarke. Neurol. Centralbl., Leipz., Bd. xvi (1897). S. 1094-1097.



might very well be called the *systema [neuronicum] spino-cerebellare ventro-laterale conjunctivale*. The researches of Edinger,\* Mott,† and others make it appear that several other neurone systems exist, whose axones take a similar course for at least a long distance in the spinal cord and rhombencephalon.

Edinger, in 1889, from studies of myelinization, came to the conclusion that many of the medullated axones ascending in the fasciculi proprii of the ventral and lateral funiculi arise from cells of the dorsal column of gray matter in the opposite side of the spinal cord. The crossing of the axones, he believed, occurs partly behind the *canalis centralis*, partly in front of it, by way of both the *commissura grisea* and the *commissura alba*. He separated this crossed ascending ventro-lateral system from Gowers's tract.

The most important observations in this connection are those of Mott, who, experimenting on monkeys, studied the resulting degenerations by the method of Marchi. Mott has clearly distinguished, in addition to the (largely crossed) conjunctival spino-cerebellar system, (1) a ventro-lateral superior spino-quadrigeminal system and (2) a ventro-lateral spino-thalamic system.

The ventro-lateral spino-quadrigeminal system (or, as it might very well be designated, the *systema [neuronicum] spino-quadrigeminum ventro-laterale superius*) sends its axones, the exact origin of which is still doubtful, upward in the *substantia alba* of the spinal cord, where they are situated at first in the internal (central) of the three zones of white matter at the region of exit of the ventral roots. Passing up through the ventro-lateral region of the cord, they ascend into the medulla oblongata, where they are found among the other fibres which represent the ventro-lateral portion of the continuation (in the medulla) of the ventro-lateral funiculi of the cord. The fibres

---

\* Edinger, L. Ueber die Fortsetzung der hinteren Rückenmarkswurzeln zum Gehirn. *Anat. Anz.*, Jena, Bd. iv (1889), S. 121-128.

† Mott, F. W. Results of Hemisection of the Spinal Cord in Monkeys. *Phil. Tr.*, Lond. (1891): also, Ascending Degeneration, resulting from Lesions of the Spinal Cord in Monkeys. *Brain*, Lond., vol. xv (1892), pp. 215-229; also, Experimental Inquiry upon the Afferent Tracts of the Central Nervous System of the Monkey. *Ibid.*, vol. xviii (1895), pp. 1-20; also, Die zuführenden Kleinhirnbahnen des Rückenmarks bei dem Affen. *Monatsschr. f. Psychiat. u. Neurol.*, Berl., Bd. i (1897), S. 104-121.

which at first lie lateral from the nucleus olivaris inferior come higher up to be situated ventro-laterally from the nucleus olivaris superior. While the ventro-lateral conjunctival spino-cerebellar system turns dorsalward, at a level corresponding to the nervus trigeminus, just behind the colliculus inferior, so as to pass lateral from the tractus spinalis nervi trigemini into the velum, the spino-quadrigeminal system of Mott continues a course ventro-medial from the tractus spinalis nervi trigemini and from the nuclei terminales nervi trigemini running mixed with the bundle of fibres which descends from the nucleus ruber of the opposite side to the lateral funiculi. Accordingly, the spino-quadrigeminal bundle comes to lie dorsal from the level of the nucleus olivaris superior and between the fibres of the lemniscus lateralis which here pass dorsalward. The fibres of the spino-quadrigeminal system lie in the medial portion of the lemniscus lateralis medial from the nucleus lemnisci lateralis. At the level of the colliculus superior the spino-quadrigeminal fibres become separated from the descending axones from the opposite red nucleus, since the bundle of the latter, ventro-lateral from the nucleus ruber, has reached this lateral position by passing from the nucleus ruber of the opposite side through the decussatio tegmenti ventralis in the raphe lateralward. The spino-quadrigeminal system, on the other hand, turns medialward into the substantia grisea of the colliculus superior in order to terminate by end-ramifications in among the perikaryons and dendrites of the neurone systems situated there, mixing with similar end-ramifications from the tractus opticus and from the auditory axones of the lateral lemniscus system.

Mott's spino-thalamic fibre system (or, as it might be called, *systema [neuronicum] spino-thalamicum ventro-laterale*) also takes its origin in cells in the gray matter of the spinal cord, but just in what regions and whether on the same or on the opposite side, or both, does not seem clear. The medullated axones ascend through the ventro-lateral region of the cord mixed with those of the spino-quadrigeminal system and to a certain extent with those of the conjunctival spino-cerebellar system. In the medulla oblongata the course of the path is the same as has been described above for the spino-quadrigeminal system, and the fibres of Mott's spino-thalamic system appear to be mixed, not only with those of his spino-quadrigeminal

system, but, like the latter, also with the descending fibres from the midbrain to the spinal cord. At the level of the colliculus superior, as has been mentioned above, the descending medullated axones from the red nucleus to the cord become separated from the common bundle (in the medial part of the lateral lemniscus), as do also the ascending spino-quadrigeminal fibres. The medullated axones of Mott's ascending spino-thalamic system, however, are continued with that portion of the lemniscus lateralis which goes past the colliculus inferior without stopping in it. Further on they become more or less mixed with the medullated axones of the lemniscus medialis which are scattered more or less diffusely in that region of the tegmentum which lies medial from the corpus geniculatum mediale. It seems likely that the axones of the spino-thalamic system enter the hilus thalami and terminate in the ventro-lateral region of the thalamus along with the principal axones of the lemniscus medialis (those derived from the cell bodies in the nucleus funiculi gracilis and the nucleus funiculi cuneati) and the axones from the cerebellum (by way of the brachium conjunctivum and red nucleus, to be described further on).

For further notes on ascending (central-axone) spino-thalamic neurone systems, the reader is referred to the publications of Mott,\* Patrick,† von Sölder,‡ and Tschermak.\*

Before leaving the subject of the fasciculus ventro-lateralis superficialis (Gowersi) reference must be made (1) to the recent publications of Rossolimo and (2) to the findings of Tschermak concerning an ascending ventro-lateral restiform cerebellar system.

Rossolimo,|| in an article accompanied by seventeen illustrations, describes his findings concerning secondary degenerations in the region of Gowers' tract. He employed the method of Busch,<sup>Δ</sup> a modification of the method of Marchi, which possesses, he thinks, certain advantages over the latter procedure. The patient, a girl of twelve years, had suffered from retroperi-

\* *Op. cit.* † *Op. cit.* ‡ v. Sölder, F., *op. cit.*

\* Tschermak, A. Ueber den centralen Verlauf der aufsteigenden Hinterstrangbahnen und deren Beziehungen zu den Bahnen im Vorderseitenstrang. Arch. f. Anat. u. Physiol., Anat. Abth., Leipz. (1898), S. 291-400.

|| Rossolimo, G. J. Ueber den centralen Verlauf des Gowers'schen Bündels. Neurol. Centralbl., Leipz., Bd. xvii (1898), S. 935-940.

<sup>Δ</sup> Busch, C. Neurol. Centralbl., Leipz., Bd. xvii (1898), S. 476.

toneal sarcoma, with multiple metastases, the spinal cord being involved chiefly in the lower thoracic and lumbar region. In the ventro-lateral region he found a very definite degeneration, which on the whole corresponded to the position of Gowers' tract in the spinal cord as well as in the medulla and pons. A few of the degenerated fibres left the bundle to enter the cerebellum by way of the corpus restiforme. No fibres, according to Rossolimo, passed by way of the brachium conjunctivum or velum medullare anterius into the cerebellum. On the other hand, the fibres undergo a partial decussation in the velum and then run to three different regions—(1) into the colliculus inferior, (2) into the substantia nigra Soemmeringii, and (3) into the globus pallidus of the nucleus lentiformis. Rossolimo concludes that his case is a sharp contradiction of the series of results obtained by Loewenthal, Anerbach, Mott, Hoche, and others concerning the termination of Gowers's tract in the cerebellum by way of the brachium conjunctivum and velum. This I can not agree with. On the contrary, Rossolimo's studies are to be looked upon not as contradicting previous knowledge, but as extending it in a most desirable way. Rossolimo appears not to have recognized the fact that Gowers's tract can no longer be considered a morphological entity. It is much rather a complex of fibre systems by no means homologous with one another. We have seen above that it contains (1) the medullated axones of the systema neuronium spino-cerebellare ventro-laterale conjunctivale, (2) the medullated axones of the systema neuronium spino-quadrigenum superius, and (3) the medullated axones of the systema neuronium spino-thalamicum. We shall see in a moment from Tschermak's studies that Gowers' tract also contains (4) a systema neuronium spino-cerebellare ventro-laterale restiformale. It appears to me that the correct interpretation to put upon Rossolimo's studies is the following: From the lower portion of the spinal cord there ascend medullated fibres in the course of Gowers' tract mixed with the fibres of the neurone systems above mentioned. The termination of these fibres is partly in the cerebellum (corresponding to Tschermak's ventro-lateral restiformal spino-cerebellar system), but chiefly in regions hitherto not known as receiving fibres of Gowers' tract—viz., the colliculus inferior of the corpora quadrigemina, the substantia nigra, and the nucleus lentiformis. If Rossolimo's observations and the interpretation



here suggested be correct, we shall have to push the analysis of the complex of fibre systems represented by Gowers' tract still farther than that given above, and add (5) a systema neuronium spino-quadrigenum inferius, (6) a systema neuronium spino-pedunculare (ad substantiam nigram), and (7) a systema neuronium spino-lentiformale.

Tschermak\* has described at some length a ventro-lateral spino-cerebellar restiformal neurone system.† After section of the ventro-lateral funiculi at the level of the nuclei of the dorsal funiculi, he found by Marchi's method degenerated fibres passing dorsalward, in part at least, from the region now usually designated as that of Gowers' tract in the medulla. These fibres consist of two groups: (1) fibres at first lying in the fissural part of the remains of the ventral funiculus, and farther on coming to pass lateralward dorsal from the remains of the ventral horns, and still higher dorsal from the nucleus olivaris inferior, and (2) fibres which join the former—viz., transverse fibres situated at first on the medial side of the nucleus funiculi lateralis as well as latero-dorsal from the nucleus olivaris inferior. All these fibres (*Fibræ transversales dorso-olivares et dorso-nucleares*) become aggregated into a thick transverse bundle dorsal from the nucleus funiculi lateralis, in which probably terminate numerous branches of ascending fibres from the spinal cord; the bundle arrives in the white matter at the ventral angle of the tractus spinalis nervi trigemini. The fibres under consideration next pass, looplike, dorsalward and arrive, by way of the medial portion of the tangential fibre-covering of the tractus spinalis nervi trigemini, into the ventral part of the corpus restiforme. Tschermak thinks that the fibres pass by way of the lateral bundle, of the two bundles into which the corpus restiforme divides, into the vermis superior, probably to both sides of the middle line. It is, as Tschermak remarks, rather interesting to note that whereas Patrick describes a few fibres of the direct dorso-lateral cerebellar tract which, instead of entering the cerebellum by way of the corpus restiforme, pass on to enter that organ higher up by way of the ventro-lateral conjunctival spino-cerebellar system, these findings make it appear that an exact counterpart exists in these fibres of the ventro-lateral

\* *Op. cit.*

† *His aufsteigendes anterolaterales restiformales Cerebellarsystem.*

spino-cerebellar tract which, lower down than their fellows, pass into the cerebellum, taking the short cut by way of the corpus restiforme. I take it that the few fibres observed by Rossolimo, above referred to, passing from Gowers' tract into the corpus restiforme, belong to the same neurone system as that of Tschermak here mentioned. It seems likely, too, that Tschermak's system is identical with the third of the three ascending spino-cerebellar systems of Auerbach above referred to.


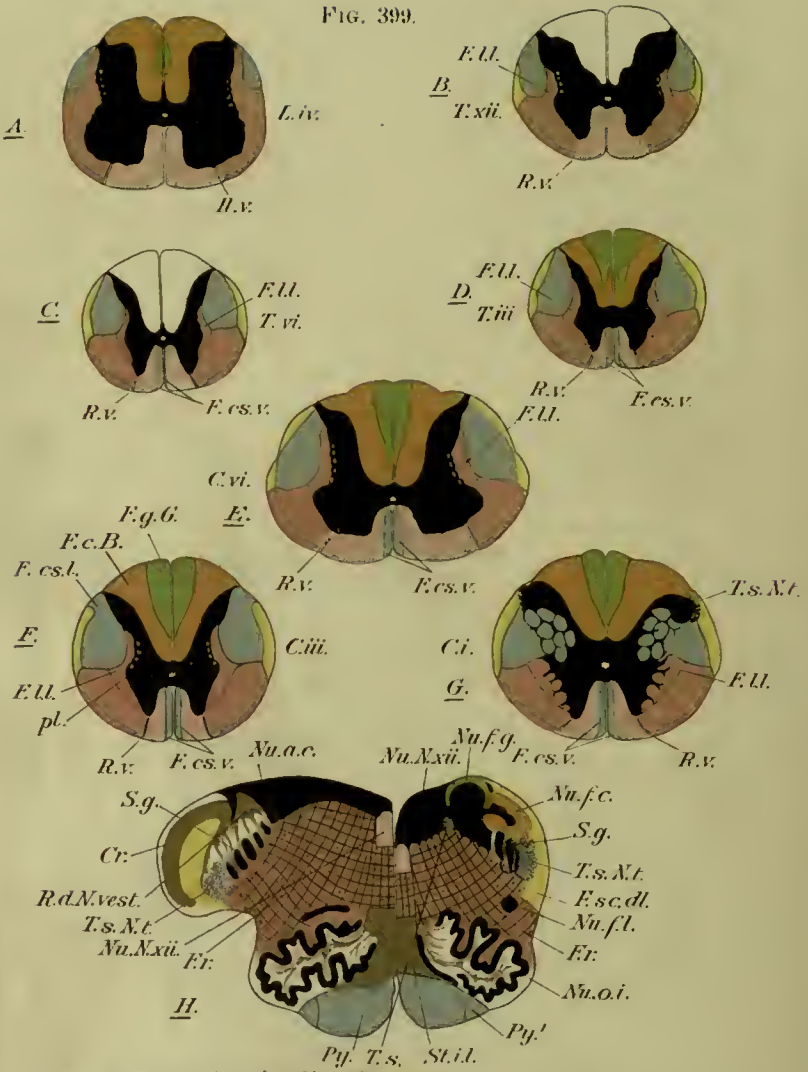


FIG. 399.



- |  |   |  |   |
|--|---|--|---|
|  | Fasciculus lateralis proprius and its continuation in the medulla oblongata (fibres connecting reflex fields of the medulla oblongata and the lateral funiculi of the spinal cord). |  | Fasciculus gracilis (Goll).   |
|  | Fasciculi cerebro-spinales (pyramidal tracts from pallium to spinal cord).  |  | Fasciculus gracilis (Burdach); in the lumbar cord, Flechsig's oval bundle.  |
|  | Fasciculus spino-cerebellaris dorso-lateralis (direct dorso-lateral cerebellar tract of Flechsig).  |  | Fibres olivo-cerebellares and other fibres in the corpus restiforme; radix descendens N. vestibuli; atrium interolivare lemnisci. |
|  | Fasciculus ventralis proprius (continuous in the medulla oblongata with the fasciculus longitudinalis medialis).  |  | Substantia grisea; the black stipple represents the tractus spinalis N. trigemini.  |



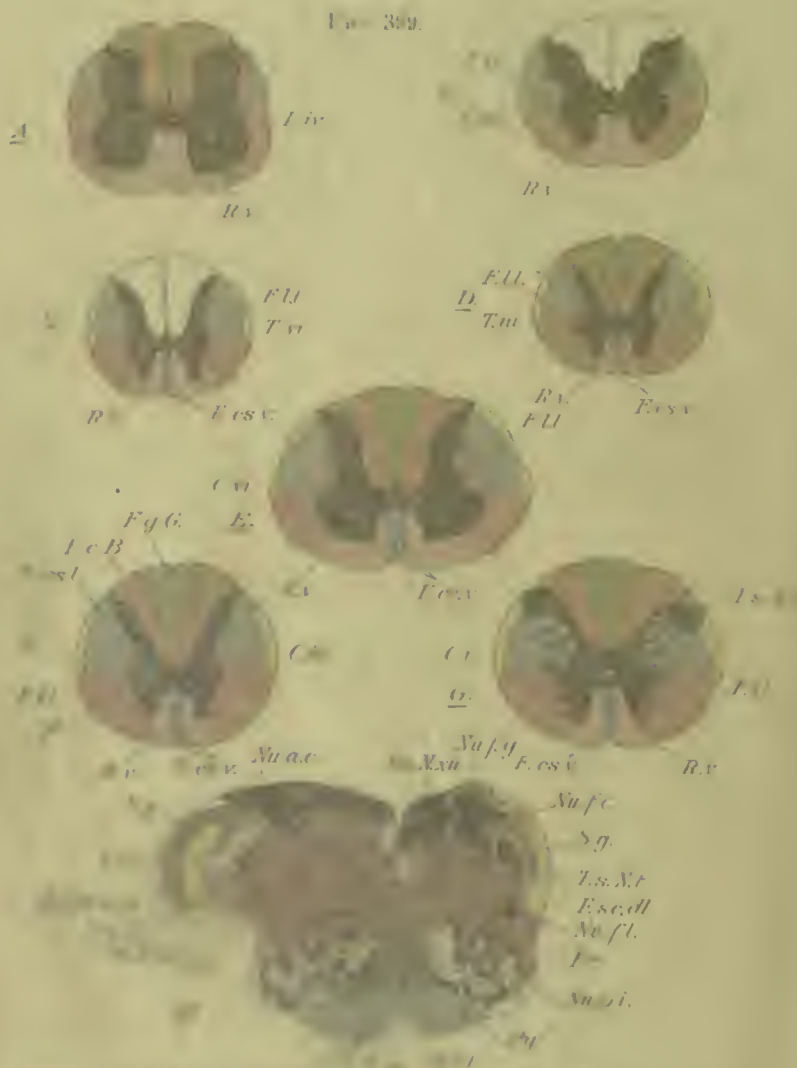## CHAPTER III

### THE CENTRAL-AXONE (CENTROGENIC) SYSTEM OF THE FASCICULI PROPRII OR OLIGOGENIC SYSTEM OF THE SPINAL CORD

The second longer neurone system—the second longest in the spinal cord—is the central-axone (centrogenic) system of the fasciculi proprii or oligogenic system of the spinal cord. It is a system of neurones which are situated in the gray matter of the spinal cord and whose axons descend in the white matter of the spinal cord. The system is composed of two parts—the ventral and dorsal parts. The ventral part is composed of the ventral horns of the spinal cord and the dorsal part is composed of the dorsal horns of the spinal cord. The system is composed of two parts—the ventral and dorsal parts. The ventral part is composed of the ventral horns of the spinal cord and the dorsal part is composed of the dorsal horns of the spinal cord. The system is composed of two parts—the ventral and dorsal parts. The ventral part is composed of the ventral horns of the spinal cord and the dorsal part is composed of the dorsal horns of the spinal cord.

(1st 7) The central-axone (centrogenic) system of the fasciculi proprii or oligogenic system of the spinal cord is a system of neurones which are situated in the gray matter of the spinal cord and whose axons descend in the white matter of the spinal cord. The system is composed of two parts—the ventral and dorsal parts. The ventral part is composed of the ventral horns of the spinal cord and the dorsal part is composed of the dorsal horns of the spinal cord. The system is composed of two parts—the ventral and dorsal parts. The ventral part is composed of the ventral horns of the spinal cord and the dorsal part is composed of the dorsal horns of the spinal cord. The system is composed of two parts—the ventral and dorsal parts. The ventral part is composed of the ventral horns of the spinal cord and the dorsal part is composed of the dorsal horns of the spinal cord.

The central-axone (centrogenic) system of the fasciculi proprii or oligogenic system of the spinal cord is a system of neurones which are situated in the gray matter of the spinal cord and whose axons descend in the white matter of the spinal cord. The system is composed of two parts—the ventral and dorsal parts. The ventral part is composed of the ventral horns of the spinal cord and the dorsal part is composed of the dorsal horns of the spinal cord. The system is composed of two parts—the ventral and dorsal parts. The ventral part is composed of the ventral horns of the spinal cord and the dorsal part is composed of the dorsal horns of the spinal cord. The system is composed of two parts—the ventral and dorsal parts. The ventral part is composed of the ventral horns of the spinal cord and the dorsal part is composed of the dorsal horns of the spinal cord.



1. *Butor* 2. *Butor* 3. *Butor* 4. *Butor* 5. *Butor* 6. *Butor* 7. *Butor* 8. *Butor* 9. *Butor* 10. *Butor* 11. *Butor* 12. *Butor*

1. *Butor* 2. *Butor* 3. *Butor* 4. *Butor* 5. *Butor* 6. *Butor* 7. *Butor* 8. *Butor* 9. *Butor* 10. *Butor* 11. *Butor* 12. *Butor*

1. *Butor* 2. *Butor* 3. *Butor* 4. *Butor* 5. *Butor* 6. *Butor* 7. *Butor* 8. *Butor* 9. *Butor* 10. *Butor* 11. *Butor* 12. *Butor*

1. *Butor* 2. *Butor* 3. *Butor* 4. *Butor* 5. *Butor* 6. *Butor* 7. *Butor* 8. *Butor* 9. *Butor* 10. *Butor* 11. *Butor* 12. *Butor*

## CHAPTER XLII.

### ON CENTRAL-AXONE (CENTRIPETAL) NEURONE SYSTEMS IN THE FASCICULI PROPRII OR GROUND-BUNDLES OF THE SPINAL CORD.

Shorter and longer neurone systems—Intersegmental or internuncial association axones—Perikaryons and dendrites—Tautomerie, heteromerie, and heeteromerie neurones—Axones and collaterals—The lateral limiting layer—Its ventral and dorsal parts—Bundles in the rhombencephalon continuous with the fasciculi proprii of the spinal cord—The ascending spino-cerebral system in the fasciculus longitudinalis medialis—Relative numbers of ascending and descending axones in these bundles.

(*ad d*) The central sensory conduction paths corresponding to neurones the cell bodies of which are situated in the gray matter of the cord, the axones helping to make up the fasciculi proprii of the ventral, lateral, and dorsal funiculi of the white matter of the cord, have been the object of much study, but as yet only partial and unsatisfactory information concerning them is available.\* The fasciculi proprii of the white matter contain fibres of shorter and longer neurone systems, both ascending and descending, crossed and uncrossed. The shorter fibres appear to run up and down close to the gray substance; the longer fibres tend to occupy areas nearer the periphery of the cord. The neu-

---

\* The fasciculus ventralis proprius corresponds to the *Vorderstranggrundbündel* of the Germans; their *Seitenstrangreste* includes the fasciculus lateralis proprius and Gowers' tract. Thus, Flechsig (*Leitungsbahnen*, S. 299 ff.) describes the *Seitenstrangreste* as being made up of two territories: (1) the *vordere gemischte Seitenstrangzone*, and (2) the *seitliche Grenzschicht der grauen Substanz*. As von Beehterew showed, Gowers' bundle corresponds to a portion of Flechsig's *vordere gemischte Seitenstrangzone*. The remainder of the latter, together with the lateral limiting layer or fasciculus lateralis limitans (*seitliche Grenzschicht der grauen Substanz*), make up the *Seitenstranggrundbündel* or the fasciculus lateralis proprius (Fig. 399). The Germans often speak of the fasciculus ventralis et lateralis proprius together as the *Vorderseitenstrangreste*.

rones concerned serve to connect segments of various levels with one another, and their axones are accordingly sometimes referred to as "intersegmental" or "internuncial" axones or as those of "longitudinal association fibres." The shortest ones connect segments immediately adjacent to one another; the longer ones may connect widely separated levels of the spinal cord and rhombencephalon, or may even bring the spinal cord into relation with the mesencephalon and diencephalon. There is much reason to believe that many of these neurones, especially those with ascending axones the myelin sheaths of which accordingly undergo secondary ascending degeneration after lesion, have to do with the carrying of centripetal impulses toward the higher centres, and they are accordingly appropriately considered here.

The perikaryons and dendrites of these neurones have been studied especially by Ramón y Cajal, von Kölliker, van Gehuchten, and von Lenhossék. Those which send axones to the fasciculus ventralis proprius are situated (1) in the most medial part of the ventral horn (*Kommissurengruppe* of von Lenhossék), and (2) in the ventral and middle parts of the gray substance. Those which send axones to the fasciculus lateralis proprius are situated in the middle regions of the gray substance and in the dorsal horns as far back as the substantia gelatinosa of Rolando. Those which send axones to the fasciculus dorsalis proprius (endogenous fibres of the dorsal funiculi) are but few in number, and appear to be situated in the gray matter of the dorsal horn (Fig. 400). The axones of these various cells pass partly to the white matter of the same side (those of tautomerie neurones, van Gehuchten), partly to the white matter of the opposite side (those of heteromerie neurones), and occasionally, after division, to the white matter of both sides (those of hecateromerie neurones). The calibre of the axone sometimes increases at a distance from the cell body. In the white matter an axone often divides into an ascending and a descending limb. Numerous collaterals are given off into the gray substance, so that a given neurone may affect not only the gray matter of the segment in which its axone terminates, but also, by means of collaterals, the gray matter of intervening segments. The arrangement of the whole mechanism here under consideration seems to be that especially adapted for co-ordinating the activities of the gray matter of different levels. In so far as it is concerned in mediating the conduction



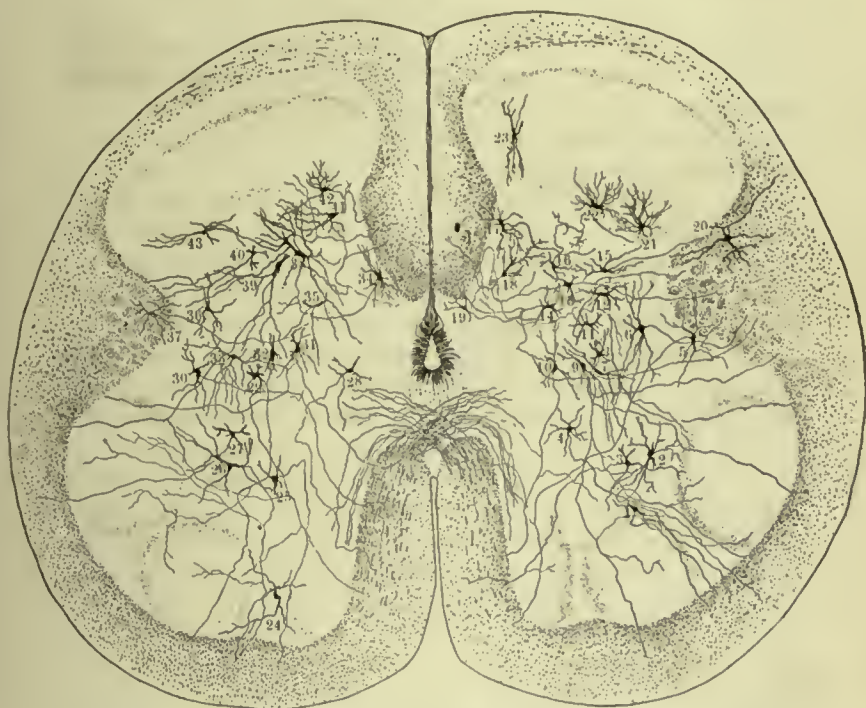

FIG. 400.—Tautomeric, heteromeric, and hecateromeric neurones as revealed by Golgi's method in the pars lumbalis of the human spinal cord. Combined from a number of preparations taken from a human embryo 30 cm. long. The lower motor neurones, the commissural neurones, the perikaryons of which are situated in the ventromedial part of the ventral horn, and the dendraxones of the substantia grisea have not been represented. (After M. von Lenhossék, *Der feinere Bau des Nervensystems*, etc., II. Aufl., Berl., 1893, Taf. iv.) 1, 2, 3, 4, tautomeric neurones, the perikaryons of which are situated in the middle zone of the substantia grisea, their axones passing to the ventral or lateral funiculus, where they assume a longitudinal direction; 5, neurone, with perikaryon in lateral region of gray matter and axone passing ventralward to bifurcate, the limbs of bifurcation entering, one of them the ventral funiculus, the other the ventral commissure; 6, neurone situated in lateral part of gray matter sending axone to lateral funiculus; 7, 8, 9, 10, groups of nerve cells in middle region sending axones to ventral or lateral funiculus; 11, 12, 13, 14, 15, 17, perikaryons in dorsal horn sending axones to lateral funiculus; 16, dendraxone; 18, neurone transitional in type between an inaxone and a dendraxone, the axone *a* bifurcating and branching manifoldly in the gray matter, but sending a branch to the substantia alba; 19, perikaryon in dorsal commissure; 20, perikaryon in substantia alba; 21, 22, 23, cells just ventral to substantia gelatinosa; 24, 25, 26, neurones sending axones to ventral funiculus; 27, neurones sending axone to lateral funiculus; 28, 29, 30, 31, neurones in middle region sending axones to ventral funiculus; 32, 33, 34, 35, 36, 39, 40, neurones in dorsal horn whose axones go to the lateral funiculus; 37, perikaryon in substantia alba (formatio reticularis); 38, 40, 41, 42, 43, nerve cells in dorsal part of dorsal horn, some of which send axones to the dorsal funiculi.

of impulses to the higher centres concerned in sensation, the mechanism must, for the most part, be looked upon as a conduction path of many relays, that is, of many superimposed neurones, the impulses which travel along it passing alternately from gray matter to white matter and from white matter to gray matter over and over again as the neural axis is ascended.

The so-called lateral limiting layer, or fasciculus lateralis limitans,\* was first described by Flechsig on the ground of studies of myelinization in 1876. By it he meant the portion of the lateral funiculus, close to the substantia grisea (F. l. l. in Fig. 399). Flechsig's ideas of the origin of the fibres of this lateral limiting layer were vague, although he felt sure that it represented a complex of fibres of different sorts. The area has been further differentiated by von Bechterew and by Bruce.

Von Bechterew † states that the fibres of the lateral limiting layer do not have their origin in fibres of the dorsal roots, since this layer does not degenerate when the dorsal roots are injured. Nor do the fibres of the layer arise from the cells of the nucleus dorsalis, for though the axones from the nucleus dorsalis run through the fasciculus lateralis limitans on their way to the dorso-lateral periphery of the cord, they do not turn to run longitudinally near the gray substance.

From the study of developing spinal cords von Bechterew has been able to divide the lateral limiting layer into (1) a more ventral portion which is medullated early, and (2) a more dorsal portion which is medullated later. The latter he has designated "the medial bundle of the lateral funiculus." ‡ This bundle lies just lateral from the substantia grisea, dorsalward from the columna grisea lateralis, and thus occupies a part of the space between the fasciculus cerebro-spinalis lateralis and the substantia grisea. Its broader ventral extremity (as seen in cross section) lies in the angle between the ventral and dorsal horns. The topographical relations, however, vary somewhat at different levels. Von Bechterew believes that his "medial bundle" is

---

\* *Die seitliche Grenzschicht der grauen Substanz* of Flechsig.

† von Bechterew, W. *Die Leitungsbahnen im Gehirn und Rückenmark*, Leipz. (1894).—*Ueber das besondere, mediale Bündel der Seitenstränge*. Neurol. Centralbl., Leipz., Bd. xvi (1897), S. 680-682.

‡ *Mediales Seitenstrangbündel* of von Bechterew.

composed of short medullated axones, which arise from cells in the dorsal horns. The more ventral part of the lateral limiting layer, von Beehterew believes, is made up of the medullated axones of cells situated in the ventral horns.

An interesting and important extension of our knowledge in this connection has been furnished by Bruce, of Edinburgh.\* This observer, studying a case of amyotrophic lateral sclerosis, found partial degeneration of the ventral part of the lateral limiting layer along with degeneration of the ventral horns and of the fasciculus cerebro-spinalis lateralis. The dorsal part of the lateral limiting layer (von Beehterew's "medial bundle") was intact, as was also the gray matter of the dorsal horn. It seems likely, therefore, that the fibres of the ventral part of the lateral limiting layer have their origin in cells of the ventral horn. In speaking or writing of the lateral limiting layer, or fasciculus lateralis limitans, care should therefore be taken to mention whether one is referring to its *pars dorsalis*, its *pars ventralis*, or both.

The fasciculi proprii are largest in volume in the intumescentiae. In the thoracic region of the cord they are relatively small.

The continuation of these paths upward in the medulla and pons has been carefully studied by Flechsig,† von Beehterew,‡ Edinger, and Held.\* According to von Beehterew, the relations can be easily made out in human foetuses 25 to 27 cm. long, when but few tracts are medullated in the rhombencephalon. Indeed the fasciculi proprii of the cord are among the earliest parts of the substantia alba to become medullated. The results at which he has arrived may be briefly summed up as follows: The fibres of the ventral and lateral fasciculi go over into the formatio reticularis. The

---

\* Bruce, A. D'un faisceau spécial de la zone latérale de la moelle épinière. . Rev. neurol., Par., t. iv (1896), No. 23, pp. 698-700; also, On a Special Tract in the Lateral Limiting Layer of the Spinal Cord. Scot. M. and S. J., Edinb., vol. i (1897), No. 1.

† *Op. cit.*

‡ von Beehterew, W. Ueber die Längsfaserzüge der Formatio reticularis medullæ oblongatæ et pontis. Neurol. Centralbl., Bd. iv (1885), S. 337-346.

\* Held, H. Die Beziehungen des Vorderseitenstranges zu Mittel- und Hinterhirn. Abhandl. der math. phys. Cl. der K. Sachs. Gesellsch. d. Wissensch., Bd. xviii, No. 6, Leipzig (1892).



fibres of the fasciculus ventralis proprius, together with a large tract of those of the fasciculus lateralis proprius, go over,

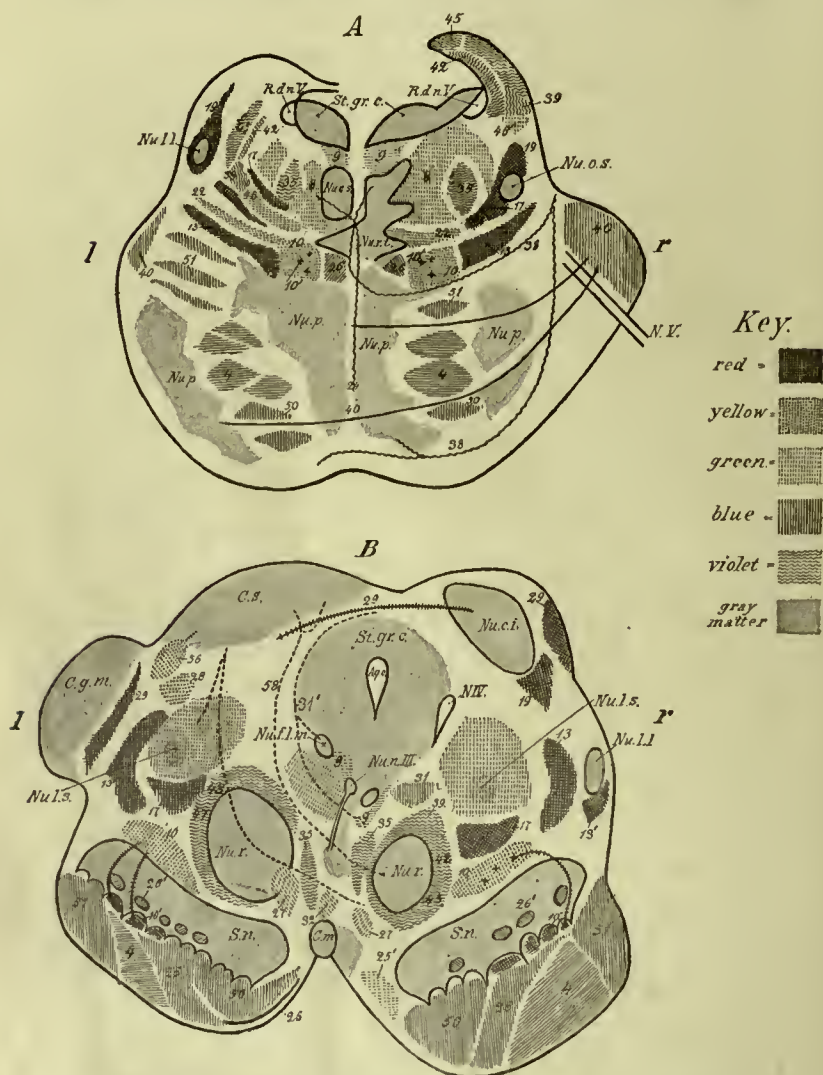


FIG. 401.—A, transverse section through the posterior half of the pons. The left half of the illustration corresponds to the anterior, the right half to the posterior portion of the pons. (After W. von Bechterew, 1894, somewhat modified.) Nu.c.s., nucleus centralis superior; Nu.l.l., nucleus lemnisci lateralis; Nu.o.s., nucleus olivaris superior; Nu.p., nuclei pontis; Nu.r.t., nucleus reticularis tegmenti; N.V., radix N. trigemini; R.d.n.V., radix descendens



through a marked curve dorsalward corresponding to the course of the central canal, into the so-called "medial field" and into the adjacent regions of the "lateral field" of the formatio reticularis (Fig. 401). The fibres of the most dorsal portion of the fasciculus lateralis proprius become separated from the other fibres and run as a distinct bundle on the lateral periphery of the medulla. They can be followed by the embryological method only as far as the superior olivary complex,

(mesencephalica) nervi trigemini; *St.gr.c.*, stratum griseum centrale. *Red*—13, fibres of the lemniscus medialis pertaining to the nucleus funiculi cuneati; 10, scattered bundles in the lemniscus medialis; 17, region of scattered fibres which develop late in the lateral field of the formatio reticularis; 19, lemniscus lateralis. *Yellow*—10, fibres of lemniscus medialis originating in nucleus funiculi gracilis; 22, fibres from the region of the colliculus inferior to the nucleus reticularis tegmenti and to the pons. *Violet*—35, fibres of fasciculus centralis tegmenti (*centrale Haubenbahn*); 24, fibres passing by the raphe from the nuclei pontis to the formatio reticularis grisea; 38, fibres of the spinal bundle (von Bechterew) of the brachium pontis; 45, 39, 42, different bundles in the brachium conjunctivum. *Blue*—4, fasciculi longitudinales (pyramidales); 26, fibres of medial accessory bundle in lemniscus medialis (to motor nuclei of cerebral nerves); 46, fibres of cerebral bundle of brachium pontis; 50, frontal cerebrocorticopontal path; 51, temporo-occipital cerebrocorticopontal path. *Green*—9, fasciculus longitudinalis medialis; 8, fibres which represent the pontal continuation of the fasciculus lateralis proprius of the spinal cord; 46, commissural bundle lying ventralward from the brachium conjunctivum.

B, transverse section through the brain stem; level of pedunculi cerebri. The right half illustrates the level of the colliculus inferior, the left half that of the colliculus superior. (After W. von Bechterew, 1894, somewhat modified.) *Aq.c.*, aqueductus cerebri; *C.g.m.*, corpus geniculatum mediale; *C.m.*, corpus mammillare; *C.s.*, colliculus superior; *N.IV*, radix N. trochlearis; *Nu.c.i.*, nucleus colliculi inferioris; *Nu.f.l.m.*, nucleus fasciculi longitudinalis medialis or nucleus commissure posterioris (*oberer Oculomotoriuskern* of Darkschewitsch); *Nu.l.l.*, von Bechterew's *Corpus parabigemini*; *Nu.l.s.*, nucleus lateralis superior of Flechsig (*nucleus innominatus* of von Bechterew); *Nu.n.III*, nucleus nervi oculomotorii; *Nu.r.*, nucleus ruber; *S.n.*, substantia nigra; *St.gr.c.*, stratum griseum centrale. *Red*—19, fibres of lemniscus lateralis which enter colliculus inferior; 20, fibres of brachium quadrigeminum inferius from the colliculus inferior of the same and of the opposite side; 13, fibres of the lemniscus medialis originating in the nucleus funiculi cuneati; 13', fibres of the lemniscus medialis going to the corpora quadrigemina; 10', scattered bundles of the lemniscus which go over into the basis pedunculi; 17, region of the scattered fibres (late to develop) of the formatio reticularis. *Yellow*—10, fibres of lemniscus medialis from the nucleus funiculi gracilis; 28, fibres from the nucleus colliculi inferioris to the thalamus (according to von Bechterew); 56, fibres from the colliculus superior to the cerebral cortex. *Violet*—39, 42, 45, fibres of the brachium conjunctivum before their entrance into the red nucleus; 47, 48, fibres from the red nucleus to the nucleus lentiformis, the thalamus, and the cerebral cortex (these are the radiations of the red nucleus); 35, fibres of the fasciculus centralis tegmenti (*centrale Haubenbahn*). *Green*—9, fasciculus longitudinalis medialis; 31, fibres of the dorsal part of the commissura posterior; 31', fibres of the ventral part of the commissura posterior; 27, fasciculus retroflexus Meynerti; 32, fasciculus thalamomammillaris (Vicq d'Azyri); 25', fasciculus pedunculomammillaris pars basilaris (pedunculus corporis mammillaris); 58, fibres from the substantia grisea of the colliculus superior to the region of the nucleus ruber of the opposite side. *Blue*—4, fasciculi longitudinales (pyramidales); 50, fibres of frontal cerebrocorticopontal path (medial bundle in basis pedunculi); 51, fibres of occipito-temporal cerebrocorticopontal path (lateral bundle in basis pedunculi); 26, fibres of the accessory bundle of the lemniscus; 26', fibres connecting the substantia nigra with the cerebral hemispheres.



with a part of those from the fasciculus lateralis proprius, are seen in the form of a compact rectangular bundle, one on each side of the raphe. These bundles are directly continuous above with the fasciculus longitudinalis medialis (posterior longitudinal bundle of many authors) on each side. Between the compact bundle in the dorsal region and the stratum interolivare lemnisci are situated more loosely arranged strands of fibres, which, von Bechterew thinks, represent in the main the upward continuation of the more ventral fibres of the fasciculus lateralis proprius of the cord. Another portion of the fasciculus lateralis proprius is continued upward in the form of isolated bundles in a region lateral to that just described dor-

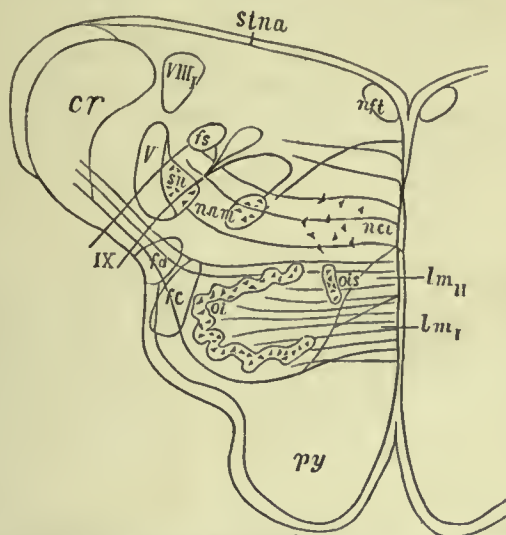


FIG. 403.—Schematic section through the upper part of the medulla oblongata at the level of the root of the N. glossopharyngeus. (After W. von Bechterew, *Die Leitungsbahnen im Gehirn und Rückenmark*, Deutsch von R. Weinberg, II. Aufl., Leipz., 1899, S. 156, Fig. 133.) *cr*, corpus restiforme; *VIII*, radix descendens N. vestibuli; *nft*, nucleus funiculi teretis; *IX*, roots of N. glossopharyngeus; *fs*, tractus solitarius; *fa*, continuation of fasciculus lateralis of the spinal cord (von Bechterew's "aberrant bundle"); *lm*, fibres of interolivary layer from contra-lateral nucleus funiculi cuneati; *lm<sub>II</sub>*, fibres of interolivary layer from contra-lateral nucleus funiculi cuneati; *nci*, nucleus centralis inferior; *na*, nucleus ambiguus; *ol*, nucleus olivaris inferior; *ois*, nucleus olivaris accessorius; *py*, pyramis; *stna*, stria medullares; *fc*, fasciculus centralis tegmenti (*centrale Haubenbahn*).

sal to the olive. These last fibres, together with the more ventral of the fibres of the fasciculus longitudinalis medialis, appear

to be connected intimately with the nucleus funiculi ventralis\* and the nucleus centralis inferior,† inasmuch as, when serial sections are studied, the fibres followed up from below suddenly vanish, at least in large part, at the level of these nuclei.

The fibres of the main compact bundle (continuous cerebralward with the fasciculus longitudinalis medialis) representing most of the fibres from the fasciculus ventralis proprius, and probably a few of the fibres of the fasciculus lateralis proprius, can be followed above the nucleus centralis inferior as far as the nucleus reticularis tegmenti‡ (Fig. 401, *vide supra*). Here a number of the fibres appear to undergo interruption, but many go farther. Of the latter, a few cross in the raphe to pass to the nucleus centralis superior\* and possibly to the ganglion interpedunculare Guddeni. Those most dorsally situated, however, are continuous with the cerebral extension of the fasciculus longitudinalis medialis (Fig. 406), which extends at any rate as far cerebralward as the nucleus fasciculi longitudinalis medialis *sen* nucleus commissuræ posterioris (*oberer Oculomotoriuskern* of Darkschewitsch).

\* Misslawsky's "respiratory nucleus," Obersteiner's *Kern des Vorderstranggrundbündels* or, as I call it, the nucleus funiculi ventralis (Fig. 402).

† Nucleus centralis of Roller, the mass of formatio reticularis grisea seen in sections taken through the middle of the olive, situated midway between the pyramids and the floor of the fourth ventricle and separating the fasciculus longitudinalis medialis from the stratum interolivare lemnisci (Fig. 403).

‡ A mass of formatio reticularis grisea near the raphe in the pars dorsalis pontis. It corresponds in part at least to Flechsig's nucleus centralis et lateralis medius.

\* By the nucleus centralis superior is meant the mass of gray matter seen on both sides of the raphe, ventral to the fasciculus longitudinalis medialis in sections taken at a level just below the colliculus inferior of the corpora quadrigemina. The nucleus centralis superior extends from the decussation of the brachium conjunctivum above through the region of the central tegmental nucleus, being situated mainly dorsal to the latter. The fibres of the formatio reticularis curve outward to give place to this nucleus. Von Bechterew calls it the *innerer oberer centraler Kern* (nucleus centralis superior medialis), to distinguish it from a small mass of large cells (nucleus centralis superior lateralis) at about the level of the nucleus lemnisci lateralis, situated in among the white fibres of the middle of the formatio reticularis on each side (Fig. 404). This latter nucleus lies in the angle made by the main decussatio brachii conjunctivi with the decussating fibres of the commissure between the nuclei Nn. vestibulorum superiores of the two sides (Fig. 405).



Of the recent studies dealing with the ascending fibres of spinal origin in the fasciculus longitudinalis medialis, those of Held,\* Hoche,† and Tschermak‡ may be mentioned.

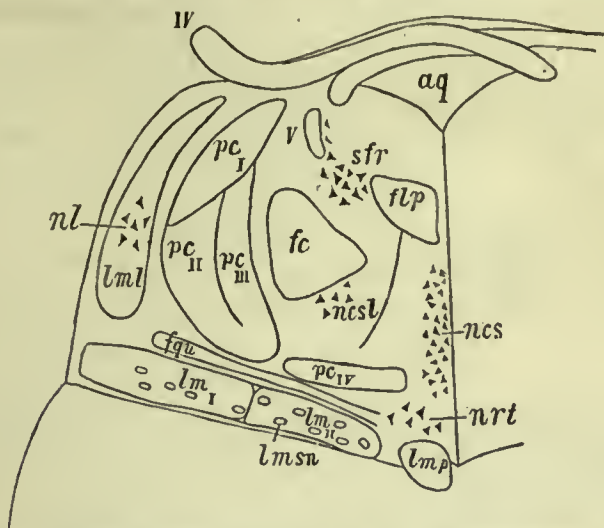


FIG. 404.—Schematic cross section through the pars dorsalis pontis at its junction with the isthmus rhombencephali. (After W. von Bechterew, *Die Leitungsbahnen im Gehirn und Rückenmark*, Deutsch von R. Weinberg, II. Aufl., Leipzig. (1899), S. 236, Fig. 198.) *aq*, aqueductus cerebri; *flp*, fasciculus longitudinalis medialis; *fc*, fasciculus centralis tegmenti (*centrale Haubenbahn*); *fqu*, fibres from the region of the colliculus inferior to the nucleus reticularis tegmenti; *IV*, N. trochlearis; *lmi*, fibres of the lemniscus medialis from the contra-lateral nucleus funiculi euneati; *lmsn*, fibres of the lemniscus medialis from the contra-lateral nucleus funiculi gracilis; *lmp*, von Bechterew's medial accessory lemniscus; *lmsn*, von Bechterew's scattered bundles of the lemniscus; *lml*, lemniscus lateralis; *ncs*, nucleus centralis superior, pars medialis; *ncl*, nucleus centralis superior, pars lateralis; *nrt*, nucleus reticularis tegmenti pontis; *pcI*, dorsal, *pcII*, middle, *pcIII*, medial, *pcIV*, ventral bundle of the brachium conjunctivum; *pcIV* represents the commissure between the nuclei superiores nervorum vestibulorum; *sfr*, substantia ferruginea. *V*, radix descendens (mesencephalica) nervi trigemini.

Held, with the myelinization method, was able to show the relation of the fibres, and especially of their collaterals, to the nuclei of the formatio reticularis grisea and to the nuclei of origin of the nerves governing the eye muscles. His researches

\* *Op. cit.*

† Hoche, A. Zur Pathologie der bulbärspinalen spastisch-atrophischen Lähmungen. *Neurol. Centralbl.*, Leipz., Bd. xvi (1897), S. 242-252.

‡ Tschermak, A. Ueber den centralen Verlauf der aufsteigenden Hinterstrangbahnen und deren Beziehungen zu den Bahnen im Vorderseitenstrang. *Arch. f. Anat. u. Physiol., Anat. Abth.*, Leipz. (1898), S. 291-400.

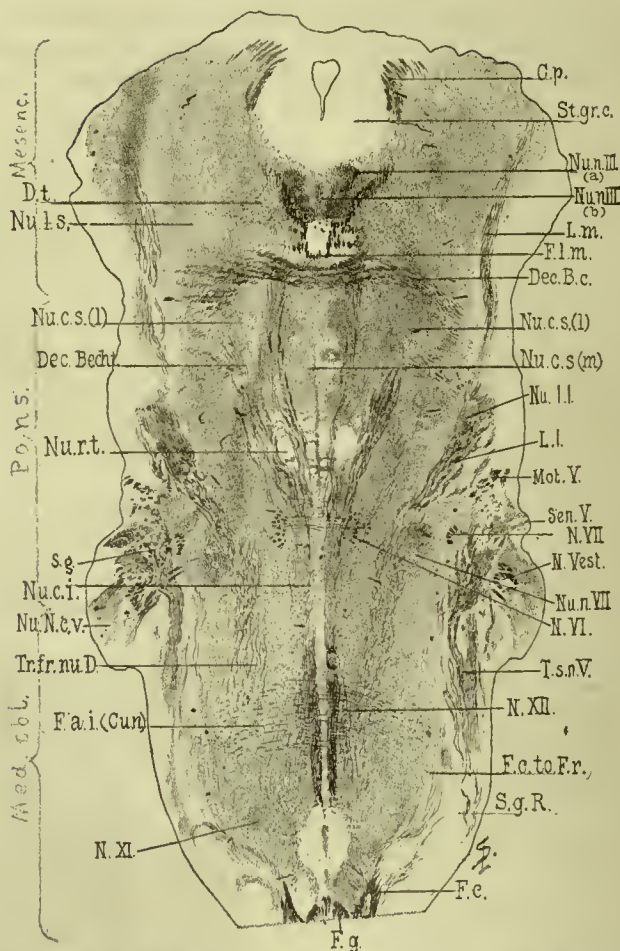


FIG. 405.—Horizontal section through the medulla, pons, and midbrain of a newborn babe. Weigert-Pal staining. Level of decussatio brachii conjunctivi and of nucleus reticularis tegmenti. (Series iii, section No. 108.) *Cp.*, commissura posterior cerebri; *Dec.B.c.*, decussatio brachii conjunctivi; *Dec.Bchr.*, commissure between Bechterew's nuclei; *Dt.*, fibres to decussatio tegmenti; *F.a.i.(Cun.)*, fibre arcuatae internae from the nucleus funiculi cuneati; *F.e.*, fasciculus euneatus; *F.c.to.Fr.*, bundle from fasciculus euneatus to formatio reticularis; *F.g.*, fasciculus gracilis; *Fl.m.*, fasciculus longitudinalis medialis; *L.m.*, lemniscus medialis; *L.l.*, lemniscus lateralis; *Mot.V.*, radix motorius N. trigemini; *N.VII.*, radix N. facialis, pars secunda; *N.vest.*, radix N. vestibuli; *N.VI.*, radix N. abducentis; *N.VII.*, radix N. hypoglossi; *N.XI.*, radix N. accessorii; *Nu.n.III.(a)*, nucleus N. oculomotorii, pars lateralis; *Nu.n.III.(b)*, nucleus N. oculomotorii, pars impar; *Nuc.s.(l)*, nucleus centralis superior, pars lateralis; *Nuc.s.(m)*, nucleus centralis superior, pars medialis; *Nu.l.l.*, nucleus lemnisci lateralis; *Nu.n.VII.*, nucleus N. facialis; *Nu.N.c.v.*, nucleus N. cochleae ventralis; *Nu.c.i.*, nucleus centralis inferior; *Nu.r.t.*, nucleus reticularis tegmenti; *Nu.l.s.*, nucleus lateralis superior; *St.gr.c.*, stratum griseum centrale; *Sen.V.*, sensory root of N. trigeminus; *S.g.*, substantia gelatinosa Rolandi; *Tr.fr.nu.D.*, tract from Deiters' nucleus to the spinal cord; *T.s.n.V.*, tractus spinalis N. trigemini. (Preparation by Dr. John Hewetson.)

deal more particularly, however, with the descending fibres in this region, and will be referred to more at length in Chapter LVIII.

Hoehe studied the degenerations in a case of progressive bulbar paralysis with Weigert's method and with the method of Marchi.

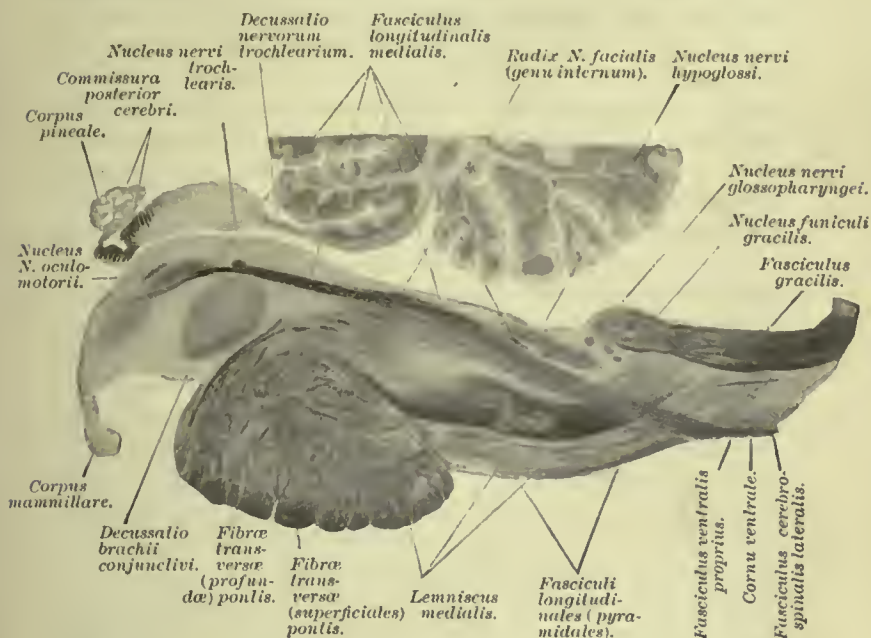


FIG. 406.—A sagittal section of the medulla oblongata, pons, and mesencephalon parallel and close to the middle line; child aged three months; method of Weigert. (After A. Bruce, *Illustrations of the Nerve Tracts in the Mid- and Hind Brain and the Cranial Nerves arising therefrom*, Edinb. and Lond., 1892, pl. xxvii, Fig. 1.) The fasciculus longitudinalis medialis and its relation to the fasciculus ventralis proprius of the spinal cord are particularly well shown.

Tschermak, after experiments upon cats and studies with Marchi's method, has given the latest description. According to him, the long neurone system from the spinal cord to the cerebrum by way of the fasciculus longitudinalis medialis\* has its origin in the ventral horn of the spinal cord. The perikaryons and dendrites are situated in the group of commissural

\* *Das aufsteigende (centralaxone) Spinocerebralsystem im dorsalen Längsbündel* of Tschermak.

cells in the ventral horn, the axones ascending in the ventral funiculus. In the medulla oblongata, at the level where the central canal of the spinal cord widens out to form the fourth ventricle, the ventral and lateral funiculi become separated into two groups of fibres, one medio-dorsally placed (continuous farther up with the fasciculus longitudinalis medialis), the other ventro-laterally placed. The ascending spino-cerebral system under consideration enters the first-named fibre complex.\* The ascending fibres give off many collaterals to the same side and to the opposite side. The collaterals to the same side pass lateralward to the nucleus nervi hypoglossi, the nucleus nervi abducentis, the nucleus nervi trochlearis, the nucleus nervi oculomotorii, the nucleus centralis et lateralis inferior, the nucleus centralis et lateralis medius, and the nucleus centralis et lateralis superior. The collaterals to the opposite side pass medialward across the raphe and end in the various nuclei of the formatio reticularis grisea.

The longest fibres of the ascending system of the fasciculus longitudinalis medialis, having reached the level of the colliculus superior of the corpora quadrigemina, swing around latero-dorsalward, to pass between Darkschewitsch's nucleus and the nucleus lateralis superior, the axones terminating in the cells of both nuclei. A part of the fibres go through the pars ventralis of the commissura posterior cerebri to terminate in the corresponding nuclei of the opposite side.†

According to Held and Tschermak, the neurone system under discussion represents a deep crossed connection (the crossing taking place low down) between the spinal cord and the nuclei of origin of the motor cerebral nerves as well as the nuclei of the formatio reticularis grisea of both sides as far up as the commissura posterior cerebri.

There has been a great deal of controversy between von Beehterew, von Kölliker, Held, Ramón y Cajal, van Gehuchten,

\* *Vorderseitenstrangrest der Mittellinie* (Held).

† The superior lateral nucleus is continuous headward with the *centre médian* of the nucleus medialis thalami. It will be noted that the pars ventralis of the commissura posterior cerebri contains crossed fibres of the ascending spino-cerebral system which run in the fasciculus longitudinalis medialis, while the pars dorsalis of the commissura posterior cerebri contains axones from the nuclei of the dorsal funiculi which arrive in this region by way of the lemniscus medialis.



Mahaim, and others concerning the relative number of ascending and descending fibres in the fasciculus longitudinalis medialis and in the other bundles of the *formatio reticularis alba*. Some authors hold that the majority of the fibres are for centripetal conduction; others maintain that certainly the majority of the fibres conduct in a centrifugal direction, and that the paths are motor, not sensory. The truth seems to lie in a mean between these two extreme views. In all probability we have here to deal (1) with ascending or centripetal paths consisting of some long inaxones and also of a number of shorter superimposed inaxones (sensory neurones of the second and of higher orders) by means of which motor nuclei may be affected by impulses arriving along sensory nerves and possibly by means of which impulses concerned in sensation can be carried toward the cortex; and (2) with descending or centrifugal paths by means of which the motor nuclei of the rhombencephalon and spinal cord are brought under the influence of the centres of the midbrain and perhaps of higher regions.

Some of the ascending fibres may pass directly into the medial lemniscus, or independently into the hypothalamic region, or from some of the gray masses in which many of these fibres end axones may be given off which run by way of the medial lemniscus or through the *formatio reticularis* to join the other sensory paths in the hypothalamic region.

Just here it may be mentioned that Ciagliński \* has described a long centripetal path situated in the *substantia grisea* of the spinal cord. He is of the opinion that the bundle he describes may have to do with the conduction of impulses concerned in pain and temperature sensation. I have no personal knowledge of this bundle, and thus far I know of no research confirming the results obtained by Ciagliński. The subject of centripetal paths in the *substantia grisea* is of course of deep interest in connection with the elective sensory disturbances met with in syringomyelia and in central hæmatomyelia.

The paths dealt with in this chapter will be further considered in Chapters XLVIII and XLIX. †

---

\* Ciagliński, A. Lange sensible Bahnen in der grauen Substanz des Rückenmarkes und ihre experimentelle Degeneration. *Neurol. Centralbl.*, Leipz., Bd. xv (1896), S. 773.

† Cf. also, Campbell, A. W. On the Traets of the Spinal Cord and their Degenerations. *Brain*, Lond., vol. xx (1897), pp. 488-535.

2. Central Neurones, the Perikaryons and Dendrites of which are situated in the Nuclei terminales of the Axones of the Cerebral Peripheral Centripetal Neurones.

### CHAPTER XLIII.

#### CENTRAL NEURONES PERTAINING TO THE N. VAGUS, N. GLOSSOPHARYNGEUS ET N. INTERMEDIUS.

Cerebral centripetal neurones of the second order—The nucleus alæ cinereæ—Studies of Roller and Holm—The nucleus tractus solitarii—The nucleus commissuralis.

WE pass next to the consideration of the central neurones pertaining to the cerebral sensory nerves. Their cell bodies are situated in the various masses of gray matter (nuclei terminales) in the rhombencephalon, in which are found the end ramifications of the axones of the peripheral sensory neurones belonging to the N. vagus, N. glossopharyngeus, N. vestibuli, N. intermedius, and N. trigeminus. The medullated axones of these central neurones pass, partly directly, partly after decussation, into the medial lemniscus, into the fasciculus longitudinalis medialis, and into certain other bundles which run longitudinally in the formatio reticularis. The neurones here concerned connect directly or indirectly by means of superimposed neurones with the cerebrum through the cerebral peduncle. A few of the axones doubtless pass into the cerebellum. The individual groups of central neurones can best be understood if each be described separately.

It has been stated above (under the description of the peripheral sensory neurones) that the sensory axones of the N. VAGUS, N. GLOSSOPHARYNGEUS, and N. INTERMEDIUS terminate mainly in (1) the nucleus alæ cinereæ, (2) the nucleus tractus solitarii, and (3) the nucleus commissuralis at the spinal extremity of the tractus solitarius.

The nucleus alæ cinereæ, that obliquely longitudinal mass of gray matter extending forward from near the spinal extremity of the nucleus nervi hypoglossi below to a few millimetres beyond the anterior (or cerebral) extremity of the same nucleus in front, corresponds, in the floor of the fourth ventricle, to the fovea inferior and ala cinerea (Fig. 407). It is characterized in transverse sections stained by Weigert's method by its poverty in medullated fibres, thus contrasting strikingly in appearance with the nucleus nervi hypoglossi which lies medial and ventral to it. Just how much of the nucleus alæ cinereæ receives terminals and collaterals from the N. vagus and just how much of it receives fibres from the N. glossopharyngeus seems to be doubtful. While some authors, along with von Kölliker,\* assert that in microscopic preparations it is impossible to decide this further than to state that the uppermost parts of the nucleus belong to the N. glossopharyngeus, and the lowermost parts of it to the N. vagus, others, with Roller† and Holm,‡ are strong supporters of the view that the nuclei of these two nerves are entirely independent of, and on close examination easily distinguishable from, one another. Certain it is that in the gray mass which we call the nucleus alæ cinereæ it is possible to make out more or less distinct groups of nerve cells. According to Holm (Fig. 408), in a section through the middle of the terminal nucleus of the vagus, three groups of cells can be distinctly made out—(1) a ventro-medial portion of the vagus nucleus consisting mainly of large cells; (2) a dorso-lateral portion of the vagus nucleus consisting chiefly of small cells; and (3) the nucleus of termination of the N. glossopharyngeus.\* The view that the dorsal vagus nucleus is not sensory, but a real *nucleus originis* for motor fibres of the nervus vagus, advanced

---

\* *Op. cit.*, S. 240.

† Roller, C. F. W. Der centrale Verlauf des Nervus Glossopharyngeus; des Nucleus lateralis medius. Arch. f. mikr. Anat., Bonn, Bd. xix (1880-'81), S. 347-383.

‡ Holm, H. Die Anatomie und Pathologie des dorsalen Vaguskerne; ein Beitrag zur Lehre der Respirations- und Hustenreflex-Centra, ihrer Entwicklung und Degeneration. Arch. f. path. Anat., etc., Berl., Bd. exxxi (1893), S. 78-120.

\* Holm, from his study of pathological cases, has concluded that the centre for the tracheo-bronchial (coughing) reflex is to be sought in the dorso-lateral part of this dorsal nucleus of the vagus, while the true respiratory centre belongs exclusively to the ventro-medial part of the nucleus.





FIG. 407.—Diagram prepared by Miss F. Sabin from a series of sections through the brain of a new-born babe, showing the nuclei of the cerebral nerves and the area of exit and of entrance of the roots of the cerebral nerves in flat projection. *a*, line of lateral edge of fourth ventricle; *d, d, d, d*, fovea inferior; *e*, fovea superior; *g*, lateral surface of rhombencephalon; *III.*, area of exit of N. oculomotorius; *IV.*, area of exit of N. trochlearis; *V.*, area of exit and entrance of N. trigeminus; *VI.*, area of exit of N. abducens; *VII.*, area of exit of N. facialis; *VIII. (coch.)*, area of entrance of N. cochleæ; *VIII. (vestib.)*, area of entrance of N. vestibuli; *IX. and X.*, area of entrance of N. glossopharyngeus et vagus; *XI.*, area of exit of N. accessorius; *XII.*, area of exit of N. hypoglossus; *Nu.n.III.*, nucleus N. oculo-motorii; *Nu.n.IV.*, nucleus N. trochlearis; *Nu.n.V. (m.p.)*, nucleus motorius princeps N. trigemini; *Nu.n.VI.*, nucleus N. abducens; *Nu.n.VII.*, nucleus N. facialis; *Nu.a.*, nucleus ambiguus; *Nu.a.c.*, nucleus ala cineræ; *Nu.n.r.m.*, nucleus N. vestibuli medialis; *Nu.n.r.s.*, nucleus N. vestibuli superior; *Nu.n.r.l.*, nucleus N. vestibuli lateralis (Deiters); *Nu.n.c.d.*, nucleus N. cochleæ dorsalis; *Nu.n.c.v.*, nucleus N. cochleæ ventralis; *Nu.n.XII.*, nucleus N. hypoglossi; *R.d.n.t.*, radix descendens [mesencephalica] N. trigemini; *R.d.n.v.*, radix descendens N. vestibuli; *S.g.*, substantia gelatinosa; *T. sol.*, tractus solitarius; *Tr.s.n.l.*, tractus spinalis N. trigemini; *Vent.*, ventral horn cells. The numbers to the left of the drawing indicate approximately the levels of the corresponding transverse sections represented by Figs. 308 to 317.

The plane of the sections from which this diagram was made is not quite transverse but somewhat oblique; the dorsal surface of the medulla has been struck by the knife more cerebralward than the ventral surface, the angle formed by the plane of the section with the longitudinal axis being approximately seventy degrees, as measured on the cerebral side. This accounts for the evident (slight) displacement cerebralward of the structures in the ventral portions of the sections as compared with those in the dorsal portions.



by Dees \* as a result of study with the method of atrophy, and recently supported (for smooth muscle) by Marinesco, † as a result of his studies of the nucleus by Nissl's method after section of the nerve, does not seem to be well founded. We know now that the changes such as Marinesco describes can result

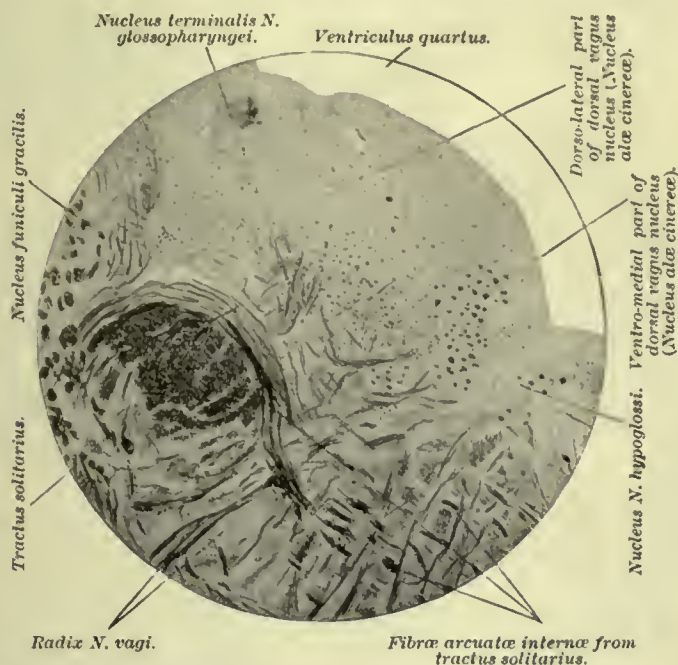


FIG. 408.—Pal preparation from the medulla of a child six weeks old; section through the middle third of the nucleus alæ cinereæ. (After H. Holm, Arch. f. path. Anat., etc., Berl., Bd., cxxxi, 1893, Taf. ii, Fig. 3.)

not only from lesions of the axone of a given neurone, but also from injury to other neurones the axones of which bring impulses to it. (Cf. Chapter XXV.)

Strange as it may appear, the information we possess concerning the course of the axones of the neurones, the cell bodies of which are situated in this important nucleus alæ cinereæ, is extremely meagre. It really amounts to a few vague state-

\* Dees, O. Ueber die Beziehung des Nervus accessorius zu den Nn. vagus und hypoglossus. Allg. Ztschr. f. Psychiat., etc., Berl., Bd. xlv (1888), S. 655.

† Marinesco, G. Les noyaux musculo-striés et musculo-lisses du pneumogastrique. Compt. rend. Soc. biol., Par., 10 s., t. iv (1897), p. 168.

ments as to the origin of *fibræ arcuatæ internæ* from the nucleus, some of which are supposed to pass to the medial lemniscus, others to the fasciculus longitudinalis medialis or to the *formatio reticularis alba*.

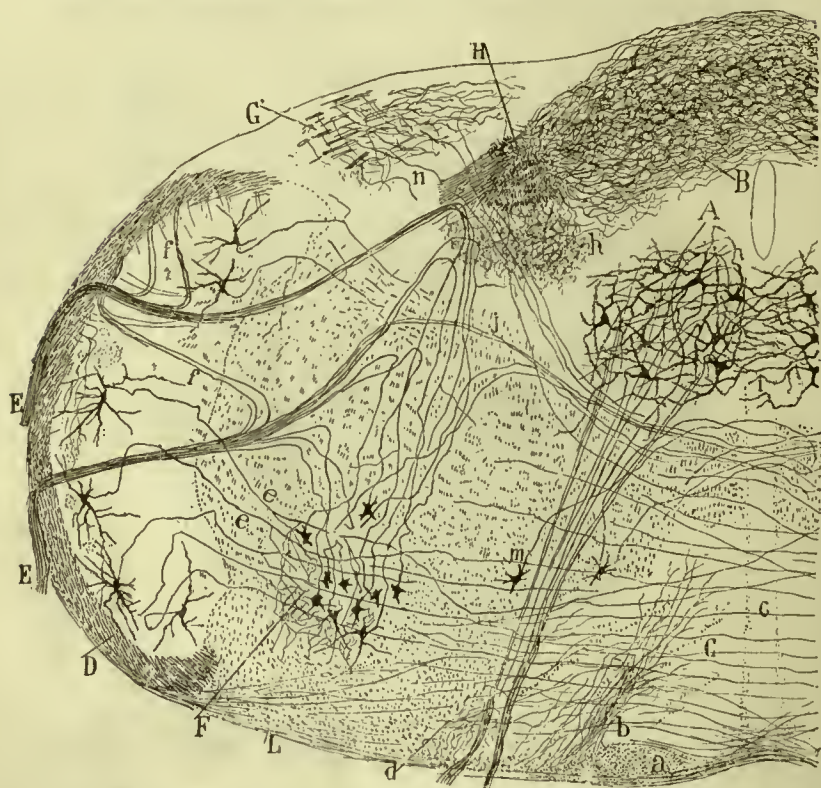

FIG. 409.—Cross section through the rhombencephalon of a four-day-old mouse. (After S. Ramón y Cajal, *Beitrag zum Studium der Medulla Oblongata*, etc., Leipz., 1896, S. 48, Fig. 13.) *A*, nucleus N. hypoglossi; *B*, nucleus commissuralis; *C*, nucleus olivaris inferior; *D*, tractus spinalis N. trigemini; *E*, motor root of N. vagus and N. glossopharyngeus; *F*, nucleus ambiguus; *G*, posterior extremity of nucleus N. vestibuli radialis descendens; *H*, cross section of tractus solitarius; *L*, fibres going to nucleus olivaris inferior; *a*, pyramis; *b*, collaterals from the pyramid and from the substantia alba lateral from it; *d*, collaterals from the fasciculus lateralis proprius; *e*, sensory collaterals for the nucleus ambiguus; *f*, recurrent fibres in motor roots which run toward tractus spinalis N. trigemini; *j*, crossed motor root fibres of N. vagus and N. glossopharyngeus; *h*, collaterals of the sensory root of the N. vagus and N. glossopharyngeus running in the fasciculus solitarius; *i*, protoplasmic commissure between the nuclei N. hypoglossi of the two sides.

The views held concerning the nucleus tractus solitarii are also very divergent. A study of horizontal sections through



the baby's rhombencephalon has, however, convinced me that while the majority of fibres entering the tractus solitarius and terminating in its nucleus are derived from the N. glossopharyngeus, nevertheless a goodly number of fibres from the N. vagus also follow the same course. It seems probable that the nucleus tractus solitarius also receives terminals and collaterals of fibres entering as the N. intermedius. The nucleus tractus solitarii, aside from the nucleus commissuralis at its

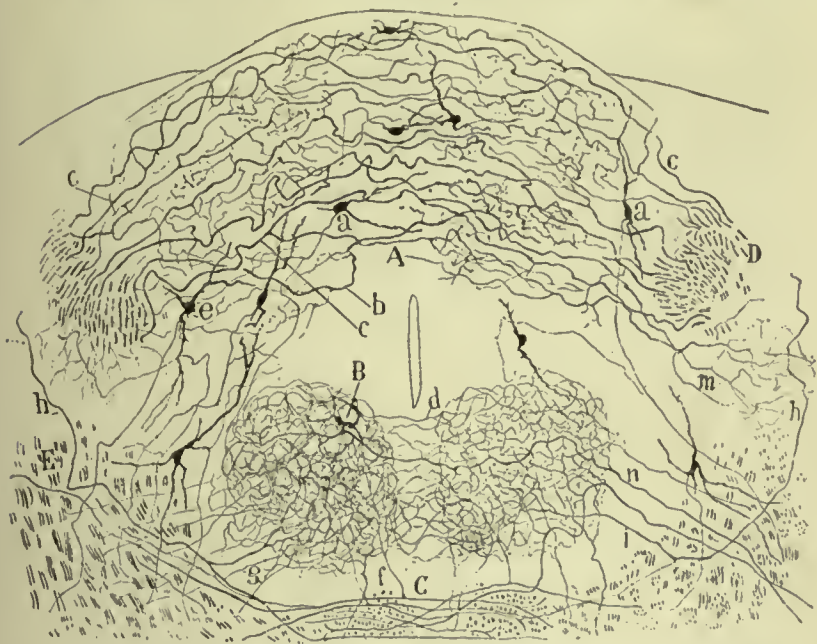

FIG. 410.—Transverse section through the medulla oblongata of a mouse at the level of the nucleus commissuralis. (After S. Ramón y Cajal, *Beitrag zum Studium der Medulla Oblongata*, etc., Bresler, Leipz., 1896, S. 47, Fig. 12.) A, nucleus commissuralis; B, nucleus N. hypoglossi; C, decussatio lemniscorum; D, transverse section of tractus solitarius; E, central path for N. V. IX; a, cell of nucleus commissuralis; b, c, terminal fibres of N. vagus et N. glossopharyngeus; d, commissure formed by collaterals of hypoglossal nuclei; g, f, collaterals of sensory axones of the second order for the nucleus N. hypoglossi.

spinal extremity, consists of a mass of gray matter which surrounds the tractus solitarius along its whole longitudinal extent almost like a cylinder. In this mass end certain collaterals and a few terminals from the tractus solitarius, and in it are situated the perikaryons and dendrites of sensory neu-

rones of the second order. Whither their axones go has not yet been satisfactorily determined.

If Ramón y Cajal's studies be confirmed, then the nucleus commissuralis (his *Commissurenkern* or *ganglion commissurale*) must be regarded as one of the main depots of the cell bodies of the central neurones now being described. According to him,\* three fourths of the fibres of the tractus solitarius decussate at its spinal extremity and terminate in the form of a most complicated plexus of fibrils in this nucleus (Fig. 409). He describes the cell bodies of this nucleus as being small, spindle-shaped, ovoid, or triangular; their dendrites are delicate and almost smooth. The axis cylinders are extremely delicate and form small bundles, which, passing laterally and forward, reach the lemniscus, some of them crossing in the raphe. Isolated fibres can be followed through the formatio reticularis grisea to a region (Fig. 410) which corresponds to the path of the axones of the central neurones of the trigeminus.

---

\* *Op. cit.*, S. 46.

## CHAPTER XLIV.

### CENTRAL VESTIBULAR NEURONE SYSTEMS.

The nuclei terminales *N. vestibuli*—Axones from these nuclei—Medial and lateral central vestibular paths of Ramón y Cajal—The ventral part of the decussatio brachii conjunctivi a vestibular commissure—The central vestibulo-spinal bundle—The fibres extending between the nucleus fastigii and Deiters' nucleus—Influence of vestibular impulses upon the eye-muscle nuclei.

THE cell bodies of the sensory neurones of the second order pertaining to the *N. VESTIBULI* are situated mainly in (1) the nucleus nervi vestibuli medialis, (2) the nucleus nervi vestibuli spinalis (radicis descendents), (3) the nucleus nervi vestibuli superior, and (4) the nucleus nervi vestibuli lateralis (Fig. 411). Finally, (5) a few of them, as we have seen, must be situated in the cerebellum (Ramón y Cajal's nucleus cerebello-acusticus, the nucleus fastigii, and perhaps in the nucleus dentatus and the substantia grisea of the cerebellar cortex). The exact location and reciprocal relations of these nuclei have been described above in connection with the peripheral centripetal neurones. The course followed by the axones which go out from the cells of these nuclei is what interests us here. In the brain of the new-born child, stained by the method of Weigert-Pal, there can be made out going from the nucleus nervi vestibuli medialis and from the nucleus nervi vestibuli spinalis radicis descendents numerous medullated internal arcuate fibres. These fibres differ from the majority of internal arcuate fibres of the rhombencephalon in that they pass close to the dorsal surface instead of making a deep curve ventralward. The most dorsal of these run toward the raphe and pass in among the fibres of the fasciculus longitudinalis medialis. Some of them turn to run forward in the fasciculus of the same side; others of them, after decussation, turn forward in the fasciculus

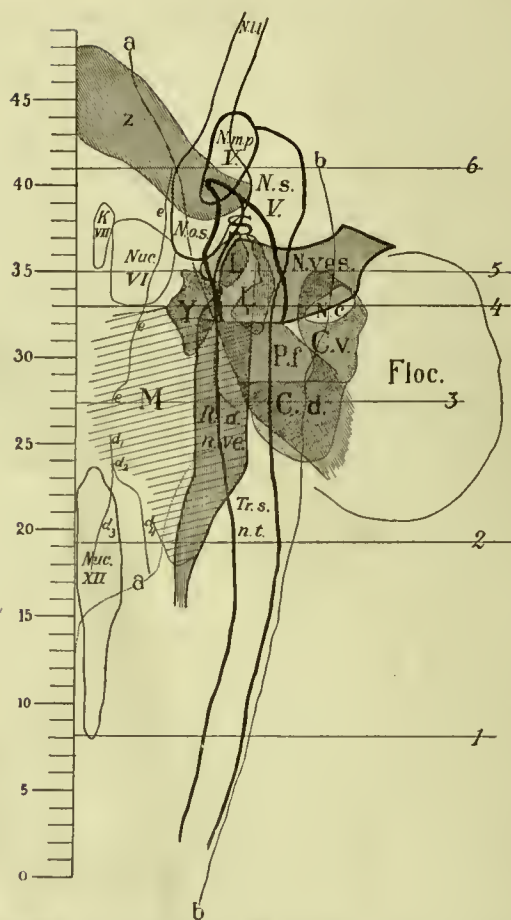


FIG. 411.—Diagram representing flat reconstruction of the nuclei of termination of the cochlear and vestibular nerves. (After Florence R. Sabin, Johns Hopkins Hosp. Bull., Balt., vol. viii, 1897, Fig. 1.) The line *a*, *a* represents the lateral wall of the ventricle; the line *b* corresponds to the lateral outline of the corpus restiforme; the line *d*<sub>1</sub> to *d*<sub>4</sub>, *d*<sub>1</sub> to *d*<sub>3</sub>, and the line *e*, *e*, *e* correspond to the sulci in the floor of the fourth ventricle; *C. d.*, nucleus nervi cochleæ dorsalis; *C. v.*, nucleus nervi cochleæ ventralis; the graduated line corresponds to the middle line of the floor of the ventricle; *Floc.*, flocculus; *K. VII.*, knee of nervus facialis; *L.*, medial portion of nucleus nervi vestibuli lateralis (Deiters); *L.*, lateral portion of nucleus nervi vestibuli lateralis (Deiters); *M.*, together with *V.*, nucleus nervi vestibuli medialis (Schwalbe); *Nuc. XII.*, nucleus nervi hypoglossi; *Nuc. VI.*, nucleus nervi abducentis; *P. f.*, pedunculus flocculi; *N. m. p. V.*, nucleus motorius princeps nervi trigemini; *N. o. s.*, nucleus olivaris superior; *N. s. V.*, nucleus nervi trigemini (sensory); *N. c.*, root bundle of nervus cochleæ; *N. rest.*, root bundle of nervus vestibuli; *R. d. n. v.*, radix descendens nervi vestibuli; *S.*, nucleus nervi vestibuli superior (Bechterew) (area inclosed in the broad black line); *Tr. s. n. t.*, tractus spinalis nervi trigemini; *V.*, nucleus *y.* = antero-lateral portion of nucleus nervi vestibuli medialis; *z.*, decussatio nervi trigemini.



of the opposite side.\* The majority of the axones, from the medial nucleus and from the nucleus of the descending or spinal root, however, appear to run to a region in the formatio reticularis situated lateral and ventral from the nucleus nervi abducentis (Fig. 412), where they assume a longitudinal direction,† sometimes bifurcating into an ascending and a descending limb. A good many of the axones cross the middle line

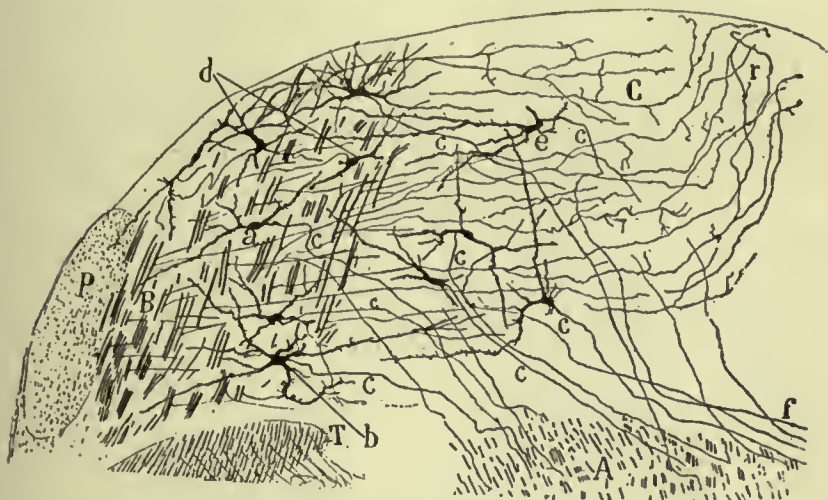


FIG. 412.—Section through the rhombencephalon below the genu internum radialis N. facialis. (After S. Ramón y Cajal, *Beitrag zum Studium der Medulla Oblongata*, etc., Bresler, Leipz., 1896, S. 74, Fig. 20.) A, formatio reticularis grisea in which the lateral central path (axones of eentripetal neurones of the second order connected with the N. vestibuli) lies; B, lateral portion of the nucleus N. vestibuli spinalis; C, medial portion of the same; T, tractus spinalis N. trigemini; P, corpus restiforme; a, b, cells the axones of which go lateralward; e, f, axones which run to the raphe. The letter c indicates the axones.

and reach a similar "lateral vestibular bundle" on the opposite side. A number of the cells in the nucleus of the descending root send their axones lateralward and dorsalward to mingle with the fibres of the descending root. As yet the exact termination of these axones has not been satisfactorily made out.

\* The central vestibular path running in the fasciculus longitudinalis medialis is the one referred to by Ramón y Cajal as the "innere Vestibularisbahn," or medial vestibular path.

† This longitudinal bundle is called by Ramón y Cajal "die laterale Vestibularisbahn."

The nucleus nervi vestibuli superior (von Beehterew) contains large numbers of multipolar cells of smaller size than those of Deiters' nucleus. The axones follow at least two directions. A part of them pass through the nucleus and

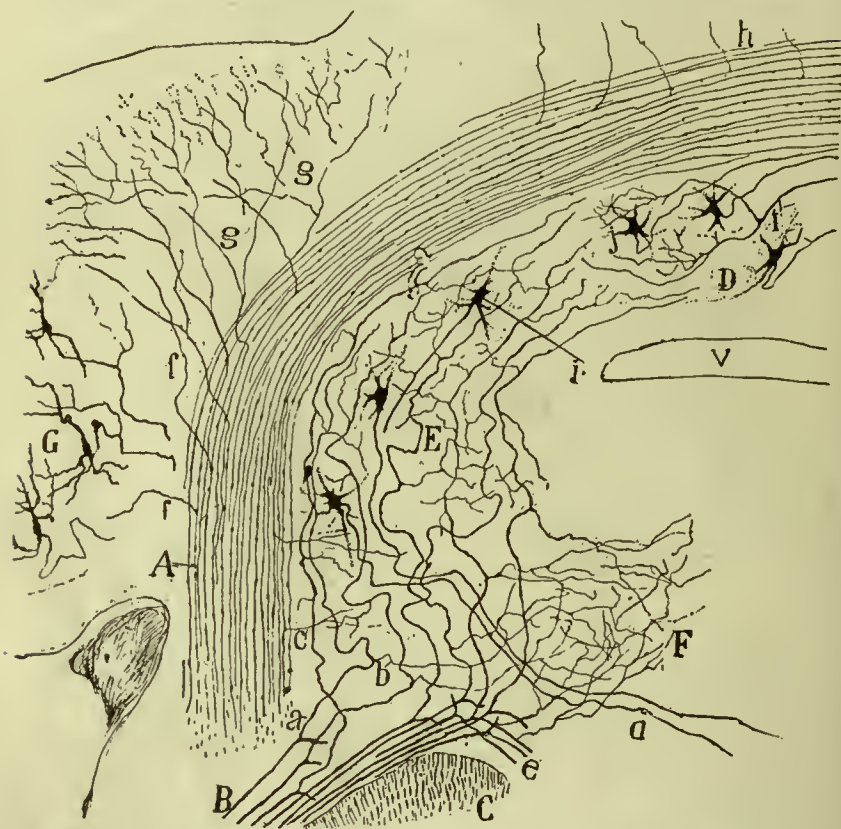

FIG. 413.—Frontal section through the pons, including the corpus restiforme, Deiters' and Beehterew's nucleus and the vermis of the cerebellum of a newborn mouse. (After S. Ramón y Cajal, *Beitrag zum Studium der Medulla Oblongata*, etc., Bresler, 1896, S. 65, Fig. 18.) A, corpus restiforme cut lengthwise; B, radix N. vestibuli; C, tractus spinalis N. trigemini; D, nucleus fastigii; E, nucleus N. vestibuli superior (von Beehterew); F, superior extremity of nucleus N. vestibuli lateralis (Deiters); G, nucleus dentatus; a, ascending limbs of bifurcated axones of N. vestibuli; b, collaterals from these to Deiters' nucleus; c, collaterals from axones of corpus restiforme; d, descending limbs of bifurcated axones of N. vestibuli; e, axone from cell in Beehterew's nucleus; f, collaterals from the axones of the corpus restiforme to the cerebellar hemisphere; g, fibres from corpus restiforme which appear to branch in the cerebellar cortex; h, collaterals from the corpus restiforme to the vermis; i, free branching of an axone in the nucleus fastigii; j, cells of the nucleus fastigii, the axones of which enter the vermis.

through the brachium conjunctivum into the cerebellum, apparently following the same course as the fibres connecting Deiters' nucleus with the cerebellum (*vide infra*). The majority pass ventralward and medialward (Fig. 413) to the region of

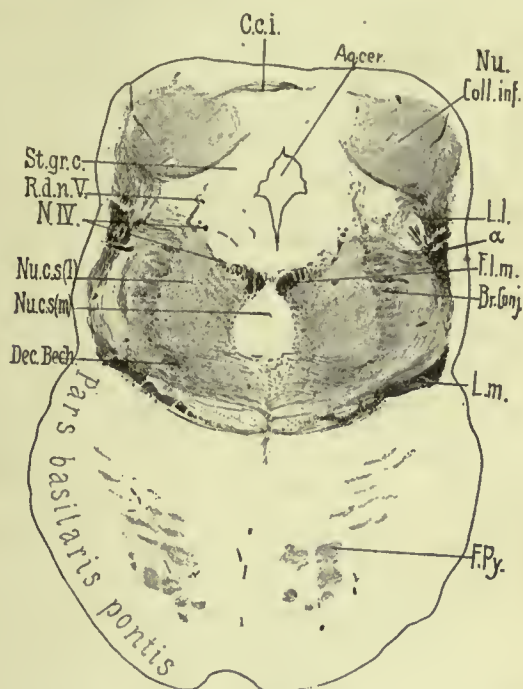


FIG. 414.—Transverse section through brain of newborn babe. Level of colliculi inferiores of corpora quadrigemina. (Weigert-Pal, series ii, section No. 290.) *Aq.cer.*, aqueductus cerebri;  $\alpha$ , fibres running from lateral lemniscus toward dorsal border of brachium conjunctivum; *Br. Conj.*, brachium conjunctivum; *C.c.i.*, commissure between the colliculi inferiores; *Dec.Bech.*, ventral portion of brachium conjunctivum, which in reality forms a commissure between the superior nuclei of the vestibular nerves of the two sides; *F.l.m.*, fasciculus longitudinalis medialis; *F.Py.*, fasciculi longitudinales pontis (pyramidales); *L.l.*, lemniscus lateralis in large part terminating in the nucleus of the colliculus inferior; *L.m.*, lemniscus medialis; *N.IV.*, N. trochlearis; *Nu.Coll.inf.*, nucleus colliculi inferioris; *Nu.cs.(l)*, nucleus centralis superior, pars lateralis; *Nu.cs.(m)*, nucleus centralis superior, pars medialis; *R.d.n.V.*, radix descendens [mesencephalica] N. trigemini; *St.gr.c.*, stratum griseum centrale. (Preparation by Dr. John Hewetson.)

Deiters' nucleus, where some of them probably end, though most appear to pass through the nucleus (perhaps giving off collaterals to it) in order to follow the same course as that pursued by the axones arising in it. The axones from Ramón y

Cajal's nucleus cerebello-acusticus apparently follow the same course as those from von Bechterew's nucleus.

Von Bechterew\* describes a bundle of fibres running from the nucleus nervi vestibuli superior of one side to that of the other by way of the brachia conjunctiva. The fibres which make up this bundle are the first of all the fibres of the brachium conjunctivum to become medullated, and occupy in the middle of the pons its most ventral part. Von Bechterew asserts that the fibres have nothing to do with the cerebellum, that they run forward as far as the upper part of the pons, but before reaching the general decussation they leave the brachium conjunctivum and pass over to the other side in the form of a commissure. Portions of this vestibular commissure, which is relatively independent of the main decussatio brachii conjunctivi, are shown in Fig. 414 and Fig. 415. The connection of the axones of these fibres with the cells which give them origin by Golgi's method has thus far not been established. In Miss Florence Sabin's wax model of the medulla oblongata, however, the reconstruction shows the intimate relation of von Bechterew's nucleus to the ventral part of the brachium conjunctivum.

The course of the axones of the neurones, the cell bodies and dendrites of which constitute the nucleus nervi vestibuli lateralis (Deiters), has been studied by nearly all investigators who have been active recently in this field, and he who will know this region in its details should study the articles of Obersteiner, von Kölliker,† Sala, ‡ Held, \* Ramón y Cajal, || and Risien Russell.<sup>A</sup> The cell bodies in Deiters' nucleus are large and multipolar, resembling closely, by all methods of examination (including that of Nissl), the motor cells of the ventral horns of the spinal cord. The axones of the cells are of large

\* von Bechterew, W. *Op. cit.*, S. 117 u. 135.

† *Op. cit.*, S. 269 ff.

‡ Sala, L. Ueber den Ursprung des Nervus acusticus. *Arch. f. mikr. Anat.*, Bonn, Bd. xlii (1893), S. 18-52.

\* Held, H. Beiträge zur feineren Anatomie des Kleinhirns und des Hirnstammes. *Arch. f. Anat. u. Physiol.*, Anat. Abth., Leipz. (1893), S. 435-446.

|| Ramón y Cajal, S. Beitrag zum Studium der Medulla Oblongata, etc. Deutsch von Bresler, Leipzig (1896), S. 67 ff.

<sup>A</sup> Russell, J. S. R. The Origin and Destination of Certain Afferent and Efferent Tracts in the Medulla Oblongata. [Abstr.] *Brit. M. J.*, Lond. (1897), i, p. 1155. Also in *Proc. Roy. Soc.*, Lond., vol. lxi (1897), pp. 73-76.



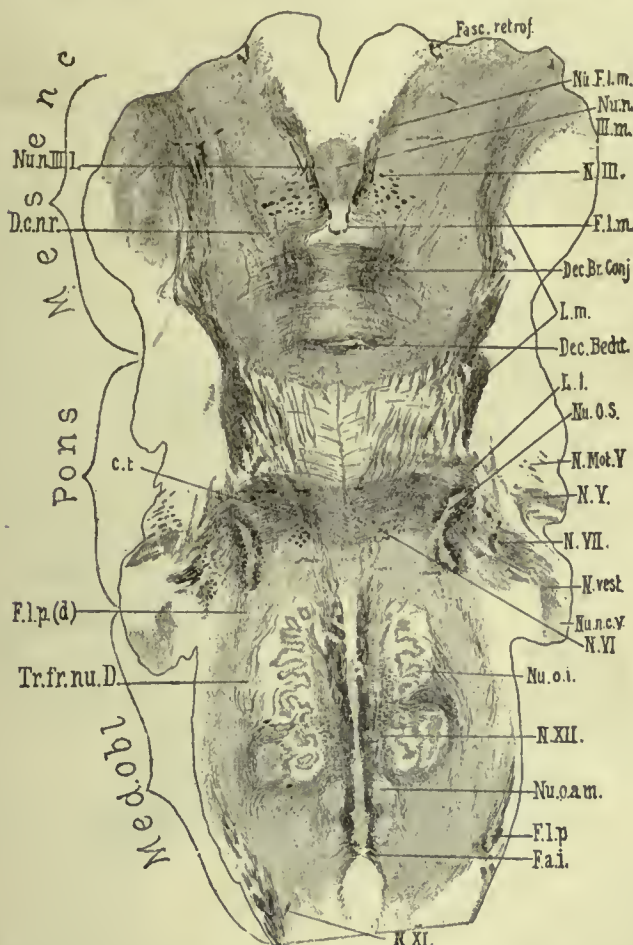
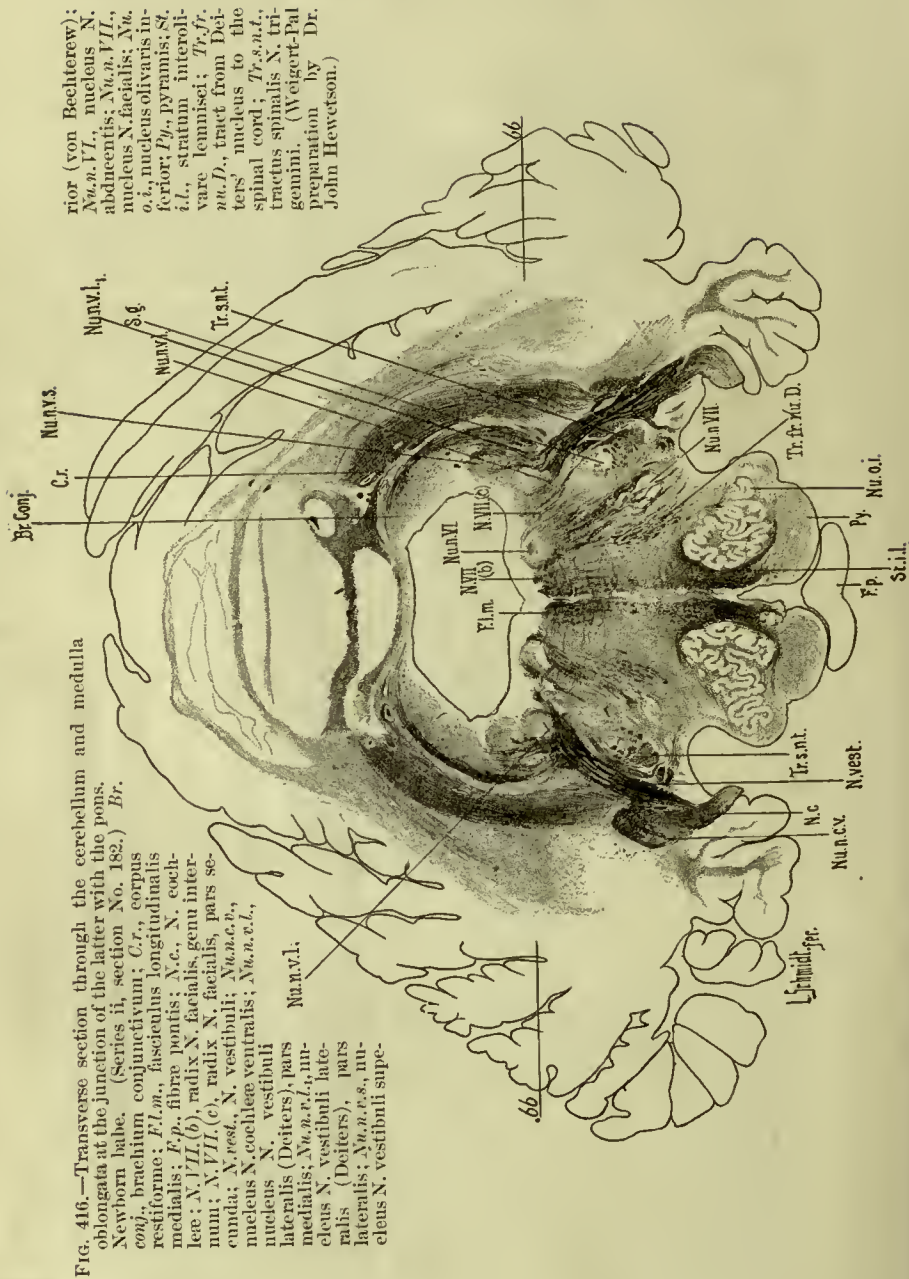


FIG. 415.—Horizontal section through the medulla, pons, and midbrain of a newborn babe. Weigert-Pal staining. Level of dorsal part of corpus trapezoidum and dorsal portion of nucleus olivaris inferior. (Series iii, section No. 122.) *C.t.*, corpus trapezoidum; *Dec. Br. Conj.*, decussatio brachii conjunctivi; *Dec. Becht.*, commissure between Bechterew's nuclei; *D.c.n.r.*, dorsal capsule of nucleus ruber; *F.a.i.*, fibrae arcuatae internae; *Fasc. retrof.*, fasciculus retroflexus Meynerti; *F.l.m.*, fasciculus longitudinalis medialis; *F.l.p.*, bundle continuous with the fasciculus lateralis proprius of the cord; *F.l.p.(d)*, dorsal portion of bundle continuous with fasciculus lateralis proprius of the cord; *L.l.*, lemniscus lateralis; *L.m.*, lemniscus medialis; *N. III.*, radix N. oculomotorii; *N. Mot. V.*, motor root of N. trigeminus; *N. V.*, sensory root of N. trigeminus; *N. VI.*, radix N. abducentis; *N. VII.*, radix N. facialis, pars secunda; *N. vest.*, radix N. vestibuli; *N. XII.*, radix N. accessorii; *N. XII.*, radix N. hypoglossi; *Nu. F.l.m.*, nucleus fasciculi longitudinalis medialis, or nucleus commissurae posterioris (oberer Oculomotoriuskern of Darkschewitsch); *Nu. n. III.m.*, pars inpar of nucleus N. oculomotorii; *Nu. n. III.l.*, pars lateralis of nucleus N. oculomotorii; *Nu. o.s.*, nucleus olivaris superior; *Nu. n.c.V.*, nucleus N. cochleae ventralis; *Nu. o.i.*, nucleus olivaris inferior; *Nu. o.a.m.*, nucleus olivaris accessorius medialis; *Tr. fr. nu. D.*, tract from Deiters' nucleus to the spinal cord. (Preparation by Dr. John Hewetson.)



calibre and devoid, or almost devoid, of collaterals. The exact courses which they follow are still not entirely settled, but at any rate, concerning certain groups of axones, we now possess

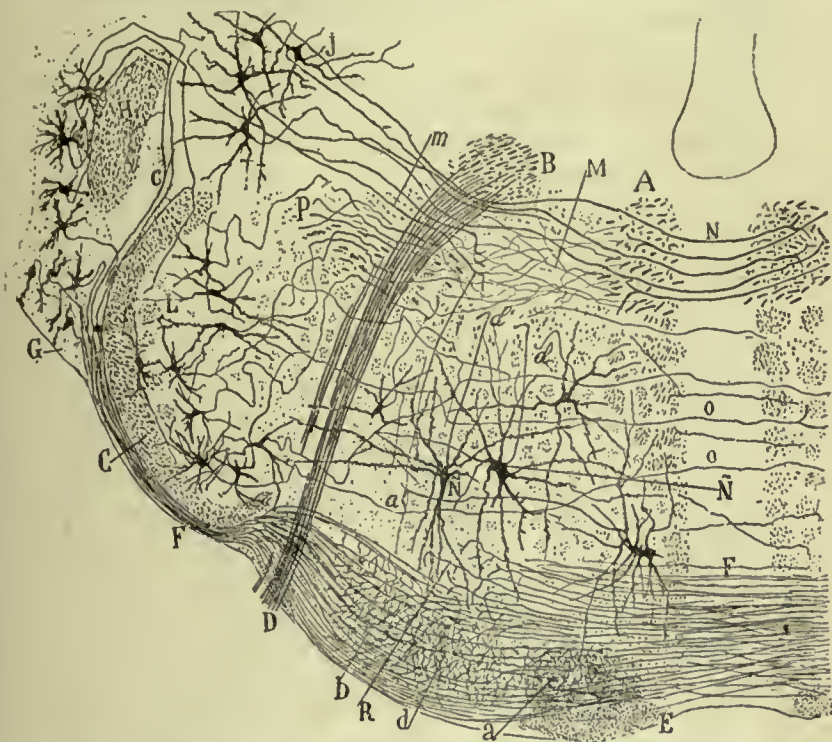


FIG. 417.—Transverse section through the rhombencephalon of a mouse at the level of Deiters' nucleus and the corpus trapezoideum. (After S. Ramón y Cajal, *Beitrag zum Studium der Medulla Oblongata*, etc., Bresler, Leipz., 1896, S. 10, Fig. 3.) A, fasciculus longitudinalis medialis; B, radix N. facialis genu internum; C, tractus spinalis N. trigemini; D, radix N. facialis; E, pyramis; F, corpus trapezoideum; G, nucleus N. cochleae ventralis; H, corpus restiforme; I, giant cells of substantia gelatinosa of N. trigeminus; J, collaterals from axones of fasciculus longitudinalis medialis; K, raphe; L, vertical path formed by axones of nuclei terminales connected with the N. V, VIII, IX, and X; M, terminal axones of corpus trapezoideum; N, axones from cells in the nucleus N. cochleae dorsalis; O, nucleus N. vestibuli lateralis (Deiters); P, axones from cells in Deiters' nucleus; Q, axones from cells in substantia gelatinosa.

definite information. Thus it is known that a large number of the axones pass dorsalward through the nucleus nervi vestibuli superior (von Bechterew) and through the brachium conjunctivum into the cerebellum. These end in the gray masses



situated in the roof of the fourth ventricle (chiefly in the nucleus fastigii, but possibly also in the nucleus globosus and nucleus emboliformis) of the same side and of the opposite side—mainly, it would seem, in the latter. Every one who has studied serial sections of the new-born babe's medulla and cerebellum must have been impressed by the bands of medullated fibres which obviously extend between the nuclei of the roof and the region of Deiters' nucleus (Fig. 416). Now, while the majority, perhaps, of investigators regard these bundles as medullated axones arising from cells situated in the nuclei of the roof and

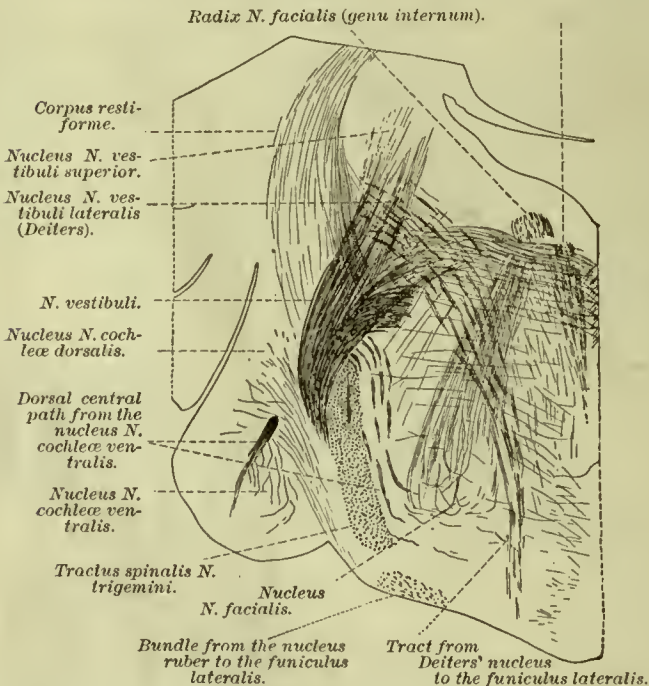


FIG. 418.—Oblique section through the brain stem of a newborn cat. The course of the path from the nucleus nervi vestibuli lateralis (Deiters) to the remains of the ventro-lateral funiculi is illustrated. (After H. Held, Abhandl. d. math.-phys. Cl. d. k. Sächs. Gesellsch. d. Wissensch., Leipz., Bd. xviii, No. 6, 1892, Taf. ii, Fig. 8.)

passing to Deiters' nucleus of the opposite side, still von Kölliker's studies by the method of Golgi show clearly that a part of these fibres represent axones passing in the opposite direction, having their origin in the cells of Deiters' nucleus.



The majority of the axones from Deiters' nucleus do not, however, pass into the cerebellum, but, together with the axones from the nucleus nervi vestibuli superior, pass medialward, in order to reach certain longitudinal bundles of fibres to be immediately described. The fibres passing medialward may be divided into two groups: (1) those more dorsally situated, and (2) those passing more ventralward. The former group of fibres, as Ramón y Cajal describes them in the mouse, pass from Deiters' nucleus medialward, avoiding the knee of the facial nerve; they go sometimes behind, sometimes through the nucleus nervi abducentis, cross the raphe, and enter the fasciculus longitudinalis medialis, where they bifurcate into an ascending and descending limb, the former often being the stouter (Fig. 417). This "medial or crossed central vestibular path," Ramón y Cajal thinks, is the principal constituent of the fasciculus longitudinalis medialis. The second group of fibres passing to a more ventral and lateral position has been seen and studied by several neurologists. Thus Bruce\* saw and pictured it as early as 1889, and the bundle is indicated in Fig. 150, page 382, of Obersteiner's text-book published in 1892. The bundle was carefully described by Held† in 1891 and in 1892, and I have for illustration reproduced one of the pictures accompanying his articles (Fig. 418). The axones going into this bundle have been studied by Golgi's method, especially by von Kölliker and by Ramón y Cajal. It may correspond to Ramón y Cajal's "lateral or direct central vestibular path" (Fig. 419). Having reached the bundle (which, as the figures show, is situated laterally as regards the root fibres of the nervus abducens, and dorso-medially as regards the superior olive), the fibres turn in it to assume a longitudinal direction. Some, probably the majority, turn down toward the spinal cord; others turn up to run toward the midbrain, while still others bifurcate, one branch turning upward, the other downward into the fasciculi proprii of the spinal cord (Held), and in all probability come into anatomical relations with the cell bodies and dendrites of the lower

\* Bruce, A. On the Connections of the Inferior Olivary Body. *Proc. Roy. Soc. Edinb.* (1889-'90), 1891, vol. xvii, pp. 23-27.

† Held, H. Die centralen Bahnen des Nervus acusticus bei der Katze. *Arch. f. Anat. u. Physiol., Anat. Abth., Leipz.* (1891), S. 271-291.—Die Beziehungen des Vorderseitenstranges zu Bahnen im Mittelhirn, *Abhandl. d. k. Sächs. Gesellsch. d. Wissensch., Leipz.*, Bd. xviii (1892).

motor neurones situated in the ventral horns. The bundle marked *Tr. fr. nu. D.* in the accompanying illustration represents the system under description (Fig. 420).<sup>\*</sup> This vestibular

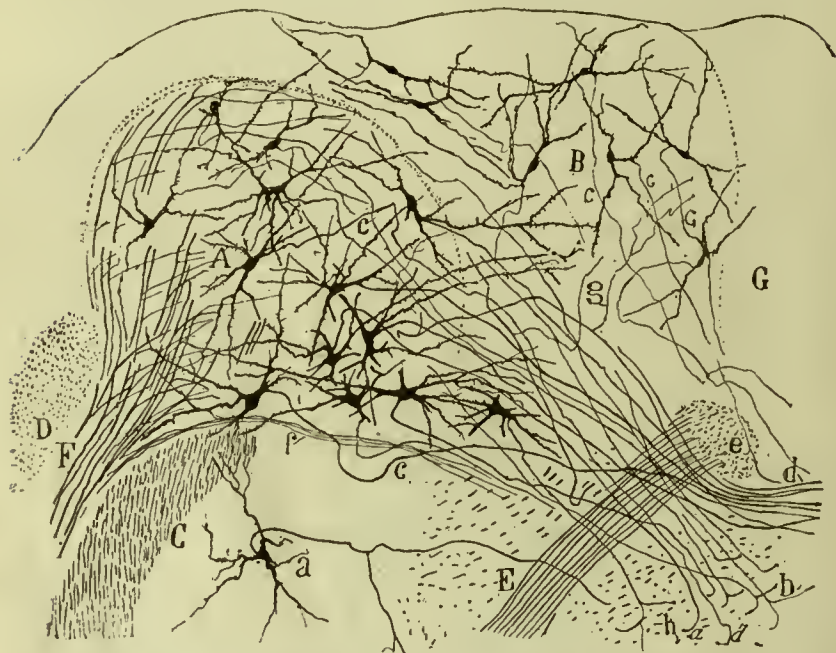


FIG. 419.—Transverse section through Deiters' nucleus of a mouse a few days old. (After S. Ramón y Cajal, *Beitrag zum Studium der Medulla Oblongata*, etc., Bresler, Leipz., 1896, S. 69, Fig. 19.) A, nucleus N. vestibuli lateralis (Deiters'); B, nucleus N. vestibuli medialis; C, tractus spinalis N. trigemini; D, corpus restiforme; E, radix nervi facialis, pars secunda; G, stratum griseum centrale; F, N. vestibuli; a, cells of substantia gelatinosa of N. trigemini; b, lateral central vestibular path; d, central vestibular path reaching the raphe; e, genu internum (Rad. N. facialis); f, axones from N. vestibuli which appear to go toward the raphe; g, collaterals from central vestibular axones; h, bifurcation of an axone coming from Deiters' nucleus; the letter c indicates axone.

spinal bundle will be described more fully in Chapters LVII to LIX. The ascending fibres of both medial and lateral central vestibular paths may be of importance in furthering the trans-

<sup>\*</sup> Deiters' nucleus thus in all probability represents an important way-station between the cerebellum and the spinal cord. The fact that many axones from Deiters' nucleus pass down into the ventro-lateral ground bundle doubtless explains the interesting observation of Roller, who found that the cells of Deiters' nucleus atrophied after section of the upper cervical cord.

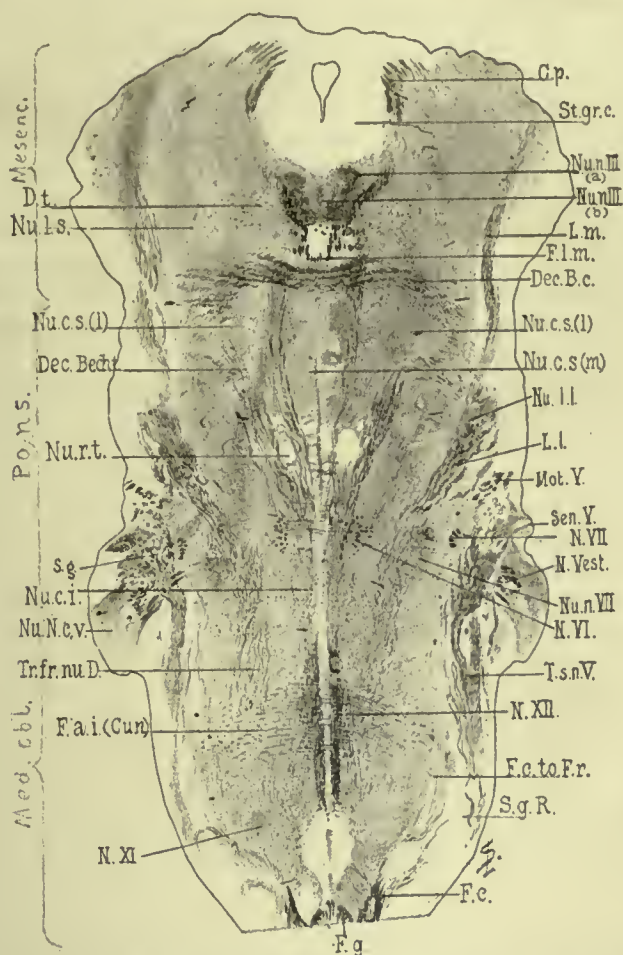


FIG. 420.—Horizontal section through the medulla, pons, and midbrain of a newborn babe. Weigert-Pal staining. Level of decussatio brachii conjunctivi and of nucleus reticularis tegmenti. (Series iii, section No. 108.) *C.p.*, commissura posterior cerebri; *Dec.B.c.*, decussatio brachii conjunctivi; *Dec.Beht.*, commissure between Bechterew's nuclei; *D.t.*, fibres to decussatio tegmenti; *F.a.i.(Cun.)*, fibræ arcuatae internæ from the nucleus funiculi cuneati; *F.c.*, fasciculus cuneatus; *F.c.to.F.r.*, bundle from fasciculus cuneatus to formatio reticularis; *F.g.*, fasciculus gracilis; *F.l.m.*, fasciculus longitudinalis medialis; *L.m.*, lemniscus medialis; *L.l.*, lemniscus lateralis; *Mot.V.*, radix motorius N. trigemini; *N.III.*, radix N. facialis, pars secunda; *N.vest.*, radix N. vestibuli; *N.VII.*, radix N. abducentis; *N.XII.*, radix N. hypoglossi; *N.XI.*, radix N. accessorii; *Nu.n.III.(a)*, nucleus N. oculomotorii, pars lateralis; *Nu.n.III.(b)*, nucleus N. oculomotorii, pars impar; *Nu.c.s.(l)*, nucleus centralis superior, pars lateralis; *Nu.c.s.(m)*, nucleus centralis superior, pars medialis; *Nu.l.l.*, nucleus lemnisci lateralis; *Nu.n.VII.*, nucleus N. facialis; *Nu.N.c.v.*, nucleus N. cecblæ ventralis; *Nu.c.i.*, nucleus centralis inferior; *Nu.r.t.*, nucleus reticularis tegmenti; *Nu.l.s.*, nucleus lateralis superior; *St.gr.c.*, stratum griseum centrale; *Sen.V.*, sensory root of N. trigeminus; *S.g.*, substantia gelatinosa Rolandi; *Tr.fr.nu.D.*, tract from Deiters' nucleus to the spinal cord; *T.s.n.V.*, tractus spinalis N. trigemini. (Preparation by Dr. John Hewetson.)

port of impulses toward the cerebral cortex; if so, they are properly regarded as axones of sensory neurones of the second order in the general path from the periphery of the body to the somæsthetic area of the cortex. The exact course of the ascending fibres is not wholly clear; those of the medial path accompany the fibres of the fasciculus longitudinalis medialis;\* indeed, if Ramón y Cajal be right, they make up a large part of this bundle; those of the lateral bundle either join the lemniscus medialis or run up as a separate bundle in the *formatio reticularis*, some of them ultimately, in all probability, passing through the tegmentum of the cerebral peduncle into the diencephalon.

---

\* The afferent vestibular impulses in the fasciculus longitudinalis medialis probably exercise a controlling effect upon the eye muscle nuclei. In vestibular disease a peculiar form of nystagmus is not infrequently met with.



## CHAPTER XLV.

### CENTRAL CENTRIPETAL TRIGEMINAL NEURONES.

The substantia gelatinosa and *nuclei tractus spinalis nervi trigemini*—Interstitial cells—Marginal cells—Deep or medial cells—The giant cells—Axones and collaterals of central trigeminal neurones.

THE cell bodies and dendrites of the sensory neurones of the second order pertaining to the sensory part of the *NERVUS TRIGEMINUS* are situated in the substantia gelatinosa and adjacent gray matter. The substantia gelatinosa adjacent to the tractus spinalis nervi trigemini may, therefore, be called the *nuclei tractus spinalis nervi trigemini*. The large mass of substantia gelatinosa situated opposite to and somewhat above the entrance of the nerve, often referred to as the main sensory nucleus terminalis of the trigeminus, is really only an expanded upper extremity of the substantia gelatinosa, which accompanies the tractus spinalis, inasmuch as serial sections show that these masses are directly continuous with one another. A portion of this large main mass of the anterior extremity of the nucleus is intercalated between the motor and sensory bundles, and is possibly destined to receive the ascending limbs of bifurcation of the entering sensory axones.

These terminal nuclei of the sensory trigeminus have been studied especially by von Kölliker\* and by Ramón y Cajal.† According to von Kölliker, the cells may be divided into two kinds: (1) large cells and (2) small cells. Their axones, he believes, pass medialward as *fibræ arcuatae internæ*, decussate in the raphe, and turn to run longitudinally, probably in the medial lemniscus.

Ramón y Cajal's studies concerned chiefly the nuclei in the

---

\* von Kölliker. *Op. cit.*, S. 281 ff.

† Ramón y Cajal, S. Beitrag zum Studium der Medulla Oblongata. Deutsch von Bresler, Leipz. (1896), S. 6 ff.

mouse. He divides the cells of the sensory nucleus into three zones: (1) the interstitial cells, (2) the marginal cells (*Randzellen*), and (3) the deep or medial cells. The interstitial cells are triangular or stellate, sometimes spindle-shaped. They are located between the bundles of the deep layer (*vide supra*, p. 522) of the tractus spinalis or between this and the superficial layer. Their dendrites pass ventrally, dorsally, or medially in among the bundles mentioned. Their axones assume usually a longitudinal direction either in the adjoining bundles of the tractus spinalis or in the substantia gelatinosa itself. The cells are nearly of medium size, although many of them reach considerable dimensions (Fig. 421, a).

The marginal cells form a thin layer just medial to the bundles of the deep layer of the tractus spinalis. Many of them are spindle-shaped, others are pear-shaped, the dendrites assuming variable directions. The axones run in part ventralward, giving off collaterals to the substantia gelatinosa and being continued as longitudinal fibres of the *plenum fibrillare profundum*, in part medialward, in order to help in the formation of the central sensory path.

The deep or medial cells, those of the substantia gelatinosa proper, are very numerous. In shape they are usually triangular or stellate, and can be divided into giant cells and small cells. The latter are the more numerous and are arranged chiefly in the form of small, sometimes indistinctly limited, islands. These islands, which appear never to be absent from the dorsal region of the substantia gelatinosa, consist of three elements: (1) Very finely branched varicose dendrites, arising from the spindle-shaped or triangular cells and lying in the interspaces between the islands; (2) extremely complicated dendrites, which have their origin in the small cell bodies lying within the cell islands; (3) a number of very dense plexuses made up of the end ramifications of collaterals or terminals from the axones of the tractus spinalis nervi trigemini. The very delicate axis cylinders of the small cells of the islands give off branched collaterals in the substantia gelatinosa and follow an irregular course, so that Ramón y Cajal could rarely follow them beyond the substantia gelatinosa itself. Occasionally, however, he saw one reach the formatio reticularis grisea, and he assumes that such axones perhaps enter the central sensory path.

The giant cells are scattered irregularly through the whole substantia gelatinosa; the axones from these cells could be easily and certainly followed. Arising ordinarily from a den-

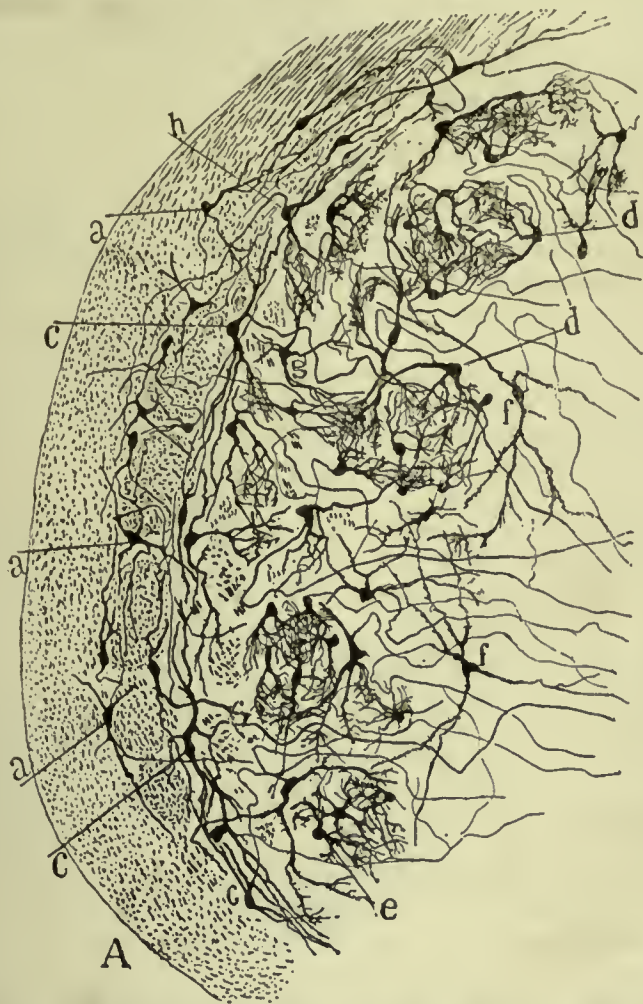

FIG. 421.—Transverse section through the tractus spinalis N. trigemini and adjacent substantia gelatinosa of a newborn rabbit. (After S. Ramón y Cajal, *Beitrag zum Studium der Medulla Oblongata*, etc., Bresler, Leipz., 1896, S. 8, Fig. 2.) A, ventral part of tractus spinalis; a, interstitial cells; c, marginal cells; d, cell islands in substantia gelatinosa; e, small cells of these islands; f, stellate giant cells not arranged in islands; g, interinsular cells; h, a marginal cell, the axone of which appears to go into the white substance or into the tractus spinalis N. trigemini.

drite near the cell body, such an axone turns dorsally and medially in the form of a curve, giving off two or more collaterals to the substantia gelatinosa and to the formatio reticularis grisea; it is continued finally after having crossed the dorsal part of the raphe at a level which varies for different axones, as a longitudinal ascending fibre of the medial lemniscus of the opposite side. The fibre often bifurcates into an ascending and a descending limb.

The axones of other giant cells do not cross the middle line, but, having arrived at the dorsal border of the formatio reticularis grisea, bend around in the neighborhood of the knee of the nervus facialis to run in a longitudinal bundle. This bundle, representing one central path of the trigeminus, receives axones not only from the substantia gelatinosa of the same side, but also from that of the opposite side. According to Ramón y Cajal, it finds a special location in the formatio reticularis alba, close to the central longitudinal path, made up of the axones of sensory neurones of the second order associated with the nervus vagus and nervus glossopharyngeus.

Other axones from the substantia gelatinosa may follow a still different course, but for the details the reader is referred to the original contribution of Ramón y Cajal. All important, however, is the observation that the axones of the central neurones now under description, in their transverse as well as in their longitudinal course, give off collaterals into the formatio reticularis grisea and alba, some of which certainly reach the motor nuclei, in which are situated the cell bodies and dendrites of the lower motor neurones, the axones of which go to make up the nervus facialis and the motor part of the nervus vagus and nervus glossopharyngeus. In Fig. 422 are shown some of the fibres of the trigeminal path entering the bundle continuous with the ventro-lateral funiculi of the cord.

While many of the axones of the central neurones just described are concerned in more or less complex reflex activities, certainly some of them, either directly, or indirectly by means of neurones of a higher order, take part in the formation of the longitudinal bundles which go through the tegmentum of the cerebral peduncle into the hemisphere.

The two human cases reported by Hoesel\* make it seem

---

\* *Op. cit.*, Chapter xlvii.



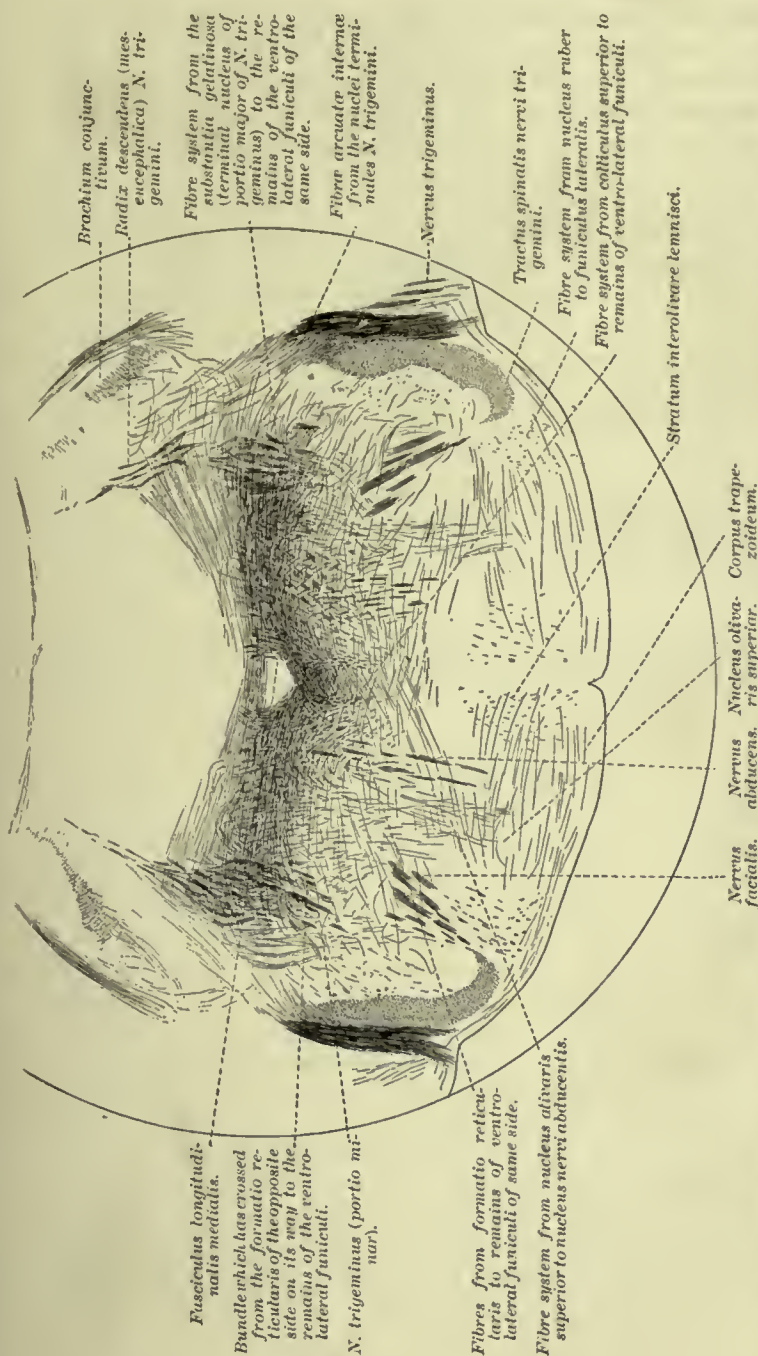


FIG. 422.—Transverse section through the brain stem of a young rat, illustrating the crossed and uncrossed fibres from the nuclei N. trigemini to the bundles continuous with the ventro-lateral funiculi of the spinal cord. (After R. Held, Abhandl. d. math.-phys. cl. d. k. sächs. Gesellschaft. d. Wissenschaft., Leipzig, Bd. xviii. 1892, Taf. ii, Fig. 5.)

likely that the central trigeminal conduction path is a crossed path terminating in the central gyri of the pallium. The indications are that it is interrupted in the ventro-lateral group of nuclei of the thalamus. If this be the case, then in the trigeminal conduction paths at least three neurone systems are superimposed, the crossing taking place in the domain of the system of the second order. This view has been confirmed by the experiments of Wallenberg.\* After injury to the substantia gelatinosa in the upper cervical cord on one side, he found degeneration of a bundle of fibres which crossed the raphe ventral to the nucleus N. hypoglossi, and then ascended in the formatio reticularis, being at first situated medio-dorsally and higher up latero-dorsally. Having reached the level of the hilus thalami the fibres entered the lamina medullaris medialis, and a large part of them ended in the ventral group of nuclei of the thalamus. Another group of degenerated fibres could be followed by Wallenberg across the raphe, thence by way of the inter-olivary layer and medial lemniscus to the ventral part of the thalamus.

---

\* Wallenberg, A. Zur secundären Bahn des sensiblen Trigeminus. Anat. Anz., Jena, Bd. xii (1896), S. 95-110.

3. Central Neurones, the Perikaryons and Dendrites of which are situated in the Cerebellum, the Axones running Cerebralward, and possibly representing Indirect Central Centripetal Conduction Paths.

## CHAPTER XLVI.

### THE SOMÆSTHETIC PATH TO THE CEREBRUM BY WAY OF THE CEREBELLUM.

Cerebello-cerebral paths—The brachium conjunctivum or superior cerebellar peduncle—Experimental degenerations—Degenerations in human cases—Myelinization of the brachium conjunctivum—Studies by Golgi's method—The fasciculus cerebellaris lateralis descendens.

TAKING a backward glance for a moment, it will be seen that from all the groups of sensory neurones of the second order, pertaining to the spinal and cerebral nerves which bring impulses concerning the body itself into the central nervous system, there are axones (aside from those of short paths mediating reflexes) passing in two main directions: (*a*) toward the cerebral hemisphere by way of the tegmentum of the cerebral peduncle; (*b*) into the cerebellum. Of the former, the groups of axones going to make up the medial lemniscus, the fasciculus longitudinalis medialis, and certain longitudinal bundles in the formatio reticularis will be recalled; of the latter will be remembered the fasciculus spino-cerebellaris dorso-lateralis or direct cerebellar tract of Flechsig, the cerebellopetal systems in the fasciculus ventro-lateralis (Gowersi), the fibræ arenatæ externæ ventrales et dorsales pertaining to the spinal paths, as well as certain less definitely worked out cerebellar connections of the nuclei of termination of the nerves of the rhombencephalon. Further must be mentioned the fact that from many of the axones from the nuclei of the dorsal funiculi, as they pass through the stratum interolivari lemnisci, there are given off collaterals to the nucleus olivaris inferior. Thence the cerebellum may be influenced by the fibræ olivocerebellares.

The question naturally arises, Can these nerve fibres, which run in to terminate in the gray matter of the cerebellum, help to carry impulses toward the cerebral cortex by means of neurones of a higher order? That they can do so seems fairly

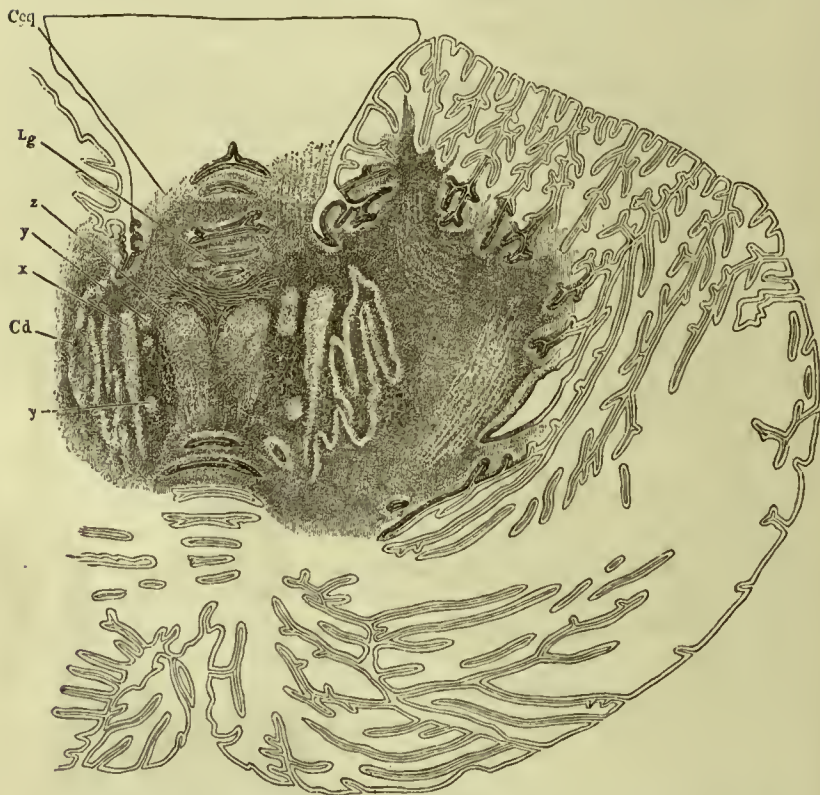


FIG. 423.—Horizontal section of the cerebellum passing through the marginal thickenings of the lingula. (After B. Stilling, *Neue Untersuch. u. d. Bau d. kleinen Gehirns d. Mensch.*, Cassel, 1878, Taf. xv, Fig. 98, taken from J. Henle, *Handbuch der Nervenlehre des Menschen*, II. Aufl., Braunsch., 1879, S. 259, Fig. 173.) *Ceq*, brachium conjunctivum; *Cd*, nucleus dentatus; *x*, nucleus emboliformis; *y*, *y*, parts of the nucleus glohosus; *z*, nucleus fastigii.

certain, partly from clinical evidence that need not now be discussed, and partly from anatomical findings to be immediately mentioned. We have seen that the axones entering the cerebellum from the nuclei of termination of the sensory nerves do so chiefly by way of the corpus restiforme (inferior cerebellar peduncle); a few of them enter by way of the brachium con-





Given these conditions, it is not difficult to find an anatomical path which could serve for the further conduction of sen-

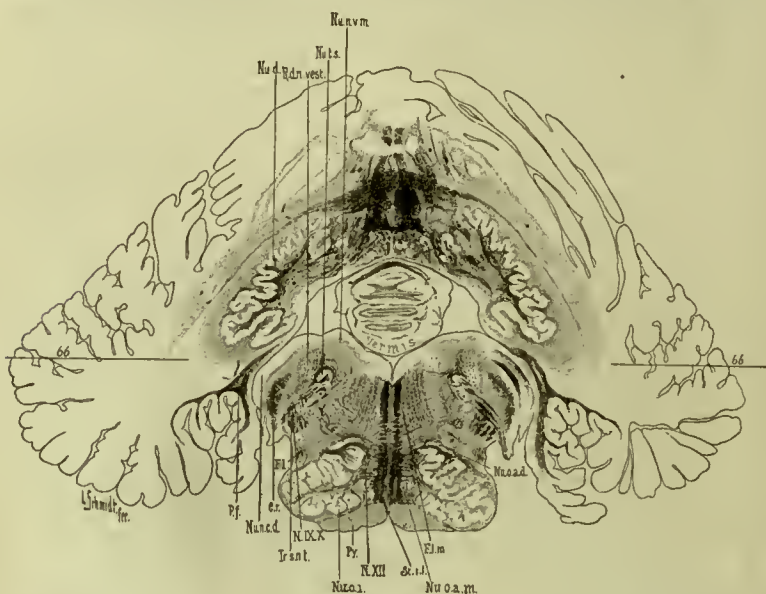


FIG. 425.—Transverse section of medulla oblongata and cerebellum of newborn child. (Series ii, section No. 146.) *C.r.*, corpus restiforme (the part medullated corresponds in the main to the direct cerebellar tract); *F.l.*, bundle continuous with the funiculus lateralis of the cord; *F.l.m.*, fasciculus longitudinalis medialis; *N. IX. X.*, N. glossopharyngeus et vagus; *N. XII.*, N. hypoglossus; *Nu. d.*, nucleus dentatus; *Nu. n. c. d.*, nucleus N. cochleae dorsalis shown more typically on opposite side of figure; *Nu. n. v. m.*, nucleus N. vestibuli medialis; *Nu. o. a. d.*, nucleus olivaris accessorius dorsalis; *Nu. o. a. m.*, nucleus olivaris accessorius medialis; *Nu. o. i.*, nucleus olivaris inferior; *Nu. t. s.*, nucleus tractus solitarius; *P. f.*, pedunculus flocculi; *Py.*, pyramis; *R. d. n. vest.*, radix descendens N. vestibuli; *St. i. l.*, stratum interolivare lemnisci; 66, plane of longitudinal section No. 66. [NOTE.—This figure has been disproportionately reduced in the reproduction.]

sory impulses cerebralward. The axones of this path\* constitute the main portion of the brachium conjunctivum † (Figs. 426 and 427).

The study of degenerations in pathological cases in human beings (Turner, v. Monakow, Turner and Chareot), and after experimental section of the brachium conjunctivum in ani-

\* Van Gehuchten's *voie cérébello-cérébrale*.

† The brachium conjunctivum was first pictured by Leveille. It was carefully described by Stilling as the *processus cerebelli ad cerebrum*. Stilling's picture is reproduced in Fig. 428. In English books it is usually referred to as the superior cerebellar peduncle.

mals,\* have led to results which have been interpreted in different ways. There is abundance of evidence to show the interdependence of one cerebral hemisphere and the opposite cerebellar hemisphere (1) by way of the brachium conjunctivum, and (2) by way of the brachium pontis. That the connection is

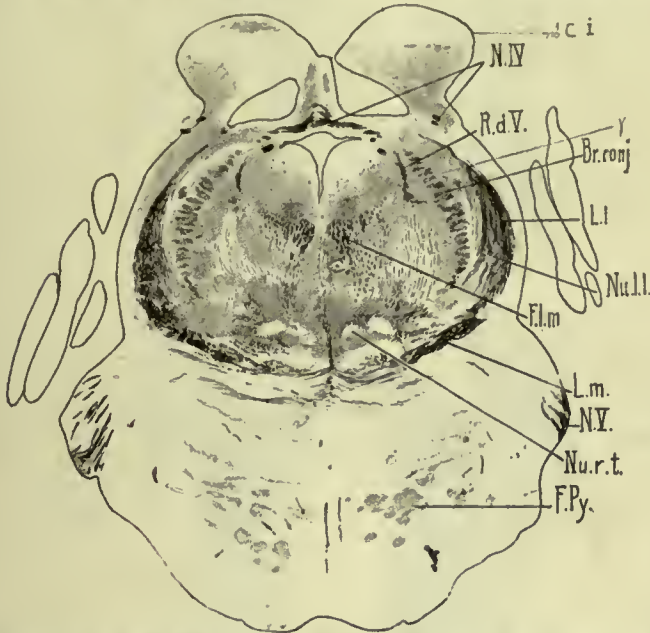


FIG. 426.—Transverse section through isthmus rhombencephali of newborn babe. (Weigert-Pal, series ii, section No. 268.) *Br.conj.*, brachium conjunctivum; *C.i.*, colliculus inferior;  $\gamma$ , nucleus described by Westphal as probably concerned in the origin of the N. trochlearis; *F.l.m.*, fasciculus longitudinalis medialis; *F.Py.*, fasciculi longitudinales [pyramidales]; *L.l.*, lemniscus lateralis; *L.m.*, lemniscus medialis; *N.IV.*, decussatio nervorum trochlearium; *N.V.*, N. trigeminus; *Nu.l.l.*, nucleus lemnisci lateralis; *Nu.r.t.*, nucleus reticularis tegmenti pontis; *R.d.V.*, radix descendens [mesencephalica] nervi trigemini. (Preparation by Dr. John Hewetson.)

\* Forel, A. Tagebl. der Verhandl. der Naturf. in Salzburg, 1881, Sekt. xviii, Sitz., Sept. 19.—von Monakow, C. Stria acustica und untere Schleife. Arch. f. Psychiat. u. Nervenkr., Berl., Bd. xxii (1890), S. 1-26.—Cramer, A. Einseitige Kleinhirnatrophie mit leichter atrophie der gekreuzten Grosshirn-Hemisphäre, nebst einem Beitrag zur Anatomie der Kleinhirnstiele. Beitr. z. path. Anat. u. z. allg. Path., Jena, Bd. xi (1891), S. 39-58.—Mahaim, A. Recherches sur la structure anatomique du noyau rouge et ses connexions avec le pédoncule cérébelleux supérieur. Brux. (1894), F. Hayez, 44 pp., 5 pl., 8vo. Also in Mém. couron. Acad. de roy. méd. de Belg., Brux. (1894), t. xiii.

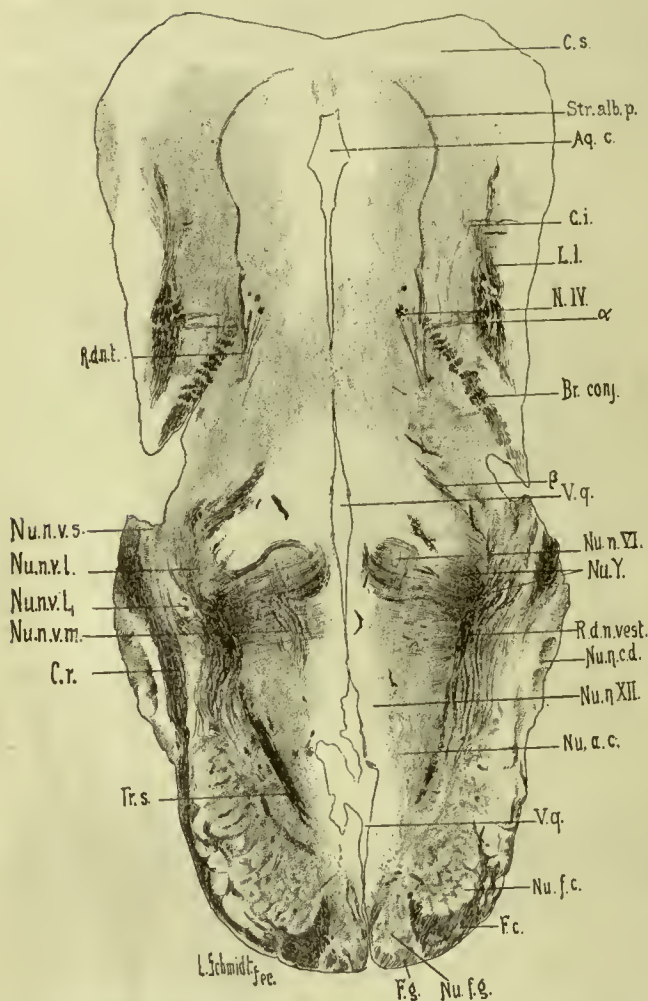


FIG. 427.—Horizontal section through the rhombencephalon and mesencephalon of a newborn babe. Level of nucleus nervi abducentis. (Weigert-Pal staining, series iii, section No. 66.) *α*, fibres running from region of lemniscus lateralis toward region of brachium conjunctivum; *Aq.c.*, aqueductus cerebri; *β*, decussating portion of root of N. trigeminus; *C.s.*, colliculus superior; *C.i.*, colliculus inferior; *Br.conj.*, brachium conjunctivum; *C.r.*, corpus restiforme; *F.c.*, fasciculus cuneatus; *F.g.*, fasciculus gracilis; *L.l.*, lemniscus lateralis; *N.IV.*, N. trochlearis; *Nu.α.c.*, nucleus alae cineræ; *Nu.f.c.*, nucleus funiculi cuneati; *Nu.f.g.*, nucleus funiculi gracilis; *Nu.n.c.d.*, nucleus N. cochleæ dorsalis; *Nu.n.VI.*, nucleus N. abducentis; *Nu.n.v.l.*, nucleus N. vestibuli lateralis (Deiters) pars medialis; *Nu.n.v.l.*, nucleus N. vestibuli lateralis (Deiters) pars lateralis; *Nu.n.v.m.*, nucleus N. vestibuli medialis (Schwalbe); *Nu.n.v.s.*, nucleus N. vestibuli superior (von Bechterew); *Nu.n.XII.*, nucleus N. hypoglossi; *Nu.Y.*, antero-lateral extremity of nucleus N. vestibuli medialis; *R.d.n.t.*, radix descendens [mesencephalica] nervi trigemini; *R.d.n.vest.*, radix descendens N. vestibuli; *Str.alb.p.*, stratum album profundum; *Tr.s.*, tractus solitarius; *V.q.*, ventriculus quartus. (Preparation by Dr. John Hewetson.)



not direct, however, is shown by the fact that after cerebral lesion the changes in the cerebellar peduncles (superior and middle) are those of simple atrophy rather than of actual secondary degeneration. It further appears that after experi-

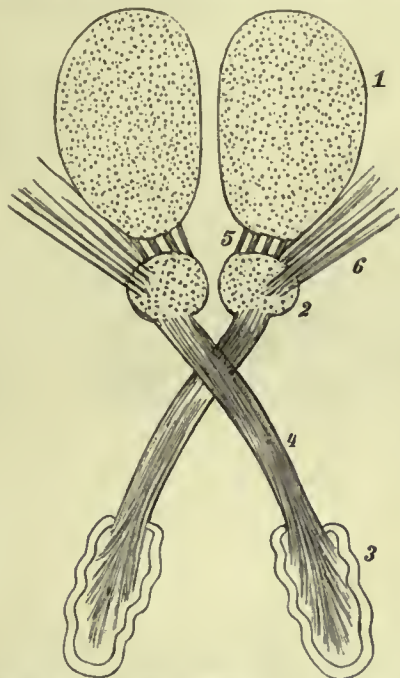


FIG. 428.—Stilling's large and small "scissors" of the brain. (From A. Ranber, *Lehrbuch der Anatomie des Menschen*, V. Aufl., Leipz., 1898, Bd. ii, S. 438, Fig. 387.) 1, thalamus; 2, nucleus ruber; 3, nucleus dentatus cerebelli; 4, brachium conjunctivum; 5, bundle from the nucleus ruber to the thalamus; 6, radiation from the region of the nucleus ruber to the capsula interna.

mental section of, for example, the right brachium conjunctivum, all or nearly all the fibres degenerate through the decussation\* to the red nucleus, and there results not only alteration in the cells of the nucleus dentatus and cerebellar hemisphere on the side of section (Mahaim), but also atrophy of the posterior part of the red nucleus of the opposite side, the cells of the anterior part of the red nucleus and a few scattered cells in the posterior part remaining intact (Forel,

\* The decussation (horseshoe commissure of Wernekinek) is situated just ventral to the inferior colliculus of the corpora quadrigemina (Figs. 429 and 430).

Gudden, Mahaim). While some authorities believe that the fibres of the brachium conjunctivum have their origin in the cerebellum, others think that they originate in those cells of the red nucleus which atrophy on section of the brachium

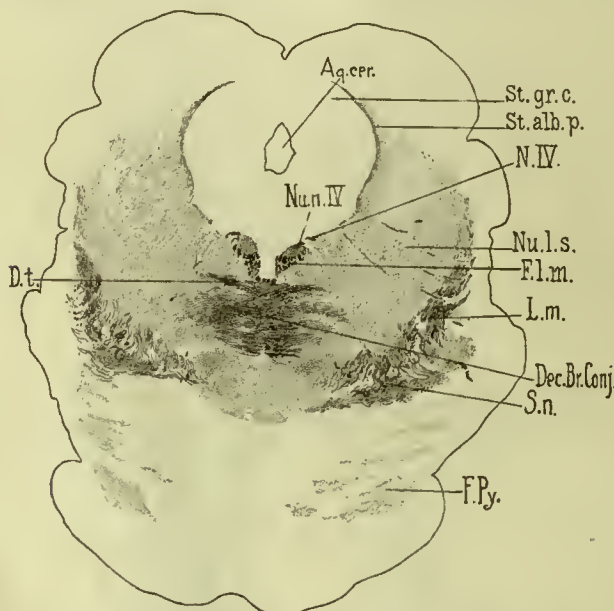


FIG. 429.—Transverse section through mesencephalon of newborn babe. Level of colliculi superiores of corpora quadrigemina. (Weigert-Pal, series ii, section No. 338.) *Aq.cer.*, aqueductus cerebri; *Dec.Br.Conj.*, decussatio brachii conjunctivi; *D.t.*, decussatio tegmenti ventralis (*ventrale Haubenkreuzung* of Forel); *Fl.m.*, fasciculus longitudinalis medialis; *F.Py.*, fasciculi pyramidales in the pars basilaris pontis; *L.m.*, lemniscus medialis; *N.IV.*, N. trochlearis; *Nu.l.s.*, nucleus lateralis superior of Flechsig; *Nu.n.IV.*, nucleus N. trochlearis; *St.alb.p.*, stratum album profundum; *St.gr.c.*, stratum griseum centrale; *S.n.*, substantia nigra. (Preparation by Dr. John Hewetson.)

conjunctivum, and that they do not begin in the cerebellum but end there. The experiments in which one half the cerebellum has been extirpated \* have, on the whole, afforded

\* Vegas, P. Experimentelle Beiträge zur Kenntniss der Verbindungsbahnen des Kleinhirns und des Verlaufs der Funiculi graciles und euneati. Arch. f. Psychiat., etc., Berl., Bd. xvi (1885), S. 200-214.—Marchi, V. Des dégénérationes consécutive a l'extirpation totale et partielle du cervelet. Arch. ital. de biol., Turin, t. vii (1886), pp. 357-362.—Mingazzini, G. Sulle degenerazioni consecutive alle estirpazioni emicerebellari. Ricerche n. lab. di anat. norm. d. r. Univ. di Roma, vol. iv (1894), pp. 73-124.—Ramón y Cajal, S. Algunas contribuciones al conocimiento de los ganglios del eneefalo.

no more exact conclusions, though Marchi asserts that the fibres of the brachium conjunctivum do not undergo complete decussation, since he can follow a small bundle, past the region of crossing, directly to the thalamus of the same side. This uncrossed bundle of Marchi appears to be reinforced to a slight extent by the medullated axones of cells situated in the part of the nucleus ruber designated by Mahaim as the "nucleus minimus" (von Bechterew). Ferrier and Turner describe complete degeneration of the brachium conjunctivum after extirpation of the lateral lobe of the cerebellum.

Von Kölliker\* interprets the findings in the cases of secondary degeneration above referred to differently than do some of those who have carried out the experiments. He believes that the majority of the fibres of the brachium conjunctivum arise in the cerebellum, run cerebellofugally, and nearly all undergo decussation; part of them end in the red nucleus of the opposite side, especially in its posterior part (that region which atrophies after section of the brachium conjunctivum); part, on the other hand, go through the red nucleus, without ending in it, to join the bundle of fibres lateral from it and to enter the area in the hypothalamic region, known as Forel's "Feld H," to be referred to later. Held† believes that the majority of the fibres of the brachium conjunctivum arise in the nucleus dentatus, a view quite in accord with the observations of Menzel, Arndt, and Dejerine, which prove that, in lesions of the cerebellum involving only the cortex and subjacent white matter, no marked alterations in the brachium conjunctivum or in the red nucleus result.

---

ii. Ganglios cerebelosos vi. Conexiones distantes de los celulas de Purkinje. *Anales de la Sociedad española de historia natural*, Madrid, 1894.—Russell, J. S. R. Degenerations Consequent on Experimental Lesions of the Cerebellum. *Proe. Roy. Soc., Lond.*, vol. lvi (1894), pp. 303-305.—Ferrier, D., and W. A. Turner. A Record of Experiments Illustrative of the Symptomatology and Degenerations following Lesions of the Cerebellum and its Peduncles and related Structures in Monkeys. *Phil. Tr. Lond. Soc.*, vol. clxxxv (1894), B., pp. 719-778.—Thomas, A. *Le cervelet: étude anatomique, clinique et physiologique*. 8vo, Paris, 1897.

\* *Op. cit.*, S. 450.

† Held, A. Beiträge zur feineren Anatomie des Kleinhirns und des Hirnstammes. *Arch. f. Anat. u. Physiol., Anat. Abth.*, Leipz. (1893), S. 435-446.

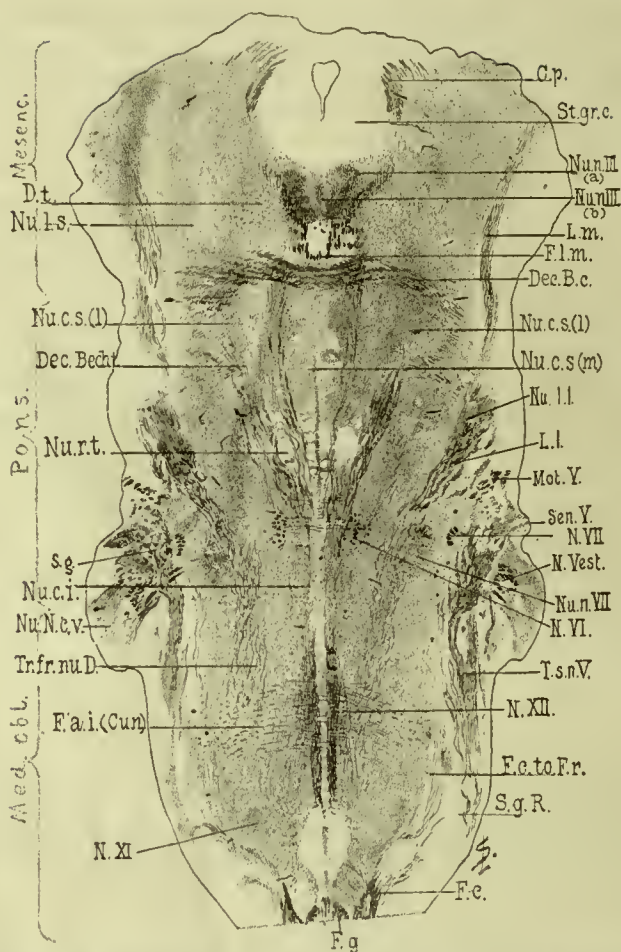


FIG. 430.—Horizontal section through the medulla, pons, and midbrain of a newborn babe. Weigert-Pal staining. Level of decussatio brachii conjunctivi and of nucleus reticularis tegmenti. (Series iii, section No. 108.) *Cp.*, commissura posterior cerebri; *Dec.B.c.*, decussatio brachii conjunctivi; *Dec.Becht.*, commissure between Bechterew's nuclei; *Dt.*, fibres to decussatio tegmenti; *E.a.i.(Cun.)*, fibre arcuate interne from the nucleus funiculi cuneati; *Ec.*, fasciculus cuneatus; *Ec.to.Fr.*, bundle from fasciculus cuneatus to formatio reticularis; *E.g.*, fasciculus gracilis; *Fl.m.*, fasciculus longitudinalis medialis; *L.m.*, lemniscus medialis; *L.l.*, lemniscus lateralis; *Mot.V.*, radix motorius N. trigemini; *N.VII*, radix N. facialis, pars secunda; *N.Vest.*, radix N. vestibuli; *N.VI.*, radix N. abducentis; *N.VII*, radix N. hypoglossi; *N.XI*, radix N. accessorii; *Nun.III.(a)*, nucleus N. oculomotorii, pars lateralis; *Nun.III.(b)*, nucleus N. oculomotorii, pars impar; *Nu.c.s.(l)*, nucleus centralis superior, pars lateralis; *Nu.c.s.(m)*, nucleus centralis superior, pars medialis; *Nu.l.l.*, nucleus lemnisci lateralis; *Nun.VII*, nucleus N. facialis; *Nu.N.c.v.*, nucleus N. cochlee ventralis; *Nu.c.i.*, nucleus centralis inferior; *Nu.r.t.*, nucleus reticularis tegmenti; *Nu.l.s.*, nucleus lateralis superior; *St.gr.c.*, stratum griseum centrale; *Sen.V.*, sensory root of N. trigemini; *S.g.*, substantia gelatinosa Rolandi; *Tr.fr.nu.D.*, tract from Deiters' nucleus to the spinal cord; *T.s.n.V.*, tractus spinalis N. trigemini. (Preparation by Dr. John Hewetson.)



In a case reported by von Monakow,\* in which there was a defect in the right cerebral hemisphere, and also a large defect in the left cerebellar hemisphere, no marked secondary degeneration occurred in the brachium conjunctivum, but only secondary atrophy (diminution in calibre of the individual fibres). It is of great importance to note that in this case von Monakow explicitly tells us that the corpus dentatum was not injured. He further believes that the fibres of the brachium conjunctivum which extend beyond the red nucleus probably arise in the opposite cerebellar hemisphere, and end free in the gray matter of the tegmentum. Von Monakow is of the opinion, therefore, that the brachium conjunctivum contains both centrifugal and centripetal fibres, and that it is preferably the latter which undergo atrophy of the second order after defects in the pallium, so that any direct connection of the brachium conjunctivum with the cortex can be safely denied.

Thomas† followed by Marchi's method degenerated fibres not only to the nucleus ruber, but also beyond it to the ventral part of the thalamus. No fibres could, however, be traced beyond the thalamus to the nucleus lentiformis or to the pallium. Mirto‡ makes the fibres of the brachium conjunctivum end chiefly in the contra-lateral nucleus ruber, but partly also in the ventro-lateral region of the thalamus. According to Flechsig, some of the fibres go to the nucleus lentiformis by way of the dorsal white matter of the nucleus hypothalamicus (corpus Luysii), otherwise known as *Feld<sub>2</sub>* of A. Forel. He is of the opinion further that a certain number of the fibres pass out to the cerebral cortex, terminating there in the region of the gyri centrales. The upper portion of the somæsthetic path to the cerebrum by way of the cerebellum will be described more fully in Chapter L.

A study of the stages of myelinization of the brachium conjunctivum makes it seem extremely probable that fibres of different systems are contained in this bundle. Thus, von

---

\* von Monakow, C. Archiv. f. Psychiat. u. Nervenkr., Berl., Bd. xxvii (1895).

† *Op. cit.*

‡ Mirto, Sulle degenerazioni secondari cerebello-cerebrali. Arch. per le sc. med., Torino, vol. xx (1896), p. 19.

Bechterew\* distinguished easily four distinct bundles which, in the middle of the pons, as seen in cross section, present a typical topographical arrangement (Fig. 431). Of these, the first to become medullated (foetus 28 cm. long) is that which in

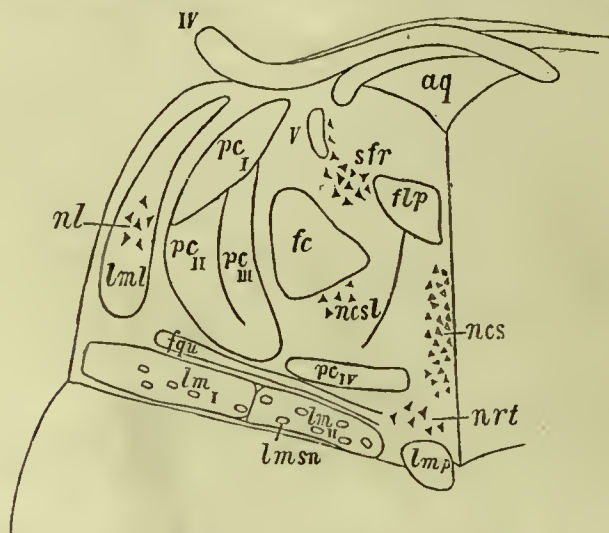


FIG. 431.—Schematic cross section through the pars dorsalis pontis at its junction with the isthmus rhombencephali. (After W. von Bechterew, *Die Leitungsbahnen im Gehirn und Rückenmark*, Deutsch von R. Weinberg, II. Aufl., Leipz. (1899), S. 236, Fig. 198.) *aq*, aqueduct cerebri; *flp*, fasciculus longitudinalis medialis; *fc*, fasciculus centralis tegmenti (*centrale Haubenbahn*); *fqu*, fibres from the region of the colliculus inferior to the nucleus reticularis tegmenti; *IV*, N. trochlearis; *lm*, fibres of the lemniscus medialis from the contra-lateral nucleus funiculi euneati; *lmsn*, fibres of the lemniscus medialis from the contra-lateral nucleus funiculi gracilis; *lmp*, von Bechterew's medial accessory lemniscus; *lmsn*, von Bechterew's scattered bundles of the lemniscus; *lml*, lemniscus lateralis; *ncs*, nucleus centralis superior, pars medialis; *ncsl*, nucleus centralis superior, pars lateralis; *nl*, nucleus lemnisci lateralis; *nrt*, nucleus reticularis tegmenti pontis; *pc*, dorsal, *pc<sub>m</sub>*, middle, *pc<sub>iv</sub>*, medial, *pc<sub>v</sub>*, ventral bundle of the brachium conjunctivum; *pc<sub>v</sub>* represents the commissure between the nuclei superiores nervorum vestibulorum; *sfr*, substantia ferruginea, *V*, radix descendens (mesencephalica) nervi trigemini.

a section through a plane corresponding to the middle of the pons lies in the most ventral part of the brachium conjunctivum (Fig. 431, *pc<sub>v</sub>*, and Fig. 432, 46). This bundle has nothing to do with the cerebellum, but is the bundle above mentioned which forms a commissure between the nuclei nervorum vestibulorum superiores of the two sides. Of the three other

\* von Bechterew, W. *Die Leitungsbahnen im Gehirn und Rückenmark*, Leipz. (1894), S. 135.

bundles, the most dorsal one (Figs. 431, *pc<sub>d</sub>*, and 432, 45) is medullated in fetuses about 33 cm. long. This bundle appears to be connected with the nucleus fastigii and with the cortex of the vermis (von Bechterew). Its fibres pass to the decussation, cross to the opposite side, and are interrupted in the red nucleus, since no fibres are medullated beyond at this stage.

The third bundle (Fig. 431, *pc<sub>m</sub>*), medullated in fetuses 35 to 38 cm. long), lies between the dorsal and ventral bundles (Fig. 432, 39). In the cerebellum it is related especially to the nucleus globosus and the nucleus emboliformis. Some of its fibres appear to be related directly with the cortex of the vermis superior. The fibres of this bundle decussate with the other fibres of the brachium conjunctivum, become partly mingled with the fibres of the dorsal bundle, and come in relation anteriorly to the cells of the red nucleus.

The fourth bundle (Fig. 431, *pc<sub>m</sub>*) (beginning to medullate in the new-born babe) consists mainly of very fine fibres which lie partly in among the fibres of the other bundles, partly medialward from them. In the cerebellum the fibres of this bundle appear to stand in relation to the cortex of the cerebellar hemispheres, and in part to the nucleus dentatus. The fibres of the bundle decussate with the other fibres of the brachium conjunctivum, and in front are related to the red nucleus.

We fortunately possess a certain amount of positive information concerning the origin from cells, of the axones of the fibres of the brachium conjunctivum. This has been gained by the application of Golgi's method, especially by Ramón y Cajal\* and Martin.†

Ramón y Cajal finds that certain of the fibres of the brachium conjunctivum in the mouse arise from the nucleus dentatus. He emphasizes the fact that by no means all the ascending fibres come from the nucleus dentatus, some having another origin, perhaps the cerebellar cortex. This view has been supported by studies made with Marchi's method, and Ramón y Cajal has shown that axones of Purkinje cells go directly into the superior cerebellar peduncle. All the thick fibres, however,

\* Ramón y Cajal, S. Beitrag zum Studium der Medulla Oblongata, etc., Leipz. (1896), S. 17; also Ganglions cérébelleux. Bibliogr. anat., Par., t. iii (1895), pp. 33-42.

† Martin, P. In Franek's Handbuch der Anatomie der Haustiere, Dritte Auflage, Bd. ii, Stuttgart (1894), S. 278.

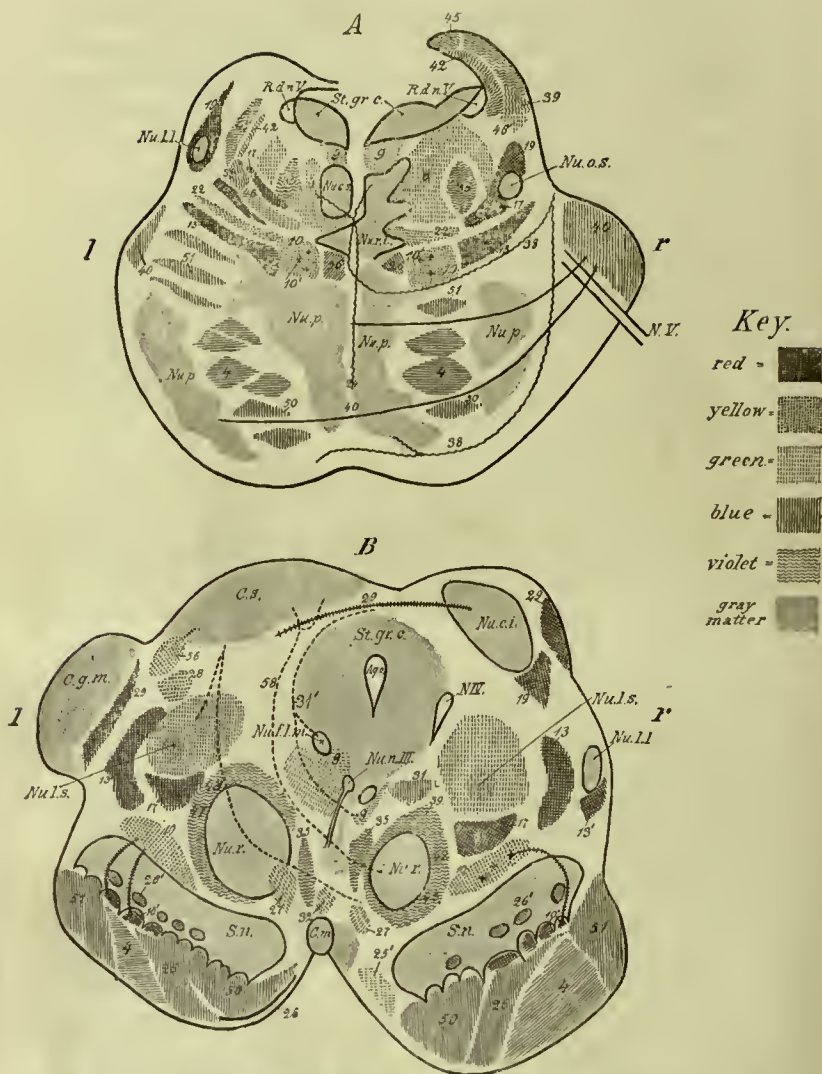


FIG. 432.—A, transverse section through the posterior half of the pons. The left half of the illustration corresponds to the anterior, the right half to the posterior portion of the pons. (After W. von Bechterew, 1894, somewhat modified.) Nu.c.s., nucleus centralis superior; Nu.l.l., nucleus lemnisci lateralis; Nu.o.s., nucleus olivaris superior; Nu.p., nuclei pontis; Nu.r.t., nucleus reticularis tegmenti; N.V., radix N. trigemini; R.d.n.V., radix descendens (mesencephalica) nervi trigemini; St.gr.c., stratum griseum centrale. Red—13, fibres of the lemniscus medialis pertaining to the nucleus funiculi cuneati; 10, scattered bundles in the lemniscus medialis; 17, region of scattered fibres which develop late in the lateral field of the formatio reticularis; 19, lemniscus lateralis. Yellow—10, fibres of lemniscus medialis originating in



which go into the brachium conjunctivum arise, he states, from the nucleus dentatus of the same side.\*

The cells of the nucleus dentatus are large, triangular, or stellate, and exhibit uneven dendrites. The thick axones arise either from the cell body or from one of the dendrites, give off one or two collaterals inside the nucleus dentatus, and pass over into the brachium conjunctivum of the same side (Fig. 433). In some cases it has been possible to follow the axone even outside the cerebellum, not only in longitudinal sections, but also in transverse sections.

nucleus funiculi gracilis; 22, fibres from the region of the colliculus inferior to the nucleus reticularis tegmenti and to the pons. *Violet*—35, fibres of fasciculus centralis tegmenti (*centrale Haubenbahn*); 24, fibres passing by the raphe from the nuclei pontis to the formatio reticularis grisea; 28, fibres of the spinal bundle (von Bechterew) of the brachium pontis; 45, 39, 42, different bundles in the brachium conjunctivum. *Blue*—4, fasciculi longitudinales (pyramidales); 26, fibres of medial accessory bundle in lemniscus medialis (to motor nuclei of cerebral nerves); 46, fibres of cerebral bundle of brachium pontis; 50, frontal cerebrocortico-pontal path; 51, temporo-occipital cerebrocortico-pontal path. *Green*—9, fasciculus longitudinalis medialis; 8, fibres which represent the pontal continuation of the fasciculus lateralis proprius of the spinal cord; 46, commissural bundle lying ventradward from the brachium conjunctivum.

B, transverse section through the brain stem; level of pedunculi cerebri. The right half illustrates the level of the colliculus inferior, the left half that of the colliculus superior. (After W. von Bechterew, 1894, somewhat modified.) *Aq.e.*, aqueductus cerebri; *C.g.m.*, corpus geniculatum mediale; *C.m.*, corpus mammillare; *C.s.*, colliculus superior; *N.II'*, radix N. trochlearis; *Nu.c.i.*, nucleus colliculi inferioris; *Nu.f.l.m.*, nucleus fasciculi longitudinalis medialis or nucleus commissure posterioris (*oberer Oculomotoriuskern* of Darkschewitsch); *Nu.l.l.*, von Bechterew's *Corpus parabigemina*; *Nu.l.s.*, nucleus lateralis superior of Flechsig (*nucleus innominatus* of von Bechterew); *Nu.n.III*, nucleus nervi oculomotorii; *Nu.r.*, nucleus ruber; *S.n.*, substantia nigra; *St.gr.c.*, stratum griseum centrale. *Red*—19, fibres of lemniscus lateralis which enter colliculus inferior; 29, fibres of brachium quadrigeminum inferius from the colliculus inferior of the same and of the opposite side; 13, fibres of the lemniscus medialis originating in the nucleus funiculi cuneati; 13', fibres of the lemniscus medialis going to the corpora quadrigemina; 10', scattered bundles of the lemniscus which go over into the basis pedunculi; 17, region of the scattered fibres (late to develop) of the formatio reticularis. *Yellow*—10, fibres of lemniscus medialis from the nucleus funiculi gracilis; 28, fibres from the nucleus colliculi inferioris to the thalamus (according to von Bechterew); 56, fibres from the colliculus superior to the cerebral cortex. *Violet*—39, 42, 45, fibres of the brachium conjunctivum before their entrance into the red nucleus; 47, 48, fibres from the red nucleus to the nucleus lentiformis, the thalamus, and the cerebral cortex (these are the radiations of the red nucleus); 35, fibres of the fasciculus centralis tegmenti (*centrale Haubenbahn*). *Green*—9, fasciculus longitudinalis medialis; 31, fibres of the dorsal part of the commissura posterior; 31', fibres of the ventral part of the commissura posterior; 27, fasciculus retroflexus Meynerti; 32, fasciculus thalamomammillaris (Vieq d'Azyri); 23', fasciculus pedunculomammillaris pars basilaris (pedunculus corporis mammillaris); 58, fibres from the substantia grisea of the colliculus superior to the region of the nucleus ruber of the opposite side. *Blue*—4, fasciculi longitudinales (pyramidales); 50, fibres of frontal cerebrocortico-pontal path (medial bundle in basis pedunculi); 51, fibres of occipito-temporal cerebrocortico-pontal path (lateral bundle in basis pedunculi); 26, fibres of the accessory bundle of the lemniscus; 26', fibres connecting the substantia nigra with the cerebral hemispheres.

\* *Op. cit.*, S. 20.

A very important observation, which we owe to Ramón y Cajal, has been made in sagittal and lateral sections. At the point where the fibres of the brachium conjunctivum leave the

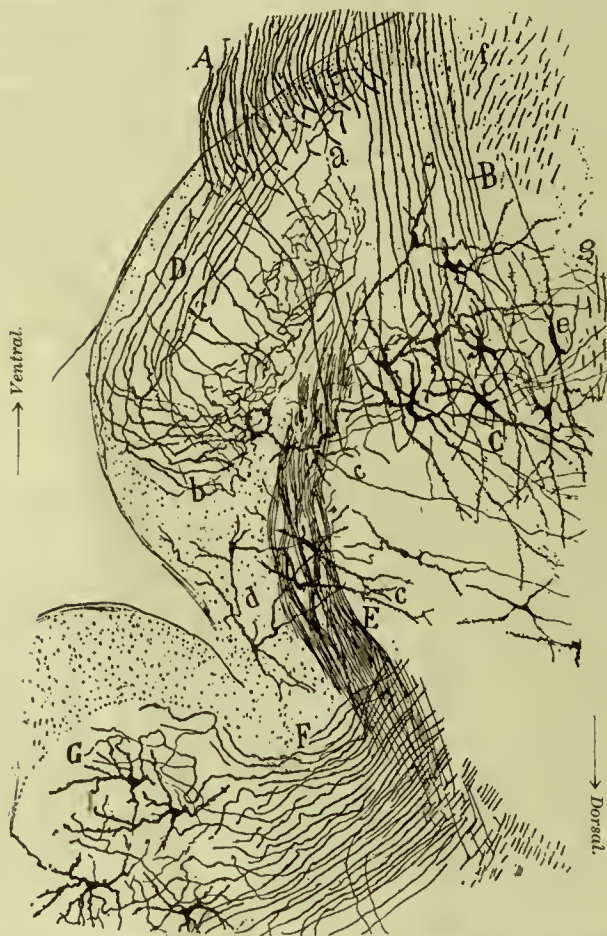

FIG. 433.—Frontal section through the cerebellum and pons of a foetal mouse. (After S. Ramón y Cajal, *Beitrag zum Studium der Medulla Oblongata*, etc., Bresler, Leipz., 1896, S. 19, Fig. 5.) A, sensory root of N. trigeminus; B, motor root of N. trigeminus; C, nucleus motorius princeps N. trigemini; D, ascending limbs of bifurcation of sensory axones of N. trigeminus; E, descending bundle from brachium conjunctivum; F, brachium conjunctivum; G, nucleus dentatus; a, bifurcating sensory axones of N. trigeminus; b, terminals of ascending limbs of bifurcation; c, cells in among fibres of descending bundle from brachium conjunctivum; e, cell bodies of lower motor neurones in the nucleus motorius princeps N. trigemini; g, axones of the lateral sensory central trigeminal and glossopharyngeal path which give off collaterals to this nucleus.

cerebellum and go over into the dorsal and lateral surface of the pons, many of the fibres give off at right angles a stout collateral, which passes in a descending direction. At times the division resembles more a bifurcation of the axone (Fig. 434). This bundle of collaterals arising from the fibres of the brachium conjunctivum leaves the brachium and descends, forming a fasciculus cerebellaris lateralis descendens (Ramón y Cajal's *laterales absteigendes Kleinhirnbündel*).

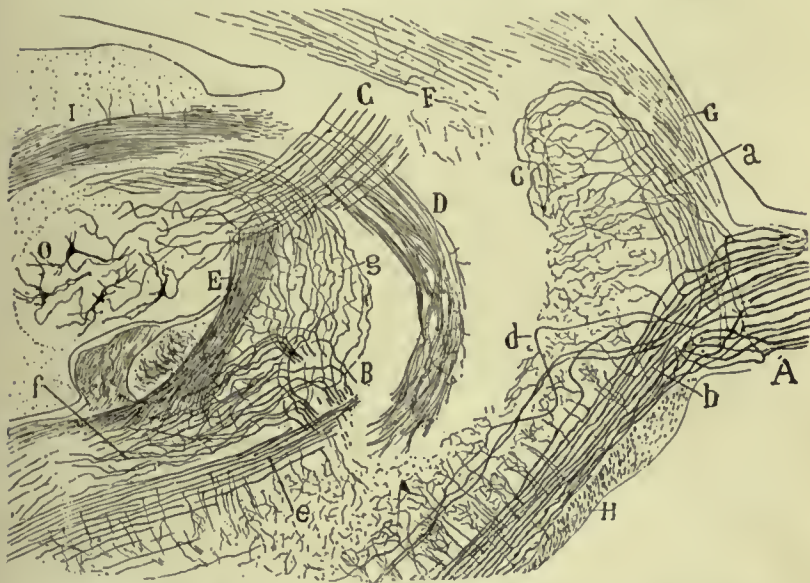


FIG. 434.—Lateral sagittal section through the pons and cerebellum of a fetal mouse, showing the sensory portion of the N. trigeminus. (After S. Ramón y Cajal, *Beitrag zum Studium der Medulla Oblongata*, etc., Leipz., 1896, S. 4, Fig. 1.) A, portio major or sensory root of N. trigeminus; the individual axones dividing into an ascending (a) and a descending limb (b); c, terminal branches of ascending limb; d, root fibres which sink into the depth; e, dorsal part of descending portion of sensory root; B, bifurcation of axones of N. vestibuli, the ascending limbs (g) going to the cerebellum, the descending limbs (f) going downward to the medulla oblongata; C, brachium conjunctivum; D, fasciculus cerebellaris descendens; E, corpus restiforme; F, lemniscus lateralis; H, corpus trapezoideum; O, nucleus dentatus.

This descending cerebellar bundle consists of several small bundles arranged more or less in the form of a plexus, and separated from one another by cells. He has been able to follow these small bundles in lateral sagittal sections along the tractus spinalis nervi trigemini, in relation to which it is medi-



ally placed. In its course collaterals are given off to adjacent regions of the *formatio reticularis*. In transverse sections the descending cerebellar bundle of Cajal is seen to run at first forward and ventralward, outside the principal motor nucleus of the trigeminus, medial from the upper part of the *substantia gelatinosa*. Soon after it has passed medial to the latter it turns to run longitudinally, and forms a large bundle of longitudinal fibres in the *formatio reticularis grisea* just medial to the *substantia gelatinosa* of the *tractus spinalis nervi trigemini*. In its transverse course, while it passes lateral from the principal motor nucleus of the trigeminus, it gives off some collaterals which branch in among the cells of this nucleus, and, further on, following the longitudinal course of the medulla, it gives off collaterals to the nucleus *nervi facialis*, the cells in the *formatio reticularis grisea*, and perhaps also to the nucleus *ambiguus* and to the nucleus *nervi abducentis*. Ramón y Cajal was unable to follow the course of this bundle below the olive, as his set of serial sections unfortunately stopped at this point, although the path was distinctly impregnated and evidently went farther. He concludes that this bundle has nothing to do with the descending cerebellar path described by Marchi. He believes that at least a part of its fibres have been described by von Bechterew as the cerebellar root of the trigeminus, by Edinger as the direct sensory cerebellar path of the trigeminus, and by Cramer as a central sensory path of the trigeminus.

Martin has observed, by Golgi's method, axones passing from cells in the red nucleus through the decussation to the *brachium conjunctivum* of the opposite side. These axones give off collaterals before and after decussation to the *formatio reticularis*. These possibly correspond to the fibres of Edinger's *tractus tegmento-cerebellaris* and to the *cerebellopetal* degeneration observed by Mendel\* and by von Bechterew.† For the structure of the nucleus *dentatus* in the new-born babe and in

---

\* Mendel, E. (cited by v. Bechterew). *Neurol. Centralbl.*, Leipz. (1885).

† v. Bechterew, W. Ueber syphilitische disseminirte, cerebro-spinale sklerose nebst Bemerkungen ueber die secundäre Degeneration der Fasern des Vorderkleinhirnschenkels des centralen Haubenbündels und der Schleifenschicht. *Arch. f. Psychiat.*, etc., Berl., Bd. xxviii (1896), S. 742-772.



adult human beings, the reader is referred to the research of Lugaro.\*

It is obvious that while by far the majority are cerebellofugal, in the brachium conjunctivum there are axones passing in both directions. The topographical distribution of these axones remains yet to be worked out. It is very important that this be determined for each of the four bundles which can so easily be isolated by the study of myelinization.

In passing it should be mentioned that a Russian investigator, Klimoff,† has demonstrated, by Marchi's method, fibres connecting the cerebellum of one side by way of the brachium conjunctivum with the contra-lateral nucleus nervi oculomotorii.

There are cerebellofugal paths also in the brachium pontis (middle cerebellar peduncle) but the evidence thus far is against the view that these are cerebropetal in nature. (Cf. Chapters LXIII and LXIV.)

---

\* Lugaro, E. Sulla struttura del nucleo dentato del cervelletto nell'uomo. *Monitore. zool. ital.*, Firenze, vol. vi (1895), pp. 5-12.

† Klimoff, I. A. On the Connection of the Cerebellum with the Nucleus of the N. oculomotorius. *Vrach*, St. Petersburg, vol. xvii (1896), p. 1013.

4. Central Sensory Axones passing into or through the Cerebral Peduncle, and the Terminations of such Axones.

CHAPTER XLVII.

ON THE STRUCTURE OF THE HYPOTHALAMIC REGION AND THE COURSE OF THE LEMNISCUS MEDIALIS.

Centripetal fibres which forward bodily impulses through the cerebral peduncle toward the somæsthetic area of the cortex—Forel's studies (1887)—*Feld II*—The zona incerta—The nucleus hypothalamicus or Luys' body—The nuclei of the thalamus—von Kölliker's studies—Researches of Nissl—Investigations of von Monakow—Tschermak's studies.

The lemniscus or fillet—Subdivisions—Lemniscus medialis—Lemniscus superior—Various neurone systems in the lemniscus. The "cortical lemniscus," direct and indirect—View of Flechsig and Hoesel—View of von Monakow and Mahaim—Other studies of lemniscus—Demonstration of direct cortical lemniscus in cats by Marchi's method (Tschermak).

ALL the centripetal paths carrying impulses toward the cerebrum must pass through the cerebral peduncle. We have seen that the bundles of fibres concerned in carrying impulses from the bodily sense organs (as opposed to those of special sense) may include the following: (1) The lemniscus medialis; (2) the fasciculus longitudinalis medialis; (3) certain longitudinal bundles of the formatio reticularis; and (4) the brachium conjunctivum and some of the axones arriving from the nucleus ruber which pass cerebralward. These various fibres (axones of central neurones) pass through the pedunculus cerebri (mainly or entirely through the tegmentum, not through the pes, or basis) to reach the diencephalon, where most of them in all probability terminate in the hypothalamus, in the thalamencephalon, or in the nucleus lentiformis; a few of the axones may pass through the diencephalon, without terminating in it,

so as to reach the cerebral cortex directly by way of the internal capsule and the corona radiata (*directe Rindenschleife* and a part of the *Haubenstrahlung* of the Germans). The fibres which terminate in the hypothalamus (mainly in the nucleus hypothalamicus) and in the thalamus (mainly in its ventro-lateral portion) apparently do so in conduction relation with the cell bodies and dendrites of neurones of the third (and often doubtless of a higher) order, the axones of which run out through the retro-lenticular portion of the occipital limb of the internal capsule and through the corona radiata to reach the cerebral cortex. The region of the cortex in which the axones of the general sensory conduction path here considered terminate, I have designated as the somæsthetic area of the cortex.\* It includes, in all probability, the central gyri, the posterior portions of the three frontal gyri, the lobulus paracentralis and perhaps in part the gyrus cinguli (Flechsig) and portions of the parietal lobe behind the posterior central gyrus (von Monakow). In addition, doubtless, fibres of this sensory path terminate in the corpus striatum.

The study of the upward continuations of the sensory conduction paths of the tegmentum is fraught with extreme difficulties, especially in man, in whom the brachium conjunctivum and red nucleus are colossally developed in comparison with the other tegmental structures. It has been attempted by purely anatomical methods; by the method of secondary degenerations, and by the embryological method. Thus far but little help has been gained in this connection by the use of Golgi's method, but a beginning has been made. The application of the method of Nissl, though full of promise, has as yet been limited.

The purely anatomical studies, extending the earlier researches of Reil, Burdach,† Arnold, Gratiolet,‡ and Luys,\* have been carried out chiefly with the aid of serial sections by Mey-

\* I wish to thank Prof. Gildersleeve, of the Johns Hopkins University, for suggesting this term as a suitable English equivalent for Munk's *Körper-fühlsphäre*.

† Burdach, K. F. *Vom Baue und Leben des Gehirns*. Leipzig, 1819-'26.

‡ Leuret et Gratiolet. *Anatomie comparée du système nerveux*. Paris, 1839-57.

\* Luys, J. *Recherches sur le système nerveux cérébrospinal*. Paris, 1865; *Iconographie photographique des centres nerveux*. Paris, 1873.

nert, \* Forel, † Ganser, ‡ Dejerine, # von Kölliker, || Mills, ^ and von Monakow. ◇

Forel, in his exhaustive description of the tegmental region, attempts to follow from the pons and midbrain the main longitudinal paths upward into the tegmentum and hypothalamic region. His conclusions regarding the various bundles which we have seen may be concerned in the carrying of impulses from the bodily sense organs—namely, the fasciculus longitudinalis medialis, certain longitudinal bundles of the formatio reticularis, the medial lemniscus and the brachium conjunctivum, and the fibres coming out of the red nucleus may here be referred to.

As regards the fibres of the fasciculus longitudinalis medialis, Forel † found that the majority of the coarse fibres and some of the fine fibres reaching the level of the posterior commissure of the brain enter into it. The majority of the finer fibres, however, went farther, passing through the fasciculus retroflexus Meynerti to become lost in the gray matter of the tegmentum, mingling with fibres from the formatio reticularis, and perhaps reaching the area in the hypothalamic region designated by Forel as *Feld H<sub>2</sub>* (*vide infra*).

The longitudinal bundles of the formatio reticularis are much confused in the midbrain by the decussatio brachii con-

\* Meynert, Th. Vom Gehirne der Säugethiere. Article in Stricker's Handbuch der Lehre von den Geweben, etc., Leipz. (1871-'72); also Psychiatry, translated into English by B. Sachs. New York, 1885.

† Forel, A. Beiträge zur Kenntniss des Thalamus opticus und der ihn umgebenden Gebilde bei den Säugethiern. Sitzungsber. d. k. Akad. d. Wissensch., Bd. lxvi, Wien (1872), S. 25-58.—Untersuchungen ueber die Haubenregion und ihre oberen Verknüpfungen im Gehirne des Menschen und einiger Säugethiere, mit Beiträgen zu den Methoden der Gehirnuntersuchung. Arch. f. Psychiat. u. Nervenkr., Berlin, Bd. vii (1877), S. 393.

‡ Ganser, S. Vergleichend-anatomische Studien ueber das Gehirn des Maulwurfs. Morphol. Jahrb., Leipz., Bd. vii (1882), S. 591-725.

# Dejerine, J. Anatomie des centres nerveux. Paris, 1895.

|| von Kölliker, A. *Op. cit.*, S. 428.

^ Mills, C. K. Sections of the Cerebral Ganglia, with Remarks on their Anatomy and Lesions. Tr. Path. Soc. Phila. (1879-'81), vol. x (1882), pp. 179-182.

◇ von Monakow, C. Experimentelle u. pathologisch-anatomische Untersuchungen ueber die Haubenregion, den Sehhügel und die Regio subthalamica, nebst Beiträgen zur Kenntniss früh erworbener Gross- und Kleinhirndefecte. Arch. f. Psychiat. u. Nervenkr., Berl., Bd. xxvii (1895), S. 1, 386.

‡ *Op. cit.*, S. 417.



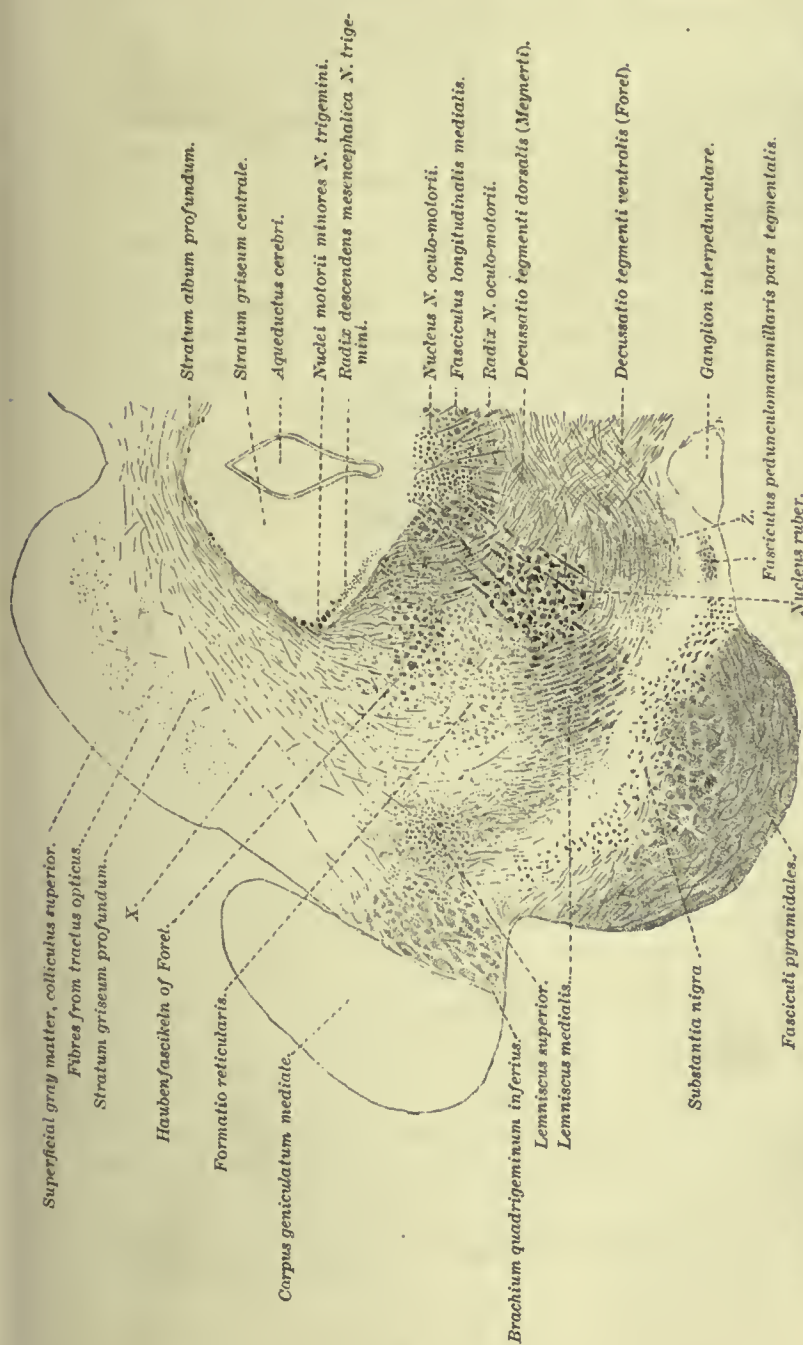


FIG. 435.—Left half of transverse section of the brain stem of a dog at about the level of the middle of the superior colliculus. (After A. Forel, Arch. f. Psychiat., Bd. vii, 1877, Taf. viii, Fig. 23.) Z, field containing bundles cut obliquely, which represent the continuation of the fibres of the decussatio tegmenti ventralis; X, fibres which run from the stratum album profundum to the region of the lemniscus superior, or of the brachium quadrigeminum inferius, and which Meynert designated as *Schleife aus dem oberen Zehnfeld*.

junctivi. They become displaced dorsally and laterally, and above the red nucleus pass apparently into the diffusely limited oval *Feld II*. A special mass of fibres of the formatio reticularis, designated as *Haubenfascikeln* or fasciculi tegmenti by Meynert, and especially well seen in the dog (Fig. 435), pass upward and apparently go directly to the most ventral parts of the thalamus.

The fibres from the brachium conjunctivum and from the red nucleus were especially studied by Forel. He describes particularly the white matter of the dorsal surface of the red nucleus and that of the lateral surface of the red nucleus. He

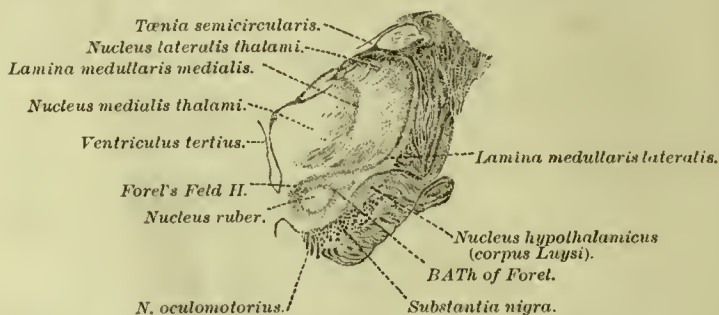


FIG. 436.—Frontal section through the human brain stem. (After A. Forel, Arch. f. Psychiat., Berl., Bd. vii, 1877, Taf. vii, Fig. 10.) BATH, large bundle of fibres which, coming from the nucleus ruber and its capsule, runs upward, lateralward, and dorsalward to the ventral part of the thalamus to the reticular layer, to the lamina medullaris lateralis, etc., where the fibres become so interwoven with others that they can not be followed farther; Forel's Feld II, dorsal white matter of regio subthalamica.

believes that the dorsal white matter consists of fibres from the brachium conjunctivum, from the fasciculus longitudinalis medialis, and from the formatio reticularis inextricably mixed.\* On the lateral surface of the red nucleus he describes a mass of fibres which passes obliquely lateralward and dorsalward toward the cerebrum, converging to form a bundle which he calls BATH (Fig. 436), and which he thinks, in the main, enters into the ventral part of the thalamus, there again to break up into secondary bundles which appear to help to form not only the lamina medullaris lateralis, but also other laminae medullares and radial bundles of the thalamus.† Lateralward this bundle

\* If one studies serial sections through the brain of the new-born babe, all of these bundles can be distinctly recognized.

† *Op. cit.*, S. 425.

touches the zona incerta, while dorsalward, somewhat above the red nucleus, it fuses with *Feld II*.

Forel's *Feld II* would therefore be made up mainly of fibres from the capsule of the red nucleus, partly of fibres passing through the red nucleus from below, partly from fibres which represent medullated axones from the cells of the red nucleus itself. There are contained in this *Feld II*, then, according to Forel, fibres from the brachium conjunctivum, from the formatio reticularis, from the fasciculus longitudinalis medialis, and from the red nucleus.

As regards the main portion of the lemniscus, Forel describes it as bending dorsalward and lateralward at a level corresponding to the lower end of the red nucleus. It passes close to and parallel with the bundle which he calls *BATH* and runs in a direction toward the pulvinar, interweaving with the *Haubenfaszikeln*, and becomes lost in the gray matter of the tegmentum, so that its fibres can not be further followed.

Very convenient for purposes of description will be found the division of the hypothalamus (regio subthalamica)\* adopted by Forel. He recognizes three layers: (1) A dorsal layer of white matter; (2) a middle layer, the so-called zona incerta, which laterally is continuous with the reticular zone of the thalamus; and (3) a ventral layer, somewhat more laterally placed, the so-called Luys' body, now known as the nucleus hypothalamicus (corpus Luysi) (Fig. 437).

The dorsal layer of white matter just cerebralward from the red nucleus consists of an area of very fine medullated fibres which Forel designates as *Feld II*. This field may receive fibres, Forel thinks, from (*a*) the fasciculus longitudinalis medialis;

---

\* The limits of the hypothalamus (regio subthalamica), or Wernicke's stratum intermedium, as defined by Forel, are as follows: Dorsally it is covered by the thalamus, being separated from it by the lamina medullaris lateralis; medially it is limited by the stratum griseum centrale of the third ventricle and by the fasciculus thalamomammillaris (Vieq d'Azyri) and the anterior root of the fornix; ventrally by the lamina perforata posterior or by the corpus mammillare, as well as by the substantia nigra with the basis pedunculi; laterally by the internal capsule and by the reticular zone (*Gitterschicht*) of the thalamus. Below it is limited by the nucleus ruber and the fasciculus retroflexus (Meynerti); above it is continuous with the substantia innominata of Reil.

(b) longitudinal bundles of the formatio reticularis; and (c) possibly also fibres from the brachium conjunctivum and the red nucleus, inasmuch as he believes it may be looked upon as a continuation cerebralward of a process of the capsule of white matter surrounding the red nucleus. It is continuous laterally

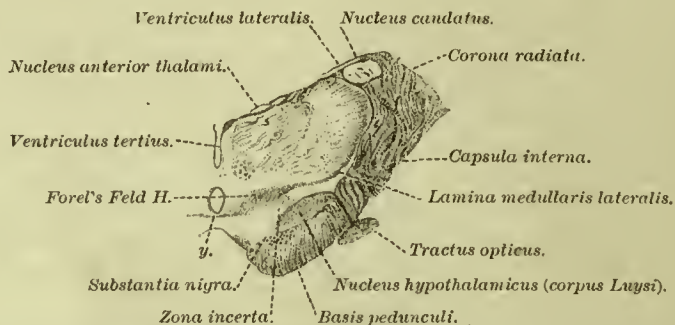


FIG. 437.—Frontal section through the human brain stem showing subdivisions of hypothalamic region. (After A. Forel, *Arch. f. Psychiat.*, Berl., Bd. vii, 1877, Taf. vii, Fig. 11.) *y*, delicate commissure just ventral to the ventriculus tertius.

with the lamina medullaris lateralis. Higher up, in sections passing through the posterior part of the corpus mammillare,\* Forel describes the *Feld II* as splitting into two portions, one dorsal (*Feld II<sub>1</sub>*), remaining in direct continuity with the lamina medullaris lateralis of the thalamus; the other ventral (*Feld II<sub>2</sub>*), sinks into the zona incerta, becomes more compact, and sends a process (of white matter) lateralward which passes as a flat lamella over the cerebral extremity of the dorsal white capsule of Luys' body. This lateral white process from the *Feld II<sub>2</sub>* grows thicker farther up, is closely attached to Luys' body, and bends around its lateral margin into the internal capsule at its junction with the basis pedunculi. In doing so, it is joined by lateral-ventral bundles from Luys' body, and, like these, divides the capsula interna into rectangular fields (Fig. 438).

The zona incerta, a mixture of gray matter and white matter, lies between the dorsal layer of white matter and Luys' body.

\* Forel's sections are cut at right angles to an axis going from the frontal pole to the occipital pole of the cerebrum, *not* at right angles to the axis of Meynert.



Forel could say nothing definite regarding the nature or relations of the fibres and cells situated in it.

The nucleus hypothalamicus (corpus Luysi), the most ventral of Forel's three layers, is a biconvex, transversely oval, lens-shaped mass, somewhat smaller than the red nucleus and very different in shape. It can be seen to begin in sections corresponding to the plane of the fasciculus retroflexus Meynerti, in which it lies dorsal to the basis pedunculi and the anterior part of the substantia nigra. More anteriorly it increases rapidly in size, assumes an exquisite spindle-shape in cross section, with somewhat more convex dorsal surface, and finally limits sharply dorsally and somewhat medially the whole basis pedunculi. It is largest in cross section at a level just posterior to the corpus mammillare. Anterior to this point it becomes smaller, but remains spindle-shaped in cross section and finally disappears in planes corresponding to the anterior part of the corpus mammillare. The dorsal surface of Luys' body is turned toward the zona incerta, while the ventral, somewhat less convex surface, is turned toward the basis pedunculi and the internal capsule. The nucleus is inclosed somewhat imperfectly by a dorsal and ventral white capsule, the two coming in contact with one another at the circular edge of the nucleus, especially at its anterior and posterior extremities.

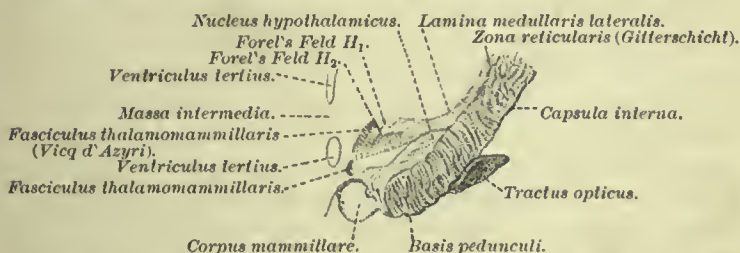


FIG. 438.—Frontal section through the brain stem. (After A. Forel, *Arch. f. Psychiat.*, Berl., Bd. vii, 1877, Taf. vii, Fig. 13.)

As regards the nuclei of the thalamus, Forel follows closely the descriptions of Burdach, who divided the thalamus (aside from the pulvinar) into three gray nuclei, which correspond to what we now designate as (1) the nucleus medialis thalami,\* (2) the nucleus lateralis thalami,† and (3) the nucleus anterior thal-

\* Burdach's *innerer Kern*, Luys' *centre moyen*.

† Burdach's *äusserer Kern*.

ami.\* In addition he recognizes the existence of Luys' *centre médian*, a nucleus hidden by many medullated fibres lying deep in the substance of the thalamus between the nucleus ruber, the nucleus medialis thalami, and the nucleus lateralis thalami. Von Tschisch,† in 1886, described an additional nucleus in the thalamus situated just dorsal to the red nucleus and lateral from the fasciculus retroflexus Meynerti. This mass of gray matter, which in reality belongs to the nucleus lateralis thalami (according to von Monakow to the ventral group of nuclei), is concave above, and in the concavity rests the *centre médian* of Luys. Von Tschisch calls it the *schalenförmiger Körper*; Dejerine writes of it as the *noyau semilunaire de Flechsig*; and von Kölliker calls it the *nucleus arcuatus* of the thalamus.

Dejerine, in a beautifully illustrated publication, describes and pictures a large number of sections—coronal, horizontal, and sagittal—through the cerebral hemispheres, from which the student, in working through the region of the thalamus and hypothalamus, will find much help. An extremely careful and detailed description of the thalamus and hypothalamus has been given to us by von Kölliker in the last edition of his textbook; it is of especial value in that it is accompanied by a large number of exquisite illustrations.

Von Kölliker‡ accepts Forel's nomenclature as regards fields H, H<sub>1</sub>, and H<sub>2</sub>. He calls *Feld H* the "tegmental bundle of the red nucleus."\* This splits into two parts: a dorsal part, Forel's *Feld H<sub>1</sub>*, which he designates as the "tegmental bundle of the thalamus,"|| and which he finds vanishes in the lamina medullaris lateralis and in the nucleus lateralis thalami; and a ventral part, Forel's *Feld H<sub>2</sub>*, which he calls the "tegmental bundle of the lentiform nucleus;"^ this goes through Luys' body and the cerebral peduncle to become lost in the nucleus lentiformis. He separates the upward continuation of the

\* Burdach's *oberer Kern*, Luys' *centre antérieur*.

† von Tschisch, W. F. Untersuchungen zur Anatomie der Gehirnganglien des Menschen. Ber. d. math.-phys. Cl. d. k. sächs. Gesellsch. d. Wissensch., 1886.

‡ *Op. cit.*, S. 434.

\* *Haubenbündel des rothen Kernes.*

|| *Haubenbündel des Thalamus.*

^ *Haubenbündel des Linsenkernes.*

medial lemniscus from *Feld II*, and states that it is situated laterally from it.

The upward continuation of the fasciculus longitudinalis medialis is discussed at length by von K  lliker.\* In his opinion, instead of breaking up in the nucleus of the posterior commissure, the medial portion of the fasciculus passes ventralward into the hypothalamus, and then passes dorsal from the corpora mammillaria to enter a commissure formed by the bundles of the two sides. A second portion, including the majority of the fibres, mixed with the arcuate fibres which surround the red nucleus on its medial and ventral aspects, becomes lost beneath the same, so that it can not be followed further. Although he formerly believed that it represented a crossed central sensory path, he now, as a result of the studies of van Gehuchten, Held, and others, is inclined to think that the majority of the fibres are descending, having their origin either in the thalamus or in the central gray matter of the third ventricle.

With regard to the bundles passing cerebralward from the region of the red nucleus, von K  lliker thinks it is difficult to state how many of them come from the brachium conjunctivum, and how many of them correspond to longitudinal bundles of the formatio reticularis.† He agrees with Forel in thinking that the bundle designated by the latter *BATH* goes over into *Feld II* and splits. His descriptions of the fibres from *Feld II*<sub>1</sub> and from *Feld II*<sub>2</sub> agree in the main with that of Forel.

The bundles from the red nucleus itself tend, von K  lliker states, to surround the *centre m  dian* on its ventral side, and are continued in the form of an arched platelet, which, cutting through a radiation of the thalamus parallel to the lamina medullaris lateralis, turns dorsalward and becomes lost before reaching the dorsal surface of the thalamus. This arched plate of fibres is seen in frontal sections farther forward at the beginning of the lamina medullaris medialis. Parallel with this plate there go stronger fibre bundles from the red nucleus through the medullated radiations of the lateral nucleus of the thalamus, representing for some distance a special intermediary lamina medullaris (Fig. 439). Between these two radiations from the red nucleus is to be found a small field of

---

\* *Op. cit.*, S. 438.

† *Op. cit.*, S. 454.



gray substance, the nucleus arcuatus, or *schalenförmiger Körper* of von Tschisch.

Von Kölliker in his text-book gives further an elaborate description of the different nuclei of the thalamus, in which he compares his findings in Weigert preparations of the brain of

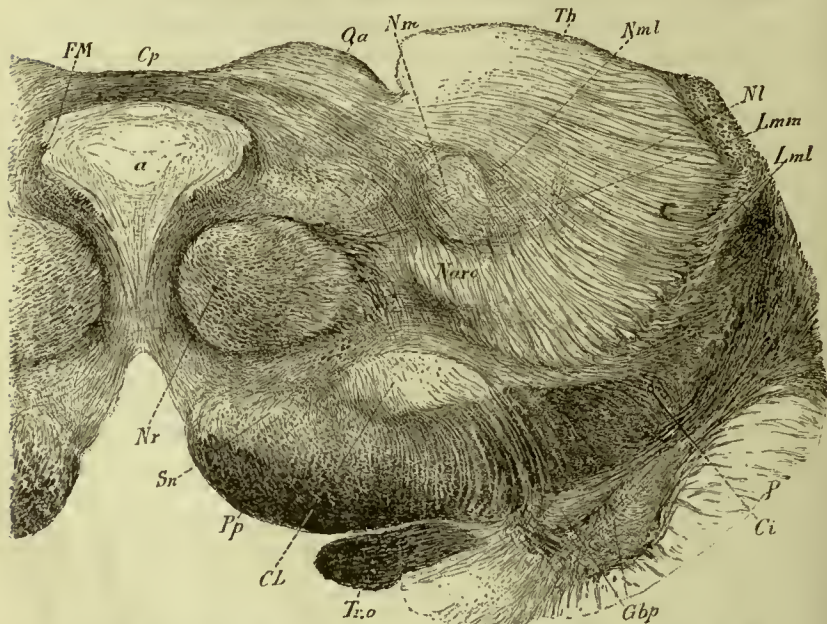


FIG. 439.—Frontal section through the brain stem of man. (After A. von Kölliker, *Handbuch der Gewebelehre*, Leipz., Bd. ii, 1898, S. 537, Fig. 660.) *a*, aqueductus cerebri; *Ci*, capsula interna; *Cl*, nucleus hypothalamicus (corpus Luysi); *Cp*, commissura posterior cerebri; *FM*, fasciculus retroflexus Meynerti; *Gbp*, globus pallidus of nucleus lentiformis; *Lmm*, lamina medullaris medialis; *Lml*, lamina medullaris lateralis; *Nl*, nucleus lateralis thalami; *Nm*, centre median of Luys (von Kölliker's nucleus medius thalami); *Nml*, nucleus medialis thalami; *Narc*, nucleus arcuatus (*schalenförmiger Körper* of Flechsig and von Tschisch); *Nr*, nucleus ruber; *P*, putamen; *Pp*, basis pedunculi; *Qa*, colliculus superior; *Sn*, substantia nigra; *Th*, thalamus; *Tr.o.*, tractus opticus.

man and animals with those of Nissl in the thalamus of rabbits. As is well known, Nissl\* has made a very thorough study of the nuclei of the thalamus in the rabbit, and has isolated, according to the form and grouping of the cells, some twenty different nuclei. In brief, his description is as follows: In the

\* Nissl, F. *Tagebl. d. 62 Versamml. deutsch. Naturf. u. Aerzte*, Heidelb. (1889-'90), S. 509.



part of the thalamus projecting most anteriorly is situated an anterior nucleus which must be divided into a smaller anterior dorsal and a larger anterior ventral nucleus. The latter shows a further differentiation, so that one can distinguish distinctly in it a dorso-medial part from a ventro-lateral part in which the cells are much closer together. Medial from the anterior nucleus is seen the rather small anterior medial nucleus which lies like a cap around the middle medial nucleus. The latter is a large nucleus situated close to the middle line, and visible for as much as half of the longitudinal extent of the thalamus. Ventral from the anterior nucleus lies the nucleus of the reticular zone (*Gitterschicht*). The first to appear in a frontal series of sections is the ventral nucleus of the reticular zone, which terminates medially at the transverse section of the columns of the fornix; laterally it adjoins the lateral nucleus of the reticular zone, an insignificant nucleus. Between the ventral nucleus of the reticular zone and the ventral anterior nucleus lies the dorsal nucleus of the reticular zone. Close to the middle line appears a narrow cell plate of spindle-shaped cells, which Nissl calls the "nucleus of the middle line," without questioning whether it belongs to the thalamus or to the stratum griseum centrale. This nucleus of the middle line is invaded by the middle medial nucleus, which quickly approaches the middle line, so that one part of it comes to lie dorsal, another ventral from the middle medial nucleus. These two parts quickly spread out lateralward, the dorsal more than the ventral.

In a slight lateral projection of the thalamus is situated the anterior extremity of the lateral nucleus. First of all comes the anterior lateral nucleus, which occupies almost two thirds of the longitudinal extent of the thalamus and which increases in size as the anterior nucleus diminishes. It has the form of a sector of a circle, the curved line of which forms the lateral curve of the thalamus, the medial radius of which adjoins the anterior nucleus, the ventral radius adjoining the dorsal nucleus of the reticular zone. Around the angle formed by the apex of the sector there is deposited a narrow row of cells also in the form of an angular mass. One series of these cell groups lies, therefore, between the anterior lateral nucleus and the ventral anterior nucleus; the other between the anterior lateral nucleus and the dorsal nucleus of the reticular zone. Since this nu-

cleus contains the largest cells which occur in the thalamus, Nissl calls it "the large-celled nucleus" of the thalamus.

As the anterior nucleus vanishes, its place comes to be occupied by the posterior medial nucleus, a large nucleus which laterally abuts against the anterior lateral nucleus. Besides, between the ventral and the dorsal nuclei of the reticular zone, which are both displaced markedly lateralward, a new nucleus develops, which had hitherto never been mentioned. Nissl calls it the ventral nucleus. It is very large, and occupies about the posterior half of the longitudinal extent of the thalamus. This nucleus is very difficult to describe, because transitions into almost all the other nuclei occur. However, it is not difficult to determine in it three cell groups of definite arrangement. The lateral ventral nucleus possesses spindle cells, the medial ventral nucleus large cells, the dorsal ventral nucleus, on the contrary, small cells. The ventral nucleus in its totality represents a triangle, the base of which rests upon the lamina medullaris lateralis.

Soon after the appearance of the lateral geniculate body the posterior lateral nucleus develops, which contains much smaller cells than the anterior lateral nucleus. The posterior lateral nucleus is situated between the lateral geniculate bodies and the anterior lateral nucleus. In these frontal planes there are to be made out in addition only some remains of the ventral nucleus of the reticular zone, the ventral nucleus, the posterior medial nucleus, and the nucleus of the middle line, the separated parts of which have again coalesced through the disappearance of the middle medial nucleus. Besides, in these planes, one finds also the ganglion habenulæ, in which a more distinct lateral nucleus can be made out, containing scattered larger cells, and a medial nucleus with cells pressed close together. While the lateral geniculate body becomes much larger, the other nuclei diminish in size, and there appears between the two lateral geniculate nuclei and the ganglion habenulæ the posterior lateral and the posterior medial nucleus. The latter shows scattered cells, which go over quickly into the stratum griseum centrale, while the former is a larger nucleus containing cells closely massed together, which stain feebly. With the appearance of the posterior commissure and of the medial geniculate body the posterior lateral nucleus alone still remains large, while only remains of the lateral geniculate body, of the

posterior medial nucleus, and of the ventral nucleus are visible. Nissl believes that Ganser is incorrect when he states that the posterior nucleus goes over into the medial geniculate body, and holds that von Monakow is also wrong in thinking that this nucleus also goes over into the lateral geniculate body. He states that the posterior nucleus is always sharply separable from the two geniculate bodies. The lateral geniculate body consists of a dorsal nucleus and a ventral nucleus. In the dorsal nucleus, again, one can make out a lateral-dorsal nucleus, which, in contrast to the dorsal nucleus proper, possesses far larger cells. This lateral-dorsal nucleus is identical with von Gudden's centre for the pupillary fibres. The ventral nucleus of the lateral geniculate body can be distinctly differentiated into a ventro-medial nucleus and a ventro-lateral nucleus containing cells of a different sort.

According to von K  lliker, Nissl has, since the publication referred to, given up his posterior medial nucleus; accordingly he designates as the "posterior" nucleus the mass of gray matter which he formerly called the "posterior lateral" nucleus. He adds still another undescribed nucleus, which he states is situated close to the t  nia thalami, and contains numerous spindle-shaped elements.

For the sake of convenient reference, I have arranged these nuclei described by Nissl in tabular form.

#### NUCLEI OF THE THALAMUS OF THE RABBIT (ACCORDING TO NISSL).

##### I. *Anterior Nucleus.*

- (a) Dorsal nucleus.
- (b) Ventral nucleus.
  - $\alpha$  Dorso-medial part.
  - $\beta$  Ventro-lateral part.

##### II. *Medial Nucleus.*

- (a) Anterior nucleus.
- (b) Middle nucleus.
- (c) Posterior nucleus (since given up).

##### III. *Nuclei of the Reticular Zone (Gitterschichtkerne).*

- (a) Ventral nucleus.
- (b) Lateral nucleus.
- (c) Dorsal nucleus.

IV. *Nucleus of Middle Line.*

- (a) Dorsal part.
- (b) Ventral part.

V. *Lateral Nucleus.*

- (a) Anterior nucleus.
- (b) Posterior nucleus.

VI. *Ventral Nucleus.*

- (a) Lateral nucleus.
- (b) Medial nucleus.
- (c) Dorsal nucleus.

VII. *Posterior Nucleus* (now designated the posterior lateral nucleus).VIII. *Unnamed Nucleus* (close to *tænia thalami*).

Von Monakow\* has carefully studied the nuclei of the thalamus in human beings and in higher mammals, and has compared his results with those obtained by Nissl in the rabbit. He widens the classification which dates from Burdach's description (*vide supra*). It would take up too much space to introduce here a detailed account of his findings, but the following table will give a fair idea of his classification of the nuclei as observable in a series of sections in human beings. It is to be especially noted that von Monakow adds a distinct ventral group of nuclei to the older descriptions. Thus, the lateral nucleus of the thalamus (of Burdach) is divided by an arbitrary plane into two halves—one dorsal (lateral nucleus of von Monakow) and one ventral (belonging to von Monakow's ventral group of nuclei).

NUCLEI OF THALAMUS IN HUMAN BEINGS (ACCORDING TO  
VON MONAKOW) (Figs. 440-444).

I. *Anterior Nucleus.*

- (a) Ant. a—the main mass (Fig. 444).
- (b) Ant. c—an accessory anterior nucleus (Fig. 444).

II. *Medial Nucleus.*

- (a) Med. a—the main portion consisting of the anterior and medial portions (Fig. 442).
- (b) Med. b—the *centre médian* of Luys (Fig. 442).

---

\* *Op. cit.* Arch. f. Psychiat. u. Nervenkr., Berl., Bd. xxvii.



III. *Lateral Nucleus* (Fig. 444)—the dorsal half of Burdach's lateral nucleus of the thalamus.

IV. *Ventral Group of Nuclei.*

- (a) Vent. ant. (Fig. 444)—the anterior ventral nucleus.
- (b) Vent. a (Fig. 442)—the middle ventral nucleus.
- (c) Vent. b (Fig. 442)—the medial ventral nucleus (*schalenförmiger Körper* of Flechsig and von Tschisch.
- (d) Vent. c (Fig. 441)—the lateral ventral nucleus.

V. *Nuclei of the Reticular Zone* (*Gitterschichtkerne*, Fig. 443).

VI. *Posterior Nucleus* (Fig. 441).

VII. *Pulvinar* (Fig. 440).

In the cat von Monakow describes, in addition to the nuclei above mentioned, (1) a nucleus *ant. b*, (2) a nucleus *med. a*. and (3) a nucleus *med. c* (nucleus magnocellularis of the medial nucleus). He divides his lateral nucleus into two parts, *lat. a*

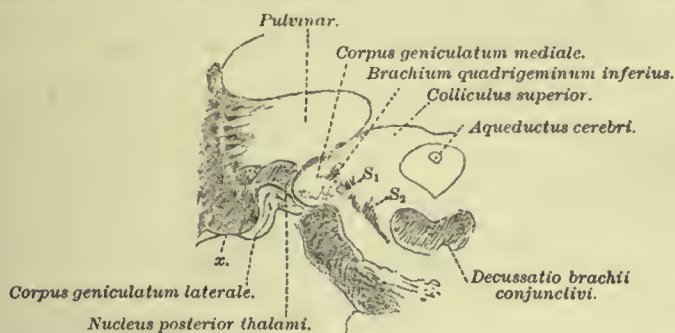


FIG. 440.—Frontal section through a normal human brain at the level of decussatio brachii conjunctivi. (After C. von Monakow, *Arch. f. Psychiat.*, Berl., Bd. xxvii, 1893, Taf. ii, Fig. 10.) *S*<sub>1</sub>, lemniscus superior (*obere Schleife*); *S*<sub>2</sub>, main portion of lemniscus medialis (*Haupttheil der Schleifenschicht*); *x*, lateral white matter of lateral geniculate body.

and *lat. b*. The nuclei of the reticular zone (*Gitterschicht*) he divides into an anterior and a posterior group.

Tschermak\* speaks of a medial ventral nucleus in the thalamus which is identical with the *schalenförmiger Körper* of Flechsig and with von Monakow's *vent. b*. The middle or central nucleus (*vent. a*) and the lateral ventral nucleus or *vent. c*

\* Tschermak, A. Ueber den centralen Verlauf der aufsteigenden Hinterstrangbahnen und deren Beziehungen zu den Bahnen im Vorderseitenstrang. *Arch. f. Anat. u. Physiol., Anat. Abth.*, Leipzig. (1898), S. 291-400.

of von Monakow are grouped together by Tschermak and called the "ventral nucleus in the narrower sense." \* He describes the *schalenförmiger Körper* as spreading out lateralward and going over without sharp limit into the nucleus lateralis thalami. It

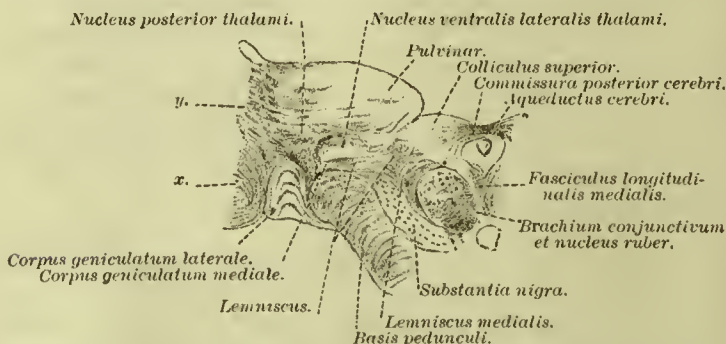


FIG. 441.—Frontal section through a normal human brain at level of upper extremity of corpus geniculatum mediale. (After C. von Monakow, Arch. f. Psychiat., Berl., Bd. xxvii, 1895, Taf. ii, Fig. 13.) *x*, lateral white matter of lateral geniculate body; *y*, lateral white matter of pulvinar.

is divided by bands of medullated fibres into a number of small groups of ganglion cells. Under the term *Thalamusmassiv* Tschermak describes the more or less egg-shaped total mass of the thalamus which, latero-ventrally and laterally, as far as the floor of the lateral ventricle, is surrounded by a lamella of gray substance, the *Gitterschicht* or *zona reticularis*. This *Thalamusschale*, as Tschermak prefers to call it, is continuous with the anterior extremity of the substantia nigra and with the corpus geniculatum mediale. Ventral from the *Thalamusschale* lies the nucleus hypothalamicus (corpus Luysi) covered by its dorsal white matter, the so-called *Feld H<sub>2</sub>* of Forel. In man the nucleus hypothalamicus lies upon the dorsal surface of the basis pedunculi, but in the cat it passes through the latter as a coarse-meshed framework of gray matter. On the lateral side of the *Thalamusschale* are situated the fibres of the capsula interna (the direct continuations of the white fibres of the basis pedunculi). Inasmuch as the *Thalamusschale* leaves the *Thalamusmassiv* uncovered only on its medio-ventral surface, a groove is formed through which fibres pass, on the one hand, between the *Thalamusschale* and the *Thalamusmassiv*, and, on

\* *Ventralkern im engeren Sinne.*

the other hand, into the gray matter of the *Thalamusschale* and of the *Thalamusmassiv* themselves. Accordingly, Tschermak designates this the *Hilus thalami*. The fibres which enter the thalamus run in company with other fibres which leave the thalamus, in places forming very definite bundles which, running through the gray matter, divide the thalamus up into a number of nuclei or groups of nuclei.

Tschermak's description is so clear and agrees so well with what one actually sees in sections through this region that some of its main features may with propriety be introduced here. Numerous bundles can be seen passing out of the hypothalamic region and radiating through the hilus thalami into the thalamus itself. These include the remains of the lateral lemniscus, the medial lemniscus, and the radiations of the red nucleus. Some fibres, however, approaching the hilus scarcely enter it, but turn aside again to break through the *Thalamusschale* and

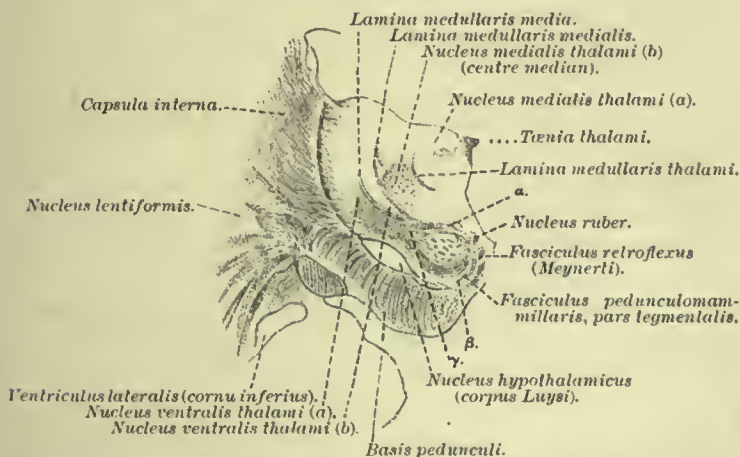


FIG. 442.—Frontal section through a normal human brain at the level of the lower end of the nucleus hypothalamicus. (After C. von Monakow, Arch. f. Psychiat., Berl., Bd. xxvii, 1895, Taf. iii, Fig. 20.) a, dorsal white matter of nucleus ruber; b, ventral white matter of nucleus ruber; c, lateral white matter of nucleus ruber.

bend around past the nucleus hypothalamicus to arrive in the basis pedunculi. In man the fibres of the main mass of white matter in the hypothalamic region, at least those most ventrally situated, do not pass through the hilus into the thalamus. These ventral fibres, on the contrary, run along the ventral surface of the *Thalamusschale*—that is, between this and the

nucleus hypothalamicus, forming the "dorsal white matter" of the latter (*Feld H<sub>2</sub>* of Forel). They pass lateralward into the basis pedunculi, and so, according to Tschermak, represent genuine direct hypothalamic fibres from the hypothalamie

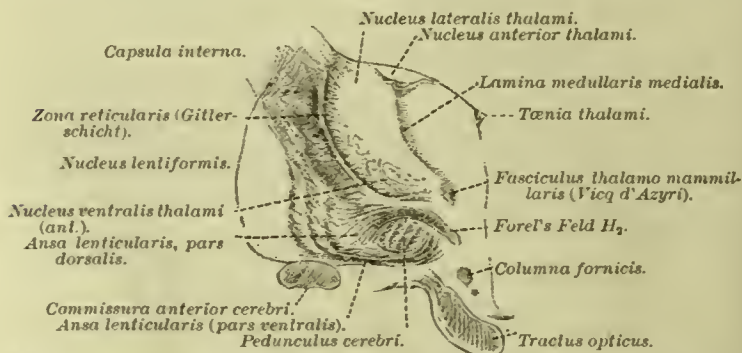


FIG. 443.—Frontal section through a normal human brain at the level of the ansa lenticularis (anterior to the nucleus hypothalamicus). (After C. von Monakow, *Arch. f. Psychiat.*, Berl., Bd. xxvii, 1895, Taf. iii, Fig. 28.)

region to the basis pedunculi. Speaking purely topographically, these direct fibres represent a continuation of the bundle which in lower regions, especially at the level of the colliculus superior, can be seen passing over from the area occupied by the lemniscus medialis ventro-lateralward into the basis pedunculi. These are the fibres which Flechsig designated the *Fussschleife* or *Pedunculusschleife*, and they are, Schlesinger believes, probably identical with the fibres of the lateral pontine bundles of the lemniscus described by the latter author.\*

---

\* *Die laterale pontine Bündeln der Schleife.* With regard to the *Fussschleife*, Flechsig is now of the opinion that its fibres are not among the centripetal fibres of the lemniscus medialis, but, on the contrary, represent descending (centrifugal) fibres which pass downward with the fibres of the pyramidal tract and, entering in all probability into relation with the most medial bundles of the lemniscus, pass with the lemniscus medialis by way of the tegmentum to terminate in the nuclei of origin of the motor cerebral nerves. On the contrary von Bechterew believes that Flechsig's *Fussschleife* is identical with his (von Bechterew's) *zerstreute accessorische Bündel*, part of which he considers to be centripetal, part centrifugal (*Leitungsbahnen*, II. Aufl. (1889), S. 234, 314, 319). Schlesinger's bundles are considered on page 237 of von Bechterew's book to correspond rather to the *mediale Schleife* than to the *zerstreute accessorische Schleife*.



In man Forel's *Feld H<sub>2</sub>* is in contact at its anterior extremity with the compact ansa lenticularis (*Linsekeranschlinge* of Flechsig), which, apparently beginning (or ending) in the nucleus lentiformis, circles around the medio-ventral border of the basis pedunculi and, in connection with the so-called medial peduncle of the thalamus, radiates into the most anterior ventral region of the thalamus. Von Monakow distinguishes in the ansa lenticularis three principal bundles: (1) A dorsal bundle which goes from the globus pallidus transversely through the peduncle to go between the *Gitterschicht* and the nucleus hypothalamicus. This bundle corresponds to the above-mentioned hypothalamic fibres (Forel's *Feld H<sub>2</sub>*, dorsal white matter of the nucleus hypothalamicus). In man the fibres are much more numerous and arranged in the form of a much more compact bundle than in the cat (Tschermak). (2) A middle portion running medio-ventralward from the fibres of (1). This middle portion of the ansa lenticularis forms the lateral and especially the ventral white matter of the nucleus hypothalamicus connecting this body with the nucleus lentiformis. (3) The ventral part of the ansa lenticularis runs between the

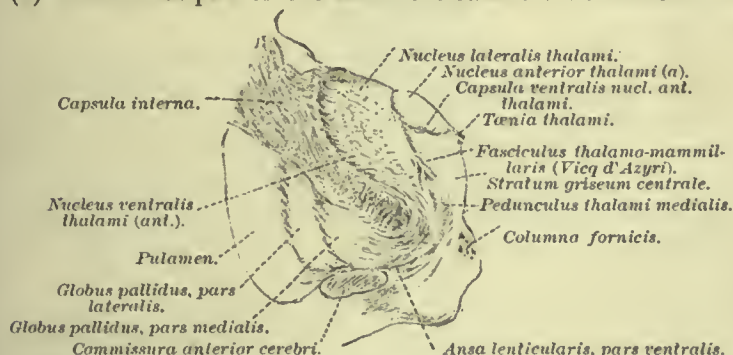

FIG. 444.—Frontal section through a normal human brain at level of anterior part of thalamus. (After C. von Monakow, Arch. f. Psychiat., Berl., Bd. xxvii, 1895, Taf. iv, Fig. 33.)

pedunculus cerebri and the tractus opticus medialward and sends some fibres into the commissura hypothalamica media of Meynert, but the main mass of its fibres form the so-called ansa peduncularis \* which extends to the most anterior ventral part of the thalamus of the same side.

\* *Hirnschenkelschlinge* of Flechsig.

It is von Monakow's opinion that the fibres of the dorsal part (Forel's *Feld II<sub>2</sub>*) unite with the main mass of the ventral part of the ansa lenticularis, and that accordingly the ansa lenticularis is in the main a connecting bundle between the nucleus lentiformis and the anterior ventral parts of the thalamus (and also the tuber cinereum), some of the fibres being interrupted in the nucleus hypothalamicus. Flechsig has come to the conclusion that there is a relatively important connection, partly direct and partly indirect, by means of the nucleus hypothalamicus, between the nucleus lentiformis and the thalamus. This is brought about, however, he believes, only by way of the middle and the ventral part of the ansa lenticularis. The dorsal part of the ansa lenticularis (*Feld II<sub>2</sub>* of Forel) represents, on the other hand, according to Flechsig, the continuation of a large part of the cerebellar tegmental (or conjunctival) radiation. The fibres go into the nucleus lentiformis and thus, according to Flechsig, represent a radiation from the brachium conjunctivum into the nucleus lentiformis.\* Another part of this radiation, however, goes by way of the red nucleus through the hilus thalami into the ventro-lateral group of nuclei of the thalamus.

We may now consider *seriatim* those bundles of centripetal fibres which, passing into or through the cerebral peduncle, may be concerned in the forwarding of somæsthetic impulses. These are (*a*) the lemniscus or fillet, (*b*) the fasciculus longitudinalis medialis, (*c*) the formatio reticularis alba, and (*d*) certain fibres of the brachium conjunctivum and radiations of the nucleus ruber.

(a) *The Lemniscus or Fillet.*

The term lemniscus laqueus, or fillet (German *Schleife*, French *ruban de Reil*), was first applied to that triangular area on the lateral surface of the isthmus rhombencephali, which separates the brachium conjunctivum from the surface (Fig. 445). This area, now called the trigonum lemnisci, corresponds to what is now known as the lateral lemniscus.

With the progress of anatomical knowledge the complexity of the nerve paths comprehended in the term lemniscus has rapidly grown until at present the beginner often has difficulty

---

\* *Bindearm-Linsenkernstrahlung.*

in understanding the meaning of the various names applied to the different portions, especially since, unfortunately, the same term has been used by different authors for designating entirely

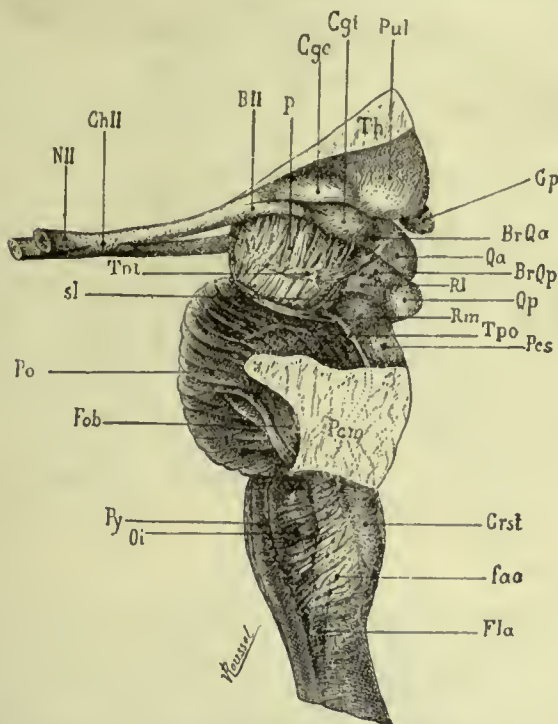


FIG. 445.—Isthmus rhombencephali seen in profile. (After J. Dejerine, *Anatomie des centres nerveux*, t. i, Paris, 1895, p. 328, Fig. 192.) *BII*, tractus opticus; *BrQa*, brachium quadrigeminum superius; *BrQp*, brachium quadrigeminum inferius; *Cgc*, corpus geniculatum laterale; *Cgt*, corpus geniculatum mediale; *ChII*, chiasma opticum; *Crst*, corpus restiforme; *Fla*, funiculus lateralis of medulla oblongata; *fao*, fibræ arcuatae externae; *Fob*, fibræ superficiales pontis; *Gp*, corpus pincale; *NII*, N. opticus; *Oi*, oliva; *P*, pedunculus cerebri; *Pem*, brachium pontis; *Pes*, brachium conjunctivum; *Po*, pons Varolii; *Pul*, pulvinar; *Py*, pyramis; *Qa*, colliculus superior; *Qp*, colliculus inferior; *RI*, trigonum lemnisci; *Rm*, lemniscus medialis; *sl*, sulcus lateralis; *Th*, thalamus; *Tpo*, tenua pontis; *Tpt*, tractus peduncularis transversus.

different paths. The two principal portions of the lemniscus are (1) the lemniscus lateralis or lateral fillet (inferior fillet, *untere Schleife* *ruban de Reil inférieur*), and (2) the lemniscus medialis\* (including the main portion of the lemniscus, † the

\* *Hauptschleife*.

† *Haupttheil der Schleifenschicht*.

superior fillet, \* certain scattered bundles of the medial lemniscus, † and, finally, the medial accessory lemniscus ‡) (Fig. 446).

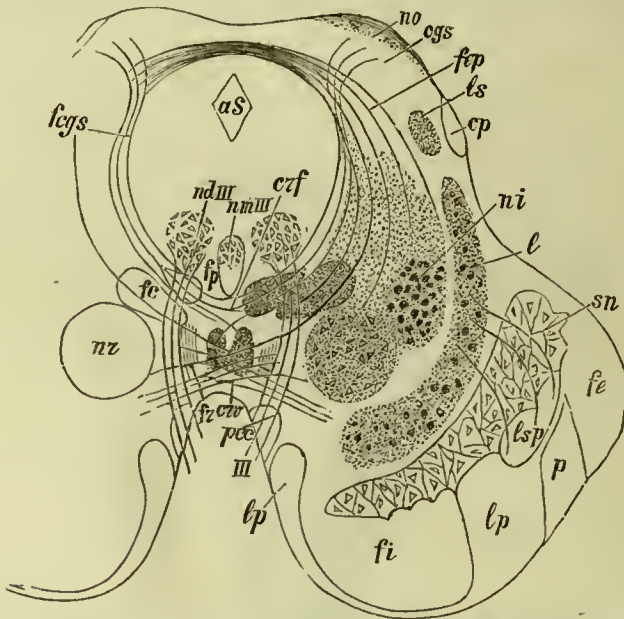


FIG. 446.—Schematic representation of the course of the fibres met with in the region of the superior colliculus of the corpora quadrigemina. (After W. von Bechterew, *Die Leitungsbahnen im Gehirn und Rückenmark*; Deutsch von R. Weinberg, II. Aufl., Leipz., 1899, S. 267, Fig. 234.) *crf*, decussatio tegmenti ventralis (Foreli); *crf*, decussatio tegmenti dorsalis (Meynerti); *as*, aqueductus cerebri; *fp*, commissura posterior cerebri; *cp*, corpus parigeminum (von Bechterew); *fe*, lateral bundle of basis pedunculi; *fr*, fasciculus retroflexus Meynerti; *fi*, fasciculus tegmenti centralis (*centrale Haubenbahn*); *fp*, fasciculus longitudinalis medialis; *fcgs*, stratum album profundum (medullated axones to dorsal decussation of Meynert); *l*, lemniscus medialis; *ls*, fibre bundle from the colliculus inferior to the thalamus; *lp*, centrifugal (motor) fibres going from basis pedunculi to region of lemniscus, probably terminating farther spinalward in the nuclei of origin of the motor cerebral nerves (Spitzka's bundle, *mediale accessorische Schleife* of von Bechterew; *Bündel vom Fuss zur Schleife* of the Germans); *lsp*, scattered bundles of the lemniscus (*zerstreute Schleifenbündel* of von Bechterew; *Fusssschleife* of Flechsig); *na*, tractus opticus; *ni*, nucleus lateralis superior of Flechsig (*nucleus inominatus* of von Bechterew); *nd III*, dorsal part of nucleus nervi oculomotorii; *nm III*, medial part of nucleus nervi oculomotorii; *p*, fasciculi pyramidales; *pcc*, fasciculus pedunculomammillaris pars basilaris (pedunculus corporis mammillaris); *nr*, nucleus ruber; *sn*, substantia nigra; *III*, nervus oculomotorius.

\* *Obere Schleife* or *ruban de Reil supérieure*.

† *Zerstreute accessorische Bündeln der Schleifenschicht*, von Bechterew; *Fusssschleife* of Flechsig.

‡ *Mediales accessorisches Bündel der Schleife*, von Bechterew, or continuation of the *Bündel vom Fuss zur Schleife*.



Of these various bundles we may exclude from the general centripetal path now being considered (1) the lateral lemniscus which is, in the main at least, a central acoustic centripetal path; (2) probably a part, at least, of the scattered bundles; and also (3) the medial accessory lemniscus which becomes medullated at a later period than the rest of the lemniscus and which, after solution of continuity, degenerates downward, not upward, and is therefore to be regarded as a centrifugal, probably a motor path, and not as a centripetal or sensory path (*vide* Chapter LXII). The old view of Meynert that the lemniscus passed through the lateral part of the basis pedunculi was disproved by Flechsig, who showed that this area in the *pes* represented a cerebro-cortico-frontal path which has nothing to do with the lemniscus.

The medial lemniscus is made up largely, as we have seen above, of the axones of neurones, the cell bodies of which are situated in the nucleus funiculi gracilis and the nucleus funiculi cuneati (the medial part of the latter, according to von Monakow) of the opposite side of the medulla oblongata. These medullated axones we have traced as internal arcuate

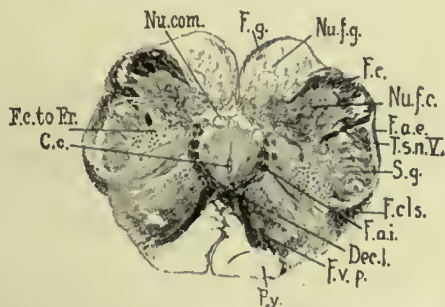


FIG. 447.—Transverse section through medulla oblongata of newborn child at level of decussatio lemniscorum. (Series ii, section No. 50.) *C.c.*, canalis centralis; *Dec.l.*, decussatio lemniscorum; *F.a.i.*, fibre arcuate internæ; *F.a.e.*, fibre arcuate externæ; *F.c.*, fasciculus cuneatus Burdachi; *F.c.to Er.*, bundles from fasciculus cuneatus to formatio reticularis; *F.cls.*, fasciculus cerebellospinalis or direct cerebellar tract; *F.g.*, fasciculus gracilis Golli; *F.v.p.*, fasciculus ventralis proprius; *Nu.com.*, nucleus commissuralis; *Nu.f.c.*, nucleus funiculi cuneati; *Nu.f.g.*, nucleus funiculi gracilis; *Py.*, pyramis; *T.s.n.V.*, tractus spinalis N. trigemini; *S.g.*, substantia gelatinosa [Kollmer]. (Weigert-Pal preparation by Dr. John Hewetson.)

fibres, which undergo decussation in the raphe (decussatio lemniscorum, Fig. 447), then to turn forward to run through the stratum interolivare lemnisci into the broad flat band situated

in the ventral part of the pars dorsalis pontis (Fig. 448). In the upper part of the pons the medial lemniscus comes to occupy a

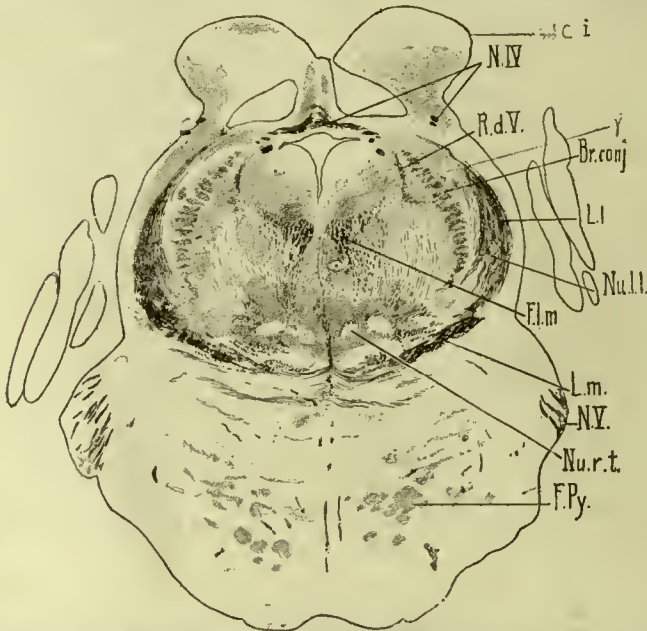


FIG. 448.—Transverse section through isthmus rhombencephali of newborn babe. (Weigert-Pal, series ii, section No. 268.) *Br.conj.*, brachium conjunctivum; *Cl.*, colliculus inferior;  $\gamma$ , nucleus described by Westphal as probably concerned in the origin of the N. trochlearis; *Fl.m.*, fasciculus longitudinalis medialis; *F.Py.*, fasciculi longitudinales [pyramidales]; *L.I.*, lemniscus lateralis; *L.m.*, lemniscus medialis; *N.IV.*, decussatio nervorum trochlearium; *N.V.*, N. trigeminus; *Nu.l.l.*, nucleus lemnisci lateralis; *Nu.r.t.*, nucleus reticularis tegmenti pontis; *R.d.V.*, radix descendens [mesencephalica] nervi trigemini. (Preparation by Dr. John Hewetson.)

more lateral position (Fig. 449), and in the midbrain changes the direction of its long diameter in cross section; whereas in the pons the long diameter of the lemniscus is transverse, or latero-medial in direction, in the midbrain it is almost vertical or dorso-ventral. The transition from the one form to the other takes place by means of a gradual curve, very well shown by a reconstruction made by Miss Florence Sabin. It is to be especially emphasized that the terms medial lemniscus and lateral lemniscus hold for only a part of the course of these two bundles, for while in the pons it is true that the lateral lemniscus is situated nearer the surface of the metencephalon than is the medial lemniscus, still in the isthmus the lateral lemniscus

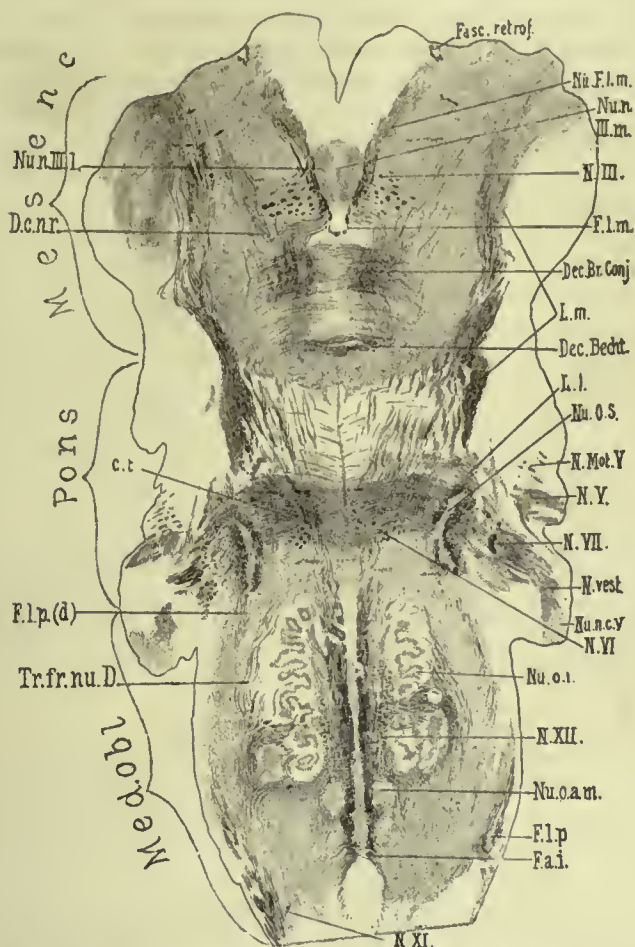


FIG. 449.—Horizontal section through the medulla, pons, and midbrain of a newborn babe. Weigert-Pal staining. Level of dorsal part of corpus trapezoidum and dorsal portion of nucleus olivaris inferior. (Series iii, section No. 122.) *C.t.*, corpus trapezoideum; *Dec.Br. Conj.*, decussatio brachii conjunctivi; *Dec. Becht.*, commissure between Bechterew's nuclei; *D.c.n.r.*, dorsal capsule of nucleus ruber; *F.a.i.*, fibre arcuate internæ; *Fasc. retrof.*, fasciculus retroflexus Meynerti; *F.l.m.*, fasciculus longitudinalis medialis; *Fl.p.*, bundle continuous with the fasciculus lateralis proprius of the cord; *Fl.p.(d)*, dorsal portion of bundle continuous with fasciculus lateralis proprius of the cord; *L.l.*, lemniscus lateralis; *L.m.*, lemniscus medialis; *N.III.*, radix N. oculomotorii; *N.Mot.V.*, motor root of N. trigeminus; *N.V.*, sensory root of N. trigeminus; *N.VI.*, radix N. abducentis; *N.VII.*, radix N. facialis, pars secunda; *N.vest.*, radix N. vestibuli; *N.XI.*, radix N. accessorii; *N.XII.*, radix N. hypoglossi; *Nu.F.l.m.*, nucleus fasciculi longitudinalis medialis, or nucleus commissuræ posterioris (*oberer Oculomotoriuskern* of Darkschewitsch); *Nu.n.III.m.*, pars impar of nucleus N. oculomotorii; *Nu.n.III.l.*, pars lateralis of nucleus N. oculomotorii; *Nu.o.s.*, nucleus olivaris superior; *Nu.n.c.V.*, nucleus N. cochleæ ventralis; *Nu.o.i.*, nucleus olivaris inferior; *Nu.o.a.m.*, nucleus olivaris accessorius medialis; *Tr.fr.nu.D.*, tract from Deiters' nucleus to the spinal cord. (Preparation by Dr. John Hewetson.)

passes medialward and dorsalward, in order to merge into the inferior colliculus of the corpora quadrigemina. At the same time a large portion of the medial lemniscus passes lateralward

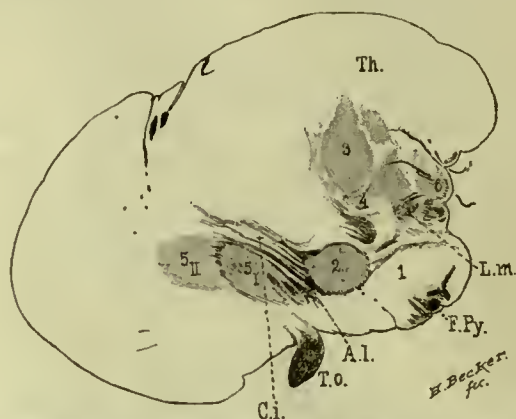

FIG. 450.—Sagittal section of babe's brain shortly after birth (section 76). *A.L.*, ansa lenticularis; *C.I.*, capsula interna; *F.Py.*, fasciculi cerebrospinales (pyramidales); *L.M.*, lemniscus medialis terminating in ventral portion of thalamus; *Th.*, thalamus; *T.O.*, tractus opticus; *1*, substantia nigra; *2*, nucleus hypothalamicus (corpus Luysi); *3*, centre median of Luys; *4*, nucleus arcuatus (*schalenförmiger Körper* of Flechsig and von Tschisch); *5*, nucleus lentiformis; *6*, corpus geniculatum mediale and beneath it the fibres of the brachium quadrigeminum inferius.

and dorsalward toward the superior colliculus of the corpora quadrigemina, and accordingly comes to occupy a position as far lateral as the lateral lemniscus. This portion of the medial lemniscus running toward the superior colliculus, and partly ending in its gray matter, is known as the superior lemniscus or fillet\* (*obere Schleife* of Forel, *ruban de Reil supérieur*). The main portion of the lemniscus runs forward and somewhat lateralward, being bounded ventro-laterally by the substantia nigra and dorso-medially by the red nucleus and the white fibres which pass from its lateral surface into the hypothalamic region. The ventral portion of the superior fillet remains, however, for a considerable distance in direct contact with the dorsal border of the main portion of the medial lemniscus.

\* While this is the description usually given of the superior lemniscus, it must be pointed out that von Beehterew in his *Leitungsbahnen* (1894), p. 113, states that the *obere Schleife* of Forel arises from the nucleus colliculi inferioris, and passes beneath the colliculus superior to become lost in the posterior part of the thalamus.



Above the decussation of the brachium conjunctivum, however, in the hypothalamic region a certain amount of gray matter is intercalated between the upward continuation of the superior lemniscus and the upward continuation of the main portion of the lemniscus, so that in coronal sections through the hypothalamic region one sees two separate and distinct bundles, that more dorsally and laterally placed corresponding to the superior lemniscus, while the larger one more ventrally and medially placed corresponds to the main portion of the lemniscus. This separation into two distinct bundles in the lower hypothalamic region, however, is not to be made out in frontal planes a little farther forward. In these planes the fibres of the superior lemniscus become inextricably mixed with those of the main portion of the lemniscus, and for some little distance farther forward any attempt to separate the fibres belonging to the two bundles by purely anatomical means is entirely impossible. The mixed bundles turn somewhat lateralward and dorsalward, and, breaking up into small fasciculi, become lost in the gray matter of the ventro-lateral portions of the thalamus (according to von Monakow, in the caudal portions of his ventral group of

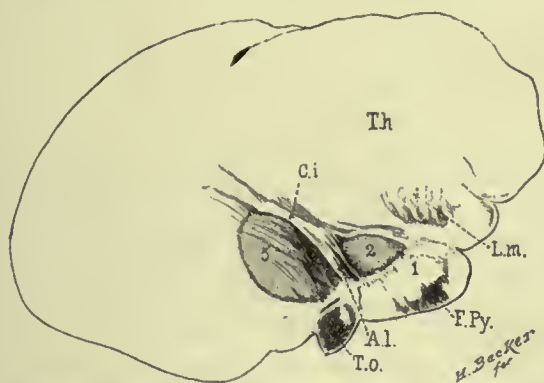


FIG. 451.—Sagittal section through portion of cerebrum of child shortly after birth (section 108). *A.L.*, ansa lenticularis; *Ci.*, capsula interna; *F.Py.*, fasciculi pyramidales in basis pedunculi; *L.m.*, lemniscus medialis terminatio in ventral nuclei of thalamus; *Th.*, thalamus; *T.O.*, tractus opticus; *1*, substantia nigra; *2*, nucleus hypothalamicus (corpus Luysi); *5*, nucleus lentiformis.

nuclei in the thalamus). In Figs. 450, 451 is shown a sagittal section of the brain of a babe shortly after birth, illustrating the relations here under discussion.

There can be but little doubt that the lemniscus considered in its whole length from the nuclei of the dorsal funiculi in the medulla oblongata to the ventro-lateral region of the thalamus includes the axones of neurones, which are of very different origin, and probably of physiological significance. Thus, there is much evidence to show that not all of the axones going from the nucleus funiculi gracilis and nucleus funiculi cuneati into the lemniscus pass as far forward as the thalamus. One large series of fibres leaves the medial lemniscus just above the corpus trapezoideum in order to terminate in the nucleus reticularis tegmenti pontis of von Bechterew. Many of them end in the gray matter of the medulla itself, others in the gray matter of the pons, still others in the gray matter of the isthmus and of the midbrain, and finally many of them terminate in the gray matter of the hypothalamic region, short of the thalamus. Tschermak, by Marchi's method, has traced degenerated fibres of the lemniscus to the *centre médian*, and Luys' body of the same side, and to the globus pallidus of the opposite side. We are thus justified in speaking of bulbo-pontal neurones, bulbo-mesencephalic neurones, bulbo-hypothalamic neurones, and the like. It seems to be true, however, that the majority of axones passing from the nuclei of the dorsal funiculi in the medulla into the lemniscus reach the ventro-lateral group of nuclei in the thalamus before terminating. In transverse and horizontal sections through the brain-stem of the newborn babe, stained by the Weigert-Pal method, I have been struck by the very evident masses of fibres of the lemniscus which enter into relation with the substantia nigra. The method does not permit one to say whether these fibres ascend in the lemniscus to terminate in the substantia nigra, or arise in the substantia nigra, and descend in the lemniscus, though, *a priori*, the former of these two possibilities seems the more probable. The bundles are so definite (Figs. 452 and 453) that Miss Sabin has been able to introduce them easily into her reconstruction of this region.

In addition to axones of different lengths arising from the cell bodies situated in the nuclei of the dorsal funiculi of the medulla, there are contained in the lemniscus axones of neurones the cell bodies of which are situated in various gray masses all the way from the medulla oblongata to the thalamus. Thus, by Golgi's method and by the method of secondary degeneration it has been shown that many of the axones of the

lemniscus arise in the gray matter of the formatio reticularis of the medulla oblongata and of the tegmental region of the pons. Further, the nuclei of reception of the sensory cerebral nerves doubtless contain cells which contribute axones (sensory neurones of the second order) to the medial lemniscus, and finally from the gray matter of the midbrain and hypothalamic region

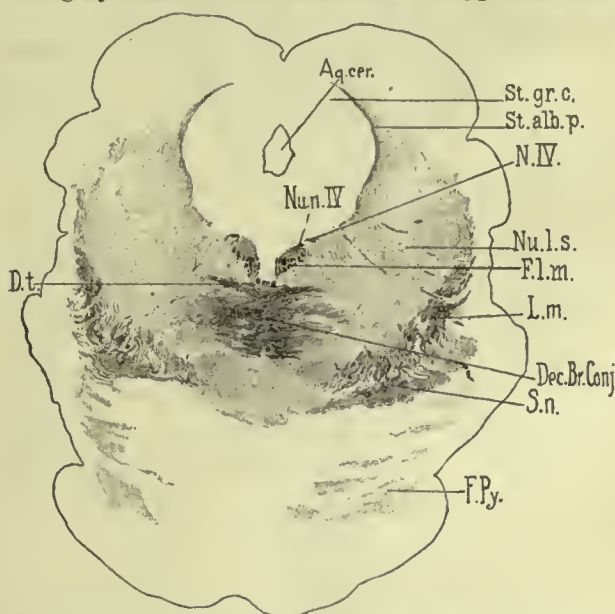


FIG. 452.—Transverse section through mesencephalon of newborn babe. Level of colliculi superiores of corpora quadrigemina. (Weigert-Pal, series ii, section No. 338.) *Aq.cer.*, aqueductus cerebri; *Dec.Br.Conj.*, decussatio brachii conjunctivi; *Dt.*, decussatio tegmenti ventralis (*ventrale Haubenkreuzung* of Forel); *Fl.m.*, fasciculus longitudinalis medialis; *F.Py.*, fasciculi pyramidales in the pars basilaris pontis; *L.m.*, lemniscus medialis; *N.IV.*, N. trochlearis; *Nu.l.s.*, nucleus lateralis superior of Flechsig; *Nu.n.IV.*, nucleus N. trochlearis; *St.alb.p.*, stratum album profundum; *St.gr.c.*, stratum griseum centrale; *S.n.*, substantia nigra. (Preparation by Dr. John Hewetson.)

it seems probable that axones pass through the lemniscus to the region of the thalamus. The medial lemniscus is, therefore, a very complex tract, consisting of fibres of different length, of different origin, and of different termination. It is thus not dissimilar in constitution from many other tracts which have been well studied—for example, certain fasciculi of the cord, the fasciculus longitudinalis medialis of the rhombencephalon, and the like.

There has been for a long time much dispute as to the rela-

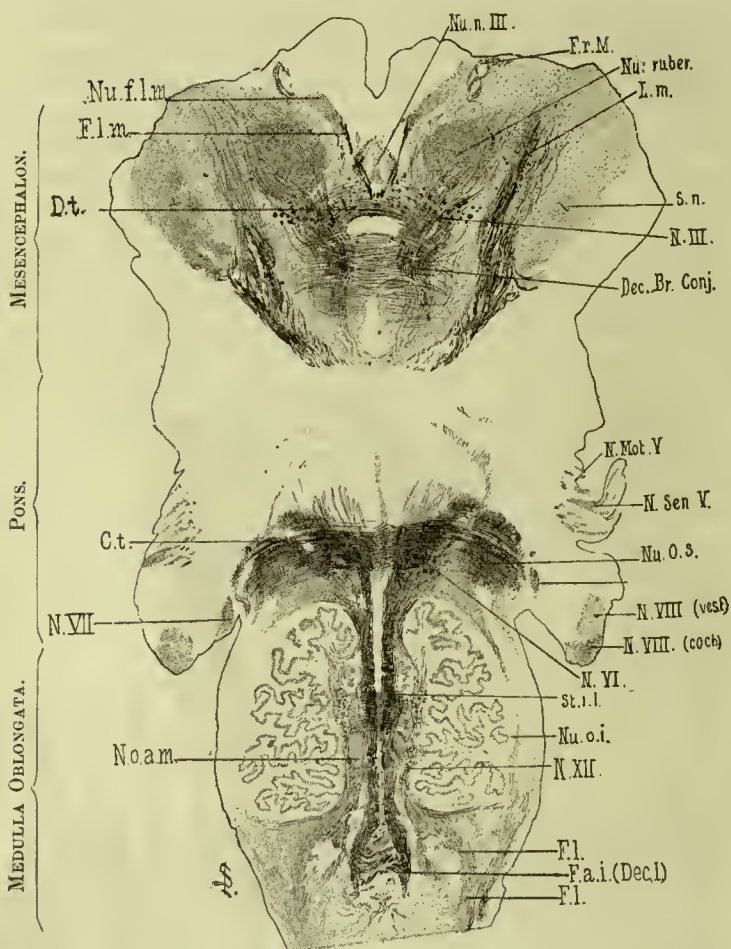


FIG. 453.—Horizontal section through the medulla, pons, and midbrain of newborn babe. Level of stratum interolivare lemnisci, corpus trapezoidicum and nucleus ruber. Weigert-Pal staining. (Series iii, section No. 136.) *C.t.*, corpus trapezoidicum; *Dec.Br. Conj.*, decussatio brachii conjunctivi; *D.t.*, decussatio tegmenti ventralis (ventral tegmental decussation of Forel); *F.a.i. (Dec. I.)*, fibræ areuatae internæ (decussatio lemniscorum); *F.l.*, fibræ continuæ with the funiculus lateralis of the spinal cord; *F.l.m.*, fasciculus longitudinalis medialis; *Fr.M.*, fasciculus retroflexus Meynerti; *L.m.*, lemniscus medialis; *N.III.*, radix N. oculomotorii; *N.Mot.V.*, motor root of N. trigeminus; *N.Sen.V.*, sensory root of N. trigeminus; *N.VIII. (coch.)*, radix N. cochleæ; *N.VIII. (vest.)*, radix N. vestibuli; *N.VI.*, radix N. abducentis; *N.VII.*, radix N. facialis, pars secunda; *N.XII.*, radix N. hypoglossi; *Nu.f.l.m.*, nucleus fasciculi longitudinalis medialis, or nucleus commissuræ posterioris (*oberer Oculomotoriuskern* of Darkschewitsch); *Nu.n.III.*, nucleus N. oculomotorii; *Nu.o.a.m.*, nucleus olivaris accessorius medialis; *Nu.o.i.*, nucleus olivaris inferior; *Nu.o.s.*, nucleus olivaris superior; *Nu.ruber*, nucleus ruber; *St.i.l.*, stratum interolivare lemnisci; *S.n.*, substantia nigra. (Preparation by Dr. John Hewetson.)



tions of the medial lemniscus to the cerebral cortex. Two main views may be said to have been dominant. According to the one, formerly championed in the main by Flechsig and Hoesel, a large majority of the axones making up the lemniscus in its course through the rhombencephalon pass without interruption through the internal capsule and out through the corona radiata to the cerebral cortex. According to the other view, supported by Mahaim, von Monakow, and others, very few, if any, of the fibres of the lemniscus pass directly without interruption to the cerebral cortex. According to the latter observers, the majority, if not all, of the fibres of the lemniscus terminate in the interbrain, chiefly in the optic thalamus, the connection with the cerebral cortex being made by means of neurones of a higher order. Inasmuch as an accurate knowledge of the exact relations existing here is of fundamental importance, it seems desirable to consider briefly the history of these two views (Fig. 454) and the evidence thus far brought forward in favor of each.

Before entering into this discussion, however, it will be well to clear the way by defining the term "cortical lemniscus" (*Rindenschleife* of the Germans, *ruban de Reil cortical* of the Belgians and French). This term was introduced by von Monakow in 1884 as the result of experiments made by von Gudden and himself. Von Gudden\* showed that removal of the cerebral hemisphere in the rabbit by his method was followed by atrophy of the lemniscus† as far down as the corpus trapezoideum. Von Monakow‡ found that removal of a portion of the parietal lobe in the cat, corresponding to the "zone F" of Munk, led to marked atrophy of the lemniscus, which extended not only as far as the corpus trapezoideum, but also through the interolivary layer and internal arcuate fibres of the opposite side to the nuclei of the dorsal funiculi in the medulla oblongata. He could make out, after a long time, not only atrophy of the fibres of the lemniscus, but also degeneration of

---

\* von Gudden, B. Beitrag zur Kenntniss des Corpus mammillare und der sogenannten Schenkel des Fornix. Arch. f. Psychiat. u. Nervenkr., Berl., Bd. xi (1881), S. 428-452.

† Reichert's *Schleife*.

‡ von Monakow, C. Experimentelle Beiträge zur Kenntniss der Pyramiden- und Schleifenbahn. Cor.-Bl. f. schweiz. Aerzte, Basel, Bd. xiv (1884), S. 129; 157. •

the ganglion cells of the nucleus funiculi gracilis and of the medial part of the nucleus funiculi cuneati of the opposite side. Inasmuch as the welfare of a large portion of the lemniscus is obviously dependent, as these experiments showed, upon the integrity of the cerebral cortex, von Monakow introduced as a designation for that part of the lemniscus which degenerated

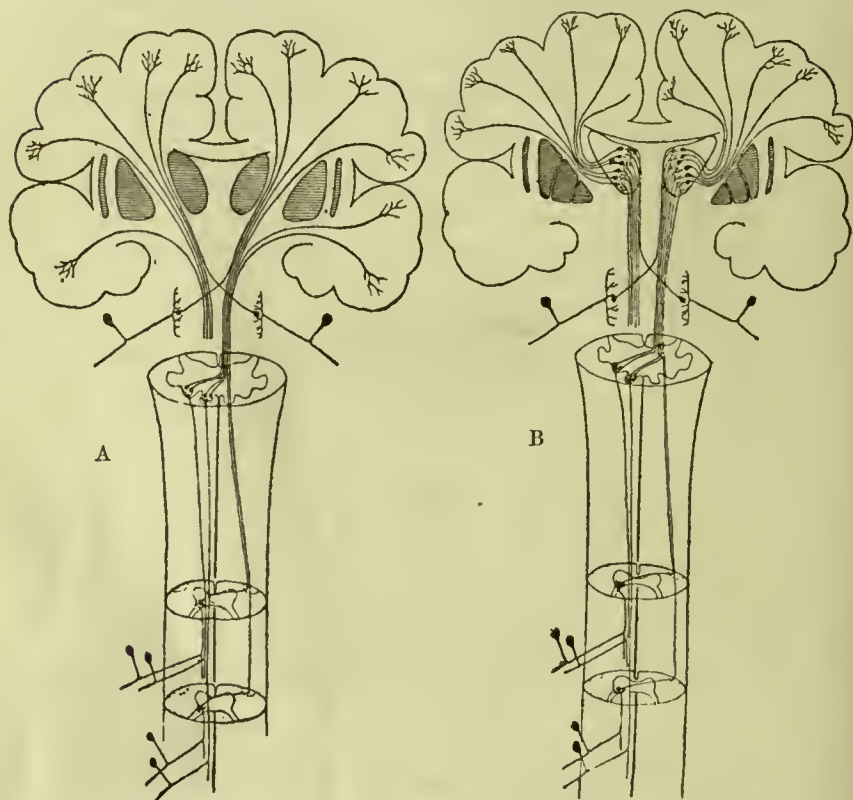


FIG. 454.—Two schemes illustrating the two main views concerning the course and interruption of the general sensory path (lemniscus medialis). (After A. van Gehuchten, *Anatomic du système nerveux de l'homme*, Louv., 1897, p. 782, Figs. 544, 545.) A, scheme illustrating the view that the lemniscus runs out directly to the cortex without interruption in the thalamus. B, scheme illustrating the view that the lemniscus is connected with the cortex indirectly, being interrupted in the thalamus.

on removal of the cortex the term "cortical lemniscus" (*Rindenschleife*). The term *Rindenschleife* has been used in a very different sense by other investigators, but it seems better to limit its use to the significance attached to it by von Monakow.

A little earlier Spitzka\* had described a case in which, following hæmorrhage in the region of the lemniscus inside the pons, there had resulted degeneration of the fibræ arcuatae internæ and of the nuclei of the dorsal funiculi on the opposite side of the medulla oblongata.

The view of Flechsig † and Hoesel and those who adhere to the same opinion dates from Flechsig's study of myelinization in 1881, but is based mainly upon the study of a case by Hoesel in Flechsig's laboratory. ‡ In this case, following an old defect (porencephaly) of the left cerebral hemisphere involving principally the posterior central gyrus, there had resulted secondary disease of the main portion of the medial lemniscus, which extended all the way to the nuclei of the dorsal funiculi in the medulla. Hoesel concluded that nine tenths of this portion of the lemniscus was "cortical lemniscus," and that not only was this true, but that the fibres passed directly all the way from the medulla, through the pons, midbrain, and tegmentum, to enter the internal capsule and to pass through it and the corona radiata without interruption anywhere to the cortex of the posterior central gyrus. If this view were correct, two neurones would suffice for the conduction of sensory impulses from the surface of the body to the cerebral cortex, one corresponding to the spinal ganglion cell, the other bulbo-cortical (that is, myelencephalo-pallial).

Forcible objections to the doctrine of Flechsig and Hoesel was offered in 1895 by Mahaim.\* This investigator, working in

\* Cf. Spitzka, E. C. A Contribution to the Morbid Anatomy and Symptomatology of Pons Lesions. *Am. J. Neurol. and Psychiat.*, N. Y., vol. ii (1883), pp. 617-661.

† Flechsig, P. Zur Anatomie und Entwicklungsgeschichte der Leitungsbahnen im Grosshirn des Menschen. *Arch. f. Anat. u. Physiol., Anat. Abth.*, Leipz. (1881), S. 12-75.

‡ Flechsig, P., and O. Hoesel. Die Centralwindungen, ein Centralorgan der Hinterstränge. *Neurol. Centralbl.*, Leipz., Bd. ix (1890), S. 417-419.—Hoesel, O. Die Centralwindungen ein Centralorgan der Hinterstränge und des Trigeminus. *Arch. f. Psychiat.*, Berl., Bd. xxiv (1892), S. 452-490.—Ein weiterer Beitrag zur Lehre vom Verlauf der Rindenschleife und centraler Trigeminusfasern beim Menschen. *Arch. f. Psychiat.*, Berl., Bd. xxv (1893), S. 1-17.

\* Mahaim, A. Ein Fall von secundärer Erkrankung des Thalamus opticus und der Regio subthalamica. *Arch. f. Psychiat. u. Nervenkr.*, Berl., Bd. xxv (1893), S. 343.

von Monakow's laboratory, studied most carefully a case of primary defect of the cerebral hemisphere which involved the white matter of both central gyri. The lemniscus was secondarily diseased. The change in the lemniscus, however, was not that of typical secondary degeneration, but rather of simple atrophy (diminution of the calibre of the individual fibres). The whole internal capsule was, however, transformed into completely degenerated tissue. Mahaim, then, having found that the fibres of the lemniscus ended free in the degenerated tissue, argued that it was improbable that the same set of medullated fibres should in one part of their course (in the lemniscus) show simple atrophy and in another part (internal capsule) typical secondary degeneration. He came, therefore, to the conclusion that the fibres of the lemniscus do not pass directly out to the cortex, but that they are interrupted in the region of the thalamus, thus confirming a view previously arrived at by von Monakow. Mahaim does not deny absolutely the existence of any direct fibres from the lemniscus to the cerebral cortex, but asserts that if such fibres exist they can be but few in number.\*

A very important contribution to our knowledge of this whole subject has been made by von Monakow † in an article in which he sums up all of his wide experience with secondary degenerations in human beings, and compares the results of these with those of the experiments which he has made upon animals. These are so important that they must be briefly reviewed here. Von Monakow finds that when the whole cerebral hemisphere of the cat or dog is extirpated without injury to the thalamus, the lemniscus undergoes a reduction in volume of as much as one third, a reduction which is due not to actual degeneration of its constituent fibres, but to simple atrophy.‡

---

\* The doctrine advanced by Flechsig and von Bechterew, of a participation of fibres of the lemniscus in the formation of the *ansa lenticularis*, thus connecting with Luys' body and the lenticular nucleus of the same side, is strongly opposed by von Monakow and Mahaim on the ground that the evidence from the study of secondary degenerations negatives it.

† von Monakow, C. Experimentelle und pathologisch-anatomische Untersuchungen ueber die Haubenregion den Schhügel und die Regio subthalamica, nebst Beiträgen zur Kenntniss früh erworbener Gross- und Kleinhirndefecte. *Arch. f. Psychiat. u. Nervenkr.*, Berl., Bd. xxvii (1895), S. 1.

‡ von Monakow does not absolutely exclude the total absorption of single fibres, but maintains that if actual secondary degeneration occurs at all it is minimal in amount.



The amount of change in the lemniscus after removal of the hemisphere decreases, *pari passu*, as one examines frontal sections successively from the upper to the lower parts of the lemniscus. Even in cases in which after cortical disease there is complete secondary degeneration of the internal capsule, the area occupied by the lemniscus in the hypothalamic region just ventral and lateral to the lateral portion of the white matter forming the capsule of the red nucleus shows no degeneration, but simple atrophy.

If the lemniscus be cut through in the region of the pons in the dog or in the cat at birth, very intense secondary degeneration in an ascending direction results, but the degenerated fibres do not extend as far upward as the internal capsule, nor do any of them enter the white matter of the hemisphere (von Monakow). The degenerated fibres can be followed, however, to the thalamus, and a distinct loss of fine fibres in the ground substance in the ventral nuclei of the thalamus can be made out. Von Monakow states that a degeneration of the lemniscus in an ascending direction has thus far not been certainly followed beyond the region of the ventral group of nuclei in the thalamus.\* Mott's experiments in this connection are especially convincing. In five cases of excision of the nuclei *funiculi gracilis et cuneati* in monkeys he could follow the degeneration as far upward as the hypothalamic region, but no farther.

I must agree, therefore, with Mahaim and von Monakow, that, *in the main path at any rate*, between the nuclei of the dorsal funiculi of the medulla oblongata and the cerebral cortex at least two neurones are superimposed, the first with a cell body situated in the nucleus *funiculi gracilis* or in the nucleus *funiculi cuneati*, its axone extending cerebralward as far as the ventral portion of the thalamus (*Systema lemniscale myelencephalo-diencephalicum*), and the second with a cell body situated in the ventral region of the thalamus, its axone passing through the internal capsule and corona radiata to the cortex (*Systema neuronicum diencephalo-pallialum*). The medullated axones from the cell bodies in the thalamus in the region in which the lemniscus terminates, at least those which run out to the region of the central gyri, occupy that portion of the in-

---

\* Since this statement was made the research of Tschermak has been published, *vide infra*.

ternal capsule which corresponds in frontal sections to the first caudal planes of Luys' body (von Monakow).

Tschermak\* has recently restudied the original brain described by Flechsig and Hoesel. The defect, which had lasted for fifty years, involved the gyrus centralis posterior down as far as the island and that part of the lobulus paracentralis which lies between the paracentral sulcus and the fissura collateralis. It extended also into the gyrus centralis anterior and the lobulus parietalis superior, but involved the white matter of these gyri only slightly in their upper portions.† Following upon the destruction of the cortex there was disappearance of the corresponding portions of the corona radiata, and farther down disappearance also of some of the fibre bundles which partly run over the dorsal corner of the putamen, partly cut through the "ridge region" of this mass of gray matter, dividing it up into wedge-shaped areas. No alteration could be found in the substantia grisea of the nucleus lentiformis, or of the nucleus caudatus. At the level of the ridge of the putamen (in its caudal part) the degenerated area divides into two portions, which assume the form of bands. One of these passes through the capsula interna in a transverse direction, breaks through the zona reticularis (*Thalamusschale* or *Gitterschicht*), and extends into the ventral half of the nucleus lateralis thalami. The other band of degeneration sinks ventral from the former to pass along the dorsal surface of the nucleus lentiformis; by way of the capsula interna the latter band passes into the basis pedunculi (Fig. 455). While in the upper part these diverging bands of the degenerated area both pass through the pars occipitalis capsulae internae, they do not, however, extend between the same frontal planes, but the band descending into the basis pedunculi comes to lie frontalward from that passing transversely into the thalamus. In the basis pedunculi the former band is no longer recognizable as a distinctly separate area, but the loss of fibres is manifest in a diffuse reduction of the total mass of the basis pedunculi. In connection with this the fasciculi longitudinales [pyramidales]

\* Tschermak, A. Ueber den centralen Verlauf der aufsteigenden Hinterstrangbahnen und deren Beziehungen zu den Bahnen im Vorderseitenstrang. Arch. f. Anat. u. Physiol., Anat. Abth., Leipz. (1898), S. 291-400.

† von Monakow, in his criticism, had assumed that a much larger amount of the white matter of the lobus parietalis had been involved.

of the same side are reduced in size as far down as the decussatio pyramidum. Tschermak states that from the level of the decussation downward into the spinal cord the fasciculus cerebro-spinalis ventralis is absent on the side of the lesion, while the contra-lateral fasciculus cerebro-spinalis lateralis is only one fourth its normal size.

The atrophic process in the thalamus, as studied by Tschermak, is of especial interest in connection with the discussion above referred to. Hoesel in his first communication had ex-

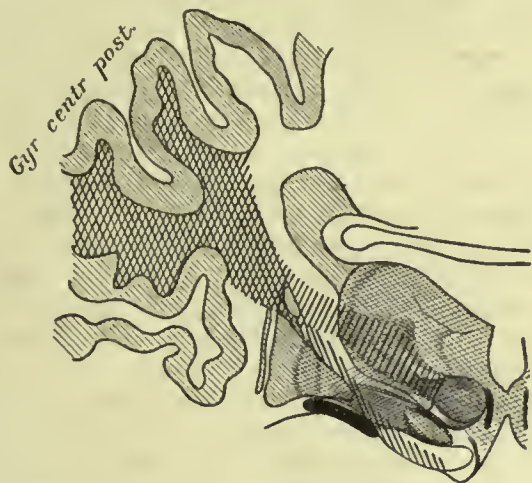


FIG. 455.—Scheme of the bands of degeneration in the case of Hoesel and Flechsig, constructed on the basis of a section inclined from above and forward in a direction downward and backward through a normal human brain. (After A. Tschermak, *Arch. f. Anat. u. Physiol., Anat. Abth.*, Leipz., 1898, S. 312, Fig. 1.)

pressed the opinion that the atrophied fibres simply passed through the thalamus into the region of the tegmental radiations of the red nucleus, and farther on into the curved area of the lemniscus medialis as well as into the contra-lateral brachium conjunctivum. He noticed that the nuclei in the thalamus were diminished in size, but believed that this was due essentially to loss of medullated fibres, the cells remaining unaltered. In a later report (1893) he admitted a moderate loss of nerve cells in the thalamus. Still later, Flechsig\* described total loss

\* Flechsig, P. *Die Localization der geistigen Vorgänge*, etc. Leipz. (1896).

of the nerve cells in the nucleus arcuatus thalami (*schalenförmiger Körper*) and in the ventral part of the nucleus lateralis thalami, that region of the thalamus whence are derived the medullated axones of Flechsig's fetal sensory system No. 1 (*vide* Chapter LI) which pass to the central gyri. Tschermak confirms Flechsig's findings, and states, in opposition to Hoesel's reports, that along with loss of the fibres between the *centre médian* and the *schalenförmiger Körper*, as well as the fibres between the *schalenförmiger Körper* and the "ventral nucleus in the narrower sense," there has actually been a great loss of ganglion cells in the *schalenförmiger Körper* on the side of the lesion. Further, the ventral part of the nucleus lateralis thalami is markedly atrophic, and great numbers of nerve cells have been destroyed in this region, especially in the ventral half of the occipital third of the nucleus lateralis thalami. In addition there was loss of cells in the lateral part of the *centre médian*. No alteration could be found, however, in the dorsal part of the *ansa lenticularis* (*Feld II<sub>2</sub>* of Forel, which Flechsig thinks represents a connection of the cerebellum, especially of the nucleus dentatus with the nucleus lentiformis) nor in the nucleus hypothalamicus.

As Tschermak emphasizes, the demonstration of the disappearance of such a large number of cells in the ventro-lateral group of nuclei of the thalamus lends to Hoesel's case a new significance and a new interest.

Hoesel's case proved the existence of a connection between the nucleus funiculi gracilis and the pars medialis of the nucleus funiculi cuneati of one side with the ventro-lateral group of nuclei of the thalamus and the central gyri (especially the posterior central gyrus) of the opposite side. Though Hoesel did not recognize the interruption of this connection in the thalamus, the bringing of the proof of the termination of this sensory *conduction path* in the central gyri—that is, more or less in the region which corresponds to the place of origin of the medullated axones of the centrifugal fasciculi cerebro-spinales—was an advance, the importance of which it is difficult to overestimate. That the *conduction path* between the medulla and the cortex consists in the main of at least two sets of superimposed *neurone systems* is clear from the later investigations.



Bielschowsky\* has studied the brains of two of Goltz's dogs, one almost two and a half years after removal of one cerebral hemisphere the other about nine months after removal of one hemisphere and two months after removal of the opposite hemisphere. In the first dog the corpus striatum on one side was also removed; in the second dog both corpora striata were extirpated, while the optic thalamus remained uninjured in both animals. Bielschowsky found secondary atrophy in the optic thalamus but no degeneration in the lemniscus, and therefore concludes that the fibres of the lemniscus do not extend beyond the thalamus, and that they can influence the cortex only through the intervention of neurones of a higher order.

Very important confirmatory work in this connection has been done by Jakob† and by the Dejerines.‡ The latter investigators have made sections of nineteen hemispheres, in which there were cortical lesions without involvement of the basal ganglia. The cortical lesion was more or less extensive, but in all these nineteen instances it involved the Rolandic region and the parietal lobe. In no one of the cases was the medial lemniscus degenerated. In three very old cases there was a slight diminution in the volume of the lemniscus, but this was due to simple atrophy and a diminution in calibre of the individual fibres, not to a decrease in the number of the fibres. In all nineteen cases there was intense secondary atrophy of the optic thalamus. They insist, therefore, that the path from the nuclei of Goll and Burdach in the medulla to the cerebral cortex consists of at least two neurones—(1) an inferior or bulbo-thalamic neurone corresponding to the medial lemniscus, and (2) a superior or cerebral neurone connecting the thalamus with the cerebral cortex. Von Bechterew's elaborate scheme of the central paths is reproduced in Fig. 456.

The view advanced by Flechsig and Bechterew, according to which the lemniscus forms connections with the nucleus hypothalamicus of Luys and the globus pallidus by means of

---

\* Bielschowsky, M. Obere Schleife und Hirnrinde. *Neurol. Centralbl.*, Leipz., vol. xiv (1895), S. 205-207.

† Jakob, C. Ein Beitrag zur Lehre von Schleifenverlauf (obere, Rinden-Thalamusschleife). *Neurol. Centralbl.*, Leipz., vol. xiv (1895), S. 308-310.

‡ Dejerine, J., et Mme. J. Dejerine. Sur les connexions du ruban de Reil avec la corticaleité cérébrale. *Compt. rend. Soc. de Biol., Par.*, 10. s., t. ii (1895), pp. 285-291.

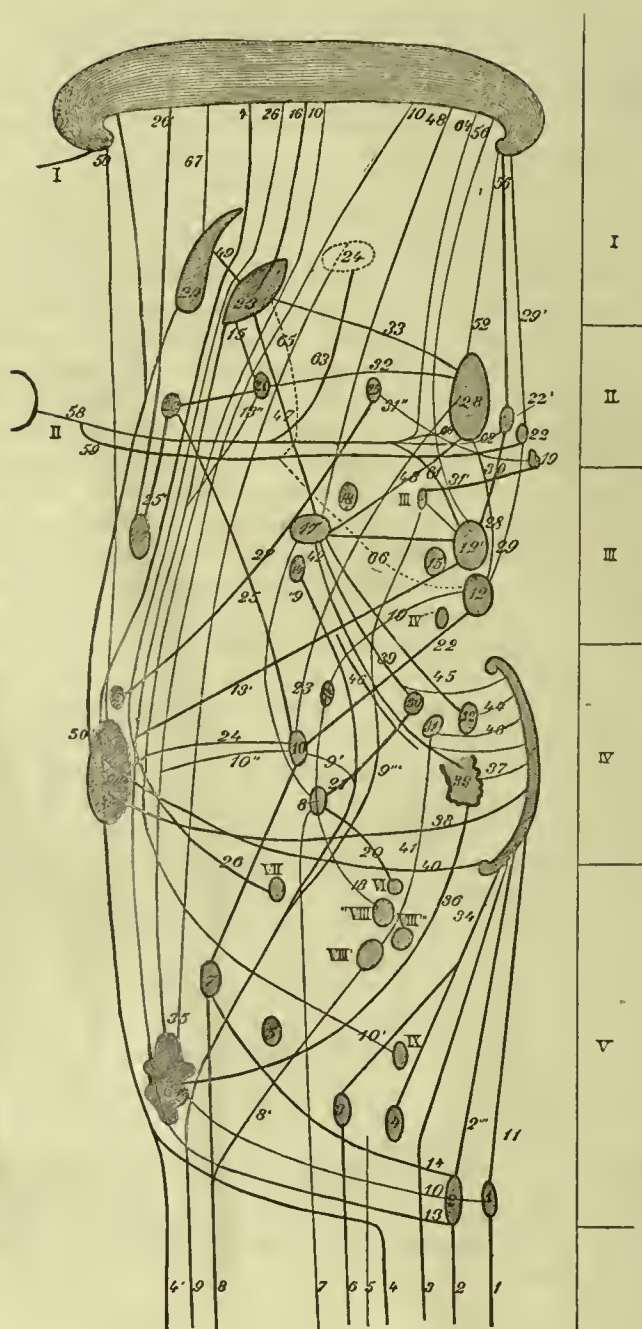


FIG. 456.—Central paths as at present understood with reference to the five embryonic subdivisions of the brain. (Scheme constructed by R. von Weinberg; taken from the chapter written by W. von Bechterew, in A. Rauber's textbook.) *Fibres*—1, fasciculus gracilis Golli; 2, fasciculus cuneatus Burdachii; 2'', fibres from the nucleus funiculi cuneati to the cerebellum; 3, fasciculus cerebello-spinalis or direct cerebellar tract of Flechsig; 4, fasciculi cerebrospinales (pyramidales); 4', fasciculus cerebro-spinalis ventralis; 5, fasciculus lateralis medialis; 6, fasciculus ventro-lateralis Gowersi; 7, fibres from fasciculus lateralis which ascend on the lateral surface of the medulla oblongata; 8, fasciculus lateralis et ventralis proprius passing into the formatio reticularis; 8', tract from the nucleus N. vestibuli lateralis (Deiters) to the fasciculus lateralis proprius; 9, fasciculus ventralis proprius; 9', 9'', fibres from the fasciculus ventralis proprius to the nucleus reticularis tegmenti and the nucleus centralis superior; 9''', fibres of the fasciculus longitudinalis medialis continuous with the fasciculus ventralis proprius; 10, fibres of the lemniscus medialis arising from the nucleus funiculi gracilis; 10', scattered bundles of the main portion of the lemniscus (from the nuclei terminales of the cerebral sensory nerves?); 10'', fibres from the lemniscus medialis to the nucleus reticularis tegmenti; 11, fibres from the nucleus funiculi gracilis to the cerebellum; 12, fibres of the main portion of the medial lemniscus arising from the nucleus funiculi cuneati; 13', 13'', fibres of the lemniscus medialis to the colliculus superior and to the nucleus hypothalamicus (corpus Luysi); 14, fibres from the nucleus funiculi cuneati to the nucleus centralis inferior (through the posterior decussation); 15, fibres connecting the nucleus hypothalamicus with the globus pallidus; 16, fibres from the globus pallidus to the cerebral cortex; 18, fibres of the corpus trapezoidum which go from the nucleus N. cochleæ ventralis to the nucleus olivaris superior and to the lemniscus lateralis; 19, fibres of the lemniscus lateralis; 20, fibres from the nucleus olivaris superior to the nucleus N. abducentis; 21, fibres connecting the nucleus fastigii with the nucleus olivaris superior; 22, fibres connecting the colliculus inferior with the nucleus reticularis tegmenti; 23, fibres from the region of the thalamus to the formatio reticularis; 24, fibres from the pons through the raphe to the formatio reticularis and to the nucleus reticularis tegmenti; 25, fasciculus pedunculo-mammillaris pars tegmentalis (*Hauzenbündel*, von Gudden); 25', fasciculus pedunculo-mammillaris pars basilaris (pedunculus corporis mammillaris); 26, accessory bundles of the lemniscus; 26', fibres connecting the substantia nigra with the cerebral cortex; 27, fasciculus retroflexus (Meynerti); 28, fibres from the nucleus colliculi inferioris to the thalamus (so-called *Oberescheitfe*, according to von Bechterew); 29, brachium quadrigeminum inferius; 29', fibres from the corpus geniculatum mediale to the cortex of the temporal lobe; 30, fibres connecting the colliculus superior with the corpus geniculatum laterale; 31', fibres of the commissura posterior cerebri (dorsal and ventral portion); 31'', fibres from the corpus pineale to the nucleus habenulae; 32, fasciculus thalamo-mammillaris (Vicq d'Azyri); 33, fibres connecting the

thalamus with the nucleus lentiformis; 34, fibres from the nuclei laterales to the cerebellum; 35, fasciculus centralis tegmenti (*centrale Haubenbahn*); 36, fibres connecting the nucleus olivaris inferior with the cerebellum; 37, fibres connecting the nucleus dentatus with the cortex of the cerebellum; 38, spinal bundle of the brachium pontis; 39, part of brachium conjunctivum; 40, cerebral bundle of brachium pontis; 41, fibres from the nucleus N. vestibuli superior (von Bechterew) and from the nucleus N. vestibuli lateralis (Deiters) to the cerebellum; 42, part of the brachium conjunctivum; 43, 44, fibres connecting the central nuclei of the cerebellum with the cerebellar cortex; 45, part of the brachium conjunctivum; 46, bundle forming a commissure between Bechterew's nuclei of the two sides and lying just ventral to the brachium conjunctivum; 47, 48, fibres from the nucleus ruber to the nucleus lentiformis, the thalamus, and the cerebral cortex; 49, fibres connecting the corpus striatum with the globus pallidus; 50, 50', fibres of the medial portion of the basis pedunculi connecting the lobus frontalis and the corpus striatum with the nuclei pontis; 52, fibres from the thalamus to the cerebral cortex; 56, fibres from the colliculus superior and the corpus geniculatum laterale to the lobus occipitalis; 57, fibres of the fornix; 58, radix lateralis tractus optici; 59, radix medialis tractus optici; 60, fibres from radix lateralis tractus optici to the thalamus; 61, fibres from same root to colliculus superior; 62, fibres from same root to the corpus geniculatum; 63, fibres from the tractus opticus to the gray matter about the ventriculus tertius; 64, direct hemispheric bundle of the optic tract (von Gudden); 65, fibres from the medial root of the optic tract to the nucleus lentiformis; 66, fibres from the medial root of the optic tract to the colliculus inferior; 67, fibres connecting the corpus striatum with the cerebral cortex. *Gray Masses*—I, nucleus funiculi gracilis; 2, nucleus funiculi cuneati; 3, nucleus lateralis ventralis; III, nucleus N. oculomotorii; 4, nucleus lateralis dorsalis; IV, nucleus N. trochlearis; 5, nucleus funiculi ventralis; 6, nucleus olivaris inferior; VI, nucleus N. abducens; 7, nucleus centralis inferior; 7, nucleus N. facialis; 8, nucleus olivaris superior; 8', nucleus N. vestibuli lateralis (Deiters); 8'', nucleus N. cochleæ ventralis; 8'', other acoustic nuclei; IX, nucleus terminalis N. glossopharyngei; 9, nuclei pontis; 10, nucleus reticularis tegmenti; 11, nucleus lenticuli lateralis; 12, nucleus colliculi inferioris; 12', colliculus superior; 13, ganglion interpedunculare; 14, nucleus centralis superior; 15, Bechterew's corpus parabigeminum; 16, substantia nigra; 17, nucleus ruber; 18, nucleus lateralis superior (Flechsig) or nucleus innominatus (von Bechterew); 19, corpus pineale; 20, nuclei corporis mammillaris; 21, nucleus hypothalamicus (corpus Luysi); 22, nucleus corporis geniculati medialis; 22', nucleus corporis geniculati lateralis; 23, nucleus lentiformis; 24, gray matter about the ventriculus tertius; 25, nucleus habenule; 28, thalamus; 29, corpus striatum; 30, nucleus fastigii; 31, nucleus globosus; 32, nucleus emboliformis; 33, nucleus dentatus.



the ansa lenticularis, is opposed by von Monakow and by the Dejerines. Von Monakow, from studying degenerations, thinks that the lenticular nucleus and the ansa lenticularis take no part in the formation of the lemniscus, or at the most an entirely minimal part. The Dejerines have examined three cases of very old lesions involving the island, the operculum, the putamen, the caudate nucleus, and the globus pallidus without injury of the internal capsule or the optic thalamus. In these cases there was a more or less pronounced degeneration of the ansa lenticularis and of the lenticulo-caudate fibres going to Luys' body. These degenerated fibres passed through the internal capsule and could be followed into Luys' body and into the thalamus, but there was absolutely no change in the medial lemniscus.

Flechsig, in his latest publications, does not distinguish sharply in the hypothalamic region the fibres which represent the upward continuation of the lemniscus from the other centripetal fibres of this area (fibres of the capsule of the red nucleus, fasciculus longitudinalis medialis, and longitudinal fibres of the formatio reticularis). He grants, however, that in all probability a large proportion of the fibres of the lemniscus are interrupted in the thalamus. Hoesel, again, in one of his later articles,\* has modified his earlier views so as to bring them more into accord with the doctrine of Mahaim and von Monakow. There is some danger in reading the articles of these various writers of misunderstanding just what each means by the term "cortical lemniscus" (*Rindenschleife*). The term indicates the portion of the lemniscus which is connected either directly or indirectly with the cortex. According to von Monakow, Mahaim, and others, all, or nearly all, of the "cortical lemniscus" is indirect—i. e., it is interrupted in the thalamus—while according to the view advanced by Hoesel in his first article the most of the "cortical lemniscus" is direct.

The utmost that can be said at present is that the weight of evidence is in favor of the view that the majority of the fibres of the medial lemniscus are interrupted in the thalamus, though some axones, helping to form the lemniscus, doubtless extend all the way from the nuclei of the medulla to the opposite cere-

---

\* Hoesel. Beiträge zur Anatomie der Schleifen. Neurol. Centralbl., Leipz., Bd. xiii (1894), S. 546-559.

bral cortex, since Tschermak\* has been able, after destruction of these nuclei in the cat, to follow degenerated fibres through the thalamus directly out to the cortex.

A full report of Tschermak's investigations in this connection has been subsequently published.† In his experiments he destroyed the nuclei of the funiculi in three cats. The symptoms which resulted corresponded to those previously found by von Bechterew‡ in dogs, and by Ferrier and Turner\* in monkeys.

Von Bechterew in dogs injured the nucleus funiculi gracilis. The animals tumbled about when they attempted to walk, and swayed on standing. There was no disturbance of cutaneous sensibility to be made out. Similar symptoms could be produced by cutting the funiculus gracilis in the upper part of the pars cervicalis of the spinal cord.

In monkeys, Ferrier and Turner found as symptoms resulting from injury to the dorsal funiculi restlessness on the part of the animals and a sprawling character to the body on exertion, and the animals exhibited a tendency to fall backward. As far as they could make out, the sensations of touch and pain were unimpaired, and the capacity for localization did not appear to be disturbed. The interference with the equilibrium of the animals vanished in a few days.

Tschermak's cats showed marked symptoms at first of disturbance of equilibrium, but these soon disappeared. On the first or second day after the lesion the cats, on attempting to walk, deviated constantly toward the side of the lesion, and often fell when they attempted to use the paw of the injured side. While the contra-lateral fore paw could be used almost normally, the homo-lateral leg sprawled about on attempts to move it. One animal kept the hind leg on the affected side lifted when it walked. Even on sitting, all three animals showed lateral

\* Tschermak, A. Notiz betreffs des Rindenfeldes der Hinterstrangbahnen. *Neurol. Centralbl.*, Leipz., Bd. xvii (1898), S. 159-162.

† *Op. cit.*, *Arch. f. Anat. u. Physiol.*, Anat. Abth., Leipz. (1898), S. 291-400.

‡ von Bechterew, W. *Arch. f. Anat. u. Physiol.*, Anat. Abth., Leipz. (1890), S. 489.

\* Ferrier, D., and Turner, W. A. A Record of Experiments illustrative of the Symptomatology and Degenerations following Lesions of the Cerebellum, etc. *Phil. Tr., Lond.*, vol. elxxxv, B, pt. 2, p. 755.

swaying to the side of lesion. Cutaneous sensibility appeared to be normal. After from two to five days the disturbances of equilibrium had practically disappeared, though in one case marked symptoms continued until the death of the animal at the end of sixteen days.

The consensus of opinion at present is, therefore, that destruction of the nuclei of the dorsal funiculi does not interfere with the sense of touch, the sense of pain, or the capacity for localization, as far as the skin is concerned. The long fibres of the dorsal funiculi, accordingly, can scarcely be concerned in the mediation of the centripetal impulses concerned in these sensations. Their function appears to be rather that of conduction of the impressions of muscular sense, a view which is supported by observations in tabes and other pathological conditions in human beings.

In Fig. 457 I have reproduced some of the illustrations accompanying Tschermak's article, which show degenerations as revealed by Marchi's method after destruction of the nuclei of the dorsal funiculus, and some of the parts just ventral to this. The *fibræ arcuatæ internæ* are seen to be markedly degenerated. The finer blackened fibres going to the nucleus *N. hypoglossus* and to the lateral and ventral portions of the *formatio reticularis grisea* probably correspond to degenerated collaterals. Large numbers of degenerated fibres can be seen passing into the nucleus *olivaris inferior*. A moderate number of degenerated fibres extend from the degenerated *contra-lateral stratum interolivare lemnisei* along the periphery of the medulla into the ventral part of the *corpus restiforme*. On their way to the cerebellum some degenerated fibres go into the vestibular nuclei. The degeneration in the *formatio reticularis alba*, including the *fasciculus longitudinalis medialis*, is well shown, but is due not to the injury of the nuclei of the dorsal funiculi, but rather to the destruction of the parts ventral to this at the time of operation.

The degenerated *interolivary layer* can be followed in the pons into the *lemniscus medialis*. Fine degenerated fibres can be seen passing from the *lemniscus dorsalward* into the *formatio reticularis grisea*, and also *ventralward* into the nuclei *pontis*. Higher up distinct bundles of degenerated fibres can be followed into the nucleus *colliculi inferioris*. Higher there are fine degenerated fibres passing *medialward* to the *formatio reticularis*,

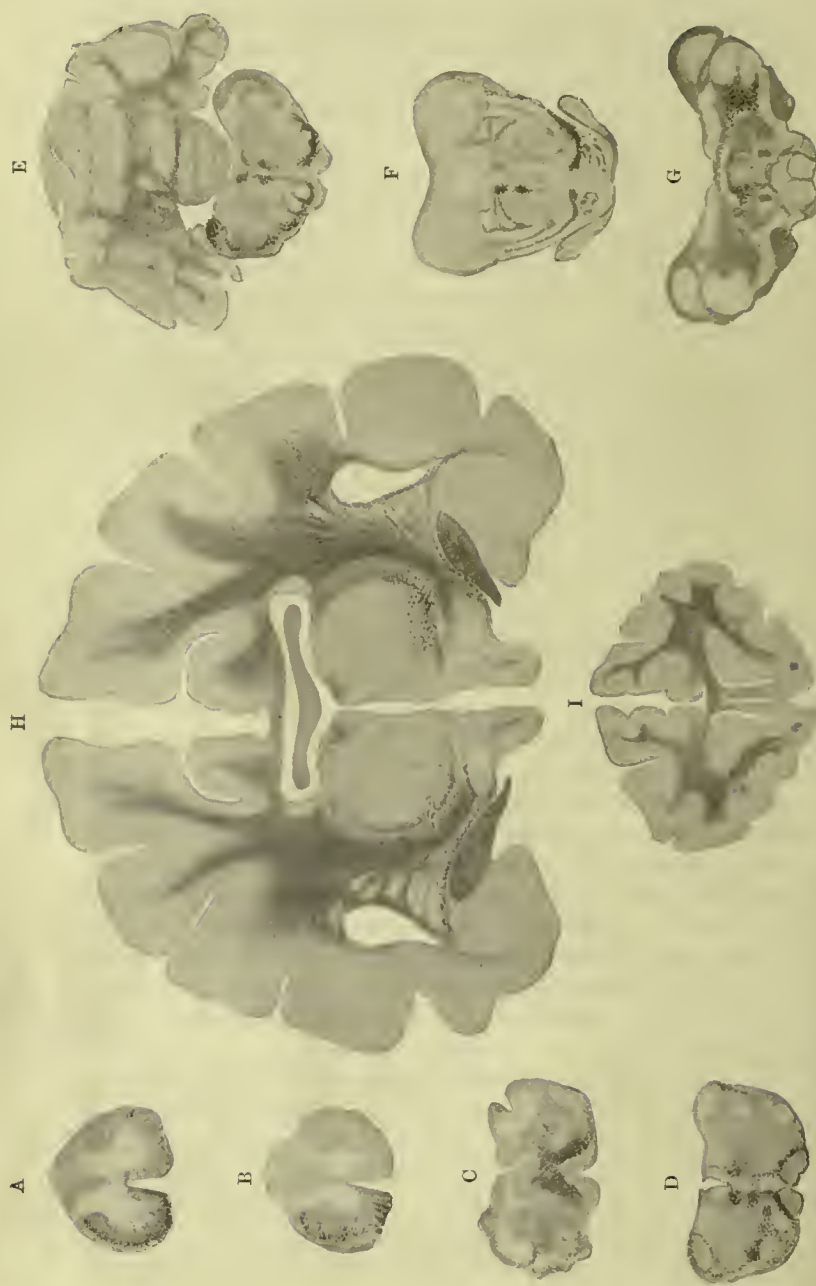


FIG. 457.—Degeneration shown by Marchi's method after destruction of the nuclei of the dorsal funiculi and parts just ventral to them on one side of the medulla oblongata of a cat. (After A. Tscherniak, *Arch. f. Anat. u. Physiol.*, 1898, Taf. xv, Figs. 2 to 10.)



and ventralward into the substantia nigra. In the hypothalamic region the degenerated fibres of the lemniscus lie scattered over a rather large area situated medial to the corpus geniculatum mediale. Farther frontalward they pass into the hilus thalami. The area of degeneration in the tegmentum is approximately triangular in shape in cross section. From the dorsal apex of this triangular area single blackened fibres can be followed through the pars dorsalis of the commissura posterior cerebri to the nucleus lateralis superior of the opposite side. Of the fibres which pass into the hilus thalami a great number seem to disappear in the ventral nuclei of the thalamus, but many run into the lamina medullaris media, and into the lamina medullaris lateralis as well as into the lateral half of the zona reticularis (*Thalamusschale*).

The rest of Tschermak's description is of the deepest interest. He follows a considerable number of single fine collaterals (never in bundles) radiating out to the ventral and ventro-lateral parts of the reticular zone to pass transversely into the basis pedunculi and into the capsula interna. Of the fibres which pass farthest ventralward, some go medio-ventrally into the nucleus hypothalamicus (corpus Luysi); farther on single fibres can be followed into the commissura superior Meynerti (or so-called commissura hypothalamica), which passes down between the basis pedunculi and the tractus opticus. They extend to the nucleus lentiformis of the opposite side.

But in addition to these Tschermak is able to follow a much greater number of isolated degenerated fibres through the capsula interna into the nucleus lentiformis; these fibres appear as fine blackened droplets, especially in the globus pallidus. A number of somewhat coarser fibres pass through the laminae medullares (and also probably through the capsula interna) to enter the corona radiata. Most of the fibres, however, which enter the corona radiata arrive there directly by way of the capsula interna. These degenerated fibres of the corona radiata pass out, according to Tschermak, chiefly to the cortex of the gyrus coronalis, and to the adjacent marginal parts of the gyrus ectosylvius (pars anterior), and to the gyrus suprasplenius (pars anterior), without, however, going to the gyrus fornicatus seu cinguli. The cortical distribution of these fibres is well illustrated in Fig. 458.

As a result of his studies, Tschermak concludes that four

principal central-axone neurone systems originate in the nuclei of the dorsal funiculi. The first two of these systems which pass to the cerebellum have already been described in Chapter XXXIX. The other two systems which pass to the cerebrum demand further discussion here.\*

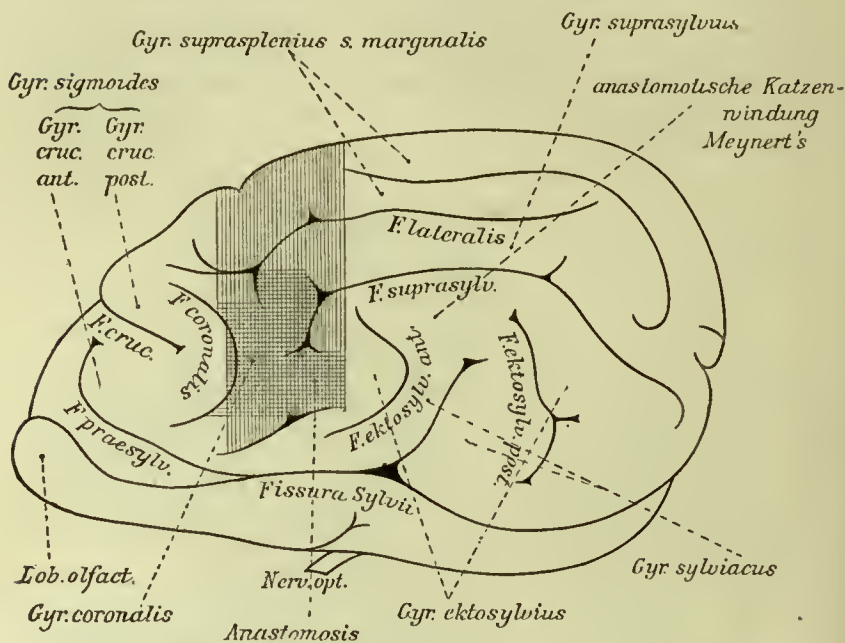


FIG. 458.—Cortical area of termination of lemniscus fibres in the cat. (After A. Tschermak, Arch. f. Anat. u. Physiol., Anat. Abth., Leipz., 1898, S. 353, Fig. 2.)

The medullated axones of these two neurone systems are those which we have already seen passing as internal arcuate fibres through the decussatio lemniscorum into the stratum interolivare lemnisci and into the lemniscus medialis (Figs. 308, 309, 322, and 323, *vide supra*). While the majority of investigators who have worked with Marchi's method have never been able to follow degenerated fibres of the lemniscus above the thalamus, Tschermak has succeeded, as we have seen, in following in his three cats a certain number of fibres still farther, even to the cerebral cortex. He concludes, therefore, that a

\* Die beiden kreuzenden Hinterstrangkern-Grosshirnsysteme (Hinterstrangkern-Hauptschleifensysteme) of Tschermak.

not inconsiderable number of fibres from the nuclei of the dorsal funiculi of the opposite side, instead of definitely terminating in the thalamus, pass through it in the form of scattered fibres.

These longer fibres, which do not stop in the thalamus, follow different paths. All those most ventrally situated in the radiating fan of the lemniscus medialis (*Hauptschleife*) very soon break through the narrow ventral marginal zone of the zona reticularis (*Thalamusschale*) and pass in a curved direction latero-ventralward to enter the basis pedunculi. Farther on a number of other fibres more laterally situated follow the same course. It is just at this level that the white fibres of the basis pedunculi are continuous latero-dorsalward with the capsula interna which lies between the zona reticularis and the nucleus lentiformis. The most ventro-medial portion of the fibre-mass surrounds the nucleus hypothalamicus.\* The degenerated fibres referred to are found in the cat to give off, on passing through the basis pedunculi, collaterals to the nucleus hypothalamicus which lies medially from them. A relatively smaller part of the degenerated fibres here turn medialward and run along the ventral margin of the basis pedunculi; they lie immediately upon the tractus opticus and run toward the region of the tuber cinereum. These fibres form one constituent of the commissura superior Meynerti (commissura hypothalamica media of Meynert), and after crossing the middle line arrive, by a similar path between the peduncle and the optic tract, in the globus pallidus of the nucleus lentiformis of the other side. According to Tschermak, therefore, this commissure is part of a high decussation of axones of the neurone system which extends from the nuclei of the dorsal funiculi to the cerebral cortex.

The greater part, however, of those fibres which go ventrally and ventrolaterally out of the thalamus and pass through the basis pedunculi arrive in the nucleus lentiformis of the same side, partly by running lengthwise (at first along its base and then bending up into the nucleus), partly by crossing over directly into the globus pallidus. It would seem likely, at first thought, from the large number of degenerated fibres met with here, that the globus pallidus receives no inconsiderable number of such fibres, but Tschermak states that in reality not very

---

\* In the cat this structure is by no means so definite and compact a lens-shaped mass as in man.

many stem fibres terminate here, the majority of terminals in this region being collaterals. On the other hand, he is of the opinion that the majority of the fibres (chiefly by way of the lamina medullaris medialis and the lamina medullaris lateralis, but in part, also, by way of the layer of white matter between the putamen and the cortex of the island of Reil) leave the nucleus lentiformis again in order to pass through the corona radiata, and finally arrive in the cortex of the pallium. The axones then from the nuclei of the dorsal funiculi which go directly to the pallium make a curious loop-shaped excursion through the nucleus lentiformis. A certain number of the so-called *direct* fibres pass straight through the zona reticularis on their way from the thalamus to the capsula interna, and ascend into the corona radiata, especially along the oblique dorsal surface of the nucleus lentiformis.

If other investigations confirm the results of Tschermak, I would suggest that the system sending axones from the nuclei of the dorsal funiculi, without interruption to the cerebral cortex be called the *systema (neuronicum) myelencephalo-palliale*.<sup>\*</sup> On the other hand, the system sending axones from the nuclei of the dorsal funiculi to terminate in the ventral region of the thalamus of the opposite side could be designated the *systema (neuronicum) myelencephalo-thalamicum*.<sup>†</sup> Whether or not a *systema (lemniscale) myelencephalo-palliale* actually exists in human beings remains to be proved. The proof of the existence of such a system in the cat, however, taken together with the researches of Hoessel and of Flechsig on human beings, make it unsafe to deny its possibility.

Tschermak discusses in his article the portion of the cortex in which the direct cortical lemniscus terminates in the cat and attempts to arrive at certainty with regard to the corresponding region in man. Whereas many observers have considered the crucial sulcus of the dog's brain as the equivalent of the sulcus centralis Rolandi of human beings, Meynert<sup>‡</sup> was the first to recognize that the fissura coronalis, not the fissura cruciata, of the cat is the homologue of the sulcus centralis

<sup>\*</sup> *Das kreuzende Hinterstrangkern-Grosshirnrindensystem* of Tschermak.

<sup>†</sup> *Das kreuzende Hinterstrangkern-Thalamussystem* of Tschermak.

<sup>‡</sup> Meynert, Th. Die Windungen der convexen Oberfläche des Vorderhirns bei Menschen, Affen und Raubthieren. Arch. f. Psychiat., Berl. (1876), Bd. vii, S. 257.



of man. All the evidence goes to prove that this view is correct, and Tschermak agrees with Meynert. He assumes, therefore, that his direct cortical system of the lemniscus in the cat ends in the region of the cortex homologous with the gyrus centralis posterior of man.

The best review of the history of the development of our knowledge concerning the lemniscus I know of is that given by Tschermak.\* Since this has appeared so recently (1898), and, moreover, has been published in a journal generally accessible, it has not seemed necessary to make any attempt at an exhaustive review of the literature here. It has seemed to me wiser to lay emphasis upon the main features of the subject, citing only the more important researches rather than to deal very fully with all publications bearing on the topic, for in the domain of the lemniscus, perhaps more than anywhere else in the central nervous system, the beginner, on approaching the bibliographic forest, runs in danger of "losing sight of the wood on account of the trees."

For those who wish to delve deeper into the bibliography, however, the articles of Flechsig,† Edinger,‡ von Bechterew,§

\* *Op. cit.*

† Flechsig, P. Die Leitungsbahnen im Gehirn und Rückenmark, etc. Leipzig, 8vo. (1876).—Ueber die Verbindungen der Hinterstränge mit dem Gehirn. *Neurol. Centralbl.*, Leipz., Bd. iii (1885), S. 97-100.—Zur Lehre vom centralen Verlauf der Sinnesnerven. *Ibid.*, Bd. v (1886), S. 545-551.—Zur Anatomie und Entwicklungsgeschichte der Leitungsbahnen im Grosshirn des Menschen. *Arch. f. Anat. u. Physiol., Anat. Abth.*, Leipz. (1881), S. 12-75.—Plan des menschlichen Gehirns. Auf Grund eigener Untersuchungen entworfen, 8vo, Leipz. (1883).—Die Localisation der geistigen Vorgänge mit besonderer Berücksichtigung der Sinnesempfindungen des Menschen. Leipz. (1896).

‡ Edinger, L. Zur Kenntniss des Verlaufes der Hinterstrangfasern in der Medulla oblongata und im hinteren Kleinhirnschenkel. *Neurol. Centralbl.*, Leipz., Bd. iii (1885), S. 73-76.

§ von Bechterew, W. Untersuchungen ueber die Schleifensehicht. *Ber. d. math. phys. Cl. d. k. sächs. Gesellsch. d. Wissensch.*, Leipz. (1885), 4 Mai.—Ueber eine bisher unbekannte Verbindung der grossen Oliven mit dem Grosshirn. *Neurol. Centralbl.*, Leipz., Bd. iv (1885), S. 194-196.—Ueber die Schleifensehicht auf Grunde der Resultate von nach der entwickelungsge-  
schichtlichen Methode ausgeführten Untersuchungen. *Arch. f. Anat. u. Physiol., Anat. Abth.*, Leipz. (1895), S. 379-395.—Die Leitungsbahnen im Gehirn und Rückenmark. Deutsch von R. Weinberg, II. Aufl., Leipzig (1899).

Darkschewitsch and Freud, \* and Cramer † on myelination, those of Meyer, ‡ Schultze, \* Spitzka, || Schrader, ^ von Monakow, ◇ Mahaim, † Vejas, ‡ Loewenthal, ‡ Gebhard, \*\* von Bechterew, †† Werdnig, †† Rossolimo, \*\* Dejerine, || Schaf-

\* Darkschewitsch, L., and S. Freud. Ueber die Beziehung des Strickkörpers zum Hinterstrang und Hinterstrangkern, nebst Bemerkungen ueber zwei Felder der Oblongata. Neurol. Centralbl., Leipz., Bd. v (1886), S. 121-129.

† Cramer, A. Beiträge zur feineren Anatomie der Medulla oblongata, der Brücke, etc. Jena (1894).

‡ Meyer, P. Ueber einen Fall von Ponshämorrhagie mit secundären Degenerationen der Schleife. Arch. f. Psychiat., Berl., Bd. xiii (1882), S. 63-98.

\* Schultze, F. Beiträge zur Pathologie und pathologischen Anatomie des centralen Nervensystems. Arch. path. Anat. etc., Berl., Bd. lxxxvii (1882), S. 510-540.

|| *Op. cit.*

^ Schrader, A. Ein Grosshirnschenkelherd mit secundären Degenerationen der Pyramide und Haube. 8vo, Halle, 1884.

◇ von Monakow, C. Experimentelle und pathologisch-anatomische Untersuchungen ueber die Beziehungen der sogenannten Sehsphäre zu den infracorticalen Opticuseentren und zum N. opticus. Arch. f. Psychiat., Berl., Bd. xvi (1885), S. 151; 317.—Experimentelle und pathologisch-anatomische Untersuchungen ueber die Haubenregion, den Sehhügel und die Regio subthalamica, nebst Beiträgen zur Kenntniss früh erworbener Gross- und Kleinhirn defecte. Arch. f. Psychiat., Berl., Bd. xxviii (1895), S. 1; 386.

‡ Mahaim, A. *Op. cit.*

‡ Vejas, P. Experimentelle Beiträge zur Kenntniss der Verbindungsbahnen des Kleinhirns und des Verlaufs der Funiculi graciles und cuneati. Arch. f. Psychiat., Berl., Bd. xvi (1885), S. 200-214.

‡ Loewenthal, N. Note relative à l'atrophie unilatérale de la colonne de Clarke observée chez un jeune chat, opéré à la partie inférieure du bulbe rachidienne dans la première quinzaine après la naissance. Rev. méd. de la Suisse rom., Genève, t. vi (1886), pp. 20-27.

\*\* Gebhard, F. Secundäre Degenerationen nach tuberkulöser Zerstörung des Pons. 8vo, Halle (1887).

†† von Bechterew, W. Zur Frage über die secundären Degenerationen des Hirnschenkels. Arch. f. Psychiat., Berl., Bd. xix (1887), S. 1-17.

†† Werdnig, G. Concrement in der rechten Substantia nigra Sömmerringii mit auf- und absteigender Degeneration der Schleife und theilweiser Degeneration des Hirnschenkelfusses. Med. Jahrb., 1888, Wien, n. F., Bd. iii (1889), S. 447-477.

\*\* Rossolimo, G. Zur Physiologie der Schleife (Ein Fall von Gliomatose eines Hinterhorns des Rückenmarks). Arch. f. Psychiat., Berl., Bd. xxi (1889-'90), S. 897-909.

|| Dejerine, J. Sur un cas d'hémianesthésie de la sensibilité générale, observé chez un hémiplegique et relevant d'une atrophie du faisceau rubané

fer,\* Hensehen,† Singer and Münzer,‡ Mingazzini,\* Hoesel,|| Bruce,<sup>^</sup> Hoffmann,◇ Mott,↓ Ferrier and Turner,↑ Greiwe,‡ Bielschowsky,\*\* Müller and Meder,†† Schlesinger,‡‡ Saxer,\*\* Mayer||| on degenerations (in human beings and in experimental animals), may be recommended.

de Reil. *Arch. de physiol. norm. et path.*, Par., 5. s., t. ii (1890), pp. 558–570.—Dejerine, J., et Dejerine, Mme. J. *Sur les connexions du ruban de Reil avec la corticalité cérébrale.* *Compt. rend. Soc. de biol.*, Par., 10. s., t. ii (1895), pp. 285–291.

\* Schaffer, K. *Beitrag zur Lehre der secundären und multiplen Degeneration.* *Arch. f. path. Anat. etc.*, Berl., Bd. cxxii (1890), S. 125–145.

† Hensehen, S. E. *Klinische und anatomische Beiträge zur Pathologie des Gehirns.* Th. I, Upsala (1890), S. 48; 65.

‡ Singer, J., et E. Münzer. *Beiträge zur Anatomie des Centralnervensystems, insbesondere des Rückenmarkes.* *Denkschr. d. Akad. d. Wissensch.*, Wien, Math.-naturw. Cl., Bd. lvii (1890), S. 569.

\* Mingazzini, G. *Intorno al decorso delle fibre appartenenti al pedunculus medius cerebelli ed al corpus restiforme.* *Arch. per le sc. med.*, Torino e Palermo, vol. xiv (1890), pp. 245–262.—*Pathologisch-anatomische Untersuchungen über den Verlauf einiger Nervenbahnen des Centralnervensystems des Menschen.* *Beitr. z. path. Anat. u. z. allg. Path.*, Jena, Bd. xx (1896), S. 413–476.

|| *Op. cit.*

<sup>^</sup> Bruce, A. *On a Case of Descending Degeneration of the Lemniscus, Consequent on a Lesion of the Cerebrum.* *Brain*, Lond., vol. xvi (1893), pp. 465–474.

◇ Hoffmann, J. *Zur Lehre von der Syringomyelie.* *Deutsche Ztschr. f. Nervenhe.*, Leipz., Bd. iii (1892–'93), S. 1–136.

↓ *Op. cit.*

◇ *Op. cit.*

‡ Greiwe, J. *Ein solitärer Tuberkel im rechten Grosshirnschenkel beziehungsweise in der Haube, mit Degeneration der Schleife.* *Neurol. Centralbl.*, Leipz., Bd. xiii (1894), S. 130; 184.

\*\* *Op. cit.*

†† Müller, F., und E. Meder. *Ein Beitrag zur Kenntniss der Syringomyelie.* *Ztschr. f. klin. Med.*, Berl., Bd. xxviii (1895), S. 117–138.

‡‡ Schlesinger, H. *Bemerkungen über den Aufbau der Schleife.* *Neurol. Centralbl.*, Leipz., Bd. xv (1896), S. 146.—See also, *Arb. a. d. Inst. d. Centralnervensyst. a. d. Wien Univ.* (1896), II. 4.

\*\* Saxer, F. *Anatomische Beiträge zur Kenntniss der sogenannten Syringomyelie.* *Beitr. z. path., Anat. u. z. allg. Path.*, Jena, Bd. xx (1896), S. 332–398.

|| Mayer, C. *Zur Kenntniss des Faserverlaufes in der Haube des Mittel- und Zwischenhirns auf Grund eines Falles von secundärer aufsteigender Degeneration.* *Jahrb. f. Psychiat.*, Leipz. u. Wien, Bd. xvi (1897), S. 221–233.

## CHAPTER XLVIII.

### CENTRIPETAL FIBRES IN THE FASCICULUS LONGITUDINALIS MEDIALIS.

Cases of secondary degeneration—Studies by Golgi's method—The nucleus of Darkschewitsch—Adjacent bundles of white fibres in the developing brain.

#### (b) *The Fasciculus Longitudinalis Medialis.*

THE course and relations of the axones in this bundle have been the subject of much dispute, and although an immense amount of work has been done to determine the origin and termination of its constituent fibres, we are still unable to make entirely positive statements in this connection. The connections of the bundle below with the upward continuation of the fasciculi proprii of the ventral and lateral funiculi of the cord are certain. The connection between the two is formed by means of a well-marked curve (Fig. 459). The intimate relation of the bundles to the eye muscle nuclei in the midbrain is also very definite, but just how far downward fibres extend and just how far upward its fibres reach we do not yet know. Nor are we certainly informed as to the exact number of ascending fibres and the exact number of descending fibres in the fasciculus. While many observers assume that the majority of fibres descend—that is, are centrifugal in conduction direction, having mainly to do with reflex activities—others hold that the majority of the fibres ascend and are centripetal in conduction direction, representing the sensory limb of reflex arcs and possibly a central conduction path for the passage of sensory impulses toward the cerebral cortex.

The study of cases of secondary degeneration thus far has thrown but little light upon the subject, though in the case studied by Jakovenko \* the degeneration of the bundle stopped

---

\* Jakovenko, V. K. vopr. o stroenii zadnjago prodol. puchka (fasciculus longitudinalis medialis). Vestnik klin. i sudebnoi psichiat. i nevroptatol., St. Petersburg, vol. vi, pt. i (1888), pp. 89-98.



suddenly anteriorly on reaching the level of the nucleus of Darkschewitsch.

Golgi's method has proved definitely the existence of numerous axones passing into the fasciculus longitudinalis medialis, axones which have had their origin in the cell bodies or

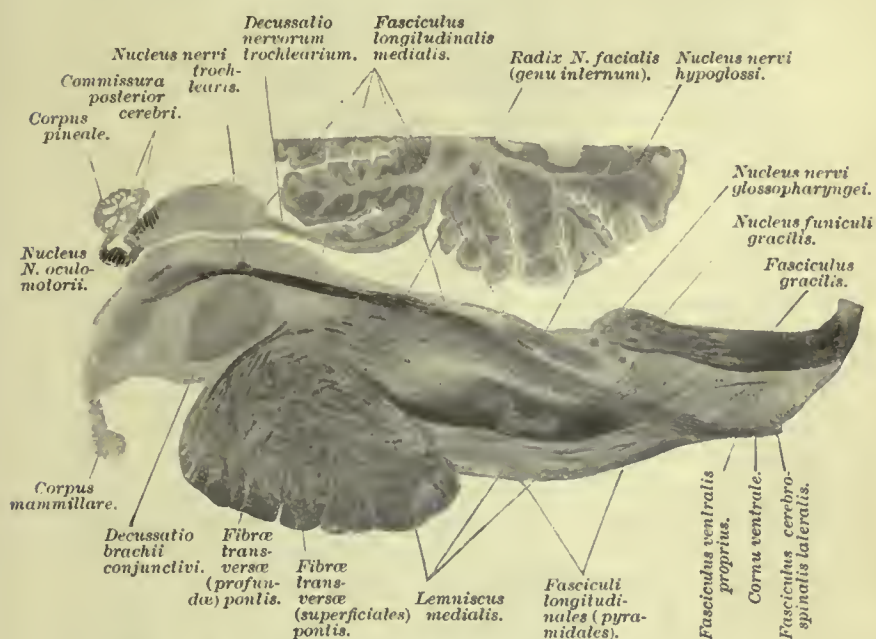


FIG. 459.—A sagittal section of the medulla oblongata, pons, and mesencephalon parallel and close to the middle line; child aged three months; method of Weigert. (After A. Bruce, Illustrations of the Nerve Tracts in the Mid and Hind Brain and the Cranial Nerves arising therefrom. Edinb. and Lond., 1892, pl. xxvii, Fig. 1.) The fasciculus longitudinalis medialis and its relation to the fasciculus ventralis proprius of the spinal cord are particularly well shown.

dendrites of neurones situated in the nuclei of termination of the sensory cerebral nerves. Axones of the cerebral conduction path connected with the vestibular and other sensory nuclei entering the fasciculus longitudinalis medialis have been referred to above. On the other hand, Golgi preparations of the midbrain have shown large numbers of axones passing from cells in the superior colliculus of the corpora quadrigemina and in the nucleus of Darkschewitsch, which pass ventral to the nucleus nervi oculo-motorii to decussate with correspond-

ing fibres in the middle line and to enter the ventral portion \* of the fasciculus longitudinalis medialis to descend in it. Simi-



FIG. 460.—Sagittal section through brain of fetal mouse in plane of the fasciculus longitudinalis medialis. (After S. Ramón y Cajal, *Beitrag zum Studium der Medulla Oblongata, etc.*, Leipz., 1896, p. 54, Fig. 14.) *A*, fasciculus longitudinalis medialis at level of pons; *B*, collaterals from it to nucleus *N. trochlearis*; *C*, collaterals to nucleus *N. oculo-motorii*; *D*, end ramifications in nucleus fasciculi longitudinalis medialis; *E*, fibres going past the fasciculus retroflexus to enter the thalamus; *F*, fasciculus retroflexus Meynerti; *G*, nucleus ruber; *H*, ganglion interpedunculare; *I*, aqueductus cerebri; *L*, space between corpus mammillare and pons; *a*, cell in ganglion interpedunculare; *b*, fibres of decussatio tegmenti dorsalis Meynerti; *d*, lower motor neurones in nucleus *N. oculo-motorii*; *j*, cells of stratum griseum centrale with ascending axones.

\* The so-called *praedorsales Langsbündel* of the Germans.

lar axones arising from the superior lateral nucleus of Flechsig pass into the fasciculus longitudinalis medialis of the same side, or after decussation into that of the opposite side, from which point they descend. It remains for future work to determine the relative number of ascending and descending fibres. It is believed by van Gehuchten that in the trout and salamander the majority of the fibres of the bundle descend (motor and reflex fibres). Large numbers of collaterals are given off from the fibres, probably from both ascending and descending fibres of the fasciculus longitudinalis medialis to the various gray masses with which it comes into contact relation in its course (nucleus nervi trochlearis, nucleus nervi oculo-motorii, formatio reticularis grisea). (Fig. 460.)

The relations of the fasciculus longitudinalis medialis at its anterior extremity are peculiarly puzzling, and one has only to read the descriptions in the various text-books and in the original articles dealing with this topic to appreciate the confusion which exists with regard to it. Especially conflicting are the views which have been held concerning the relations to the nucleus of Darkschewitsch, and to the gray matter of the hypothalamic region. It would be unfruitful to discuss at length, in the present state of our knowledge, the various theories which have been advanced. I shall restrict myself, therefore, in the main, to a mere statement of the results of my own studies, and of those of Miss Sabin and Miss Stein, who have especially studied this region.

As the fasciculus longitudinalis medialis is followed forward it is found in the region of the nucleus nervi trochlearis as a compact bundle which at this level begins to bend ventralward as it continues its course toward the cerebrum. The fibres of the fasciculus longitudinalis medialis come into very intimate relation with the nuclei of the N. trochlearis and of the N. oculo-motorius (Fig. 461), and in this region the medial fibres of the fasciculi of the two sides curve ventralward and medialward, and come into contact with one another in the middle line, so that the eye muscle nuclei lie in a long trough extending throughout their whole length.

The nucleus of Darkschewitsch,\* situated somewhat anterior-

---

\* Cf. Darkschewitsch, L. Einige Bemerkungen ueber den Faserverlauf in der hinteren Commissur des Gehirns. Neurol. Centralbl., Leipz., Bd. v (1886), S. 99-103.



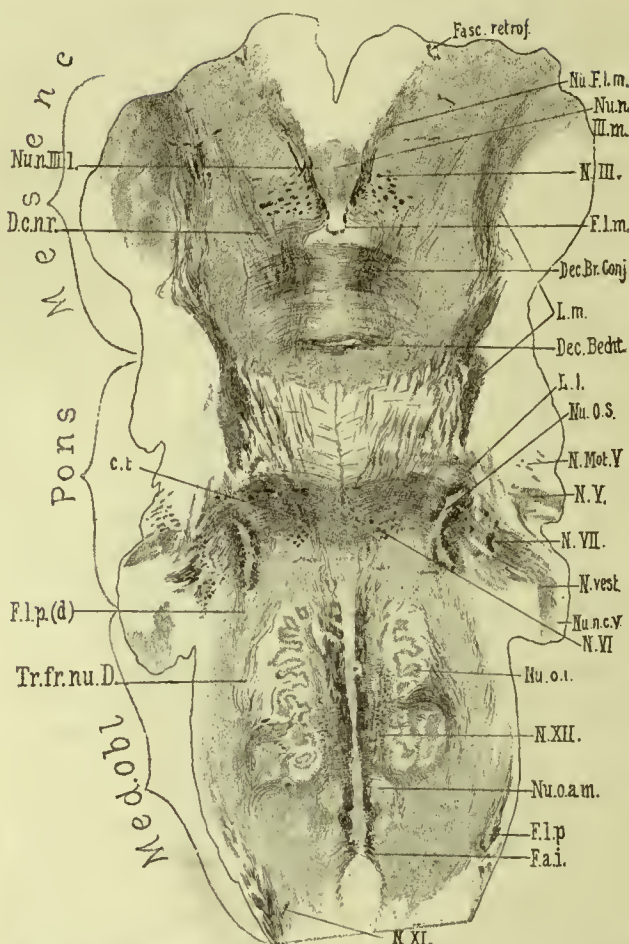


FIG. 461.—Horizontal section through the medulla, pons, and midbrain of a newborn babe. Weigert-Pal staining. Level of dorsal part of corpus trapezoidum and dorsal portion of nucleus olivaris inferior. (Series iii, section No. 122.) *C.t.*, corpus trapezoideum; *Dec. Br. Conj.*, decussatio brachii conjunctivi; *Dec. Becht.*, commissure between Bechterew's nuclei; *D.c.n.r.*, dorsal capsule of nucleus ruber; *F.a.i.*, fibre arcuata internæ; *Fasc. retrof.*, fasciculus retroflexus Meynerti; *F.l.m.*, fasciculus longitudinalis medialis; *F.l.p.*, bundle continuous with the fasciculus lateralis proprius of the cord; *F.l.p.(d)*, dorsal portion of bundle continuous with fasciculus lateralis proprius of the cord; *L.l.*, lemniscus lateralis; *L.m.*, lemniscus medialis; *N. III.*, radix N. oculomotorii; *N. Mot. V.*, motor root of N. trigeminus; *N. V.*, sensory root of N. trigeminus; *N. VI.*, radix N. abducentis; *N. VII.*, radix N. facialis, pars secunda; *N. vest.*, radix N. vestibuli; *N. XI.*, radix N. accessorii; *N. XII.*, radix N. hypoglossi; *Nu. F.l.m.*, nucleus fasciculi longitudinalis medialis, or nucleus commissure posterioris (*oberer Oculomotoriuskern* of Darkschewitsch); *Nu. n. III.m.*, pars impar of nucleus N. oculomotorii; *Nu. n. III.l.*, pars lateralis of nucleus N. oculomotorii; *Nu. o.s.*, nucleus olivaris superior; *Nu. n.c.V.*, nucleus N. cochleæ ventralis; *Nu. o.i.*, nucleus olivaris inferior; *Nu. o.a.m.*, nucleus olivaris accessorius medialis; *Tr.fr.nu.D.*, tract from Deiters' nucleus to the spinal cord. (Preparation by Dr. John Hewetson.)



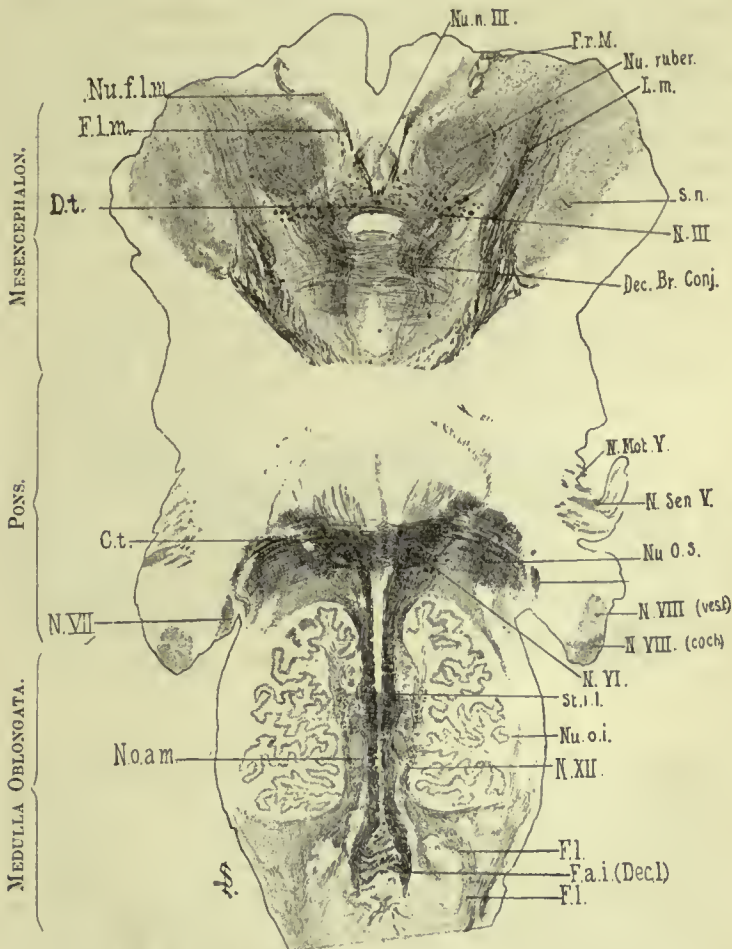


FIG. 462.—Horizontal section through the medulla, pons, and midbrain of newborn babe. Level of stratum interolivare lemnisci, corpus trapezoideum and nucleus ruber. Weigert-Pal staining. (Series iii, section No. 136.) *Ct.*, corpus trapezoideum; *Dec.Br.Conj.*, decussatio brachii conjunctivi; *Dt.*, decussatio tegmenti ventralis (ventral tegmental decussation of Forel); *Fa.i.(Decl.)*, fibre arcuate interne (decussatio lemniscorum); *Fl.*, fibres continuous with the funiculus lateralis of the spinal cord; *Fl.m.*, fasciculus longitudinalis medialis; *Fr.M.*, fasciculus retroflexus Meynerti; *L.m.*, lemniscus medialis; *N.III.*, radix N. oculomotorii; *N.Mot.V.*, motor root of N. trigeminus; *N.Sen.V.*, sensory root of N. trigeminus; *N.VIII.(coch.)*, radix N. cochleæ; *N.VIII.(vest.)*, radix N. vestibuli; *N.VI.*, radix N. abducantis; *N.VII.*, radix N. facialis, pars secunda; *N.XII.*, radix N. hypoglossi; *Nu.flm.*, nucleus fasciculi longitudinalis medialis, or nucleus commissure posterioris (oberer Oculomotoriuskern of Darkschewitsch); *Nu.n.III.*, nucleus N. oculomotorii; *Nu.o.a.m.*, nucleus olivaris accessorius medialis; *Nu.o.i.*, nucleus olivaris inferior; *Nu.o.s.*, nucleus olivaris superior; *Nu.ruber.*, nucleus ruber; *St.i.l.*, stratum interolivare lemnisci; *S.n.*, substantia nigra. (Preparation by Dr. John Hewetson.)

ly and laterally (Fig. 462) as regards the nucleus nervi oculomotorii, and in frontal sections appearing to be dorsally placed as regards the latter (Fig. 463), stands in very intimate connection with the white fibres of no less than three areas. In the first place it is directly associated with the white fibres of the fasciculus longitudinalis medialis; in the second place it is in the direct course of the fibres (distal or ventral part of posterior

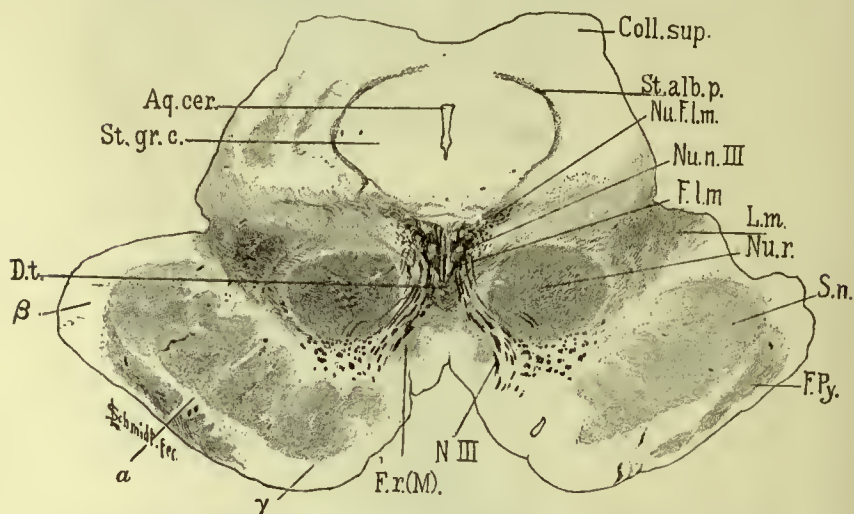


FIG. 463.—Transverse section through mesencephalon, colliculi superiores of corpora quadrigemina and cerebral peduncle of newborn babe. (Weigert-Pal, series ii, section No. 384.) *Aq.cer.*, aqueductus cerebri; *Coll.sup.*, colliculus superior; *D.t.*, decussatio tegmenti dorsalis (*fontaineartige Haubenkreuzung* of Meynert); *F.l.m.*, fasciculus longitudinalis medialis; *F.Py.*, fasciculi pyramidales in the basis pedunculi; *Fr.(M)*, fasciculus retroflexus Meynerti; *L.m.*, lemniscus medialis; *Nu.F.l.m.*, nucleus fasciculi longitudinalis medialis or nucleus commissurae posterioris (*oberer Oculomotoriuskern* of Darkschewitsch); *Nu.n.III*, nucleus N. oculomotorii; *Nu.r.*, nucleus ruber; *N.III*, N. oculomotorius; *St.alb.p.*, stratum album profundum; *St.gr.c.*, stratum griseum centrale; *S.n.*, substantia nigra; *a*, region of Flechsig's *Fusschleife*; *β*, temporo-occipital tract to pons; *γ*, frontal tract from pallium to pons. (Preparation by Dr. John Hewetson.)

commissure) which extend from the superior colliculus of the corpora quadrigemina of one side across the roof of the aqueduct of Sylvius to the region of the fasciculus longitudinalis medialis of the opposite side. In the third place, ventral to the nucleus of Darkschewitsch is a mass of white fibres which extends from the region of the nucleus ventralward and frontalward and somewhat lateralward, so as to pass between the middle line and the fasciculus retroflexus (Meynerti). The nucleus of

Darkschewitsch is intercalated, as it were, as a nodal point at the junction of these three masses of fibres. The nucleus of Darkschewitsch has a very definite outline just anterior to the nuclei of the third nerve, but farther anterior, just medial to the place where Meynert's bundle merges into the red nucleus, the nucleus of Darkschewitsch comes into relation with the gray matter of the anterior capsule of the red nucleus, and a small bundle of fibres, apparently belonging to the fasciculus longitudinalis medialis, can be followed beyond the nucleus of Darkschewitsch to the ventral portion of the capsule (F. Sabin). It is very difficult to say from the study of Weigert preparations how many of the fibres ventral to the nucleus of Darkschewitsch represent continuations of the fasciculus longitudinalis medialis, and how many represent continuations of the bundle of fibres of the commissure. Nor is it possible to say, from Weigert preparations alone, how many fibres from the opposite superior colliculus go past the nucleus of Darkschewitsch without ending in it to enter the fasciculus longitudinalis medialis. The best Golgi studies of this region are those of Held and van Gehuchten.\* The comparative anatomy is dealt with by Edinger. A full description, which, however, is not altogether satisfactory, is given by von K  lliker.

Miss Gertrude Stein, who is now studying a series of sagittal sections through this region from the brain of a babe a few weeks old, describes the nucleus of Darkschewitsch as follows: "The nucleus is more or less conical in shape. It lies dorso-medial from the red nucleus, being about as thick in a dorso-ventral direction as is the dorsal capsule of the red nucleus in which it lies. At this period of medullation the commissura posterior cerebri, considered simply topographically (that is, as a medullated fibre-mass without particular reference to the course of the fibres), appears as a dorso-ventral bundle, solid in the middle, subdivided dorsally into an anterior (proximal) portion and a posterior (distal) portion, while ventrally it expands in the form of a hollow pyramid, which rests directly upon the nucleus of Darkschewitsch." As to the bundle of fibres described above as being situated ventral to the nucleus, and passing forward and ventralward, Miss Stein in the brain she is studying can follow the fibres only as far as the fasciculus retro-

---

\* van Gehuchten, A. Le ganglion basal, la commissure post-hab  nulaire, le faisceau longitudinal post  rieur et les cellules m  dullaires dorsales du nevraxe de la Salamandre. *Verhandl. d. anat. Gesellsch., Jena*, Bd. xi (1898).

flexus. The fibres most ventrally situated are very complex in arrangement, forming a whirl in the substance of the nucleus ruber. Indeed, the nucleus ruber is divisible into two parts by this whirl of fibres—one part anterior and smaller, the other part posterior and much larger. In the anterior portion there are only delicate medullated fibres, and these are directed almost straight antero-posteriorly. In the posterior part the medullated fibres are much coarser in calibre, are arranged in small bundles, are directed diagonally, and appear to correspond to the continuation inside the red nucleus of the fibres of the brachium conjunctivum and of the formatio reticularis. The anterior fine fibres and the posterior coarse fibres are separated from one another in the medial part of the nucleus ruber by the fasciculus retroflexus. In the lateral part of the nucleus the two areas approach one another, and the peculiar differences between the two masses of fibres gradually disappear. Some of the coarse fibres of the posterior part of the red nucleus curve dorsalward to come into relation with the nucleus of Darkschewitsch at the point where the ventral bundle above mentioned originates.

The upward continuations of the fasciculus longitudinalis medialis, which could be looked upon as being concerned in the conduction of sensory impulses toward the somæsthetic area of the cortex, are not at all well understood. So far as we can find in serial sections through the baby's brain cut in all three dimensions of space, it is not possible to follow any direct upward continuations far into the hypothalamic region, and if the fasciculus longitudinalis medialis is to be regarded as one of the paths mediating sensory impulses on their way to the cerebral cortex, this path is almost certainly interrupted in the hypothalamus or thalamus.



## CHAPTER XLIX.

### CENTRIPETAL AXONES IN THE FORMATIO RETICULARIS.

Forel's *Haubenfascikeln*—Honegger's *hintere Längsbündel-formation*—  
Central paths of vagal, glossopharyngeal, and trigeminal nerves—  
Fasciculi tegmenti centrales.

#### (c) *The Formatio Reticularis Alba.*

As to the upward continuations of longitudinal bundles of fibres in the formatio reticularis we have also little information that is definite. It has been shown by von Monakow that, after extensive defect in the hemisphere of the dog, degeneration of Forel's *Haubenfascikeln*, and of many other fibres in the formatio reticularis, results. The change is that of simple atrophy rather than of actual degeneration.

It has been observed in human cases as well as in experimental animals, so that there can be but little doubt that many of these longitudinal bands of the formatio reticularis are connected by means of neurones of a higher order with the cerebral cortex. Just where the medullated axones of the formatio reticularis end is not certain. But it seems probable that the place may be the hypothalamic region, or the ventral group of nuclei of the thalamus, and that a new neurone thence sends an axone out through the internal capsule to the cerebral cortex. It seems probable that Honegger's *hintere Längsbündel-formation* is to be here included. The bundles described by Honegger do not coincide with the fasciculus longitudinalis medialis, but include the longitudinal bands of the formatio reticularis, which go between the two brachia conjunctiva dorsal to the decussation, and beyond the red nucleus into the hypothalamic region. They become mingled with the frontal and medial bundles of the capsule of white matter which surrounds the red nucleus.

Not to be forgotten in this connection are the special bundles in the formatio reticularis made up of the medullated axones of central neurones, the perikaryons of which are situated in the

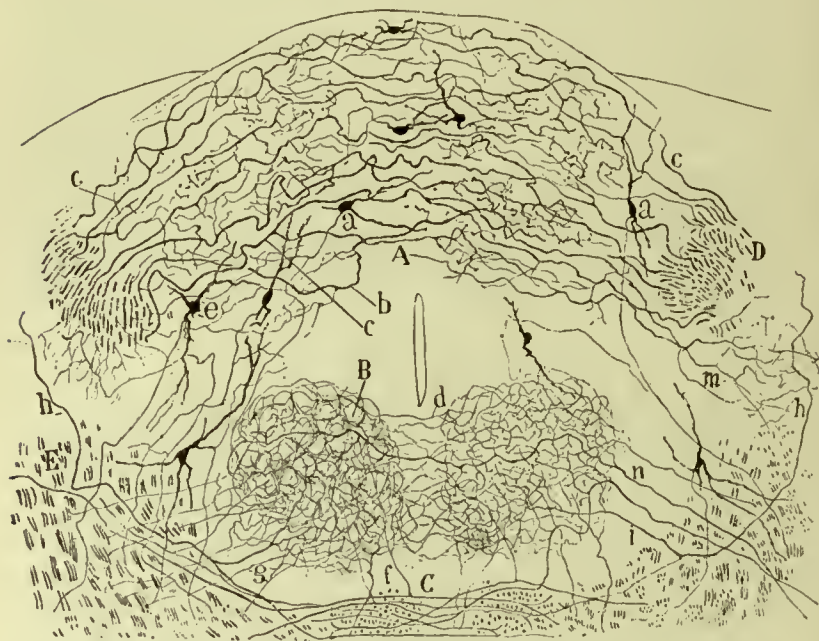

FIG. 464.—Transverse section through the medulla oblongata of a mouse at the level of the nucleus commissuralis. (After S. Ramón y Cajal, *Beitrag zum Studium der Medulla Oblongata*, etc., Bresler, Leipz., 1896, S. 47, Fig. 12.) A, nucleus commissuralis; B, nucleus N. hypoglossi; C, decussatio lemniscorum; D, transverse section of tractus solitarius; E, central path for N. N. IX; a, cell of nucleus commissuralis; b, c, terminal fibres of N. vagus et N. glossopharyngeus; d, commissure formed by collaterals of hypoglossal nuclei; g, f, collaterals of sensory axones of the second order for the nucleus N. hypoglossi.

nuclei terminales of the N. vagus, the N. glossopharyngeus, the N. vestibuli, and possibly also the N. trigeminus. It is desirable that as soon as possible these bundles, which have been localized by Golgi's method (Figs. 464 and 465), should be satisfactorily topographically located in Weigert-Pal preparations of the medullated formatio reticularis.

The fasciculus tegmenti centralis (*centrale Haubenbahn* of the Germans) may contain some centripetal fibres, but the con-



5. The Upward Continuation of the Fibres of the Brachium Conjunctivum and the Radiations of the Red Nucleus.\*

CHAPTER L.

ON THE NEURONES SUPERIMPOSED UPON THE BRACHIUM CONJUNCTIVUM, AND THE RADIATIONS OF THE RED NUCLEUS.

Termination of fibres of brachium conjunctivum—The capsule of the red nucleus—Study of secondary degenerations—Cerebello-cerebral paths—Somæsthetic area of the cortex.

WE have seen that the majority of the fibres in the brachium conjunctivum do not extend farther cerebralward than the red nucleus. The majority of the constituent fibres of each brachium conjunctivum partly arise but mainly end in the red nucleus. There is some evidence that a few of them extend beyond the red nucleus, joining the other white fibres situated on the lateral surface of this body (Fig. 324).

The study of serial sections through the brain of the newborn baby stained by Weigert's method shows medullated fibres forming a very distinct capsule to the red nucleus. These fibres are most abundant anterior to the red nucleus and on its lateral side, although large numbers are also present upon the dorsal surface of the nucleus. Relatively few medullated fibres exist ventral to the nucleus at birth, though in the adult more exist here. It is customary to divide the capsule of the red nucleus, therefore, into a lateral portion, a frontal portion, a dorsal portion, and a ventral portion (Fig. 323 and Fig. 324).

The lateral portion of the capsule of the red nucleus corresponds to the bundle which Forel designated as BATH, and represents a part at least of Flechsig's *Haubenstrahlung*. It is the bundle described by von Monakow as *lm RK*. As has been pointed out above, it lies close to the medial surface of the up-

---

\* *Haubenstrahlung*, *Ausstrahlungen des rothen Kernes* of the Germans; *Capsule du noyau rouge*, *radiations de la calotte* of the French.



ward continuation of the main portion of the lemniscus, but it is easily distinguishable from this bundle. There are certainly many cells among these fibres. Anterior to the red nucleus the fibres of the different portions of its capsule enter into a common area—the “field H” of Forel. The further continuation cerebralward is still a matter of dispute.

Von Monakow's experiments have shown that if a whole hemisphere be removed two sorts of changes take place in the fibres now being considered—(1) actual secondary degeneration and (2) simple atrophy. The total reduction in volume of the field amounts to about one half after total defect of one hemisphere. Apparently, the part of the cerebral cortex chiefly concerned, directly or indirectly, with the radiations of the red nucleus, is the region of the central gyri and the operculum. It is possible that some of the fibres are connected with the island and with the anterior portion of the parietal lobe.\* We are not sure how many fibres in Forel's “field H” ascend (from cell bodies situated in the red nucleus or gray masses still more inferiorly situated) nor how many descend (from cell bodies in the basal ganglia or in the cerebral cortex), nor how many are directly connected with the cortex, nor how many are indirectly connected with it by means of neurones of other orders. It is probable that fibres pass in both directions between the region of the red nucleus and the cortex, and it seems certain that a part of the fibres extend through the whole distance without interruption. These, in all probability, are the ones which undergo total absorption after a defect in the cortex which has existed a long time. They appear to correspond to a part of the dorsal and anterior portions of the capsule of the red nucleus. On the other hand, a great many of the ascending fibres, in all probability, end free in the hypothalamic region and in the thalamus (Mingazzini, Dejerine), and are connected with the cortex, if at all, only by means of neurones of a higher order. It seems probable that the fibres forming the lateral and ventral portions of the capsule of the red nucleus are here to be considered. Von Monakow suggests that the fibres forming the dorsal capsule of the red nu-

---

\* At least four cases of atrophy of the red nucleus after cortical lesions have been described, one by Flechsig and Hoesel, one by Mahaim, one by von Monakow, and one by the Dejerines.

cleus are identical with Honegger's *hintere Längsbündelformation*.

An observation by the Dejerines is so important in this connection that it deserves more than passing notice.\* They had the good fortune to obtain for study the nervous system from a man fifty-three years old, who had for eleven years suffered from a right-sided hemiplegia with total aphasia. At autopsy there was found a very extensive lesion of the cerebral cortex involving the whole external face of the left hemisphere and the orbital surface of the frontal lobe without injury to the central ganglia. There were multiple secondary degenerations. There was not only a degeneration of all the projection fibres of cortical origin, but also a total degeneration of the fibres of the internal capsule, of the foot of the cerebral peduncle, of the substantia nigra, and of a portion of the red nucleus. They were able to follow in this case very exactly the course of the bundles of fibres which they believed to pass uninterruptedly between the red nucleus and the cerebral cortex (*fibres cortico-rubriques directes*). They could identify them below the degenerated fibres of the internal capsule in the upper part of the hypothalamic region, whence the degenerated area extended inward, passed between the geniculate bodies on the one side and the bundle of Türek on the other, and occupied an irregular zone outside the central gray substance of the third ventricle—a position which corresponds evidently to the upper part of the capsule of the red nucleus and which is situated between the fasciculus retroflexus of Meynert and the bundle BATH of Forel. The degeneration of these fibres, which form a portion of the radiations of the red nucleus, could be followed into the whole of the dorsal and anterior portion of the red nucleus. The ventral and posterior part of the nucleus was normal, as was also the brachium conjunctivum. Not all of the dorsal part of the red nucleus was deprived of fibres. On its dorsal, anterior, and lateral surface the thalamic contingent of the radiations showed undegenerated fibres, and one could in this case easily decide, therefore, which of the radiations belonged to the thalamus and which belonged to the cerebral cortex.

---

\* Dejerine, J., et Mme. J. Dejerine. Sur les connexions du noyau rouge avec la corticalité cérébrale. *Compt. rend. Soc. de biol., Par.*, 10. s., t. ii, (1895), pp. 226-230.

Between the cortex of one cerebellar hemisphere and that of the opposite cerebral hemisphere two paths, therefore, in all probability exist, one consisting of three superimposed neurones, the other of four. The neurones of the more direct path would include (1) a neurone the axone of which extends from the cerebellar cortex to the nucleus dentatus; (2) a neurone the axone of which extends from the nucleus dentatus through the brachium conjunctivum and its decussation to the red nucleus of the opposite side; (3) a neurone with the axone extending from the red nucleus to the cerebral cortex. In the less direct path four neurones would be involved: (1) a neurone with axone extending from the cerebellar cortex to the nucleus dentatus; (2) a neurone connecting the nucleus dentatus with the opposite red nucleus by way of the brachium conjunctivum; (3) a neurone connecting the red nucleus with the hypothalamus or thalamus; (4) a neurone connecting the hypothalamic region, or the thalamus, with the cerebral cortex.

I would suggest that the term "somæsthetic area" \* be retained for all those regions of the cortex which receive centripetal impressions from these central sensory conduction paths, be it by way of the lemniscus, by way of the formatio reticularis, by way of the fasciculus longitudinalis medialis, or by way of the upward continuation of the brachium conjunctivum and the radiations from the red nucleus, and whether the conduction be directly from these bundles, or indirectly by means of neurones of a higher order interposed.

---

\* *Körperfühlsphäre* of Munk and Flechsig.

6. Central Centripetal Axones passing through the Internal Capsule (Corticopetal Projection Neurones of the General Somæsthetic Conduction Path).

CHAPTER LI.

Embryological memberment—Flechsig's system No. I—System No. II—System No. III—*Résumé* of somæsthetic conduction paths.

FROM what has been said in the foregoing chapters, it will be plain that we are in urgent need of more exact knowledge concerning the sensory paths from the tegmental portion of the cerebral peduncle to the cerebral cortex. It is certain that a large majority of the fibres are interrupted (nearly all of the lemniscus, probably all of the fibres of the fasciculus longitudinalis medialis, many of the fibres of the brachium conjunctivum, and radiations of the red nucleus). It seems likely that a part of the fibres pass directly out to the cortex (possibly a portion of the lemniscus, many of the fibres from the radiation of the red nucleus). The stations intercalated in the path are of rather wide area (ventro-lateral group of nuclei for the thalamus, for the lemniscus, gray matter of hypothalamic region, of ventro-lateral portions of the thalamus, and possibly of Luys' body, and the *centre médian* of Luys for the fibres of the other bundles). Secondary degenerations show a different path through the internal capsule for different portions of these centripetal fibres from these various intermediate stations. Thus, while they all pass through the posterior portion of the pars occipitalis of the internal capsule, still in this region it is possible to separate, to a certain extent at least, the area corresponding to the axones coming from the intermediate stations connected with the lemniscus from the areas which correspond to the intermediate stations belonging to the radiations of the red nucleus.

The embryological studies of Flechsig dealing with the sensory fibres going to the cerebral cortex may be mentioned in this connection. Flechsig unfortunately does not distinguish clearly in his work the upward continuations of the lemniscus,



direct or indirect, from those belonging to the radiations of the red nucleus, etc. He groups the large mass of centripetal fibres together, and states that passing through the internal capsule the indirect continuations of the sensory fibres of the dorsal roots of the spinal and cerebral nerves can be divided into three definite systems, which become medullated at different periods. He has designated these three systems of fibres, according to

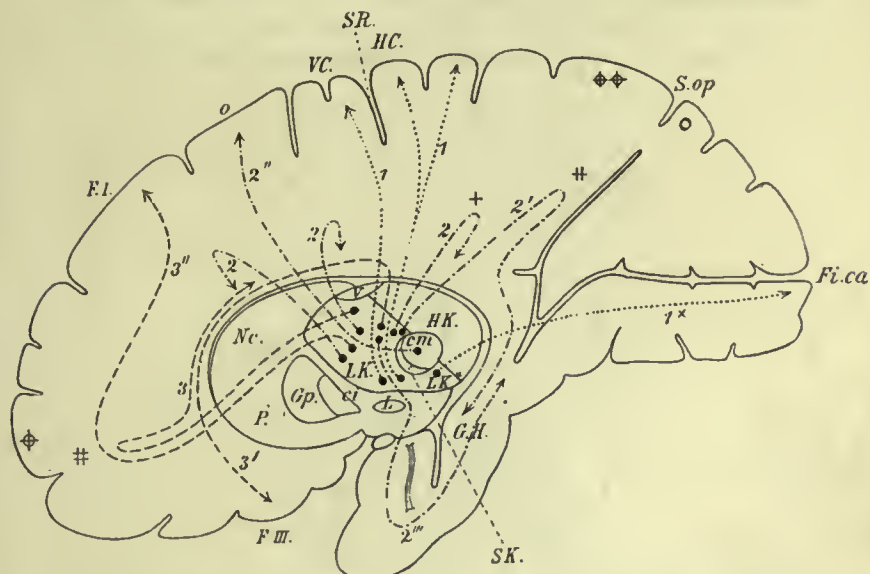


FIG. 466.—Sagittal section through the human brain; schematic. (After P. Flechsig, *Die Localisation der geistigen Vorgänge*, etc., Leipzig, 1896, S. 14, Fig. 1.) *Gp*, globus pallidus of the lenticular nucleus; *P*, putamen; *Nc*, nucleus caudatus; *LK*, lateral nucleus of the thalamus; *SK*, cup-shaped body of thalamus (*schalenförmiger Körper*); *cm*, centre median of Luys of thalamus; *HK*, medial nucleus and pulvinar; *v*, anterior nucleus of thalamus; *LK*, *SK*, *cm*, together represent Flechsig's ventro-lateral group of nuclei of the thalamus; *HK*, *v*, represent his dorso-medial group of nuclei; *ci*, internal capsule; *L*, nucleus hypothalamicus (*corpus Luysi*); *F.I*, superior frontal gyrus; *F.III*, inferior frontal gyrus; *GH*, gyrus hippocampi; *VC*, anterior central gyrus; *HC*, posterior central gyrus; *SR*, sulcus centralis Rolandi; *S.op*, sulcus parieto-occipitalis; *Fi.ca*, fissura calcarina; *1*, *1'*, *1'''*, sensory system No. 1; *2*, *2'*, *2''*, *2'''*, sensory system No. 2; *3*, *3'*, *3'''*, sensory system No. 3; different kinds of dotted lines are used to represent these three systems in all the figures. The corticopetal paths of the optic thalamus are represented in the figure; the corticofugal conduction paths of the dorso-medial group of nuclei of the thalamus, the motor paths of the cerebral cortex, etc., are not shown. The arrangement of the points in the ventro-lateral domain of the thalamus is schematic.

the order of their medullation, as systems I, II, and III (Figs. 466–468). For system No. I the myelin appears at about the

beginning of the ninth foetal month. It occupies the posterior part of the internal capsule, and in its upper half the area immediately behind the fibres of the pyramidal tract. The fibres of this system in the main pass up from the basal portions of the lateral nucleus of the thalamus, the cup-shaped body (*schalenförmiger Körper* of Flechsig and von Tschisch), and in part, Flechsig believes, directly out of the medial lemniscus. They are distributed exclusively to the cortex of the two central gyri, which are thus, the first of all, the regions of the cortex to become connected by means of medullated fibres with the

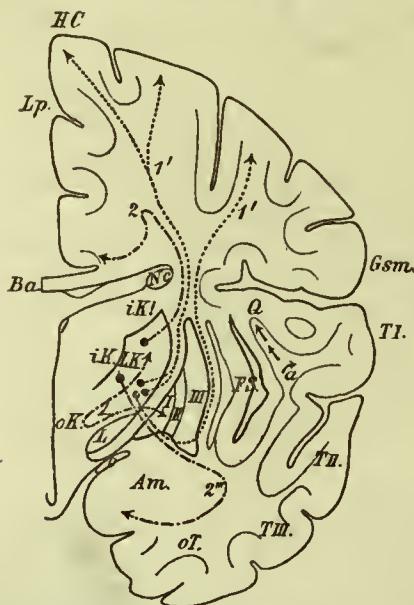


FIG. 467.—Frontal section through the human brain; schematic. (After P. Flechsig, *Die Localisations der geistigen Vorgänge*, etc., Leipz., 1896, S. 20, Fig. 2.) I, II, III, first, second, and third portion of the nucleus lentiformis; LK, lateral nucleus of thalamus; iK, iK', medial nucleus of thalamus; Nc, nucleus caudatus; L, nucleus hypothalamicus (corpus Luysi); oK, brachium conjunctivum; o, tractus opticus; Am, nucleus amygdalae; FS, Fossa Sylvii; HC, posterior central gyrus; Gsm, gyrus supramarginalis; TI, TII, TIII, superior, middle, and inferior temporal gyri; Q, anterior transverse temporal gyrus; oT, gyrus occipito-temporalis; Lp, lobulus paracentralis; Ba, corpus callosum; a, auditory conduction path.

sensory apparatus of the body. The fibres of this system are marked 1', 1'' in the diagrams.

A few of the fibres of this system, corresponding to the posterior angle of the lenticular nucleus, run in the external cap-

sule, and in the most posterior part of the lamina medullaris lateralis of the lenticular nucleus. A small bundle appears to

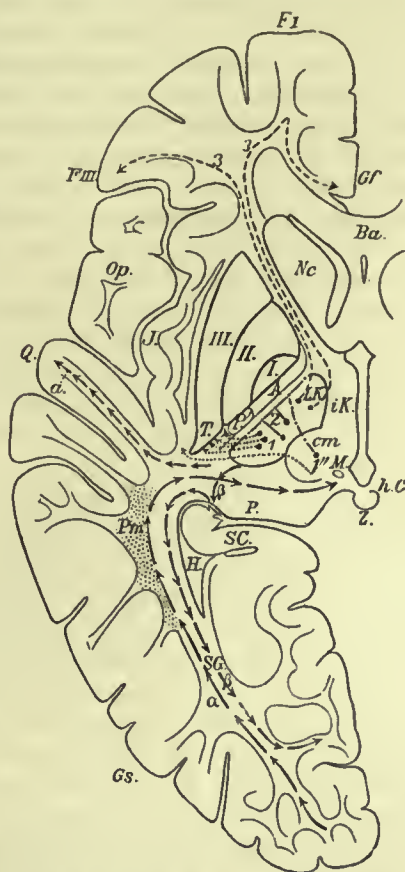


FIG. 468.—Horizontal section through the human brain; schematic. (After P. Flechsig, *Die Localisation der geistigen Vorgänge*, etc., Leipz., 1896, S. 23, Fig. 3.) *I*, *II*, *III*, first, second, and third portion of the nucleus lenticularis; *Nc*, nucleus caudatus; *LK*, lateral nucleus of thalamus; *iK*, medial nucleus of thalamus; *cm*, centre median; *P*, pulvinar; *M*, fasciculus retroflexus Meynert in cross section; *hC*, posterior commissure; *Z*, pineal body; *P*, pyramidal tract; *A*, Arnold's bundle of internal capsule; *T*, sensory region of internal capsule; *a*, auditory conduction path; *SG*, Gratiolet's radiation ("Optic radiation in the wider sense"); *α*, corticofugal paths of Gratiolet's radiation; *β*, corticopetal paths of Gratiolet's radiation, projection fibres of the lateral geniculate body; *Q*, anterior transverse temporal gyrus going over into the superior temporal gyrus; *Gs*, gyrus subangularis; *F1*, superior frontal gyrus; *FIII*, inferior frontal gyrus; *Gr*, gyrus fornicatus; *SC*, subiculum cornu Ammonis; *II*, posterior horn of lateral ventricle; *Op*, operculum; *Pm* (dotted), cross section of large association system between somæsthetic area (central gyri) and posterior large association centre; *J*, cortex of island of Reil.

go into the lower part of the optic radiation (1 +), the exact distribution of which is not yet certain.

The sensory system No. II begins to receive its myelin about a month later than does No. I. The fibres of this system also pass out of the lateral nucleus of the thalamus, but more dorsally. A few of them issue from the *centre médian* of Luys. Passing upward, they are distributed in part to the central gyri, the lobulus paracentralis, and to the foot of the superior frontal gyrus. Another portion of them, after bending around at an acute angle and passing inward, becomes distributed to the gyrus fornicatus along its whole length. The most posterior bundles (2', Fig. 466) enter into the eingulum and run toward the Ammon's horn. Still later another bundle belonging to this system runs from the lateral nucleus of the thalamus basalward and enters into the uncus, and arrives from in front and below at the subiculum cornu Ammonis. The whole of the limbic lobe thus comes to be connected with the lateral nucleus of the thalamus.

The sensory system No. III, the last to become medullated, is also connected with the lateral nucleus of the thalamus, emerging from the anterior portion of it. It enters the internal capsule in about its middle portion, and runs in part directly to the foot of the third frontal convolution, another part curving markedly, as shown in the diagram (Fig. 466, 3, 3'), before reaching the cortex. Bundles of the latter run from the region of the pyramidal tract forward into the fasciculus subcallosus, and descend at the anterior margin of the corpus striatum to the third frontal convolution (3'). The fibres of a second group pass through the pars frontalis of the internal capsule into the frontal lobe almost as far as the pole, and then bend round at an acute angle, part of the fibres reaching the middle portion of the gyrus fornicatus (3), another part the anterior half of the superior frontal gyrus, while single fibres go to the foot of the middle frontal gyrus.

It is of the highest importance, in order that the results of these researches of Flechsig and those of the study of secondary degenerations may be satisfactorily interpreted, that studies by Golgi's method be undertaken. It is to be hoped that in this way a more exact analysis of the paths under consideration may be made, so that ultimately we shall be able to state positively the exact position of the cell bodies and axones of the neurones



belonging to the different portions of the complex series of neurone systems which mediate the centripetal conduction from the sensory surfaces of the body toward the somæsthetic area of the cerebral cortex.

Let us now summarize briefly the contents of the chapters immediately preceding, bearing on the somæsthetic conduction path. We have seen that it consists of peripheral centripetal neurones (centripetal neurones of the first order of the spinal and cerebral nerves) and central centripetal neurones (centripetal neurones of the second order, and of higher orders).

The cell bodies and peripheral processes of the peripheral centripetal neurones are situated outside the central nervous system, while the axones plunge into the nerve centres and terminate in the nuclei terminales of the sensory nerves. In these nuclei terminales are situated the perikaryons and dendrites of the lowermost central centripetal neurones, and their axones carry the impulses on to higher centres. Possibly a few axones of these lowest central centripetal neurones go as far as the somæsthetic area of the cortex, but as a rule, however, they terminate in some gray mass on the way (mainly the thalamus), there coming into conduction relation with central neurones of a still higher order, whose axones carry the impulses out to the somæsthetic area of the cortex. The simplest somæsthetic conduction path then would consist of at least two superimposed neurone systems—one peripheral centripetal neurone and one central centripetal neurone. In all probability the main somæsthetic conduction path, however, consists of three sets of superimposed neurone systems—one peripheral centripetal neurone, one lower central centripetal neurone, and a third higher central centripetal neurone. In addition, in the possible somæsthetic conduction paths there are much more complex superimpositions in the domain of the central neurones, so that from the periphery to the cortex four, five, six, ten, or perhaps a great number of neurone systems may be superimposed. This is especially true of the roundabout somæsthetic conduction paths by way of the cerebellum.

The peripheral centripetal neurones have been divided into (1) those pertaining to the spinal cord and (2) those pertaining to the rhombencephalon. The central axones of the spinal peripheral centripetal neurones end in their nuclei terminales in the spinal cord, medulla oblongata, and cerebellum. The

axones of the central centripetal neurones whose perikaryons and dendrites correspond to the nuclei terminales of the peripheral spinal centripetal neurones do not all follow the same course; on the contrary, they assume in the central nervous system very different ascending paths, and have at times entirely different terminations; in other words, at the junction of the peripheral spinal centripetal neurones with the neurone systems of the second order there occurs a marked *divergence* in the somæsthetic conduction paths. Leaving out of account the terminals of axones and collaterals which reach the ventral horns of the spinal cord, we have seen that many axones of spinal centripetal neurones terminate in the nucleus dorsalis, in the dorsal horn and middle part of the gray matter of the spinal cord, in the nucleus funiculi gracilis, and the nucleus funiculi cuneati of the medulla, and some even in the cerebellum. The axones from the cells in the nucleus dorsalis ascend in the fasciculus spino-cerebellaris dorso-lateralis to enter the cerebellum by way of the corpus restiforme, and to terminate in the cortex of the worm, giving off collaterals to the nucleus dentatus as the fibres pass by it. The axones of the central centripetal neurones and perikaryons, which are situated in the dorsal horn and in the middle part of the gray matter of the cord, ascend partly in the white matter of the same side and partly in the white matter of the opposite side in the fasciculus ventro-lateralis superficialis Gowersi and in the fasciculus ventralis et lateralis proprius. These axones have various terminations: some, as we have seen, run in Gowers' tract to the upper part of the pons and then turn back alongside of the brachium conjunctivum into the cerebellum to end in the worm, others turn into the cerebellum through the corpus restiforme, still others terminate in the colliculi of the corpora quadrigemina, others in the substantia nigra, others in the thalamus, and, finally, some in the nucleus lentiformis. The fibres of the fasciculus lateralis proprius terminate in part in the nuclei laterales of the medulla, in part in the formatio reticularis grisea. Some of these axones are quite long, others are very short. The axones of the fasciculus ventralis proprius in large part enter the fasciculus longitudinalis medialis, and come into relation with the motor and sensory nuclei and great reflex centres of the medulla oblongata.

The axones from the nucleus funiculi gracilis and from

the nucleus funiculi cuneati, as we have seen, correspond to at least four neurone systems of the second order, two of them going to the cerebellum (1, *systema myelencephalo-cerebellare cruciatum*; 2, *systema myelencephalo-cerebellare non-cruciatum*), two of them going directly to the cerebrum. Of the latter, one set of axones—the main set—end in the ventro-lateral group of nuclei of the thalamus (1, *systema lemniscate myelencephalo-thalamicum*). The axones of the other set go all the way out to the cortex of the pallium, to terminate, according to Tschermak, in the gray matter of the somæsthetic area (2, *systema lemniscate myelencephalo-pallialum*). On their way these axones to the cerebrum give off collaterals to the nucleus olivaris inferior, and to the motor and reflex nuclei of the medulla oblongata, pons, and midbrain. A part of the axones undergo a high crossing in the commissura superior of Meynert, in order to enter the nucleus lentiformis of the opposite side.

Of the axones which pass into the cerebellum, we have to consider (1) those which go directly from the spinal cord to the cerebellum, and (2) those which go from the nuclei of the medulla into the cerebellum. Among the latter may be classed certain axones from the nuclei of the dorsal funiculi, the nuclei funiculi lateralis, and the nucleus olivaris inferior. The axones on entering the cerebellum terminate in the cortex of that organ, and also come into manifold relation by means of collaterals with the nucleus dentatus and adjacent gray masses, probably of both sides. The fibres from the nucleus olivaris inferior to the cerebellum form the so-called fibræ olivo-cerebellares. From the regions of the cerebellum, in turn, in which the fibres mentioned terminate, there proceed axones of neurone systems of a higher order which extend cerebralward—namely, those of the brachium conjunctivum, most of which terminate in the nucleus ruber of the opposite side, some beyond this nucleus, some, however, going to the thalamus of the same side. From the nucleus ruber of each side there go out axones of neurone systems which extend in the main to the nucleus lentiformis and to the somæsthetic area of the cortex. These make up in large part the “radiations of the nucleus ruber.”

From the ventro-lateral region of the thalamus, in which so many axones of the central neurones of the somæsthetic conduction path terminate, there extend neurone systems to the somæsthetic area of the cortex—systems which can be subdi-

vided into three great groups, according to their period of myelination. (System No. I, System No. II, and System No. III.)

The peripheral neurones pertaining to the rhombencepha-

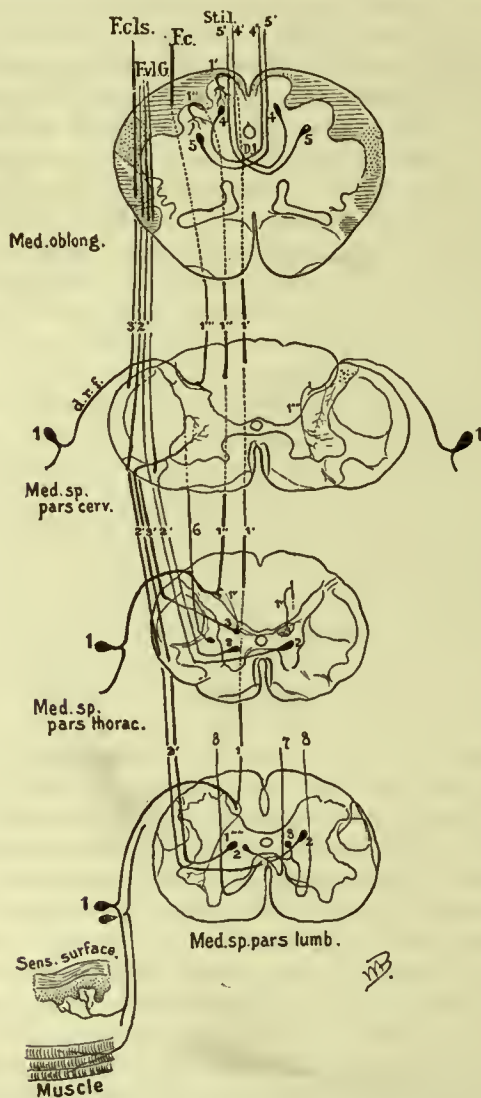


FIG. 469.—Scheme of general somæsthetic paths; lettering the same as on pl. i, Fig. 1.



lon concerned in the conduction of bodily impulses end in the nuclei terminales of the sensory cerebral nerves. The axones, as we have seen, correspond to those of the N. vagus, N. glossopharyngeus, N. vestibuli, and N. trigemini. The axones of the central neurones, which belong here, enter partly the lemniscus medialis and partly the fasciculus longitudinalis medialis—that is to say, they run in company with the principal bundles of the centripetal axones of the spinal somæsthetic conduction path. For certain of the cerebral sensory nerves, however, there are especial central bundles in the formatio reticularis that have been pointed out in their appropriate connection. (Cf. central paths for the N. vagus, N. glossopharyngeus, N. intermedius, N. vestibuli, and N. trigeminus.) It is not impossible that some of the cerebral nerves also make roundabout conduction paths by way of the cerebellum and brachium conjunctivum. From the cerebral peduncle on, it has not been possible thus far to distinguish the central paths of the cerebral nerves from those which correspond to the spinal nerves.

These manifold distributions of central axones and collaterals in the spinal cord and rhombencephalon render possible the enormous number of conduction relations necessary for the construction of the reflex and instinctive mechanisms which are associated with bodily centripetal impulses. The axones which reach the so-called somæsthetic area of the pallium are in turn able to affect association neurones which combine the activities of the somæsthetic area with those of the other sensory areas of the cortex. In the somæsthetic area are situated also the perikaryons, dendrites of the motor neurones, the axones of which extend from the pallium to the groups of perikaryons belonging to the lower motor neurones (motor nuclei of the midbrain, pons, medulla oblongata, and spinal cord). It is thus obvious that the motor conduction paths can be affected in different parts of their course by way of the various sets of superimposed neurone systems of the somæsthetic conduction path. The lower motor neurones are, by means of collaterals at least, in direct conduction relation with the peripheral centripetal neurones; the sensory neurones of the second order come, by means chiefly of collaterals, into conduction relation with the large nerve cells of the formatio reticularis, the axones of which in turn can affect the lower motor neurones, while the higher central centripetal somæsthetic neurones can





directly, in all probability, affect through the conduction relations which are established in the somæsthetic area the neurones whose axones form the pyramidal tract. Finally, it seems likely that from the association centres of the cerebral cortex which are on the one hand thrown under the influence of the somæsthetic area as well as under the influence of the other sense areas of the cortex, paths may go out to reach the motor areas of the cortex again, and thence by way of the pyramidal tract affect the groups of lower motor neurones. When one regards the possibilities of communication between sensory neurones on the one hand and motor neurones on the other hand, actually thus far established, and thinks of the infinite number of communications which may yet be demonstrated, the intimate relations of these sets of neurones with one another becomes truly astounding.

Particular attention is directed to two great subdivisions of the somæsthetic conduction paths—*A*, the paths from the periphery to the cortex but not passing through the cerebellum, and *B*, the less direct paths by way of the cerebellum and brachium conjunctivum. Here anatomical knowledge is vastly in advance of physiological research and of clinical application, but we may hope that the near future has much to reveal concerning the respective functions of these different paths.

A scheme illustrating some of the better known neurone systems of the general sensory path from the periphery to the cortex is given in Figs. 469, 470, and 471.



(B) Central Neurones of Sensory Conduction Paths Corresponding to the Organs of Special Sense.

WE have now to pass on to the neurones of the second order and of higher orders which conduct centripetally in connection with the paths which have to do with the organs of special sense—namely, the sense of taste, the sense of smell, the sense of sight, and the sense of hearing. Although on superficial examination these paths are very different from those conducting to the somæsthetic region of the cortex, we shall find on closer examination many analogies.

## CHAPTER LII.

### CENTRAL NEURONES OF THE GUSTATORY AND OLFACTORY CONDUCTION PATHS.

Central gustatory neurones—Central olfactory neurones—Structure of rhinencephalon—Studies of Sir William Turner—Studies of W. His—Studies of Retzius—*Bulbus olfactorius*—*Traetus olfactorius*—*Stria olfactoria*—*Commissura anterior cerebri*—Olfactory terminals in the frontal and temporal lobes—Olfactory association and reflex paths.

#### 1. *Central Neurones of the Gustatory Conduction Path.*

OUR knowledge of these paths is incomplete and extremely unsatisfactory. Turner,\* in reviewing the subject, finds disagreement among investigators as to the peripheral gustatory neurones and almost complete ignorance as regards the central gustatory neurones. For the pathology of taste sensations the excellent epitome of Frankl-Hochwart† is recommended. The diagrams on page 528 may also be referred to.

---

\* Turner, W. A. Note on the Course of the Fibres of Taste. *Edinb. M. J.*, vol. 1, n. s. (1897), p. 74.

† Article in Nothnagel's *Spez. Path. u. Therap.*, Abth. iv, Theil ii, Bd. xi, Wien, 1897.

*2. Central Neurones of the Olfactory Conduction Path.*

Inasmuch as the olfactory conduction path is the first path in the forebrain connected with the special sense organs to become medullated in the developing human fœtus, it may appropriately be first considered. We have already seen how the axones of the peripheral olfactory neurones terminate within the olfactory glomeruli of the olfactory bulb. It is now necessary to examine the neurones and their various processes by means of which these impulses, arriving in the olfactory bulb, are carried to higher parts of the central nervous system. Before proceeding to this description, however, it may be helpful to refer briefly to the general structure of the olfactory portion of the brain.

The more interesting of the earlier studies upon the central olfactory stations were made by Broca,\* Schwalbe,† and Zuckerkandl.‡ An important advance was made when Sir William Turner\* grouped the regions especially connected with the sense of smell under the term rhinencephalon, thus distinguishing them sharply from the rest of the forebrain (the pallium), a distinction which has been proved by His|| to be embryologically well founded, and by Edinger to agree with phylogenetic development.

The size of the rhinencephalon varies enormously in different

\* Broca, P. Localisations cérébrales; recherches sur les centres olfactifs. *Rev. d'anthrop.*, Par., 2. s., t. ii (1879), pp. 385-455.

† Schwalbe, G. *Lehrbuch der Neurologie*, 8vo, Erlangen (1881).

‡ Zuckerkandl, E. *Das periphere Geruchsorgan der Säugethiere*, 8vo, Stuttgart (1887).—*Das Riechbündel des Ammonshornes*. *Anat. Anz.*, Jena, Bd. iii (1888), S. 425-434.

\* Cf. Turner, Sir W. *The Convolutions of the Human Cerebrum Topographically Considered*. *Edinb. M. J.*, vol. xi (1865-'66), pp. 1105-1122, and especially, *The Convolutions of the Brain; A Study in Comparative Anatomy*. *J. Anat. and Physiol.*, Lond., vol. xxv (1890-'91), pp. 105-153.

|| His, W. *Die Formentwicklung des menschlichen Vorderhirns vom Ende des ersten bis zum Beginn des dritten Monats*. *Abhandl. d. math.-phys. Cl. d. k. Sächs. Gesellsch. d. Wissensch.*, Leipzig, Bd. xv (1889), S. 673-736.—*Zur allgemeinen Morphologie des Gehirns*. *Arch. f. Anat. und Physiol.*, Anat. Abth., Leipzig (1892), S. 346-383.—*Ueber die Entwicklung des Riechlappens*. *Verhandl. d. Anat. Ges.* (1893). In this connection see also Minot, C. S. *The Olfactory Lobes*. Report of the Sixty-sixth Meeting of the British Association for the Advancement of Science at Liverpool in 1896, p. 836.

animals, corresponding to the marked differences which they exhibit as regards the olfactory sense. Animals were divided by Broca into an anosmatic and an osmatic class. The latter group was further subdivided by Sir William Turner into microsmatic and macrosmatic animals. The rhinencephalon in microsmatic animals is relatively feebly developed, and to this group human beings belong. The general relations of the rhinencephalon are accordingly much more easily studied in lower animals than in man, and, as a matter of fact, for a long time the nature of certain portions of the human brain now recognized as remnants of the olfactory brain was not at all understood. In order to gain a clear conception of the relations of the various parts of the rhinencephalon to one another and to the pallium in man it is probably best to study the development.

His, of Leipzig, has shown that the developing olfactory brain becomes separated at the beginning of the second month from the anterior end of the hemisphere and appears as a projection near the lamina terminalis. Between the pallium and the rhinencephalon there is a distinct furrow which Sir William Turner has designated the *fissura rhinica*. At a very early period the rhinencephalon thus marked off is subdivided by an indentation (the fissura prima, which is especially marked on its medial surface) into an anterior half (directed more dorsalward) and a posterior half. The anterior half or anterior olfactory lobe is in contact with the region which is to become later the frontal lobe; the posterior half or posterior olfactory lobe is in contact with what is to be later the temporal lobe (Fig. 472). Above the posterior olfactory lobe the fossa Sylvii develops. As development proceeds, the anterior olfactory lobe becomes gradually depressed toward the base of the brain by the growing frontal lobes and it comes finally to occupy a plane deeper than that in which the posterior olfactory lobe is situated. Each of the two olfactory lobes consists of a portion directed toward the base and of a portion directed medialward. From the basilar portion of the anterior olfactory lobe are developed the bulbus olfactorius, the tractus olfactorius, and the trigonum olfactorium, all of which, taken together, make up what is known as the "lobus olfactorius" of the anatomists. The basilar portion of the posterior olfactory lobe corresponds to the substantia perforata lateralis which is

definitely characterized by its position at the entrance to the fossa Sylvii and by its connection with the gyrus hippocampi of the temporal lobe. It becomes in later development overarched

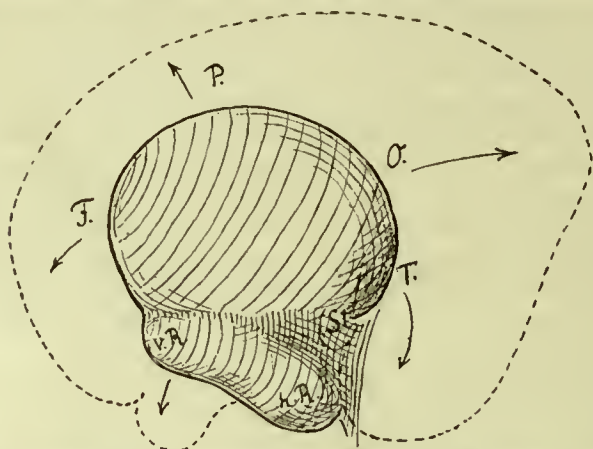


FIG. 472.—Scheme showing the relations of the anterior and posterior olfactory lobes to one another and to the lobes of the cerebral hemisphere in different stages of development. (After W. His, *Die anatomische Nomenclatur*, etc., Leipz., 1895, S. 177, Fig. 27.) *v.R.*, lobus olfactorius anterior; *h.R.*, lobus olfactorius posterior; *F.*, region of lobus frontalis; *P.*, region of lobus parietalis; *O.*, region of lobus occipitalis; *T.*, region of lobus temporalis; *St.*, corpus striatum.

secondarily by the pole of the temporal lobe. Medialward the substantia perforata lateralis is continuous with the gyrus subcallosus (medial portion of the posterior olfactory lobe), which in the adult human brain is a somewhat indefinite structure, although in the human foetus it is a very well-marked morphological entity. The gyrus subcallosus (pedunculus corporis callosi) is in front separated from the medial portion of the anterior olfactory lobe (area parolfactoria Brocæ) by a deep indentation, the so-called sulcus parolfactorius posterior (the fissura prima of the embryo). The furrow which separates Broca's field from the beginning of the gyrus cinguli and which accordingly is situated in front of the trigonum olfactorium and of the area of Broca has been called by His the sulcus parolfactorius anterior. In the adult the junction of the substantia perforata lateralis with the island of Reil is not very definitely limited, but in the human foetus at about the fourth month this junction is sharply marked off by an arched ridge,\* which con-

\* Broca's *le bord falciforme du lobe limbique*, Schwalbe's *Inselchwelle*.



nects the anterior olfactory lobe with the temporal lobe. The region, therefore, known as the *limen insulæ* in the adult is to be considered as a part of the rhinencephalon. The following table shows at a glance the various parts of the rhinencephalon as described by His :

RHINENCEPHALON ACCORDING TO HIS.

Lobus olfactorius anterior..	{	Pars basilaris .	{	Bulbus olfactorius.
			{	Tractus olfactorius.
	{	Pars medialis .	{	Trigonum olfactorium.
			{	Stria medialis.
Lobus olfactorius posterior.	{	Pars basilaris =	Substantia perforata anterior.	
		Pars medialis =	Gyrus subcallosus.	

The anterior olfactory lobe is connected with the posterior by means of the stria olfactoria lateralis and the limen insulæ.

The best recent microscopic study of the structures belonging to the rhinencephalon is that of Retzius, of Stockholm.\* He calls the area parolfactoria of Broca the gyrus olfactorius medi-

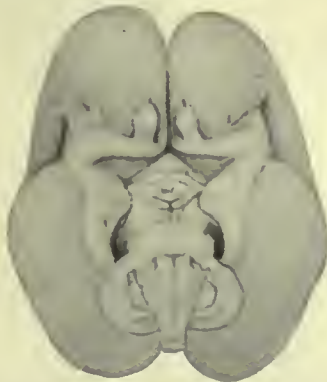

FIG. 473.—The basal surface of a human fetus 22.5 cm. long (beginning of fifth month) to illustrate developing rhinencephalon. (After G. Retzius, *Das Menschenhirn*, Stockholm, 1896, Taf. xxxii, Fig. 2.) The tractus olfactorii are developing; the gyri olfactorii mediales are distinctly visible; the gyri olfactorii laterales run lateralward, turn at an angle, and go over into the gyri semilunares and the gyri ambientes. The fissura rhinica separating the rhinencephalon from the lobus temporalis is distinctly developed; besides, one can see the triangular area terminalis and the eminentia sacularis spread out with its lateral wings in front of the corpora mammillaria, the latter being as yet but little developed.

alis, while he designates as gyrus olfactorius lateralis the region corresponding to the course of the lateral olfactory stria and

\* Retzius, G. *Das Menschenhirn*. Stockholm, 1896.

the limen insulæ (Figs. 473, 474, and 475). The lateral olfactory gyrus, directed at first laterally and posteriorly, makes a sharp turn backward at the *angulus lateralis* and goes over into the anterior extremity of the gyrus hippocampi, where it forms two minute convolutions which Retzius calls the gyrus semilunaris

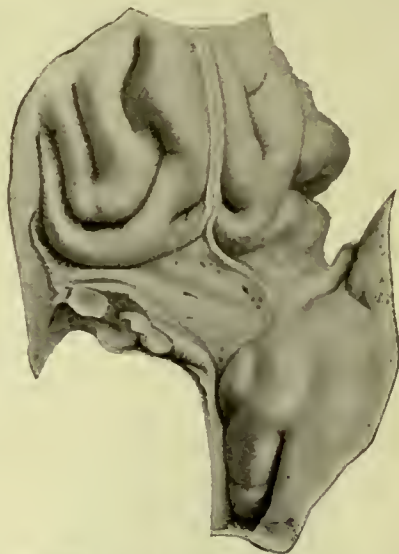

FIG. 474.—Part of the basal surface of the brain (of the left hemisphere) of a man forty-three years old, seen from below and to the right. (After G. Retzius, *Das Menschenhirn*, Stockholm, 1896, Taf. xxxii, Fig. 5.) On looking at the trigonum olfactorium one sees the two limbs running out into the gyrus olfactorius medialis and the gyrus olfactorius lateralis and behind them the somewhat bulging substantia perforata anterior, on the posterior border of which the diagonal band of Broca passing backward and lateralward from the gyrus subcallosus is distinctly visible. In the gyrus behind the substantia perforata anterior—i. e., in the gyrus olfactorius lateralis which is here separated from the gyrus transversus insulæ—can be seen the white stria olfactoria lateralis running lateralward and backward as far as the beginning of the gyrus hippocampi, where it disappears; the stria olfactoria medialis plunges deep into the substantia perforata anterior. On the gyrus hippocampi can be recognized medialward an oval, half-moon-shaped bulging, the gyrus semilunaris, which is separated by the sulcus semiannularis from the gyrus ambiens, more laterally placed.

rhinencephali and the gyrus ambiens rhinencephali, the two being separated from one another by a shallow furrow—the so-called sulcus semilunaris. The gyrus ambiens in turn is separated from the rest of the gyrus hippocampi by what Retzius calls the sulcus rhinencephali inferior (Figs. 476 and 477). That these two gyri exist in the region of the uncus, and are easily separable from it, I can confirm from the examination

of a number of hemispheres in this laboratory, and it would seem very probable that the temporal olfactory area, described

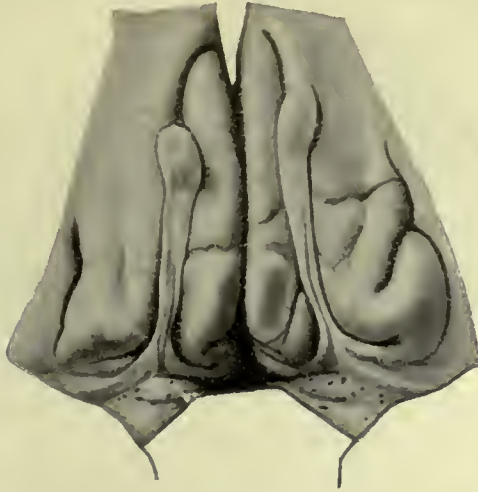

FIG. 475.—Illustration of part of the rhinencephalon of a man forty-three years old. (After G. Retzius, *Das Menschenhirn*, Stockholm, 1896, Taf. xxxii, Fig. 8.) The tractus olfactorii, with their surroundings, and the gyri olfactorii mediales et laterales going backward from them, are well seen. The gyri olfactorii laterales are distinctly separable on each side from the gyrus transversus insulae. Each lateral olfactory gyrus contains a well-marked stria olfactoria lateralis. In this instance a well-marked stria intermedia is visible plunging into the much-bulged substantia perforata anterior. The two olfactory tracts differ in length and anteriorly spread out into the bulbi olfactorii.

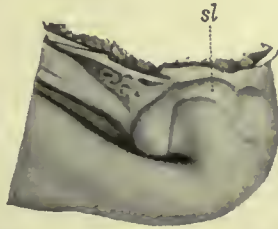


FIG. 476.—The lower part of the gyrus hippocampi, with surrounding structures from the right cerebral hemisphere of a fetus 28 cm. long. The end of the gyrus hippocampi bends around the anterior extremity of the fissura hippocampi into the uncus, and the gyrus intralimbicus sits like a cap upon the end of the uncus; the border of the latter corresponds to the limb (Giacomini); above and anteriorly the gyrus intralimbicus is continuous with the hillocklike gyrus semilunaris (*sl*); on the left the velum terminale goes over into the chorioid layer; beneath this the fornix and the fascia dentata. (After G. Retzius, *Das Menschenhirn*, Stockholm, 1896, pl. 1, Fig. 3.)

by Flechsig and other anatomists as existing in the uncus, has in reality much less to do with the uncus itself than has been

thought, and really concerns these two small gyri which, curiously enough, before Retzius's description appear to have been entirely overlooked.

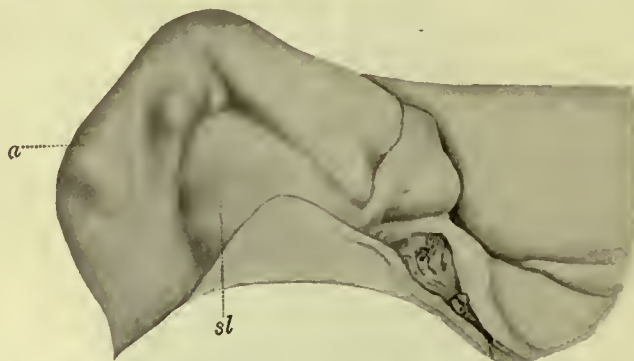


FIG. 477.—The inferior anterior extremity of the gyrus hippocampi from the brain of a fifty-nine-year-old woman, seen from above. (After G. Retzius, *Das Menschenhirn*, Stockholm, 1896, Taf. 1, Fig. 23.) One recognizes the triangular crescentic gyrus semilunaris (*sl*), which is separated by a curved furrow; the sulcus semiannularis (in the concavity of which a nodule is visible) from the gyrus ambiens (*a*) bending around the uncus. Behind the uncus, sharply marked off, is the limbus Glacomini, which goes over medially and behind into the posterior limb of the gyrus semilunaris and is separated posteriorly by a shallow furrow from the gyrus intralimbicus. Medial from this gyrus is attached a portion of the fimbria, and medial from this again is situated the lamella of the plexus chorioideus perforated by vessels along with the velum. By means of these structures the cavity of the cornu inferius is closed.

The various parts of the rhinencephalon described by Retzius are here presented in tabular form :

#### CLASSIFICATION ACCORDING TO RETZIUS.

- |   |   |
|---|---|
| 1. <i>Bulbus olfactorius.</i>                                   |   |
| 2. <i>Tractus olfactorius.</i>                                  |   |
| 3. <i>Trigonum olfactorium</i> (gyrus tubercis olfactorii)..... | <div style="display: inline-block; vertical-align: middle;">           { Stria olfactoria lateralis to gyrus olfactorius lateralis.<br/>           Stria olfactoria medialis to gyrus olfactorius medialis.         </div>                                    |
| 4. <i>Gyrus olfactorius medialis</i> .....                      | <div style="display: inline-block; vertical-align: middle;">           { Area parolfactoria Brocæ.<br/>           Pars anterior = Eberstaller's gyrus transversus insulæ and the linen insulæ.         </div>   |
| 5. <i>Gyrus olfactorius lateralis</i> .....                     | <div style="display: inline-block; vertical-align: middle;">           { Pars posterior. Extends from angulus lateralis to anterior extremity of gyrus hippocampi and terminates in the gyrus semilunaris rhinencephali and the gyrus ambiens.         </div> |



- |  |   |   |
|--|---|---|
| 6. <i>Gyrus perforatus (seu intermedius)</i>   | { | Anterior, much perforated, part   |
| <i>rhinencephali</i> . . . . .                 |   | of substantia perforata anterior.   |
| 7. <i>Gyrus diagonalis rhinencephali</i> . . . | { | Posterior, less perforated, part of substantia perforata anterior. Corresponds to the diagonal band of Broca, which extends from the gyrus subcallosus to anterior end of gyrus hippocampi. |
|  |   |   |
8. *Other portions of rhinencephalon.*
- (a) *Gyrus hippocampi.*
  - (b) *Uncus.*
  - (c) *Gyrus dentatus.*
  - (d) *Gyrus intralimbicus.*
  - (e) *Gyrus fasciolaris.*
  - (f) *Gyri Andreae Retzii.*
  - (g) *Indusium griseum* (including the *striae longitudinalis medialis et lateralis*).
  - (h) *Gyri subcallosi.*

The bulbus olfactorius (anterior extremity of the lobus olfactorius anterior of His) is relatively much smaller in man than it is in animals like the dog or the rabbit. In the embryo there is a central cavity in the olfactory bulb continuous through the olfactory lobe with the anterior horn of the lateral ventricle, but in the adult human being this cavity is obliterated, though its site is evident in coronal sections, being marked by the presence of a central gelatinous substance.

Since the rabbit's olfactory bulb has been very carefully studied, this will be described first, and the human bulb compared with it.

*The Main Bulb in the Rabbit.\**—Von Kölliker† describes the rabbit's olfactory bulb as being made up of the following layers:

- (1) Layer of olfactory nerve fibres.
- (2) Stratum glomerulorum, containing the glomeruli olfactorii.
- (3) Stratum griseum.
  - (a) Stratum moleculare seu gelatinosum, containing small and large nerve cells.
  - (b) Layer of mitral cells.

---

\* The rabbit, mouse, and cat possess, in addition to a main olfactory bulb, an accessory bulb which lies on the dorso-medial surface of the posterior end of the main bulb (von Gudden, von Kölliker).

† von Kölliker. *Op. cit.*, S. 693.

- (4) White substance, or granule layer, containing medullated nerve fibres and large numbers of minute nerve cells, the so-call "olfactory granules."

These layers are well illustrated in Fig. 478, taken from von Kölliker's book.

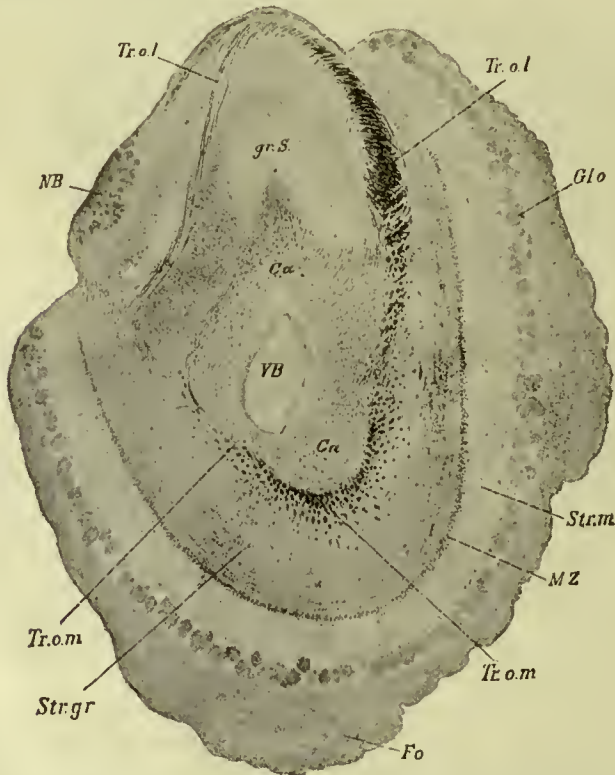


FIG. 478.—Frontal section of a bulbous olfactorius of a young rabbit; Weigert stain. (After A. von Kölliker, Handbuch der Gewebelehre des Menschen, Bd. ii, Leipz., 1896, S. 694, Fig. 747.) *Ca*, commissural fibres; *Fo*, fila olfactoria; *Glo.* glomeruli olfactorii; *MZ*, mitral cells; *NB*, accessory bulbous olfactorius; *Str.gr.* stratum granulosum; *Str.m.* stratum moleculare; *Tr.o.l.* tractus olfactorius lateralis; *Tr.o.m.* tractus olfactorius medialis; *VB*, ventriculus bulbi olfactorii; *gr.S.* substantia grisea.

Inside the layer of granules mixed with white fibres are accumulated the main bundles of medullated axones, those corresponding to the stria olfactoria lateralis (*Tr. o. l.*, Fig. 478) and the stria olfactoria medialis (*Tr. o. m.*, Fig. 478) being more superficially situated than the fibres which form the bundle

(*ca*, Fig. 478) which goes to the anterior commissure. The appearances of the human olfactory bulb are well shown in frontal section in Fig. 479 and in horizontal section in Fig. 480. The nature of the different parts are sufficiently well indicated in the legends accompanying the figures, and further description here is unnecessary.

The olfactory glomeruli receive, besides the terminals of the axones of the olfactory nerves, extremely numerous, much branched dendrites from the mitral cells and from the brush

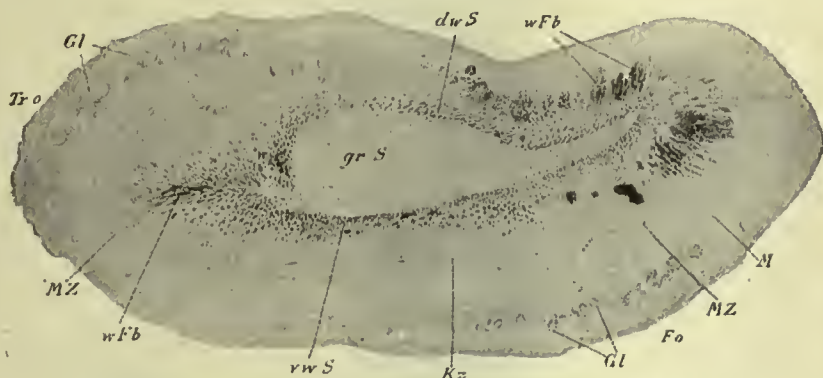


FIG. 479.—Transverse section of the human bulbus olfactorius; Weigert stain. (After A. von Kölliker, Handbuch der Gewebelehre, Bd. ii, Leipz., 1896, S. 698, Fig. 751.) *Fo*, fila olfactoria; *Gl*, glomeruli olfactorii; *Kz*, granule layer; *M*, molecular layer; *MZ*, mitral cells; *dwS*, dorsal white layer cut transversely; *grS*, inner gray nucleus; *vwS*, ventral white layer cut transversely; *wFb*, bundle of white fibres.

cells of the olfactory bulb. It is these dendrites of the mitral cells (Fig. 481) and of the brush cells (Fig. 482) which take up the impulses from the peripheral olfactory neurones and carry them farther. The peripheral sensory neurones do not come into contact directly with the cell bodies of the mitral cells, but can affect these and their axones only through the intermediation of the dendrites. The axones of the *Nn. olfactorii* are easily distinguishable from the dendrites of the mitral cells in sections which demonstrate the neurosomes, since the latter are much more numerous in the axones than in the dendrites (Fig. 483). The axones of the mitral cells and of the brush cells are medullated and run backward in the tractus olfactorius toward the main mass of the brain. On assuming a longitudinal direction they give off a number of collaterals to the stratum moleculare.

These fibres can be divided into two sets in the olfactory tract of human beings—a superficial set consisting of the fibres which

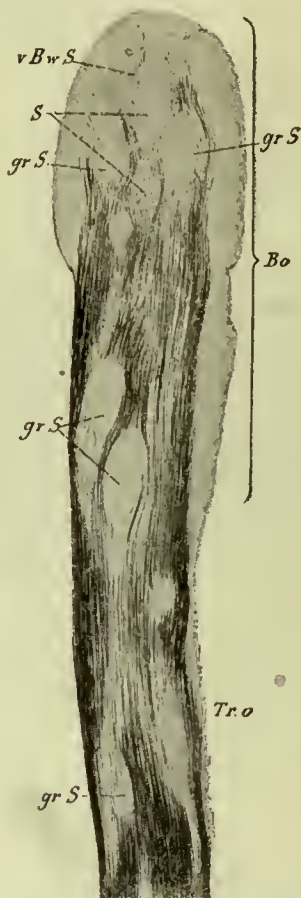

FIG. 480.—Horizontal section through the bulbus and tractus olfactorius of man; Weigert's stain. (After A. von Kölliker, *Handbuch der Gewebelehre*, Bd. ii, Leipz., 1896, S. 699, Fig. 752.) *Bo*, bulbus olfactorius; *S*, structure resembling septum; *Tr.o*, tractus olfactorius; *grS*, islands of gray substance; *vBwS*, anterior bundle of white substance.

later form the lateral and medial olfactory striæ, and a deep set consisting of fibres which run into the anterior part of the anterior commissure of the cerebrum (Fig. 484). The relations of the mitral cells and brush cells to the individual olfactory glomeruli vary in different animals. Thus, in the cat and rabbit each glomerulus receives only one dendrite from a single



mitral cell, while in the dog one glomerulus may receive dendrites from as many as five or six mitral cells. The nature of the olfactory granules (Fig. 485) is as yet not well understood.

The fibres destined for the commissure as they pass backward occupy the dorsal part of the tract and gradually collect into a bundle which is round in cross section and which enters directly into the anterior commissure forming its pars anterior. The fibres of the stria olfactoria lateralis, which includes the main mass of olfactory fibres (Fig. 486), pass backward

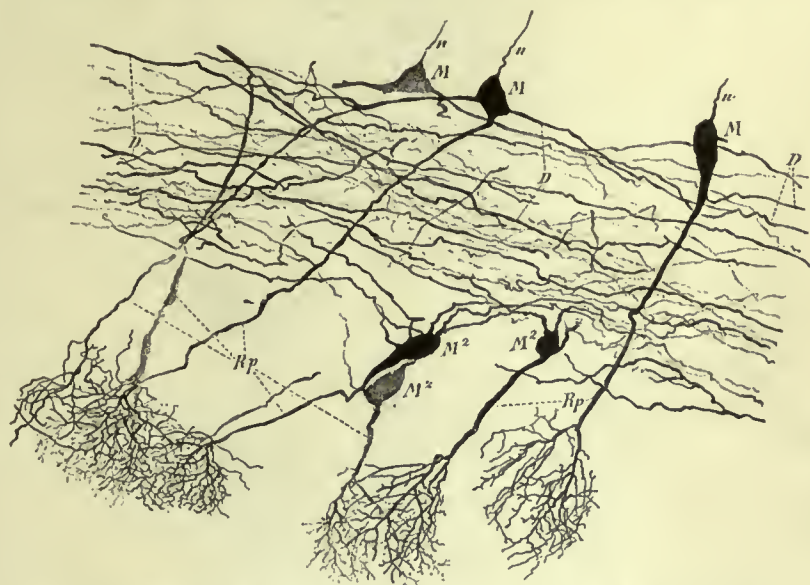

FIG. 481.—Mitral cells from a mouse twenty-four days old. Method of Golgi. (After A. von Kölliker, *Handbuch der Gewebelehre*, Bd. ii, Leipz., 1896, S. 704, Fig. 756.) *D*, dendrites of mitral cells which form a horizontal layer; *M*, deep mitral cells; *M²*, superficial mitral cells; *n*, axones; *Rp*, olfactory brush.

and outward first on the lateral side of the substantia perforata anterior, and then backward and medialward (corresponding to the posterior part of the gyrus olfactorius lateralis), to terminate apparently exclusively in the molecular layer, mainly in the cortex of the uncus (Flechsig's *temporale Riechsphäre*). According to Flechsig, the portion of the uncus in which the olfactory fibres terminate has a peculiar structure in that just beneath the uppermost layer (poor in cells) there exists a layer of "granules" (Körner) which agrees entirely in

structure with the nuclear layer of Ammon's horn, and indeed is continuous with it. As above mentioned, we may have to

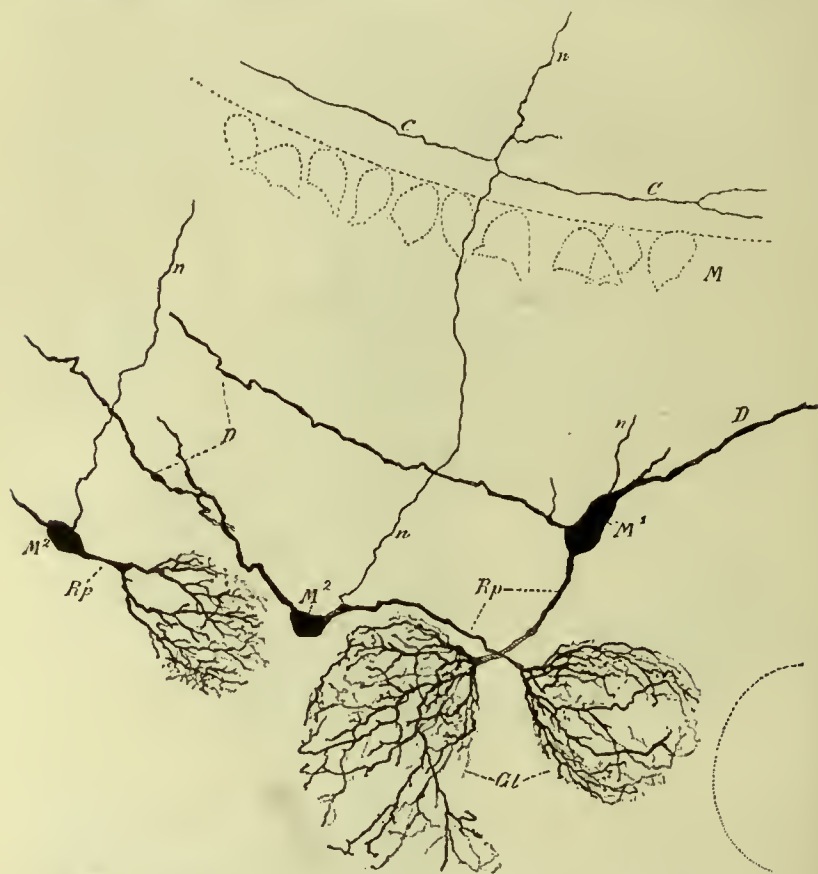

FIG. 482.—Bulbus olfactorius of a mouse twenty-four days old. Method of Golgi. (After A. von Kölliker, Handbuch der Gewebelehre, Bd. ii, Leipz., 1896, S. 707, Fig. 758.) *C*, collaterals; *Gl*, glomeruli; *M*, mitral cells; *M¹*, superficial large brush cell; *M²*, small brush cell; *Rp*, olfactory brush; *n*, axone.

deal here with the gyrus semilunaris and the gyrus ambiens rather than with the uncus proper. On their way to the uncus the olfactory fibres give off large numbers of collaterals to the double pyramidal cells which are situated in the adjacent gray matter of the rhinencephalon, each fibre thus entering into relations with a cerebral zone of considerable extent.

Of the fibres which run toward the stria medialis many ter-

minate in the gray matter of the trigonum olfactorium (Calleja).\* In the gray matter of this region the cerebral structure is much modified; here are situated the curious "olfactory islands" which were seen by Ganser but were first carefully described by Calleja (*islotes olfativos*) (Fig. 487). Each island, consisting of a mass of pyramidal cells (closely crowded to-

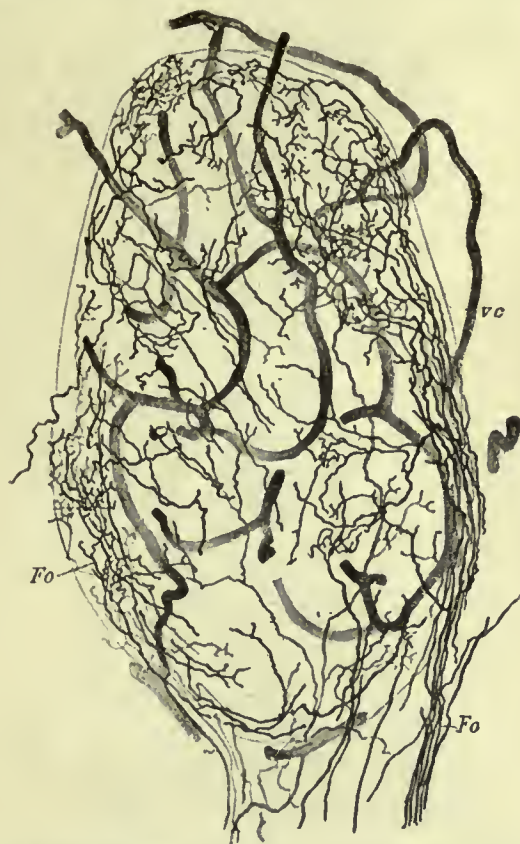

FIG. 483.—A glomerulus olfactorius from a young cat; method of Golgi. (After A. von Kölliker, *Handbuch der Gewebelehre des Menschen*, Bd. ii, Leipz., 1896, S. 701, Fig. 754). *Fo*, fila olfactoria breaking up into terminal branches inside the glomerulus; *vc*, capillary blood-vessels.

gether and distorted in shape), receives a large number of fibres which break up into an extremely rich end-plexus among the

\* Calleja, C. *La Region olfatoria del cerebro*. Madrid, 1893.

cells (Fig. 488). Some fibres from the medial olfactory stria reach the gyrus subcallosus and the basal beginning piece of the gyrus fornicatus which possesses a special structure characterized by the presence of only one ganglion cell layer (mostly spindle cells). Others positively reach the septum pellucidum and go by way of the fornix to Ammon's horn. The majority

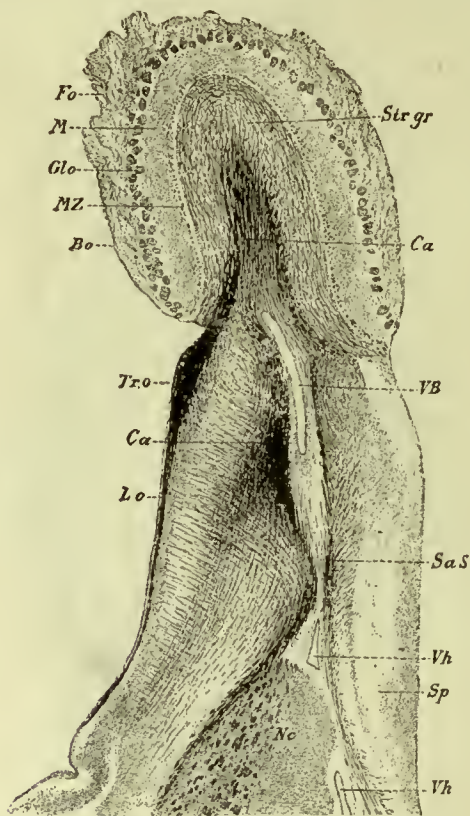


FIG. 484.—Bulbus et lobus olfactorius of a rabbit in horizontal section; Weigert's stain. (After A. von Kölliker, Handbuch der Gewebelehre, Bd. ii, 1896, S. 697, Fig. 750.) *Bo*, bulbus olfactorius; *Ca*, commissura anterior cerebri; *Fo*, fila olfactoria; *Glo*, glomeruli olfactorii; *Lo*, lobus olfactorius; *M*, molecular layer; *MZ*, mitral cells; *Nc*, nucleus candatus; *Sa S*, substantia alba septi; *Sp*, septum pellucidum; *Str gr*, stratum granulosum; *Tr o*, tractus olfactorius lateralis; *V B*, ventriculus bulbi; *Vh*, cornu anterius of the lateral ventricle.

of the fibres of the stria medialis are connected with the area parolfactoria of Broca. Thence, by means of neurones of a



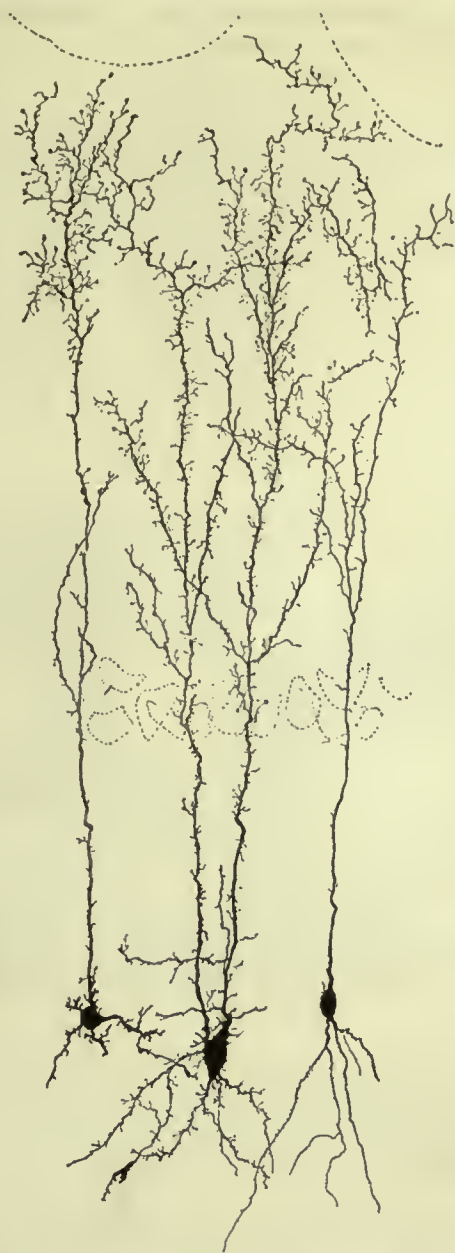

FIG. 485.—Three olfactory granules from a cat; method of Golgi. The contours of two glomeruli and of several large mitral cells are indicated. (After A. von Kölliker, *Handbuch der Gewebelehre*, Bd. ii, Leipz., 1896, S. 713, Fig. 702.)

higher order, connections with the induseum griseum, stria Lancisi, etc., are probably formed.

The fibres of the anterior commissure, much less developed in man than in many animals, enter the head of the nucleus caudatus, breaking up into two groups, an anterior set of fibres running to the olfactory bulb of the opposite side, the posterior, more numerous, running to terminate in the gyrus hippocampi (Edinger).

It is evident, therefore, that the axones of the mitral cells and of the brush cells (olfactory sensory neurones of the second order), as regards their terminals, are widely distributed. They end in different parts of the rhinencephalon of the same side, and by means of the anterior commissure in the rhinencephalon of the opposite side. Further, the various parts of the rhinencephalon are connected manifoldly with one another,

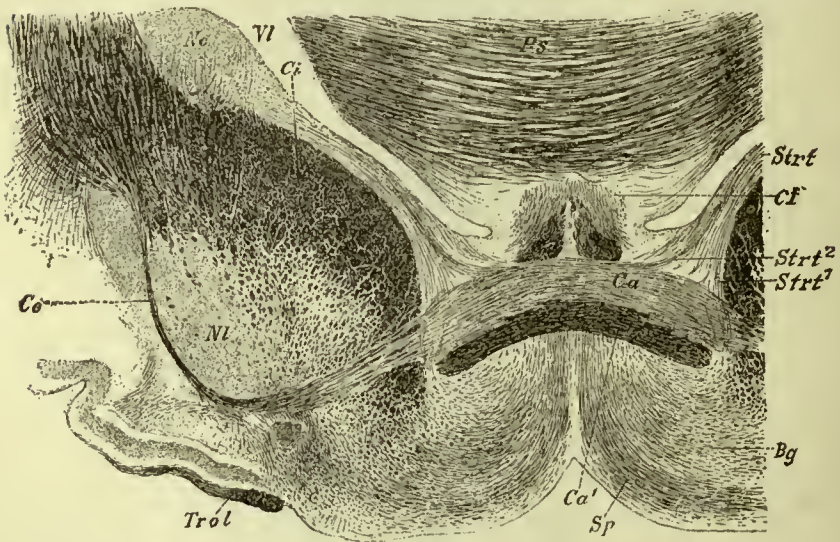


FIG. 486.—Ventral part of a frontal section of a rabbit's brain. (After A. von Kölliker, *Handbuch der Gewebelehre*, Bd. ii, Leipz., 1896, S. 722, Fig. 767.) *Bg*, basal ganglion; *Ca*, commissura anterior; *Ce*, capsula externa; *Cf*, columna fornicis; *Ci*, capsula interna; *Ne*, nucleus caudatus; *Nl*, nucleus lentiformis; *Ps*, commissura hippocampi; *Sp*, fibres from septum pellucidum; *Strt*, stria terminalis; *Strt¹*, portion of stria which goes to *Bg*; *Strt²*, portion of stria to anterior commissure; *Trol*, tractus olfactorius lateralis; *Vi*, ventriculus lateralis.

and with other parts of the brain. When the neurones in the gray masses in the tractus olfactorius, the trigonum olfactorium,

the area parolfactoria (Brocæ), the substantia perforata anterior, the gyrus olfactorius lateralis, etc., are considered in all

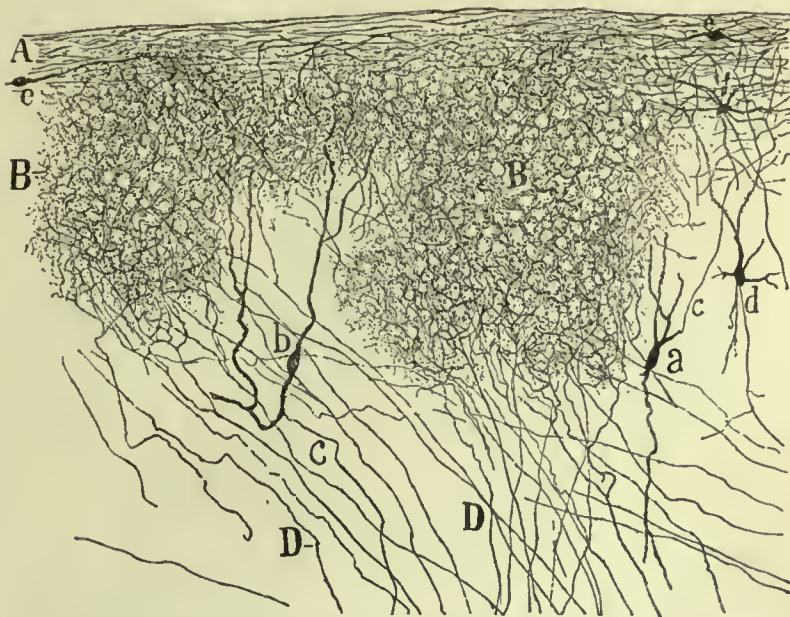


FIG. 487.—Islands of pyramidal cells in the tuberculum olfactorium of the rabbit; method of Golgi. (After C. Calleja, *La region olfactoria del cerebro*, Madrid, 1893, p. 19, Fig. 6.) *A*, external molecular layer; *B*, islands of pyramidal cells; *D*, nerve fibres running in to end in these islands; *a*, fusiform cell with ascending axone; *b*, fusiform cell with descending axone; *c*, axones of various cells; *e*, fusiform cells of molecular layer.

parts of which axones of neurones of the second order appear to terminate, the enormous number of olfactory neurones of the third and of higher orders may be vaguely appreciated.

Some interesting connections of these portions of the rhinencephalon with other parts of the brain have already been made out, though we are far from the possession of any adequate or exhaustive knowledge of all the relations which exist.

Thus there are manifold connections between the uncus (or perhaps the gyrus semilunaris and gyrus ambiens, *vide supra*) and the hippocampus (*cornu ammonis*) (*infra*, Fig. 489). The nucleus amygdalæ doubtless receives similar fibres. While there is no doubt about the intimate union of the hippocampus with the olfactory paths, there is still dispute as to whether the former



belongs to the rhinencephalon in the strict sense, or whether, as many think, it represents a portion of the pallium. The

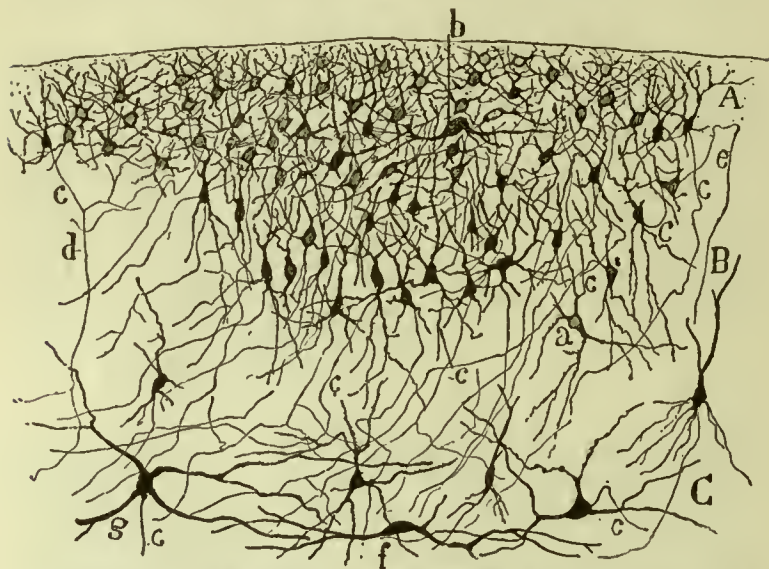


FIG. 488.—One of Calleja's islands in the olfactory tubercle of the rabbit. (After C. Calleja, *La region olfactoria del cerebro*, Madrid, 1893, p. 15, Fig. 3.) *A*, molecular layer; *B*, layer of pyramidal cells; *C*, layer of polymorphous cells; *a*, cell with ascending axis cylinder; *b*, large semilunar cell; *c*, various axones; *d*, cell with descending axis cylinder; *e*, axone which first ascends and later descends; *f*, fusiform cell of the deep layer; *g*, large stellate cell with descending axone.

general relations are well shown in the accompanying diagram taken from Edinger's text-book (Fig. 489). The hippocampus of one side is connected with that of the other by means of the commissura hippocampi.\*

The hippocampus makes important connections by way of the fornix with (*a*) the corpora mammillaria; (*b*) the nucleus habenulæ; and (*c*) the septum pellucidum and lobus olfactorius.

(*ad a*) The axones going to the corpora mammillaria pass through the whole length of the fornix (corpus fornicis) after arriving in it from the pyramidal cells of the hippocampus by way of the fimbria hippocampi,† the subiculum cornu ammonis, and the alveus. In the columna fornicis the fibres are arranged

\* Often spoken of as the psalterium or lyra.

† The fimbria hippocampi is sometimes spoken of as the limbus cornu ammonis. Von Kölliker calls it the fornix inferior.



in several bundles which can be easily followed to the corpus mamillare. Here a part of the axones end by ramifying in among the dendrites and cell bodies situated in the nucleus medialis corporis mamillaris. A large part of the fibres, however, form a knee in the corpus mamillare, and then, apparently, cross over to the opposite side, on the dorsal and posterior aspects of the corpora mamillaria (Ganser). The further fate of the crossed fibres is still not satisfactorily settled. According to Ganser they appear to go farther caudalward, in the teg-

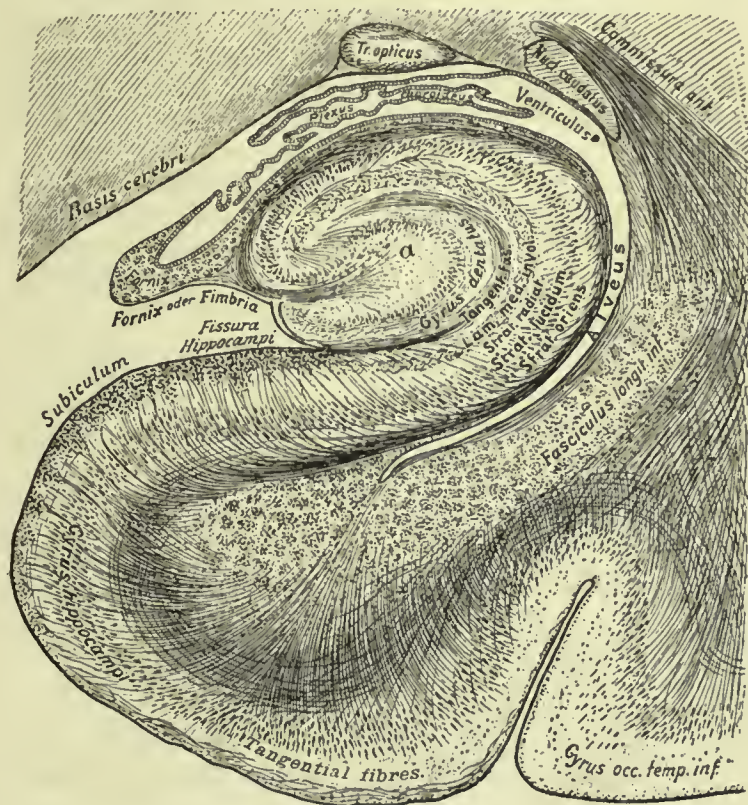


FIG. 489.—Section through the base of the brain and the hippocampus lying beneath it. (After L. Edinger, *Nervöse Centralorgane*, V. Aufl., Leipz., 1896, S. 225, Fig. 154.) Plexus chorioideus made simpler than the actual.

mentum of the pedunculus cerebri. Other observers, among them von Gudden and von Kölliker, follow them running

dorsalward between the fasciculi retroflexi to become lost in this region. The last-mentioned investigator \* inclines to the belief that they end in the nucleus nervi oculomotorii, or in the nucleus ruber, or in both. It is not impossible that they terminate in the stratum griseum centrale, since von Monakow † found this gray matter atrophic on the left side caudal from the corpus mammillare in a case of atrophy of the fornix on the right side.

Ramón y Cajal, however, does not find any decussation of the columnæ fornicis such as Ganser and others describe.

By means of the neurones, the cell bodies of which are situated in the corpora mammillaria, other important centres may be brought under the influence of the central conduction paths of the olfactory apparatus. Each corpus mammillare consists of at least two nuclei—(1) a large medial nucleus, representing the main mass; and (2) a smaller lateral nucleus, which occupies an area corresponding to the anterior half of the medial nucleus. It has for a long time been known that the corpus mammillare is connected with the nucleus anterior thalami by the fasciculus thalamomammillaris (or bundle of Vieq d'Azyr), and with both the tegmental and basilar portions of the cerebral peduncle by means of the fasciculi pedunculomammillares. Neurologists working with Weigert's method early noticed that the bundle of Vieq d'Azyr always fused with the tegmental bundle before entering the corpus mammillare. All believed, however, that the two fasciculi had a separate origin in the corpus mammillare. In this region again the method of Golgi, as applied by Ramón y Cajal, has been of service, since it has made it possible to demonstrate beyond controversy that the pars tegmentalis of the fasciculi pedunculomammillares and the fasciculus thalamomammillaris (Vieq d'Azyri) represent medullated axones which belong to the same set of neurones—indeed, are but the representatives of the two limbs of a fork-like bifurcation which the stem axones of the cells of the nucleus medialis corporis mammillaris undergo. The cells of the

---

\* von Kölliker, A. *Op. cit.*, S. 530.

† von Monakow, C. Experimentelle und pathologisch anatomische Untersuchungen neber die Beziehungen der sogenannten Sehspähre zu den infra corticalen Opticuseentren und zum N. opticus. *Arch. f. Psychiat. u. Nervenkr.*, Berl., Bd. xvi (1885), S. 181.

medial nucleus are, according to Ramón y Cajal,\* small, spindle-shaped, stellate, or triangular cells, which are provided with much-branching dendrites, and give off delicate axones difficult to follow on account of their tortuous course. The cell bodies

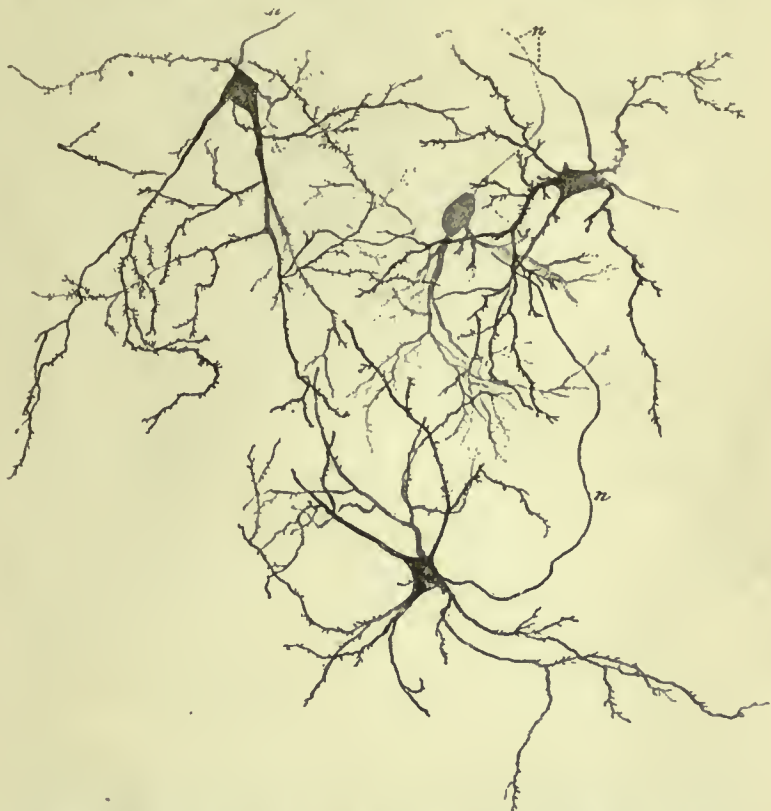


FIG. 490.—Group of cells from the pars medialis of the nucleus corporis mammillaris of a child. *n*, axones. (After A. von Kölliker, *Handbuch der Gewebelehre*, Bd. ii, Leipz., 1896, S. 529, Fig. 656.)

and dendrites have been successfully impregnated in human tissue (Fig. 490). Their axones pass dorsalward and somewhat lateralward. In a region outside the corpus mammillare, each bifurcates (Fig. 491) into an anterior process running to the nucleus anterior thalami, and a posterior, usually more delicate

---

\* Ramón y Cajal, S. *Beitrag zum Studium der Medulla oblongata*, etc. Deutsch von Bresler, Leipz. (1896), S. 111.



process, looking almost like a collateral branch which passes caudalward, to enter the tegmental bundle of the fasciculi pedunculomammillares.\*

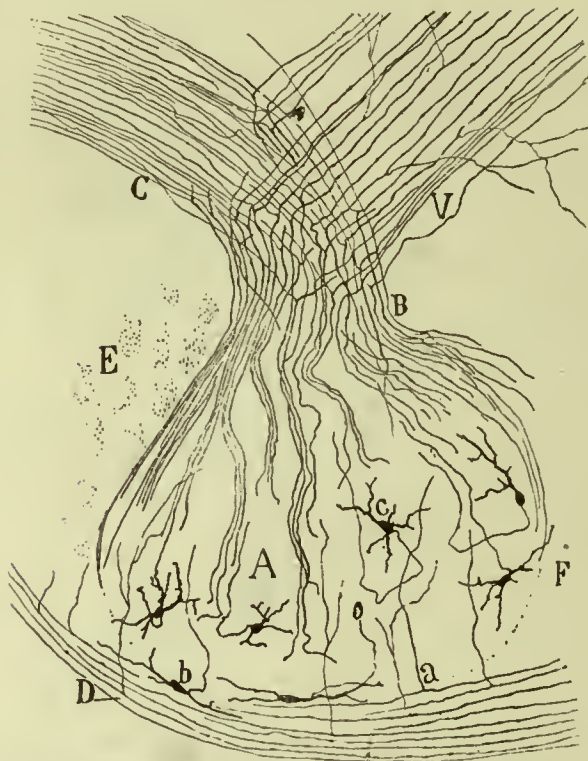

FIG. 491.—Sagittal section through the medial part of the corpus mammillare of a newborn mouse. (After S. Ramón y Cajal, *Beitrag zum Studium der Medulla Oblongata*, etc., Bresler, Leipz., 1896, S. 111, Fig. 26.) *A*, medial portion of nucleus corporis mammillaris; *B*, axones of the cells bifurcating to form two different bundles; *C*, fasciculus pedunculo-mammillaris, pars tegmentalis (*Haubenbündel* of von Gudden); *D*, axones of white capsule; *E*, commissura internammillaris; *F*, anterior region of nucleus corporis mammillaris, pars medialis; *V*, fasciculus thalamo-mammillaris Vieq d'Azyri; *a*, collateral from axone of capsule; *b*, superficial spindle-shaped cell; *c*, cell, the axone of which goes into the bundle *B* and bifurcates, sending one limb into *V*, the other into *C*.

\* von Kölliker has confirmed the work of Ramón y Cajal, and we have at the laboratory in Baltimore been able to see precisely similar pictures in sagittal sections of the embryo pig. The description given in the text holds for the mouse. In the rabbit the branch of bifurcation going to the tegmental bundle is stouter than that entering the fasciculus thalamomammillaris. Von Kölliker suggests that the bundle of stem axones be called the



The medullated axones of the fasciculus thalamomammillaris (Vicq d'Azyr) pass dorsalward and somewhat frontalward

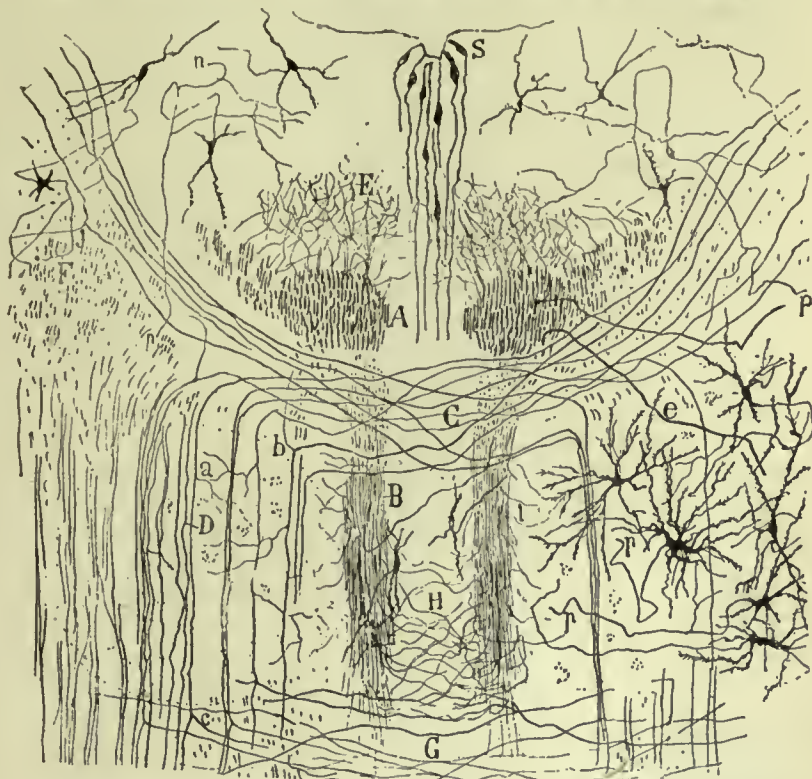

FIG. 492.—Frontal section through the nucleus ruber, the fasciculus longitudinalis medialis and the nucleus N. oculo-motorii of a fetal mouse. (After S. Ramón y Cajal, *Beitrag zum Studium der Medulla Oblongata*, etc., Bresler, Leipz., 1896, S. 114, Fig. 27.) A, fasciculus longitudinalis medialis; B, fasciculus pedunculo-mammillaris, pars tegmentalis (*Haubenbündel* of von Gudden); C, *fontaineartige Haubenkreuzung* of Meynert, or decussatio tegmenti dorsalis; D, descending bundle in formatio reticularis; E, nucleus N. oculo-motorii receiving collaterals from the fasciculus longitudinalis medialis; F, longitudinal fibres in the tegmentum; G, decussatio tegmenti ventralis (Forel's *Haubenkreuzung*); H, middle decussation or decussation of von Gudden's bundle; I, epithelium of aqueductus cerebri; a, collaterals from the descending bundle in formatio reticularis to the nucleus ruber; b, bifurcation of the fibres of the former; e, fibres of large calibre which enter the fasciculus longitudinalis medialis; b, axones of cells of nucleus ruber which pass dorsalward. Lateral from the nucleus N. oculo-motorii one sees cells the axones of which, after giving off collaterals to the stratum griseum centrale, turn to run longitudinally in the formatio reticularis.

*fasciculus mammillaris princeps*, and that the bundles corresponding to the two limbs of bifurcation be called the *fasciculus thalamomammillaris* and the *fasciculus tegmentomammillaris* respectively.

toward the nucleus anterior thalami, where the fibres diverge to come into contact with all portions of the nucleus. The individual axones inside the nucleus break up into numerous terminal branches which ramify freely in among the cell bodies and dendrites situated there.

The medullated axones of the pars tegmentalis of the fasciculi pedunculomammillares (*Haubenbündel* of von Gudden) pass caudalward into the tegmentum of the cerebral peduncle. Their ultimate destiny is still obscure. Von Gudden\* believed the bundle to be connected with the ganglion profundum tegmenti, which he described in the rabbit, but this nucleus is not well marked in human beings. The axones have been followed by Ramón y Cajal in the mouse as extremely fine fibres through the red nucleus down into the pons in the region of the corpus trapezoideum, where this tegmental bundle can still be made out as a few fine fibres lying ventral to the fasciculus longitudinalis medialis. Collaterals are given off to the medial side of the red nucleus in passing. He finds, further, a decussation of many of the axones of the bundle near the plane in which is situated the decussatio brachii conjunctivi. This decussation may be designated the middle decussation of the tegmentum, inasmuch as it lies between the dorsal decussation (Meynert's *fontaineartige Haubenkreuzung*) and the ventral decussation (Forel's *ventrale Haubenkreuzung*) (Fig. 492).

Held's studies of the region of the decussationes tegmenti are among the most interesting that have been published. Three of the figures accompanying his article are here reproduced (Figs. 493, 494, and 495).

The axones of the nucleus lateralis corporis mammillaris help to make up the *pars basilaris* of the fasciculi pedunculomammillares. This bundle of medullated axones, often spoken of as the pedunculus corporis mammillaris, runs caudalward into the cerebral peduncle. The inferior termination of this is as yet uncertain. A part probably runs to end in the ganglion tegmentum dorsale of von Gudden. Flechsig states that it terminates in the stratum griseum centrale, and that thus olfactory stimuli can be transferred to this gray matter and thence to the medulla oblongata with its nerve nuclei and automatic centres.

---

\* von Gudden. Gesammelte Abhandlungen, No. xxvii.

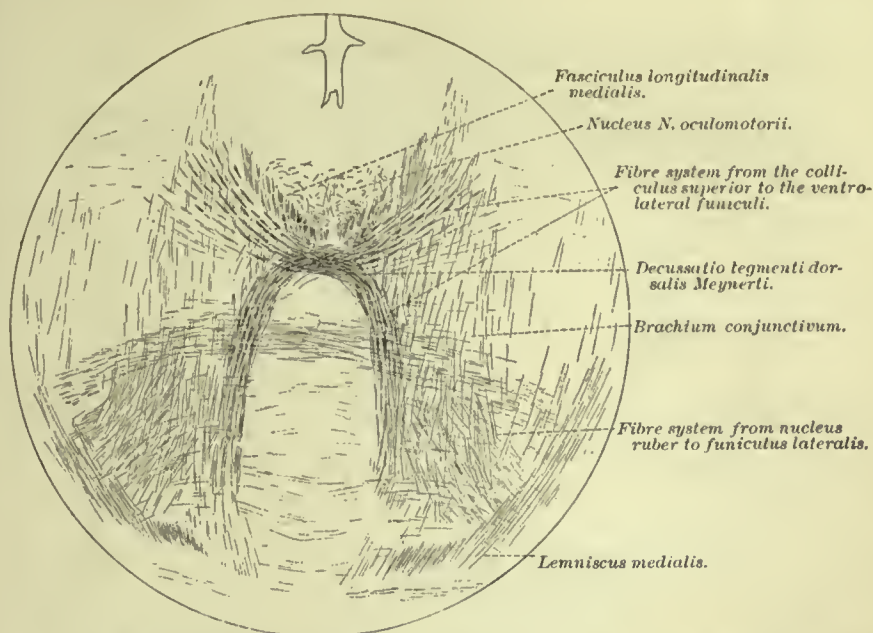


FIG. 493.—Oblique section through the brain stem of a cat four days old. (After H. Held, Abhandl. d. math.-phys. Kl. d. k. sächs. Gesellsch. d. Wissensch., Leipz., Bd. xviii, No. 6, 1892, Taf. ii, Fig. 7.)

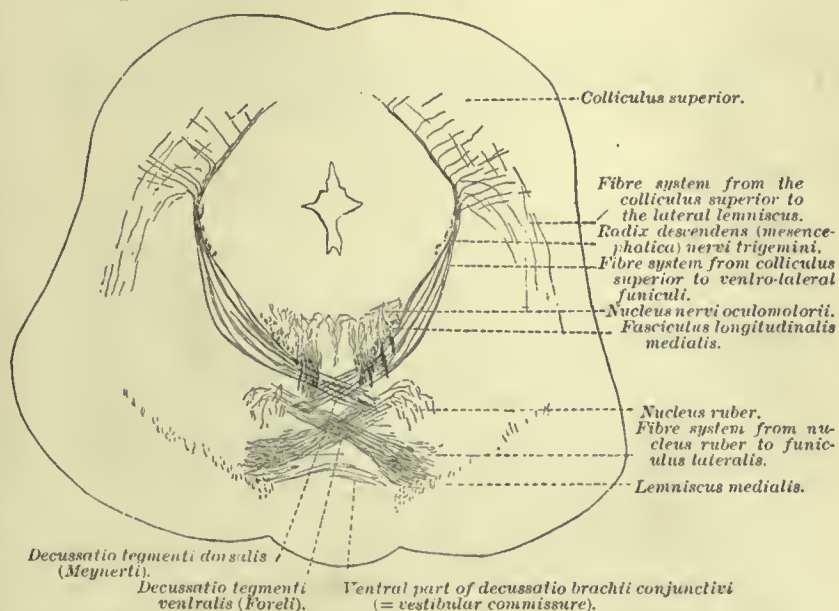


FIG. 494.—Oblique section through the brain stem of a cat four days old. (After H. Held, Abhandl. d. math.-phys. Kl. d. k. sächs. Gesellsch. d. Wissensch., Leipz., Bd. xviii, No. 6, 1892, Taf. ii, Fig. 6.) The decussationes tegmenti are well illustrated.



(*ad b*) The hippocampus is connected with the nucleus habenulæ by way of the fornix and the stria medullaris thalami.

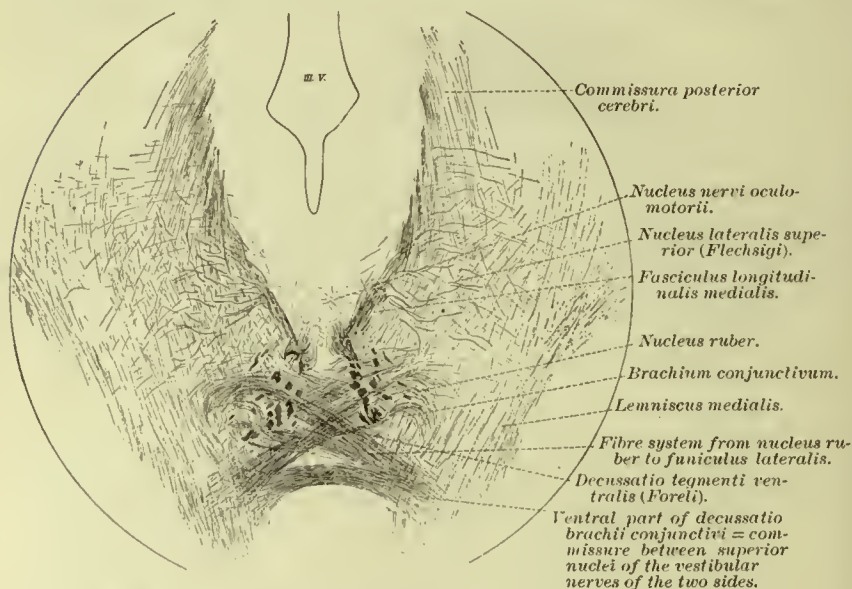


FIG. 495.—Oblique section through the brain stem of a cat eleven days old, illustrating the origin of many fibres of the fasciculus longitudinalis medialis from the nucleus lateralis superior (Flechsigi). (After H. Held, Abhandl. d. k. sächs. Gesellsch. d. Wissensch., Leipz., Bd. xviii, No. 6, 1892, Taf. iii, Fig. 10.)

The term stria medullaris is applied to the band of white matter adjacent to the tænia thalami. The latter term is limited to the line representing the junction of the white matter with the simple epithelial layer which forms, over a certain area, the wall of the ventricle. The tænia thalami begins in front of the corpus pineale and follows the free border of the stria medullaris, being continuous with the narrow epithelial lamina which covers the plexus chorioides medius on its under surface (Fig. 496). At the foramen of Monro the tænia thalami bends around backward into the tænia chorioidæa (His). A study of sagittal sections of the brain of man and animals shows that a number of the fibres running forward from the hippocampus in the fornix, near the region of the anterior commissure, turn back, following an acute curve to enter the stria medullaris thalami. This bundle from the fornix, which, by the way, appears to give



rise to the more ventral portion of the stria medullaris, is joined by a bundle of fibres from the ganglion basale. These relations are graphically illustrated in the accompanying scheme of a sagittal section of the rabbit's brain taken from von K  lliker (Fig. 497). A similar scheme is to be found in Edinger's text-book. It seems likely that in the stria medullaris axones run in both directions, though those we are now considering run toward the nuclens habenul   to end inside it among the cells and their processes situated there.

The nucleus habenul  , a part of the epithalamus, is situated in the trigonum habenul   lateral from the corpus pineale. It contains larger and smaller cells, the former predominating in the lateral portion of the nuclens, the latter in the medial portion. It has long been known that the nuclens habenul   is connected with the interpeduncular region by a strong band of medullated fibres—the fasciculus retroflexus (Meynerti). Studies by Golgi's method undertaken by van Gehuechten,\* Ram  n,† and von K  lliker‡ have shown that axones of Meynert's bundle arise from the cell bodies or dendrites of the nucleus ha-

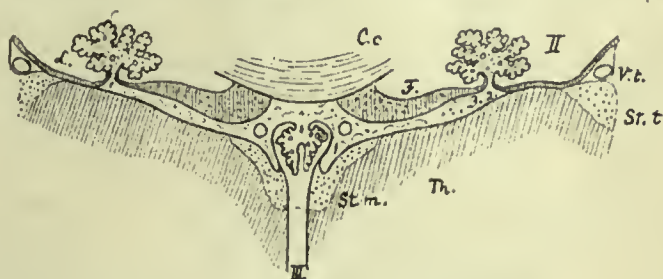


FIG. 496.—Transverse section through the tela chorioidea ventriculi tertii and its neighborhood. (After W. His, *Die Anatomische Nomenclatur*, etc., Leipz., 1895, S. 166, Fig. 21.) II, ventriculus lateralis; III, ventriculus tertius; Cc, corpus callosum; F, fornix; Th, thalamus; St.m, stria medullaris; St.t, stria terminalis; V.t, vena terminalis; L, lamina affixa; 1, tania thalami; 2, tania chorioidea; 3, tania fornicis. The figure shows the transition of the teniae into the epithelial layer of the plexus chorioidei.

benul  , and that the coarser fibres arise in the lateral, the finer fibres in the medial portion of the nucleus.

\* van Gehuechten, A. Contributions a l'  tude du syst  me nerveux des Teleost  ens. *Cellule, Lierre et Louvain* (1895), t. x.

† Ram  n, D. S. *Anales de la Sociedad espanola de historia natural*, t. iii, 2 Ser. (1894), p. 185.

‡ *Op. cit.*, S. 483.



The medullated axones of Meynert's bundle run obliquely ventralward and somewhat caudalward to the interpeduncular

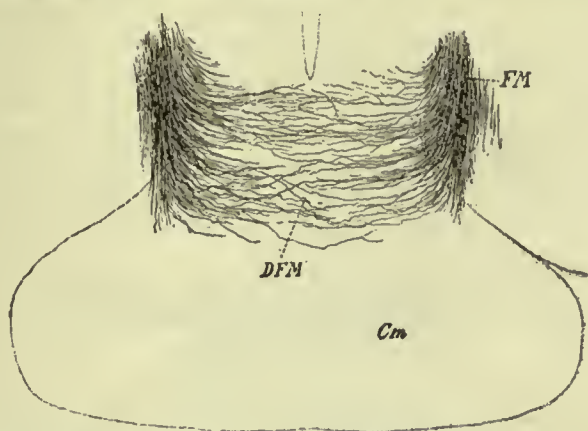


FIG. 498.—Golgi preparation from the peduncular region of a mouse five days old. (After A. von Kölliker, *Handbuch der Gewebelehre*, Bd. ii, Leipz., 1896, S. 487, Fig. 620.) *Cm*, corpus mammillare; *FM*, fasciculus retroflexus Meynerti; *DFM*, decussation of its terminal axones.

region, where (in animals at least) they terminate in the ganglion interpedunculare of von Gudden. In the mouse, according to von Kölliker, there is a terminal decussation (Fig. 498).

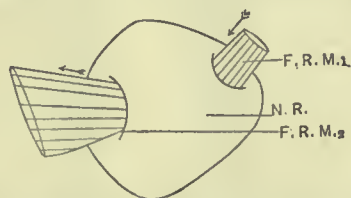


FIG. 499.—Diagram illustrating the relation of Meynert's bundle to the red nucleus. (From a reconstruction by Miss Florence Sabin, Baltimore, 1898.) *F.R.M. 1*, fasciculus retroflexus Meynerti entering the anterior extremity of the nucleus ruber; *F.R.M. 2*, fasciculus retroflexus Meynerti leaving the inferior extremity of nucleus ruber; *N.R.*, nucleus ruber.

The course of these fibres can be followed with the greatest ease in the brain of the newborn babe.\* Florence Sabin has reconstructed the bundle in this laboratory. She describes it as

\* Curiously enough, the more peripheral fibres of Meynert's bundle become medullated first, so that in horizontal sections stained with the Weigert-Pal method the section of the bundle is colorless in the centre but deeply-stained blue-black at the periphery.

follows: "The bundle enters the nucleus ruber, on its medial aspect, near the anterior extremity of the nucleus. The place of entry is a small area which, measured on the dorso-ventral diameter, is about one third the distance from the dorsal surface. The fibres pass obliquely through the nucleus, so that the place of exit is opposite the middle of the same diameter. After emerging from the nucleus ruber the fibres spread out into a bundle, the dorso-ventral diameter of which is nearly three times as great as that of the entering bundle. This mass of fibres lies just ventral to the nucleus ruber of either side,

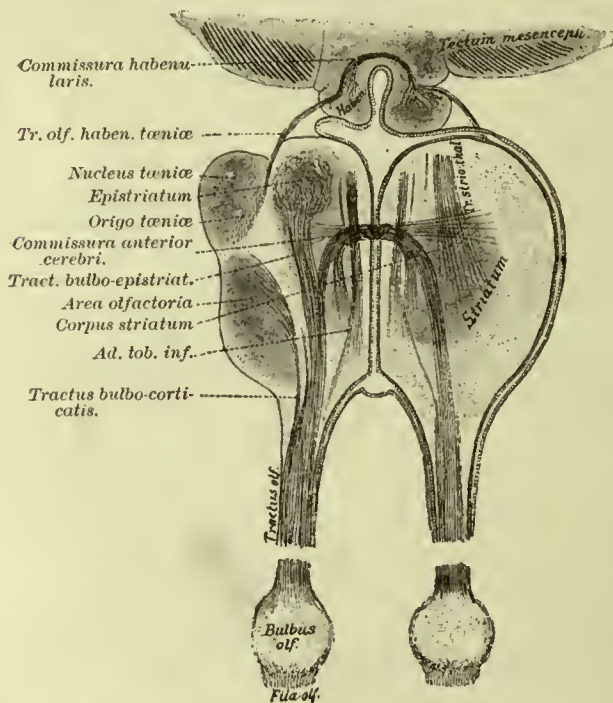


FIG. 500.—Scheme of a horizontal section through the brain of *Cyprinus carpio*. (After L. Edinger and Alice Hamilton, from Edinger's *Nervöse Centralorgane*, V. Aufl., Leipz., 1896, S. 145, Fig. 98.) The figure shows the individual subdivisions of the rhinencephalon and the course of the olfactory fibres. All parts projected into one plane.

very near the surface of the fossa interpeduncularis. Some of the root fibres of the nervus oculomotorius pass through this area. With a high power a few nerve cells can be seen between these fibres, the group probably corresponding to the ganglion



interpedunculare" (Fig. 499). Von Kölliker denies the existence of a ganglion interpedunculare in man, and states that the

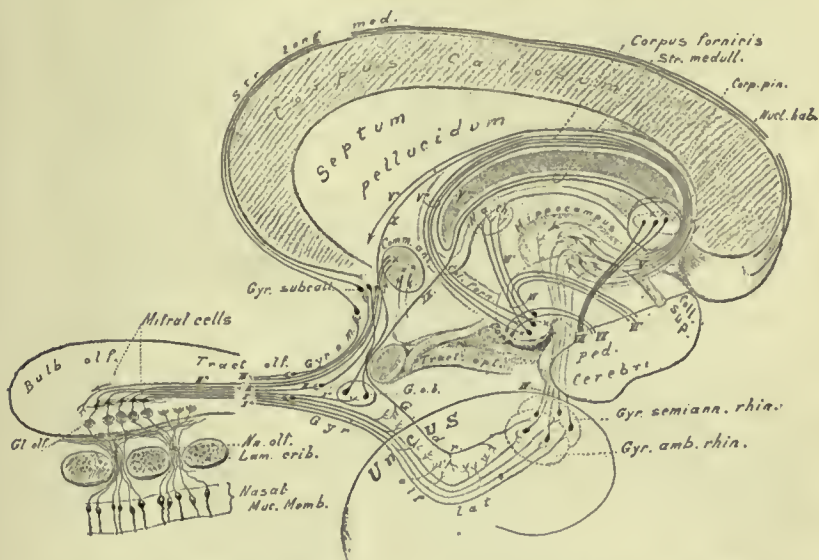


FIG. 501.—Schematic representation of some of the principal neurone systems of the olfactory conduction path. Projected into sagittal plane. *Bulb. olf.*, bulbus olfactorius; *Col. forn.*, columna fornix; *Col. sup.*, colliculus superior; *Comm. ant.*, commissura anterior cerebri; *Corp. mam.*, corpus mamillare; *Corp. pin.*, corpus pineale; *G. o. b.*, ganglion opticum basale; *Gl. olf.*, glomeruli olfactorii; *Gyr. amb. rhin.*, gyrus ambiens rhinencephali; *Gyr. olf. lat.*, gyrus olfactorius lateralis; *Gyr. o. m.*, gyrus olfactorius medialis; *Gyr. semilun. rhin.*, gyrus semilunaris rhinencephali; *Gyr. subcall.*, gyrus subcallosus; *Lam. crib.*, lamina cribrosa; *N. a. th.*, nucleus anterior thalami; *Nu. olf.*, nervi olfactorii; *Nucl. hab.*, nucleus habenulae; *Ped. cerebri*, pedunculus cerebri; *Str. long. med.*, stria longitudinalis medialis; *Str. medull.*, stria medullaris; *Tract. olf.*, tractus olfactorius; *Tract. opt.*, tractus opticus; *I*, axones of mitral cells going to stria olfactoria lateralis; *I'*, axone of mitral cell terminating in gray matter of trigonum olfactorium; *II*, axone of mitral cell terminating in gray matter of trigonum olfactorium; *II'*, axone of mitral cell terminating in gray matter of trigonum olfactorium; *III*, axone of mitral cell terminating in gyrus olfactorius medialis; *IV*, axones of neurones connecting the olfactory portion of the mucus (gyrus ambiens and gyrus semilunaris) with the hippocampus (cornu ammonis); *V*, axones from hippocampus to fornix; *V'*, axone to commissura hippocampi; *V''*, axones from fornix to septum pellucidum; *V'''*, axones from fornix to corpus mamillare; *V''''*, axone from fornix to nucleus habenulae by way of the stria medullaris; *VI*, fasciculus mammillaris princeps; *VI'*, fasciculus thalamo-mammillaris Vieq d'Azyri; *VI''*, fasciculus pedunculo-mammillaris, pars tegmentalis (*Haubenbündel* of von Gndden); *VI'*, fasciculus pedunculo-mammillaris, pars basilaris (pedunculus corporis mammillaris); *VIII*, fasciculus retroflexus Meynerti extending from the nucleus habenulae to the ganglion interpedunculare.

fibres of the fasciculus retroflexus become lost in the lamina perforata posterior.

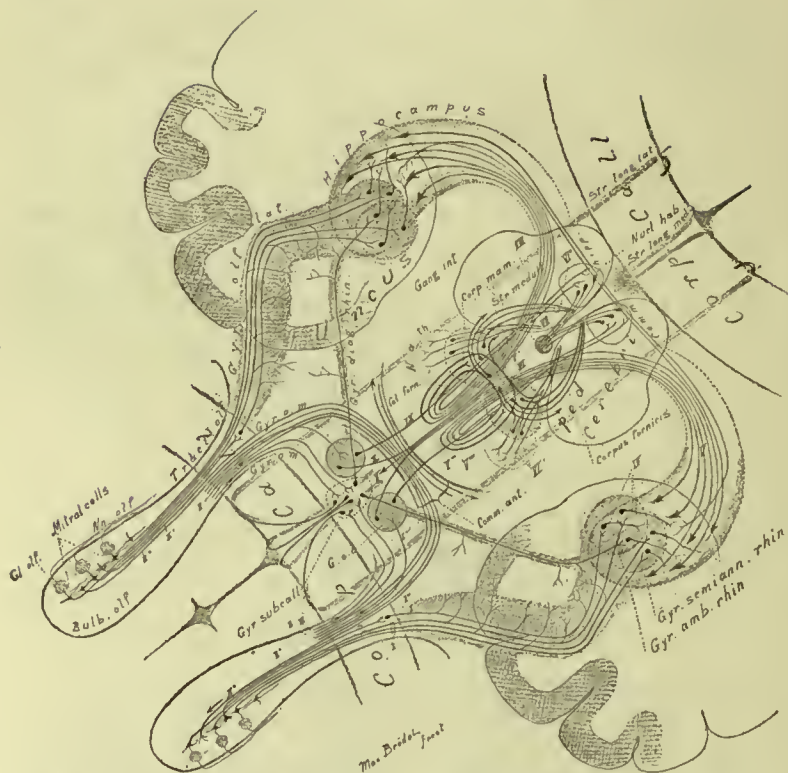


FIG. 502.—Schematic representation of some of the important neurone systems of the olfactory conduction paths; projection in horizontal plane. *Bulb. olf.*, bulbus olfactorius; *Col. forn.*, columna fornicis; *Comm. ant.*, commissura anterior cerebri; *Comm. hipp.*, commissura hippocampi; *Corp. call.*, corpus callosum; *Corp. mam.*, corpus mammillare; *Gang. int.*, ganglion interpedunculare; *Gl. olf.*, glomeruli olfactorii; *G. o. b.*, ganglion opticum basale; *Gyr. amb. rhin.*, gyrus ambiens rhinencephali; *Gyr. diag. rhin.*, gyrus diagonalis rhinencephali; *Gyr. o. m.*, gyrus olfactorius medialis; *Gyr. olf. lat.*, gyrus olfactorius lateralis; *Gyr. semiann. rhin.*, gyrus semi-lunaris rhinencephali; *Gyr. subcall.*, gyrus subcallosus; *N. a. th.*, nucleus anterior thalami; *Na. olf.*, nervi olfactorii; *Nucl. hab.*, nucleus habenulae; *Ped. cerebri*, pedunculus cerebri; *Str. long. lat.*, stria longitudinalis lateralis; *Str. long. med.*, stria longitudinalis medialis; *Str. medull.*, striae medullares; *I*, axones of mitral cell to lobus pyriformis; *I'*, axone of cell in gray matter of tractus olfactorius; *I''*, axone to basal optic ganglion; *II, II'*, axones to commissura anterior cerebri; *II''*, centrifugal axone terminating in bulbus olfactorius; *III*, axone to gyrus subcallosus; *IV*, neurones the axones of which connect the temporal olfactory sense area with the hippocampus; *V*, axones from hippocampus to fornix; *V'*, corpus fornicis; *V''*, axones from fornix to corpus mammillare; *V'''*, axones from fornix to stria medullaris; *V'*, neurones in corpora mammillaria giving off axones which bifurcate to form the fasciculus thalamo-mammillaris and the fasciculus pedunculo-mammillaris, pars tegmentalis; *VI*, axones of fasciculus thalamo-mammillaris Vieq d'Azyri terminating in the nucleus anterior thalami; *VI'*, fasciculus pedunculo-mammillaris, pars tegmentalis; *VII*, fasciculus pedunculo-mammillaris, pars basilaris; *VIII*, fasciculus retroflexus Meynerti; *IX*, axone from basal optic ganglion through stria medullaris to nucleus habenulae; *X*, axone from basal optic ganglion through the fornix to the hippocampus.

(*ad c*) Extending from the fornix into the septum pellucidum are many medullated fibres, some of which doubtless represent axones of cells in the hippocampus. Some of these may be continued farther into the basal ganglion or even into the olfactory lobe. In all probability these are accompanied by fibres running in the opposite direction, but thus far definite statements concerning the exact origin and termination of the white fibres of the septum pellucidum are not justifiable.

The study of the comparative anatomy of the olfactory apparatus has been prosecuted, among others, by Herrick, A. Meyer, Edinger, and Alice Hamilton. The last-mentioned investigators have recently pictured the relations in the olfactory apparatus of the carp. Their scheme of the tracts in this fish is reproduced in Fig. 500. It will be seen that in the carp the medial part of the secondary olfactory path ends in what Edinger calls the epistriatum; the lateral part terminates in more ventral portions of the brain stem in the posterior part of the rhinencephalon. In Figs. 501 and 502 I have represented schematically the principal groups of olfactory neurones thus far made out. It is not to be forgotten, however, that these are only schemes which must be recast as our knowledge of the complex relations advances.

## CHAPTER LIII.

### OPTIC NEURONES OF THE SECOND ORDER AND OF HIGHER ORDERS.

The morphological position of the N. opticus—Ganglion cells of the retina—Their axones—Chiasma opticum—Fasciculus cruciatus—Fasciculus non-cruciatus—Tractus opticus—Its lateral and medial roots—Termination in mesencephalon and diencephalon—Fibres to colliculus superior, corpus geniculatum laterale, and pulvinar—Commissura inferior Guddeni—Commissura superior Meynerti—Hemispheric bundle of von Gudden—Commissura ansata of Hannover—Commissura hypothalamica anterior—Tractus peduncularis transversus.

Optic neurones of Order III—The structure of the colliculus superior and the distribution of the axones arising there—The corpus geniculatum laterale and its connections—Radiatio occipito-thalamica (Gratioleti)—“Optic radiation in the narrower sense”—Superficial and deep optic paths of Ramón y Cajal—The cortical visual sense area—Hemianopsia and certain other pathological conditions—Pupillary paths—Schematic representation of principal neurone systems in visual induction path.

#### 3. Central Neurones of the Visual Conduction Paths.

It has been pointed out on an earlier page that the so-called N. opticus is in reality not a peripheral nerve at all, since it is not comparable with true peripheral nerves which contain only processes of peripheral neurones (sensory or motor). For the visual sensory system actual analogies of the peripheral sensory neurones of other systems were seen to be the bipolar cells of the retina, the cell bodies of which correspond to the “inner nuclear layer,” with dendrites distributed to the “outer molecular layer,” and with axones terminating in the “inner molecular layer” among the dendrites of the ganglion cells. The true *nuclei terminales* of the optic neurones of the first order, therefore, are situated within the retina itself. The medullated axones of the ganglion cells of the retina, which go to form the so-called N. opticus, are in reality nerve fibres inside the central



nervous system,\* and are analogous to the medullated axones of sensory neurones of the second order of other sensory conduction paths (e. g., internal arcuates and fibres of the medial lemniscus from the nucleus funiculi gracilis and the nucleus funiculi cuneati, medullated axones of the mitral cells in the bulb and tractus olfactorius). The fibres of the optic nerve and tract, besides in decussating, resemble the medial lemniscus, in that they terminate in the midbrain and interbrain.†

To call the band of fibres running from the eye toward the brain the "optic nerve" is therefore to be guilty of an inconsistency in nomenclature, though the term has been so long and so universally in use, before the actual relations were discovered, that its elimination would be difficult if not impossible, even if the attempt were thought to be advisable. It seems worth while, however, in order to avoid confusion of ideas, especially for the beginner, to emphasize the fact that the designation is a misnomer.

The appearance of the ganglion cells in the retina is familiar to all. The irregularly oval cells are multipolar, the dendrites running to the adjacent inner molecular layer, where they branch manifoldly, and come into relation with the axones of the bipolar cells. We have seen, in considering the peripheral optic neurones, that certain of these are related only to rods, others only to cones. The majority of the ganglion cells, on the other hand, appear to stand in relation to both sorts of bipolar cells, though it is not impossible that some of them, especially the monostratified forms, are connected with only one sort. The dendrites of some ganglion cells (Fig. 503) spread out in one horizontal plane of the molecular layer (monostratified cell), of others in several planes (polystratified cells), of still others throughout the whole thickness of the molecular layer (diffuse cells). The dendrites occasionally

---

\* In the so-called *N. opticus* are many glia cells, similar to those of the *substantia alba* of other parts of the central nervous system.

† Luys, and with him Meynert (S. Stricker, *A Manual of Histology*, Am. transl., ed. by A. H. Buck, 8vo, New York, 1872, p. 688), compared the retina to the bulb olfactorius, and suggested that the optic nerve was not an ordinary peripheral nerve, but in reality a central tract. Von K lliker (*Entwicklungsgeschichte des Menschen und der h heren S tgethiere*, ii Auflage) stated also that the *nervus opticus* is really a part of the brain. He compared it with the tractus olfactorius and considered the optic tracts analogous to the strie olfactori .

penetrate in among the cell bodies of the optic neurones of the first order (inner nuclear layer). Here and there at tolerably regular intervals giant ganglion cells can be made out. These as a rule correspond to very large bipolar cells in the inner nuclear layer, and it has been suggested that these are signs that the retina is divisible into more or less definite provinces, which possibly may be of importance from a physiological standpoint (Krause).

The axones of the ganglion cells pass into that layer of the retina known as the "layer of optic nerve fibres." They all run toward the "blind spot," or *papilla nervi optici*, and plunge through the *tunicæ optici* to enter the so-called *nervus opticus*. In the retina itself the axones are, except in rare instances, devoid of myelin sheaths. From the *papilla* on, however, they are medullated, though, like other white fibres within the central nervous system, they are distinguishable from those of peripheral nerves in that they possess no nucleated sheath of Schwann (or neurilemma). That the fibres of the optic nerve really have their origin in the ganglion cells of the retina has been proved over and over again by embryological study (Mall, His), by the study of secondary degenerations (von Monakow, Ganser, Manz, and others), and directly by means of Golgi's method (Tartuferi, Ramón y Cajal).

Since von Gudden undertook the investigation of the optic paths \* we have known that fibres of different calibre occur in

---

\* The contributions of Bernhard von Gudden bearing upon the visual conduction paths are the following: (1) Ueber das Verhältniss der Centralgefässe des Auges zum Gesichtsfelde. *Arch. f. Anat., Physiol u. wissenschaft. Med.*, Berl., 1849, S. 522-532.—(2) Experimentaluntersuchungen ueber das peripherische und centrale Nervensystem. *Arch. f. Psychiat. u. Nervenkr.*, Berl., Bd. ii (1870), S. 693-723.—(3, 4, 5 and 6) Ueber die Kreuzung der Nervenfasern im Chiasma nervorum opticeorum. *Arch. f. Opth.*, Berl., Bd. xx (1874), 2. Abth., S. 249-268; Bd. xxi, 3. Abth. (1875), S. 199-204; Bd. xxv, 1. Abth. (1879), S. 1-56; Bd. xxv, 4. Abth. (1879), S. 237-246.—(7) Demonstration von Präparaten ueber das sog. Ganglion opticum basale, Kreuzung der Schnervfasern im Chiasma, vordere und hintere Commissur des Chiasma. *Allg. Ztschr. f. Psychiat.*, Berl., Bd. xxix (1873); Bd. xxx (1874).—(8) Experimente, durch die man die verschiedenen Bestandtheile des Tractus opticus zu isoliren im Stande ist. *Tagebl. d. 54 Versamml. deutsch. Naturforscher in Salzburg* (1881), S. 187.—(9) Ueber die verschiedenen Nervenfasersysteme in der Retina und im Nervus opticus. *Tagebl. d. 55 Versamml. deutsch. Naturforscher in Eisenach* (1882), S. 307.—(10) Ueber die Schnerven, die Sehtractus, das Verhältniss ihrer gekreuzten und ungekreuzten Bündel,

the optic nerve—(a) coarse fibres and (b) fine fibres. Salzer's \* counts made each optic nerve contain 438,000 fibres; Krause subsequently showed that, including the finer fibres, each optic nerve contains 1,000,000 fibres. There are about 1,000,000 cells in the ganglion cell layer of the retina. The majority of researches (von Gudden, von Monakow) point to the view that the finer fibres are connected with the superior colliculus of the corpora quadrigemina, but von Leonowa states that many go also to the lateral geniculate body.

Having reached the chiasma opticum, a large proportion of the fibres (fasciculus cruciatus) of one nervus opticus cross over

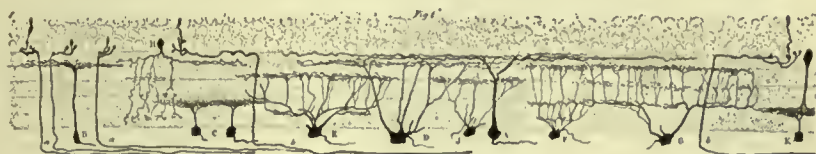

FIG. 503.—Nerve cells from the retina of the chick. (After S. Ramón y Cajal, *Die Retina der Wirbelthiere*, Greff, Wiesb., 1894, Taf. v, Fig. 1.) A, ganglion cell which spreads out in the first sublayer; B, ganglion cell for the second sublayer; C, small ganglion cell for the fourth sublayer; D, multipolar cell for the second sublayer; E, a cell which forms two horizontal plexuses, the first below the fourth sublayer, the second in the third sublayer; F, small cell with two fine plexuses, the first in the second sublayer, the second in the fourth; G, giant cell which forms three plexuses situated in the second, third, and fourth sublayers; H, cell with extremely fine plexus in the third sublayer; I, cell which branches in the fourth sublayer, its branches becoming involved with an amacrine cell going to the same layer; J, another centrifugal fibre; a, centrifugal fibre; b, another centrifugal fibre the terminal of which goes in a horizontal direction beyond the internal plexiform layer.

to enter the tractus opticus of the opposite side; a certain number of fibres (fasciculus non-cruciatus), however, do not cross but enter the tractus opticus of the same side. The fasciculus cruciatus is ordinarily much larger than the fasciculus non-cruciatus; the former appears to correspond to the fibres arising from the ganglion cells of rather more than one half of the retina on its medial or nasal side, the latter to the fibres arising from the ganglion cells of rather less than one half of

ihre Seh- und Pupillarfasern und die Centren der letzteren. *Tagebl. d. 58 Versamml. deutsch. Naturforscher in Strassburg* (1885), S. 136.

All these have been reprinted, together with his researches on other subjects, in Bernhard von Gudden's *Gesammelte und hinterlassene Abhandlungen*. Hrsg. von Dr. H. Grashey, Wiesbaden (1889).

\* Salzer, F. Ueber die Anzahl der Sehnervenfasern und der Retinazapfen im Auge des Menschen. *Sitzungsber. d. k. Akad. d. Wissensch., Math.-naturw. Cl., Wien*, Bd. lxxxi (1880), 3. Abth., S. 7-23.

the retina on its lateral or temporal side. The fibres of the two fasciculi in the chiasm of human beings are not, however, present in the form of definite bundles; those of one fasciculus interweave with those of the other of the same side and those of both of the opposite side in so complex a manner that to follow individual fibres, even in faultless serial sections, is probably an impossibility.

The secondary degenerations observed in pathological cases in higher mammals and in human beings (Gowers,\* Kellermann,† von Gudden,‡ Purtscher,§ Baumgarten,|| Singer and Munzer,^ Burdach,◇ Marehand,↓ Schmidt-Rimpler,↑ Jacobsohn (‡)) prove beyond reasonable question that there is a semi-decussation, not a total crossing, in the optic chiasm.\*\* In many of the somewhat lower forms, for example in the guinea-pig, the decussation is total. In the rabbit the decussation is almost total, but von Gudden and others have stoutly maintained

\* Gowers, W. R. Pathologischer Beweis einer unvollständigen Kreuzung der Sehnerven beim Menschen. Centralbl. f. d. med. Wissensch., Berl. (1878), Bd. xvi, S. 562.

† Kellermann, M. Anatomische Untersuchungen atrophischer Sehnerven mit einem Beitrag zur Frage der Sehnervenkreuzung im Chiasma. Stuttg. (1879), pp. 44, 8vo.

‡ *Op. cit.*

§ Purtscher, O. Traité sur le croisement et l'atrophie des nerfs et des tractus visuels. Cong. périod. internat. d'ophth. Compt.-rend. 1880, Milan (1881), t. vi, pp. 320-327.

|| Baumgarten, P. Zur sog. Semidecussation der Opticusfasern. Centralbl. f. med. Wissensch., Berl., Bd. xvi (1878), S. 561.—Zur Semidecussation der Opticusfasern. Arch. f. Ophth., Berl., Bd. xxvii (1881), 1. Abth., S. 342-344.

^ Singer, J., u. E. Munzer. Denkschr. d. math. naturw. Kl. d. Wiener Akad., Bd. iv (1888).

◇ Burdach, F. Zur Faserkreuzung im Chiasma und in den Tractus nervorum opticorum. Arch. f. Ophth., Berl., Bd. xxix (1883), 3. Abth., S. 135-142.

↓ Marehand, F. Beitrag zur Kenntniss der homonymen bilateralen Hemianopsie und der Faserkreuzung im Chiasma optieum. Arch. f. Ophth., Berl., Bd. xxviii (1882), S. 63-96.

↑ Schmidt-Rimpler, H. Semidecussationsfrage der Sehnerven. Deutsche med. Wehnschr., Berl., Bd. xxii (1896), Vereinsbeilage, S. 158.

‡ Jacobsohn, L. Zur Frage der Sehnervenkreuzung. Neurol. Centralbl., Leipz., Bd. xv (1896), S. 838-840.

\*\* Cf. also Dreschfeld, J. Pathological Contributions on the Course of the Optic Nerve Fibres in Man. Brain, Lond., vol. iv (1881-'82), p. 543; vol. v (1882-'83), p. 118.



that even in this animal there is a small fasciculus non-cruciat. Von Gudden \* expressed the opinion that in all animals in which the visual fields fall together (binocular vision) there is semi-decussation in the chiasm, and that in all animals in which the visual fields of the two eyes are entirely separate the decussation is total. Thus, in fish, amphibia, and birds, the decussation is complete, while in mammals and man von Gudden agreed with the Hannover-Henle view that the decussation is partial.† The illustrations which accompany von Gudden's articles are very convincing. In Fig. 504 are shown (A) the base of the brain in a normal rabbit; (B)

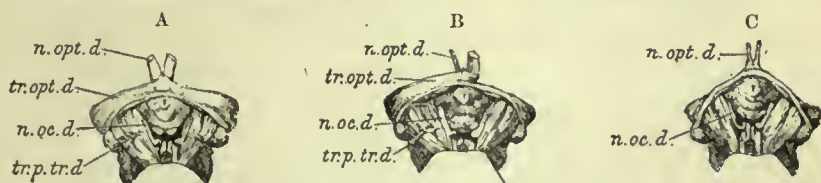

FIG. 504.—Brains illustrating atrophy following experimental removal of the eye in a newborn rabbit. (After B. von Gudden, *Gesammelte und Hinterlassene Abhandlungen*, Wiesb., 1889, Taf. xv, Figs. 1, 2, and 3.) A. Base of an adult rabbit's brain with normal optic nerves. B. Base of a rabbit's brain in which the right N. opticus is atrophied. C. Base of a rabbit's brain with bilateral atrophy of the Nn. optici. *n.opt.d.*, N. opticus dexter; *n.oc.d.*, N. oculo-motorius dexter; *tr.opt.d.*, tractus opticus dexter; *tr.p.tr.d.*, tractus peduncularis transversus dexter.

the base of the brain of a rabbit the right eye of which had been extirpated at birth; and (C) the base of the brain of a rabbit both eyes of which had been removed at birth. In A the Nn. optici, chiasma opticum, and Tr. optici are normal; in B the right N. opticus and the left tractus opticus are atrophic; in C both Nn. optici are atrophic, and the corresponding portions of the optic chiasm and optic tracts have degenerated; the portions of the optic chiasm and of the two tracts which persist correspond to the commissura inferior (Guddeni), which has no connection, it is believed, with either retina (*vide infra*). The fasciculus non-cruciat in the rabbit is illustrated in Fig.

\* von Gudden, B. Demonstration von Präparaten neber das sog. Ganglion opticum basale, Kreuzung der Sehnervfasern im Chiasma; vordere und hintere Commissur des Chiasma. *Allg. Ztschr. f. Psychiat.*, Berl., Bd. xxix and xxx (1873-'74).

† Johannes Muller believed that the identity of the retina in man and in animals is organically conditioned. Helmholtz, on the other hand, thought that it might be a matter of education (*anerzogene*).

505. The same bundle in man, much more voluminous, is well shown in the remarkable case studied by Ganser,\* in which this

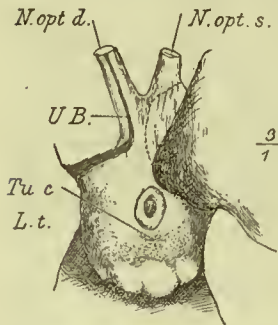


FIG. 505.—Removal of the left half of the chiasma opticum along with the commissura inferior Guddeni in the rabbit. (After R. von Gudden, *Gesammelte und Hinterlassene Abhandlungen*, Grashy, Wiesb., 1889, Taf. xvi, Fig. 3.) *N.opt.d.*, atrophic optic nerve on right side, the uncrossed bundle (*U.B.*) retained; *N.opt.s.*, N. opticus sinister, atrophic; *Tu.c.*, tuber cinereum; *L.t.*, lobus temporalis.

bundle ran as a separate tract, practically completely isolated, from the retina into the optic tract of the same side. The example is unique, and is of such importance that I have had Ganser's drawing reproduced in Fig. 506. Although Reich,† of St. Petersburg, confirmed the results of von Gudden, Mandelstamm‡ and Michel# have supported the view of von Biesiadecki,|| who, as early as 1861, asserted that even in man the decussation is total. Von Michel based his conclusions upon (1) serial sections of the whole normal chiasm stained by the method of Weigert; (2) sections of the optic nerves, optic chiasm, and optic tracts in cases of degeneration in both man and animals; and (3) certain physiological considerations.

\* Ganser, S. Ueber die periphere und centrale Anordnung der Sehnervenfaser und ueber das Corpus bigeminum anterius. *Arch. f. Psychiat. u. Nervenkr.* Berl., Bd. xiii (1882), S. 341-381.

† Reich, M. On the Complete and Incomplete Crossing of Nervous Filaments (in chiasma nerv. opticeorum). *Protok. zasaid. Obsh. russk. vrah. v. St. Petersburg*, vol. xli (1874), pp. 351-361. *Abstr. in Centralbl. f. d. med. Wissensch.*, Berl., Bd. xiii (1875), No. 29.

‡ Mandelstamm, E. Ueber Sehnervenkreuzung und Hemioptie. *Arch. f. Ophth.*, Berl., Bd. xix (1873), 2. Abth., S. 39-58.

# Michel, J. Ueber den Bau des Chiasma nervorum opticeorum. *Arch. f. Ophth.*, Berl., Bd. xix (1873), 2. Abth., S. 59; 3. Abth., S. 375.—Zur Frage der Sehnerv-Kreuzung im Chiasma. *Ibid.*, Bd. xxiii (1877), 2. Abth., S. 227-254.—Ueber Sehnerv-Degeneration und Sehnerv-Kreuzung, *Festschrift der med. Fak. d. Univ. Würzburg z. Feier des lxx Geburtstages d. Dr. A. v. Kölliker*, Wiesbaden (1887).—*Lehrbuch der Augenheilkunde*, 2. Aufl. (1890), S. 494.

|| von Biesiadecki, A. Ueber das Chiasma nervorum opticeorum des Menschen und der Thiere. *Sitzungsber. d. k. Akad. d. Wissensch., math.-naturwiss. Cl.*, Wien, Bd. xlii (1861), S. 86; und in *Untersuch. z. Natural. d. Mensch. u. d. Thiere*, Giessen, Bd. viii (1862), S. 156-173.

In serial sections of the normal chiasm he found that the fibres of one optic nerve meet those of the optic tract of the same side almost at a right angle, and he contended that the view that an uncrossed bundle passing from the optic nerve to the optic tract was due to the presence of looplike excursions of certain of the fibres of the nerve for some distance into the tract of the same side, before actually crossing through the chiasm into the tract of the opposite side. Von Michel can not confirm the investigations of others concerning degenerations either in man or in animals, and asserts that there is no evidence from this source in his specimens in favor of a fasciculus non-cruciatus. Finally, von Michel does not consider semi-decussation a necessary physiological postulate. He argues that if homonymous bilateral hemianopsia\* is to be explained

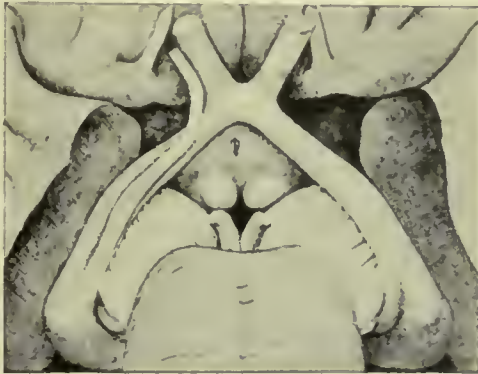


FIG. 506.—Region of the chiasma opticum and tractus opticus found in human brain at autopsy by S. Ganser. (*Arch. f. Psychiat., Berl.*, Bd. xiii, 1882, Taf. vi, Fig. 11.) The fasciculus non-cruciatus dexter is seen as an isolated bundle.

by the decussation in the optic chiasm the proportion of crossed to uncrossed fibres should be as 1:1, and contrasts with this the admission of even those who adhere to the doctrine of partial decussation, that the relation is as 3:1, or as 4:1, at most as 5:3. As further evidence against the generally accepted view he cites the well-known fact that in by far the majority of cases of hemianopsia central vision is sharp on both sides, and urges that, in spite of the hypotheses which

\* The condition in which there is loss of the lateral visual field on one side, and of the medial visual field on the other.

have been advanced to explain this, there are no anatomical grounds for the assumption that each macula lutea is doubly represented.

Von Gudden, up to the time when his brilliant career was so tragically cut short, combated vigorously the doctrine of complete decussation, backing up his views with a large number of elaborate and most ingenious experiments, which have been sufficient to convince at least the majority. In his articles from 1879 to 1885 he dealt with all the objections which had been raised, and in the minds of many definitely settled the question in favor of a partial decussation in man and the higher animals. He took carefully into account the commissura superior (Meynerti), the commissura inferior (Guddeni), and the hemispheric bundle which bears his name, and demonstrated methods by which each of these, as well as the fasciculus cruciatus and the fasciculus non-cruciatus, can be individually isolated. Von Gudden cited the experiments of Nicati,\* who, through the mouths of cats, cut the optic chiasm in the middle line. The cats could still see, which would be difficult to explain were the decussation total. Even had they been totally blind after the operation, the decussation need not be total, for, as Gruetzner points out, we do not know how near the uncrossed fibres go to the median line before passing into the optic tract of the same side. At von Gudden's instigation, Bumm examined the retina in cases of degeneration as to the origin there of the uncrossed and crossed fasciculi. Bumm came to the conclusion that the uncrossed bundle is related to the lateral part of the retina, the crossed bundle mainly to the medial part of the retina.

In von Gudden's time the embryological studies which had been made threw but little, if any, light upon the topic under discussion. Whereas von Mihalkovics and von Kölliker had assumed total decussation from the mode of development, von Baer, on the contrary, thought that the mode of origin of the

---

\* Nicati, W. De la distribution des fibres nerveuses dans le chiasma des nerfs optiques. *Arch. de physiol. norm. et path.*, Par., 2. s., t. v (1878), pp. 658-678.—Preuve expérimentale du eroisement incomplet des fibres nerveuses dans le chiasma des nerfs optiques; section longitudinale et médiane du chiasma non suivie de éécité. *Compt. rend. Acad. d. Sc.*, Par., t. lxxxvi (1878), pp. 1472-1474; also, *Centralbl. f. d. med. Wissenseh.*, Berl., Bd. xvi (1878), S. 449.



chiasm was consonant with semi-decussation. I have recently (1898), through the courtesy of Prof. Mall, examined the optic paths of several human embryos cut in various planes (sagittal, coronal, horizontal), but have found the relations so complex, even in faultless serial sections, that I can not decide from the appearances, at least in these carmine preparations, whether or not the decussation is partial or total. A lateral bundle can be seen passing from the optic nerve through the chiasm well toward the tractus opticus of the same side, but one is not justified in asserting from these sections that it actually enters it to be distributed to the optic centres on the same side. What strikes one most in the study of embryonic tissues is the intimate relation of the optic chiasm and of the optic tracts to the basal plate of the diencephalon. I should not be surprised if it should turn out that a considerable number of fibres, possibly of no mean significance, run into the base of the brain from the chiasm and optic tracts, to end there without passing through the whole length of the latter to the regions usually designated as the optic centres (lateral geniculate body, pulvinar, superior colliculus of corpora quadrigemina). Thus far, studies with Golgi's method have not succeeded in demonstrating the partial decussation, though much is to be hoped from its application to the study of embryonic tissues, especially if Born's method of reconstruction be used in connection with it.

Since the death of von Gudden, von Michel has reiterated his former statements, and has received substantial support from the Nestor of German histologists, von Kölliker, of Würzburg.

At the meeting of the Anatomical Congress in Berlin in 1896 von Kölliker, on the ground of his own studies and of a careful control of von Michel's preparations, stated that he had come to the conclusion that the optic nerves undergo complete decussation in the chiasm in man and in the dog, cat, fox, and rabbit. Curiously enough, this statement met with scarcely a dissenting voice. Von Kölliker, later, in his text-book described fully his findings, and reviewed at considerable length the bibliography of the subject.\* On the whole, he confirms the statements of von Michel and urges the necessity of ana-

---

\* von Kölliker, A. Handbuch der Gewebelehre, Bd. ii, Hälfte ii, S. 560 ff.

tomical demonstration of the uncrossed bundle. He denies the alleged results of the study of secondary degenerations, and emphasizes that decussation is not a necessary postulate for the explanation of physiological findings, and that even were it apparently impossible to explain all known physiological facts without the assumption of a partial decussation anatomists would not be justified in admitting decussation in the chiasm until it had been actually demonstrated by anatomical methods.

Gruetzner,\* in the summer semester of 1896, undertook to restudy the whole subject by the methods of the investigators who had preceded him and by special methods devised by himself. From his own work and from a consideration of that of others he concludes that only a part of the fibres of the optic nerves cross. He made models of the chiasm in which he made half the fibres cross, while the other half passed through uncrossed into the optic tract of the same side. He then dehydrated these models and imbedded them in paraffin and cut them into horizontal sections. In the sections he could make out only fibres which crossed, although he knew perfectly well that only half of the fibres actually crossed. He concludes, therefore, that the microscopical study of horizontal sections is absolutely of no value for the decision of the question whether or not all of the fibres actually cross in the chiasm.

In the human case studied by Siemerling,† in which one optic tract was completely destroyed, there was diminished sharpness of vision in the opposite eye, but the patient could still see with the temporal side of his retina. This could not have been possible had there been complete decussation of his optic nerves. Nor are the experiments of Munk‡ or the clinical pathological observations of Baumgarten, Marchand, and others (*vide supra*) compatible with the assumption of total decussation.

---

\* Gruetzner, P. Kritische Bemerkungen ueber die Anatomie des Chiasma opticum. Deutsche med. Wehnsehr., Berl., Bd. xxiii (1897), S. 2.

† Siemerling, E. Ein Fall gummoëser Erkrankung der Hirnbasis mit Betheiligung des Chiasma nervorum opticorum. Ein Beitrag zur Lehre vom Faserverlauf im optischen Leitungsapparat. Arch. f. Psychiat. und Nervenkr., Berl., Bd. xix (1888), S. 401-437.

‡ Munk, H. Zur Physiologie der Grosshirnrinde. Arch. f. Anat. u. Physiol. Physiol. Abth., Leipz. (1878), S. 162-178.

The ingenious experiments of Pick,\* so far as they go, tend to confirm the results of von K  lliker. This investigator, working with the rabbit, destroyed circumscribed areas of the retina by means of a galvano-caustic needle, and subsequently studied the optic nerve, the optic chiasm, and the optic tract with the aim of establishing the topographical relations which exist between the retina and the optic nerve on the one hand and the chiasm and the optic tract on the other. His results led him to conclude that the relations are very simple, the relative position of the fibres in the cross section of one optic nerve corresponding *in toto* to that of the transverse section of the optic tract of the opposite side. The dorsal and ventral fibres of the optic nerve are the dorsal and ventral fibres of the opposite tract, and in the same way the lateral and medial fibres of the nerve occupy the same relative positions in the optic tract of the opposite side. His studies were carried out by the method of Marchi. It is highly desirable that his results be controlled, and that studies by the same method be carried out on animals higher than the rabbit in which there is evidence of a larger fasciculus non-crossed. In the rabbit the uncrossed bundle, if it exists, is very small, and von Gudden missed it in his earlier studies. The monkey would be a particularly suitable animal for the prosecution of such a research.

Most interesting in this connection are the painstaking and extensive studies of the Swedish investigator Henschen.† He has been able to accumulate a large amount of human material, which he has studied clinically and worked up pathologically with care. On analyzing his results he has compared his findings thoroughly with the cases recorded in the bibliography, and comes to important conclusions regarding the localization of the bundles in the optic nerve, in the chiasm, and in the tract, and the relations of these to the higher centres. His publications

---

\* Pick, A. Untersuchungen ueber die topographischen Beziehungen zwischen Retina, Opticus und gekreuzten Tractus Opticus beim Kaninehen. Nova acta der Kaiserl. Leop-Carol., Deutschen Academie der Naturforscher, Bd. lxvi. Abstract in Neurologisches Centralbl., Bd. xx (1896), S. 691. Cf. also Pick u. Herrenheiser. Untersuchungen ueber die topographischen Beziehungen zwischen Retina, opticus und gekreuzten Tractus opticus beim Kaninehen. Halle, 1895.

† Henschen, S. E. Klinische und anatomische Beitr  ge zur Pathologie des Gehirns. Zweiter Theil, Upsala (1892), S. 217 ff.

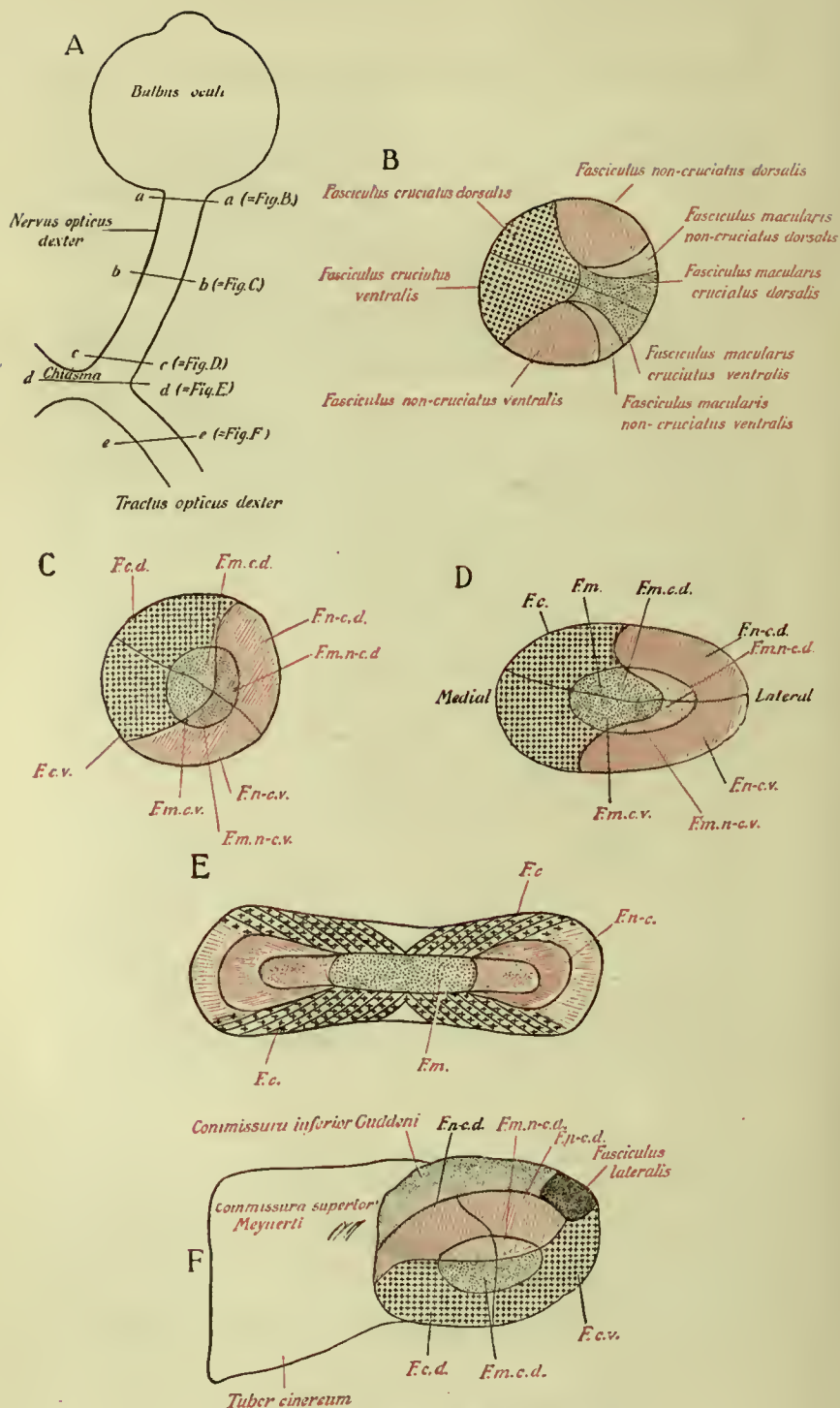


FIG. 507.—Localization of optic fibres (Henschen).



represent a mine of rich material, and must be consulted by every student who wishes to go beneath the surface in this field. In Fig. 507 is reproduced the plate in which his conclusions regarding localization are epitomized. The fasciculus non-cruciatus of the optic nerve (see accompanying figures) arises in the main from the temporal side of the retina. It follows a tolerably isolated course as far as the chiasm, occupying the latero-ventral portion of the transverse section of the optic nerve. The fasciculus cruciatus, on the other hand, is situated more medially and dorsally. The bundle from the macula lutea (fasciculus macularis) on each side runs in the central part of the optic nerve, and maintains its central position in the optic chiasm and in the optic tract. The relations of the crossed and uncrossed bundles to the inferior and superior commissure in the optic tract will be sufficiently clear from the diagrams if the legends be consulted.

The researches by Marchi's method, carried out by Singer and Münzer\* and Ramón y Cajal,† support the doctrine of partial decussation. Even in the rat and mouse, in which it has been generally supposed that decussation in the optic chiasm is total, Ramón y Cajal finds an uncrossed bundle, and states that it goes only to the lateral geniculate body of one side, while the crossed bundle goes to the lateral geniculate body and also to the superior colliculus and the thalamus.

We must conclude, therefore, from the evidence before us, that as a rule the decussation in the optic chiasm in man and of higher animals is partial, not total. That in individual cases there may be considerable variation seems certain. Even in the anatomy of Vesalius we find a human case reported in which the optic chiasm was entirely absent (Fig. 508), the right optic nerve going bodily over into the right optic tract, and



FIG. 508.—Absence of optic chiasm. (After Andreas Vesalius; taken from A. Ranber's text-book.) *Præsentî figura nervorum quos hic describimus ductus exprimitur. ac, cerebri portuunculam indicat.*

\* Singer and Münzer. *Beiträge zur Kenntniss der Sehnervenkreuzung.* Wien, 1888.

† Ramón y Cajal, S. *Ann. de la Socied. Espanola di hist., nat., 2. Ser., t. iii (1894), p. 236.*

Henle \* has collected a number of such cases from the bibliography. It is not impossible that occasionally there is actually complete decussation in the chiasm, in which event we should expect total amblyopia in the opposite eye (instead of hemianopsia involving the two eyes) to follow upon lesion of one optic tract. The rarity of such observations is, however, very striking, especially since the exact studies concerning hemianopsia have been inaugurated. Between these two possible extremes of no decussation and total decussation there may be all sorts of degrees of decussation, the most frequent proportion of uncrossed to crossed fibres in man probably being about as 1 : 2 or as 3 : 5.

The optic tract on each side behind the chiasm runs around the cerebral peduncle of the same side and arrives at the junction of the mesencephalon with the diencephalon, where it divides into two distinct roots, (1) a lateral root and (2) a medial root (Fig. 509).

The optic tract on the right side, for example, includes the fasciculus cruciatus from the left optic nerve, the fasciculus non-cruciatus from the right optic nerve, fibres of the commissura superior Meynerti, fibres of the commissura inferior Guddeni, fibres of the direct hemispheric bundle of von Gudden, a certain number of centrifugal fibres running from the higher centres of the retina, and possibly fibres of still other categories.

The fibres of the lateral root of the optic tract include the centripetal and centrifugal fibres connected with the retina, and terminate (or in case of the centrifugal fibres have their origin) in the lateral geniculate body, in the pulvinar of the thalamus, and in the superior colliculus of the corpora quadrigemina. In these centres the terminals of the optic neurones of the second order come into conduction relation with the cell bodies and dendrites of the optic neurones of the third order. Of the optic neurones of the third order, those in the lateral geniculate body and the pulvinar send their axones, in large part at least, to the visual area in the occipital cortex, while those in the superior colliculus of the corpora quadrigemina send their axones in large part to enter into conduction relation with neu-

---

\* Henle, J. Handbuch der systematischen Anatomie des Menschen. Nervenlehre (1879), S. 393.

rones which throw the eye-muscle nuclei under their influence (*vide infra*).

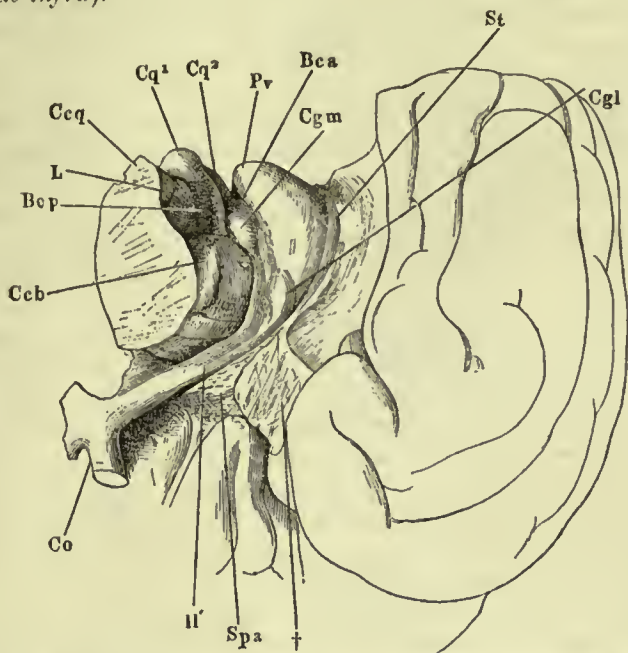


FIG. 509.—A portion of the right cerebral hemisphere resting on the *polus frontalis*, to illustrate the *basis cerebri*. (After J. Heule, *Handbuch der Nervenlehre des Menschen*, 11. Aufl., Braunsch., 1879, S. 155, Fig. 80.) *Bca*, brachium quadrigeminum superius; *Bcp*, brachium quadrigeminum inferius; *Ccb*, pedunculus cerebri; *Cgl*, corpus geniculatum laterale; *Cgm*, corpus geniculatum mediale; *Ccq*, brachium conjunctivum; *Co*, chiasma opticum; *Cq¹*, colliculus inferior; *Cq²*, colliculus superior; *L*, lemniscus; *Pv*, pulvinar of thalamus; *Spa*, substantia perforata anterior; *St*, stria terminalis; *II'*, tractus opticus. The radix medialis and the radix lateralis are well illustrated; †, cut surface of tip of temporal lobe which has been removed.

The lateral geniculate body and the superior colliculus of the corpora quadrigemina have accordingly been designated, especially by the German writers, as "primary optic centres" in the brain. This designation is, however, not wholly suitable, for we have seen that the peripheral optic neurones correspond to the bipolar cells of the retina, and the ganglion cells of the retina really represent a part of the brain. It would be much more logical, therefore, to designate the ganglion cell layer of the retina as the primary optic centres of the brain, and to name the lateral geniculate body, the pulvinar, and the superior colliculus of the corpora quadrigemina the "secondary optic

centres" of the brain; for it is obvious that the ganglion cell layer of the retina corresponds to the nucleus funiculi gracilis, and the nucleus funiculi cuneati of the general sensory path and the termination of the optic tract in the superior colliculus and the lateral geniculate body corresponds to the terminations of the medial lemniscus in the mesencephalon and in the diencephalon respectively. The neurones extending between the lateral geniculate body and the cortex would, for the visual path, therefore, be the analogues of the sensory neurones of the third order of the general sensory path extending between the ventro-lateral group of nuclei of the thalamus and the cerebral cortex.

The exact areas occupied in the optic centres of the mesencephalon and diencephalon by the terminals of the fibres of the lateral root of the optic tract have been demonstrated by the degeneration experiments of von Monakow. After enucleation of both eyes in the new-born puppy, this observer found, on killing the animal at the end of six months, that the gelatinous substance of a large part of the lateral geniculate body—that portion of it which he designates *a*—undergoes degeneration. This substantia gelatinosa consists, in the main, of the terminal branches of the fibres of the optic tract.

In the dog von Monakow divides the lateral geniculate body into several nuclei—*a*, *a*<sub>1</sub>, *b*, *b*<sub>1</sub>, and *v*, the ventral nucleus.\* While a few of the optic fibres apparently terminate in *a*, *b*, *b*<sub>1</sub>, and in the ventral nucleus, by far the majority of them end in *a*<sub>1</sub>, the dorso-caudal part of the lateral geniculate body (Fig. 510).

The fibres going to the pulvinar from the lateral root of the optic tract in the dog are distributed to the superficial part of the dorsal zone.

The fibres of the lateral root of the optic tract which go to the superior colliculus correspond, so many have thought, to the superficial white matter of that body (von Gudden, Forel, Ganzer,†

\* Monakow divides the corpus geniculatum laterale in the dog into two main parts—(1) *den Sehsphärenantheil* (*a*, *b*, *b*<sub>1</sub>, and *v*), and (2) *den Retinantheil* (*a*<sub>1</sub>).

† Ganzer, S. Ueber die Anatomie des vorderen Hügels vom Corpus quadrigeminum. Arch. f. Psychiat. und Nervenkr., Berl., Bd. xi (1880), S. 278–281. —Ueber die periphere und centrale Anordnung der Sehnervenfasern und ueber das Corpus bigeminum anterius. Arch. f. Psychiat. und Nervenkr., Berl., Bd. xiii (1882), S. 341–381.



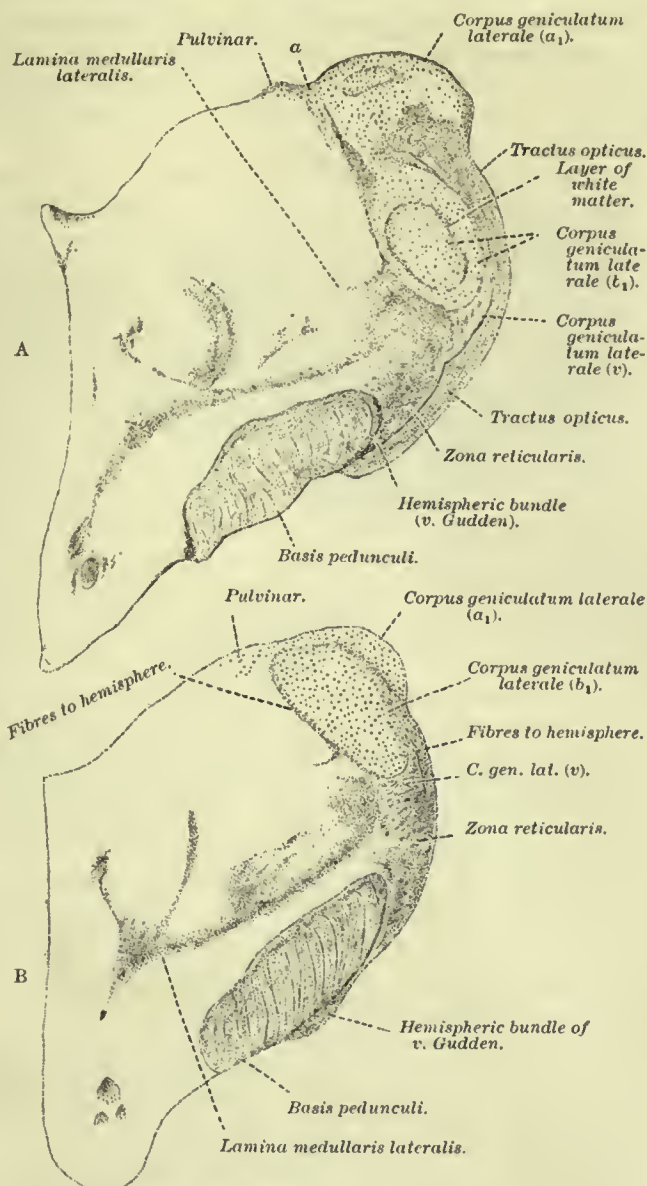


FIG. 510.—Frontal sections through the corpus geniculatum laterale of a dog. A. Section through caudal plane of a healthy dog;  $a$ , nucleus frontalis dorsalis of the corpus geniculatum laterale;  $a_1$ , nucleus caudalis dorsalis;  $b_1$ , caudal ventral nucleus of the corpus geniculatum laterale;  $v$ , most ventral nucleus of corpus geniculatum laterale. B. Frontal section through the corpus geniculatum laterale of a dog from which both eyes had been enucleated. (After C. von Monakow, Arch. f. Psychiat., Bd. xx, 1889, Taf. xiii, Figs. 22 and 23.)

von Monakow,\*) although, as Tartuferi has pointed out, the most medial part of the superficial white matter belongs to another system of fibres, and recently it has seemed more likely that the optic fibres are those which assume an antero-posterior direction, just beneath the *cappe cinérée*.

The *lateral geniculate body* in man, especially in horizontal sections, is heart-shaped, the apex being directed forward. The appearance is very characteristic. The mass consists of alternating, somewhat irregular layers of gray and white substance, (Fig. 511) the white matter consisting of optic tract fibres in the main and partly of the medullated axones which pass from the lateral geniculate body into the optic radiations to pass to the cerebral cortex. The gray matter of the nucleus contains cell bodies and dendrites of the optic neurones of the third order. In man, probably 80 per cent. of the fibres of the optic tract end in the lateral geniculate body (von Monakow). The endings of the fibres of the optic tract in the lateral geniculate body have been studied by Golgi's method, by P. Ramón,† von Kölliker,‡ and Ramón y Cajal.\* The terminations of the optic fibres in the lateral geniculate body of the newborn cat are well shown in the accompanying figure taken from Ramón y Cajal's article

---

\* The principal contributions of von Monakow as regards the optic nerve and optic centres are the following: Experimentelle und pathologisch-anatomische Untersuchungen ueber die Beziehungen der sogenannten Sehsphäre zu den infracorticalen Opticuseentren und zum N. opticus. Arch. f. Psychiat. u. Nervenkr., Berl., Bd. xiv, S. 699, and Bd. xvi, S. 151, 317.—Einiges ueber die Ursprungseentren des N. opticus und ueber die Verbindungen derselben mit der Sehsphäre. Arch. f. Anat. u. Physiol., Physiol. Abth., Leipz. (1885), S. 329.—Experimentelle und path.-anatomische Untersuchungen ueber die optischen Centren und Bahnen (Neue Folge). Arch. f. Psychiat. u. Nervenkr., Berl., Bd. xx, S. 714.—Experimentelle und path.-anatomische Untersuchungen ueber die optischen Centren und Bahnen nebst klinischen Beiträgen zur corticalen Hemianopsie und Alexie (Neue Folge). Arch. f. Psychiat. u. Nervenkr., Berl., Bd. xxiii, S. 609; Bd. xxiv, S. 229.

† Ramón, P. (1) Gaeeta sanitaria de Barcelona, iii (1890), No. 1, p. 10; (2) Invest. sobre los centros opticos de los vertebrados, Tesis del doctorado (1890); (3) El encefalo de los reptiles, Barcelona (1891), pp. 11–22; (4) Invest. en el encefalo de los batracios y reptiles, cuerpos geniculados y tuberculos cuadrigeminos de los maniferos. Zaragoza (1894).

‡ von Kölliker, A. Verhandl. d. anat. Gesellsch., Jena (1895), S. 16; also Handbuch der Gewebelehre des Menschen. Leipz. (1896), Bd. ii, S. 585 ff.

\* Ramón y Cajal, S. Beitrag zum Studium der Medulla Oblongata, des Kleinhirns und des Ursprungs der Gehirnnerven. Deutsch von Bresler. Leipz. (1896), S. 101 ff.

(Fig. 512). The terminations of the optic fibres in the pulvinar of the thalamus are well illustrated in von Kölliker's cut (Fig. 513). From the manifold divisions of the terminals of

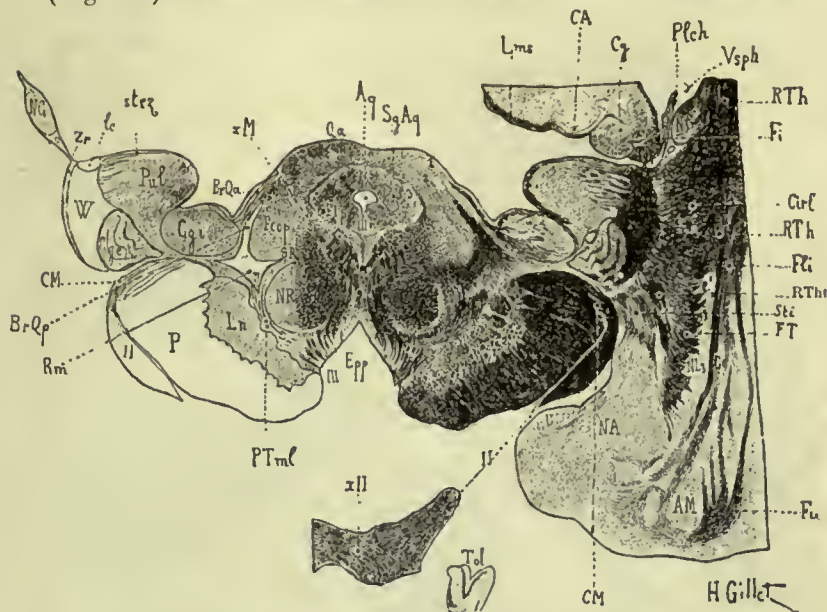


FIG. 511.—Horizontal oblique section through the cerebral peduncle and hypothalamus; Pal staining. (After J. Dejerine, *Anatomie des centres nerveux*, Paris, 1895, p. 654, fig. 325.) *AM*, claustrum; *Aq*, aqueductus cerebri; *BrQa*, brachium quadrigeminum superius; *BrQp*, brachium quadrigeminum inferius; *CA*, hippocampus; *Ce*, capsula externa; *Cg*, fascia dentata hippocampi; *Cge*, corpus geniculatum laterale; *Cgi*, corpus geniculatum mediale; *Cip*, capsula interna pars occipitalis; *Cirl*, retrolentiform portion of pars occipitalis capsule interna; *CM*, commissura superior Meynerti; *Epp*, substantia perforata posterior; *Ecp*, fasciculus of the commissura posterior cerebri; *Fi*, fimbria hippocampi; *Fli*, fasciculus longitudinalis inferior; *Flp*, fasciculus longitudinalis medialis; *Fl*, bundle of Türek; *Fu*, fasciculus uncinatus; *lc*, lamina cornea; *Lms*, lamina medullaris superficialis; *Ln*, substantia nigra; *NA*, nucleus amygdalæ; *NC'*, cauda nuclei caudati; *NL*, putamen; *NR*, nucleus ruber; *P*, basis pedunculi; *Plch*, plexus chorioideus; *PTml*, fasciculus pedunculo-mammillaris, pars basilaris, or peduncle of the mammillary body; *Pul*, pulvinar; *Qa*, colliculus superior; *1*, superficial layer; *2*, middle layer; *3*, deep layer; *Rm*, lemniscus medialis; *RTh*, radiatio occipitohthalmica Gratioleti; *RTh*<sup>1</sup>, cortical projection fibres from the globus pallidus; *RTh*<sup>2</sup>, projection fibres from the anterior part of the temporal lobe going to the pulvinar (?); *SgAq*, stratum griseum centrale; *SR*, formatio reticularis; *Sti*, substantia innominata of Reichert; *U*, uncus; *Vsph*, cornu inferius of ventriculus lateralis; *W*, field of Wernicke; *XM*, fontaineartige Haubenkrenzung of Meynert; *Zr*, zona reticularis; *II*, tractus opticus; *IIIu*, nucleus N. oculo-motorii; *III*, fila radicularia N. oculo-motorii; *XII*, chiasma opticum.

the optic fibres it is obvious that a single fibre must come into contact relation with the cell bodies and dendrites of many



neurones of a higher order. For a minute description of the terminals of these fibres the original articles of these investigators must be consulted.

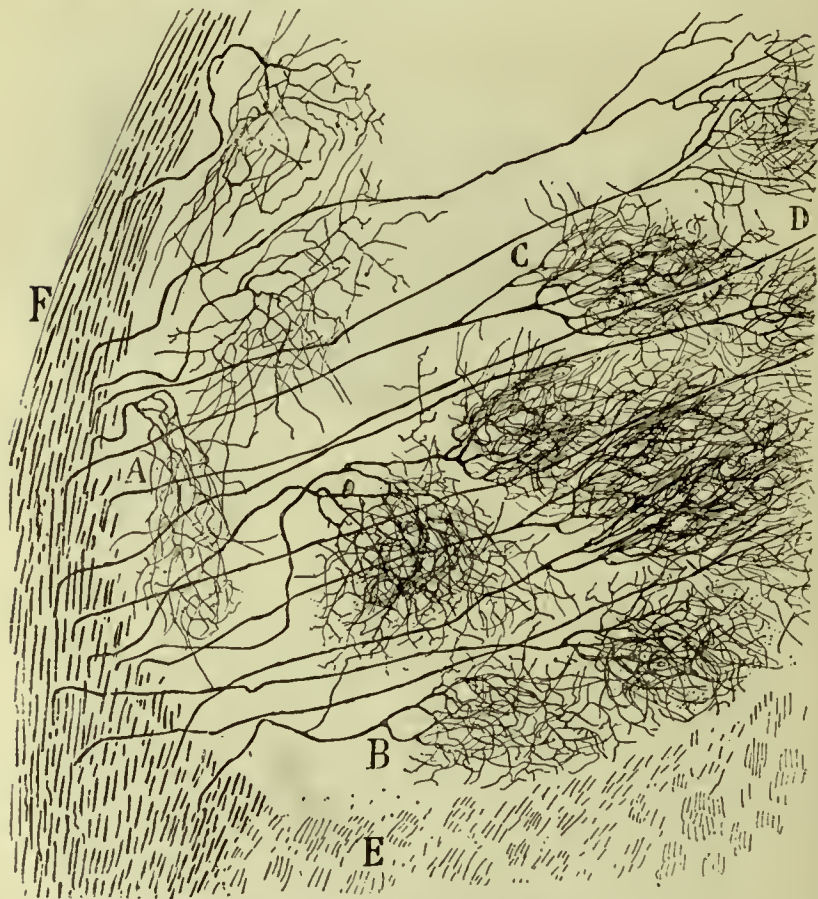


FIG. 512.—Lower portion of corpus geniculatum laterale of a newborn cat. (After S. Ramón y Cajal, *Beitrag zum Studium der Medulla Oblongata*, etc., Bresler, Leipz., 1896, S. 104, Fig. 24*b*.) *A*, optic fibres forming somewhat flattened end arborizations; *B*, optic fibres terminating in middle level; *C* and *D*, optic fibres with very closely interwoven end arborizations situated in the depth; *E*, bundle of central optic path; *F*, fibres continuous with the tractus opticus; the letter *E* corresponds to the lower portion of the corpus geniculatum laterale.

Von Monakow believes that between the terminals of the fibres of the optic tract in the lateral geniculate body and the cell bodies and dendrites of the neurones, the axones of which go



into the optic radiations, Golgi cells of Type II are intercalated. He thinks that otherwise it is difficult to explain the findings in cases of hemianopsia.

A certain number of optic fibres have long been known to stand in intimate relation to the white matter of the colliculus superior of the corpora quadrigemina. Thanks to the researches of Ramón y Cajal\* and van Gehuchten,† the proof was brought

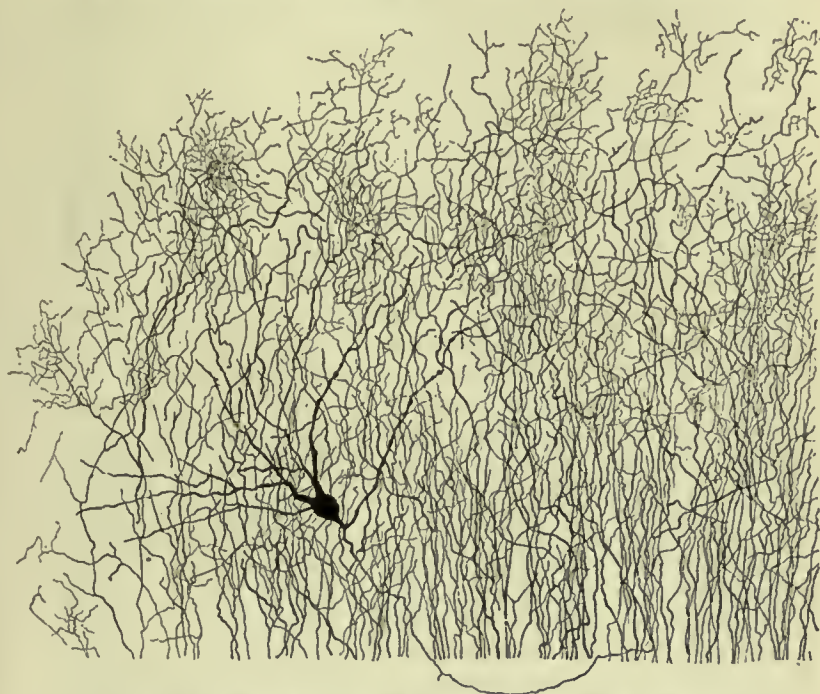

FIG. 513.—Golgi preparation from the pulvinar of a mouse five days old. One large multipolar cell, with its axone, is visible. (After A. von Kölliker, *Handbuch der Gewebelehre*, Bd. ii, Leipz., 1896, S. 585, Fig. 696.) The terminals of the tractus opticus are visible.

that the axones which terminate here in the superficial gray layers are those of optic fibres which have their origin in the

\* Ramón y Cajal, S. Sur la fine structure du lobe optique des oiseaux et sur l'origine réelle des nerfs optiques. [Transl. from *Rev. trim. de histol.*, 1889.] *Internat. Monatehr. f. Anat. u. Physiol.*, Leipz., Bd. viii (1891), S. 337-376.

† van Gehuchten, A. La structure des lobes optiques chez l'embryon de poulet. *Cellule, Lierre and Louvain*, t. viii (1892), pp. 1-43.

ganglion cell layer of the retina. Since their studies our knowledge of this region has been extended by the researches of Tartuferi and Held. The endings of the optic fibres surround ganglion cells whose axones partly shorter break up in the superficial gray matter immediately on entrance, partly longer run radially into the deeper layers of the superior colliculus so as to reach the same regions of the superior colliculus in which terminate many of the fibres of the lateral lemniscus.

The difference in significance of the superior colliculus for the optic paths in different animals has been emphasized especially by von Gudden \* and Edinger.† In lower forms the optic lobes—that is, the region of the corpora quadrigemina—are the main visual organs. In higher forms the corpora quadrigemina appear to be active mainly in reflex functions, while the lateral geniculate body represents the way station in the visual path to the occipital cortex. In higher mammals it seems probable that the occipital cortex alone takes part in visual perception, for the superior colliculus can be destroyed without any disturbance of light or color vision. Phylogenetically the superior colliculus is older than the lateral geniculate body, and the latter in turn than the occipital cortex. In the fish, practically the whole of the optic nerve ends in the roof of the midbrain; in birds, according to Edinger, one gets a differentiation of a mesencephalic nucleus (superior colliculus) from a diencephalic nucleus (lateral geniculate body), and in them for the first time one meets with a genuine occipital cortex.

The medial root of the optic tract runs into the medial geniculate body where most of its fibres appear to terminate, although some, according to Obersteiner, may pass through the brachium quadrigeminum inferius into the colliculus inferior. This medial root of the optic tract has no connection, as von Gudden proved, with either retina, nor with the optic centres of the mesencephalon and diencephalon. It consists in the main of the commissura inferior (Guddeni), which extends between the two medial geniculate bodies. It therefore probably represents a commissure in connection with the auditory system, for, as will be seen later, the medial geniculate body

---

\* *Op. cit.*

† Edinger, L. Vorlesungen ueber den Bau der nervösen Centralorgane. V. Auflage, Leipz. (1895), S. 268 ff.

and the inferior colliculus of the corpora quadrigemina are important way stations in the auditory conduction path.

This medial root of the optic tract, and the inferior commissure of von Gudden, are well isolated by extirpation in the new-born of both eyes, as has been seen above (Fig. 510).

The view of Darkschewitsch and Pribytkow,\* that von Gudden's commissure represents a crossed connection of the medial geniculate body with the nucleus lentiformis, is supported by von Bechterew,† but is opposed by other investigators.

In addition to the commissura inferior Guddeni, certain other bundles of fibres, some of which may be connected with the optic tract, others not, have to be considered before we leave this portion of the optic conduction path. These are the commissura superior Meynerti, the hemispheric bundle of von Gudden, the commissura ansata of Hannover, the commissura hypothalamica anterior, and the tractus peduncularis transversus.

The *commissura superior Meynerti* has been described by Meynert,‡ Forel,\* and von Gudden. ¶ In the middle line in the rabbit it lies almost dorsal from the optic chiasm. It then descends ventrally and becomes visible lateral from the optic tract, first looking narrow, and then becoming broader. It can be followed lateralward as far as the junction of the medial and lateral part of the base of the cerebral peduncle, where it vanishes from view (von Gudden). In human beings it is never visible except in sections, but in general the relations are the same (Figs. 514 and 515). Schnopfhagen helped to confuse investigators in that he designated Meynert's commissure as the inferior commissure. The term commissura superior should be applied to Meynert's commissure, and the term commissura inferior should be reserved for the commissure of von Gudden. The ultimate termination of the fibres of Meynert's commissure is as yet not known. According to Darkschewitsch and Pribytkow the commissura superior Meynerti represents a tract connecting the nucleus lentiformis of one side with the nucleus

---

\* Darkschewitsch, L., und G. Pribytkow. Ueber die Fasersysteme am Boden des dritten Hirnventrikels. *Neurol. Centralbl.*, Leipz., Bd. x (1891), S. 417-429.

† von Bechterew, W. Die Leitungsbahnen im Gehirn und Rückenmark. Leipz. (1894), S. 103.

‡ Meynert, T. Stricker's Handbuch, iv Lief., S. 732.

\* Forel, A. Untersuchungen über die Haubenregion und ihre oberen Verknüpfungen im Gehirn des Menschen und einiger Säugethiere, mit Beiträgen zu den Methoden der Gehirnuntersuchung. *Arch. f. Psychiat. und Nervenkr.*, Berl., Bd. vii (1877), S. 481.

¶ *Op. cit.*

hypothalamicus (corpus Luysi) of the opposite side, while Flechsig assumes that it represents a decussation between the medial lemniscus of the two sides. These theories of its nature are contradicted by the results of Mahaim's investigations of secondary degenerations in human beings.\*

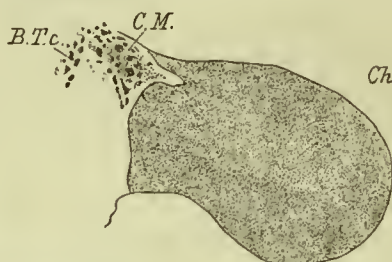


FIG. 514.—Transverse section of a normal human optic chiasm about the middle. (After B. von Gudden, *Gesammelte und Hinterlassene Abhandlung*, Grashey, Wiesb., 1889, Taf. xix, Fig. 20.) *B.T.c.*, bundle to the tuber cinereum; *Ch*, chiasma opticum; *C.M.*, commissura superior Meynerti.

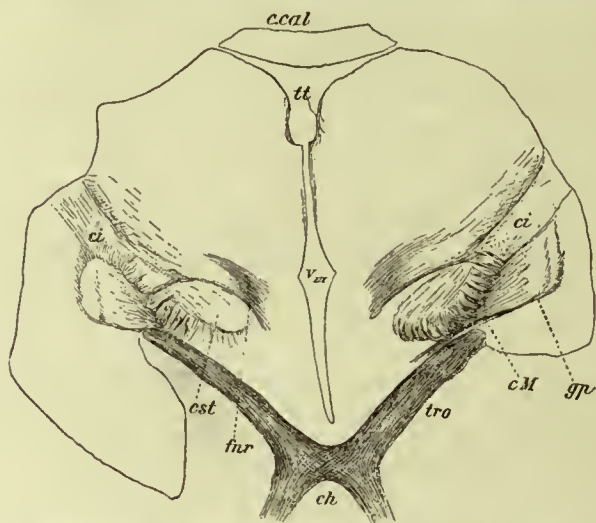


FIG. 515.—Section from the brain of a child three months old. Weigert-Pal preparation. (After W. von Bechterew, *Die Leitungsbahnen im Gehirn und Rückenmark*. Deutsch von R. Weinberg, II. Aufl., Leipz., 1899, S. 203, Fig. 174.) *c.cal*, corpus callosum; *ch*, chiasma opticum; *ci*, capsula interna; *cM*, commissura superior Meynerti; *cst*, nucleus hypothalamicus (corpus Luysi); *gp*, globus pallidus; *fur*, fibres from the nucleus ruber and the continuation of the brachium conjunctivum to the globus pallidus and to the thalamus; *tt*, tænia thalami; *tro*, tractus opticus; *v. 3r*, ventriculus tertius.

\* Mahaim, Albert. Ein Fall von secundären Erkrankung des Thalamus opticus und der Regio subthalamica. *Arch. f. Psychiat. und Nervenkr.* Bd. xxv (1893), S. 343-382.



The *hemispheric bundle of von Gudden*\* he describes as a bundle of fibres in the optic tract which goes over to the most lateral part of the base of the peduncle, that portion of the pes which lies nearest to the tractus opticus, and thence enters the cerebral hemisphere. This bundle, von Gudden stated, does not atrophy on extirpation of the eyes, but disappears after extirpation of the cerebral hemisphere. He cites especially the experiment of Ganser, who in the new-born rabbit destroyed the chiasm and the commissura inferior Guddeni, thus leading to complete atrophy of the corresponding parts of the optic tract and leaving the hemispheric bundle uninjured and completely isolated (Fig. 516). Since these studies of von Gudden and Ganser, however, but little has been added to our knowledge of this bundle.

Under the name of the *commissura ansata* of Hannover von Kölliker describes those fine fibres seen in horizontal sections through the chiasm cut transversely and obliquely on its anterior border. In sagittal sections one can make out that these fibres descend from the lamina cinerea terminalis and from the gyrus subcallosus. Some authors have thought that they are continued into the optic nerve.

The *commissura hypothalamica anterior* (the bundle designated by von Gudden as B. T. c.) was first named by Ganser the *decussatio subthalamica anterior*. According to von Kölliker it runs dorsalward lateral from the columns of the fornix and then becomes lost in the other fibre bundles running in the same direction (*ansa lenticularis*, inferior peduncle of the thalamus and portions of the stria medullaris) (Fig. 517).

The *tractus peduncularis transversus*, according to von Gudden, is a bundle beginning in front of the superior colliculus and running obliquely over the base of the cerebral peduncle, turning around its medial border to sink into the base of the brain in front of the region of exit of the nervus oculo-motorius. Von Gudden stated that it atrophied entirely in the rabbit after removal of

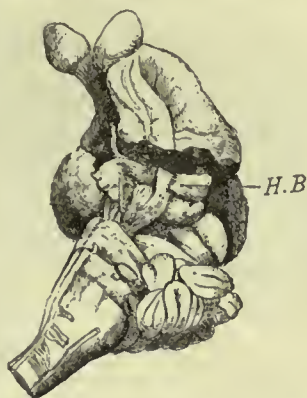

FIG. 516.—Brain of rabbit operated upon by Ganser. One eye was removed and the tractus opticus near the middle line torn across. In this way von Gudden's hemispheric bundle of the optic tract was isolated as a band of white matter which passes from the surface of the corpus geniculatum laterale into the basis pedunculi. (After B. von Gudden, *Gesammelte und Hinterlassene Abhandlungen*, Grashy, Wiesb., 1889, Taf. xxix, Fig. 2.) H. B., hemispheric bundle of the tractus opticus.

\* von Gudden, B. *Op. cit.*

both eyes. Its significance is, however, as yet but imperfectly understood. The best recent description is that of von Kölliker,\* who finds three tractus pedunculares transversi on each side in the rabbit—a main bundle and two accessory bundles. This author states that the main bundle arises from a small round

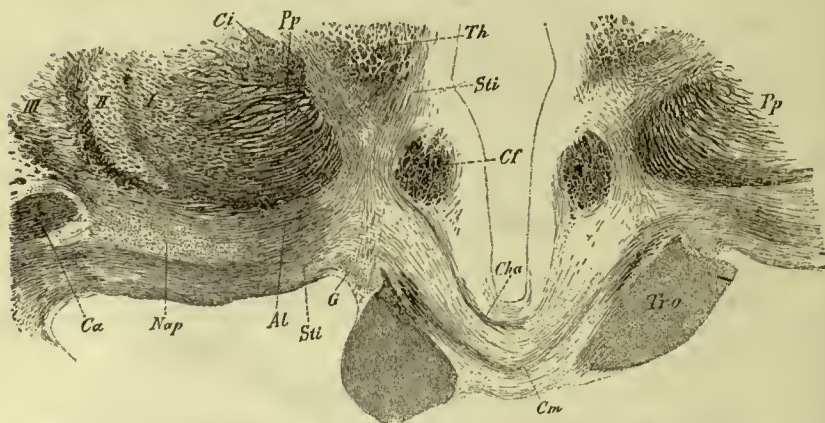


FIG. 517.—Frontal section through the human hypothalamus. Weigert staining. (After A. von Kölliker, *Handbuch der Gewebelehre*, Bd. ii, Leipz., 1896, S. 576, Fig. 686.) *Al*, ansa lenticularis; *Ca*, commissura anterior cerebri; *Cf*, columna fornicis; *Cha*, commissura hypothalamica anterior; *Ci*, capsula interna; *Cm*, commissura superior Meynerti; *G*, ganglion opticum basale; *Nap*, nucleus ansae peduncularis; *Pr*, basis pedunculi; *Sti*, stilus inferior thalami; *Th*, thalamus; *Tr.o*, tractus opticus; *I, II, III*, nucleus lentiformis.

nucleus which lies lateralward from the nucleus ruber at the ventral end of the nucleus lateralis posterior thalami of Nissl. He believes that the bundle terminates in the superior colliculus of the corpora quadrigemina, probably in its deeper layers. Von Bechterew† derives the bundle from a small oblong conical mass of gray matter which lies between the nucleus ruber and the substantia nigra which he calls the nucleus tractus peduncularis transversi.

We may next properly consider the cell bodies and dendrites of the neurones (optic neurones of the III Order) in the centres in which the retinal fibres terminate and trace the distribution of their axones.

The *colliculus superior* of the corpora quadrigemina, so largely developed in lower animals, is but rudimentary in man. On section one can make out in it a distinct stratum zonale on

\* *Op. cit.*, S. 606 ff.

† *Op. cit.*, S. 55.

the surface beneath which is the stratum griseum colliculi superioris, which in turn is separated from the stratum griseum centrale (the so-called *centrale Höhlengrau* of the Germans) by the stratum album profundum. The general disposition of white and gray matter in the superior colliculus will be clearest if we refer to sections through this body in the rabbit.

The stratum zonale consists of a thin peripheral layer of white fibres (von Kölliker's *äussere weisse Lage*).

The stratum griseum colliculi superioris can be subdivided into several layers, among which is to be seen the so-called middle white matter (von Kölliker's *mittlere weisse Lage*) of the superior colliculus, which may with propriety be designated the stratum album medium. These white fibres assume an antero-posterior direction, and are in large part terminals of optic fibres which have entered the colliculus superior by way of the brachium quadrigeminum superius. The superficial layer of gray substance, which I shall call the stratum griseum superficiale, is narrow, contains relatively few ganglion cells, and is of rather small size. This is the so-called *cappa cinerea* of the superior colliculus (von Kölliker's *äussere graue Zone*).

The stratum griseum profundum contains a relatively large number of nerve cells, many of which are of very large size. The medullated axones of these help to form the stratum album profundum.

Von Kölliker describes the gray matter between the stratum album medium and the stratum album profundum as the "middle gray zone," reserving the term "deep gray zone" for the gray matter in among the superficial and deep fibres of the stratum album profundum (Fig. 518). In the nomenclature of Tartuferi, the stratum album medium plus the middle gray zone of von Kölliker become the *strato bianco-cinereo superficiale*, while the stratum album profundum with its gray matter is designated by him the *strato bianco-cinereo profundo*.

According to Ramón y Cajal, the most important optic fibres ending in the superior colliculus come from the zone of antero-posterior medullated nerve fibres, designated above as the stratum album medium (Tartuferi's *strato bianco-cinereo superficiale*), which lies beneath the peripheral gray cortex. Apparently the fibres of the stratum zonale are not direct continuations of optic fibres, since after extirpation of the eye no



degeneration of these fibres can be demonstrated by Marchi's method. Ramón y Cajal suggests that they represent end

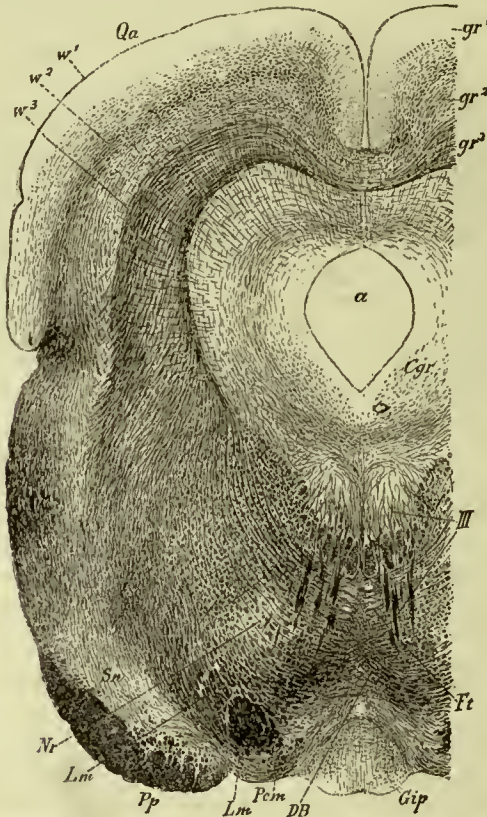


FIG. 518.—Frontal section through the colliculus superior of the rabbit. Staining by Weigert's method. (After A. von Kölliker, *Handbuch der Gewebelehre*, Bd. ii, Leipz., 1896, S. 411, Fig. 571.) *Cgr*, stratum griseum centrale with arcuate fibres and radial fibres; *a*, aqueductus cerebri; *DB*, decussatio brachii conjunctivi; *Ft*, fasciculus pedunculo-mammillaris, pars tegmentalis, in transverse section; *Gip*, ganglion interpedunculare; *Lm*, lemniscus medialis; *Nr*, nucleus ruber; *Pem*, fasciculus pedunculo-mammillaris, pars basilaris (pedunculus corporis mammillaris); *Bp*, basis pedunculi; *Qa*, colliculus superior; *Sn*, substantia nigra; *III*, nucleus N. oculo-motorii, with its root fibres; *gr*, *gr*<sup>1</sup>, *gr*<sup>2</sup>, gray layers of the colliculus superior; *w*<sup>1</sup>, *w*<sup>2</sup>, *w*<sup>3</sup>, white zones.

arborizations of axones which arise from cells in the cortex of the colliculus itself.

In the *cappa cinerea* of Tartuferi, besides the small conical stellate or spindle-shaped cells described there by Tartnferi and



P. Ramón y Cajal,\* S. Ramón y Cajal describes certain other cell types: (*a*) marginal cells, (*b*) horizontal spindle-shaped cells, (*c*) small cells with dendrites directed outward.

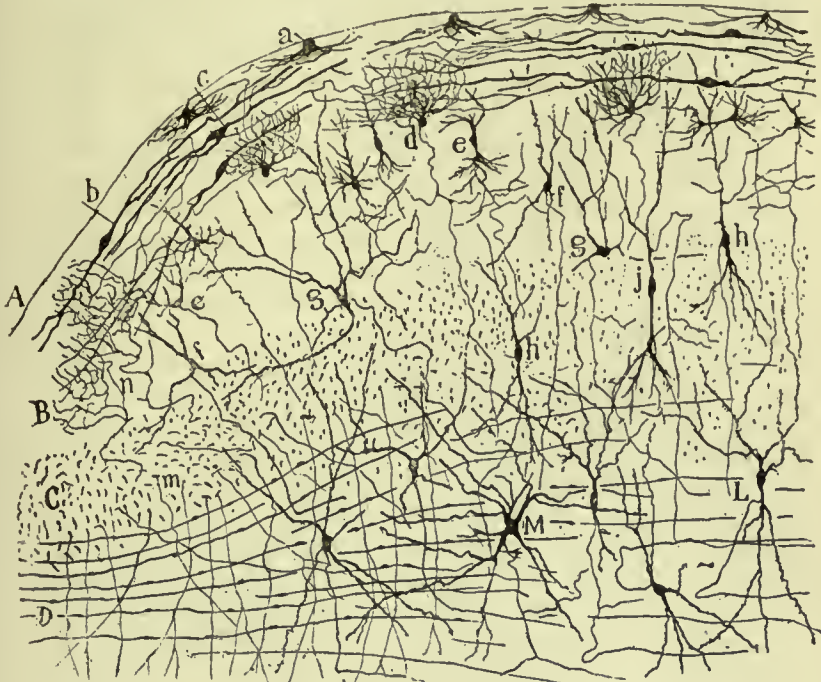

FIG. 519.—Transverse section through the colliculus superior of a rabbit eight days old. (After S. Ramón y Cajal, *Beitrag zum Studium der Medulla Oblongata*, etc., Bresler, Leipz., 1896, S. 30, Fig. 7.) *A*, surface at middle line; *B*, lamina grisea superficialis (Tartuferi's *cappa cinerea*); *C*, layer of optic fibres; *D*, layer of fibres running transversely (Tartuferi's *stratobianco-cinereo profundo*); *a*, marginal cells; *b*, horizontal spindle cells; *c*, same kind of cell with well-marked axone; *d*, small cell with complicated dendrites; *e*, vertical spindle cells; *f*, *g*, *h*, different types of cells of the gray layer; *j*, *h*, spindle-shaped types of cells of the optic layer; *M*, *L*, cells of the layer of transverse fibres; *m*, collateral descending toward the stratum griseum centrale; *n*, end arborization of an optic fibre.

The axones of the small marginal cells (Fig. 519, *a*) are delicate; they run downward, but their termination is uncer-

\* Ramón y Cajal, P. *Investigaciones de histología comparada en los centros de la vision de distintos vertebrados*, 1890; *Investigaciones micrograficas en el encefalo de los batracios y reptiles*, *corpos geniculados y tuberculos cuadrigeminos de los mamiferos*. Zaragoza, 1894.

tain. The spindle-shaped cells placed parallel to the surface of the colliculus show polar dendrites, two or three in number, which run horizontally, divide once or twice dichotomously, and end with free, somewhat jagged terminals (Fig. 519, *b*). Their axones usually arise from the dendrites and also run horizontally, soon breaking up into a number of small branches which are distributed in the first layer. They appear to be Golgi cells of type II. The small cells with dendrites directed outward are triangular, ovoid, or stellate in shape. They possess from one to three or more dendrites, which, branching manifoldly, form an irregular complex bundle of delicate tortuous terminals. The dendrites are so delicate that they might be taken for axones. The axones, however, descend; they are short, but little branched, and reach as far as the zone of optic or antero-posterior fibres (Fig. 519, *d*).

The ending of the optic fibres has already been described. The axones of the large nerve cells of the stratum griseum profundum and in the stratum album profundum itself pass ventralward in the stratum album profundum, bending around the gray matter which surrounds the central canal, and giving off in their course collaterals to the adjacent gray matter. As they curve they often undergo T-shaped division, one branch passing dorsalward, the other ventralward, the dorsal branches terminating, as a rule, soon after their origin, a few of them passing, however, to the superior colliculus of the opposite side. The ventral branches, along with the undivided axones, unite to form the curved system of fibres which run along the margin of the central gray matter (Held). These arched fibres pass ventral to the fasciculus longitudinalis medialis and nucleus N. oculo-motorii as far as the middle line, where they decussate, as Held has shown, with similar fibres from the opposite side in what Forcl has called the "*fontaineartige Haubenkreuzung* of Meynert." The fibres then pass downward toward the medulla, and in human beings soon enter into the fasciculus longitudinalis medialis. In cats and rats Held found it forming a separate bundle from the fasciculus longitudinalis medialis for some distance. As these axones pass downward they give off, from different regions, collaterals and terminals to the various motor nuclei which innervate the eye muscles, a fact which accounts for the eye muscle reflexes which result from retinal stimulation. The superior colliculi of the corpora quadri-

gemina appear to represent the central organ concerned in the control of the eye-muscle movements.

The *corpus geniculatum laterale* is a part of the metathalamus of the thalamencephalon. It, together with the pulvinar

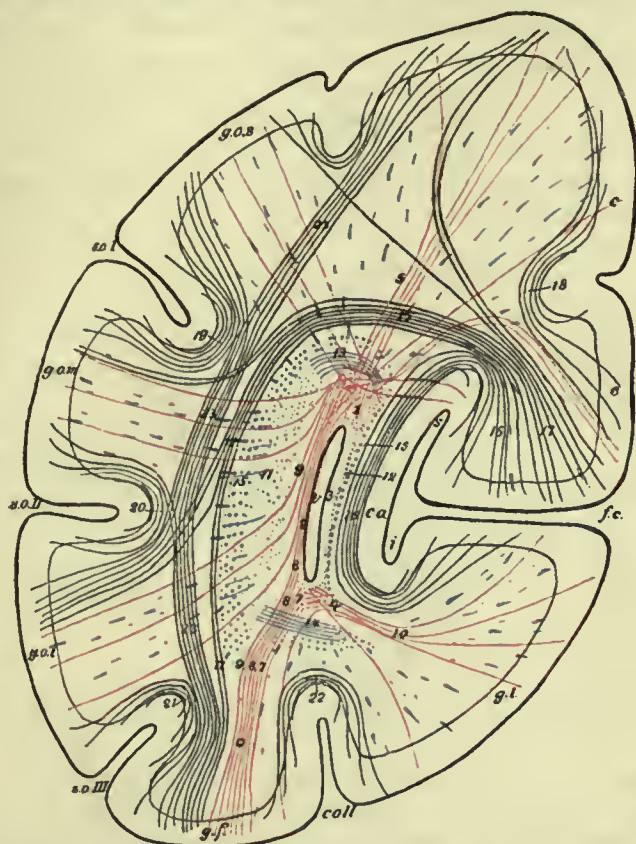


FIG. 520.—Schematic frontal section through the occipital lobe. (After H. Sachs, *Das Hemisphärenmark des Menschlichen Grosshirns*, 1. Der Hinterhauptlappen, Leipz., 1892, S. 6, Fig. 3.) *v*, cornu posterius ventriculi lateralis; *f.c.*, fissura calcarina; *s*, upper division; *i*, lower division; *coll*, sulcus colateralis; *s.o.I*, sulcus occipitalis superior (fissura interparietalis); *s.o.II*, sulcus occipitalis medius; *s.o.III*, sulcus occipitalis inferior; *c.a.*, calcar avis; *g.l.*, gyrus lingualis; *g.f.*, gyrus fusiformis; *g.o.s.*, gyrus occipitalis superior; *g.o.m.*, gyrus occipitalis medius; *g.o.i.*, gyrus occipitalis inferior; *c.*, cuneus; 1-10, forceps; 11-14, stratum sagittale internum; 15, stratum sagittale externum; 16, stratum calcarinum; 17, stratum cunei transversum; 18, stratum proprium cunei; 19, stratum proprium *s.o.I*; 20, stratum proprium *s.o.II*; 21, stratum proprium *s.o.III*; 22, stratum proprium *s.coll.*; 23, stratum profundum convexitatis.

of the thalamus, represents the main termination of optic fibres in the diencephalon. The general characters of the lateral geniculate body have already been described (*vide supra*). The gray matter inside the lateral geniculate body in human beings is known as the nucleus corporis geniculati lateralis. The majority of the cells situated here possess axones which run out through the radiatio occipito-thalamica (Gratioleti) to

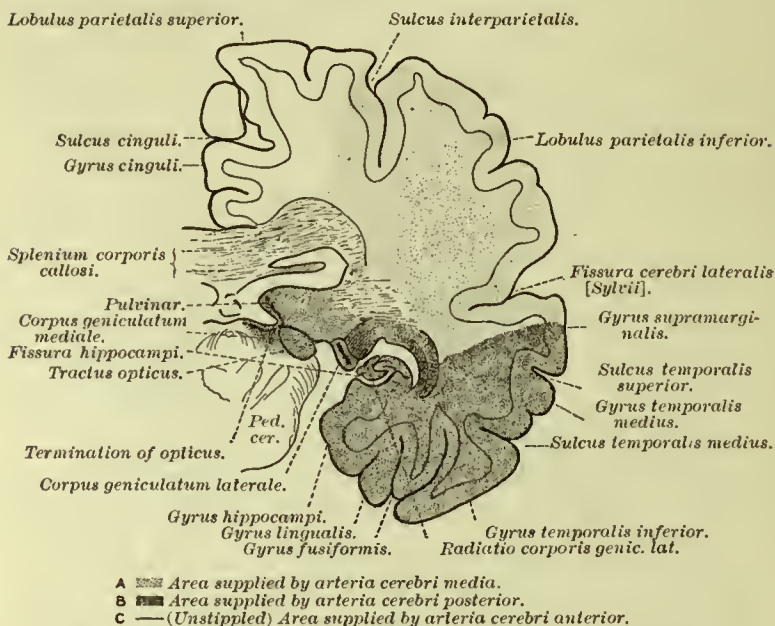


FIG. 521.—Frontal section of human brain, illustrating the visual conduction path. (After C. von Monakow, *Gehirnpathologie*, Wien, 1897, S. 23, Fig. 16.)

terminate in the cortex of the occipital lobe of the hemisphere. The medullated axones extending between the lateral geniculate body and the cortex pass at first lateral from the lateral geniculate body and form an area known as Wernicke's field.\* The fibres are joined by others from the pulvinar and from the colliculus superior of the corpora quadrigemina. They then turn around the nucleus caudatus and the lamina semicircularis and enter the optic radiation. Gratiolet's radiation forms a

\* von Monakow calls this "*das laterale Mark*" of the lateral geniculate body.



large sagittal bundle (*stratum sagittale internum* of Sachs,\* Fig. 520), which runs all the way back, dorsal and lateral, from the cornu posterius of the lateral ventricle to the cuneus.

The white matter of this region includes the tapetum, the genuine optic radiations, and the so-called fasciculus longitudinalis inferior. The relations of these bundles to one another are well shown in the accompanying diagrams (Figs. 521, 522, and 523), selected from von Monakow. The medullated axones from the lateral geniculate body are situated in the occipito-thalamic radiations, ventral from those arising in the pulvinar. As the fibres extend toward the occipital pole, those arising in the lateral geniculate body tend to become distributed to the

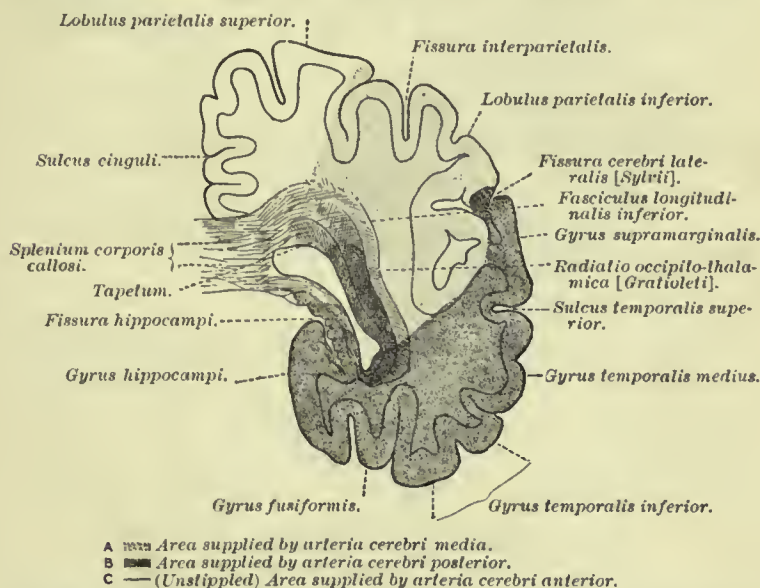


FIG. 522.—Frontal section of normal human brain, illustrating occipito-thalamic radiation, etc. (After C. von Monakow, *Gehirnpathologie*, Wien, 1897, S. 22, Fig. 14.)

medial surface of the hemisphere, especially to the cuneus in the region of the calcarine fissure (Fig. 524).

\* Sachs, H. Das Hemisphärenmark des menschlichen Grosshirns. 1. Der Hinterhauptlappen. Arb. a. d. psychiat. Klinik in Breslau, Leipzig (1892).

A superb demonstration of the exact position of the axones from the cells in the lateral geniculate body is afforded by horizontal sections through the brain of a newborn babe. At this age, as Flechsig has shown, these fibres are medullated, while all the other fibres of Gratiolet's radiation are as yet non-medullated, and one can follow them as a very definite bundle passing out fan-shaped from the posterior superior lateral surface backward as far as the wall of the ventricle, and upward almost to the upper border of the thalamus. This bundle has been called by Flechsig\* the "optic radiation in the narrower sense" to distinguish it from Gratiolet's radiation, or the "optic radiation in the wider sense." Flechsig feels sure that the axones from the lateral geniculate body ("optic radiation in the narrower sense") end exclusively in the wall of the fissura calcarina

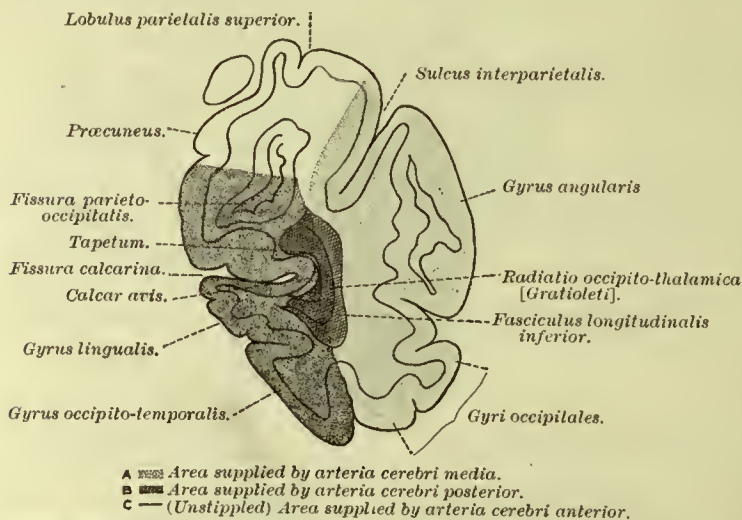


FIG. 523.—Frontal section of normal human brain, illustrating occipito-thalamic radiation, etc. (After C. von Monakow, *Gehirnpathologie*, Wien, 1897, S. 20, Fig. 10.)

(Fig. 525). He assumes, further, that these fibres represent the indirect continuations of the fibres from the macula lutea. If he be correct, the clinical significance of the fact is obvious.

By the study of secondary degenerations the relation existing between the lateral geniculate body and the cortex has

\* Flechsig, P. *Gehirn und Seele*, ii. Aufl., Leipz. (1896), Anm. 29, S. 72.

been well illustrated. Von Monakow has shown that in lesions of the occipital cortex in man involving the region in which the occipito-thalamic regions terminate, there results degeneration, with absorption, of the radiation of the lateral geniculate

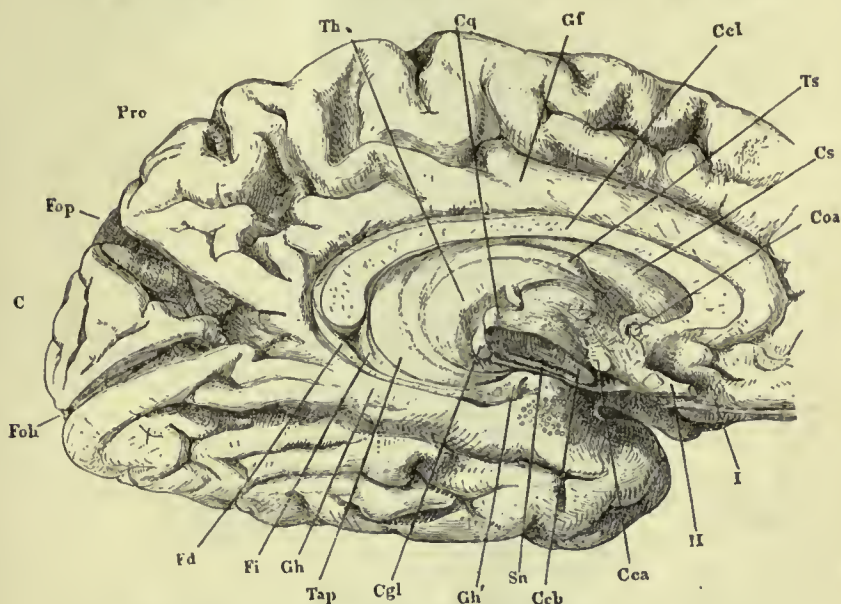


FIG. 524.—Posterior part of left cerebral hemisphere; medial surface. The septum lucidum has been removed and the pedunculus cerebri cut through close to the thalamus. (After J. Henle, *Handbuch der Nervenlehre des Menschen*, II. Aufl., Braunsch., 1879, S. 186, Fig. 105.) *C*, cuneus; *Cca*, corpus mammillare; *Ccb*, cross section of pedunculus cerebri; *Ccl*, corpus callosum; *Cgl*, corpus geniculatum laterale; *Coa*, commissura anterior cerebri; *Cq*, colliculus superior; *Cs*, corpus striatum (nucleus caudatus); *Ed*, fascia dentata; *Fi*, fimbria; *Foh*, fissura calcarina; *Fop*, fissura parieto-occipitalis; *Gf*, gyrus cinguli; *Gh*, gyrus hippocampi; *Gh'*, uncus; *Pre*, præcuneus; *Sn*, substantia nigra; *Tap*, tapetum; *Th*, thalamus; *Ts*, tuberculum anterius thalami; *I*, tractus olfactorius; *II*, nervus opticus.

body, and the ganglion cells of the lateral geniculate body atrophy, and finally disappear (Fig. 526). Von Monakow has further shown, by repeated experiments on animals, that extirpation of the visual sense area of the cortex leads to degeneration and disappearance of the majority of the ganglion cells of the lateral geniculate body. The changes in the lateral geniculate body under these conditions are in marked contrast with those which occur when the optic tract is diseased or experimentally cut. Whereas, in the former case, it is the ganglion cells of the lateral geniculate body and the white matter of

Wernicke's field which degenerate, in the latter instance the ganglion cells and the white matter of Wernicke's field are

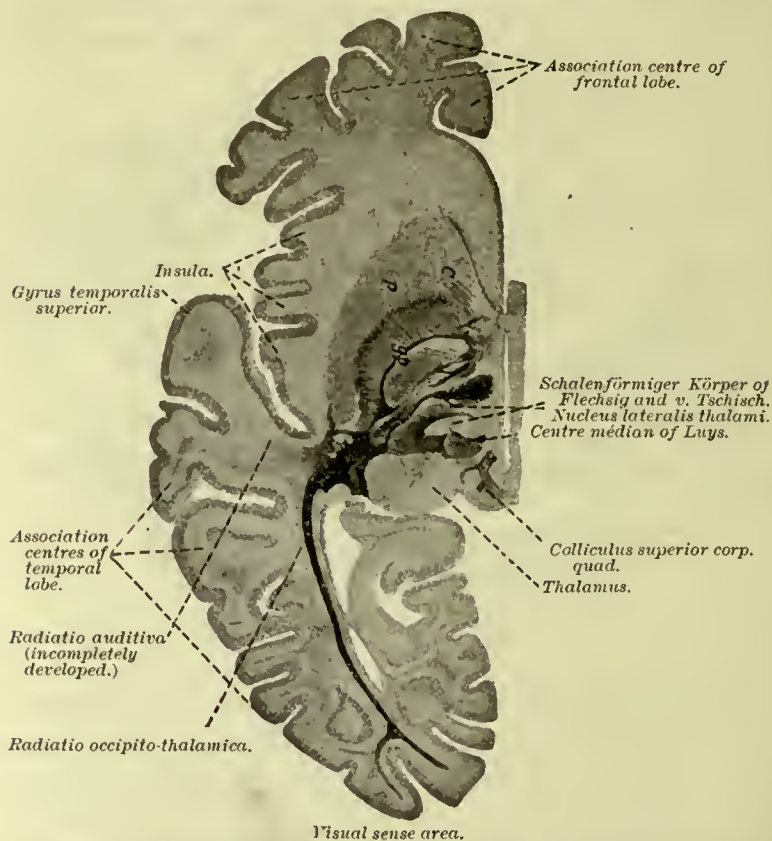


FIG. 525.—Horizontal section from the brain of a child in the second week of life. (After P. Flechsig, *Gehirn und Seele*, Leipz., 1896, Taf. iii, Fig. 4.) C, nucleus caudatus; P, putamen; Ggp, globus pallidus.

practically uninjured, but the fibres of the optic tract and their terminals (substantia gelatinosa of the lateral geniculate body) vanish.

The region of the pulvinar in which the optic-tract fibres terminate resembles very closely in its histological appearances the lateral geniculate body. The cell bodies situated here give off axones which enter the radiatio occipito-thalamica [Gratioleti] in a plane dorsal from that occupied by the medullated axones from the lateral geniculate body.



As to the existence in man of neurones with cell bodies situated in the colliculus superior and axones extending to the visual sense area in the occipital cortex, there is, as yet, some doubt, although the findings in the superior colliculus, after disease of the visual sense area, would lead one to believe that at least a certain number of such neurones exist. It is probable that the cell bodies of these neurones are situated in the stratum griseum colliculi superioris, and that the axones pass by way of the brachium quadrigeminum superius and the radiatio occipito-thalamica to the cortex. Just what impulses are carried by

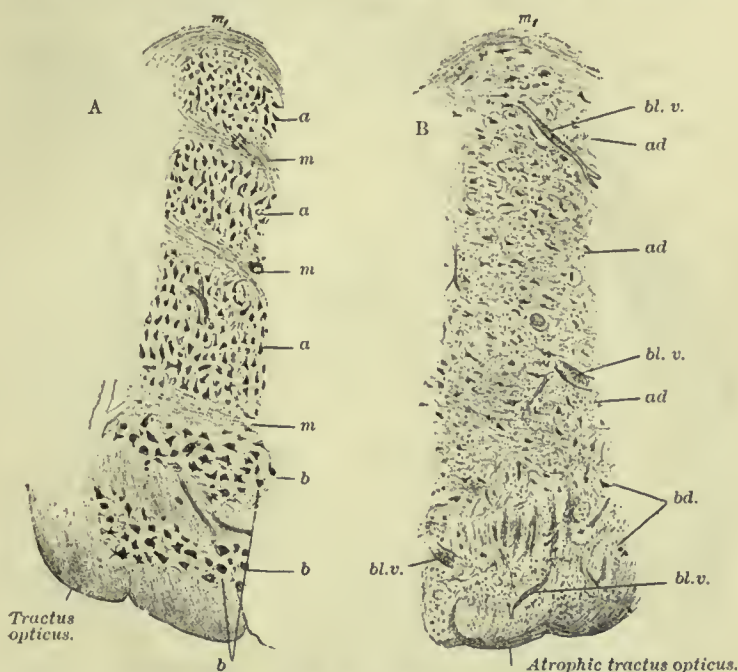


FIG. 526.—Normal and degenerated corpus geniculatum laterale. (After C. von Monakow, *Gehirnpathologie*, Wien, 1897, S. 260, Figs. 88 and 89.) A. Normal corpus geniculatum laterale. B. Corpus geniculatum laterale, degenerated after extensive lesion in the lobus temporalis and lobus occipitalis of the left side. *a*, masses of small ganglion cells arranged in layers, shown atrophic (*ad*) in B; *m*, lamina medullares, shown atrophic (*mt*) in B; *b*, ventral mass of large elements; *to*, tractus opticus; *m'*, dorsal white capsule. In Fig. B.—*ad*, loss of ganglion cells in the dorsal layers; *bd*, total degeneration of the large cells in the central region. The optic tract is atrophic in B.

these fibres does not yet seem clear, for in man the superior colliculus can be entirely destroyed without any recognizable disturbance of light or color vision.

The neurones of the optic paths in the region between the terminations of the optic tract and the occipital cortex have been carefully studied by Ramón y Cajal in the mouse, rat, and

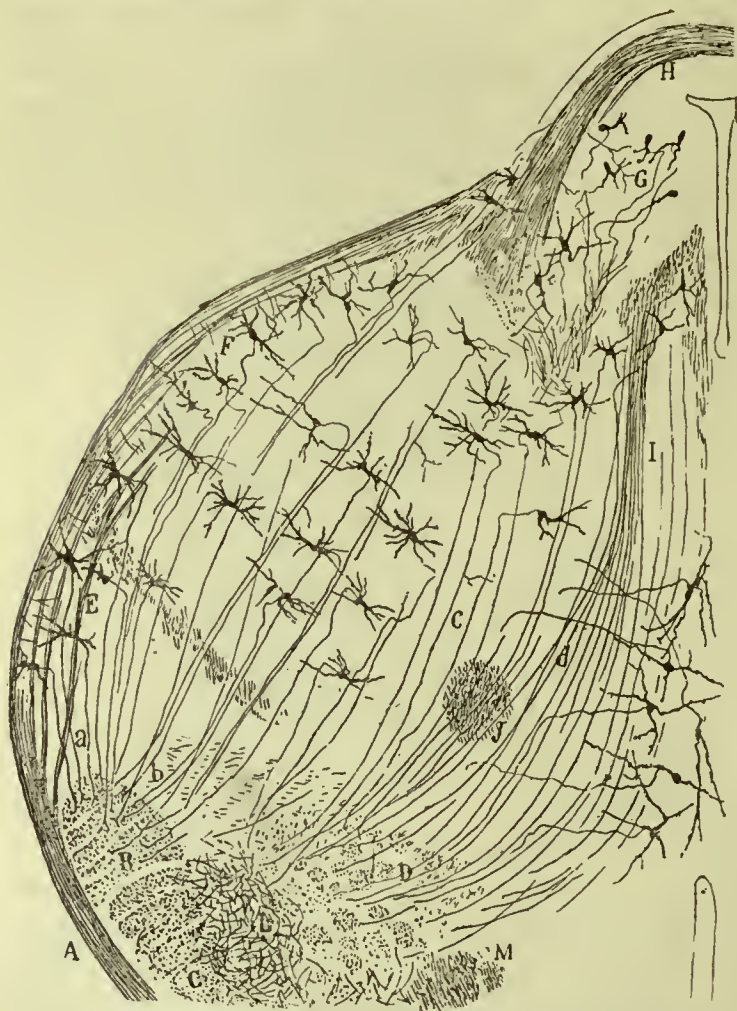

FIG. 527.—Frontal section through the nucleus habenula and the thalamus of a newborn mouse. (After S. Ramón y Cajal, *Beitrag zum Studium der Medulla Oblongata*, Bresler, Leipz., 1896, S. 105, Fig. 25.) A, tractus opticus; B, central optic path; C, pedunculus cerebri; D, bundle collecting the deep fibres from the thalamus; E, corpus geniculatum laterale; F, stratum zonale; G, nucleus habenula; H, commissura interhabenularis; I, medial thalamic bundle; J, fasciculus thalamo-mammillaris; L, fasciculus thalamo-mammillaris Vieq d'Azyri; M, columna fornicis; a, axones of the corpus geniculatum laterale going to the central optic path; b, deep axones.

rabbit.\* Ramón y Cajal distinguishes a superficial and a deep optic path extending from these lower centres to the occipital cortex.

The superficial path arises from the superficial zones of the lateral geniculate body, and perhaps from the region of the stratum zonale of the thalamus. This path accompanies in part the continuation of the optic tract itself, and having arrived at the pedunculus cerebri, turns medialward in order to enter into the upper portion of the latter, where a large triangular bundle exists, sometimes separated distinctly from the other fibres of the peduncle, a bundle which Ramón y Cajal calls the "central optic path" (Fig. 527).

The deep optic path is much more important. It collects the axis cylinders of the cells lying deep in the lateral geniculate body as well as those of the stratum zonale, forms a curve slightly concave lateralward, and enters the "central optic path" on its medial border.

Some of the axones entering the "central optic path" undergo bifurcation, one branch ascending with the main bundle of this path into the corpus striatum, the other descending toward the tegmentum. Ramón y Cajal suggests that the descending branches may represent a reflex path between the visual centres and the motor nuclei of the eyes, of the head, and of the neck.

It is of the highest interest and importance that Ramón y Cajal has been able to follow the axones of the "central optic path" in the new-born mouse throughout their entire course, from their entrance into the corpus striatum as far as their termination in the occipital lobe. He describes the bundle as occupying the most medial part of the peduncular radiation in its passage through the corpus striatum, and states that the fibres having arrived in the white substance beneath the cortex, go upward into the gray substance of those cortical regions in which the white stripe of Gennari or Vieq d'Azyr † is especially

\* Ramón y Cajal, S. *Struktur des thalamus opticus*. Beitrag zum Studium der Medulla Oblongata des Kleinhirns und des Ursprungs der Gehirnnerven. Leipz. (1896), S. 101.

† This stripe is also sometimes called Baillarger's layer. In the cortex of the calcarine fissure it is split into two bands of white fibres which run parallel to one another, the so-called internal and external stripes of Baillarger.



FIG. 528.—Section through the cortex of the gyrus occipitalis superior. (After C. Hammarberg, *Studior öfver Idiotiens Klinik och Patologi*, etc., Upsala, 1893, Taf. ii, Fig. 4.)

well developed, a finding which agrees entirely with the embryological observations of Flechsig. Unfortunately, the ultimate terminals in the gray matter of the cortex were not impregnated in Ramón y Cajal's preparations, possibly because the terminals in the new-born mouse had not yet developed. Von Kölliker, in discussing these findings, finds it striking that Ramón y Cajal has referred all of the axones of the cells which lie in the distribution of the opticus to the centripetal optic path, especially as it was Ramón y Cajal himself who discovered centrifugal optic fibres in mammals, and believed that he had found such in birds.

The structure of the primary visual sense area in the cerebral cortex—that is, of the region in which the fibres of the occipito-thalamic radiations terminate—has been studied by a number of investigators. One of the best descriptions is that of S. Ramon y Cajal.\* We can not do better perhaps, in order to illustrate the extreme complexity of the cortex in this region, than to introduce here the figure embodying the results of the exact studies of the Swedish investigator Hammarberg † (Fig. 528).

As to the termination of the fibres of the occipito-thalamic radiation in the cerebral cortex, von Monakow believes, from the study of secondary degenera-

\* Ramón y Cajal, S. Ueber den Bau der Rinde des unteren Hinterhauptlappens der kleinen Säugethiere. *Ztschr. f. wissensch. Zool.*, Bd. lvi (1893), Heft 4.

† Hammarberg, C. *Studior öfver Idiotiens Klinik och Patologi Jämte Undersökningar af Hjärnbarkens Normala Anatomi*. Upsala, 1893.



tions, that the ultimate end-arborizations correspond more particularly to the fibre plexus of the fifth layer, and in part also to the third and fourth layers. Here he would place Golgi cells of Type II, which, by means of their much-branched axones, transfer the impulses to the cells of the same and other cortical layers. This view is supported by the findings of von Leonowa\* in cases of congenital anophthalmia. On account of the large number of valuable contributions which von Monakow has made by his investigations of the optic paths in man and animals, the scheme which he has constructed for the explanation of the route followed by the impulses is worthy of special consideration. It is reproduced in Fig. 529.

The area in the cerebral cortex, in which the axones from the optic centres in the mesencephalon and diencephalon terminate, is designated, as has been mentioned above, as the visual sense area (*Sehosphäre* of the Germans). Its exact extent in the cortex is as yet the subject of much dispute. Whereas Flechsig, for example, maintains that the fibres of Gratiolet's radiation are distributed only to the medial surface of the occipital lobe and to a small area close to the fissura longitudinalis cerebri on the lateral surface of the hemisphere, other investigators (including H. Sachs and C. von Monakow) believe that fibres of the occipito-thalamic radiations are distributed to the whole of the cortex of the occipital lobe, and possibly also to the posterior part of the parietal lobe. It seems certain that the majority of the fibres from the lateral geniculate body end in the region of the calcarine fissure. Pathological cases in human beings thus far studied have not been uniform enough in their results to permit of decisive statements regarding the matter. In the majority of the cases in which hemianopsia has resulted from cortical disease, the region about the calcarine fissure has been involved, in some instances the posterior part of the fissure to a greater extent, in other instances the anterior part. The view of Ferrier, that the gyrus angularis represents the visual centre, is opposed by both Flechsig and von Monakow. Certain it is that lesions in the region of the angular gyrus are, as a rule, accompanied by defects in the visual field, but it

---

\* von Leonowa, O. Beiträge zur Kenntniss der secundären Veränderungen der primären optischen Centren und Bahnen im Fällen von congenitärer Anophthalmie und Bulbusatrophie bei neugeborenen Kindern. Arch. f. Psychiat. u. Nervenkr., Berl., Bd. xxviii (1896), S. 53-96.

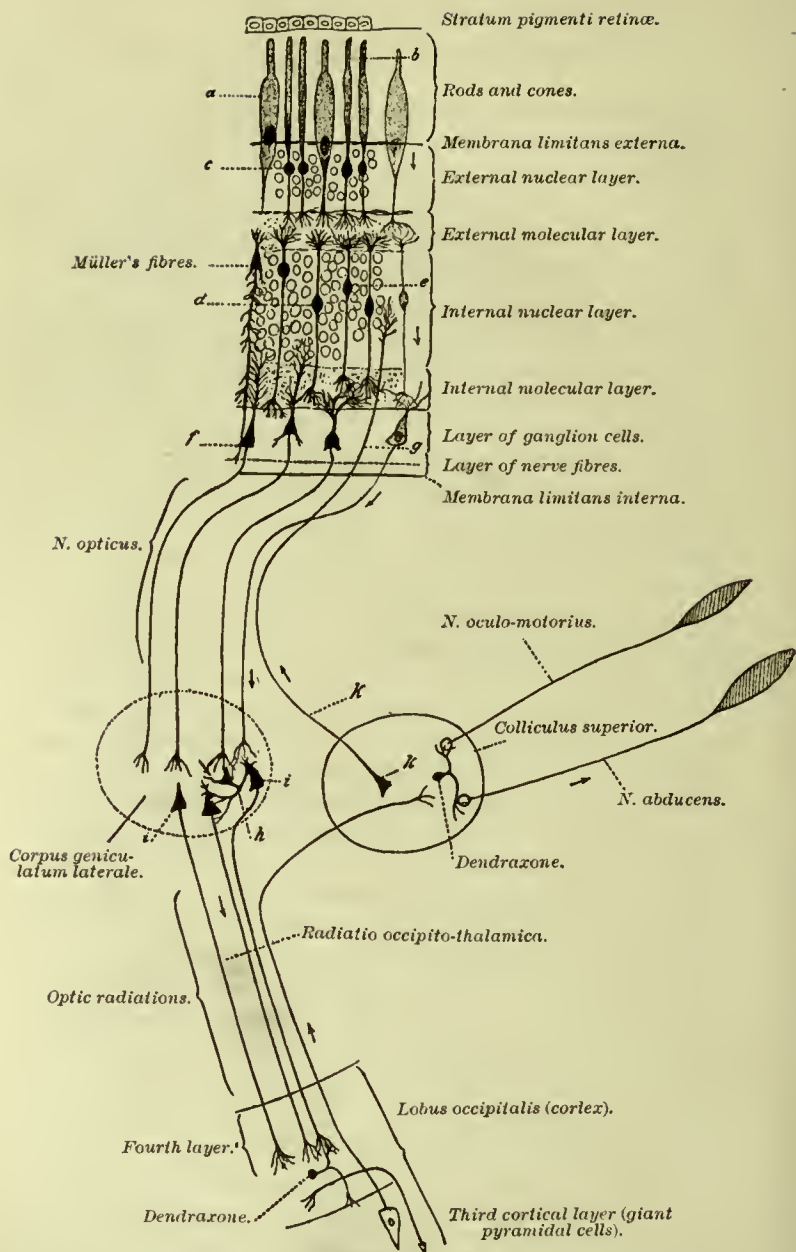


FIG. 529.—Scheme of the visual conduction paths. (After C. von Monakow, *Gehirnpathologie*, Wien, 1897, S. 440, Fig. 120.) *a*, rods and cones; *b*, rods; *c*, nuclei of rods; *d*, bipolar cells for the cones; *e*, bipolar cells for the rods; *f*, large multipolar ganglion cells giving rise to the axones of the N. opticus; *g*, centrifugal axone of a neurone, the cell body of which is situated in the colliculus superior, its telodendrion being situated in the retina; *h*, Golgi cell of Type II, or dendraxon in the corpus geniculatum laterale; *i*, neurone connecting the corpus geniculatum laterale with the lobus occipitalis, its axone running in the radiatio occipito-thalamica (Gratioleti). The visual impulses are indicated by the arrow.

seems probable that in every such instance the lesion has not been limited to the cortex in the region of the angular gyrus, but has extended into the white matter beneath and has involved the fibres of the radiatio occipito-thalamica (Gratioleti) on their way to the occipital lobe.

Attempts have been made by Munk and others to connect certain areas of the occipital cortex functionally with definite regions of the retina. Thus Munk would make the lateral part of the retina correspond to the lateral part of the visual sense area in the occipital cortex, the medial border of the retina to the medial portion of the cortical area, and similarly for the upper and inferior portions of the retina. He believes that the region of the macula lutea is represented only in the opposite visual sense area. But this view is not wholly in accord with the findings in cases of hemianopsia. It is rare in instances of homonymous hemianopsia to find defect of the visual field corresponding to the fixation point (macula lutea). Various theories have been offered as attempts to explain this pe-

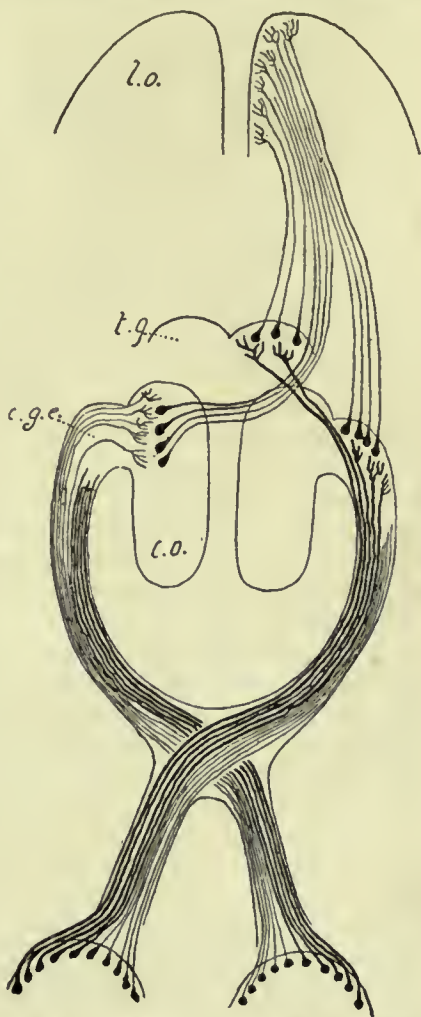


FIG. 530.—Scheme of a hypothetical decussation of the axones passing from the corpus geniculatum laterale to the lobus occipitalis. (After A. van Gehuchten, *Anatomie du Système Nerveux de l'homme*, 2<sup>m</sup>e éd., Louv., 1897, p. 641, Fig. 447.) *l.o.*, lobus occipitalis; *c.g.c.*, corpus geniculatum laterale; *c.o.*, thalamus; *t.g.*, colliculus superior.

culiarity of the majority of cases of hemianopsia. Thus van Gehuchten suggests a partial decussation of the optic fibres, extending between the centres in the diencephalon and the occipital cortex (Fig. 530), but this view as yet lacks anatomical support. The explanation of von Monakow is ingenious if not entirely satisfactory. This author\* assumes that the macula lutea fibres are very widely distributed in the lateral geniculate body, the fibres from the macula of each side being distributed in each lateral geniculate body so as to come into conduction relation with cells in all parts of this nucleus (Fig. 531). With such an anatomical relation in the lateral geniculate body there could always be a path from the macula to the cortex unless all the cortical connections with the lateral geniculate body were destroyed. Von Monakow, therefore, believes that the macula lutea is represented in the occipital lobe, neither solely in the middle nor in the peripheral parts of the visual sense area, but that probably no part of the cortex of the occipital lobe, and perhaps also of the posterior part of the angular gyrus, is unconnected with macular representation. The cortical field for the macula lutea would thus exceed by far that ordinarily assumed for the visual sense area. The view of Wilbrand † is somewhat similar to, although by no means identical with, that of von Monakow.

Henschen's ‡ idea that the field for the macula corresponds to the region of the anterior part only of the calcarine fissure is negated by cases in the bibliography, while the view of Förster and Sachs,\* which assumes that the region corresponding to the posterior part of the calcarine fissure is that in which the macular representation exists, is negated by the instances cited by Henschen.

On reviewing the whole subject of hemianopsia it would seem possible to do without such an elaborate scheme as that

---

\* von Monakow, C. Experimentelle und pathologisch-anatomische Untersuchungen ueber die optischen Centren und Bahnen nebst klinischen Beiträgen zur corticalen Hemianopsie und Alexie (Neue Folge). *Arch. f. Psychiat. u. Nervenkr.*, Berl., Bd. xxiii (1891-'92), S. 609; Bd. xxiv (1892), S. 229.

† Wilbrand, H. Die Doppelversorgung der Macula lutea. *Festschrift für Professor Förster*, Wiesbaden, 1895.

‡ *Op. cit.*

\* Sachs, S. Das Gehirn des Förster'schen Rindenblinden. *Arb. aus d. psychiat. Klinik in Breslau*, 1895, S. 53-104.



suggested by von Monakow or that suggested by Wilbrand. While it is not impossible that the macular representation in the lateral geniculate body is widespread,\* as von Monakow

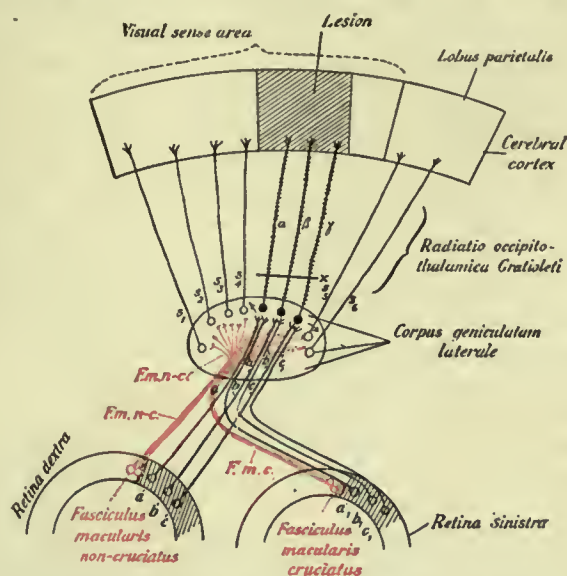


FIG. 531.—Scheme of the central optic paths, illustrating von Monakow's view of the representation of different portions of the retina in the corpus geniculatum laterale and his explanation of the fact that macular vision is undisturbed in cortical hemianopsia. (After C. von Monakow, *Gehirnpathologie*, Wien, 1897, S. 458, Fig. 131.) *a b c*, ganglion cells of retina on right side sending axones to N. opt.; *a1, b1, c1*, ganglion cells in the homonymous part of the left retina; *F.m.-c.*, macular neurones of the right side; *F.m.c.*, macular neurones of the left side; *s1, s2, s3, s4*, neurones the axones of which run through the radiatio occipito-thalamica Gratioleti to the lobus occipitalis; *a, b, c*, neurones with interrupted axones at *x*. While most of the retina has limited representation in the corpus geniculatum laterale, von Monakow believes that the macula fibres are distributed over the whole nucleus. With every crossed optic fibre there terminates also an uncrossed optic fibre, according to his view.

suggests, yet it seems to me unnecessary to assume that the fibres from the lateral geniculate body have so wide a cortical distribution as he would give them. Indeed, there is very much anatomical evidence against such a wide distribution. It seems to me much more likely that the macular field corre-

\* Henschen, in a recent article (*Ueber Localisation innerhalb des äusseren Knieganglions*. *Neurol. Centralbl.*, Leipz., Bd. xvii (1898), S. 194), speaks for a restricted localization in the lateral geniculate body, and cites a case in which the findings demonstrate that the dorsal portion of the lateral geniculate body corresponds to the dorsal quadrant of the retina.

sponds to the whole length of the cortical area corresponding to the calcarine fissure, and that involvement of the whole of this area is necessary to cause defect of the visual field corresponding to the fixation point. This would be in accord not only with the findings of Henschen but also with those of Förster and Sachs, and, as far as I am aware, there are no anatomical data thus far which contradict it.\*

In the periphery of this visual sense area in the narrower sense there is doubtless a considerable area of cortex which receives fibres from the occipito-thalamic radiation. From the visual sense area in the wider sense—that is, the region corresponding to the distribution of all of the fibres of the occipito-thalamic radiation—there pass out doubtless many axones to neighboring gyri in the parietal and temporal lobe, axones of neurones associative in function which bring the activities of the visual sense area into relation with the activities of other centres in the cerebral cortex. Some reference to these association neurones, which may, in a sense, be looked upon as the neurones of higher visual centres, will be made further on.

---

\* In a very important case described by Förster (*Arch. f. Ophth., Berl.*, Bd. xxxvi) and studied anatomically by Sachs (*Arbeiten aus d. psychiat. Klinik im Breslau* (1895), H. 2) the patient had had, in 1884, an attack with sudden loss of the right half of both visual fields with the exception of from one degree to two degrees near the fixation point. Five years later hemianopsia involving the left halves of the visual field set in. With this double hemianopsia, however, central vision was retained. Hearing and writing were not at all disturbed, although it is true that the sharpness of vision had diminished by one half, the power of distinguishing colors was lost, and there was inability to recognize the reciprocal position of things in space. In 1893 the individual died, and at autopsy a doubled-sided lesion, involving the medial surface of both occipital lobes, was found. The brain was divided into serial sections, and it was discovered that practically the whole of the medial surface of both occipital lobes and the adjacent white matter were destroyed, with the exception of a small portion of the peduncle of the cuneus lying anteriorly and the most posterior part of the region of the calcarine fissure which had escaped uninjured. This case, more than any other in the bibliography, suggests that macular representation extends beyond the medial surface of the occipital lobe. But it is not impossible that the small area at the posterior extremity of the calcarine fissure sufficed for the central vision. At any rate, until a case has been studied in which there has been complete loss of the visual sense area in the region of both calcarine fissures, with retention of central vision, we may hold on to the view that the macular representation corresponds to the region of the calcarine fissure in its whole length.

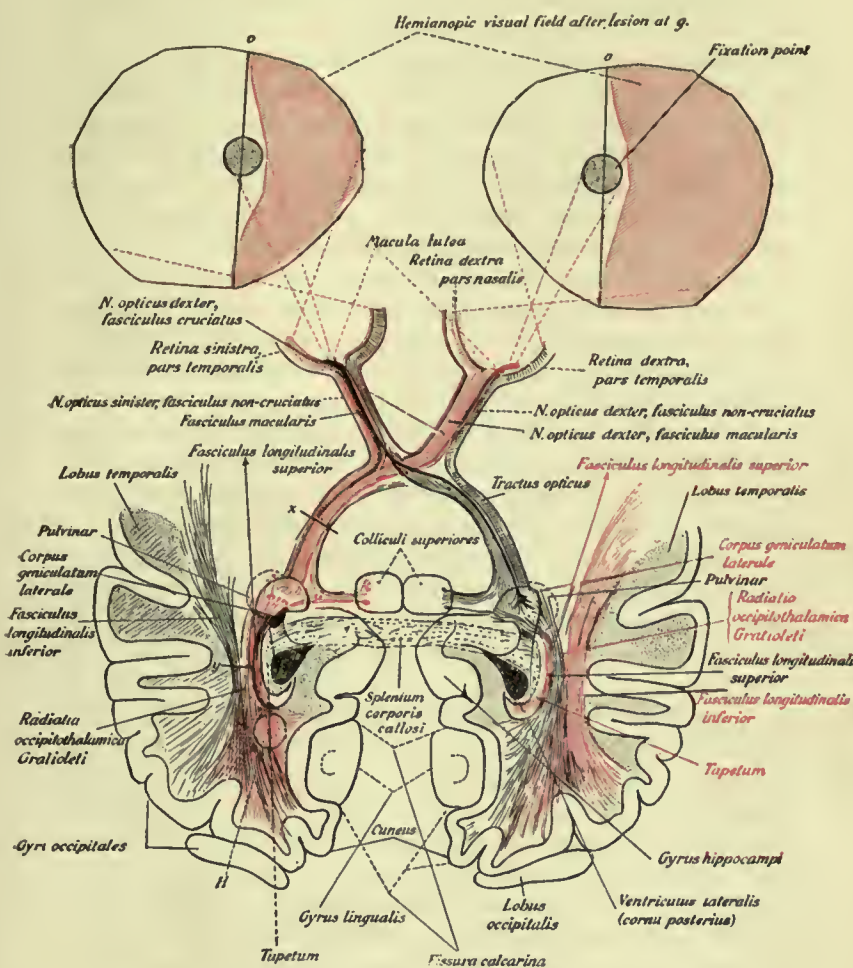


FIG. 532.—Scheme of the course of the optic paths represented in a horizontal plane, with illustration of the occurrence of cortical and subcortical hemianopsia. (After C. von Monakow, *Gehirnpathologie*, Wien, 1897, S. 446, Fig. 121.) On the left side the optic paths are red; on the right side black. *x*, hypothetical lesion in tractus opticus; *y*, hypothetical lesion in white matter of occipital lobe. With lesion at *y* there would be interruption not only of the fibres of the optic radiation, but also of the axones of the fasciculus longitudinalis inferior, so that along with right-sided hemianopsia there would be also alexia. *II*, nodule in the white matter near the fissura calcarina which could cause hemianopsia without alexia.

In the diagram (Fig. 532), also taken from von Monakow, the principal lesions which occur in human beings in the domain of the optic paths are well illustrated.

With regard to the centripetal fibres carrying the impulses to the nucleus nervi oculo-motorii and leading to reflex contraction of the pupil the following positive statements can be made:

In the first place, they arise from all portions of the retina, inasmuch as a ray of light thrown upon any given minute area on the surface of the retina will lead to reflex contraction, provided the nerve tracts are in a normal condition.\*

In the second place, these fibres run through the optic nerve, the chiasm, and the tract, and undergo partial decussation in the chiasm. This is proved by the so-called "hemianopic pupillary inaction" of Wernicke. Wernicke showed that in hemianopsia due to a lesion of the optic tract illumination of the homonymous halves of the retina affected will not cause contraction of the pupil, while, on the other hand, illumination of the opposite halves of the retina leads to pupillary contraction, and the pupil contracts normally on convergence.

It is further known that the pupillary path passes through the brachium quadrigeminum superius to reach the colliculus superior of the corpora quadrigemina and thence goes to the nucleus nervi oculomotorii in the floor of the aqueductus cerebri.

More than this, perhaps, can not be said with certainty, and the most divergent views are held regarding certain details of the path. Thus, for example, the total number of neurones concerned in the passage from the retina to the nucleus nervi oculomotorii is disputed. Whereas a certain number of investigators hold that the retinal axones pass directly to the region of the oculomotor nucleus, others maintain the existence of intermediary pupillary centres. Bogroff and Flechsig† have described a root of the optic tract which passes directly into the stratum griseum centrale of the third ventricle. The evi-

---

\* In this connection the following articles should be consulted: (1) Peretti. Ein Fall von Atrophia Nervi optici descendens nach Schädel Verletzung. Deutsche med. Wchnschr., Leipz. u. Berl., Bd. xix (1893), S. 301. (2) Sachs, Z. Einschnürung der Sehnerven durch gesammte Gefässe der Hirnbasis. Arch. f. Augenh., Wiesb., Bd. xxvi (1892-'93). S. 237-274.

† Bogroff and Flechsig. Neurol. Centralbl., Leipz., Bd. v (1886), S. 551. Cited by von Bechterew.



dence at present is in favor of an intermediary nucleus in the pupillary path, but just where that nucleus is situated is still a matter of doubt.

Darkschewitsch \* believes that the pupillary fibres leave the tractus opticus in the region of the corpus geniculatum laterale, and pass through the thalamus to the corpus pineale and the ganglion habenulæ. Hence the reflexes are mediated by means of fibres which pass through the posterior commissure to his *obere Oculomotoriuskern*. His conclusions were arrived at after study of degenerations following physiological experiments, and they have received support from Bellonci † on the ground of his studies in comparative anatomy.

The views of Darkschewitsch have received a partial confirmation from the studies of Mendel, who supports the doctrine that the ganglion habenulæ is a pupillary nucleus. Mendel extirpated the iris in new-born animals, and asserts that he found atrophy of the ganglion habenulæ of the same side, and of certain fibres of the posterior commissure. According to his view, therefore, the reflex path for the iris would be through the optic nerve, chiasm, and optic tract to the ganglion habenulæ of the same side, thence by way of the commissura posterior to von Gudden's nucleus, and to the nucleus nervi oculomotorii.

A somewhat different idea is advocated by von Bechterew. He follows the pupillary fibres through the optic nerve of the chiasma opticum, but states that they do not enter the tractus opticus nor the geniculate bodies, but close behind the chiasm and without decussation enter the stratum griseum centrale of the third ventricle, whence they pass uncrossed to the nucleus nervi oculomotorii. ‡ He bases his view upon the following findings: (1) Section of the optic tract in the dog caused hemianopsia but no alteration in the pupil; (2) destruction of the superior colliculus, or of the corpora geniculata, did not abolish the reaction of the pupil to light.

\* Darkschewitsch, L. Ueber die sogenannten primären Opticuseentren und ihre Beziehung zur Grosshirnrinde. Arch. f. Anat. u. Physiol., Anat. Abth., Leipz. (1886), S. 249-270.

† Bellonci, G. Ztschr. f. wissensch. Zool., Bd. lxxiv, H. 1, S. 25.

‡ von Bechterew, W. Ueber den Verlauf der die Pupille verengenden Nervenfasern im Gehirn und ueber die Localisation eines Centrums für die Iris und Contraction des Augenmuskeln. Arch. f. d. ges. Physiol., Bonn, Bd. xxxi (1883), S. 60-87.

Henschen \* emphasizes the fact that Wernicke's observation of hemianopic pupillary inaction in lesions of the optic tract is decisive in favor of the view that the pupillary fibres run in the tractus opticus. They go at least as far as the border of the pedunculus cerebri. The case reported by Leyden † is especially valuable in this connection, as is also a case reported by Dercum, of Philadelphia. Henschen states that a series of cases supports the view that the pupillary fibres do not enter the lateral geniculate body, and holds that Knies is probably wrong in thinking that lesion of the lateral geniculate body can give rise to Wernicke's hemianopic pupillary sign.

Although the evidence is not yet conclusive, it seems to me most probable that the pupillary fibres run through the brachium quadrigeminum superius into the superior colliculus, there to come into contact with the cell bodies and dendrites of neurones in the nucleus colliculi superioris, and thence the impulses pass by way of the axones of the latter to the nucleus nervi oculomotorii of the same and of the opposite side. At any rate, the histological investigations of Held make such a view plausible.

The statement is frequently made that the coarse fibres of the optic nerve are those which are concerned in pupillary reflexes. But even this is not definitely proved.‡

The conduction paths in connection with the eyes should not be dismissed without reference to the centrifugal fibres of the optic nerve discovered by Ramón y Cajal. The existence of these fibres has been confirmed by van Gehuchten, von Kölliker, Held, and others. The cells of origin of these centrifugal axones are situated in the centres in the mesencephalon and diencephalon. They have not only been demonstrated by Golgi's method, but their existence and disposition has been proved also by the methods of secondary degeneration. Ac-

\* Henschen, S. E. Ueber hemianopische Pupillenreaktion. Klinische und anatomische Beiträge zur Pathologie des Gehirns. Dritter Theil, I Hälfte, Upsala (1894), S. 109.

† Leyden, E. Beiträge zur topischen Diagnostik der Gehirnkrankheiten. Internat. Beitr. z. wissensch. Med., Festschr. R. Virchow . . . , Berl., Bd. iii (1891), S. 283-306.

‡ The visual and pupillary paths have recently been reviewed by K. Baas. Die Seh.- und Pupillen-Bahnen. Breslau (1898). The article has not thus far been accessible to me.



under the influence of the cerebral cortex through these centrifugal neurones, since the large pyramidal cells in the third cortical layer, the so-called solitary cells of the visual sense area, send their axones down through the optic radiation and through the posterior limb of the internal capsule to the optic centres in the diencephalon and mesencephalon. These cells degenerate after lesion of the internal capsule or of the occipito-

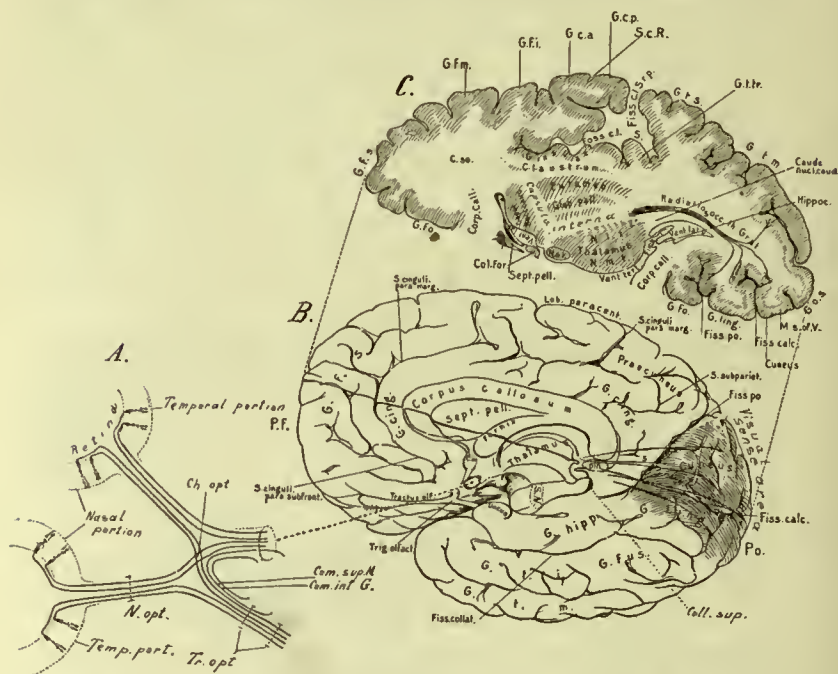


FIG. 534.—Scheme of visual conduction paths; the lettering is the same as for Plate I.

thalamic radiation. It seems probable that the majority of these axones run to come into conduction relation with the mesencephalic organ controlling the eye muscle nuclei, but it is not impossible that some of them terminate about the cell bodies and dendrites of the neurones, the axones of which form the centrifugal fibres of the optic tract and optic nerve.

In connection with the visual conduction paths it would have been interesting to discuss the various theories of vision which have been put forward, especially those propounded by



Helmholtz,\* Hering,† Gölher,‡ Donders,# von Kries,|| and Mrs. Franklin,<sup>Δ</sup> but they can only be mentioned here, accompanied by the bibliographic references.

In Figs. 533 and 534 the more important and best known centripetal neurones of the visual conduction path are schematically represented.

\* Helmholtz, H. Ueber die Theorie der zusammengesetzten Farben. 8vo, Berlin, 1852.—Handbuch der physiologischen Optik., II. Aufl., Leipz. (1888).

† Hering, E. Lehre vom Lichtsinn. II. Aufl., Wien (1878).

‡ Gölher, A. Die Analyse der Lichtwellen durch das Auge. Ein Beitrag zur Erklärung der Farbenempfindung. Arch. f. Anat. u. Physiol., Physiol. Abth. (1888), S. 139-162.

# Donders, F. C. Noch einmal die Farbensysteme. Arch. f. Ophthalm., Bd. xxx, Abth. 1 (1884).

|| von Kries, J. Entgegnung an Herrn E. Hering. Arch. f. d. ges. Physiol., Bonn, Bd. xli (1887), S. 389-397.—Ueber die Farbenblindheit der Netzhautperipherie. Ztschr. f. Psychol. u. Physiol. d. Sinnesorg., Hamb. u. Leipz., Bd. xv (1897), S. 247-289.

<sup>Δ</sup> Franklin, Christine Ladd. Eine neue Theorie der Lichtempfindungen. Ztschr. f. Psychol. u. Physiol. d. Sinnesorg., Hamb. u. Leipz., Bd. iv (1892).—On Theories of Light Sensation. Mind, Lond. and Edinb., n. s., vol. ii (1893), pp. 473-489.—A New Theory of Light Sensation. Johns Hopkins Univ. Circ., Balt., vol. xii (1893), pp. 108-110.—Professor Ebbinghaus' Theory of Color Vision. Mind, Lond. and Edinb., n. s., vol. iii (1894), p. 103.—Professor Müller's Theory of the Light Sense. Psychol. Rev., N. Y. and Lond., vol. vi (1899), pp. 70-85.—Mrs. Franklin's observations upon "normal faint-light foveal blindness" are recorded in Psychol. Rev., N. Y. and Lond., vol. ii (1895), pp. 137-148.

## CHAPTER LIV.

### AUDITORY NEURONES OF THE SECOND AND OF HIGHER ORDERS.

Nuclei terminales of N. cochleæ—General view of central auditory paths—Striæ medullares—Corpus trapezoideum—Superior olivary complex—Lemniscus lateralis—Nucleus lemnisci lateralis—Colliculus inferior—Corpus geniculatum mediale.

Nucleus nervi cochleæ ventralis—Nucleus nervi cochleæ dorsalis—Nucleus olivaris superior—Nucleus corporis trapezoidei—Nucleus præolivaris—Nucleus semilunaris—Corpus trapezoideum—Lemniscus lateralis—Nuclei lemnisci lateralis—Relations of the lemniscus lateralis to the nucleus colliculi inferioris, the corpus geniculatum mediale, and the pallium—Acoustic reflex paths—Auditory sense area in the cerebral cortex—Schemes of auditory path.

#### *4. Central Neurones of the Auditory Conduction Paths.*

THE peripheral auditory neurones connecting the organ of Corti with the rhombencephalon have been described in an earlier chapter. We have seen that the cell bodies of the peripheral auditory neurones are situated in the ganglion spirale, that their dendrites are distributed to the organon spirale (Corti), and that their axones pass through the radix cochlearis of the nervus acusticus to terminate chiefly in the nucleus nervi cochlearis ventralis and the nucleus nervi cochlearis dorsalis (tuberculum acusticum), a portion of the fibres, however (according to Held), going farther, to terminate first in the nucleus olivaris superior of the same or of the opposite side, or in masses of gray matter situated even higher up in the central nervous system.

With regard to the central auditory paths, the results of different investigators in earlier years were markedly discordant. Thus, while Forel, Onufrowicz, and von Monakow denied that the fibres of the trapezoid body had anything to do with the central auditory path, Flechsig, von Bechterew, Baginsky, Bumm, and others maintained the opposite view. Neurologists

are to be congratulated that through the researches of the past few years, by means of a variety of methods, we have finally arrived to much more definite and satisfactory ideas regarding this portion of the nervous system. The views to be outlined here, which may be considered to represent the present status of our knowledge regarding the auditory conduction inside the central nervous system, are based upon researches of Flechsig,\* von Monakow,† Held,‡ von Kölliker,\* Ramón y Cajal,|| and Florence Sabin.<sup>A</sup>

In general, it may be said that from the nuclei terminales of the cochlear nerve, axones of neurones of the second order pass by way of both the striæ medullares and the corpus trapezoidum to the region of the superior olivary complex of both sides, principally of the opposite side. Many of the fibres terminate in the nucleus olivaris superior and in the gray nuclei of the corpus trapezoidum. Others of them go on (accompanied by axones arising in the nuclei in which their fellows stop) to pass through the lemniscus lateralis to the colliculus inferior of the corpora quadrigemina (Fig. 535). On their way a num-

---

\* Flechsig, P. Zur Lehre vom centralen Verlauf der Sinnesnerven. Neurol. Centralbl., Leipz., Bd. v (1886), S. 97-100; also Weitere Mittheilungen ueber die Beziehungen des unteren Vierhügels zum Hörnerven. Neurol. Centralbl., Leipz., Bd. ix (1890), S. 98-100.—Die Localisation der geistigen Vorgänge, insbesondere der Sinnesempfindungen des Menschen. Leipzig, 1896.

† von Monakow, C. Ueber einige durch Exstirpation circumscripter Hirnrindenregionen bedingte Entwicklungshemmungen des Kaninchengehirns. Arch. f. Psychiat. u. Nervenkr., Berl., Bd. xii (1882), S. 141; 535.—Neue experimentelle Beiträge zur Anatomie der Schleife. Neurol. Centralbl., Leipz., Bd. iv (1885), S. 265-268.—Cor. Bl. f. Schweiz. Aerzt., 1887, No. 5.—Striæ Acusticæ und untere Schleife. Arch. f. Psychiat. u. Nervenkr., Berl., Bd. xxii (1890), S. 1-26.

‡ Held, H. Die centralen Bahnen des Nervus acusticus bei der Katze. Arch. f. Anat. u. Physiol., Anat. Abth., Leipz. (1891), S. 271-291.—Die centrale Gehörleitung. Arch. f. Anat. u. Physiol., Anat. Abth., Leipz. (1893), S. 201-248.

\* von Kölliker. *Op. cit.*, S. 258 ff.

|| Ramón y Cajal, S. Orígenes del acustico en los aves. Algunas contribuciones al conocimiento de los ganglios del encéfalo. Madrid, 1894.—Nervio cochlear y ganglios acusticos. Apuntes para el estudio del bulbo raquídeo, cerebelo y origen de los nervios encefálicos. Madrid, 1895.

<sup>A</sup> Sabin, Florence. On the Anatomical Relations of the Nuclei of Reception of the Cochlear and Vestibular Nerves. Johns Hopkins Hosp. Bull., Balt., vol. viii (1897), pp. 253-259.

ber of them terminate in all probability in the nucleus lemnisci lateralis.

The colliculus inferior must be looked upon as one of the most important way-stations in the central auditory path. In the nucleus colliculi inferioris terminate, perhaps, the majority of the fibres of the lemniscus lateralis; a certain number, however, go farther forward. These fibres pass on mainly through

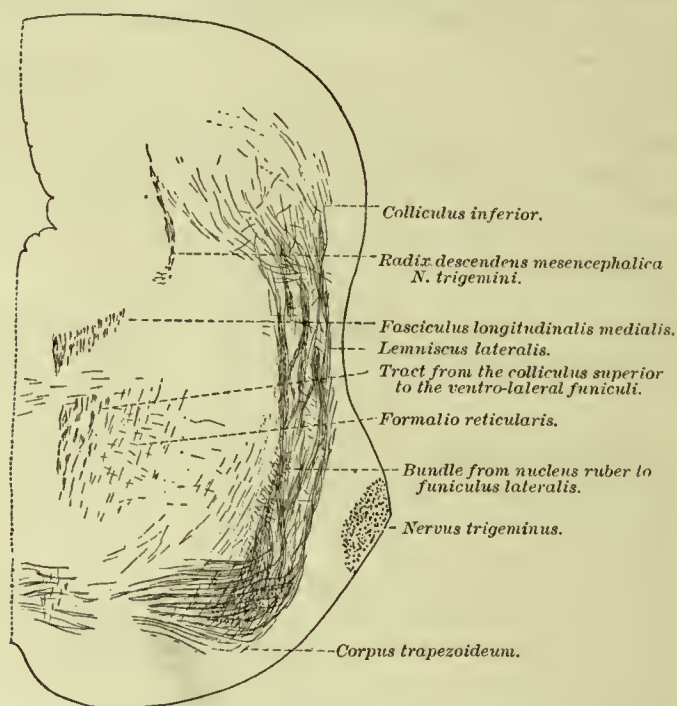


FIG. 535.—Oblique section through the brain stem of a newborn cat, illustrating (1) the separation, in the superior part of the pons, of the fasciculus longitudinalis medialis from the fibre system descending from the colliculus superior to the ventro-lateral funiculi; and (2) the relation of the lateral lemniscus to the colliculus inferior. (After H. Held, Abhandl. d. math.-phys. Cl. d. k. sächs. Gesellsch. d. Wissensch., Leipz., Bd. xviii, No. 6, 1892, Taf. ii, Fig. 9.)

the brachium quadrigeminum inferius to reach the corpus geniculatum mediale, where apparently a large number of them terminate in the nucleus corporis geniculati medialis. In the latter nucleus are situated the cell bodies of neurones, the axones of which pass forward through the retrolentiform portion of the capsula interna to reach, by way of the corona radiata,



the auditory sense area in the cerebral cortex (junction of third and fourth fifths of gyrus temporalis superior, together with the gyri temporales transversi). It is possible that some fibres from the lateral lemniscus go past the geniculate body without stopping to terminate first in the auditory sense area in the cerebral cortex (so called direct acoustic cortical path of Held).

The smallest number of neurones superimposed to form the auditory conduction path from the internal ear to the cerebral cortex is therefore, in all probability, three—one extending from the organ of Corti to the nuclei terminales of the cochlear nerve (peripheral auditory neurone or auditory neurone of the first order); a second passing from the nuclei terminales of the auditory nerve to the corpus geniculatum mediale (rhombencephalo-diencephalic auditory neurone or auditory neurone of the second order); a third extending from the medial geniculate body to the temporal lobe of the cerebral cortex (diencephalo-telencephalic auditory neurone or auditory neurone of the third order). While such a superimposition of neurones is to be regarded as the simplest and most direct arrangement possible in the auditory conduction path, it seems likely that there are other more complicated and perhaps far less direct combinations of neurones which make up the apparatus of the conduction of auditory impulses.

Thus it may even be that the simplest auditory conduction path consists of at least four superimposed neurones, one extending from the organ of Corti to the nuclei terminales of the cochlear nerve (peripheral auditory neurone or auditory neurone of the first order); a second passing from the nuclei terminales of the auditory nerve to the colliculus inferior of the corpora quadrigemina (rhombencephalo-mesencephalic auditory neurone or auditory neurone of the second order); a third extending from the colliculus inferior to the corpus geniculatum mediale (mesencephalo-diencephalic auditory neurone, or auditory neurone of the third order); a fourth extending from the medial geniculate body to the auditory sense area in the cortex (diencephalo-telencephalic auditory neurone, or auditory neurone of the fourth order). Further, a whole series of nuclei intercalated in this conduction path have to be considered: the nuclei terminales of the cochlear nerve, the nucleus olivaris superior, the nucleus corporis trapezoidei, the nucleus præolivaris, the

nucleus semilunaris, the nucleus lemnisci lateralis, the nucleus colliculi inferioris, and in addition the nucleus corporis geniculati medialis, and possibly other masses of gray matter in the hypothalamus not yet clearly defined.

It is not impossible that, besides neurones extending between these different gray masses and connecting them with one another, Golgi cells of Type II, or dendroxones situated inside the individual gray masses, may play a part in the conduction of auditory impulses.

No attempt will be made to give here an exhaustive description of all the neurones which are probably concerned directly or indirectly in the auditory conduction path. In the first place, our knowledge of these neurones is by far too fragmentary to permit of an exhaustive description, and in the second place, for practical purposes, it would seem to be much more important that the student possess a clearly defined idea of one or two of the principal paths than that he have his conception confused by a mass of bewildering details which can not as yet be adequately valued.

Since their discovery by Piccolomini the *striae medullares*, those white bands which run across the floor of the fourth ventricle and which vary so enormously in different individuals, have attracted the attention of many neurologists (cf. Fig. 372, pp. 557). Sometimes they may be entirely absent on one or both sides; in other instances they are very markedly developed, forming a very striking anatomical feature. The bands do not run, as a rule, exactly transversely, nor are they all parallel to one another, for one band may even cross some of the others. One stripe, often seen running obliquely forward and to the side, is known as the conductor sonorus (*Klangstab* of Bergmann).<sup>\*</sup> Later studies make it seem likely that Bergmann's stripe really has nothing to do with the conduction of auditory impulses. Embryological studies of von Bechterew show that the *striae medullares* become medullated at a relatively late period. He thinks that they have nothing to do with the acoustic path, but represent cerebellar connections.

The study of secondary degenerations has thrown considerable light upon the peripheral and central relations of the *striae*

---

<sup>\*</sup> Bergmann, G. H. *Neue Untersuchungen ueber die innere Organisation des Gehirns*, Hannover (1831), 8vo.

medullares. Section of the cochlear nerve causes but little degeneration in the striæ [Forel,\* and Onufrowicz †]. That certain of the fibres of the cochlear nerve enter directly into the striæ medullares was shown to be probable by the studies of Baginsky and of Held, and has recently been proved definitely by Marchi's method by Thomas.‡ The experiments of von Monakow proved directly that the lateral lemniscus is in part a continuation of the striæ medullares,\* and the later studies of the same investigator || have made the relations of the striæ still clearer. Thus section of the lateral lemniscus in a newborn cat leads to atrophy of the striæ acusticæ, and of the nucleus nervi cochlearis dorsalis of the opposite side. It is especially the cells of the middle layer of the nucleus nervi cochlearis dorsalis which atrophy on section of the lemniscus lateralis. The fibres can be followed from the dorsal cochlear nucleus around the corpus restiforme on to the floor of the ventricle, whence they plunge down ventrally to pass between the stratum griseum centrale and the nucleus nervi vestibuli lateralis of Deiters to reach the raphe, where they decussate with similar fibres of the opposite side, and pass to the dorsal white matter of the nucleus olivaris superior on that side. Thence they turn upward into the lateral lemniscus. It seems not unlikely that in the striæ medullares are contained fibres which run in both directions; namely, (1) fibres which represent axones of cells situated in the nucleus nervi cochlearis dorsalis, and which pass upward to the lateral lemniscus of the opposite side; and (2) fibres which represent axones arising in the gray matter of the colliculus inferior, and run downward to end in the dorsal cochlear nucleus. Von Kölliker, who has carefully studied the striæ medullares, reserves the term striæ acusticæ for the fibres which represent central connections of the cochlear nerve, and

---

\* Forel, A. Vorläufige Mittheilung ueber den Ursprung des Nervus acusticus. *Neurol. Centralbl.*, Leipz., Bd. iii (1885), S. 101-103.

† Onufrowicz, B. Experimenteller Beitrag zur Kenntniss des Ursprungs des Nervus acusticus des Kaninchens. *Arch. f. Psychiat.*, Berl., Bd. xvi (1885), S. 711-742.

‡ Thomas, A. Les terminaisons centrales de la racine labyrinthique. *Compt. rend Soc. de biol.*, Par., 10. s., t. v. (1898), p. 183.

\* von Monakow, C. *Schweiz. naturf. Versamml. in Genf* (1886), and *Arch. d. sc. phys. et nat.*, Genève, 1886.

|| von Monakow, C. Striæ Acusticæ und untere Schleife. *Arch. f. Psychiat.*, Berl., Bd. xxii (1890), S. 1-26.

the term *striae medullares* for the fibres not concerned in the auditory path. He pictures a large bundle running across the floor of the ventricle in the middle line, then running ventralward in the raphe to become external arcuate fibres which go toward the cerebellum (Fig. 536). It is by no means certain,

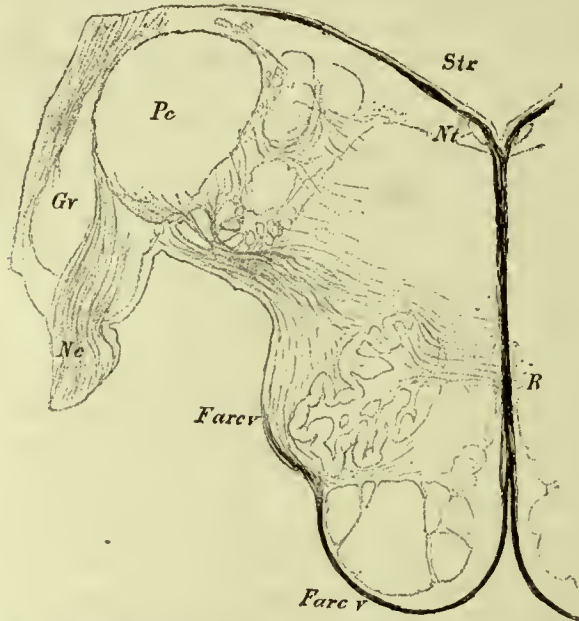


FIG. 536.—Transverse section of the human medulla oblongata. Weigert staining. (After A. von Kölliker, *Handbuch der Gewebelehre*, VI. Aufl., Bd. ii, Leipz., 1896, S. 384, Fig. 556.) *Gr*, nucleus N. cochlearis ventralis; *Ne*, N. cochlearis; *Nt*, nucleus funiculi teretis; *R*, continuation of *striae medullares dextrae et sinistrae* through the raphe and decussation of the same at the bottom of the ventral sulcus; the fibres then go over into *fibræ arcuatæ ventrales* (*Farcv*) lateral from the pyramid and olives as far as the corpus restiforme (*Pc*).

however, that the latter fibres have anything to do with the auditory conduction paths. It seems tolerably certain that the *striae medullares* in man are quite different from those of many animals, for in man there seem to be many more fibres which have to do with the cerebellum than in the cat and rabbit, in which the *striae medullares* seem to be almost exclusively auditory fibres.

The *striae acusticae* have been carefully studied by Golgi's method by Held and by Ramón y Cajal, and the results at which these observers have arrived will be mentioned as soon



as passing notice has been given to some of the other bundles of fibres and gray masses in connection with the auditory conduction path.

The broad bundle of transverse fibres lying in the ventral portion of the tegmental part of the pons near its junction with the medulla and dorsal to the fasciculi pyramidales is known as the *corpus trapezoideum* (Figs. 537 and 538). In the interspaces between the transverse fibres are seen in transverse section many nerve fibres running longitudinally; these represent in the main the continuation upward of the stratum interolivare lemnisci to form the lemniscus medialis of the general sensory path.

Just dorsal to the corpus trapezoideum, somewhat laterally placed, is situated the *nucleus olivaris superior* on each side. In the trapezoid body itself is to be found the *nucleus corporis trapezoidei*. Near by are situated the *nucleus præolivaris* and the *nucleus semilunaris*. The mixture of white and gray matter in the region of the nucleus olivaris superior is often referred to as the "*superior olivary complex*."

As to the nature of the corpus trapezoideum there has been perhaps as much dispute as in the case of the striæ medullares. Nevertheless, there can no longer be any doubt that the fibres of the corpus trapezoideum in the main represent medullated axones of auditory neurones of the second order, the cell bodies of the neurones being situated chiefly in the ventral cochlear nuclei of the two sides. The proof was first brought by Flechsig and von Bechterew, who adduced the results of embryological investigation (study of myelinization), and their position has been confirmed by means of Golgi's method by Held, von K  lliker, and Ram  n y Cajal (*vide infra*), and by means of reconstruction methods (F. Sabin).

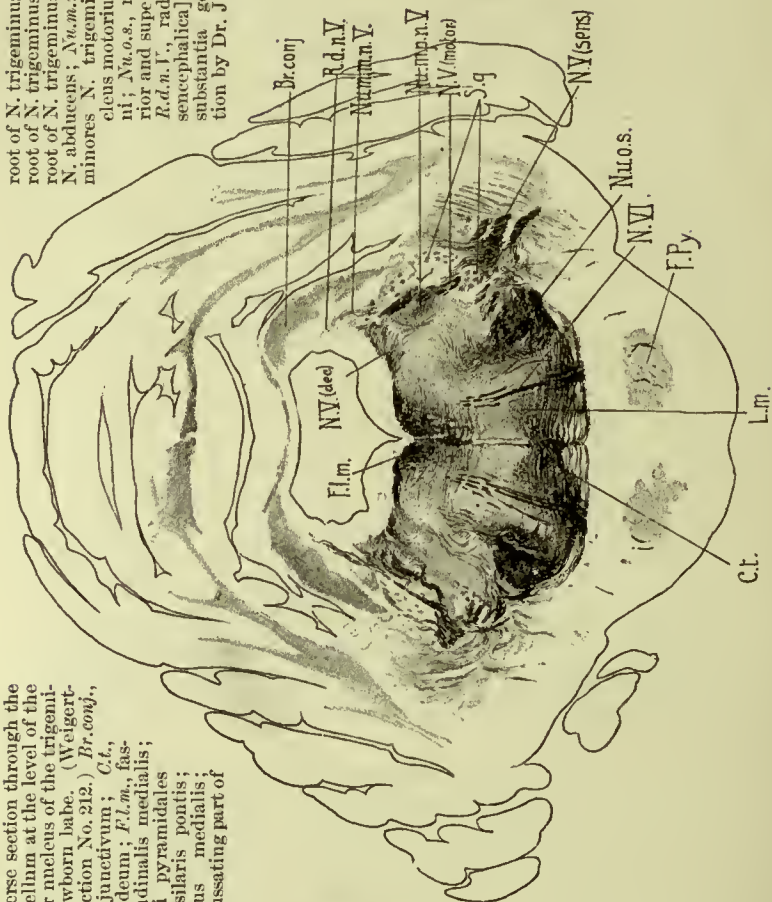
Just above the superior olivary complex begins the *lemniscus lateralis*.\* This bundle passes upward toward the mesencephalon, dorsal and at first somewhat lateral from the lemniscus medialis. The majority of its fibres having reached the colliculus inferior of the corpora quadrigemina, terminate there, although many go on still farther through the brachium quadrigeminum inferius to reach the region of the corpus geniculatum mediale. In sections of the brain of the newborn babe, taken

---

\* *Untere Schleife* of the Germans, *ruban de Reil inf  rieur* of the French.

FIG. 537.—Transverse section through the pons and cerebellum at the level of the principal motor nucleus of the trigeminal nerve. Newborn babe. (Weigert-Pal, series ii, section No. 212.) *Br.conj.*, brachium conjunctivum; *Ct.*, corpus trapezoidum; *F.l.m.*, fasciculus longitudinalis medialis; *F.Py.*, fasciculi pyramidales in the pars basilaris pontis; *L.m.*, lemniscus medialis; *N.V.(dec.)*, decussating part of

root of N. trigeminus; *N.V.(motor)*, motor root of N. trigeminus; *N.V.(sens.)*, sensory root of N. trigeminus; *N.V.L.*, root fibres of N. abducens; *Nu.m.m.n.V.*, nuclei motorii minores N. trigemini; *Nu.m.p.n.V.*, nucleus motorius princeps N. trigemini; *Nu.o.s.*, nucleus olivaris superior and superior olivary complex; *R.d.n.V.*, radix descendens [mesencephalic] N. trigemini; *S.g.*, substantia gelatinosa. (Preparation by Dr. John Hewetson.)



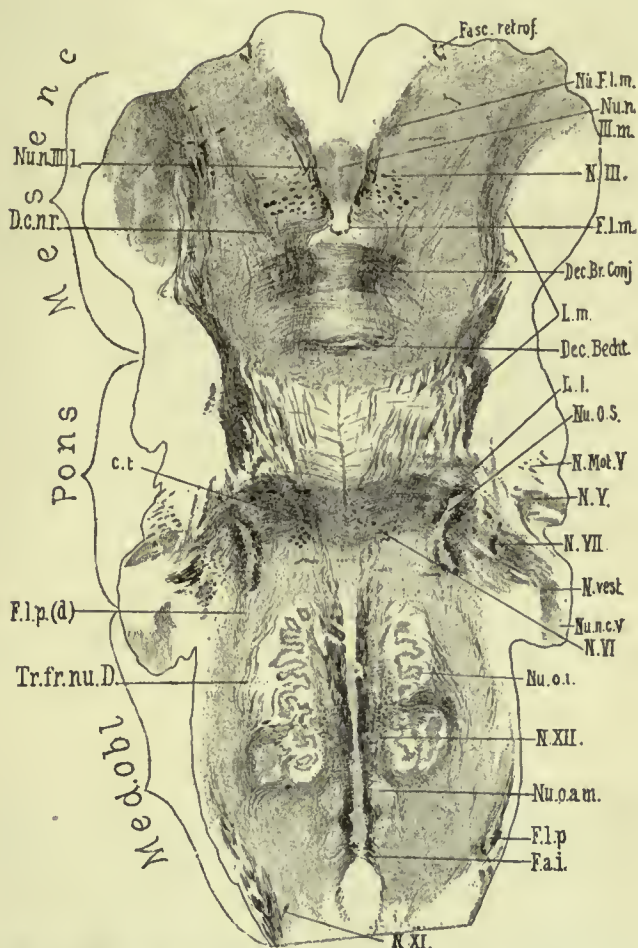


FIG. 538.—Horizontal section through the medulla, pons, and midbrain of a newborn babe. Weigert-Pal staining. Level of dorsal part of corpus trapezoidum and dorsal portion of nucleus olivaris inferior. (Series iii, section No. 122.) *C.t.*, corpus trapezoideum; *Dec.Br.Conj.*, decussatio brachii conjunctivi; *Dec.Becht.*, commissure between Bechterew's nuclei; *D.cn.r.*, dorsal capsule of nucleus ruber; *F.a.i.*, fibrae arcuatae internae; *Fasc. retrof.*, fasciculus retroflexus Meynerti; *F.l.m.*, fasciculus longitudinalis medialis; *F.l.p.*, bundle continuous with the fasciculus lateralis proprius of the cord; *F.l.p.(d)*, dorsal portion of bundle continuous with fasciculus lateralis proprius of the cord; *L.l.*, lemniscus lateralis; *L.m.*, lemniscus medialis; *N.III.*, radix N. oculomotorii; *N.Mot.V.*, motor root of N. trigeminus; *N.V.*, sensory root of N. trigeminus; *N.VI.*, radix N. abducentis; *N.VII.*, radix N. facialis, pars secunda; *N.vest.*, radix N. vestibuli; *N.XI.*, radix N. accessorii; *N.XII.*, radix N. hypoglossi; *Nu.F.l.m.*, nucleus fasciculi longitudinalis medialis, or nucleus commissurae posterioris (*oberer Oculomotoriuskern* of Darkschewitsch); *Nu.n.III.m.*, pars impar of nucleus N. oculomotorii; *Nu.n.III.l.*, pars lateralis of nucleus N. oculomotorii; *Nu.o.s.*, nucleus olivaris superior; *Nu.n.c.V.*, nucleus N. cochleae ventralis; *Nu.o.i.*, nucleus olivaris inferior; *Nu.o.a.m.*, nucleus olivaris accessorius medialis; *Tr.fr.nu.D.*, tract from Deiters' nucleus to the spinal cord. (Preparation by Dr. John Hewetson.)

transversely through the colliculus inferior, the fibres of the lateral lemniscus can be seen surrounding the ventral surface

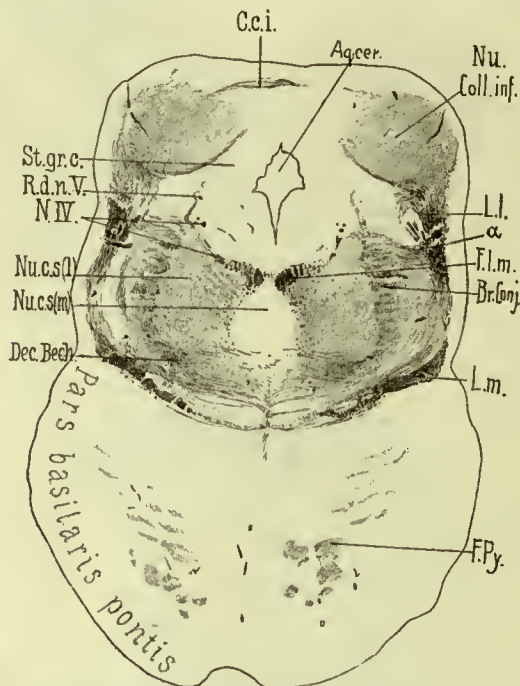


FIG. 539.—Transverse section through brain of newborn babe. Level of colliculi inferiores of corpora quadrigemina. (Weigert-Pal, series ii, section No. 290.) *Aq.cer.*, aqueductus cerebri; *a*, fibres running from lateral lemniscus toward dorsal border of brachium conjunctivum; *Br. Conj.*, brachium conjunctivum; *C.c.i.*, commissure between the colliculi inferiores; *Dec.Bech.*, ventral portion of brachium conjunctivum, which in reality forms a commissure between the superior nuclei of the vestibular nerves of the two sides; *Fl.m.*, fasciculus longitudinalis medialis; *F.Py.*, fasciculi longitudinales pontis (pyramidales); *L.l.*, lemniscus lateralis in large part terminating in the nucleus of the colliculus inferior; *L.m.*, lemniscus medialis; *N.IV.*, N. trochlearis; *Nu.Coll.inf.*, nucleus colliculi inferioris; *Nu.c.s(l)*, nucleus centralis superior, pars lateralis; *Nu.c.s(m)*, nucleus centralis superior, pars medialis; *R.d.n.V.*, radix descendens [mesencephalica] N. trigemini; *St.gr.c.*, stratum griseum centrale. (Preparation by Dr. John Hewetson.)

of the nucleus colliculi inferioris very much like a calyx (Fig. 539).

The *nucleus lemnisci lateralis* is anatomically continuous with the nucleus olivaris superior, although the character of the cells situated in the former is very different from that of the cells in the latter. The nucleus lemnisci lateralis, in reconstruction, forms a long columnar mass, which lies in a trough,



medial from it, made by the fibres of the lateral lemniscus. Ramón y Cajal divides this nucleus into an inferior and a superior part (*vide infra*).

The *colliculus inferior* of the corpora quadrigemina, much better developed in man and higher mammals than in lower forms, presents inside a very much more distinct nucleus than does the colliculus superior. This is known as the nucleus colliculi inferioris. On the lateral surface of the mesencephalon the lateral lemniscus is visible as the so-called trigonum lemnisci. The colliculus inferior is connected with the corpus geniculatum mediale of the diencephalon through the brachium quadrigeminum inferius.

The *corpus geniculatum mediale* forms a small ovoid mass situated medialward from the lateral geniculate body at the junction of the mesencephalon with the diencephalon. On its surface is situated a superficial layer of white substance which stands in relation to the medial root of the tractus opticus (commissura inferior Guddeni), and also with the brachium

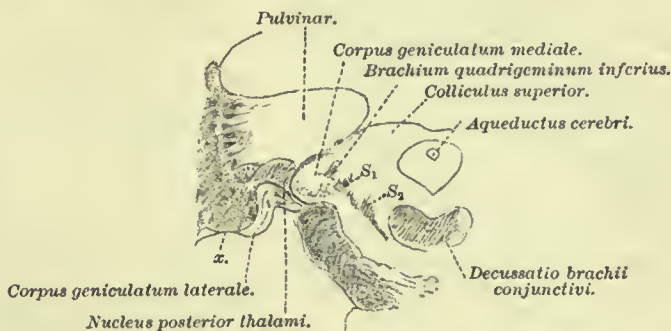


FIG. 540.—Frontal section through a normal human brain at the level of decussatio brachii conjunctivi. (After C. von Monakow, Arch. f. Psychiat., Berl., Bd. xxvii, 1895, Taf. ii, Fig. 10.) *S*<sub>1</sub>, lemniscus superior (*obere Schleife*); *S*<sub>2</sub>, main portion of lemniscus medialis (*Haupttheil der Schleifenschicht*); *x*, lateral white matter of lateral geniculate body.

quadrigeminum inferius from the colliculus inferior (Fig. 540). Inside the capsule of white matter is situated a gray mass known as the nucleus corporis geniculati medialis.

The topographical relations of the nuclei terminales of the cochlear nerve have been described in Chapter XXXVIII, where the peripheral auditory neurones were considered. The difference in character between the nucleus nervi cochlearis

ventralis and the nucleus nervi cochlearis dorsalis were referred to in the same chapter.

The *nucleus nervi cochleæ ventralis* can be subdivided into two parts: the anterior part or head, and the posterior part or

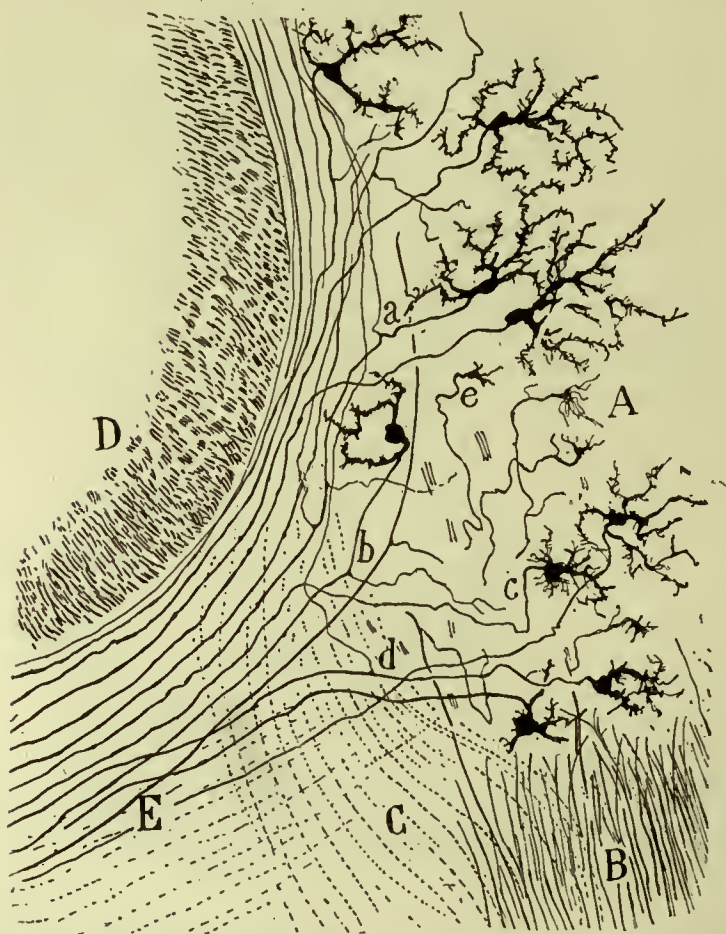

FIG. 541.—Nucleus N. cochleæ ventralis of a newborn cat. (After S. Ramón y Cajal, *Beitrag zum Studium der Medulla Oblongata*, etc., Bresler, Leipz., 1896, S. 81, Fig. 21A.) A, anterior portion of nucleus; B, axones of N. cochleæ; C, axones of N. vestibuli; D, tractus spinalis N. trigemini; E, corpus trapezoideum; a, axone from cell body in nucleus going to corpus trapezoideum and giving off a collateral which runs dorsalward; b, axone with collateral running to the anterior portion of the ventral nucleus; c, unbranched axone going directly into the corpus trapezoideum; d, another axone with collateral passing dorsalward; e, end bulb of axone of N. cochleæ.

tail of the nucleus. The cells in the tail are somewhat less regular and rather larger than those in the head. In both regions they possess numerous dendrites, which branch manifoldly in the gray matter. The medullated axones of the cells situated in the anterior or head portion of the nucleus (Fig. 541) pass forward and medialward in a rather narrow bundle to enter the trapezoid body, where they spread out to form the transverse fibres of this structure. The axones arise usually from the cell body, but occasionally come off from the dendrites at a considerable distance from the cell, a fact to which P. Martin attributes Sala's mistaking certain of the cells of this nucleus for spinal ganglion cells. As Held has shown, not all of the axones from the ventral cochlear nucleus pass ventral to the corpus restiforme into the trapezoid body; a certain number of them, those in the tail portion of the nucleus (Fig. 542), go dorsal to the corpus restiforme to plunge down again medialward and forward to enter the corpus trapezoidum, passing either medial to or lateral from the fibres of the tractus spinalis nervi trigemini. Some of these fibres give off, in passing, collaterals to the nucleus nervi vestibuli lateralis of Deiters. The axones from the nucleus nervi cochlearis ventralis, having arrived in the corpus trapezoidum either by a path ventral to the corpus restiforme or by one dorsal to that body, proceed, as a rule, through this structure to the region of the superior olivary complex of the opposite side, where they turn to run forward in the opposite lemniscus lateralis.\* Not all the axones, however, from the ventral cochlear nucleus go into the lateral lemniscus of the opposite side. Many of them appear to terminate in the nuclei of the superior olivary complex of the same side and more of them in the nuclei of the superior olivary complex of the opposite side. Further, a few in all probability run to terminate in the nucleus nervi cochlearis ventralis of the opposite side, for, besides the terminal fibres of the cochlear nerve, there are to be made out within each ventral cochlear nucleus terminal axones arriving from the trapezoid body.

---

\*This is difficult to bring into accord with von Monakow's statement that after section of the lateral lemniscus in young animals there is no atrophy or degeneration of the trapezoid body. The conflicting results of the various investigators are carefully compared and subjected to a searching criticism in the article of Held, 1891.

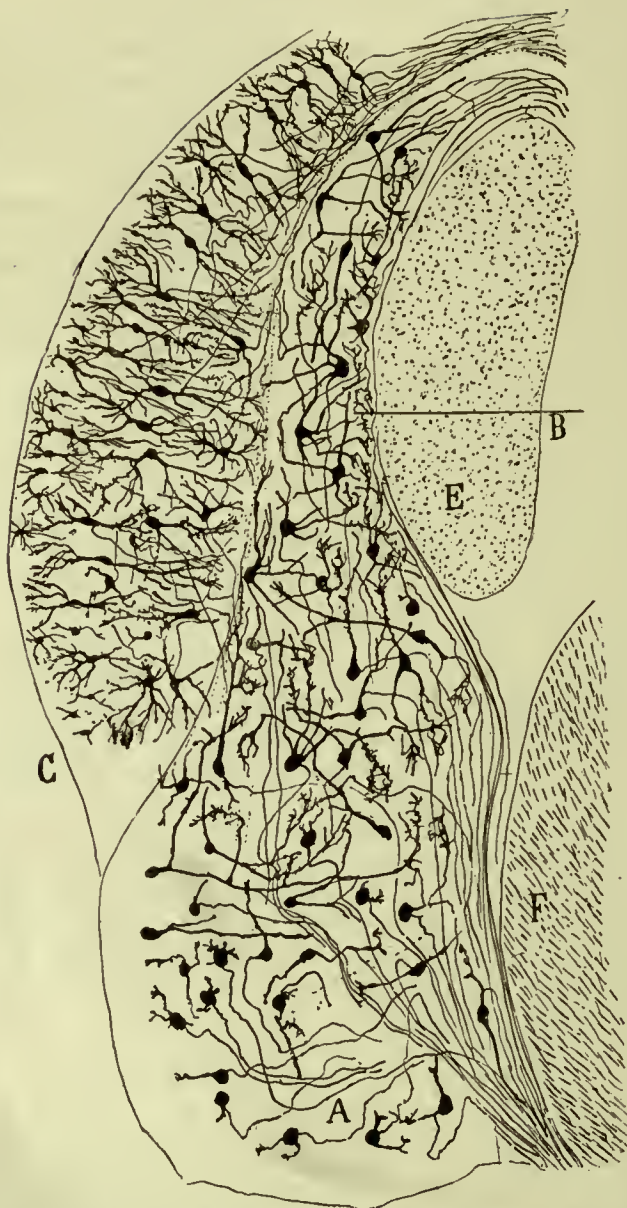


FIG. 542.—Nuclei terminales of the *N. cochleæ* of a four-day-old rabbit. (After S. Ramón y Cajal, *Beitrag zum Studium der Medulla Oblongata*, Bresler, Leipz., 1896, S. 84, Fig. 22.) *A*, nucleus *N. cochleæ* ventralis; *B*, caudal portion of ventral nucleus; *C*, nucleus *N. cochleæ* dorsalis (tuberculum acusticum); *E*, corpus restiforme; *F*, tractus spinalis *N. trigemini*.



The *nucleus nervi cochleæ dorsalis*, often spoken of as the tuberculum acusticum, is a leaflike mass of gray matter wrapped about the dorso-lateral surface of the corpus restiforme. In transverse section through the rhombencephalon this nucleus appears to be divided into three zones, of which the middle one is almost entirely free from medullated fibres. The medullated axones of the cells situated here all pass dorsal to the corpus restiforme, but the fibres can be divided into two groups: (a) those which enter the striæ medullares to pass to the middle line, there to decussate with similar fibres from the opposite side and to dip down and become involved in the superior olivary complex, the impulses ultimately finding their further course forward in all probability through the fibres of the lemniscus lateralis, and (b) those which, instead of entering the striæ medullares, plunge directly downward to arrive in the superior olivary complex, the trapezoid body, or the lateral lemniscus. The former group represents the dorsal path of Held, and the latter group the ventral path of Held from the dorsal cochlear nucleus.

It is thus seen that from both the ventral cochlear nucleus and the dorsal cochlear nucleus we have to deal with a dorsal and a ventral path. The exact terminations of the axones has not been clearly made out for any one of these paths. How many terminate in the gray matter of the superior olivary complex of the same side or of the opposite side is not yet clear; and how many fibres, if any, are directly continued on into the lemniscus lateralis of the opposite side or of the same side we do not yet know. It seems certain that the majority of the impulses coming out from the nuclei terminales of the cochlear nerve on one side ultimately travel forward directly or indirectly through the lemniscus lateralis of the opposite side. That a certain proportion of the impulses pass up on the same side seems, however, to be generally accepted.\*

The best general description of the *nucleus olivaris superior* since the articles of J. Lockhart Clarke, Schröder van der Kolk, Dean, and Spitzka, is that of von Kölliker.† The nucleus

---

\* For a report on an interesting case of pathological implication of the nuclei of the cochlear nerve the reader is referred to the article by Adolf Meyer, Anatomical Findings in a Case of Facial Paralysis of Ten Days Duration in a General Paralytic, with Remarks on the Termination of the "Auditory" Nerves. J. Exper. Med., N. Y., vol. ii (1897), pp. 607-611.

† von Kölliker, *op. cit.*, S. 263 ff.

is much smaller in human beings than in animals. Flechsig, in his lectures during the summer semester of 1895, suggested that the nucleus olivaris superior might be concerned with the innervation of the muscles of the ear, inasmuch as it is much larger in animals that have large, very movable ears. It is described by von Kölliker as consisting of three portions: a larger medial portion, and two lateral cylindrical masses. Its situation in the pons is ventro-medial as regards the nucleus nervi facialis. It is surrounded by and partly imbedded in the fibres of the corpus trapezoideum. The structure is most easily studied in the medulla of the cat or rabbit; according to Spitzka, it is highly developed in cetaceans.

In the nucleus olivaris superior are situated a very large number of nerve cells which send their axones in various directions, while the nucleus receives terminals and collaterals in enormous numbers. The attempt has been made to establish the relations of the nucleus to other portions of the nervous system by studies with the embryological method of Flechsig, with secondary degenerations, and with the method of Golgi. The researches of Flechsig and von Bechterew show a correspondence in myelinization of a portion of the white matter of the superior olive to that of the trapezoid body and the lateral lemniscus. Von Bechterew has further postulated (from studies of myelinization) a connection of the nucleus olivaris superior with the nucleus fastigii through a bundle which passes through the medial part of the corpus restiforme. He has also described a connection between the nucleus olivaris superior and the nucleus nervi abducentis by means of a bundle of fibres, which passes out of the dorsal portion of the superior olivary nucleus, runs parallel to the root fibres of the nervus facialis, and goes to terminate in the nucleus nervi abducentis. This bundle is known as the peduncle of the nucleus olivaris superior, and is shown in its first portion at least in the accompanying figure (Fig. 543) taken from von Kölliker's text-book.

According to Baginsky, if the cochlea be destroyed in a newborn animal there results atrophy and disappearance of the cells and white matter of the nucleus olivaris superior of the same side. Von Monakow found that, on cutting the lateral lemniscus on the right side in the cat or dog, the dorsal white matter of the right upper olive atrophied and disappeared. Not all of the white matter, however, of the upper olive stands

in relation to the lateral lemniscus, and, what is more, section of the lateral lemniscus leads to atrophy and degeneration of only a portion of the cells in the nucleus olivaris superior. Von Monakow, therefore, holds that the nucleus olivaris superior stands only in part in relation to the lemniscus lateralis of the opposite side, the fibres concerned passing through the dorsal white matter of the olive and occupying the dorsal field in cross sections of the lateral lemniscus.\*

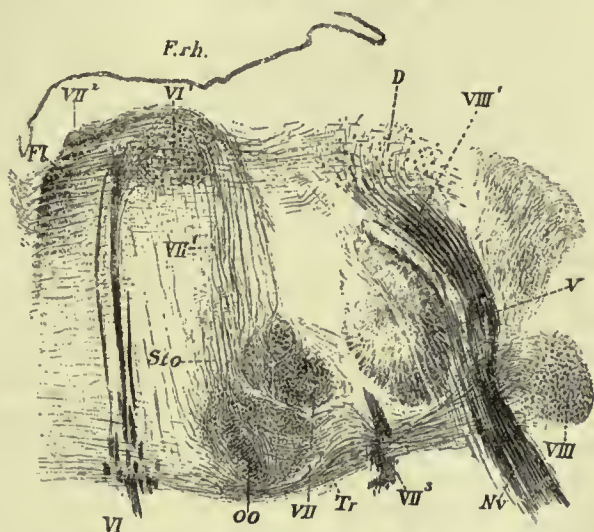


FIG. 543.—Cross section through the dorsal part of the pons at the level of the nucleus N. cochleæ ventralis. (After A. von Kölliker, *Handbuch der Gewebelehre*, VI. Aufl., Bd. ii, Leipz., 1896, S. 263, Fig. 483.) *D*, nucleus N. vestibuli lateralis (Deiters); *Fl*, fasciculus longitudinalis medialis; *Frh*, ventriculus quartus; *oo*, nucleus olivaris superior; *Sto*, peduncle of nucleus olivaris superior; *Tr*, corpus trapezoideum; *V*, tractus spinalis N. trigemini; *Nr*, N. vestibuli; *VI*, radix N. abducantis; *VI¹*, nucleus N. abducantis; *VII*, nucleus N. facialis; *VII¹*, radix N. facialis, pars prima; *VII²*, radix N. facialis genu internum; *VII³*, radix N. facialis, pars secunda; *VIII*, nucleus N. cochleæ ventralis; *VIII¹*, radix descendens N. vestibuli.

The studies undertaken by the Golgi method have led to somewhat more satisfactory results in this region. These have been carried out by Held, von Kölliker, and Ramón y Cajal. Without going into a detailed description, the following general statements may be made: The cell bodies in the nucleus olivaris superior resemble a good deal in type those of the nucle-

\* von Monakow, C. *Striæ Acusticæ und untere Schleife*. *Arch. f. Psychiat.*, Berl., Bd. xxii (1890), S. 1-26.

us olivaris inferior and those of the nucleus dentatus of the cerebellum. They possess numerous much-branched dendrites, which are turned toward the interior of the nucleus, the axones being directed in the main toward the periphery of the nucleus. The axones of the cells, according to Ramón y Cajal, pass in three directions: (1) The majority of them, after giving off collaterals in the nucleus itself, pass to the dorsal surface of the nucleus, and then turn to run vertically (either by bending or by bifurcation) in a longitudinal bundle, which is continuous with the lemniscus lateralis of the same side. (2) A certain number of axones much curved inside the nucleus leave the latter at its lateral border to enter the trapezoid body, where they can be followed nearly as far as the nucleus nervi cochlearis ventralis. Held describes similar axones as actually terminating inside the ventral cochlear nucleus. (3) Other axones arising in the nucleus olivaris superior pass out at the medial side of the nucleus to enter the plexus of the nucleus præolivaris, there to mingle with the fibres of the trapezoid body. Further, according to Held, axones can be followed from the cells of the nucleus olivaris superior directly into the nucleus nervi abducentis, these axones doubtless corresponding to the bundle which has long been described in Weigert preparations as the peduncle of the nucleus olivaris superior.\* It is not unlikely that such a path is of importance in connection with the acoustic eye muscle reflexes.

Terminating in the nucleus olivaris superior can be made out many fibres from the corpus trapezoideum. Many of these are doubtless terminal fibres, but the main mass of them consists of an enormous number of collaterals given off almost at a right angle from the transverse fibres of the corpus trapezoidenm. These terminals and collaterals, together with the terminals and collaterals which enter the nucleus from the formatio reticularis, and the collaterals from the axones arising from the cells in the nucleus itself, form a dense plexus of fibres as complicated, perhaps, as any met within the central nervous system. The accompanying figure illustrates well some of these relations (Fig. 544).

The *nucleus corporis trapezoidei* is also better developed in other mammals than in man, but can nearly always be distinctly

---

\* *Stiel der kleinen Olive* of the Germans.



made out. It is situated between the nucleus olivaris superior and the root fibres of the nervus abducens, the cells which compose it lying in among the fibres of the corpus trapezoideum. In this nucleus terminate many collaterals from the transverse fibres of the corpus trapezoideum, and a certain number of terminal fibres which come from the region of the raphe. In ad-

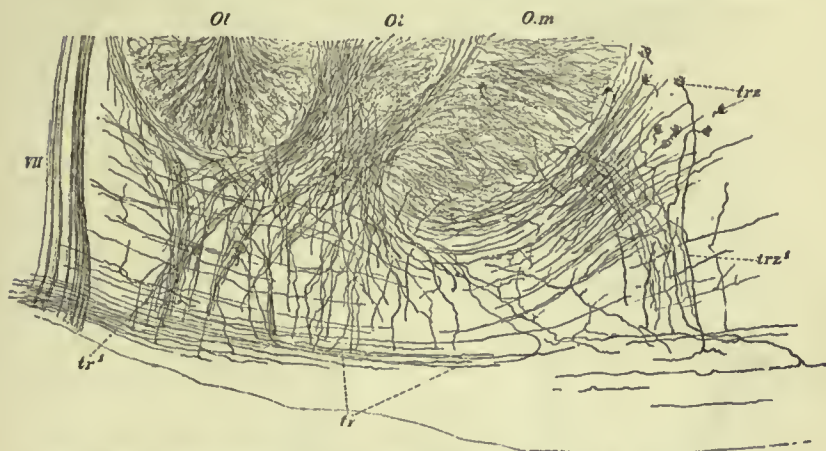


FIG. 544.—Transverse section through the ventral part of the nucleus olivaris superior with the adjacent fibres of the corpus trapezoideum of a newborn cat. Method of Golgi. (After A. von Kölliker, *Handbuch der Gewebelehre*, VI. Aufl., Bd. ii, Leipz., 1896, S. 267, Fig. 486.) VII, radix N. facialis, pars secunda; Ol, lateral lobe of nucleus olivaris inferior; O.m, medial lobe; tr, axones in corpus trapezoideum; tr¹, bundles of collaterals from trapezoid axones passing into nucleus olivaris inferior; trz, cells of nucleus corporis trapezoidei; trz¹, axones to the same.

dition there terminate in this nucleus a certain number of rather large thick axones which, on coming into contact with the cell bodies situated in the nucleus, expand into those peculiar end-plaques or acoustic calyces which were discovered by Held, and which have been so carefully studied by him and by Ramón y Cajal. The latter fibres come from the region of the raphe, possibly from the nucleus nervi cochleæ ventralis (Ramón y Cajal), or possibly from the nucleus corporis trapezoidei of the opposite side (Held); they enter the nucleus of the trapezoid body, where the axone widens and spreads out to form the yellowish, almost homogeneous, cup-shaped expansion, which fuses with a spherical cell body inside the nucleus. Ramón y Cajal has compared this plaque to the *Tastmenisken* (of Merkel), and to the ivy-shaped endings which Ranvier has

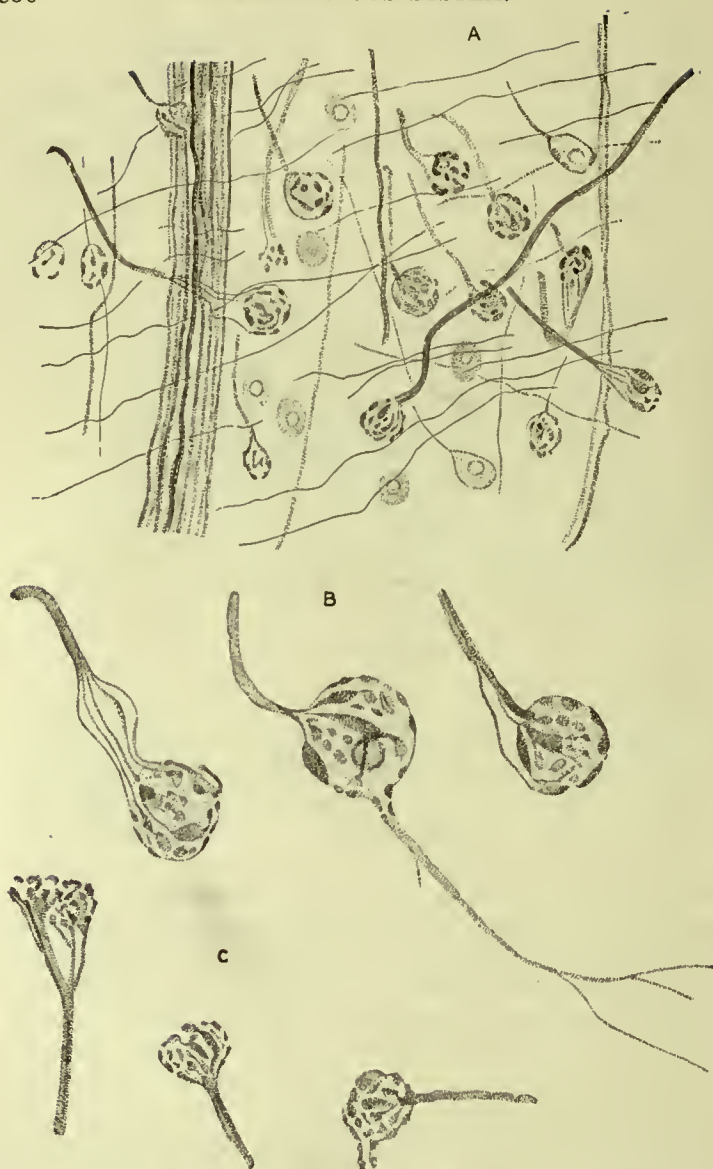


FIG. 545.—Terminals of axones upon the cells in the nucleus corporis trapezoidalis. (After S. Meyer, *Arch. f. mikr. Anat.*, Bonn, Bd. xlvii, 1896, Taf. xxxviii, Figs. 1, 2, 3.) A. From a section through the region of exit of the N. abducens of a newborn guinea-pig; methylene-blue staining. Between the axones of the N. abducens are seen numerous axones terminating upon the cells of the nucleus of the trapezoid body. B. End apparatus from another section of the same series. C. The same structures stained by the slow Golgi method from a rabbit several weeks old. Only a few of the endings are shown upon each cell in all the figures.

described in the skin. These axones terminating in acoustic calyces on the cells of the trapezoid nucleus are much larger than the axones arising from the cells of the nucleus. It is possible to stain them with hæmatoxylin and carmine in ordinary sections (Ramón y Cajal), and recently they have been stained in the newborn guinea-pig, rat, and rabbit with methylene-blue (Semi Meyer)\* (Fig. 545). Held has recently undertaken again the study of these structures by the most careful methods, and has utilized his results to support his doctrine of conerescence as one mode of interneuronal relation† (Figs. 546 and 547).

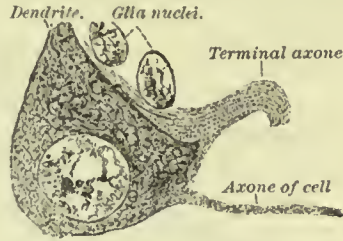


FIG. 546.—Cell from nucleus corporis trapezoidei of newborn cat. (After H. Held, Arch. f. Anat. u. Physiol., Anat. Abth., 1897, Taf. xii, Fig. 2.) Fixation with van Gehuchten's mixture; staining with iron hæmatoxylin. The large axone is seen terminating upon the cell and exhibiting what Held calls conerescence relation. The small axone with its axone hillock is arising from the cell body shown in the figure.

Under the designation *nucleus præolivaris*, Ramón y Cajal includes the mass of cells lying ventral from the nucleus olivaris superior and lateral from the nucleus corporis trapezoidei. This nucleus is included by most writers in the nucleus of the trapezoid body, but its cells are much larger and are of different shape. The dendrites are large and manifoldly branched. The axones pass into the lateral lemniscus in its medial part (Fig. 548). A few axones pass lateralward, perhaps, to form an association path between the nucleus præolivaris and the nuclei terminales of the cochlear nerve. The curious calyxlike endings characteristic of the nucleus corporis trapezoidei are not found in the nucleus præolivaris.

Still another nucleus in this region is defined by Ramón y Cajal. He describes as the *nucleus semilunaris* a mass of nerve cells situated just ventral to the convexity of the nucleus oli-

\* Meyer, S. Ueber eine Verbindungsweise der Neuronen; nebst Mittheilungen ueber die Technik und die Erfolge der Methode der subcutanen Methylenblauinjection. Arch. f. mikr. Anat., Bonn, Bd. xlvii (1896), S. 734-748.

† Held, H. Beiträge zur Structur der Nervenzellen und ihrer Fortsätze. Zweite Abhandlung. Arch. f. Anat. u. Physiol., Anat. Abth., Leipz. (1897), H. iii and iv, S. 257 ff.

varis superior, embracing its ventral surface (Fig. 549). The cells in this crescentic mass are stellate, triangular, or spindle-shaped; they are separated from one another by interspaces in

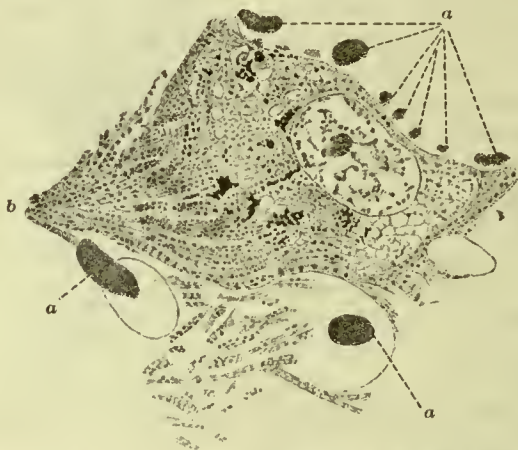

FIG. 547.—Cell of the nucleus corporis trapezoidi of an adult rabbit. Fixation with van Gehuchten's mixture; paraffin section 1.5 microns thick; erythrosin methylene-blue staining. (After H. Held, Arch. f. Anat. u. Physiol., Anat. Abth., Leipz., 1897, Taf. x, Fig. 3.) The axis cylinders (*a*) which go by the cell are stained homogeneously; the fibres (*b*) terminating in the cell contain large numbers of isolated neurosomes; the lower border of the cell inclosed by the terminal axone shows very distinctly a most intimate union between the axis-cylinder protoplasm and the ground substance of the cell body, since here the same plasma layer is common to both. On the right-hand side the cytospongium is wide-meshed owing to coarse vacuolization on account of which the axis-cylinder terminal looks to be mere independent from the rest of the cell mass.

which an enormous number of collaterals are distributed. The axones of the cells situated here are extremely difficult to follow, but appear to run lateralward to become associated with other fibres of the corpus trapezoidum. The nucleus is characterized definitely by the entrance into it of two or more bundles of collaterals of such extraordinary delicacy that Ramón y Cajal considers them to be without doubt the finest in the whole nervous system (*a* in the figure). There are usually two such bundles, the lateral being somewhat more voluminous than the medial bundle. They have their origin in the more superficial and delicate axones of the corpus trapezoidum, from which they come off almost at a right angle. The terminal branches of these collaterals inside the nucleus semilunaris are so extremely delicate and so closely interwoven that they can be



made out only by means of the highest powers of the microscope. In Golgi preparations they are so fine that they do not stain of a black color, but look yellowish, and resemble minute pearly threads. These bundles of collaterals extending between the trapezoid body and the nucleus semilunaris are easily visible in Weigert-Pal preparations. They are often mistaken for collaterals which go to the nucleus olivaris superior, but Ramón y Cajal insists that the latter are quite different from those under discussion, inasmuch as they are much coarser, and have their origin in deeper trapezoid fibres (*C* in the figure).

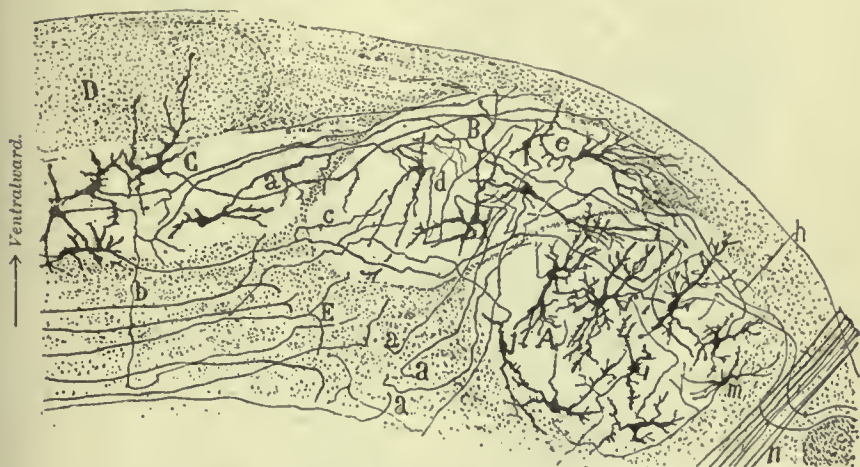

FIG. 548.—Transverse section through the region of the corpus trapezoideum of a newborn mouse. The upper border of the figure represents the ventral surface. (After S. Ramón y Cajal, *Beitrag zum Studium der Medulla Oblongata*, Bresler, Leipz., 1896, S. 88, Fig. 23.) *A*, nucleus olivaris superior; *B*, nucleus preolivaris; *C*, nucleus corporis trapezoidei; *D*, fasciculi pyramidales in cross section; *E*, central acoustic path or place where the axones of the trapezoid body turn to run vertically into the lemniscus lateralis; *a*, cell of nucleus of trapezoid body the axone of which gives off collaterals to this nucleus and to the nucleus preolivaris; *b*, another analogous fibre which bifurcates; *c*, collateral from another fibre of the same sort for the nucleus preolivaris; *d*, cell of the nucleus preolivaris the axone of which appears to go lateralward; *e*, cells the axones of which go to the white substance to form an ascending path (*a, a, a*); *f, m, j*, cells of the nucleus olivaris superior; *n*, radix N. facialis, pars secunda.

From what has gone before, it will be seen that the *corpus trapezoideum* is a very complex structure containing medullated axones of very different origin, and probably of very different termination. Von Kölliker thinks it probable that the majority of the transverse fibres represent medullated axones arising from cells situated in the ventral cochlear nuclei of the two

sides. But, in addition, there are undoubtedly fibres from the nucleus nervi cochlearis dorsalis of each side, from the nucleus corporis trapezoidei, from the nucleus olivaris superior, from




FIG. 549.—Nucleus semilunaris of a newborn cat; method of Golgi. (After S. Ramón y Cajal, *Beitrag zum Studium der Medulla Oblongata*, etc., Bresler, Leipz., 1896, S. 90, Fig. 23a.) *A*, main portion of nucleus semilunaris; *B*, nucleus olivaris superior; *C*, coarse collaterals which go to the nucleus olivaris superior; *a*, bundle of very fine collaterals which go to the nucleus semilunaris; *b*, delicate superficial fibres of the corpus trapezoideum; *c*, terminals of axones in the nucleus olivaris superior; *d*, spindle cells of the nucleus olivaris superior, the axones of which go into the hilus.

the nucleus præolivaris, and possibly from the nucleus semilunaris.

The finer structure of the *lateral lemniscus* must next be

considered. The medullated fibres of which it consists are separated from one another by islands of gray matter. The gray masses form two main nuclei: the nucleus lemnisci lateralis inferior, which is directly or almost directly continuous with the nucleus olivaris inferior, and which extends for a considerable distance upward, and the so-called nucleus lemnisci lateralis superior, composed of a number of gray masses more or less separated from one another, although with high powers minute columns of cells can be seen connecting this nucleus with the lower one.

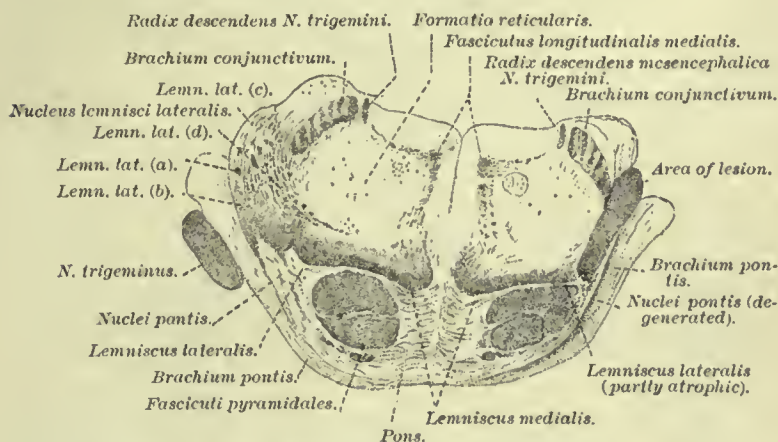


FIG. 550.—Cat's brain after section of lemniscus lateralis on right side; frontal section through the pons just inferior to the colliculus superior. (After C. von Monakow, Arch. f. Psychiat., Berl., Bd. xxii, 1890, Taf. i, Fig. 1.)

The most careful studies of secondary degeneration following lesions of the lateral lemniscus are those of von Monakow.\* He concludes from his experiments that the fibres of the lateral lemniscus can be divided into five portions:

- (1) A portion connected with the striæ acusticæ (Fig. 550, *c*).
- (2) A portion connected with the nucleus olivaris superior (Fig. 550, *c*).
- (3) A portion connected with the ventral decussation of the tegmentum (Fig. 550, *d*).
- (4) A portion connected with the nucleus lemnisci lateralis (Fig. 550, *a*).
- (5) A portion consisting of very short fibres (Fig. 550, *b*).

\* von Monakow, C. *Op. cit.*



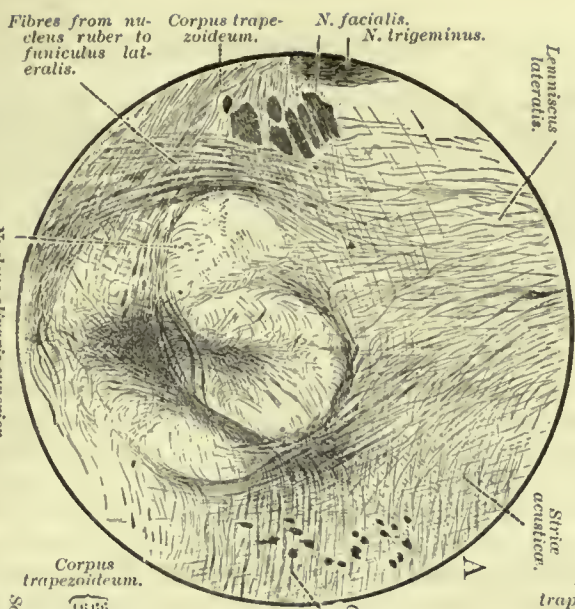
The first portion, that connected with the *striae acusticae*, he thinks, serves to connect the nuclei terminales of the cochlear nerve with the cerebrum. The region of the lateral lemniscus occupied by these fibres is shown in the diagram (Fig. 550).

Von Monakow's statements regarding the portion of the lateral lemniscus connected with the ventral decussation of the tegmentum are not very satisfactory. He believes, however, that it is the medial portion of the lateral lemniscus which is concerned. Later studies have, however, shown the correctness of this view of von Monakow, and in Chapters LVII and LVIII it will be pointed out that the fibres here mentioned are the axones of cells situated in the nucleus ruber. They descend to the spinal cord.

The fibres in the lateral lemniscus, which are connected with the nucleus olivaris superior, occupy the dorsal portion of the lateral lemniscus, being mixed with the portion of the lateral lemniscus which is connected with the *striae acusticae*. The bundle in the lateral lemniscus connected with the nucleus lemnisci lateralis is situated in its central portion. The fifth portion of the lateral lemniscus described by von Monakow as consisting of short fibres is probably concerned in connecting neighboring masses of gray matter with one another.

The lateral lemniscus has been studied by Golgi's method by Held, von K  lliker, and Ram  n y Cajal. Held believes that the medullated axones of the lateral lemniscus are derived from the nucleus nervi cochle   ventralis of the same side and of the opposite side, from the nucleus olivaris superior of both sides, from the nucleus corporis trapezoidei of both sides, and from the nucleus nervi cochle   dorsalis of both sides by way of the *striae acusticae*. His views concerning the relations here are well shown in his diagram (Fig. 551). Von K  lliker confirms these results in part, and states that he finds fibres from the nucleus nervi cochle   ventralis going to the lateral lemniscus of the opposite side to form its ventral part; further, fibres from the nucleus olivaris superior and nucleus lemnisci lateralis of the same side. He also confirms von Monakow's findings of the relations of fibres in the ventral decussation of the tegmentum to the lateral lemniscus. The *striae acusticae*, he believes, undoubtedly help to form the lateral lemniscus in mammals.





- Fibres from nucleus olivaris superior to lemniscus lateralis.
- Fibres from the nucleus nervi cochlear dorsalis of one side to the opposite lemniscus lateralis (striae opticae).
- Fibres from the nucleus X. cochleae ventralis of one side to the opposite lemniscus lateralis.
- Dorsal path from the nucleus X. cochleae ventralis to lemniscus lateralis.

Nucleus olivaris superior.

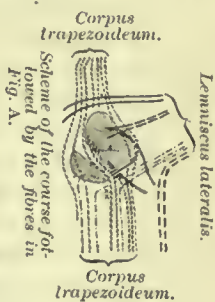
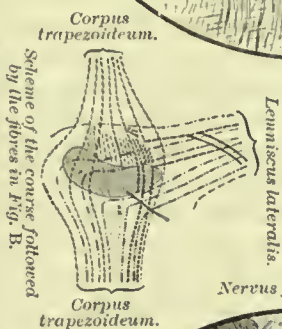
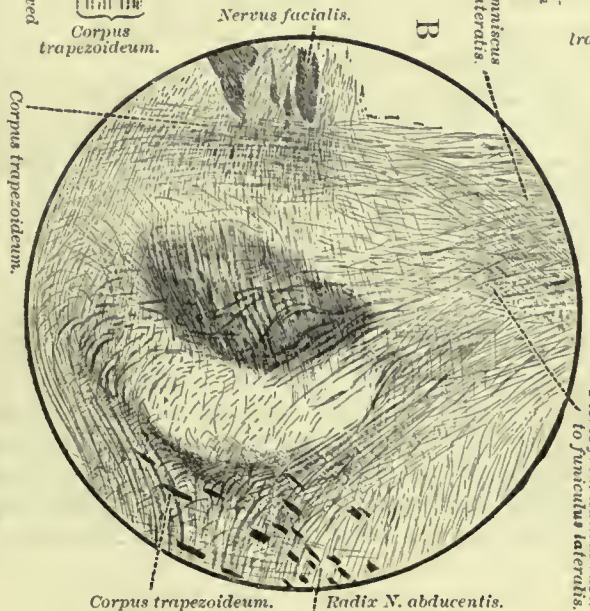

Fig. A.



- Ventral paths from the nuclei X. cochleae.
- Fibres from the cochlear nuclei of one side to the opposite lemniscus lateralis.
- Fibres from the nucleus olivaris superior to the nucleus X. abducentis and to the funiculus lateralis.
- Fibres from the nucleus ruber to the funiculus lateralis.

Corpus trapezoideum.

Scheme of the course followed by the fibres in Fig. B.

Corpus trapezoideum.

FIG. 551.—Transition of the corpus trapezoidum into the lemniscus lateralis. (After H. Held, Arch. f. Anat. u. Physiol., Anat. Abth., 1891, Taf. xvii, Figs. 13 and 14.) At X and XX one sees the transverse fibres of the corpus trapezoidum turn often at a right angle directly into the lemniscus lateralis. B is at a level 0.28 mm. anterior to that of A. The course of the fibres will be easily understood if the accompanying schemata be studied. One sees the central paths, originally running separately from the nuclei terminales of the N. cochlear, finally unite and pass forward in the lateral lemniscus.

How many fibres of the lateral lemniscus are ascending axones arising in nuclei lower down, and how many represent descending axones, is not yet fully decided. Certainly the majority of fibres ascend and represent an auditory conduction path. That some fibres descend seems certain, from the studies of Held, but further investigation is necessary to determine their exact number, their origin, and their terminal relations.

The studies of Ramón y Cajal with regard to the *nuclei of the lateral lemniscus* are helpful. He holds that while the lower nucleus of the lateral lemniscus is anatomically continuous with the nucleus olivaris superior, it is nevertheless to be sharply separated from the latter nucleus, for its constituent cells are very different in shape, and the axones are entirely different in their distribution. The cells in the lower nucleus of the lateral lemniscus are large, stellate, or spindle-shaped, and possess long, smooth dendrites, which are much branched. The axones of these cells, in contradiction to Held, Ramón y Cajal asserts, do not ascend; at any rate, in the majority of his preparations he found that they passed medialward, appearing to run in the direction of the raphe, although he was not able to follow the fibres to their termination. The cells of the lateral lemniscus come into conduction relation with an enormous number of collaterals, which come off from the fibres of the lateral lemniscus as they pass by, a fact which has been confirmed both by Held and Ramón y Cajal.

The cells of the upper nucleus of the lateral lemniscus are more scattered. Ramón y Cajal states that in general they are spindle-shaped with polar dendrites, which extend transversely. Here again the axones almost all go medialward, and, he believes, decussate in the middle line in order to help to form the ventral decussation of the tegmentum.

There has been much dispute as to the nature of the transverse bundles of rather fine fibres, which are easily visible in Weigert preparations from the newborn babe (Fig. 552), extending between the lateral lemniscus and the region of the brachium conjunctivum. Held assumed that these fibres represented medullated axones which pass from the lateral lemniscus to enter the brachium conjunctivum, and to follow a course farther cerebralward, similar to that of the fibres of the latter bundle. This view has been opposed by von Bechterew, von

Kölliker, and Ramón y Cajal. According to von Bechterew,\* these fibres pass to the lateral surface of the stratum griseum

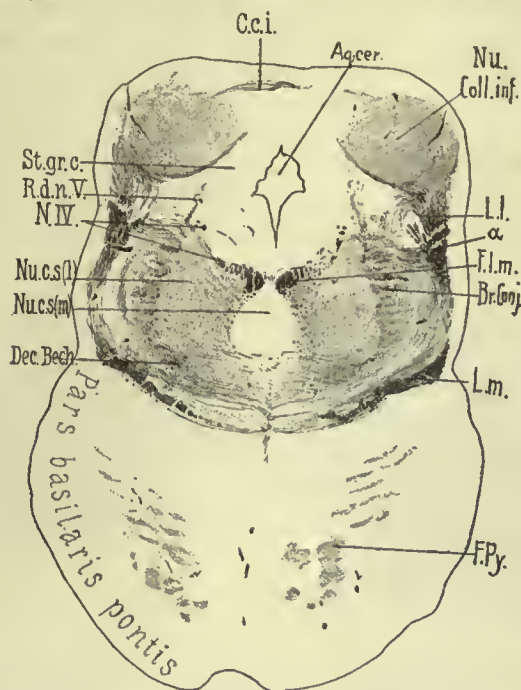


FIG. 552.—Transverse section through brain of newborn babe. Level of colliculi inferiores of corpora quadrigemina. (Weigert-Pal, series ii, section No. 290.) *Aq.cer.*, aqueductus cerebri; *α*, fibres running from lateral lemniscus toward dorsal border of brachium conjunctivum; *Br. Conj.*, brachium conjunctivum; *C.c.i.*, commissure between the colliculi inferiores; *Dec.Bech.*, ventral portion of brachium conjunctivum, which in reality forms a commissure between the superior nuclei of the vestibular nerves of the two sides; *F.l.m.*, fasciculus longitudinalis medialis; *F.Py.*, fasciculi longitudinales pontis (pyramidales); *L.l.*, lemniscus lateralis in large part terminating in the nucleus of the colliculus inferior; *L.m.*, lemniscus medialis; *N.IV.*, N. trochlearis; *Nu.Coll.inf.*, nucleus colliculi inferioris; *Nu.c.s.(l.)*, nucleus centralis superior, pars lateralis; *Nu.c.s.(m.)*, nucleus centralis superior, pars medialis; *R.d.n.V.*, radix descendens [mesencephalica] N. trigemini; *St.gr.c.*, stratum griseum centrale. (Preparation by Dr. John Hewetson.)

centrale, and thence run along it toward the raphe, where they vanish from view. Von Kölliker denies any direct relation of these fibres to the brachium conjunctivum, and, on the contrary, assumes that they represent arcuate fibres. He describes them as passing beyond the brachium conjunctivum, and then bend-

\* von Bechterew. *Die Leitungsbahnen im Gehirn und Rückenmark* (1894), S. 113.



ing down either lateral or medial from the mesencephalic root of the nervus trigeminus, in order to form definite fibræ arcuatæ internæ (Fig. 553). Ramón y Cajal could not find these fibres described by Held, nor could he find any cells in the nuclei of the lateral lemniscus, which sent axones downward, such as Held describes. We have frequently, in Prof. Mall's laboratory in Baltimore, observed fibres extending from the region of the lateral lemniscus to the region of the brachium conjunctivum, but have not been able, thus far, to come to any positive conclusion regarding their ultimate distribution.

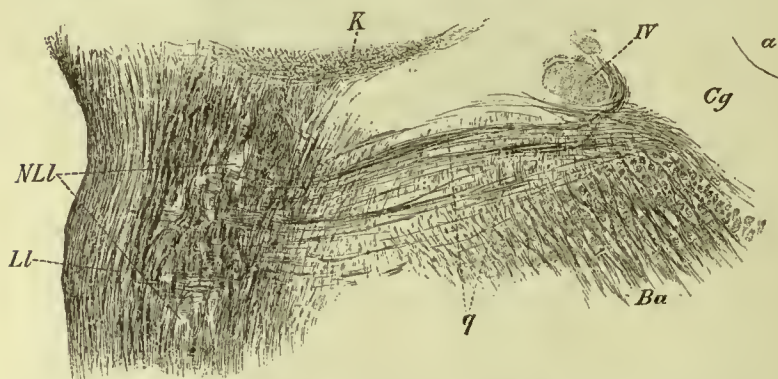


FIG. 553.—Part of a transverse section of the spinal extremity of the colliculus inferior of the cat. (After A. von Kölliker, *Handbuch de Gewebelehre*, etc., VI. Aufl., Bd. ii, Leipz., 1896, S. 595, Fig. 564.) *α*, aqueductus cerebri; *Ba*, brachium conjunctivum; *Cg*, stratum griseum centrale; *K*, ventral limit of nucleus colliculi inferioris; *NLL*, nucleus lemnisci lateralis; *LL*, lemniscus lateralis; *q*, fibres running from region of lemniscus lateralis to become internal arcuate fibres; *IV*, N. trochlearis.

The lemniscus lateralis, having arrived at the inferior border of the mesencephalon, passes in large part dorsalward, as has been stated, to plunge into the colliculus inferior of the corpora quadrigemina (Fig. 554). At this level the reciprocal relations of the lemniscus lateralis, the lemniscus medialis, and the brachium conjunctivum, become much altered. In the pons the lemniscus lateralis is situated close to the lemniscus medialis, the fibres of the one bundle going over into the other without sharp limit. But from this point on the two bundles are easily distinguishable from one another, inasmuch as the lemniscus medialis continues its course without marked change of direction, while the lemniscus lateralis turns sharply dorsalward and enters, at least in large part, the nucleus col-



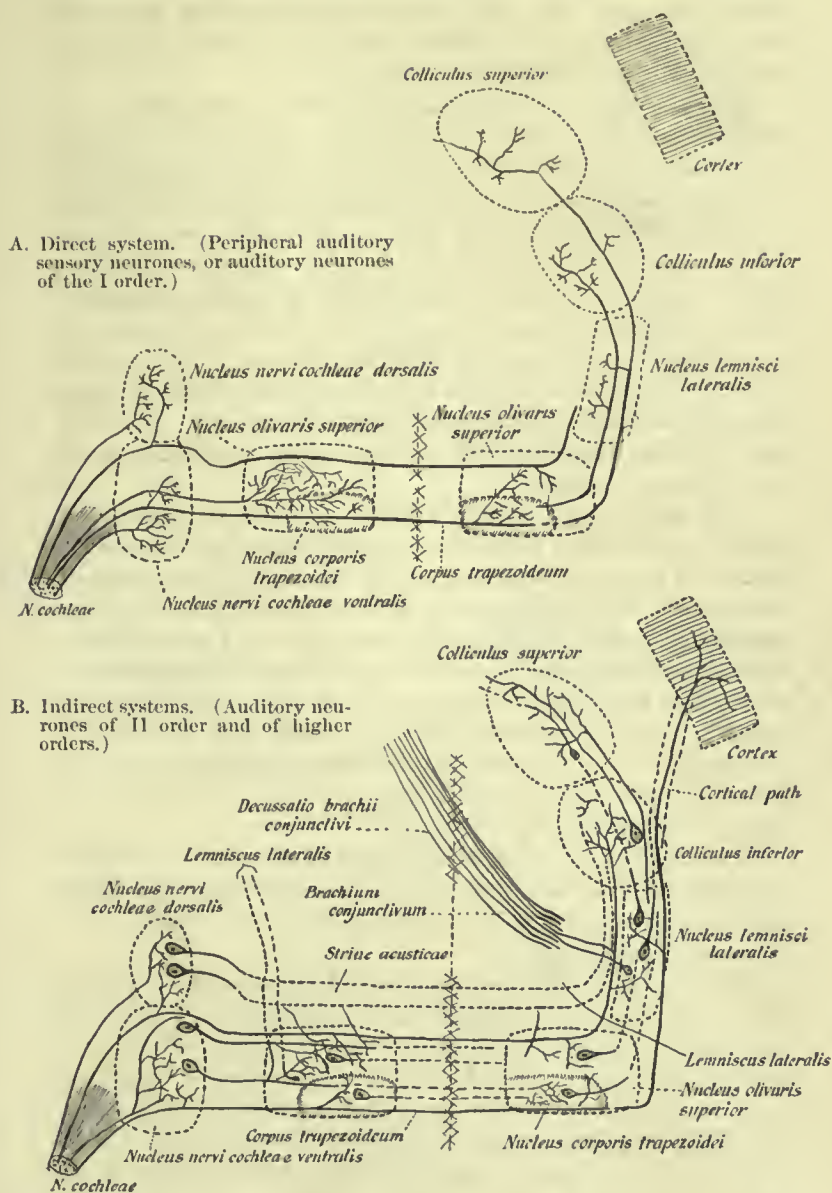


FIG. 554.—Schemes illustrating termination of axones of N. cochleae in the central nervous system, together with some of the central auditory neurones. (After H. Held, Arch. f. Anat. u. Physiol., Anat. Abth., Leipz., 1893, S. 240, Fig. 15.)

liculi inferioris. The brachium conjunctivum at the same level begins to turn ventralward, and a little higher up enters into the decussatio brachii conjunctivi.

The relations of the lemniscus lateralis to the nucleus colliculi inferioris are very characteristic, and lend an especial stamp to this portion of the brain, so that Weigert preparations of transverse sections through the inferior colliculus are recognizable at first glance, when one is once familiar with the appearances. The nucleus of the inferior colliculus sits like a berry on a stem, the latter being formed by the diverging fibres of the lateral lemniscus. A portion of the fibres pass over the dorsal surface of the nucleus colliculi inferioris to decussate in the velum medullare anterius with similar fibres from the opposite side (so-called *Hirnkappenschleife* of Meynert). Von Kölliker believes that many of the fibres enter the frenulum veli medullaris anterioris.

Still another portion of the lateral lemniscus passes by the colliculus inferior to enter the colliculus superior, there to terminate in the middle portion of the stratum griseum colliculi superioris. This bundle, being one of the earliest to become medullated in the colliculus superior, is extremely easy to follow. Doubtless these fibres are of no inconsiderable significance in connection with reflex movements of the eyes depending upon acoustic stimuli, inasmuch as we have seen that the superior colliculus of the corpora quadrigemina represents the most important subcortical central organ for the control of the eye-muscle movements (Figs. 555-558).

And, finally, a portion of the fibres of the lateral lemniscus probably pass forward through the brachium quadrigeminum inferius to terminate in the corpus geniculatum mediale or its immediate neighborhood.

Held describes fibres of the lateral lemniscus which pass on directly through the tegmentum, the hypothalamic region, and the internal capsule to the cerebral cortex (Held's *directe acustische Rindenbahn*). That such fibres may exist is not impossible, though that there are many such seems unlikely, since, as von Kölliker points out, the experiments of von Monakow prove that after removal of the temporal lobe in the rabbit and in the cat no alterations result in the lemniscus lateralis even after the lapse of a long time.

The nucleus colliculi inferioris has, unfortunately, not yet

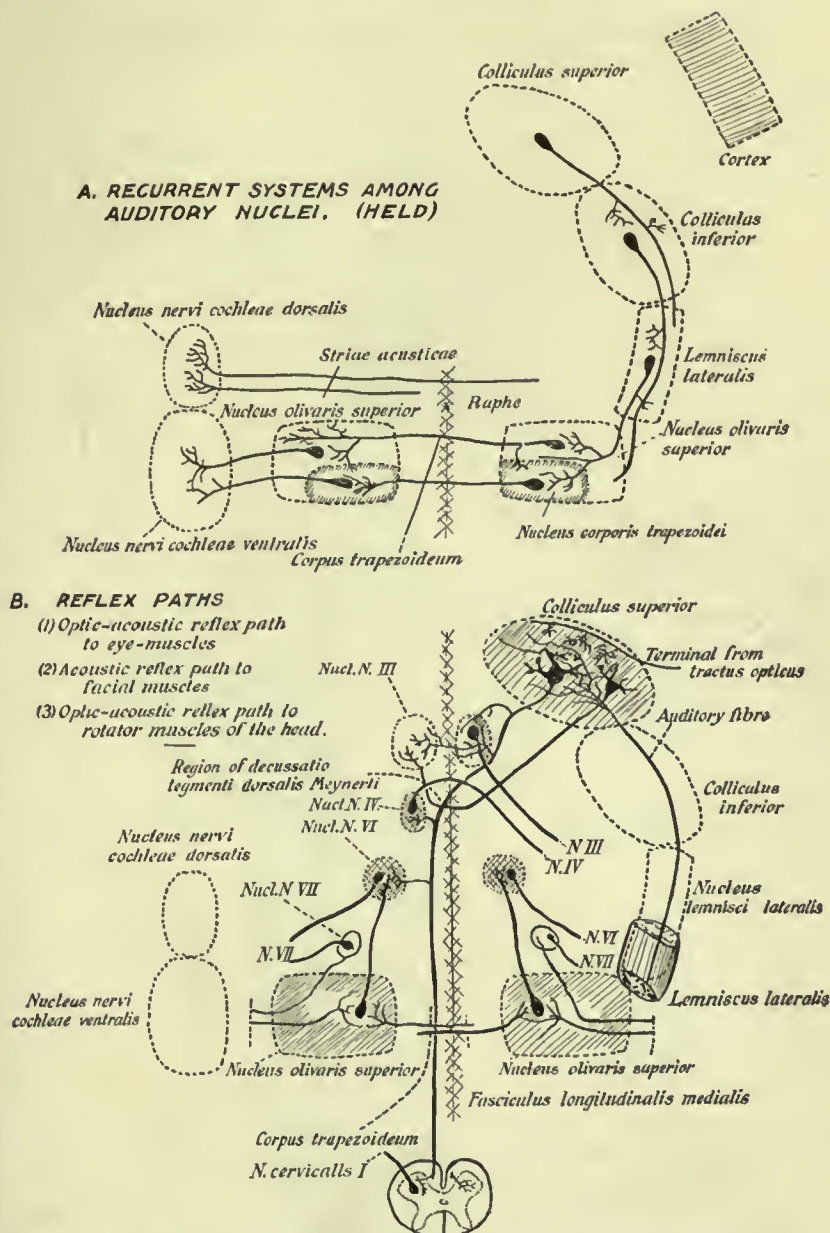


FIG. 555.—A. Neurones with descending axones, the perikaryons and dendrites of which are situated in nuclei of the central acoustic paths. B. Optic-acoustic reflex paths. (After H. Held, Arch. f. Anat. und Physiol., Anat. Abth., 1893, S. 241, Fig. 16.)

been sufficiently studied to permit of more than fragmentary statements regarding the neurones situated in it, and the dis-

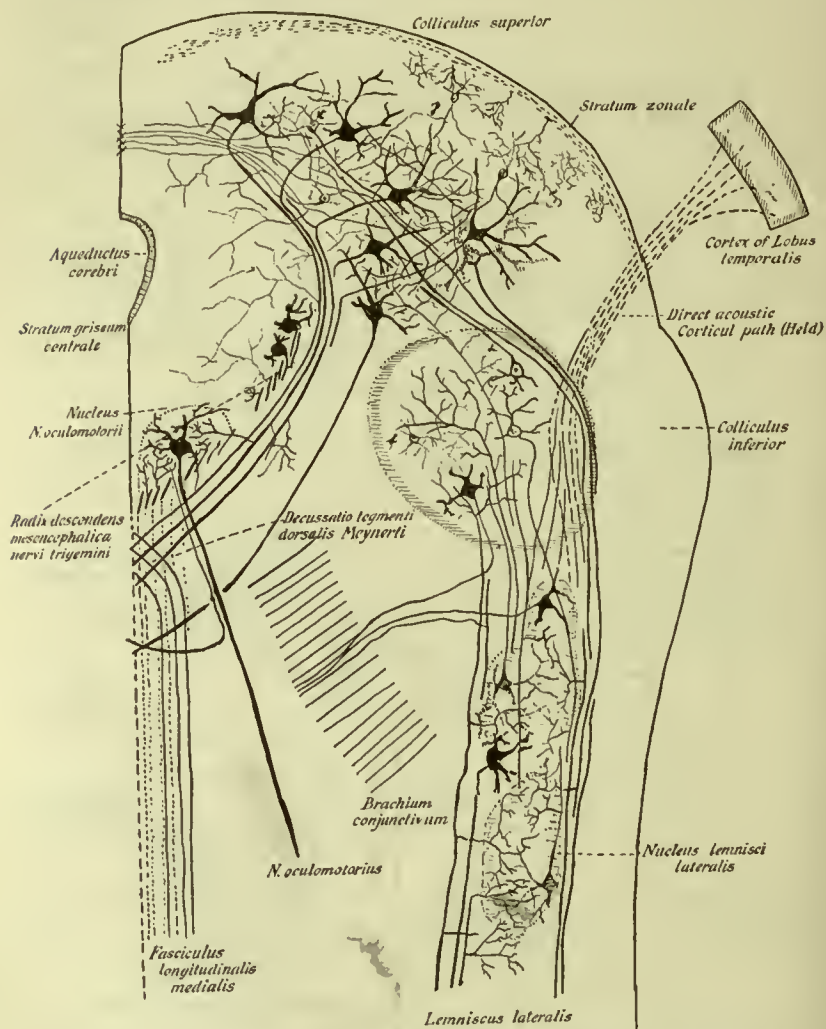


FIG. 556.—Semi-schematic drawing illustrating the relations of the lemniscus lateralis to the corpora quadrigemina. (After H. Held, Arch. f. Anat. u. Physiol., Anat. Abth., Leipz., 1893, S. 228, Fig. 10.)

tribution of their axones. It would appear that there are contained in it both inaxones (Golgi cells of Type I) and dendrax-



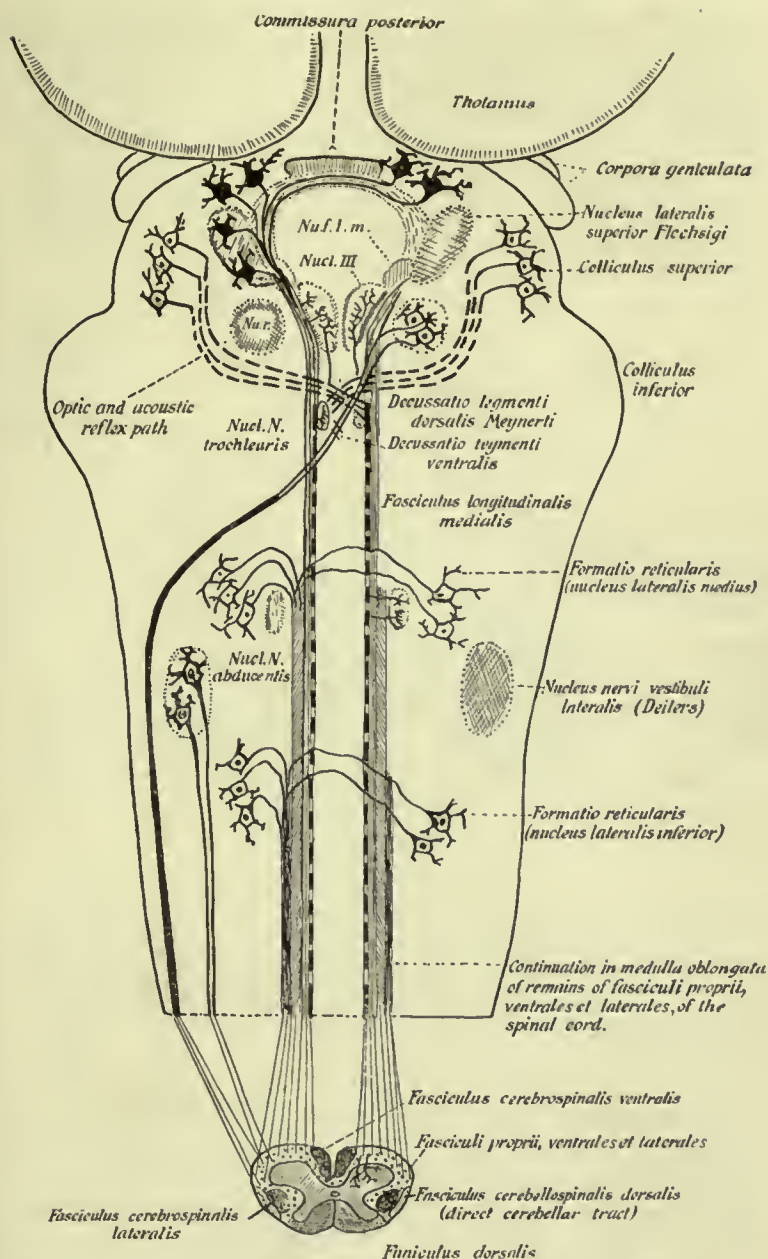


FIG. 557.—Scheme of the course of the optic and acoustic reflex paths in the formatio reticularis. (After H. Held, Arch. f. Anat. u. Physiol., Anat. Abth., Leipz., 1893, S. 229, Fig. 11.) Nucl. III, nucleus nervi oculo-motorii; Nu. f. l. m., nucleus fasciculi longitudinalis medialis seu nucleus commissure posterioris; Nu. r., nucleus ruber.

ones (Golgi cells of Type II). The long axones apparently take two directions; the majority of them ascend, passing mainly through the brachium quadrigeminum inferius to go, along with the continuation of the lateral lemniscus, to the corpus geniculatum mediale. A few of the fibres which pass into the brachium quadrigeminum inferius leave it again, according to von Beehterew,\* to decussate in the roof of the aqueductus cerebri, and probably to terminate in the nucleus of the opposite inferior colliculus.

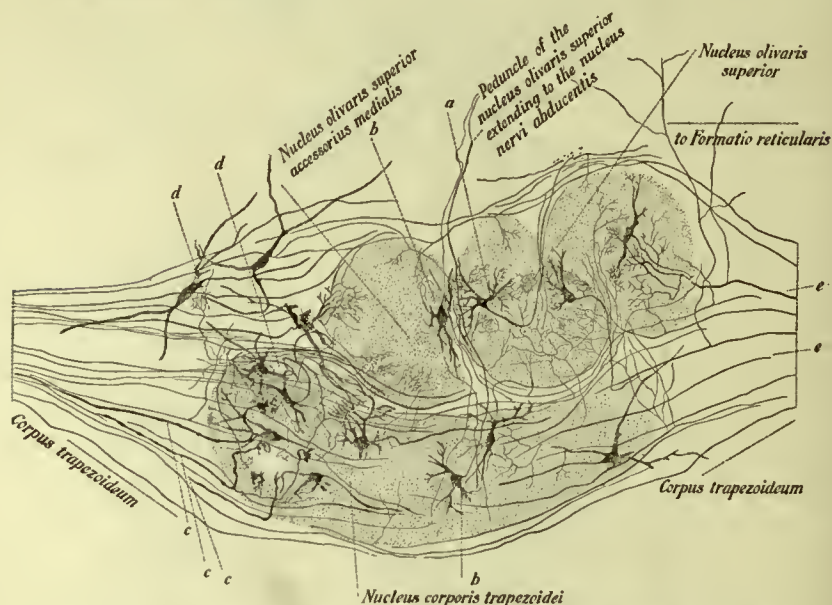


FIG. 558.—Corpus trapezoideum, with adjacent masses of gray matter on the right side of the brain of the rabbit; method of Golgi. Combined picture. (After H. Held, Arch. f. Anat. u. Physiol., Anat. Abth., Leipz., 1893, Taf. xiii, Fig. 6.) *a*, cell in nucleus olivaris superior; *b*, cell in nucleus olivaris superior accessorius medialis, its axone going through the peduncle of the upper olive to the nucleus N. abducentis; *c*, axones of corpus trapezoideum terminating in nucleus corporis trapezoidei; *e*, *e*, axones running to terminate in superior olivary complex.

Held found that another portion of the long axones arising from cell bodies in the nucleus of the inferior colliculus descend, and pass by way of the lateral lemniscus to the various nuclei of the auditory path situated below this level. That there must be other connections of the inferior colliculus seems very likely,

\* von Beehterew. *Op. cit.*, S. 114.

and the impression is gradually gaining ground that this quadrigeminal body is of the highest significance for the setting free of reflexes in connection with auditory stimuli. It appears to stand in the same relation to the auditory conduction path as does the superior colliculus to the visual conduction path.

It will be of the greatest importance in the future to determine exactly the relation of the inferior colliculus to the most direct acoustic path which extends from the ear to the cortex. Do the auditory fibres carrying impulses concerned in sharp, clean-cut visual sensation undergo interruption in the inferior colliculus? It would seem to me probable, in analogy with the general sensory conduction path and with the conduction path for visual impulses, that the colliculus inferior is not a way station in the *shortest* auditory conduction path to the cortex. It would seem much more likely that, for the auditory conduction path, the corpus geniculatum mediale supplies the interruption, thus corresponding to the ventro-lateral group of nuclei of the thalamus for the general sensory conduction path, and to the corpus geniculatum laterale for the visual conduction path.

The best description of the brachium quadrigeminum inferius, since the articles of Meynert and Forel, is that of von Monakow.\* The origin and termination were not at all clear to the older writers. Even Forel was satisfied with saying that it went, along with the lemniscus, into the region of the tegmentum, while Meynert put forward the hypothesis that from the tegmental region there pass projection fibres to the cerebral cortex. Von Monakow finds only the indirect form of atrophy in the brachium quadrigeminum inferius after experimental lesion of the cerebral hemisphere in the dog and after defect in the region of the operculum and of the temporal lobe in man (his cases "Widmer" and "Seeger"). He believes, therefore, that the fibres of the arm of the inferior colliculus do not extend directly to the cerebral cortex, but are interrupted in the diencephalon (Fig. 559). In all probability this interruption occurs in the corpus geniculatum mediale.

---

\* von Monakow, C. Experimentelle und pathologisch-anatomische Untersuchungen über die Haubenregion, den Sehhügel und die Regio subthalamica nebst Beiträgen zur Kenntniss früh erworbener Gross- und Kleinhirndefecte. Arch. f. Psychiat., Berl., Bd. xxvii (1895), S. 454.

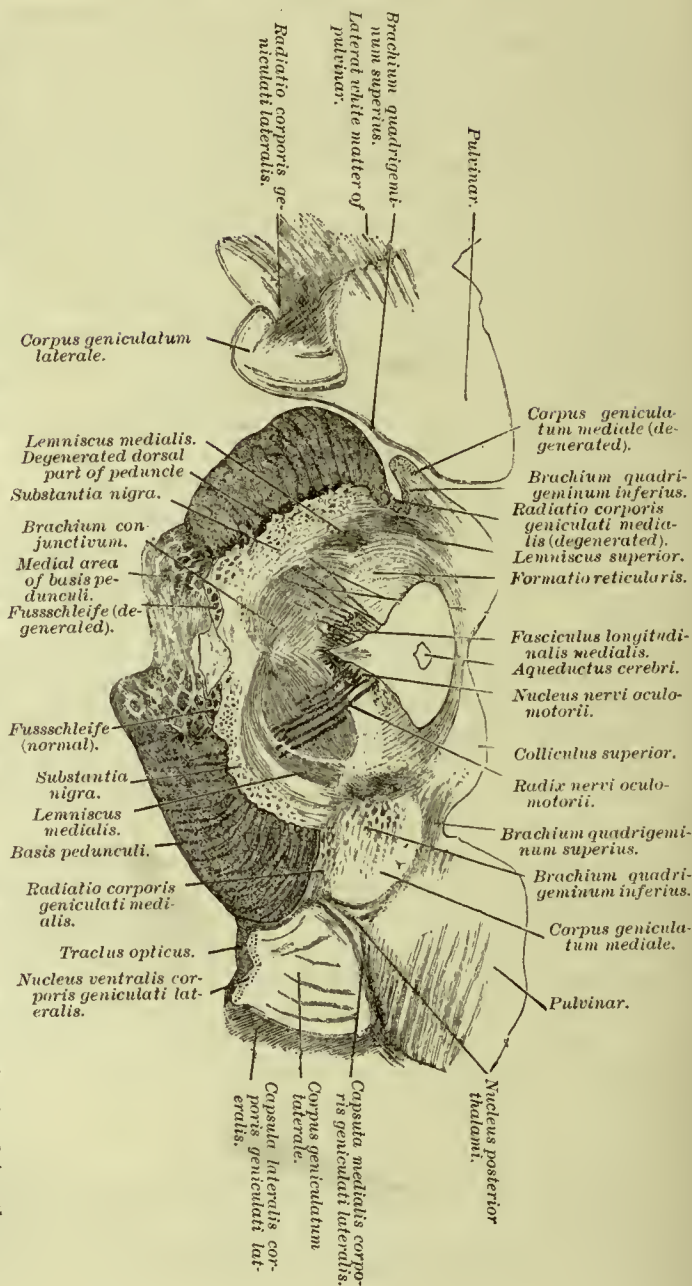


Fig. 559.—Frontal section through the human brain of von Monakow's case Wimer, in which there was a lesion involving the gyrus frontalis inferior, the operculum, the insula, the gyrus temporalis superior and the putamen on the left side, and in which he could make out degeneration of the corpus geniculatum mediale of the nuclei *vent. a*, *vent. c*, *vent. lat. med.* (*medial part*), *med. a*, *med. b*, of the nucleus ruber, of the substantia nigra, and of the colliculus inferior. (After C. von Monakow, Arch. f. Psychiat., JbL. xxvii, 1895, S. 112, Fig. 64.)



The topographical relations of the corpus geniculatum mediale and its general histological characteristics have already been described (*vide supra*). When the lateral lemniscus has been cut, degenerated fibres can be traced all the way to the medial geniculate body, but the cells of the medial geniculate body do not atrophy or disappear. On removal of the temporal lobe of the cerebral cortex, however, or on section of the white fibres passing from the region of the medial geniculate body to the internal capsule, the corpus geniculatum mediale degenerates *in toto* (von Monakow).\* Nissl subdivides the corpus geniculatum mediale in the rabbit into an anterior nucleus, a posterior nucleus containing large cells, a ventral nucleus closely crowded with cells, a dorsal nucleus, a medial nucleus, and a posterior nucleus. Unfortunately, thus far these nuclei have not been thoroughly studied by Golgi's method. It seems almost certain, however, from the researches of von Monakow, that a large portion, at any rate, of the axones arising in the medial geniculate body run through the retro-lentiform portion of the internal capsule to terminate in the cortex of the gyrus temporalis superior, to end, he believes, by free terminal ramifications in the deep layer of the cortex. Von Monakow holds that Golgi cells of Type II (dendraxones) are interposed in the medial geniculate body between the terminals of the auditory conduction fibres coming from below and the neurones which send their axones out to the cerebral cortex. The bundle of white fibres issuing from the medial geniculate body (*Stiel des medialen Kniehöckers* of the Germans) to enter the internal capsule occupies in the retro-lentiform portion of the capsule the region just anterior to and a little lateral from the fibres of the occipito-thalamic radiation. It and the brachium quadrigeminum inferius are easily demonstrable in sagittal sections of the developing brain, now being studied by Miss Gertrude Stein (Fig. 560).

The path followed by the auditory conduction fibres is beautifully demonstrable in the cerebral hemisphere by the method of Flechsig in the brain of the babe shortly after birth, although the following of the conduction path out to the auditory sense area in the cortex is rendered somewhat difficult by the fact that the fibres of this path do not run in one plane in the corona radiata, but make many curves owing to their relation

---

\* von Monakow. *Op. cit.*

to the fossa Sylvii. The axones of the cells of the medial geniculate body become medullated later than those from the

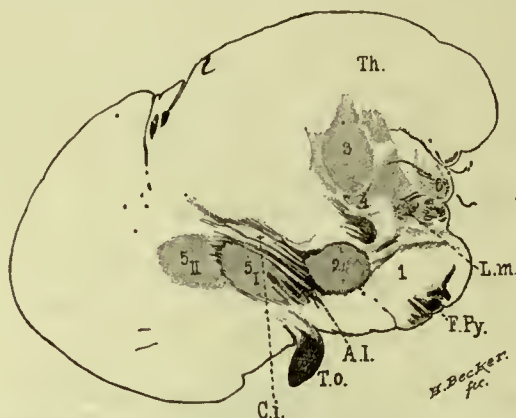


FIG. 530.—Sagittal section of babe's brain shortly after birth (section 76). *A.l.*, ansa lenticularis; *Ci.*, capsula interna; *F.Fy.*, fasciculi cerebrospinales (pyramidales); *L.m.*, lemniscus medialis terminating in ventral portion of thalamus; *Th.*, thalamus; *T.o.*, tractus opticus; *1*, substantia nigra; *2*, nucleus hypothalamicus (corpus Luysi); *3*, centre médian of Luys; *4*, nucleus arcuatus (*schalenförmiger Körper* of Flechsig and von Tschisch); *5*, nucleus lentiformis; *6*, corpus geniculatum mediale and beneath it the fibres of the brachium quadrigeminum inferius.

lateral geniculate body, but earlier, according to Flechsig, than any of the other fibres of the region in which they are situated. Flechsig\* has been able to follow the path satisfactorily by means of horizontal and sagittal serial sections. He says: "The fibre bundles of the brachium quadrigeminum inferius, in which are represented without doubt the continuations of the cochlear nerves, partly become lost in the medial geniculate body where the fibres break up, partly go past this, but close by it. With the latter are associated the fibres which arise in the medial geniculate body, and the two sets of fibres go together behind and beneath the thalamus to the internal capsule, pass transversely through the same, and then go in two separate bundles to the transverse gyri of the temporal lobe. The one bundle ascends near the external capsule and arrives from behind and above into the auditory sense area. The second runs for some distance along with the occipito-thalamic radiations and ascends,

\* Flechsig, P. *Gehirn und Seele*, ii. Ausgabe, Leipzig (1896), Anm. 29, S. 74.






FIG. 563.—Nerve cells in the cortex of the gyrus temporalis superior. (After C. Hammarberg, *Studier öfver Idiotens klinik och Patologi*, etc., Upsala, 1893, Taf. ii, Fig. 2.)

passing around the fossa Sylvii from behind and below into the temporal lobe itself, close by the second and third temporal gyri, to reach the transverse temporal gyri" (Figs. 561 and 562).

The exact extent of the region in the cerebral cortex in which the auditory fibres terminate is not precisely settled, but, according to Flechsig, corresponds to the two transverse gyri of the temporal lobe (particularly the anterior), and that portion of the gyrus temporalis superior immediately adjacent, namely, the third and fourth fifth reckoned from its anterior extremity.

The cortex of the auditory sense area has a special structure in that the number of layers is here larger than in any other part of the cortex except in the visual sense area (Flechsig).<sup>\*</sup> Six layers are to be made out, among them some so rich in medullated horizontal fibres that, at least in many brains, the auditory sense area can be said to possess a Vieq d'Azyr stripe similar to that of the visual sense area. Certain peculiar cell forms with cylindrically shaped bodies and numerous large pyramidal cells have been described. Giant pyramidal cells seem to be absent. I know of no illustration exactly corresponding to the auditory sense area, but the accompanying picture, taken from Hammarberg, shows the structure of the cortex in the gyrus temporalis superior, very close to the auditory sense area (Fig. 563). In this region, according to Flechsig, begins the temporal cerebro-corticopontal path (cf. Chapter LXIV). In addition to the centripetal and centrifugal projection neurones associated with the auditory sense area there are present in it a number of associa-

<sup>\*</sup> Flechsig, P. *Gehirn und Seele*, Leipzig (1896), S. 75.



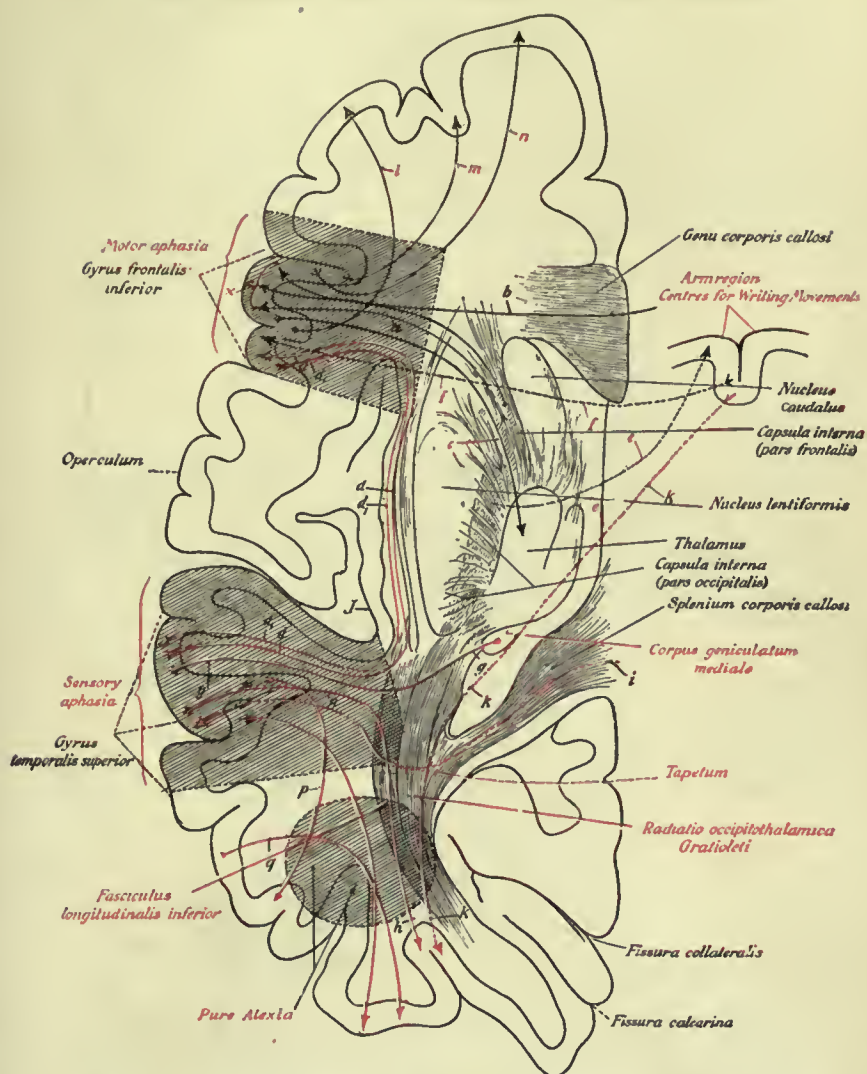


FIG. 564.—Horizontal section through brain showing the relations of the auditory sense area to the other speech centres. (Von Monakow.)



the so-called fasciculus longitudinalis inferior, is stated to connect the auditory sense area with the occipital lobe of the same side, while a portion of the fasciculus arcuatus (fasciculus longitudinalis superior) connects it with the island and with the gyrus frontalis inferior. In these bundles of association fibres are axones running in both directions. In the auditory sense area in all probability terminate the axones from numerous association neurones, the cell bodies of which are situated in various portions of the cerebral cortex, but a vast deal of research will be required before very definite statements concerning these can be made.

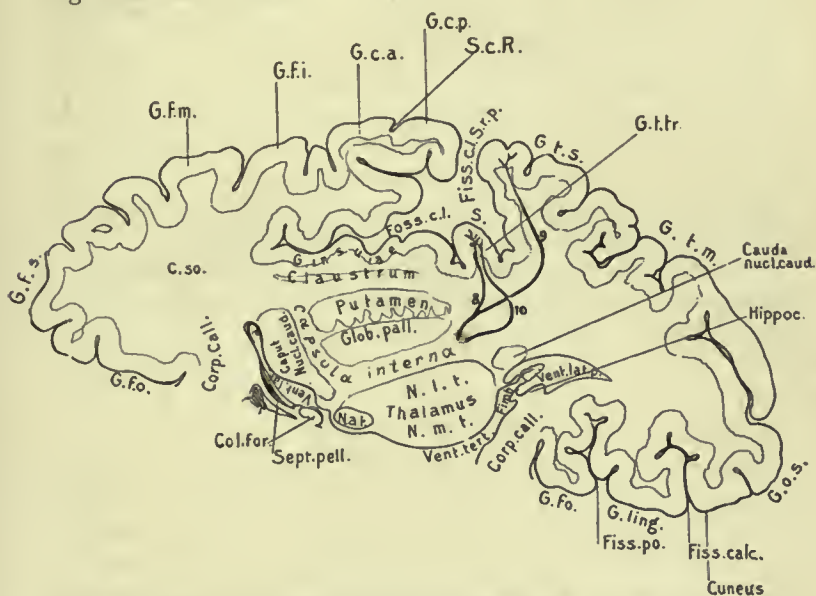

FIG. 566.—Scheme of neurones of auditory conduction path. Lettering the same as in Plate I, Fig. 3.

The auditory sense area on the left side has been proved to be of especial importance in connection with the functions of speech. It is, in fact, identical with the "centre for the sounds of words" which are so necessary for the development of the so-called "internal speech." Lesion of this region on the left side leads to "word deafness." This centre is related to the other speech centres by means of association fibres. Present ideas concerning these relations are schematically represented in the diagram taken from von Monakow (Fig. 564).

A lesion of the auditory sense area, on one side only, does not destroy hearing in the opposite ear, but probably interferes to a certain extent with the hearing of both sides. Bilateral lesion, involving the auditory sense area on the two sides, causes total deafness. It is not surprising that unilateral lesion does not cause complete deafness, since, as we have seen, there are manifold decussations of the auditory fibres in the lower portions of the central nervous system. Thus there is partial decussation in the corpus trapezoideum, and again in the mesencephalon, especially between the two inferior colliculi of the corpora quadrigemina. A further commissure in the auditory path to which little attention has been paid is to be found in the commissura inferior Guddeni. All the evidence goes to show that this commissure connects the medial geniculate bodies of the two sides, and, as we have seen, the medial geniculate body on each side represents a most important way station in the conduction path from the internal ear to the cerebral cortex. I should not be surprised, therefore, if the commissura inferior Guddeni were of the highest significance as an auditory commissure.

In the diagrams, Figs. 565 and 566, the principal groups of neurones in the auditory conduction path are schematically represented.



### SUBSECTION III.

#### Neurones Connecting the Central Nervous System with the Voluntary Muscles of the Body. (Lower Motor Neurones, or Peripheral Centrifugal Neurones.)

---

### CHAPTER LV.

#### THE LOWER MOTOR NEURONES.

General description—Those pertaining to the spinal cord—Perikaryons of the ventral horn—The "middle cells"—The ventral roots of the spinal nerves—Motor nerve-endings in muscle—Physiological studies—Localization of motor function in the segments of the spinal cord—Starr's table—Researches of Sano, Bernheimer, and Schwabe—Columna medialis—Columna intermedio-lateralis—Columna extremitatis superioris—Columna extremitatis inferioris.

THE neurones next to be considered are those which bring the voluntary muscles of the body under the influence of the nerve centres. Between the nerve centres and the voluntary muscles one set of neurones—the lower motor neurones—exist, just as we have seen that for the connection between peripheral sensory surfaces and the nerve centres one set of neurones suffice.

The cell bodies and dendrites of the lower motor neurones are all situated within the central nervous system, so that the distance between the central nervous system and the voluntary muscles is traversed by the medullated axones of these neurones. These axones make their exit from the nerve centres always (with the exception of those of the nervus trochlearis, *vide infra*) from the ventral or lateral surface of the cerebro-spinal axis. The bundles of medullated axones make up the ventral roots of the spinal nerves and the motor portions of the cerebral nerves.

The lower motor neurones are situated in the parts of the cerebro-spinal axis below the diencephalon—that is, in the mesen-

cephalon, rhombencephalon, and medulla spinalis. The cell bodies and dendrites of these neurones occupy a very definite position in the cerebro-spinal axis, being situated always ventral to the central canal, occupying in the medulla spinalis certain portions of the ventral and lateral horns of the gray matter, and in the rhombencephalon and mesencephalon regions which correspond to those mentioned for the cord.

It will be convenient to describe first the lower motor neurones incident to the medulla spinalis and afterward those belonging to the rhombencephalon and mesencephalon.

#### (A) Those Pertaining to the Spinal Cord.

In the spinal cord the cell bodies, it has generally been taught, are arranged in the ventral and lateral columns of gray matter more or less segmentally\*—that is to say, longitudinal sections through the cord show that the cells are not evenly distributed, but arranged more or less definitely into groups (Schiefferdecker,† Schwalbe,‡ and others). The literature of the subject has been collected and analyzed by Lüderitz.\* The total number of motor cells varies much in different portions of the cord. They are most numerous in the cervical and lumbar enlargements, corresponding to the innervation of the muscles of the extremities, least numerous in the thoracic cord whence the comparatively small bulk of trunk muscles receives its nerve supply. In addition to the longitudinal grouping, in cross section also the cells show an arrangement in definite groups, as Gerlach first pointed out (*vide infra*). Waldeyer,|| in his elaborate study of the spinal cord of the gorilla, divided the ventral horn cells into a medial ventral and a lateral dorsal group, a classification agreed to by Kaiser<sup>^</sup> in his very thorough study of the cervical cord.

\* It is to be noted that one true embryological neuromere probably corresponds to several of the segments or segmental groups of nerve cells which the histologists have described.

† Schiefferdecker, P. Beiträge zur Kenntniss des Faserverlaufs in Rückenmark. Arch. f. mikr. Anat., Bonn, Bd. x (1874), S. 471-494.

‡ Schwalbe, G. Lehrbuch der Neurologie, Svo, Erlangen (1881), S. 384.

\* Lüderitz, C. Ueber das Rückenmarksegment. Arch. f. Anat. u. Physiol., Anat. Abth., Leipz. (1881).

|| Waldeyer, W. Das Gorilla-Rückenmark. Abhandl. d. kgl. Akad. d. Wissensch. zu Berlin, aus dem Jahre 1888, Berl. (1889), S. 91.

<sup>^</sup> Kaiser, O. Die Funktionen der Ganglienzellen des Halsmarkes. Ge-krönte Preisschrift, Haag, Mart. Nijhoff (1891), p. 71.

The arrangement of the motor cell groups in human beings has been carefully studied by von Lenhossék in the cord of a healthy young man.\* Inasmuch as the application of Golgi's method has convinced von Lenhossék that the cells situated most medially and ventrally in the ventral horns send all their axones not into the ventral roots of the spinal nerves, but through the ventral commissure to the other side of the cord, this investigator excludes these from the motor cell groups, designating them the commissural group (Fig. 567).† In the ventral horn, as far as the third cervical nerve, von Lenhossék makes out only a single small longitudinal, rather narrow group of ventral horn cells, separated from the group of commissural cells by a narrow space free from nerve cells. From the fourth cervical nerve to the beginning of the cervical enlargement this interspace becomes much broader, and, in addition, the motor-cell group becomes divided into two well-separated cell nests—a ventral group more medially placed, and a dorsal group more laterally placed. The interspace between these groups is characterized not only by the absence of motor cells, but also by the presence of large numbers of fine nerve fibres which run in between the groups.

In the region of the cervical enlargement (from the level of the fourth to that of the seventh cervical nerve) von Lenhossék finds a progressive though gradual increase in the number of nerve cells in both motor groups, so that the motor area here is relatively large. The increase takes place, however, mainly in the dorso-lateral group, which now exceeds very markedly in size the ventro-medial group. In places the dorso-lateral group shows a division into two compartments. At this level the medial group is separated from the group of commissural cells by a broad field, which corresponds to a distinct indentation in the ventral margin of the ventral horn. A similar indentation of this margin

---

\* von Lenhossék. *Op. cit.*, S. 321.

† This is the group of cells which in the bibliography is frequently referred to as the "medial anterior group of anterior horn cells." They have been so described by Kaiser as an uninterrupted column running almost the whole length of the cord, supplying, he believed, the long muscles of the back. According to von Lenhossék, their axones are in part short, terminating in the gray matter of the opposite ventral horn, in part longer, running out into the white matter of the opposite side of the cord—heteromeric neurones in the sense of van Gehuchten.

exists between the dorso-lateral and ventro-medial group of motor cells. The size of the ventral horns rapidly diminishes between the level of the eighth cervical and that of the first thoracic nerve, and the relations in the lower part of this region cor-

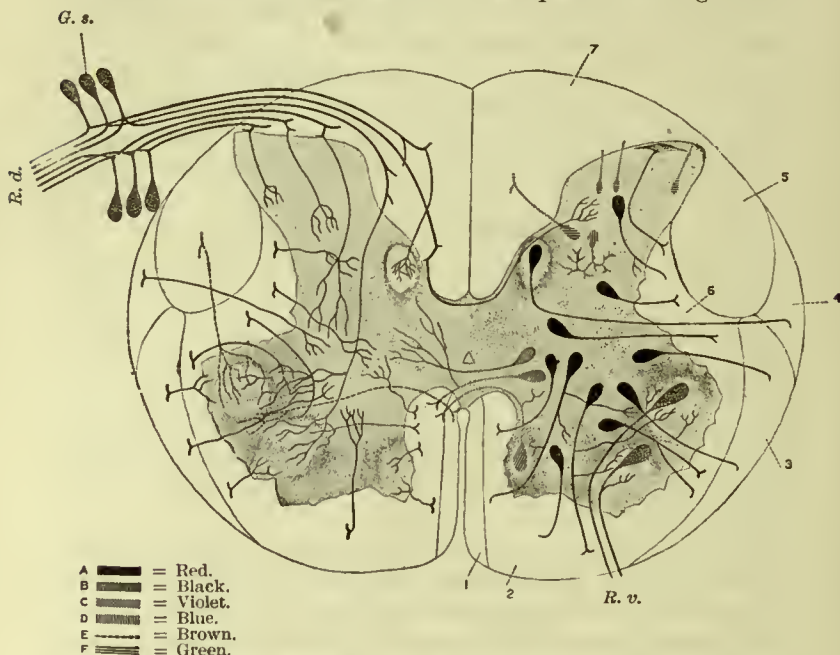


FIG. 567.—Scheme of the structure of the spinal cord; nerve cells shown in the left half of the cord; collaterals shown in the right half of the cord. (After M. von Lenhossék, *Der feinere Bau des Nervensystems*, etc., 2. Aufl., Berl., 1895, Taf. vi.) Left half of the cord, black cells are motor; side fibrils are seen arising from their axones; red cells are tautomeric neurones, the axones going to the ventral and lateral funiculi. Among these are the cells in the nucleus dorsalis and some cells in the substantia gelatinosa of Rolando; collaterals are coming off from the axones. Violet cells are commissural cells or heteromeric neurones; one is seen sending its axone into the gray substance of the other side; the others send their axones into the white matter of the opposite side. The green cells send their axones to the dorsal funiculi. In blue is seen represented a Golgi cell of Type II, or dendraxone. In the right half of the cord the black cells represent the cell bodies of peripheral sensory neurones situated in the ganglion spinale; their central prolongations are shown entering the spinal cord as dorsal-root fibres, which bifurcate and send collaterals to terminate in various parts of the substantia grisea. Thus the reflex collaterals are seen going to the ventral horn; other collaterals enter the nucleus dorsalis; some pass through the dorsal commissure to the dorsal horn of the opposite side. The red collaterals come from the white fibres in the ventral and lateral funiculi; the lilac collaterals belong to the axones of heteromeric neurones; the brown collaterals and terminals represent fibres from the fasciculi cerebrospinales or pyramidal tract. 1, fasciculus cerebrospinalis ventralis; 2, fasciculus ventralis proprius; 3, fasciculus ventrolateralis Gowersi; 4, fasciculus cerebellospinalis; 5, fasciculus cerebrospinalis lateralis; 6, fasciculus lateralis proprius; 7, funiculus dorsalis; R. v., radix ventralis; R. d., radix dorsalis; G. s., ganglion spinale.



respond to those described by von Lenhossék in the upper part of the cervical region—that is, the motor cells are represented by a small single longitudinal mass, separated from the commissural cells by a narrow stripe free from nerve cells. In the upper two thirds of the thoracic cord the group of motor cells is no longer separated from that of the commissural cells; both sets of cells are reduced in numbers, and the two together make up the narrow longitudinal column of nerve cells in the small thoracic ventral horn, the medial cells being commissural, the more lateral ones motor root cells.

From the level of the ninth thoracic nerve on, von Lenhossék describes again a progressive change in the appearances. The motor cells become gradually separated from the commissural cells, so that beginning from the level of the first lumbar nerve there is seen a very broad interspace between the two groups of cells, broader indeed than in any other region of the spinal cord. The motor cells increase here enormously in numbers, until the level of the first sacral segment has been reached, where the motor cells are so numerous as to cause the ventral horn to project as a broad, plump hemisphere. Very soon within the motor group two subdivisions, as in the cervical cord, can be made out—a ventro-medial and a dorso-lateral group. In addition, from the level of the fourth lumbar segment on, a third, or central cell group, corresponding about to the middle point of the ventral horn, is distinguishable. This group is most distinct at the level of the first and second sacral segments. Lower down the characteristic grouping gradually vanishes, the first to disappear being the central group. Soon a division into dorso-lateral and ventro-medial ceases to be visible, and again the motor cells become united into a single cell column which gradually diminishes in extent. The reduction, however, does not express itself, von Lenhossék states, as in the thoracic cord, by thinning and sharpening of the whole ventral horn, but the ventral horn remains plump as far as its lower extremity, the cells gradually becoming less numerous.\*

---

\* Golgi has always combated the view of a definite localization of the motor cells in groups in the gray matter. I quote from his *Sulle fina anatomia degli organi centrali del sistema nervoso*, Editore U. Hoepli, Milano, 1885, p. 213: "As regards the distribution of the motor cells in the gray substance of the spinal cord, I must here remark that it is a mistake to try to establish the seat of these as the chief characteristic for a judgment re-

Argutinsky\* has recently taken up the subject in Waldeyer's laboratory. He concludes that in the columns of motor cells and in the nucleus dorsalis there is no distinct memberment of any sort. For the "middle cells" (*Mittelzellensäulen*) and the cells of the lateral horns he finds an extraordinarily sharp separation into groups (Fig. 568), but emphasizes the fact that thus far no one has proved the existence of a *true* segmental arrangement of the cells in any of the gray columns of the cord.

The cell bodies of the largest motor cells form the most prominent elements in the spinal cord. There are among the motor cells, however, smaller forms the axones of which undoubtedly enter into the formation of the ventral roots of the spinal nerves. The differences in calibre of the ventral root fibres have long been recognized. The coarser fibres are medullated earlier than are the finer (von Bechterew). According to Gaskell and Mott, the coarse fibres are destined for the voluntary muscles, the fine fibres for involuntary muscles, by way of the sympathetic system. The structure of the axone hillock is shown in Fig. 570.

The internal structure of the motor ventral horn cells has been already described (Section III). It will be recalled that they are typical multipolar stichochrome cells in the sense of Nissl (Fig. 569). The dendrites arising from all parts of the

---

garding their function. The cells situated in the ventral columns are, it is true, predominantly motor in nature, because the greatest number of these send their functional process into the ventral roots. However, just as one can not say, without reservation, that all the cells of the ventral columns enter into relation with the corresponding nerve roots, so it is also not true that it is not exclusively the cells which belong more or less strictly to the ventral horns which become connected with the ventral roots.

"I am certain that the cells which send their axis-cylinder processes out into the (motor) ventral roots can be met with in every part of the gray substance: (1) in the ventral horns where they are certainly predominant; (2) in the zone of gray substance which I have named the 'intermediate zone,' and which, lying in the region limited by the lateral columns of white matter and the central canal, forms a zone intermediate between the ventral columns and the dorsal columns of the cord; (3) in the dorsal horns with the exception of the dorsal border—that is, the border which forms the so-called gelatinous substance of Rolando. In this latter, up to the present time, only cells have been found the axones of which branch in an extremely complicated way."

\* Argutinsky, P. Ueber eine regelmässige Gliederung in der grauen Substanz des Rückenmarks beim Neugeborenen und über die Mittelzellen. Arch. f. mikr. Anat., Bonn, Bd. xlviii (1897), S. 496-523.

cell spread out into various regions of the cord, so that the possibilities of contact relation are very great. Ramón y Cajal divides

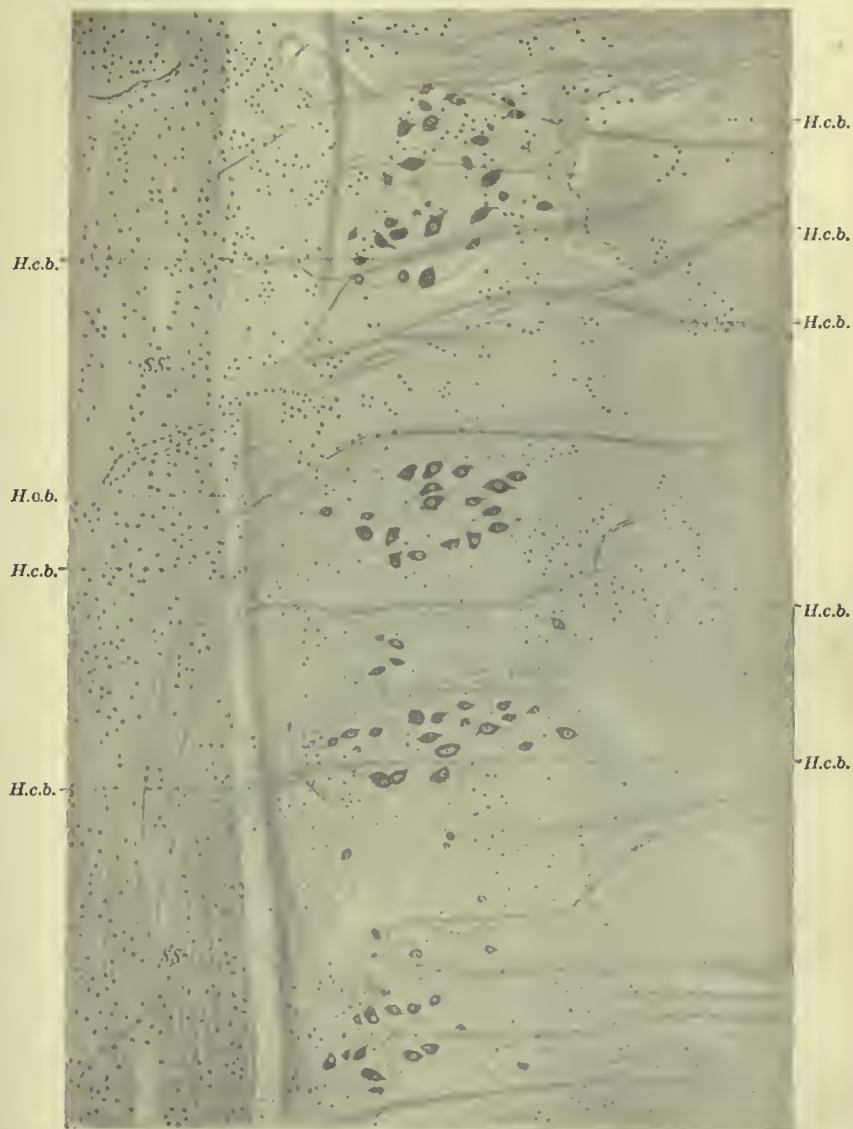


FIG. 568.—Groups of middle cells in a frontal longitudinal section through the thoracic spinal cord of newborn babe. (After P. Argutinsky, Arch. f. mikr. Anat., Bonn, Bd. xlviii, 1897, Taf. xxii, Fig. 2.) *ss*, funiculus lateralis; *H.c.b.*, horizontal cerebellar bundles of Flechsig.

the dendrites into three sets: (1) a medial group which passes toward the ventral commissure in some animals decussating with those of the opposite side, so as to give rise to a definite "protoplasmic commissure" (Fig. 571); (2) a dorsal set running toward the dorsal horn; (3) a lateral set running out toward and into the lateral funiculus, in some animals reaching the surface of

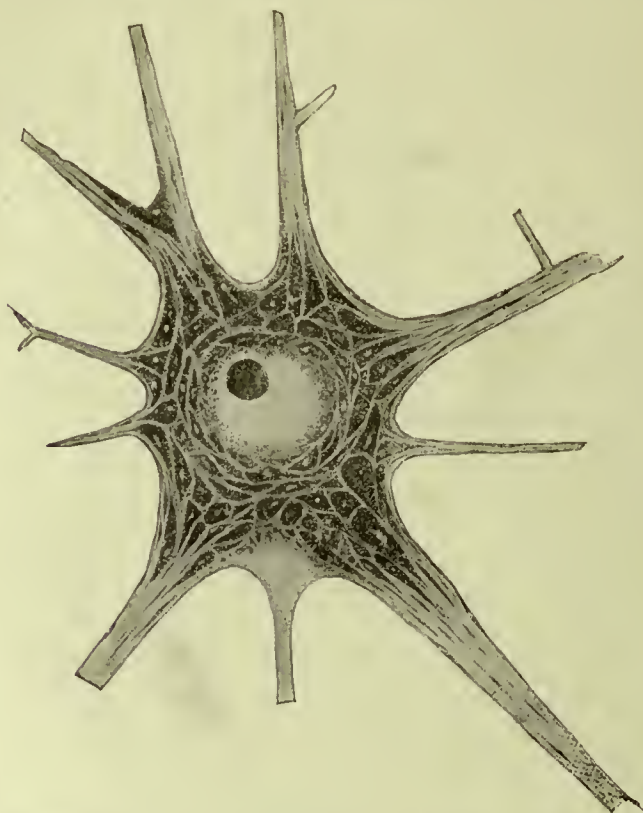


FIG. 569.—Motor nerve cell from ventral horn of gray matter of spinal cord of rabbit. (After Nissl.) Of the three lower processes, the middle one represents the axone. All the other processes are dendrites. The margins of the cells and of the masses of stainable substance appear too sharp in the reproduction. At the angle of the division of the large dendrite at the left superior angle of the cell is shown one of the "wedges of division" (*Verzweigungskegeln*). The spindle-shaped Nissl bodies are well shown, especially in the dendrites. This cell is classed by Nissl as a stichochrome nerve cell in the apyknemorphous condition.

the cord in large numbers so as to make a sub-pial plexus of dendrites. The large axone arising at the axone hillock plunges



usually by the shortest route, sometimes, however, by a devious course, into the nearest ventral root of a spinal nerve, leaving the spinal cord at the ventro-lateral sulcus. The myelin sheath

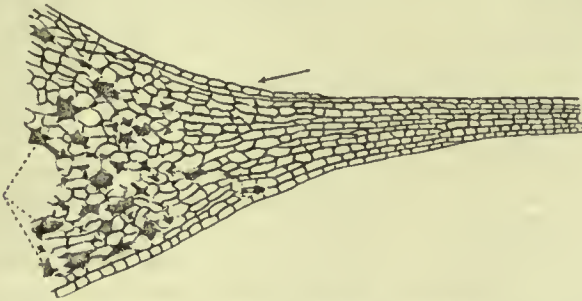


FIG. 570.—Ventral horn cell from the lumbar cord of the ox, showing axone hillock. (After Held, Arch. f. Anat. u. Physiol., Anat. Abth., 1897, Taf. ix, Fig. 10.) Treatment with ammonium bichromate, 1 to 1000. Paraffin section 1.5 microns thick. Staining with erythrosin and methylene blue. The ground substance is markedly vacuolized. The neurosomes are decolorized.

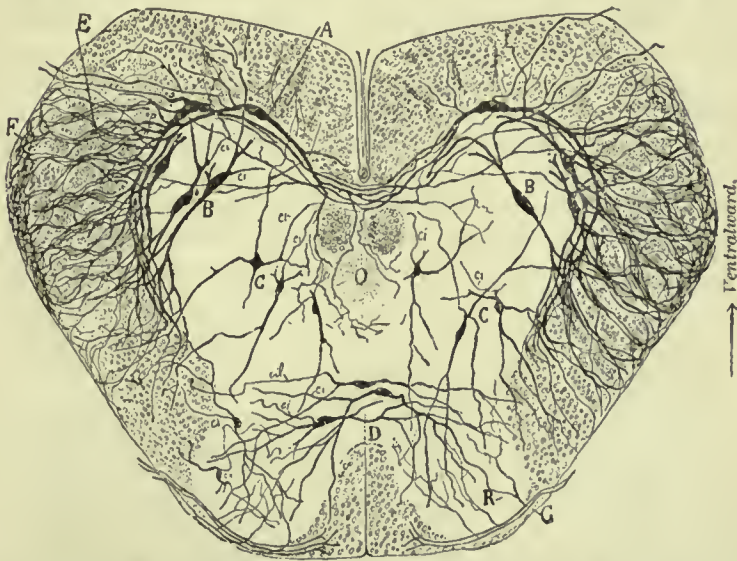


FIG. 571.—Transverse section of the spinal cord of *Lacerta Agilis*. (After S. Ramón y Cajal, *Les nouvelles idées*, etc., Azoulay, Paris, 1894, p. 27, Fig. 7.) A, cells of ventral horns, the dendrites of which help to make up a ventral protoplasmic commissure; B, heteromeric neurones; C, tautomer and heteromeric neurones; D, dorsal protoplasmic commissure; E, dendrites of ventral horn cells extending far out into white matter and forming a perimedullary plexus (F) situated beneath the pia mater, especially over the funiculus lateralis, where these dendrites come into contact relation with the collaterals and possibly of terminals of the axones of the white matter; G, radix dorsalis; R, collateral from dorsal root fibre; ci, axones.

does not begin until the axone has passed for a short distance from the cell. From the non-medullated portion of the axone there arise constantly in human beings, inconstantly in many animals, from one to four delicate branches, the "side fibrils" of Golgi. These are always non-medullated and run back toward the cell bodies which give rise to the corresponding axones. Several have thought that they come into contact with the cell body just as do the side fibrils from the spinal ganglion cells, which Huber has described.\* Others, however, believe that in running back they come in contact rather with the terminals of sensory collaterals of the dorsal root fibres. This view has already been mentioned in the discussion regarding the possible cellulipetal conduction by the side fibrils (Section V).

The ventral roots of the spinal nerves contain the motor fibres of the peripheral nerves. They are, in actuality, nothing more than the medullated axones of the motor cells of the ventral horns. A number of fibres from each ventral root pass by means of the rami communicantes into the sympathetic trunk.† In the spinal cord on each side there are thirty-one of these ventral motor roots—eight cervical, twelve thoracic, five lumbar, five sacral, and one coccygeal (Fig. 572). The nerve roots do not everywhere correspond to the vertebræ. The exact relations of the various roots to the spinous processes of the vertebræ are clear in the table prepared by Reid.‡ It would be a mistake to assume that each ventral root corresponds to a definite peripheral nerve, for this is not the case. It has been proved (*vide infra*)

\* Held (1897) has suggested that these recurrent "autocellular" collaterals of the lower motor neurones may represent an important mechanism in connection with the so-called muscle sense.

† The axones of ventral horn cells which pass through the rami communicantes in order to terminate by free end-arborizations about the cells of the various sympathetic ganglia are believed to be motor and secretory in their function. The secreting glands and the smooth muscle of the blood-vessels, and of the viscera generally, are innervated by means of sympathetic axones. The exact relations here have yet to be determined. Certain it is that the complicated local mechanisms of which the sympathetic system is the seat are, to some extent at least, brought under the influence of the neurones of the cerebrospinal system. The motor nerve-endings in smooth muscle have been carefully studied by Berkley. The neurones of the cardiac ganglia of the sympathetic are subordinated to centrifugal impulses from the medulla oblongata.

‡ J. Anat. and Physiol., vol. xxiii (1889).

that each peripheral motor nerve, especially those going to the extremities, receives fibres from a whole series of different ventral roots, the opportunity for such distribution being afforded by the different nerve plexuses (cervical, lumbar, sacral), and also by the large nerve trunks themselves, which, it seems, are to be looked upon as a kind of nerve plexus. It would seem unnecessary to repeat here what has already been discussed at some length in Chapters XVII and XVIII. The remarks made there with regard to the neurotome and its relation to the myotome, and the distribution of the fibres in the mixed nerve stem formed by the union of the ventral and dorsal roots, are just as applicable here as there, and can be referred to.

The motor axones of the peripheral neurones may divide several times on their way to the voluntary muscles, so that one neurone is capable of innervating a considerable number of striped muscle fibres. Arrived at the muscle in which they terminate, the bundle of nerve fibres breaks up in the perimysium, forming in it a plexus (Fig. 573). The individual nerve

FIG. 572.—Spinal cord in connection above with the medulla oblongata and pons. (After A. Rauber, *Lehrbuch der Anatomie des Menschen*, V. Aufl., Leipzig, 1898, Bd. ii, S. 504, Fig. 485.) *V*, nervus trigeminus; *XII*, nervus hypoglossus; *C*<sub>1</sub>, first cervical nerve; *C*<sub>2-8</sub>, second to eighth cervical nerve; *T*<sub>1-12</sub>, first to twelfth thoracic nerve; *L*<sub>1-15</sub>, first to fifth lumbar nerve; *S*<sub>1-5</sub>, first to fifth sacral nerve; *6*, nervus coccygeus; *x*, *x*, filum terminale of the spinal cord. From the root marked *L*<sub>1</sub> to *x*, cauda equina; *Rr*, plexus brachialis; *Cr*, nervus femoralis; *Sc*, nervus ischiadicus; *O*, nervus obturatorius; the enlargement opposite *L*<sub>3</sub>, *L*<sub>4</sub>, and *L*<sub>5</sub> represent the spinal ganglia on the dorsal roots. On the left side of the figure the sympathetic trunk is shown. *a* to *ss* are ganglia; *a*, ganglion cervicale superius; *b* and *c*, ganglion cervicale medium et inferius; *d*, first thoracic ganglion; *d'*, last thoracic ganglion; *l*, first lumbar ganglion; *ss*, first sacral ganglion.

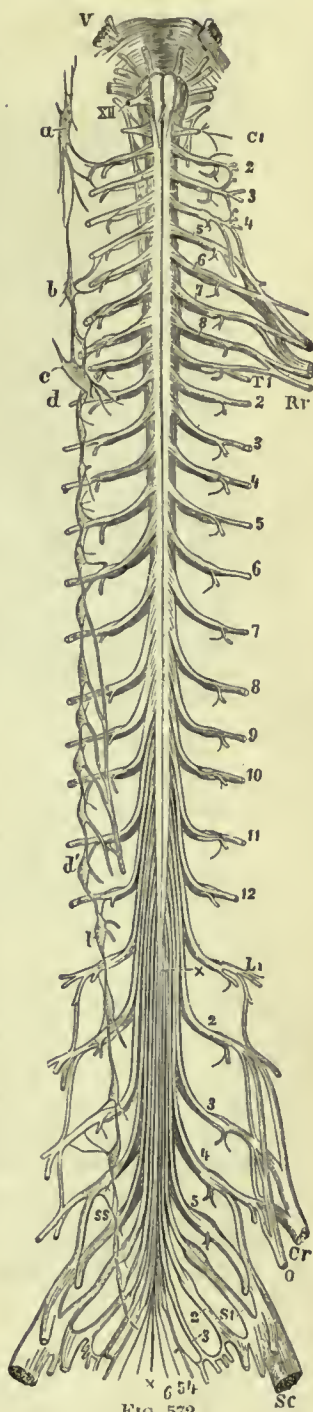


FIG. 572.



fibres can divide from one to three times, each time giving rise to from two to five subdivisions. In this way the number of




FIG. 573.—Nerve plexuses and terminals from the muscle of a lizard, after treatment with dilute acetic acid. (After P. Schiefferdecker, *Gewebelehre*, Braunsch., 1891, S. 147, Fig. 96.) The plexus on the left gives off branching fibres, which go to the motor nerve endings, indicated by the nucleolus-like appearances. The nuclei of the muscle fibres and those of Schwann's sheath have not been drawn, and the connective tissue is omitted.

nerve fibres is considerably increased, until finally there are a sufficient number to supply every muscle fibre with one or several nerve-endings (Schiefferdecker). The number of nerve-endings for the individual fibres varies; thus the fibres of the gastrocnemius and of the triceps of the frog always receive, according to Sandmann, one nerve-ending at about the middle of the fibre.\* The fibres of the sartorius, on the contrary, each receive from two to six nerve-endings. In the rectus abdominis muscle a fibre of each muscle segment is said to receive its own special nerve-ending. While this appears to be true for frogs, in mammals, in

\* Sandmann. Ueber die Vertheilung der motorischen Nervenendapparate in den quergestreiften Muskeln der Wirbelthiere. *Arch. f. Anat. u. Physiol., Physiol. Abth.*, Leipz. (1885), S. 240-252.



spite of their great length, the individual muscle fibre appears to need only one nerve-ending.

The views concerning the exact mode of nerve-ending vary; it is generally stated that the medullated fibre, having arrived at the muscle in which it is to terminate, sends its axis cylinder only into the fibre itself, the neurilemma appearing to fuse with the sarcolemma, the myelin sheath disappearing. The continuation of the axone then branches manifoldly so as to form telodendrions of various appearance. In reptiles one sees typical motor end plates so well known since the studies of Kuehne.\* In Fig. 574 the appearances to be met with in *Lacerta* are shown. The appearances are quite different in different animals. In Fig. 575 the relations of the frog are illustrated; in Fig. 576, those in

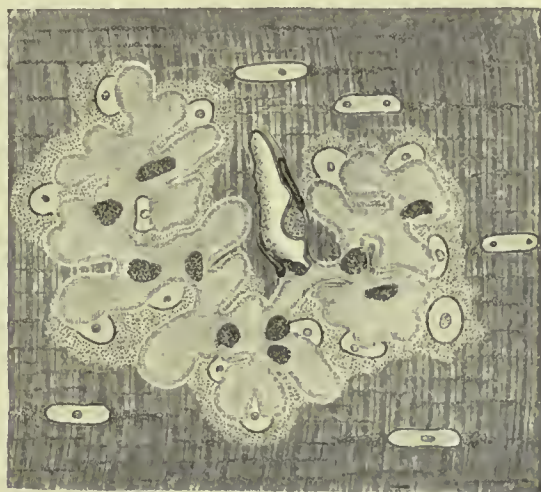


FIG. 574.—Motor telodendrion; examined fresh in physiological salt solution from *Lacerta Agilis*. (After W. Kühne, *Ztschr. f. Biol.*, Bd. xxiii; taken from Schiefferdecker's *Gewebelehre*.) The medullated axone has been torn off short; the nuclei of the *Sohlensubstanz* are well shown. One nucleus of the neurilemma and two nuclei of Henle's sheath are shown on the nerve fibre. The nuclei of the muscle fibre are easily visible.

the rabbit. In every case the axone breaks up into a number of subdivisions, many of which appear to spread out into disklike platelets. Von Kölliker, Krause, and others do not believe that the axis cylinder and telodendrions are situated between the sarco-

\* Kuehne, W. Neue Untersuchungen über motorische Nervenendigung. *Zeitschr. f. Biologie*, Bd. xxiii, pp. 1-149.

lemma and the muscle, but assert that it lies upon the sarcolemma itself; that this neurilemma accompanies the subdivi-

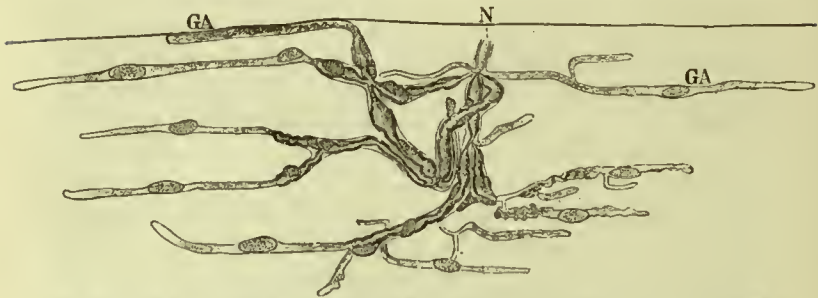


FIG. 575.—Motor nerve ending on the *M. gastrocnemius* of the frog. (After W. Kühne, as modified by P. Schiefferdecker in his *Gewebelehre*, Braunsch., 1891, S. 152, Fig. 100.) The medullated nerve fibre *N*. divides into several medullated terminal branches; the crossed striation of the muscle is not shown. *GA*, non-medullated terminal fibrils with adjacent nuclei.

sions to their terminations, and that it is Henle's sheath which unites with the sarcolemma. The majority of investigators, however, including Kuehne and Schiefferdecker, take the opposite view. Sihler, of Cleveland, believes that the nerve fibrils are situated outside the sarcolemma, and I must say that the beautiful specimens prepared by his method, which through his kindness I have had the opportunity of studying, speak strongly in favor of his view—at any rate, so far as the endings in the

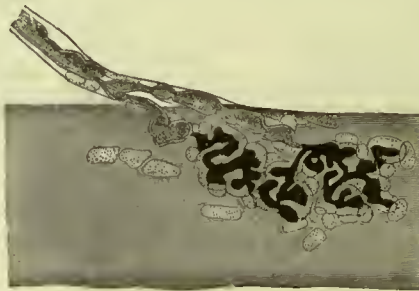


FIG. 576.—Nerve ending on an intercostal muscle of the rabbit. Gold preparation. (After W. Kühne, *Ztschr. f. Biol.*, Bd. xxiii; taken from Schiefferdecker's *Gewebelehre*.)

frog are concerned. Apáthy, however, by means of his gold-chloride method, demonstrates the existence of a very complicated arrangement of his *neurofibrillæ*, inside the individual

muscle cells. His observations have been already referred to in Chapter VI, and Fig. 27 in that chapter may again be referred to.

Since the introduction of the vital staining with methylene-blue a number of researches bearing upon the endings of motor axones in striated voluntary muscle have been forthcoming. We need only mention those of Ehrlich,\* Dogiel,† and especially Retzius.‡ The investigations of Retzius are of particular value, since they include objective descriptions of the motor endings in a long series of vertebrate classes. The recent literature has been collected and briefly epitomized by Kallius.\* The whole lower motor neurone from the nerve centre to the muscle is schematically illustrated in the diagram (Fig. 577).

The localization of function in connection with the lower motor neurones of the spinal cord is a topic which in late years has interested a progressively increasing number of investigators. After the proofs brought by Sir Charles Bell in regard to the motor nature of the ventral roots and of the sensory nature of the dorsal roots had been generally recognized, there arose conflicting opinions in the earlier part of this century concerning the functions of the individual spinal nerve roots.

Panizza,|| as a result of his experiments, decided that section of one nerve root caused only temporary weakness of the limb as a whole, the weakness increasing in proportion to the number of roots divided. Complete paralysis resulted only when the last root had been cut. According to Panizza, therefore, the various roots acted as a whole, each one of them being capable of maintaining the functions in their integrity. Johannes Müller and van Deen decided, from their own experiments and from those of Kronenberg, that the purpose of the nerve plexus, so far as the

---

\* Ehrlich, P. Ueber die Methylenblaureaktion der lebenden Nervensubstanz. Deutsche med. Wehnschr., Berl., Bd. xii (1886), S. 49-52.

† Dogiel, A. S. Methylenblauinktion der motorischen Nervenendigungen in den Muskeln der Amphibien und Reptilien. Arch. f. mikr. Anat., Bonn, Bd. xxxv (1890), S. 305-320.

‡ Retzius, C. Zur Kenntniss der motorischen Nervenendigungen. Biol. Untersuch., Stockholm, n. F., Bd. iii (1892), S. 41-52.

\* Kallius, E. Endigungen motorischer Nerven in der Muskulatur der Wirbelthiere. Merkel-Bonnet's Ergebn. der Anat. u. Entwick., Bd. vi for 1896, Wiesbaden (1897), S. 26-43.

|| Panizza, B. Ricerche sperimentali sopra i nervi, 8vo, Pavia (1834). Also Abstr. in Edinb. M. and S. J., vol. xlv. (1836), pp. 70-98.

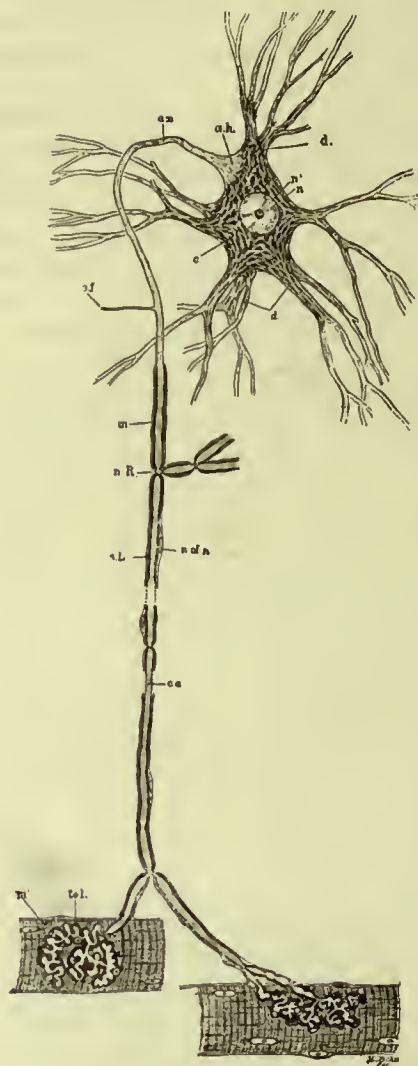


FIG. 577.—Scheme of lower motor neurone. The motor cell body, together with all its protoplasmic processes, its axis-cylinder process, side fibrils, or collaterals, and end ramifications, represent parts of a single cell or *neurone*. *a.h.*, axone-hillock devoid of Nissl bodies, and showing fibrillation; *ax.*, axis cylinder or axone. This process, near the cell body, becomes surrounded by myelin, *m.*, and a cellular sheath, the neurilemma, the latter not being an integral part of the neurone; *c.*, cytoplasm showing Nissl bodies and lighter ground substance; *d.*, protoplasmic processes (dendrites) containing Nissl bodies; *n.*, nucleus; *n'*, nucleolus; *n.R.*, node of Ranvier; *s.f.*, side fibril; *n. of n.*, nucleus of neurilemma sheath; *tel.*, motor end plate or telodendrion; *m'*, striped muscle fibre; *s.L.*, segmentation of Lantermann.



motor nerves are concerned, is to convey fibres to each muscle from different parts of the brain and spinal cord.

The careful dissections and electrical experiments of Peyer\* proved that the group of muscles supplied by each spinal root was a complex one, and also that each muscle is supplied as a rule by more than one root, findings which were confirmed in large part and extended by the researches of Krause.†

The electrical experiments of Erb on the brachial plexus of man made it seem probable that the researches which had been conducted upon lower animals also applied to the functional relations of the roots in human beings.

From the clinical side, too, Remak ‡ suggested that functionally related or synergic muscles are represented together in the ventral horns of the spinal cord. He arrived at this conclusion from his observations in cases of atrophic spinal paralysis, since he observed that the muscles simultaneously affected corresponded to those concerned in definite movements. He even went so far as to indicate the probable position of the centres of certain brachial and crural muscular groups in the cervical and lumbar portions of the spinal cord respectively.

Some help was gained with regard to motor localization at this period from the study of the spinal cord after amputations and from experiments on animals undertaken by von Gudden's method. But the next significant advance in knowledge dates from 1881, when the experiments with localized faradic excitation were undertaken by Ferrier and Yeo.\* These investigators, by stimulation of the individual ventral roots in the monkey, proved not only that various muscles contract, but that a definite group

\* Peyer, J. Ueber die peripherischen Endigungen der motorischen und sensiblen Fasern der in den Plexus brachialis des Kaninchens eintretenden Nervenwurzeln. *Ztschr. f. rat. Med., Heidelb.*, 2 R., Bd. iv (1854), S. 52-77.

† Krause, W. Beiträge zur Neurologie der oberen Extremität, 4to, Leipz. u. Heidelb. (1865).

‡ Remak, E. Zur Pathogenese der Bleilähmungen. *Arch. f. Psychiat. u. Nervenkr., Berl.* (1876).—Zur Pathologie der Lähmungen des Plexus brachialis. *Berl. klin. Wehnsehr.*, Bd. xiv (1877), S. 116-118.—Ueber die Localisation atrophischer Spinallähmungen und spinaler Atrophien; klinische Beiträge zur Pathologie und Physiologie des Rückenmarks. *Arch. f. Psychiat. u. Nervenkr., Berl.*, Bd. ix (1878-79), S. 510-635.

\* Ferrier, D., and G. F. Yeo. The Functional Relations of the Motor Roots of the Brachial and Lumbo-sacral Plexuses. *Proc. Roy. Soc. Lond.*, vol. xxxii (1881), pp. 12-20.

of muscles in synergic combination is set into activity, the effect being to produce a highly co-ordinated movement such as Remak had suggested must be the case. They found, for example, that stimulation of the *first thoracic root* causes adduction of the thumb and flexion of the fingers at the metacarpo-phalangeal joints; stimulation of the *eighth cervical root* leads to a complex reaction, comprising firm closure of the fist (intrinsic muscles and long flexors of fingers and thumb), pronation and flexion of the wrist (to the ulnar side), and extension of the forearm with retraction of the upper arm (long head of the triceps, especially in action). Stimulation of the *seventh cervical root* caused adduction of the upper arm with rotation inward and retraction; the forearm became extended so as to bring the dorsum of the hand against the rump, the wrist and fingers being flexed (at their second phalanges), the so-called *scalptor ani* movement, involving the co-operation of numerous muscles. In the same way they determined the complex movements which result on stimulation of the ventral roots of C vi, C v, C iv, S i, L vii, L vi, L v, L iv, and L iii.

Since the muscles thrown into action by each ventral root are innervated in most cases by several nerve trunks, Ferrier and Yeo concluded that the plexiform junctions of the various roots are for the purpose of distributing the requisite motor fibres in different trunks to the various muscles engaged in each functional combination. Such a view would explain why section of a motor root, while causing paralysis of the corresponding combination, need not necessarily paralyze the individual muscles involved, and the remarkable findings of Panizza were thus made less unintelligible. These experiments were in large part confirmed by Bert and Marcacci,\* and were confirmed and extended by Forgue,† the latter investigator stating that each root passing to the upper or lower extremity supplies the two opposite surfaces of the limb; that, in the cervical region, as the thoracic roots are approached, the resulting muscular contractions involve the

---

\* Bert, P., ed A. Mareacci. *Comunicazione preventiva sulla distribuzione delle radici motrici nei muscoli degli arti*. Sperimentale, Firenze, vol. xlviii (1881), pp. 356-358.—*Compt. rend. Soc. de Biol.* (1881); also *Gaz. méd. de Paris* (1881), p. 512.

† Forgue, É. *Distribution des racines motrices dans les muscles des membres*. *Gaz. hebdomadaire de médecine de Montpellier*, t. v (1883), p. 253; 279; 329; 388.—Also *Thèse Montpellier* (1883).

inferior segments of the limb, and that, further, passing in this direction the contractions progressively involve the muscular masses proceeding from the radial to the ulnar side of the limb.

The whole subject was again taken up in 1892 by Risien Russell,\* of London. Russell began his research by cutting individual roots and exciting the peripheral ends in order to observe the total compound movement produced. Subsequently he attempted to make a minute analysis of this combined movement, dividing it into its component factors by using minimal currents of excitation applied to the separate bundles of nerve fibres in each nerve root. He makes the remarkable statement that stimulation of each of the various bundles visible on the surface of the transverse section of a root leads to a different movement. He attempted also, by exciting successively the various roots and their parts, to find out whence individual muscles received their innervation. Again, when a given muscle was found to be innervated from several ventral roots the attempt was made to determine to what degree any given root supplies it.

It is impossible here to give more than a single example of the results reached by this investigator, but for this the effect of stimulation of the eighth cervical root and its constituent parts will serve very well. Russell found that on excitation of the whole root of the *eighth cervical nerve* the whole upper limb becomes extended straight down by the side of the trunk parallel to its long axis and in a straight line, with the digits very slightly separated. Further, on excitation of the individual bundles of the same nerve root he was able to differentiate no less than twelve constituent movements: (1) Arm drawn to the side of the trunk with tilting of the elbow outward; (2) arm drawn down from the shoulder and fixed to the side; (3) arm drawn across the thorax to the opposite side; (4) arm drawn to the same side of the thorax; (5) retraction of the elbow; (6) extension of the elbow; (7) flexion of the wrist; (8) extension of the wrist; (9) supination of the forearm; (10) pronation of the forearm; (11) flexion of the digits; (12) extension of the digits. Russell determined that the fibres representing a certain movement, as a rule, preserve the same position in a given nerve root. Thus, for example, extension of the wrist is represented by a bundle of fibres

---

\* Russell, J. S. R. An Experimental Investigation of the Nerve Roots which enter into the Formation of the Brachial Plexus of the Dog. Phil. Tr. Roy. Soc. Lond., vol. clxxxiv (B.). Lond. (1894), pp. 39-63.

in the upper part of the circumference, while flexion is represented by a bundle of fibres in the lower part of the same root. Each bundle of nerve fibres representing a single simple movement in a nerve root remains, Russell states, distinct in its course to the muscle or muscles producing such a movement without inosculating with other motor nerve fibres.

It is interesting to note that all the recent investigations indicate that the group of muscles supplied by any given root to a limb occupies not only the anterior but also the posterior surface of the limb; in other words, that muscles, the unimpeded action of which would produce a certain movement, are represented in the same root as others, the action of which would produce a movement diametrically opposite (antagonistic muscles). In such combinations, however, one set of muscles is always more extensively represented than others, so that with sufficiently energetic stimulation of all the fibres of a given nerve root certain muscular contractions—for example, those of flexion of the joint—predominate in their action over others. That the individual bundles of fibres in the nerve roots do not go to single muscles is proved by the fact that it is impossible by stimulation of such a single bundle to produce contraction of a single muscle alone. As might have been expected from what we know of the relation of the myotome to the neurotome, when the same muscle is represented in two nerve roots, the fibres of a muscle which are innervated by one nerve root are not innervated by the other.

In general, these results have been confirmed by a whole series of researches in embryology, comparative anatomy, clinical medicine, pathological anatomy, and experimental physiology. In 1888 M. Allen Starr\* did great service by combining in the form of a table the data which up to that date had been accumulated. We produce here the table, slightly modified, including some of the changes suggested by Edinger.

---

\*Starr, M. Allen. Syringomyelia; its Pathology and Clinical Features, with a Study of a Case and Remarks upon its Diagnosis. *Am. J. Med. Sc., Phila., n. s., vol. xev (1888), pp. 456-468.* -



*Localization of Function in the Different Segments of the Spinal Cord. (M. Allen Starr, slightly modified by Edinger.)*

Segments.	Muscles.	Reflexes.	Cutaneous areas innervated.
C. ii-iii	M. sterno-cleido-mastoideus. M. trapezius. Mm. scaleni et colli. Diaphragma.	Inspiratory reflex on quick pressure beneath ribs.	Neck and back of head.
C. iv	Diaphragma. M. supraspinatus. M. infraspinatus. M. deltoideus. M. biceps brachii. M. coraco-brachialis. M. supinator longus. M. rhomboidei.	Dilatation of the pupil on irritation of the neck (C. iv-vii).	Neck. Upper part of shoulder. Outer side of arm.
C. v	M. deltoideus. M. biceps brachii. M. coraco-brachialis. M. supinator longus. M. supinator brevis. M. pectoralis major (pars clavicularis). M. serratus anterior. Mm. rhomboidei. M. brachialis anticus. M. teres minor.	Scapular reflex (C. v-T. i). Tendon reflexes of the corresponding muscles.	Back of shoulder and arm. Outer side of upper arm and of the forearm.
C. vi	M. biceps brachii. M. brachialis anticus. M. pectoralis major (pars clavicularis). M. serratus anterior. M. triceps brachii. Mm. extensores manus et digitorum. Mm. pronatores.	Tendon reflexes of the Mm. extensores lacerti et brachii. Tendon reflexes of the muscles of the wrist.	Outer side of forearm. Back of hand and radial region.
C. vii	M. triceps brachii (caput longum). Mm. extensores manus et digitorum. Mm. flexores manus. Mm. pronatores manus. M. pectoralis major (pars sterno-costalis). M. subscapularis. M. latissimus dorsi. M. teres major.	Blow upon the palm of the hand causes closure of the fingers. Palmar reflex (C. vii-T. i).	Radial region of hand.
C. viii	Mm. flexores manus et digitorum.	Pupillary reflex.	} Distribution of N. medianus.
T. i	Mm. minores manus. Mm. extensores pollicis. Mm. minores manus. Mm. eminent. thenar. et hypothenar.	.....	
			} Ulnar region.

*Localization of Function in the Different Segments of the Spinal Cord.*  
(Continued.)

Segments.	Muscles.	Reflexes.	Cutaneous areas innervated.
T. ii-xii	Mm. dorsi. Mm. abdominis. Mm. erectores spinæ.	Epigastric reflex (T. iv-vii). Abdominal reflex (T. vii-xi).	Skin of thorax, back, abdomen, and upper gluteal region.
L. i	M. iliopsoas. M. sartorius. Mm. abdominis.	Cremaster reflex (L. i-iii).	Skin of pubic region. Anterior part of serotum.
L. ii	M. iliopsoas. M. sartorius. Mm. flexores genus (Remak ?) M. quadricieps femoris.	Patellar tendon reflex (L. ii-iv).	Outer side of hip.
L. iii	M. quadricieps femoris. Mm. rotatores femoris (inward).	.....	Anterior and inner side of thigh.
L. iv	Mm. adductores femoris. Mm. abductores femoris. Mm. adductores femoris. M. tibialis anterior. Mm. flexores genus (Ferrier ?)	Gluteal reflex (L. iv-v).	Inner side of thigh and leg as far as ankle; inner side of foot.
L. v	Mm. rotatores femoris (outward). Mm. flexores genus (Ferrier f) Mm. flexores pedis. Mm. extensores digitorum. Mm. peronæi.	.....	Back of hip and thigh and outer part of foot.
S. i-ii	Mm. flexores pedis et digitorum. Mm. peronæi. Mm. minores pedis.	Plantar reflex.	Back of thigh; outer side of leg and foot.
S. iii-v	Mm. perinæi.	Achilles tendon reflex. Vesical and rectal centres.	Skin over sacrum, perinæum, genitalia, and about anus.

The starting point for the recent studies of the grouping of the nerve cells inside the spinal cord is the exhaustive research of Waldeyer\* upon the spinal cord of the gorilla to which we have already referred. The groups designated by him, or modifications of these, are still in use.

The next important research bearing upon the topic now

\* Waldeyer, W. Das Gorilla-Rückenmark. Abhandl. d. K. Akad. d. Wissensch. zu Berlin (1888), S. 91.

under consideration is that of Kaiser.\* This author analyzed most carefully the work of previous investigators and then himself made an elaborate study of the cell groups in the ventral horns of the cervical region of the spinal cord. Nor was he satisfied with simply grouping the cells morphologically, but attempted to get at the functional meaning of the various groups of cells in the ventral horns. His findings are illustrated in Figs. 578 to 582.

The studies of von Lenhossék have already been referred to (*vide supra*).

Two American researches worthy of note must here be mentioned, that of Hammond† and that of Collins.‡ Hammond was able to state that in the third lumbar segment of the spinal cord (Fig. 583, A) the nucleus of the quadriceps femoris occupies the middle part of the ventro-lateral column of cells in the ventral horn; at the level of the tenth thoracic segment (Fig. 583, B) the cells of the abdominal muscles are situated in the ventro-lateral and intermedio-lateral columns; in the lower cervical

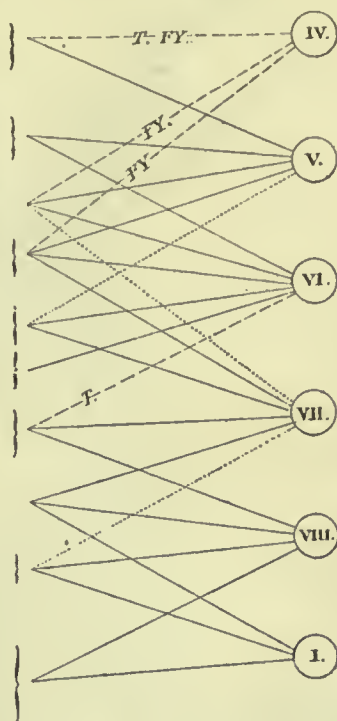


FIG. 578.—Muscle nuclei of the human cervical cord according to Forgue and Lanuegrace. (After O. Kaiser, *Die Funktionen der Ganglienzellen des Halsmarkes*, etc., Haag, 1891, S. 7.) The lines marked *T* and *FY* have been drawn with regard to the results of Thorburn and Ferrier and Yeo.

\* Kaiser, O. *Die Function der Ganglienzellen des Halsmarkes*. Haag, 1891.

† Hammond, G. *Two Cases of Progressive Muscular Atrophy; a Report of the Pathological Examination, with Special Reference to the Functions of Certain Cell Groups in the Spinal Cord*. N. Y. Med. J., vol. lix (1894), pp. 15-19.

‡ Collins, J. *A Contribution to the Arrangement and Functions of the Cells of the Cervical Spinal Cord, to which is Appended a Note on Central Changes Secondary to Long-continued Disuse of One Extremity*. N. Y. Med. J., vol. lix (1894), pp. 40; 98.

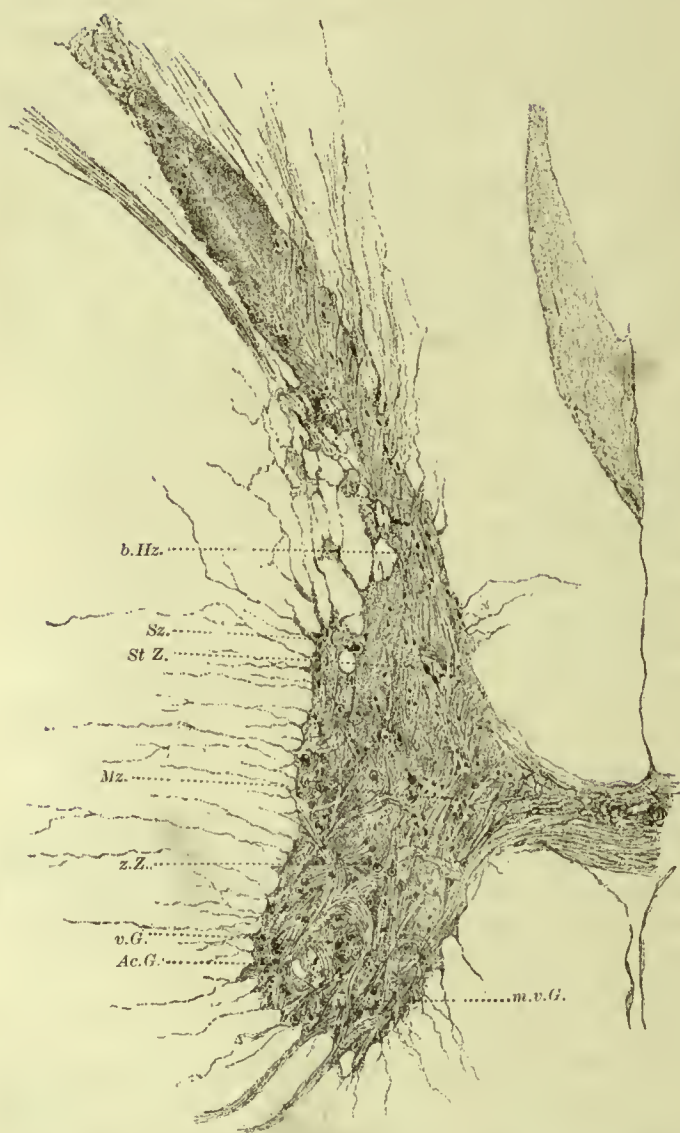

FIG. 579.—Spinal cord of adult man at level of C III, to show the grouping of the nerve cells. (After O. Kaiser, *Die Funktionen der Ganglienzellen des Halsmarkes*, etc., Haag, 1891, Taf. ii, Fig. 2.) *Ac.G.*, accessorius group; *b.Hz.*, basal cells of dorsal horn; *m.b.G.*, medial ventral group; *Mz.*, middle cells; *St.Z.*, nucleus dorsalis (cervical nucleus of Stilling); *Sz.*, cells of cornu laterale; *v.G.*, ventral group; *z.Z.*, scattered cells.



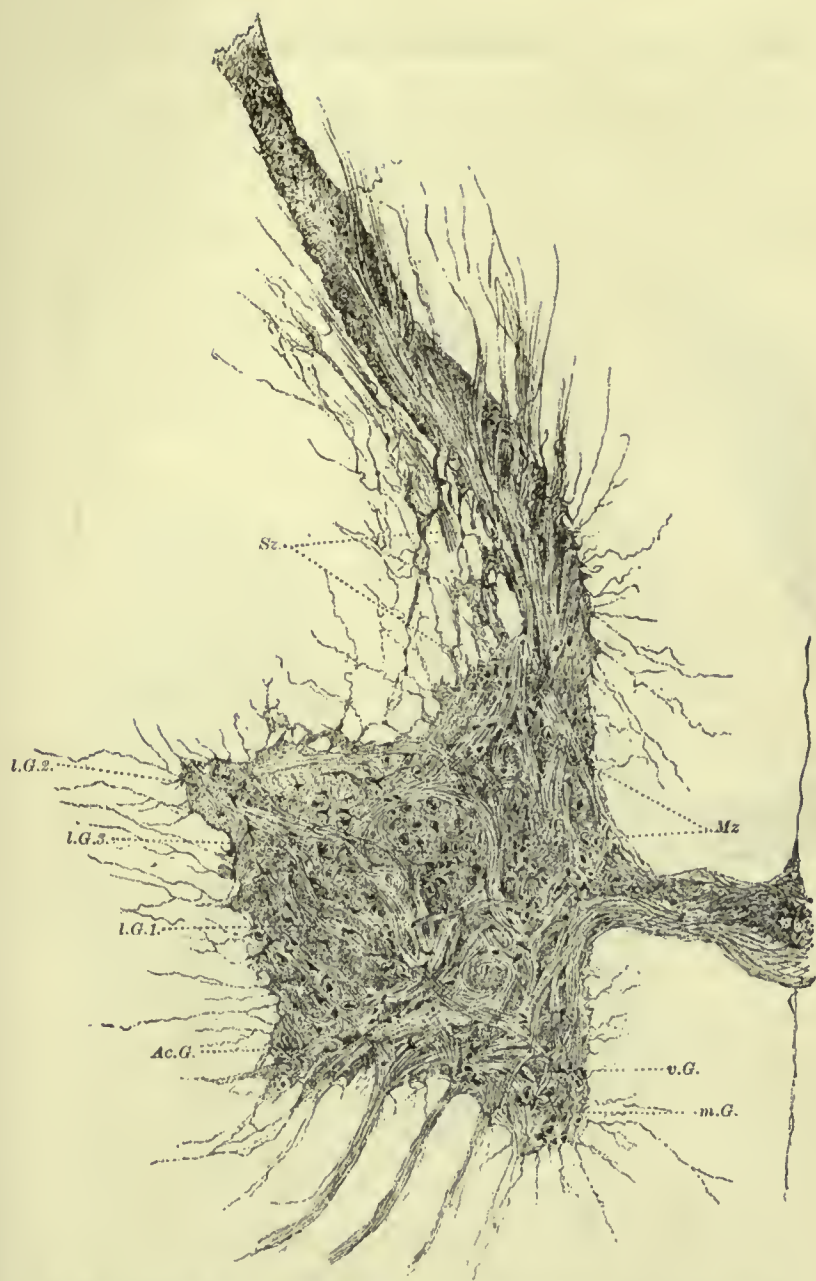

FIG. 580.—Transverse section through human spinal cord at level of C.V. (After O. Kaiser, Die Funktionen der Ganglienzellen des Halsmarkes, etc., Haag, 1891, Taf. iv, Fig. 4.) *Ac.G.*, accessorius group; *l.G.1.*, lateral group 1; *l.G.2.*, lateral group 2; *l.G.3.*, lateral group 3; *m.G.*, medial group; *Mz.*, middle cells; *Sz.*, cells of cornu laterale; *v.G.*, ventral group.

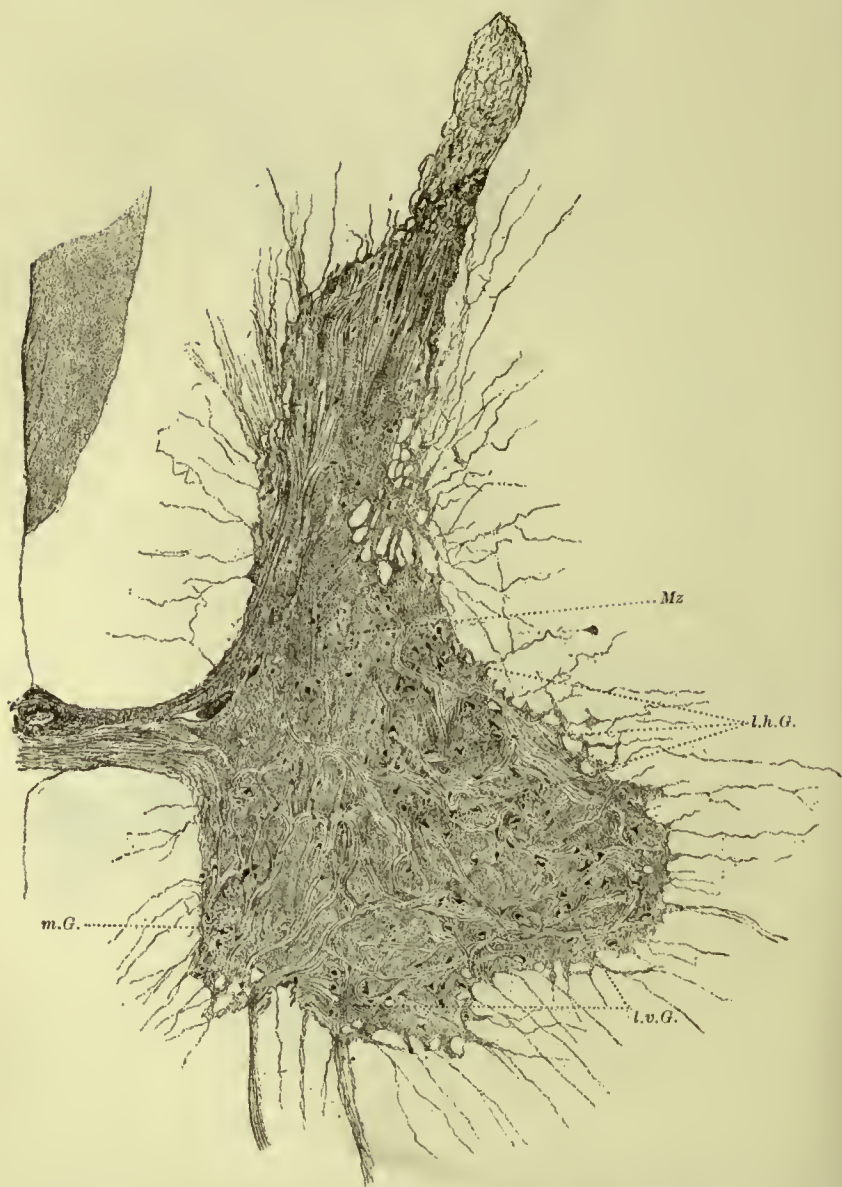


FIG. 581.—Transverse section through the human spinal cord at the level of C VIII. (After O. Kaiser, *Die Funktionen der Ganglienzellen des Halsmarkes*, etc., Haag, 1891, Taf. vii, Fig. 7.) *L.h.G.*, lateral dorsal group; *L.v.G.*, lateral ventral group; *m.G.*, medial group; *Mz*, middle cells.

region (Fig. 583, C) the nuclei of the muscles of the forearm are situated in the ventro-lateral column, while the muscles of the hand are represented behind these in the most dorsal and inferior parts of the nucleus of the superior extremity.

Collins compared the cervical enlargement from a normal cord with that from a case of poliomyelitis. By careful examination of serial sections he concluded that the vast majority of the motor cells of the cervical cord show a definite arrangement; that certain of these cells form columns which extend through several spinal segments; that definite functions can be attributed to certain groups and to certain columns of cells in-

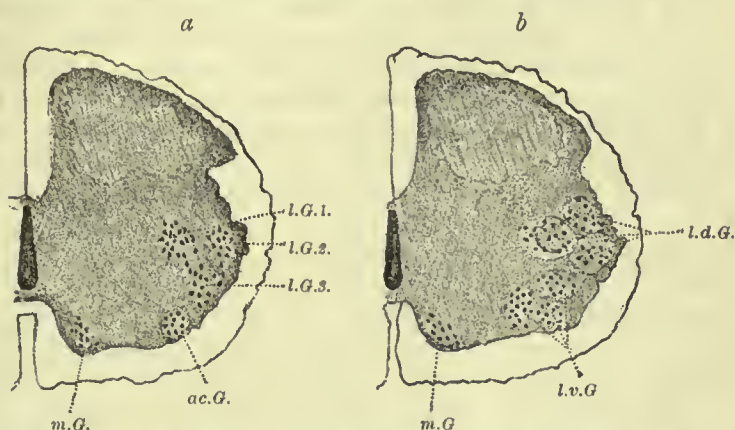


FIG. 582.—Transverse sections of the fetal human cord 18.7 cm. long. (After O. Kaiser, *Die Funktionen der Ganglienzellen des Halsmarkes, etc.*, Haag, 1891, Taf. ix, Fig. 10a and Fig. 10b.) a. Junction of C V with C VI. b. Junction of C VII with C VIII. ac.G., accessorius group; L.G.1, L.G.2, L.G.3, three portions of lateral group; L.d.G., lateral dorsal group; L.v.G., lateral ventral group; m.G., medial group.

side the spinal cord; that the main cellular groups corresponding to the brachial plexus are three in number, and extend from the upper part of the fourth cervical segment to the lower part of the first thoracic segment, the cells of the upper part of this territory innervating the muscles of the shoulder and of the arm, the cells of the lower part innervating the muscles of the arm and of the hand. The group of cells innervating the flexor muscles is situated outside and below that innervating the extensor muscles. On the other hand, the cells innervating the extensor muscles are more medially placed than those innervating the flexors. The muscles of the back are innervated, he be-

lieves, by the cells situated ventrally and medially in the ventral horn. Collins believes that the number of cells and cell groups is in direct relation with the motor functions of the parts corresponding to them topographically. The nucleus for the phrenic nerve, according to Collins, occupies the ventro-medial portion of the ventral horn at the lower part of the third cervical segment (Fig. 584).

The localization of cells corresponding to various muscles entered upon a new era with the introduction of the special method devised by Nissl in 1894.\* This method (*Methode der primären Reizung*), and some of the results to which it has led, have already been referred to in Chapter XX. It depends upon the fact that if the axone of a lower motor neurone be severed, certain definite and easily recognizable changes occur in the cell body of that neurone. There is disintegration or disappearance of the tigroid masses in the protoplasm, and the nucleus becomes dislocated to the side of the cell. The inventor's application of his own method was not so happy as that of recent investiga-

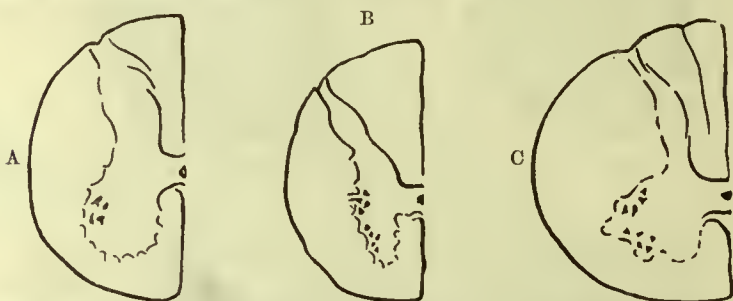


FIG. 583.—Grouping of cell bodies of lower motor neurones innervating various muscles. (After G. Hammond, N. Y. M. J., 1894, as modified by F. Sano.) A. Level of L III, cells governing M. quadriceps femoris. B. Level of T X, cells innervating the abdominal muscles. C. Level of inferior cervical cord; ventral nucleus governing muscles of forearm; dorso-lateral nucleus governing intrinsic muscles of the hand.

tors, for, instead of extirpating individual muscles, Nissl cut definite nerves such as the radial, the ulnar, and the median. He found changes in cells in the spinal cord, not in compact groups, but more or less at intervals, a fact which is not surprising

\* Nissl, F. Ueber eine neue Untersuchungsmethode des Centralorgans speciell zur Feststellung der Localisation der Nervenzellen. Centralbl. f. Nervenheilk. u. Psychiat., Coblenz. u. Leipz., Bd. xvii (1894), S. 337-374; also in Arch. f. Psychiat. u. Nervenkr., Berl., Bd. xxvi (1894), S. 597-612.



when one considers the central and peripheral relations of these nerves, and those of the neurotomes and myotomes to which they correspond. His results have been in general confirmed by Colenbrander,\* by Marinesco,† Flatau,‡ and by others. By means of this method attempts at localization in the nucleus nervi oculomotorii have been made by Bernheimer# and Schwabe|| (*vide infra*).

J. Erlanger, in Prof. Mall's laboratory in Baltimore, has used this method to determine the position of the cells in the spinal cord, which innervate the biceps muscle in rabbits. After extirpating the muscle or cutting the motor nerve going to it he studied the changes in serial sections in the spinal cord, the animals having been killed fifteen days after the experiments.

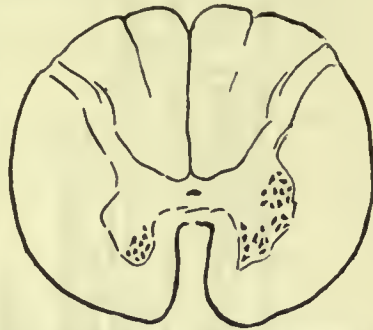

FIG. 584.—Diagram of the human spinal cord at the level of C III from a case of poliomyelitis. (After J. Collins, N. Y. M. J., 1894, as modified by F. Sano.) The nucleus of the phrenic is shown.

A most important series of researches in this connection have been undertaken by Sano,<sup>^</sup> who has studied a number of spinal cords by Nissl's method after amputation, and has made a number of ingenious experiments on cats, pigeons, and rabbits. From

\* Colenbrander. Over de Structuur der Gangliencel uit den boorsten Hoorn (1896), cited by Sano.

† Marinesco. *Op. cit.*

‡ *Op. cit.*

# Bernheimer, S. Zur Kenntniss der Localisation in Kerngebiete des Oculomotorius. Wien. klin. Wchnschr., Bd. ix (1896), No. 5.

|| Schwabe, H. Ueber die Gliederung des Oculomotoriushauptkerns und die Lage der den einzelnen Muskeln entsprechenden Gebiete in demselben. Neurol. Centralbl., Leipz., Bd. xv (1896), S. 792-794.

<sup>^</sup> Sano, F. Les localisation motrices dans la moelle lombo-sacrée. J. de neurol. et hypnol., Par., t. ii (1897); Les localisations motrices dans la moelle épinière. Communication au Congrès de Neurologie et d'Hypnologie, Septembre. Bruxelles. Résumé dans le J. de neurol. et hypnol., 1897; Les localisations des fonctions motrices de la moelle épinière. Annales de la Société Médico-Chirurgicale d'Anvers, 19 Novembre (1897); De la constitution des noyaux moteurs médullaires. J. de neurol. et hypnol. (1898), p. 62; Localisations médullaires motrices et sensitives. *Ibid.* (1898), p. 129.

the results of these and a very careful consideration of the literature, this author has formulated his views concerning the con-

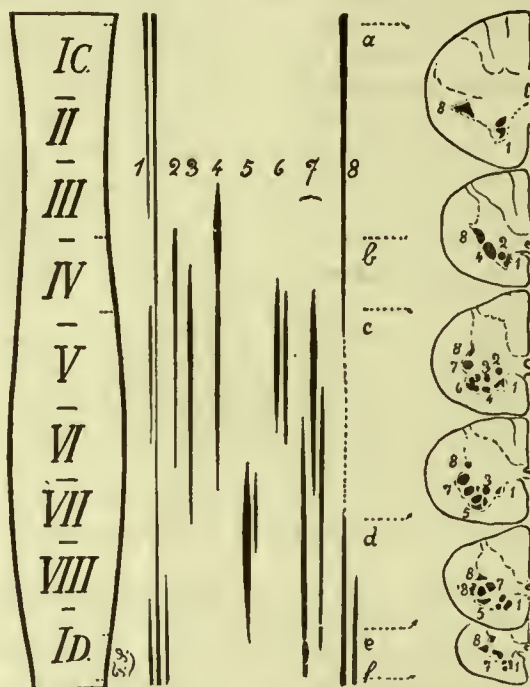


FIG. 585.—Columns of gray matter and motor nuclei of *intumescentia cervicalis*. (After F. Sano, *Les Localisations des fonctions motrices de la moelle épinière*, Anvers, Bruxelles, 1898, p. 32.) *Columna medialis*—1. *a*, short rotators of head; *M. subhyoid* muscles; *b, c, d, e, f*, extensors and rotators of the vertebral column. 2, nucleus diaphragmatis (the series of sympathetic nuclei composed of small cells have not been drawn in); they are situated behind the *columna medialis* near the *columna canalis centralis*. *Columna intermedio-lateralis*—8. *a*, accessorius *M. trapezius* and *M. sterno-cleido-mastoideus*; *b, c*, plexus cervicalis; *Mm.* trapezius sterno-cleido-mastoideus; *d, e*, middle portion of *M. trapezius*; *f*, inferior part of *M. trapezius*; *e*, beginning of the nucleus for the *M. latissimus dorsi*. *Columna extremitatis superioris*—3. *Mm.* pectorales; 4. *b, M. levator scapulae*; *c, M. serratus major*; 6, muscles of the shoulder; 7. *c, M. biceps*; lower down supinators and extensors of the fingers; between *d* and *e* flexores and pronators; *e*, thenar and hypothenar muscles; *f*, hypothenar muscles; 5. *d, M. triceps brachii*; *e, M. anconæus*.

stitution of the columns of motor cells in the spinal cord. His work is of value and interest and should be consulted by every one who wishes to become familiar with the most recent findings dealing with spinal motor localization.

In brief, Sano distinguishes, as do most neurologists, in the ventral horn two longitudinal columns of motor cells which are

almost constant throughout the whole length of the cord—the *columna medialis* and the *columna intermediolateralis*;\* on transverse section these are designated the nuclei mediales and the nuclei intermediolaterales. Each of these columns may be subdivided in places into two, three, or four secondary columns.

Between the *columna medialis* and the *columna intermedio-*

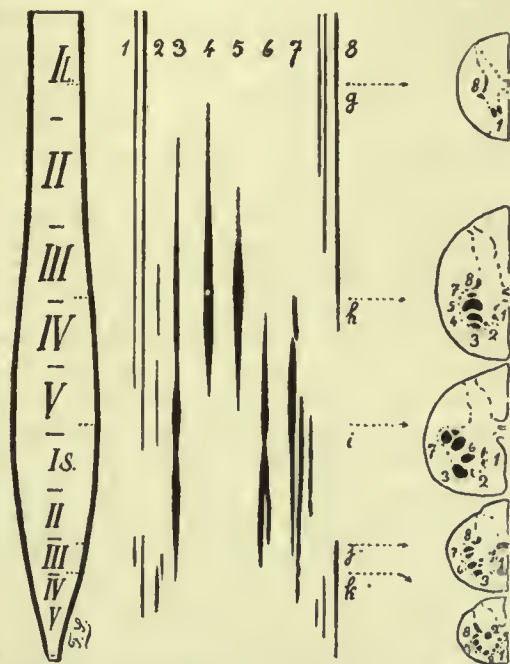


FIG. 586.—Columns of gray matter and motor nuclei of the intumescencia lumbalis. (After A. Sane, *Les Localisations des fonctions motrices de la moelle épinière*, Anvers, Bruxelles, 1898, p. 33.) *Columna medialis*—1. *g, h, i*, extensor and rotator muscles of the spine; *j, k*, musculus ischiococcygeus and *M. levator ani*; 2. *k*, in front *M. sphincter vesicalis*; behind *M. sphincter ani*; the sympathetic nuclei are not figured for the visceral muscles. *Columna intermediolateralis*—8. *g*, abdominal muscles; *h*, *M. cremaster*; *j, k*, muscles of the perineum. *Columna extremitatis inferioris*—2. *i*, *M. pyramidales*; 3. *h*, *M. ilio-psoas*; *i*, *Mm. glutæi*; *j*, *Mm. gemelli*, *M. pyriformis*; 4. *M. quadriceps femoris*; 5. *M. pectoneus*; *Mm. adductores*; 6. *i*, flexors of the knee; lower down *M. popliteus*, *M. triceps suræ*; *j*; 7. *h*, *M. tibialis anticus*; *i*, extensor muscles of the toes, *Mm. peronei*; lower down, *M. tibialis posticus*; flexors of the toes; *j, k*, intrinsic muscles of the foot.

\* The term *columna intermedio-lateralis* corresponds to the *Seitenhornzellen* of Waldeyer. These, together with his *Mittelzellen*, correspond to J. Lockhart Clarke's *Tractus intermedio-lateralis*, described in his *Further Researches on the Gray Substance of the Spinal Cord*. Phil. Trans. Roy. Soc., Lond., Bd. cxlix (1859).

lateralis there are intercalated, in the cervical and lumbar enlargements, longitudinal motor nuclei of considerable size which are related especially to the muscles of the extremities. These intercalated nuclei are known in the cervical enlargement as the *columna extremitatis superioris* (Kaiser's nucleus extremitatis superioris), and in the lumbar enlargement as the *columna extremitatis inferioris*.

In Fig. 585 the various nuclei in the cervical enlargement are shown not only in their longitudinal extent, but also in their reciprocal positions in transverse section. In Fig. 586 the motor nuclei of the lumbar enlargement are represented. If the legends accompanying these be carefully consulted they will, it is believed, be understood without further description. It is to be remembered that not every one of these nuclei has as yet been definitely established by means of Nissl's method, but the figures represent accurately the present status of knowledge gained from a great many different sources. The articles of Flatau\* and van Gehuchten† may with profit be consulted in this connection.

On the whole, then, it is seen that in the spinal cord each muscle is represented by a nucleus of ventral horn cells. Further, each segment of the spinal cord may contain portions of the nuclei of a number of different muscles; and these portions, judging from electrical excitation of a whole ventral root, may correspond to a very complex movement. Section of the ventral root, as Warrington has shown, leads to degeneration of the nerve cells in all the groups in a given segment. Russell's experiments, in which he excited electrically the individual bundles of a single ventral root, render it almost certain that the very complex movement represented in a whole ventral root can be analyzed into a large series of simpler component movements. The nerve cells corresponding to these individual simpler component movements have not been localized inside the spinal cord, but there can be but little doubt that they will be at some later time.

---

\* Flatau, E. Ueber Veränderungen im menschlichen Rückenmark nach Wegfall grösserer Gliedmassen. Deut. med. Wchnsehr., Bd. xxiii (1897), S. 278-279.

† van Gehuchten, A. L'Anatomie fine de la cellule nerveuse. Verhandl. d. Internat. Congr., Moscow, 1897.



(B) Those pertaining to the Rhombencephalon, Isthmus, and Mesencephalon.

## CHAPTER LVI.

### THE LOWER MOTOR NEURONES (CONTINUED).

Lower motor neurones above the spinal cord—Columna medialis—Columna lateralis—Curves of central canal—The so-called “head-cavities”—Proximal or proötic cavities—Distal or postotic cavities—Cephalic myotomes—The so-called “components” of the peripheral nerves—Somatic motor, somatic sensory, visceral motor, visceral sensory, and acustico-lateral components—N. hypoglossus—N. accessorius—N. vagus—N. glossopharyngeus—N. facialis—N. abducens—N. trigeminus—N. trochlearis—N. oculomotorius.

THE lower motor neurones pertaining to the rhombencephalon and mesencephalon are those the axones of which go to make up the motor cerebral nerves. Continuous with the motor gray columns in the cord are similar columns, though less regular and more interrupted in the medulla, pons, and midbrain. The motor cells in these upper regions (Fig. 587) are divided into two very distinct longitudinal masses, one placed more medially, the other more laterally. To the medial column passing from below upward belong the nucleus N. hypoglossi and the nucleus N. abducentis; while to the lateral column passing from below upward belong the motor nuclei of the N. accessorius, N. vagus, N. glossopharyngeus, N. facialis, N. trigeminus, and probably also the nucleus N. trochlearis and the nucleus N. oculomotorii, although there is some doubt as to whether the last two nuclei belong to the lateral or to the medial column of motor cells. In the medulla oblongata the motor cells form almost a continuous column, but in the pons, isthmus, and midbrain there are wide interspaces between the groups of motor cells.

The central canal, in passing from the cord to the ventriculus tertius, shows two marked curves. The first is at the junction of cord and medulla, where the canal curves rapidly dorsalward to

open into the ventriculus quartus. The second is above the aqueductus cerebri (Sylvii), where the canal curves ventralward to enter the ventriculus tertius. It will be noticed that the longitudinal fibres near the raphe follow the same curve. Opposite

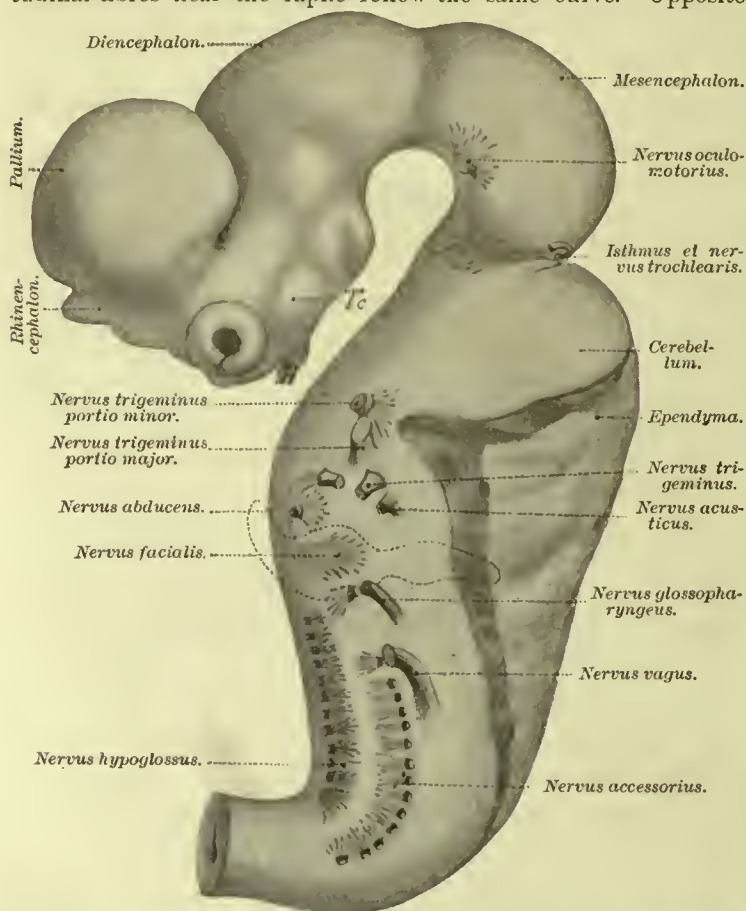


FIG. 587.—Brain, showing the origin and termination of the nervi cerebrales; human embryo. From a reconstruction enlarged about eighteen times. (After W. His, taken from J. Kollmann's *Lehrbuch der Entwicklungs-geschichten des Menschen*, Jena, 1898, S. 542, Fig. 331.) *Tc*, tuber cinereum; *H*, hypophysis.

the lower curve the fibres of the fasciculus ventralis proprius pass dorsalward to enter the fasciculus longitudinalis medialis. Opposite the upper curve the fibres of the fasciculus longitudinalis medialis pass ventralward to the region of the nucleus fasciculi

longitudinalis medialis (nucleus of Darkschewitsch). The two cerebral motor nuclei of these regions—namely, the nucleus nervi hypoglossi and the nucleus nervi oculomotorii—conform also to the curve, so that when looked at from the side, these two nuclei are seen to lie obliquely to the long axis of the medulla, pons, and midbrain.

The cell bodies in all these nuclei are very much like those of the spinal motor cells, being typical multipolar stichochrome cells. Their axones plunge out as a rule almost directly into the peripheral nerves. The exceptions to this rule are met with in the motor axones of the ninth and tenth, which run backward from the nucleus ambiguus toward the floor of the ventricle, then to run out in the same bundle in which enter the sensory portions of these nerves. The fibres of the seventh nerve make a remarkable discursion after leaving their nucleus. They pass upward and medialward (*pars prima*) to the inner side of the nucleus nervi abducentis, then pass cerebralward along the floor of the fourth ventricle for a short distance (*genu internum*), and again turn lateralward and afterward ventralward (*pars secunda*), to take their exit from the central nervous system at the junction of the medulla with the pons. The most remarkable behavior of axones is perhaps that met with in connection with the fourth cerebral nerve. Although the nucleus N. trochlearis is situated in the isthmus ventral to the aqueductus cerebri, all its axones pass dorsal to the aqueduct, and undergo total decussation with the fibres from the opposite side. The relations of the cerebral and upper spinal nerve roots to the central nervous system are clearly visible in Fig. 588.

The axones of the cerebral motor nerves run in the peripheral nerve trunks to the muscles which they govern, and end on the muscle fibres as typical motor telodendria, just as do the spinal nerves. The periods of myelinization of the various cerebral nerves has recently been very carefully established by Westphal.\*

Much work has been done, especially from the embryological side, with the view of establishing the exact relation of the lower motor neurones corresponding to the cerebral nerves and the muscles which they supply. It would appear that the muscles

---

\* Westphal, A. Ueber die Markscheidenbildung der Gehirnnerven des Menschen. Arch. f. Psychiat. u. Nervenkr., Berl., Bd. xxix (1897), S. 474-527.

of the head, of the eyes, and of the middle ear arise from certain so-called "head cavities," which appear at a certain period of development in the mesoderm of the head. As has been pointed

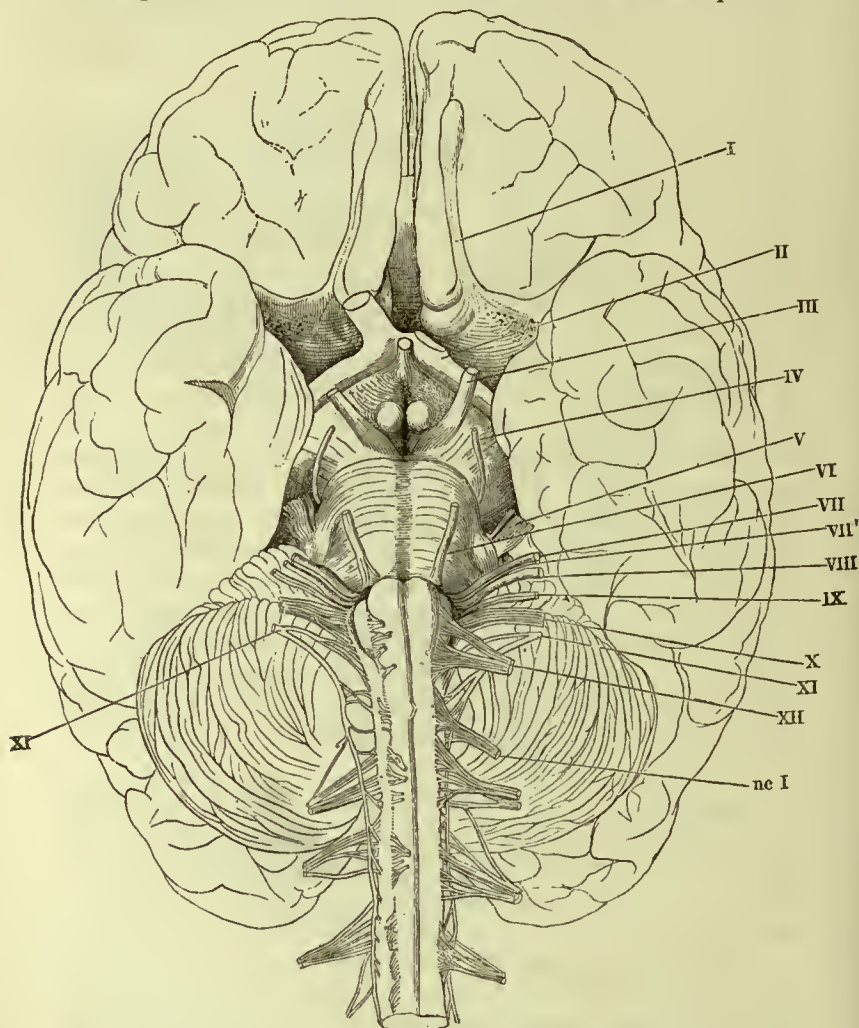


FIG. 588.—Cerebrum, with a portion of the spinal cord, viewed from the ventral surface. On the right-hand side the ventral roots are cut off short and turned medialward. (After Rüdinger and Henle, from A. Rauber's text-book.) *I*, tractus olfactorius; *II*, tractus opticus; *III*, N. oculomotorius; *IV*, N. trochlearis; *V*, N. trigeminus, portio major et portio minor; *VI*, N. abducens; *VII*, N. facialis; *VII'*, N. intermedius; *VIII*, N. acusticus; *IX*, N. glossopharyngeus; *X*, N. vagus; *XI*, N. accessorius; *XII*, N. hypoglossus; *nc I*, N. cervicalis primus.



out in Chapter XVIII, there is some dispute as to the exact nature and origin of these head cavities. Whereas many observers, and it would seem the majority at present, look upon them as portions of myotomes, others regard them as corresponding to cut-off portions of the body cavity. According to the former view, the muscles of the head and eyes would be a part of the general skeletal musculature, while according to the second view they would represent portions of the visceral musculature.

Assuming for the moment that they are portions of the skeletal musculature, and have their origin in myotomes, it will be interesting to refer, if only briefly, to the views held with regard to certain details of their development. Most observers seem to look upon the "head cavities" as corresponding to the ventral fields of the myotomes, the dorsal fields having disappeared, owing to the great extent of the capsule of the brain, which, on account of its firmness and immobility, makes a dorsal musculature superfluous (Kollmann).

The relations have been perhaps best studied in the bony fishes in which nine cephalic myotomes are distinguished, four of which are proximal or proötic—that is, lying in front of the auditory vesicle—and five distal or postotic, lying behind the auditory vesicle.\* Thus far the proötic cephalic cavities have not been made out in man or in mammals, although it is not impossible that traces of them may yet be found. The relation of the individual muscles in man to cephalic myotomes is up to the present time largely a matter of speculation, but it is believed that the muscles supplied by the N. oculomotorius are derived from the first proötic myotome or cephalic cavity (Fig. 589), the muscles supplied by the N. trochlearis from the second proötic myotome, and the muscles supplied by the N. abducens from the third myotome.

The fourth myotome is supposed to give rise to the muscles of mastication (Fig. 590), the M. tensor tympani and the M. tensor veli palatini, all supplied by the motor part of the N. tri-

---

\* The reader is referred to the articles of Gegenbaur, van Wighe, Rabl, Renter, Harrison, Corning, and especially to the publications of von Kupffer, C., *Die Entwicklung von Petromyzon Planeri*. Arch. f. mikr. Anat., Bonn, Bd. xxxv. (1890), S. 469–558.—The Development of the Cranial Nerves of Vertebrates. J. Comp. Neurol., Cincin., vol. i (1891), p. 246.—And Studien zur vergleichenden Entwicklungsgeschichte der Kranioten. München, H. 3, 1895.

geminus. It has been suggested also that the *M. mylohyoideus* and the anterior belly of the *M. digastricus*, on account of their innervation, are also derived from the fourth cephalic cavity.

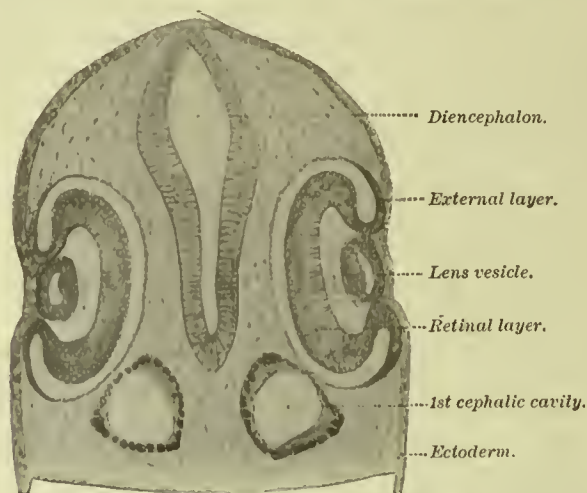


FIG. 589.—First cephalic cavity; præchordal part of skull. *Lacerta viridis* of twenty-eight primitive segments. (After a preparation by Corning, from J. Kollmann's *Lehrbuch der Entwicklungsgeschichte des Menschen*, Jena, 1898, S. 294, Fig. 167.)

The myotome corresponding to the *N. facialis* gives rise to the whole musculature of the face, the *platysma*, the *M. stapedius*, the *M. levator veli palatini*, and the *M. uvulæ*.

The ventral processes of the five postotic myotomes (lying in the chordal part of the head) give rise in the bony fishes and in reptiles to the muscles of the tongue (Fig. 591). This has not been definitely proved in man and mammals, but from the behavior of the *N. hypoglossus* and the relations of this nerve to the muscles concerned, it seems likely that a similar origin will be found true in them.

The *N. accessorius* is primarily a spinal nerve, and the myotomes corresponding to it are myotomes of the trunk, not cephalic myotomes.

The comparative morphology of this region, so important for the proper understanding of the problems of cephalogenesis, has been discussed in a recent paper by Fürbringer.\*

---

\*Fürbringer, M. Ueber die spino-occipitalen Nerven der Selachier und Holocephalen und ihre vergleichende Morphologie. Festschrift f. Gegen-

The comparative morphology of the cerebral nerves has been carefully studied, by Huxley, Gegenbaur, Strong, Ewart, Herriek, Kingsbury, Pinkus, Cole, Allis, E. L. Mark and his associates, and others.

This seems a suitable place to mention the ideas which have been developed, especially by American morphologists, concerning the *components* of the peripheral nerves. In this connection the researches of Strong, Herriek,\* Shore, Cole, Kingsbury,† Johnston,‡ and others may be referred to.

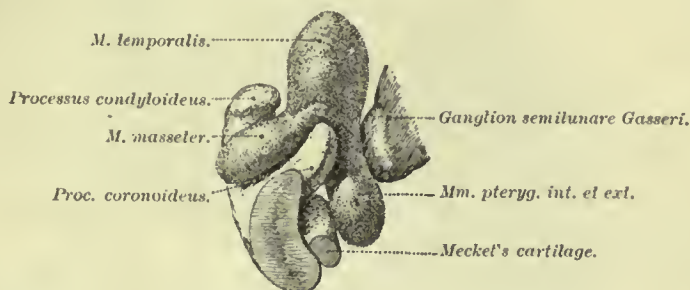


FIG. 590.—Development of muscles of mastication. Reconstruction from a pig's embryo 18 mm. long. (After Reuter, taken from J. Kollmann's *Lehrbuch der Entwicklungsgeschichte des Menschen*, S. 295, Fig. 168.)

These investigators recognize in a typical spinal nerve (in the gnathostome vertebrates) four different components:

- (1) A somatic motor component originating in the ventral horn cells.
- (2) A somatic sensory or general cutaneous component, the axones terminating in the dorsal horn.
- (3) A visceral motor component.
- (4) A visceral sensory component. The exact central relations of the visceral components have not yet been satisfactorily worked out, though the general opinion seems to be that the sen-

---

baur, Leipz. (1897), S. 351-788. Herriek has published a full review of this article, together with tables illustrating the metamerism of the spinal and cerebral nerves, in the *Journal of Comparative Neurology*, vol. vii (1898), pp. 25-48.

\* Herriek, C. J. The Cranial Nerves of the Bony Fishes. *J. Comp. Neurol.*, Granville, vol. viii (1898), pp. 162-170.

† Kingsbury, B. F. The Encephalic Evagination in Ganoids. *J. Comp. Neurol.*, Granville, vol. vii (1897), p. 37.

‡ Johnston, J. B. *Anat. Anz.*, Jena, Bd. xiv (1896), S. 22-23.

sory visceral fibres enter the cord by the dorsal root, the visceral motor fibres leave the cord by the ventral root, in higher mammals, and by both dorsal and ventral roots in inframammalian

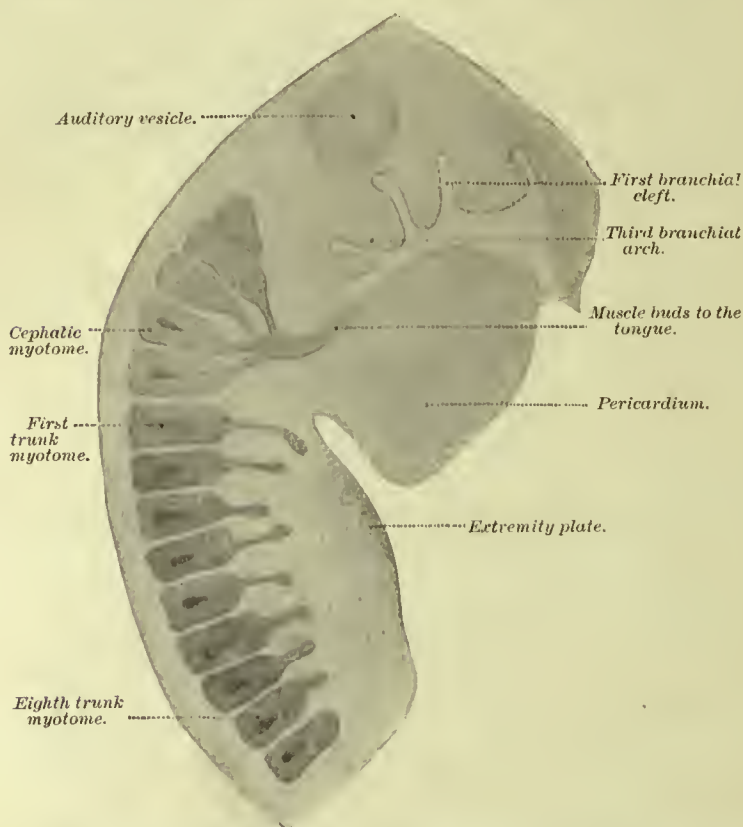


FIG. 591.—Embryo of *lacerta viridis*; combined picture to show especially the origin of the muscles of the tongue. (After Corning, taken from J. Kollmann's *Lehrbuch der Entwicklungsgeschichte des Menschen*, Jena, 1898, S. 296, Fig. 169.)

groups. In the spinal cord it is believed that both sorts of fibres are related to the columna intermedialis or region of the cornu laterale, the motor fibres in all probability arising there, and the sensory fibres terminating there.

Herriek, in his study of the cerebral nerves of the bony fishes, states that in the cerebral nerves these four components are present, and in addition a fifth component, the so-called acustico-



lateral. The somatic motor component, for example, is represented by the motor nerves of the eye muscles, the somatic sensory or general cutaneous component by the general sensory fibres of the nervus trigeminus and the nervus vagus. The

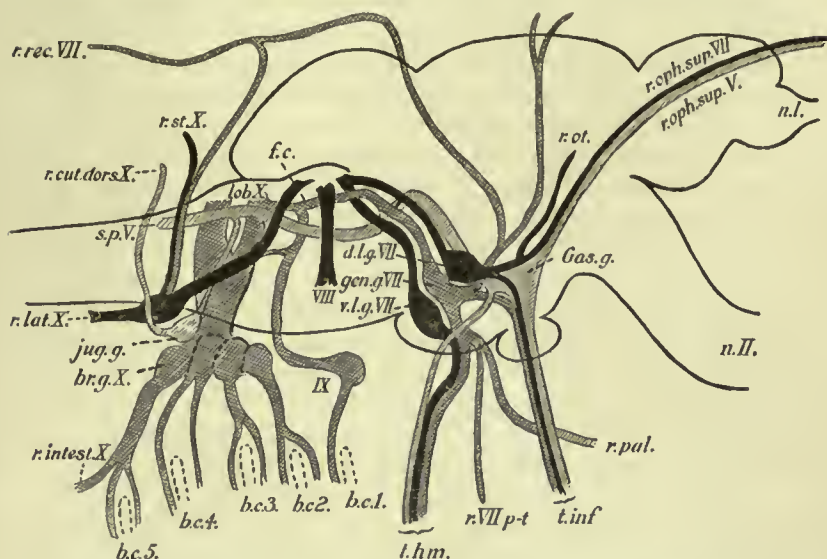


FIG. 592.—A diagrammatic view of the sensory components of the cerebral nerves of *Menidia*, as seen from the right side. The diagram is based upon a projection of the cerebral nerves upon the sagittal plane made by reconstruction from serial sections. The general cutaneous component is indicated by the single cross-hatching the communis component by double cross-hatching and the acustico-lateral is drawn in black. (After C. J. Herrick, *J. Comp. Neurol.*, Granville, vol. viii, 1898.) *bc.1* to *bc.5*, the five branchial clefts; *br.g.X*, the ganglia of the four branchial rami of the vagus, the last one containing also the ganglion of the *r. intestinalis*; *d.l.g.VII*, the dorsal lateral line ganglion of the seventh nerve; *f.c.*, fasciculus communis; *Gas.g.*, Gasserian ganglion; *gen.g.VII*, geniculate ganglion of the seventh nerve; *IX*, the glosso-pharyngeal nerve and its ganglion; *Jug.g.*, the general cutaneous ganglion of the vagus nerve (jugular g. of Shore and Strong); *lob.X*, the lobus vagi; *n.I*, the olfactory nerve; *n.II*, the optic nerve; *r.cut.dors.X*, ramus cutaneous dorsalis of the vagus; *r.intest.X*, ramus intestinalis of the vagus; *r.lat.X*, ramus lateralis of the vagus; *r.oph.sup.V*, ramus ophthalmicus superficialis trigemini; *r.oph.sup.VII*, ramus ophthalmicus superficialis facialis; *r.ot.*, ramus oticus; *r.pal.*, ramus palatinus facialis; *r.rec.VII*, ramus recurrens facialis; *r.st.X*, ramus supratemporalis vagi; *r.VII p-t*, ramus pre-trematicus facialis; *sp.V.t*, tractus spinalis nervi trigemini; *t.a*, the tuberculum acusticum; *t.hm*, truncus hyomandibularis of the facial nerve; *t.inf*, infra-orbital trunk, containing the *r. mandibularis V*, the *r. maxillaris V*, and the *r. buccalis VII*, together with communis fibres; *VIII*, the eighth nerve; *v.l.g.VII*, the ventral lateral line ganglion of the seventh nerve.

visceral motor component corresponds to the motor fibres of the other cerebral nerves, and these fibres leave the brain by dorsal roots to become distributed to the branchial musculature. The

visceral sensory component as well as the visceral motor component is very largely developed, and, according to Herrick, is represented by the communis system of the nervus vagus, nervus glossopharyngeus, and nervus facialis. The fibres of this component terminate either directly or by mediation of the fasciculus communis in the vagal lobe which corresponds to the nucleus alæ cinereæ of higher forms. The communis system of the head itself differs from the corresponding visceral sensory system of the trunk in that it receives fibres from the taste buds and from other sense organs not belonging to the system of the lateral line. By the acustico-lateral system is meant the structure which receives fibres from the ear and from the organs of the lateral line, but no other fibres. These fibres in the bony fish terminate apparently together in the tuberculum acusticum. The motor fibres for the unstriped visceral musculature pertaining to the cerebral nerves are, like those in the spinal nerves, very small, while those for the striated visceral musculature of the branchial arches and for the somatic eye muscles are large. The fibres of the acustico-lateral system are of two sorts; those from the organs of the lateral line are usually large, while the auditory fibres are of medium size.

The general cutaneous fibres are usually of small size or of medium size, while the visceral sensory system (or communis system of the head) consists of very small fibres. In Fig. 592 is reproduced the diagram which accompanies Herrick's article, and which illustrates the relations of the sensory components in the cerebral nerves of *Menidia*.

The various groups of motor neurones corresponding to the individual motor cerebral nerves may now be properly considered somewhat more in detail.

#### 1. Those the Axones of which belong to the N. Hypoglossus.

Those corresponding to the N. HYPOGLOSSUS have their cells of origin in the so-called nucleus N. hypoglossi. This consists of a gray column some eighteen mm. long, from one to two mm. broad, and about one mm. in thickness. It corresponds to the continuation upward into the medulla oblongata of the medial portion of the ventral column of gray matter of the spinal cord. In its lower part it lies ventral to the central canal of the medulla oblongata. Above, the column is thicker and is situated beneath the floor of the fourth ventricle adjacent to the sulcus medianus on either side. It extends anteriorly as far as the region of the



FIG. 593.—Diagram prepared by Miss F. Sabin from a series of sections through the brain of a new-born babe, showing the nuclei of the cerebral nerves and the area of exit and of entrance of the roots of the cerebral nerves in flat projection. *a*, line of lateral edge of fourth ventricle; *d, d, d, d*, fovea inferior; *e*, fovea superior; *g*, lateral surface of rhombencephalon; *III.*, area of exit of N. oculomotorius; *IV.*, area of exit of N. trochlearis; *V.*, area of exit and entrance of N. trigeminus; *VI.*, area of exit of N. abducens; *VII.*, area of exit of N. facialis; *VIII. (coch.)*, area of entrance of N. cochleæ; *VIII. (vestib.)*, area of entrance of N. vestibuli; *IX. and X.*, area of entrance of N. glossopharyngeus et vagus; *XI.*, area of exit of N. accessorius; *XII.*, area of exit of N. hypoglossus; *Nu.n.III.*, nucleus N. oculo-motorii; *Nu.n.IV.*, nucleus N. trochlearis; *Nu.n.V.(m.p.)*, nucleus motorius princeps N. trigemini; *Nu.n.VI.*, nucleus N. abducens; *Nu.n.VII.*, nucleus N. facialis; *Nu.a.*, nucleus ambiguus; *Nu.a.c.*, nucleus alæ cineræ; *Nu.n.v.m.*, nucleus N. vestibuli medialis; *Nu.n.v.s.*, nucleus N. vestibuli superior; *Nu.n.v.l.*, nucleus N. vestibuli lateralis (Deiters); *Nu.n.c.d.*, nucleus N. cochleæ dorsalis; *Nu.n.c.v.*, nucleus N. cochleæ ventralis; *Nu.n.XII.*, nucleus N. hypoglossi; *R.d.n.t.*, radix descendens [mesencephalic] N. trigemini; *R.d.n.v.*, radix descendens N. vestibuli; *S.g.*, substantia gelatinosa; *T. sol.*, tractus solitarius; *Tr.s.n.t.*, tractus spinalis N. trigemini; *Vent.*, ventral horn cells. The numbers to the left of the drawing indicate approximately the levels of the corresponding transverse sections represented by Figs. 308 to 317.

The plane of the sections from which this diagram was made is not quite transverse but somewhat oblique; the dorsal surface of the medulla has been struck by the knife more cerebralward than the ventral surface, the angle formed by the plane of the section with the longitudinal axis being approximately seventy degrees, as measured on the cerebral side. This accounts for the evident (slight) displacement cerebralward of the structures in the ventral portions of the sections as compared with those in the dorsal portions.





striae medullares. It is separated from the floor of the fourth ventricle by some gray matter which corresponds to the general stratum griseum centrale. In this are a number of fine white fibres which give the opaque whitish appearance on the surface of the trigonum N. hypoglossi. Posteriorly, as is seen from Fig. 593, the nucleus N. hypoglossi is overlapped by the nucleus alae cinereae.

The more or less spherical mass of small ganglion cells lying ventral to the nucleus N. hypoglossi is the so-called small-celled hypoglossal nucleus of Roller. It probably, however, has no direct connection with the N. hypoglossus. The group of small cells lying just medial to the hypoglossal nucleus in its upper half continues with a mass of cells running longitudinally; in the floor of the fourth ventricle is the so-called nucleus funiculi teretis. On its lateral side and between it and the nucleus alae cinereae is situated an anterior group of small nerve cells, the *nucleo intercalato* of Staderini.

The cells in the nucleus N. hypoglossi are typical motor cells. Their axones pass ventralward and slightly lateralward and—partly after perforating the medial accessory olive, and even portions of the nucleus olivaris inferior, partly by passing between the nucleus olivaris inferior and the medial accessory olive—arrive on the surface of the medulla oblongata in the sulcus lateralis ventralis, appearing in the form of from ten to fifteen fila radicularia. A few fibres may pass from the nucleus of one side through the raphe into the nerve of the opposite side; but this is disputed.

The fibres are coarse and much branched, and, according to van Gehuchten and Ramón y Cajal, may extend even as far as the nucleus of the other side so as to form a definite protoplasmic commissure.

The nucleus N. hypoglossi receives from its lateral and ventral surfaces an enormous number of collaterals and terminals, part of which are sensory, while part, in all probability, represent fibrils coming from axones higher up in the nervous system (possibly fibres of the pyramidal tract). The sensory fibres appear to have their origin from the axones of cerebral sensory neurones both of the first order and of the second order (Fig. 594).

In the embryo the N. hypoglossus, like the spinal nerves, is provided with a dorsal sensory root and sensory ganglion, or occasionally with dorsal sensory roots and sensory ganglia. We have seen that the N. hypoglossus corresponds apparently to at least five neurotomes, since it innervates muscles derived from no less

than five myotomes. Thus far, however, only two sensory ganglia and dorsal hypoglossal roots have been observed in higher animals (in the cat by P. Martin); in man a single hypoglossal ganglion (Froiep) has occasionally been observed, but only rarely.

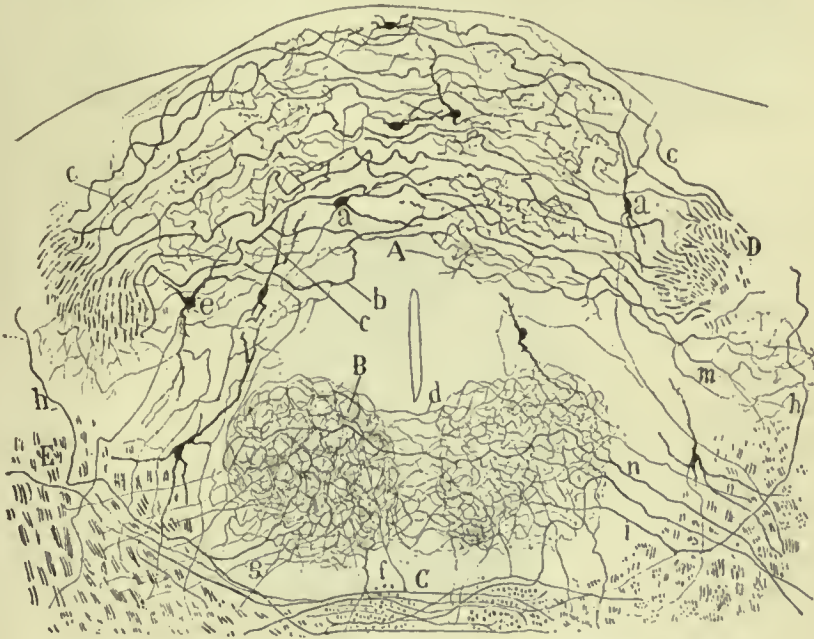

FIG. 594.—Transverse section through the medulla oblongata of a mouse at the level of the nucleus commissuralis. (After S. Ramón y Cajal, *Beitrag zum Studium der Medulla Oblongata*, etc., Bresler, Leipz., 1896, S. 47, Fig. 12.) A, nucleus commissuralis; B, nucleus N. hypoglossi; C, decussatio lemniscorum; D, transverse section of tractus solitarius; E, central path for N. N. IX; a, cell of nucleus commissuralis; b, c, terminal fibres of N. vagus et N. glossopharyngeus; d, commissure formed by collaterals of hypoglossal nuclei; g, f, collaterals of sensory axones of the second order for the nucleus N. hypoglossi.

The upper motor neurones bringing the nucleus nervi hypoglossi under the influence of the pallium will be described further on. The nucleus N. hypoglossi is, of course, of especial clinical interest on account of its connection with disturbances of speech.

## 2. Those the Axones of which belong to the N. Accessorius.

The lower motor neurones corresponding to the N. ACCESSORIUS are usually described as being partly spinal, partly cerebral, in origin.

Embryological studies warrant the conclusion that originally the nervus accessorius is distinctly a spinal nerve, its cerebral connections being made only secondarily. This is proved not only by investigations on its nucleus of origin inside the central nervous system, but also by the fact that it innervates muscles which have their origin in myotomes belonging to the trunk. Rudimentary ganglia have been observed upon it by Chiarugi.

The so-called cerebral part of the N. accessorius in all probability belongs to the N. vagus.

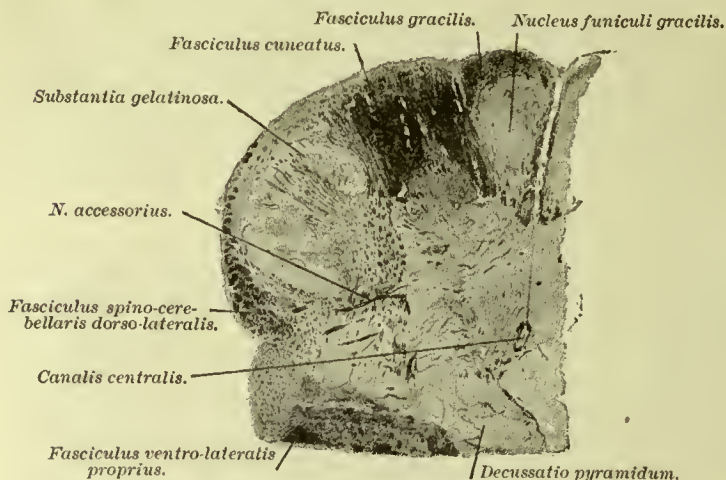


FIG. 595.—Transverse section through one side of central nervous system of newborn babe at junction of pars cervicalis medullae spinalis with the medulla oblongata, showing the N. accessorius. (Weigert-Pal preparation by Dr. John Hewetson, drawing by A. Karsted.)

In the spinal cord the cell bodies of the neurones pertaining to the N. accessorius are situated in the lateral horn, where they form a part of the so-called columna intermedio-lateralis. The nucleus is usually described as beginning at the level of origin of the fifth cervical nerve, and extending as far as the junction of the lower with the middle third of the nucleus olivaris inferior of the oblongata. The medullated axones arising from these cell bodies pass lateralward with a sharp bend to find their exit from the sulcus lateralis of the cervical cord (Fig. 595). Von Kölliker distinguishes sharply between the spinal portion of the N. accessorius and the cerebral portion. All those root bundles finding exit ventral from the tractus spinalis nervi trigemini he classes



with the spinal part, but all root bundles situated higher up or passing through the tractus spinalis nervi trigemini he speaks of as being accessory to the nervus vagus.

### 3. Those the Axones of which belong to the N. Vagus and N. Glossopharyngeus.

The lower motor neurones corresponding to the N. VAGUS and the N. GLOSSOPHARYNGEUS possess axones which arise from the cell bodies situated in the nucleus ambiguus and possibly in other masses of gray matter in the medulla oblongata. This nucleus ambiguus lies dorsalward from the nucleus olivaris accessorius dorsalis, medial to the tractus spinalis nervi trigemini, in the formatio reticularis. It is difficult to make out in ordinary Weigert preparations, but is beautifully demonstrable in Nissl preparations, where it is seen to consist of a group of typical multipolar stichochrome motor cells. The nucleus ambiguus extends a little more anteriorly than does the nucleus nervi hypoglossi. The axones from the cells situated in the nucleus do not form a compact bundle, but pass out as separate fibres from the cells in a dorsal direction in order to reach the plane in which are situated the entering axones of the peripheral sensory neurones of the N. vagus and the N. glossopharyngeus. Then they turn sharply lateralward and ventralward to pass out of the medulla oblongata at the sulcus lateralis dorsalis in common with the entering sensory portions of the nerve. In the nucleus ambiguus terminate a number of fine medullated axones and collaterals which correspond to (1) fibres from the cerebral sensory neurones and (2) fibres from motor neurones which throw the nucleus ambiguus under the influence of higher centres.

The nucleus ambiguus corresponds to the lateral horn of the spinal cord. The N. vagus and N. glossopharyngeus are typical branchial arch nerves, but their exact neurotome relations are still obscure.

### 4. Those the Axones of which belong to the N. Facialis.

The lower motor neurones corresponding to the N. FACIALIS have their cells of origin in the nucleus nervi facialis, which is situated in the pars dorsalis pontis just anterior to the junction of the medulla oblongata with the pons. This nucleus corresponds to the columna intermedio-lateralis of the spinal cord. It is essentially the nerve of the hyoid arch—the same arch which in the embryo yields a part of the hyoid bone, the styloid process,

the stylohyoid muscle, the posterior belly of the digastric muscle, the small muscles of the ear, the whole of the muscles of the face, the platysma, etc. An unusual interest pertains to the neurones corresponding to the N. facialis, since it is they that govern the muscles of facial expression. The cell bodies of the neurones here concerned are typical multipolar stichochrome motor cells, easily recognizable as a large group (Fig. 596) in the formatio reticularis medial from the tractus spinalis nervi trigemini and dorsal from the corpus trapezoidum. The medullated axones from the cells of this nucleus pass as separate fibres (not in a compact bundle) dorsalward and somewhat medialward (*pars prima*) toward the floor of the fourth ventricle. They then bend and run anteriorly along the floor of the fourth ventricle dorsal and medial to the nucleus nervi abducentis, and then again turn lateralward to plunge ventro-laterally in the form of a compact bundle (*pars secunda*) to their place of exit from the rhombencephalon, passing between the nucleus olivaris superior and the tractus spinalis nervi trigemini. The double bend beneath the floor of the fourth ventricle is known as the *genu nervi facialis*.

It would appear that a certain number of the root fibres of the nervus facialis of each side have their origin in the nucleus nervi facialis of the opposite side, the decussation taking place in the raphe dorsal to the fasciculus longitudinalis medialis (Stieda, Obersteiner, Cramer). In the nucleus nervi facialis terminate many axones and collaterals from cerebral sensory neurones of the first and probably of higher orders, and also axones and collaterals, throwing the nucleus under the influence of motor neurones, the cell bodies of which are situated higher up in the central nervous system.

It is customary to speak of a "lower facial" and an "upper facial" nerve. The so-called "upper facial" is the part which innervates the M. frontalis and the M. orbicularis oculi; the "lower facial" innervates all the other muscles which receive their nerve supply from the N. facialis. The principal literature on this topic is referred to in an article by Bregmann.\* In certain paralyses the muscles innervated by the "lower facial" may be paralyzed, those innervated by the "upper facial" being

---

\* Bregmann, L. E. Ueber Diplegia facialis. Neurol. Centralb., Leipz., Bd. xv (1896), S. 242-248.

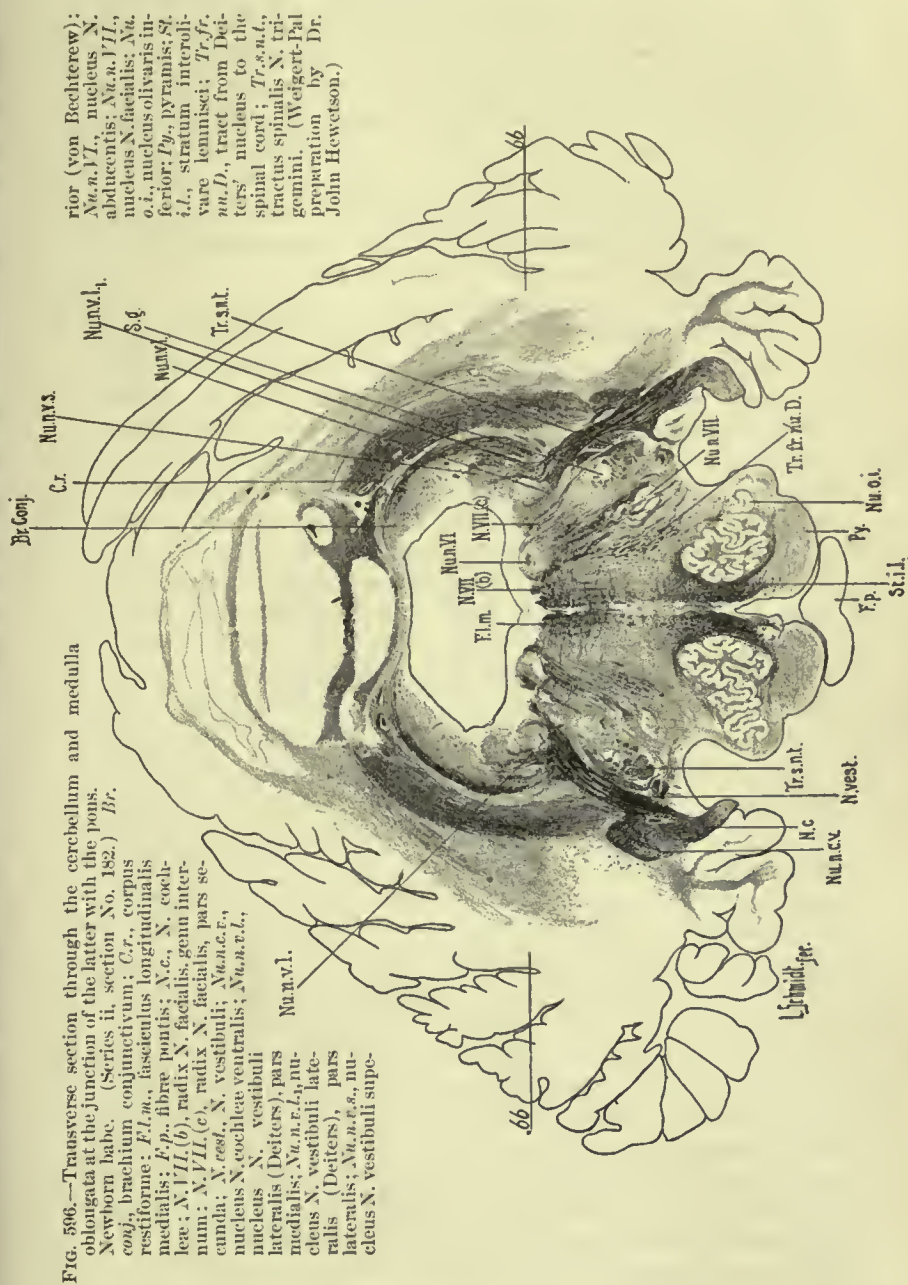


FIG. 596.—Transverse section through the cerebellum and medulla oblongata at the junction of the latter with the pons. Newborn babe. (Series ii, section No. 182.) *Br.*

*conj.*, brachium conjunctivum; *Cz.*, corpus restiforme; *Elm.*, fasciculus longitudinalis medialis; *F.p.*, fibre pontis; *N.c.*, N. cochleae; *N. VII (b)*, radix N. facialis, genu internum; *N. VII (c)*, radix N. facialis, pars secunda; *N. VII (d)*, N. vestibuli; *N. VII (e)*, nucleus N. cochleae ventralis; *N. VII (f)*, nucleus N. vestibuli lateralis (Deiters); *N. VII (g)*, nucleus N. vestibuli lateralis (Deiters); *N. VII (h)*, nucleus N. vestibuli superioris (Deiters); *N. VII (i)*, nucleus N. vestibuli superioris (Deiters); *N. VII (j)*, nucleus N. vestibuli superioris (Deiters); *N. VII (k)*, nucleus N. vestibuli superioris (Deiters); *N. VII (l)*, nucleus N. vestibuli superioris (Deiters); *N. VII (m)*, nucleus N. vestibuli superioris (Deiters); *N. VII (n)*, nucleus N. vestibuli superioris (Deiters); *N. VII (o)*, nucleus N. vestibuli superioris (Deiters); *N. VII (p)*, nucleus N. vestibuli superioris (Deiters); *N. VII (q)*, nucleus N. vestibuli superioris (Deiters); *N. VII (r)*, nucleus N. vestibuli superioris (Deiters); *N. VII (s)*, nucleus N. vestibuli superioris (Deiters); *N. VII (t)*, nucleus N. vestibuli superioris (Deiters); *N. VII (u)*, nucleus N. vestibuli superioris (Deiters); *N. VII (v)*, nucleus N. vestibuli superioris (Deiters); *N. VII (w)*, nucleus N. vestibuli superioris (Deiters); *N. VII (x)*, nucleus N. vestibuli superioris (Deiters); *N. VII (y)*, nucleus N. vestibuli superioris (Deiters); *N. VII (z)*, nucleus N. vestibuli superioris (Deiters).

rior (von Bechterew): *N. VII (a)*, nucleus N. vestibuli superioris (Deiters); *N. VII (b)*, nucleus N. vestibuli superioris (Deiters); *N. VII (c)*, nucleus N. vestibuli superioris (Deiters); *N. VII (d)*, nucleus N. vestibuli superioris (Deiters); *N. VII (e)*, nucleus N. vestibuli superioris (Deiters); *N. VII (f)*, nucleus N. vestibuli superioris (Deiters); *N. VII (g)*, nucleus N. vestibuli superioris (Deiters); *N. VII (h)*, nucleus N. vestibuli superioris (Deiters); *N. VII (i)*, nucleus N. vestibuli superioris (Deiters); *N. VII (j)*, nucleus N. vestibuli superioris (Deiters); *N. VII (k)*, nucleus N. vestibuli superioris (Deiters); *N. VII (l)*, nucleus N. vestibuli superioris (Deiters); *N. VII (m)*, nucleus N. vestibuli superioris (Deiters); *N. VII (n)*, nucleus N. vestibuli superioris (Deiters); *N. VII (o)*, nucleus N. vestibuli superioris (Deiters); *N. VII (p)*, nucleus N. vestibuli superioris (Deiters); *N. VII (q)*, nucleus N. vestibuli superioris (Deiters); *N. VII (r)*, nucleus N. vestibuli superioris (Deiters); *N. VII (s)*, nucleus N. vestibuli superioris (Deiters); *N. VII (t)*, nucleus N. vestibuli superioris (Deiters); *N. VII (u)*, nucleus N. vestibuli superioris (Deiters); *N. VII (v)*, nucleus N. vestibuli superioris (Deiters); *N. VII (w)*, nucleus N. vestibuli superioris (Deiters); *N. VII (x)*, nucleus N. vestibuli superioris (Deiters); *N. VII (y)*, nucleus N. vestibuli superioris (Deiters); *N. VII (z)*, nucleus N. vestibuli superioris (Deiters).

scarcely, if at all, affected (so-called supranuclear paralysis). In other forms of paralysis all of the muscles innervated by the N. facialis may be equally paralyzed—as, for example, from a lesion involving the N. facialis at its exit from the rhombencephalon. All attempts made to locate separate groups of lower motor neurones corresponding to the “upper facial” and “lower facial” have thus far been unsuccessful, though, as we shall see, in the cerebral cortex these two functional groups are separately represented.

#### 5. Those the Axones of which belong to the N. Abducens.

The lower motor neurones corresponding to the N. ABDUCENS have their cell bodies and dendrites situated in the nucleus nervi abducentis in the pars dorsalis pontis. This nucleus, more or less spherical in shape, lies close beneath the floor of the fourth ventricle, being partly surrounded by the genu nervi facialis. The cells and their dendrites have all the characteristics which we have seen so often in other groups of lower motor neurones. The medullated axones pass ventralward and slightly spinalward, plunging through the formatio reticularis and corpus trapezoides medial to the nucleus olivaris superior. Then plunging farther through the pars basilaris pontis, they make their exit from the rhombencephalon just a little anterior to the junction of the medulla oblongata and pons in the form of from fifteen to eighteen fila radicularia. In leaving the nucleus the axones go, in the main, from its dorso-medial border. According to van Gehuchten, who has studied the chick thoroughly with Golgi's method, a certain number of fibres of the N. abducens on each side arise from cells close to the nucleus nervi facialis. The axones bend around and join the main bundles of fibres from the principal nucleus. This accessory mass of cells, which has also been seen by Lugaro, is referred to by van Gehuchten as the “ventral nucleus of the sixth nerve.”

In the nucleus nervi abducentis terminate axones and collaterals from various sources: (1) from the peripheral cerebral sensory neurones; (2) from the cerebral motor paths; (3) from the nucleus olivaris superior (cf. auditory neurones of the second and higher orders); and, especially, (4) from the fasciculus longitudinalis medialis. By means of the collaterals from the latter bundle the nucleus nervi abducentis is in all probability brought under the influence of the superior colliculus of the corpora



quadrigemina, and the innervation of the rectus lateralis muscle of the eye is such as to lead to movements co-ordinated with those of the other eye muscles (especially the rectus medialis) which are innervated by the nervus oculomotorius and the nervus trochlearis.

#### 6. Those the Axones of which belong to the N. Trigemini.

The lower motor neurones corresponding to the motor part of the N. TRIGEMINUS may be divided into two groups: (1) those having their cell bodies of origin in the nucleus motorius princeps nervi trigemini, and (2) those having their cell bodies of origin in the nuclei motorii minores nervi trigemini.

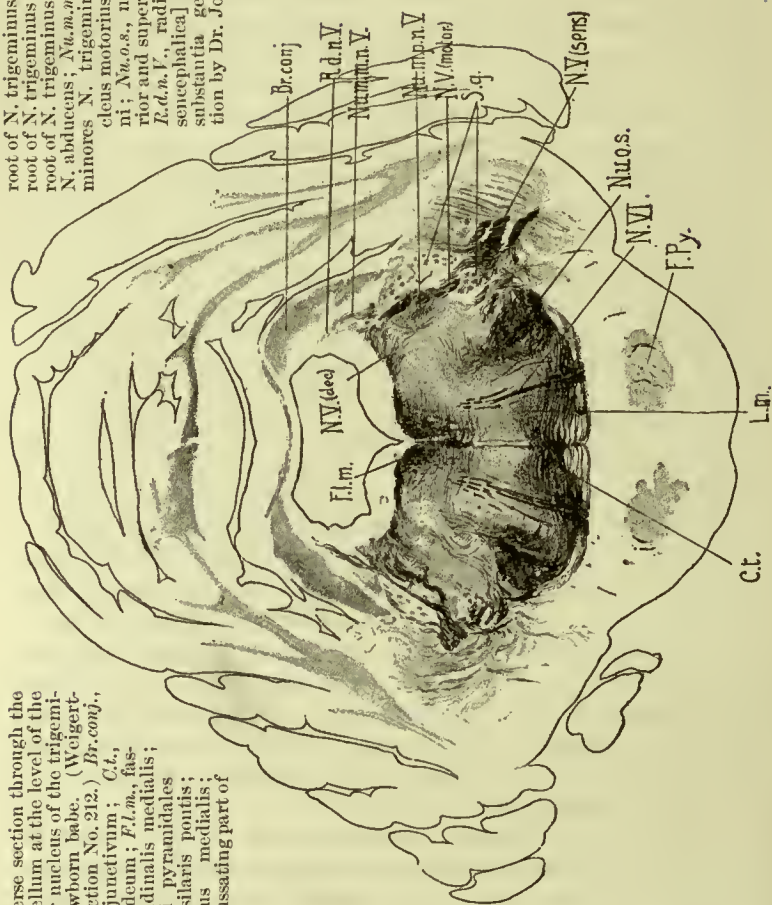
The nucleus motorius princeps nervi trigemini (*noyau masticateur* of the French authors) is situated in the pars dorsalis pontis just a little anterior to the nucleus nervi facialis and the nucleus nervi abducentis (Fig. 597). It lies medial to the main mass of axones of the peripheral sensory neurones of the trigeminus as they plunge into the pars dorsalis pontis. The nucleus is a large one, and in Nissl preparations it is seen, like the other motor nuclei of the rhombencephalon and of the spinal cord, to contain a large number of typical multipolar stichochrome motor cells. The medullated axones of these cells, joined by the medullated axones of the nuclei motorii minores nervi trigemini, to be presently described, form the motor portion of the nervus trigeminus (Fig. 598). The motor root fibres easily distinguishable from the entering sensory axones pass obliquely out of the pons to become distributed entirely through the nervus mandibularis (Fig. 599), or third portion of the nervus trigeminus, to the muscles of mastication. A certain number of axones from the cells of the dorsal motor nucleus of one side pass to the motor portion of the nervus trigeminus of the opposite side (Obersteiner, Edinger, Bruce), the decussation taking place in the dorsal part of the pars dorsalis pontis.

In among the cell bodies and dendrites of the principal motor nucleus of the nervus trigeminus terminate many axones and collaterals (1) from the cerebral sensory neurones of the first and of higher orders, and (2) doubtless from the upper motor neurones.

The nuclei motorii minores nervi trigemini contain the cell bodies and dendrites of the neurones, the axones of which form the radix descendens (mesencephalica) nervi trigemini. The

FIG. 597.—Transverse section through the pons and cerebellum at the level of the principal motor nucleus of the trigeminal nerve. Newborn babe. (Weigert-Pal, series II, section No. 212.) *Br.conj.*, brachium conjunctivum; *Ct.*, corpus trapezoidaleum; *Fl.m.*, fasciculus longitudinalis medialis; *F.Py.*, fasciculi pyramidales in the pars basilaris pontis; *L.m.*, lemniscus medialis; *N.V.(dec.)*, decussating part of

root of N. trigeminus; *N.V.(mотор)*, motor root of N. trigeminus; *N.V.(sens.)*, sensory root of N. trigeminus; *N.VI.*, root fibres of N. abducens; *Nu.m.m.V.*, nuclei motorii minores N. trigemini; *Nu.m.p.n.V.*, nucleus motorius princeps N. trigemini; *Nu.o.s.*, nucleus olivaris superior and superior olivary complex; *R.d.n.V.*, radix descendens [encephalica] N. trigemini; *S.g.*, substantia gelatinosa. (Preparation by Dr. John Hewetson.)



cells which form these nuclei are vesicular rather than stellate; their dendrites are rudimentary (Lugaro, Ramón y Cajal). Their axones descend, giving off many collaterals on the way, some of which always enter the nucleus motorius princeps nervi trigemini. The cells, as described by Ramón y Cajal, form a column which, descending from the region of the corpora quadrigemina, passes obliquely over the brachium conjunctivum, growing larger in size as the nucleus princeps is approached. The axones of these cells are of large calibre at their origin, and, gradually growing more delicate, run along with those of other cells in a curved longi-

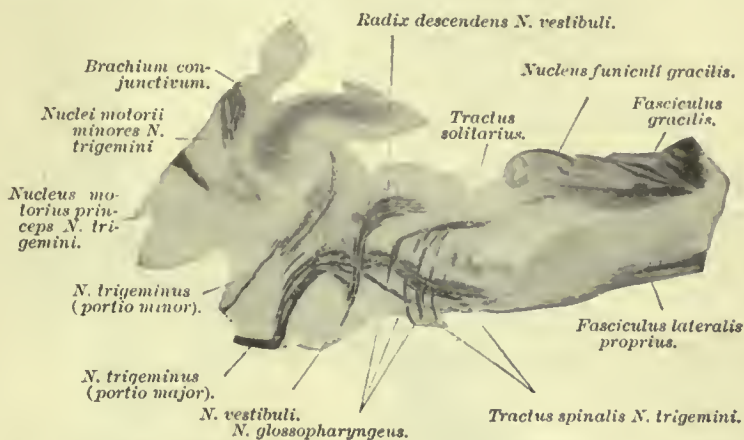


FIG. 598.—Sagittal section through rhombencephalon of human fœtus. (After A. Bruce, *Illustrations of Mid- and Hind-Brain*, Edin., 1892.)

tudinal bundle, which increases in volume as it descends (radix descendens). Before the axones of the descending roots reach the nucleus princeps they undergo a plexiform arrangement, whereby they are distributed between groups of spherical cells, and finally the bundles of the descending root become mixed up with the cells of the nucleus princeps (Fig. 600). Ramón y Cajal states that the extremely complex plexus of fibrils among the cells of the nucleus princeps arises almost exclusively from the terminals of collaterals given off by the fibres of the descending root. He suggests that these collaterals may be of the greatest physiological importance, and suggests that the absolute coincidence in point of time of the movements of the masticatory muscles might be explained by the view that the voluntary excitation received by the nuclei minores is transferred by means of these

collaterals to the nerve cells of these nuclei as well as of the nucleus princeps. He thinks that these and other examples make it seem likely that the collaterals of the motor roots, and perhaps those of every axone, have the function of distributing the excitation received from a single cell, or from a small number of cells, among all the cells of the same nucleus or in a group of similar cell elements situated in different regions of the gray

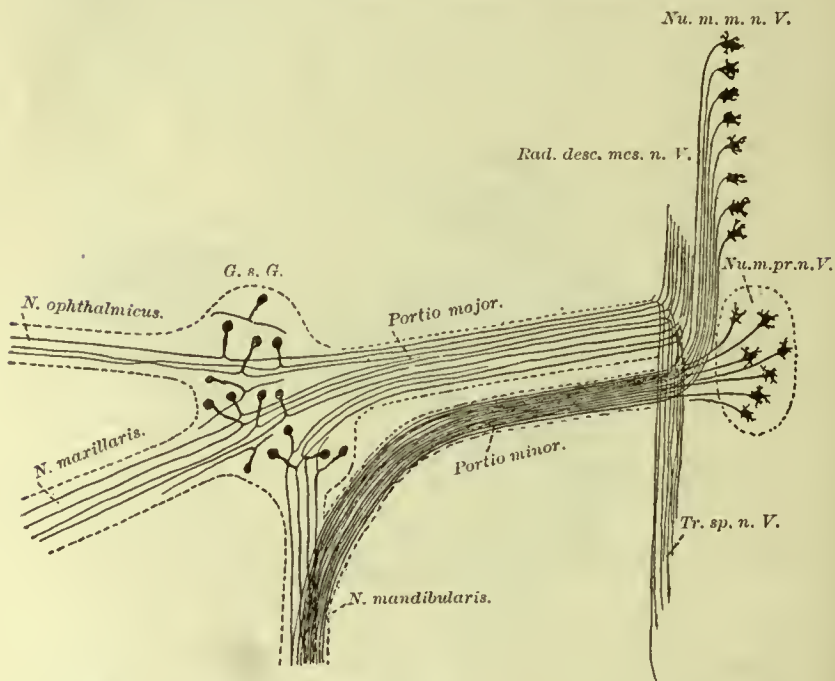


FIG. 599.—Scheme showing the motor and sensory neurones, the axones of which enter into the formation of the N. trigeminus. (After A. van Gehuchten, *Anatomie des système nerveux de l'homme*, Louvain, 1897, p. 543, Fig. 384.) *G. s. G.*, ganglion semilunare Gasseri; *Nu. m. m. n. V.*, nuclei motorii minores nervi trigemini; *Nu. m. pr. n. V.*, nucleus motorius princeps nervi trigemini; *Rad. desc. mes. n. V.*, radix descendens [mesencephalica] nervi trigemini; *Tr. sp. n. V.*, tractus spinalis nervi trigemini.

substance. Accordingly, the nervous excitation, feeble in the beginning as it comes out from one cell, would, in proportion to the number of neurones intercalated, grow and attain to its greatest effect at the beginning of the exit of the motor root. If the stimulus of the voluntary excitation is transferred exclusively to one muscle or one group of muscle bundles, then the collaterals



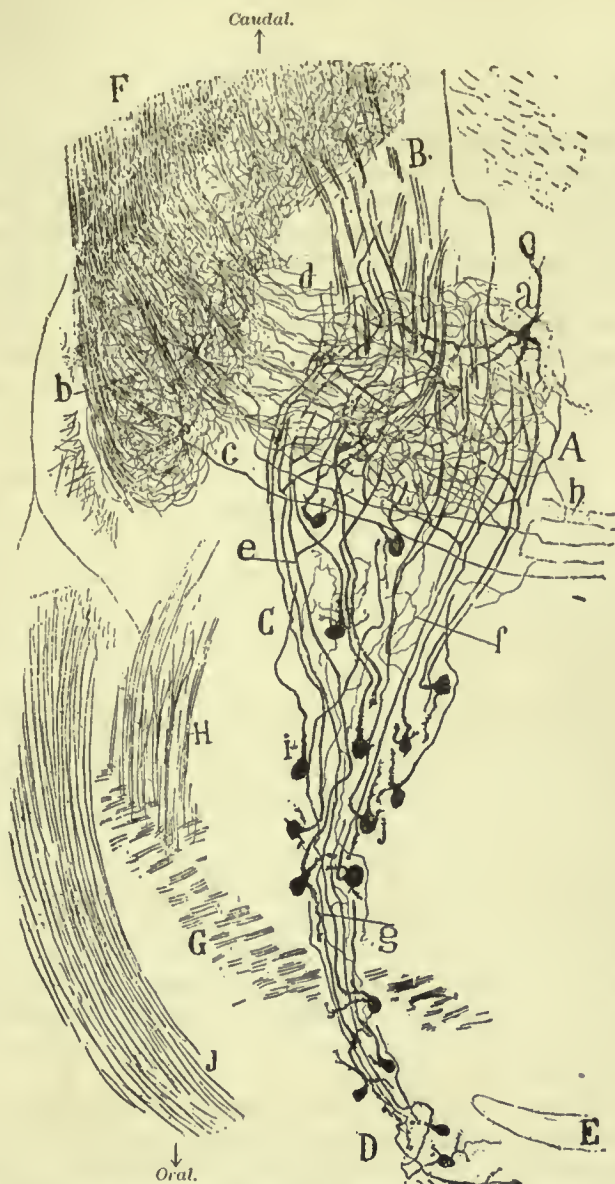


FIG. 600.—Frontal section through the brain stem of a fetal mouse. (After S. Ramón y Cajal, *Beitrag zum Studium der Medulla Oblongata*, etc., Bresler, Leipz., 1896, S. 15, Fig. 4.) *A*, nucleus motorius princeps *N. trigemini*; *B*, radix motorius *N. trigemini*; *C*, lower portion of nuclei motorii minores *N. trigemini*; *D*, upper portion of nuclei minores near the fourth ventricle (*E*); *F*, radix sensorius *N. trigemini*; *G*, brachium conjunctivum; *H*, bundle of descending axones from brachium conjunctivum; *a*, cells of nucleus motorius princeps; *b*, sensory collaterals through the substantia gelatinosa of the trigeminus; *c*, axone of sensory trigeminal neurone of the second order; *d*, sensory collaterals which appear to enter the nucleus motorius princeps; *f*, fine collaterals from the axones of the nuclei minores; *i*, pear-shaped cell; *j*, cell without dendrites; *e*, coarse limbs of bifurcation of the axones in the radix descendens (mesencephalica) *N. trigemini* with branch inside the nucleus motorius princeps.

of the motor roots are either only moderately developed or entirely absent, as is seen in the nucleus nervi hypoglossi and in the nucleus nervi oculomotorii. In these cases, according to Ramón y Cajal, the number of cells associated with the motor impulse will depend upon the number of fibres of the pyramidal tract received by the motor nucleus, or perhaps upon the distribution of the end branchings of such fibres.

Merkel's view that the radix descendens nervi trigemini represents a trophic root has not been confirmed by other investigators.

#### 7. Those the Axones of which belong to the N. Trochlearis.

The lower motor neurones, corresponding to the N. TROCHLEARIS, or fourth cerebral nerve, may next be described. The cell bodies and dendrites of these neurones form the so-called nucleus nervi trochlearis, which is to be seen in sections passing through the isthmus rhombencephali and inferior colliculus (Fig. 601).

The cells are typical multipolar stichochrome motor cells, and the nucleus forms a spherical nodule, which lies ventral to the aqueduct of Sylvius in a trough on the dorsal surface of the fasciculus longitudinalis medialis, somewhat posterior to the spinal extremity of the nucleus nervi oculo-motorii. In Weigert preparations many fine medullated axones can be seen passing from the region of the fasciculus longitudinalis medialis into the nucleus nervi trochlearis. Through these, in all probability, the activities of the nucleus nervi trochlearis are co-ordinated with those of the other eye-muscle nuclei. It is likely that the nucleus also receives axones and collaterals from peripheral cerebral sensory neurones and from neurones which throw this nucleus under the influence of the pallium.

The medullated axones from the cells of the nucleus nervi trochlearis pass out of the nucleus mainly from its dorsal and lateral surfaces. They curve lateralward and dorsalward through the stratum griseum centrale until they reach the level of the radix descendens nervi trigemini, when they make a tolerably sharp turn spinalward and run for a short distance longitudinally backward, so that in transverse section the root bundle, or sometimes two or three root bundles, are met with in cross section on each side. Having reached the level of the velum medullare anterius, the fibres turn sharply medialward and dorsalward to undergo




FIG. 601.—Horizontal section through the medulla, pons, and midbrain of a newborn babe. Weigert-Pal staining. Level of nucleus nervi oculomotorii and nucleus nervi trochlearis. (Series iii, section No. 100.) *Aq. cer.*, aqueductus cerebri; *Br. conj.*, brachium conjunctivum; *Cp.*, commissura posterior cerebri; *C. Bechl.*, commissure between Bechterew's nuclei of the two sides; *Cr.*, corpus restiforme; *FLm.*, fasciculus longitudinalis medialis; *F.c. to Fr.*, fibres from fasciculus cuneatus to formatio reticularis; *Fib. arc. int.*, fibre arcuata internæ; *F. cu.*, fasc. cuneatus; *Fr.a.*, formatio reticularis alba; *Mot. V.*, radix motorius N. trigemini; *N.VI.*, radix N. abducentis; *N. rest.*, radix N. vestibuli; *N. VII.(c.)*, radix N. facialis, pars secunda; *N. IX and X.*, radices Nn. glossopharyngei et vagi; *N.XII.*, radix N. hypoglossi; *Nu.c.s.(m)*, nucleus centralis superior, pars medialis; *Nu.c.s.(l)*, nucleus centralis superior, pars lateralis; *Nu.L.L.*, nucleus lemnisci lateralis; *Nu.L.s.*, nucleus lateralis superior; *Nu.n. III.*, nucleus N. oculomotorii; *Nu.n. IV.*, nucleus N. trochlearis; *L.s.*, lemniscus superior; *Nu.f.g.*, nucleus funiculi gracilis; *Nu.n.c.r.*, nucleus N. cochleæ ventralis; *Nu.n. VII.*, nucleus N. facialis; *S.g.*, substantia gelatinosa; *St.i.l.*, stratum interolivare lemnisci; *Sen.V.*, radix sensorius N. trigemini; *St.g.c.*, stratum griseum centrale; *Sub. gel.*, substantia gelatinosa near entrance of sensory part of N. trigeminus; *Tr.s.n.t.*, tractus spinalis N. trigemini; *Tr.fr.mu.D.*, tract from Deiters' nucleus to the spinal cord. (Preparation by Dr. John Hewetson.)



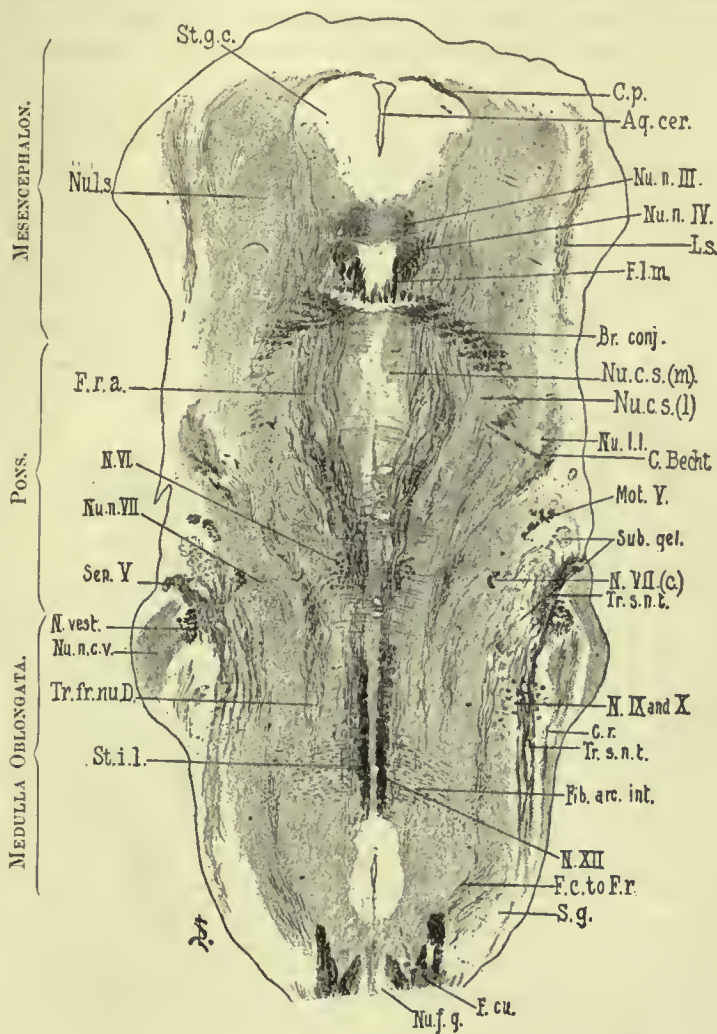


FIG. 601.

decussation in the substance of the velum (Fig. 602). It is believed that this decussatio nervorum trochlearium is complete, and that no fibres enter the nervus trochlearis from the nucleus of the same side. Immediately after the decussation the root bundles make their exit from the dorsal surface of the nervous system at the

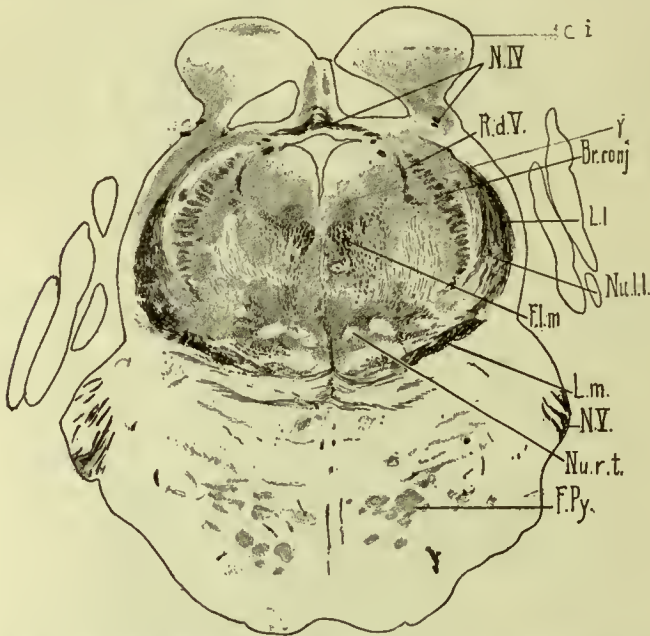


FIG. 602.—Transverse section through isthmus rhombencephali of newborn babe. (Weigert-Pal, series ii, section No. 268.) *Br.conj.*, brachium conjunctivum; *C.i.*, colliculus inferior;  $\gamma$ , nucleus described by Westphal as probably concerned in the origin of the N. trochlearis; *F.l.m.*, fasciculus longitudinalis medialis; *F.Py.*, fasciculi longitudinales [pyramidales]; *L.l.*, lemniscus lateralis; *L.m.*, lemniscus medialis; *N.IV.*, decussatio nervorum trochlearium; *N.V.*, N. trigeminus; *Nu.l.l.*, nucleus lemnisci lateralis; *Nu.r.t.*, nucleus reticularis tegmenti pontis; *R.d.V.*, radix descendens [mesencephalica] nervi trigemini. (Preparation by Dr. John Hewetson.)

lateral border of the velum medullare anterius, lateral from the frenulum veli medullaris anterioris, close behind the lamina quadrigemina. There is often asymmetry of the root bundles on the two sides; whereas the nerve of one side may go out in the form of a compact bundle, the root fibres on the other side may form two or more well-separated bundles (fila radicularia). These bundles, however, unite almost immediately to form a common nerve trunk. The nervus trochlearis passes into the porus trochlearis of the dura mater, runs through a small dural canal alongside of

the N. ophthalmicus to the fissura orbitalis superior. Having arrived in the orbit, it passes across the origin of the M. levator palpebrae superioris to the M. obliquus oculi superior, into which it enters in order to innervate it. It is estimated that in the N. trochlearis there are some twelve hundred nerve fibres.

8. Those the Axones of which belong to the N. Oculomotorius.

The lower motor neurones corresponding to the N. OCULOMOTORIUS, or third cerebral nerve, possess cell bodies and dendrites which are situated in the nucleus nervi oculomotorii. This nucleus is located in the mesencephalon. In sections taken through the pedunculus cerebri it is seen to occupy a position in the tegmentum ventral to the aqueductus cerebri and to the stratum griseum centrale which lies beneath the aqueduct. It

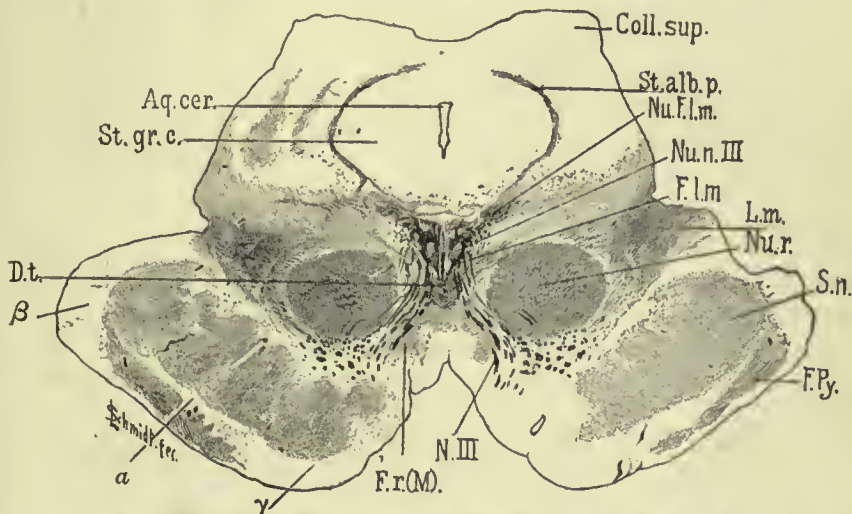


FIG. 603.—Transverse section through mesencephalon, colliculi superiores of corpora quadrigemina and cerebral peduncle of newborn babe. (Weigert-Pal, series ii, section No. 384.) *Aq.cer.*, aqueductus cerebri; *Coll.sup.*, colliculus superior; *Dt.*, decussatio tegmenti dorsalis (*fontaineartige Haubenkreuzung* of Meynert); *F.l.m.*, fasciculus longitudinalis medialis; *F.Py.*, fasciculi pyramidalis in the basis pedunculi; *Fr.(M)*, fasciculus retroflexus Meynerti; *L.m.*, lemniscus medialis; *Nu.F.l.m.*, nucleus fasciculi longitudinalis medialis or nucleus commissurae posterioris (*oberer Oculomotoriuskern* of Darkschewitsch); *Nu.n.III*, nucleus N. oculomotorii; *Nu.r.*, nucleus ruber; *N.III*, N. oculomotorius; *St.alb.p.*, stratum album profundum; *St.gr.c.*, stratum griseum centrale; *S.n.*, substantia nigra; *a*, region of Flechsig's *Flossschleife*; *β*, temporo-occipital tract to pons; *γ*, frontal tract from pallium to pons. (Preparation by Dr. John Hewetson.)

is situated just dorsal to the fasciculus longitudinalis medialis on each side (Fig. 603). Since the aqueductus cerebri is here di-

rected obliquely, the long axis of the nucleus nervi oculomotorii is inclined at an angle to a line drawn parallel to the long axis of the fourth ventricle (*vide supra*).

The axones of each nervus oculomotorius arise mainly from the nucleus of the same side but partly from the nucleus of the opposite side; that is to say, there is a partial decussation of the root fibres. This decussatio nervorum oculomotoriorum concerns mainly the posterior or distal (spinal) third of the nucleus. There is but little, if any, decussation of the axones arising from the cell bodies situated in the anterior or proximal (cerebral) two thirds of the nucleus.

The nuclei of the N. oculomotorii are very complex, consisting of numerous cell groups; and although they have been studied by many able investigators, notably by Duval and Laborde,\* Spitzka,† Starr,‡ von Gudden,§ Perlia,|| Westphal,^ Edinger,◇ van Gehuchten,↓ Obersteiner,↑ von Kölliker,‡ and Bernheimer,\*\* we are still far from possessing an adequate and satisfactory knowledge concerning their various parts. That they should be anatomically complex is not surprising when one remembers that the N. oculomotorius innervates a relatively large number of

\* Duval, M., et J. V. Laborde. De l'innervation des mouvements associés des globes oculaires; études d'anatomie et de physiologie expérimentale. Jour. de l'anat. et de la physiol., Par., t. xvi (1880), pp. 56-89.

† Spitzka, E. C. The Oculo-motor Centres and their Co-ordinators. Jour. of Nerv. and Ment. Dis., N. Y., vol. xv (1888), pp. 413-432.

‡ Starr, M. A. Ophthalmoplegia Externa Partialis. Jour. of Nerv. and Ment. Dis., N. Y., vol. xv (1888), pp. 301-316.

\* von Gudden. Gesammelte Abhandl., Wiesbaden (1889).

|| Perlia. Die Anatomie des Oculomotoriuscentrums beim Menschen. Arch. f. Ophth., Leipz., Bd. xxxv, Abth. 4 (1889), S. 287-308.

^ Westphal, C. Ueber die chronische progressive Lähmung der Augenmuskeln. Unter Benützung der von G. Westphal hinterlassenen Untersuchungen, bearbeitet und herausgegeben von E. Siemerling. Suppl.-Bd., Arch. f. Psych. u. Nervenkr., Berl., Bd. xxii (1891), S. 1-206.

◇ Edinger. Verh. der central. Hirnnervenbahnen. Arch. f. Psychiat. u. Nervenkr., Bd. xvi (1885).

↓ van Gehuchten. De l'origine du nerf oculomoteur commun. Bull. de l'Ac. roy. de Belg. (1892).

↑ Obersteiner. Anzeig. d. k. k. Gesellsch. d. Aerzte in Wien (1880).

‡ von Kölliker, A. Ueber den Ursprung des Oculomotorius beim Menschen. Sitzungsber. d. phys.-med. Gesellsch. zu Würzb. (1892), S. 118-120.

\*\* Bernheimer, S. Das Wurzelgebiet des Oculomotorius beim Menschen. 8vo, Wiesbaden (1894), pp. 1-80.



muscles, anatomically and physiologically more or less independent of one another, and recalls further that these muscles, both inside and outside the eyeball, are co-ordinated in the most delicate way with one another and with the muscles innervated by other groups of lower motor neurones (*M. obliquus superior*, *M. rectus lateralis*, *Mm. capitis et colli*).

It will be convenient, owing to the existence of a nucleus impar, to describe the nuclei of the two sides together. In the newborn babe there can be very distinctly made out a large lateral nucleus on each side and a nucleus impar in the middle line. The nucleus impar does not extend quite as far either anteriorly or posteriorly as do the lateral masses. With the high power of the microscope, cells can be made out connecting the nucleus impar (except at the posterior and dorsal extremity) with the lateral nucleus on its ventral aspect on each side. The lateral masses of the two sides are more widely separated from one another and more independent at the postero-dorsal extremity of the nucleus than at the anterior ventral extremity; in fact, in the latter region the two lateral masses fuse and form a solid mass of nerve cells occupying the middle line and a region just lateral from this on each side. These appearances are well shown in a reconstruction made by F. Sabin in the anatomical laboratory in Baltimore.

The nuclei of the two sides in three dimensions looked at from the dorso-anterior surface of the reconstruction are of the shape of an arrow with its apex pointing ventralward and anteriorly, its base pointing dorsalward and posteriorly; or, on account of the hollowed-out appearance, it may be said to resemble the anterior half of a canoe along the floor of which, from the bow to the middle, projects a thick vertical bar—the nucleus impar. Looked at from the ventro-posterior aspect, the surface is seen to be convex and tolerably uniform, except at the postero-dorsal extremity, where the nucleus impar is separated by a narrow chink on each side from the lateral masses of nerve cells.

A very elaborate description has been given by Perlia (Fig. 604). This author describes a number of groups of nerve cells which he says he makes out distinctly. He divides the masses into a superior group and an inferior group. The inferior group forming the main mass of the nucleus consists of a central nucleus situated in the middle line (*Nucl. centralis*), of a nucleus containing small cells known as the Edinger-Westphal nucleus

(Nucl. Edinger-Westphal.), and of four nuclei containing rather large cells, two dorsal and two ventral, of which one is anterior and the other posterior.

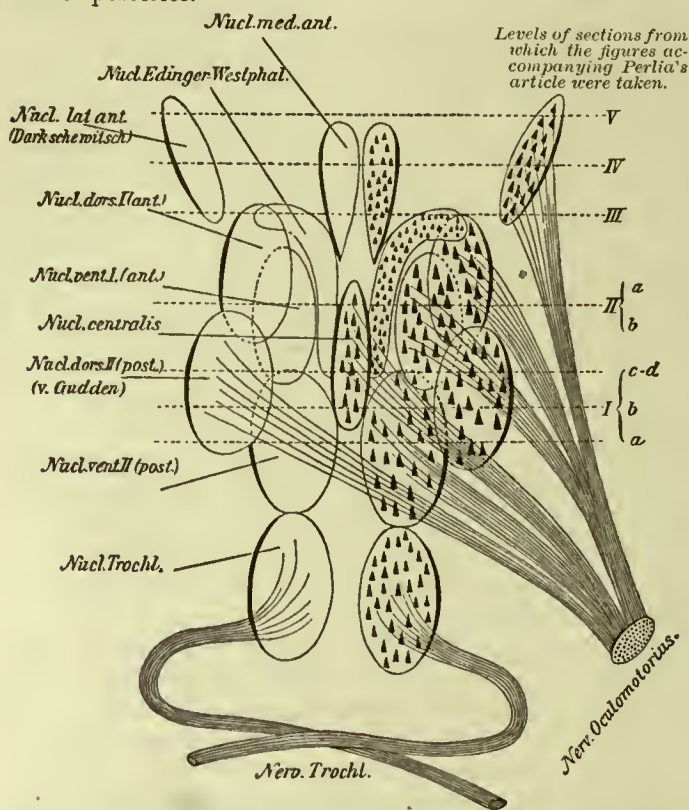


FIG. 604.—Scheme of the nuclei nervorum oculomotorium. (After Perlia, Arch. f. Ophth., Leipz., Bd. xxv, Abth. iv, S. 297.)

The superior group, much smaller than the inferior, consists of two nuclei—(1) a median nucleus (Nucl. med. ant.) and (2) a lateral nucleus (Nuc. lat. ant.). Perlia believed that root fibres of the N. oculomotorius come from all of these groups of nerve cells except the nucleus of Edinger-Westphal and the anterior median nucleus. It will be noticed that Perlia's nucleus lateralis anterior is in reality identical with the *oberer Oculomotorinskern* of Darkschewitsch,\* but, as we have seen, the newer investigations

\* Darkschewitsch, L. Neurol. Centralbl., Leipz. (1885), S. 101 and *Ibid.* (1886).

have shown that Perlia, Darkschewitsch, and others were wrong in believing that this nucleus gives origin to root fibres of the N. oculomotorius. It has, we believe now, nothing to do directly with the N. oculomotorius, but is connected with the fasciculus longitudinalis medialis on the one hand and with the commissura posterior (distal commissure) on the other. Von Kölliker has therefore referred to it as the nucleus of the posterior commissure, and it has been described in a previous chapter of this book as the nucleus fasciculi longitudinalis medialis.

Von Kölliker has made a very careful study of serial sections of this nucleus in the newborn babe, and his description should be consulted by any one who wishes to study the nucleus thoroughly. He decides that the N. oculomotorius has on each side essentially only one nucleus.\* From this main nucleus a round dorsal mass branches off at the cerebral end. He does not find any paired dorsal medial nucleus, but describes only an unpaired central nucleus, which apparently corresponds to what has been mentioned above as the nucleus impar. Von Kölliker does not find the nucleus of Edinger-Westphal in his embryo preparations, although he states that he sees it perfectly well in sections of the adult brain.

The partial decussation of the root fibres of the Nn. oculo-motorii was first proved for the rabbit by von Gudden. It has also been made out in man by Perlia and von Kölliker and by van Gehuchten in the duck (Fig. 605). The decussation in human beings has been perhaps most carefully described by Bernheimer. This author believes that the distal part of the main nuclei give off almost entirely decussating axones. In the most posterior ten sections he found exclusively crossed fibres; a little anteriorly a few uncrossed fibres appeared, which gradually became more numerous; while at the middle of the nuclear mass the uncrossed fibres predominated, and in the anterior half of the lateral main nucleus there were no decussating fibres at all. He assumes that on the whole one fourth of all the fibres from each nucleus decussate. The decussation occurs as follows: Out of all parts of one nucleus there arise fibres which pass more or less on the medial side of the nucleus and descend at the same time toward the median space, there to pass over like a commissure to the opposite nuclear mass, in order again to radiate out, fan-shaped,

---

\* *Op. cit.*, S. 299.

into the latter. After passing through the nucleus of the opposite side, united in bundles they go through the fasciculus longitudinalis medialis. The fibres arising most dorsalward go out of the opposite nuclear mass farthest ventralward, while those arising more ventrally pass out farthest dorsalward. Hence one can distinguish among the crossed fibres some with longer roots, others with shorter roots.

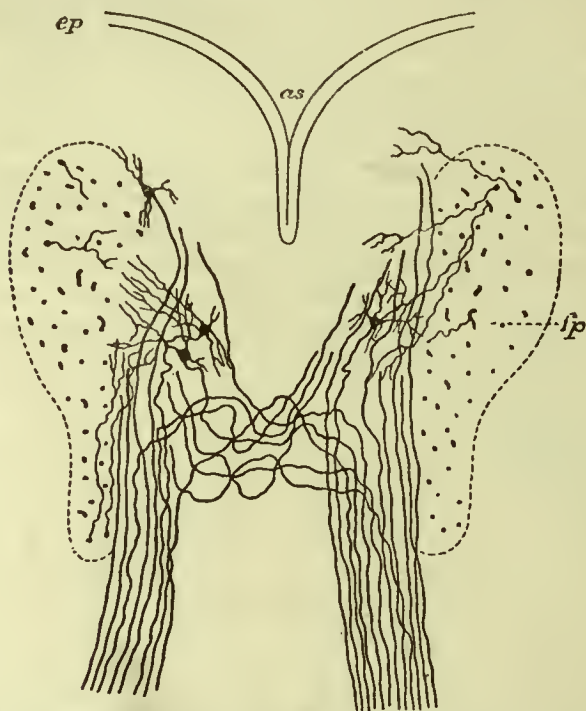


FIG. 605.—Nucleus originis et fila radicularia N. oculo-motorii of an embryo duck. (After A. van Gehuchten, *Anatomic du système nerveux de l'homme*, 2<sup>me</sup> ed., Louv., 1897, p. 614, Fig. 432.) *as*, aqueductus cerebri; *ep*, ependymal epithelium; *fp*, fasciculus longitudinalis medialis.

According to Bernheimer, crossed fibres never leave the main nucleus in the neighborhood of the median line. The crossed fibres go through the fasciculus longitudinalis medialis in its dorsal part, and, after a somewhat curved course, pass near the lateral border of the red nucleus and then turn toward the middle line to the region of exit of the nerve.

The uncrossed fibres from the main nuclei arise unmixed only from the proximal half of them. They leave the nuclear



masses and pass exclusively between the fibres of the fasciculus longitudinalis medialis which lie close to the middle line—that is, to the most ventral fibres of the fasciculus longitudinalis medialis.

It seems likely that the various groups of nerve cells in the nuclei nervorum oculomotoriorum are connected with one another by means of large numbers of association neurones.

Ending in the nucleus nervi oculomotorii of each side are collaterals and axones which in the main come from the fasciculus longitudinalis medialis. By just what paths, if any, other than the fasciculus longitudinalis medialis the nucleus nervi oculomotorii is brought under the influence of cerebral sensory peripheral nerves and of neurones, the cell bodies of which are situated in the pallium, is not yet clear.

The relation of the nucleus nervi oculomotorii to the nucleus nervi abducentis, on account of the physiology of the muscles supplied by these two nuclei, is of the highest interest, especially with regard to the lateral movements of the eyes, the *M. rectus medialis* being supplied by the nucleus nervi oculomotorii and the *M. rectus lateralis* being supplied by the nucleus nervi abducentis. Duval and Laborde are of the opinion that there is a crossed relation of the oculomotor nerve to the contra-lateral nucleus of origin of the nervus abducens mediated by the fasciculus longitudinalis medialis. If their view be correct, fibres leave the nucleus nervi abducentis at its cerebral extremity, enter the fasciculus longitudinalis medialis, and farther cerebralward pass into the dorsal decussation of the tegmentum, to go over to the other side, where they meet with the root fibres of the nervus oculomotorius, and join them on their medial surface. Spitzka, on the other hand, and Obersteiner think such a view unnecessary. Assuming that the *M. rectus medialis* is innervated mainly by crossed root fibres of the nervus oculomotorius, they suggest that a connection by means of the fasciculus longitudinalis medialis exists between the nucleus nervi abducentis and the nucleus nervi oculomotorii of the same side. This would afford an anatomical basis for the synergism existing between the *M. rectus medialis* of one side and the *M. rectus lateralis* of the other side. Held's studies with Golgi's method have demonstrated so many collaterals from the fasciculus longitudinalis medialis entering the eye-muscle nuclei that it seems very likely that the co-ordination of the activities of these various nuclei is brought about by means of fibres in the fasciculus longitudinalis medialis (Fig. 606).

A great many attempts have been made to localize in the nucleus nervi oculomotorii and in the bundles of root fibres coming

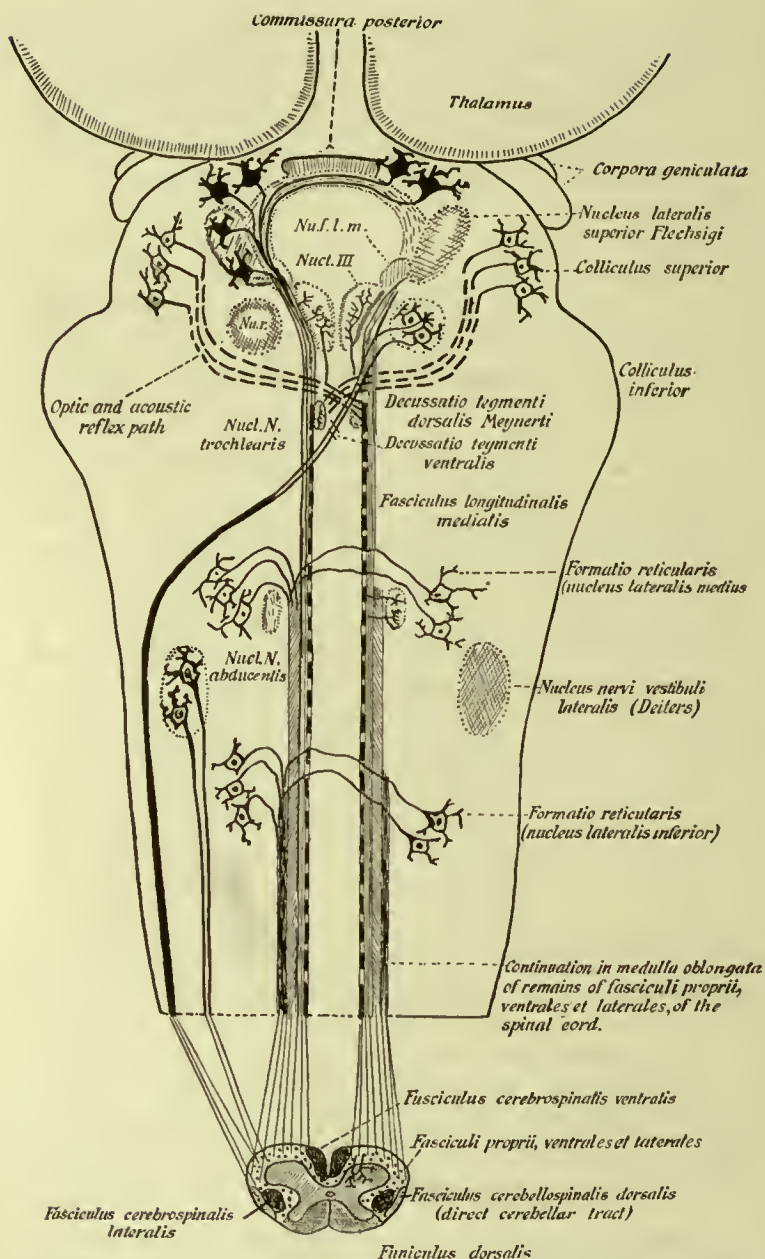


FIG. 606.—Scheme of the course of the optic and acoustic reflex paths in the formatio reticularis. (After H. Held, Arch. f. Anat. u. Physiol., Anat. Abth., Leipz., 1893, S. 229, Fig. 11.) Nucl. III, nucleus nervi oculo-motorii; Nu. f. l. m., nucleus fasciculi longitudinalis medialis seu nucleus commissuræ posterioris; Nu. r., nucleus ruber.

from them structures corresponding to individual eye muscles. Thus, Hensen and Völkens\* in the dog stimulated electrically individual bundles of fibres coming out of the different portions of the nucleus. They concluded that from before backward the fibres of the nervus oculomotorius in the dog have the following arrangement: (1) Nerves of accommodation; (2) those for the M. sphincter iridis; (3) those for the M. rectus medialis; (4) those for the M. rectus superior; (5) those for the M. levator palpebræ superioris; (6) those for the M. rectus inferior; (7) those for the M. obliquus inferior.

Other investigators (Starr, Kahler and Pick, Leube, Spitzka, Siemerling, Westphal, von Monakow) have examined the pathological alterations in the nucleus in cases in which partial paralysis of function had been observed during life.

Thus Starr† distinguishes in the nucleus nervi oculomotorii a medial portion and a lateral portion. From the former he believes there arise from before backward the fibres for the ciliary muscle, those for the M. rectus inferior, and those for the M. rectus medialis; from the latter arise the nerve fibres for the M. sphincter iridis, M. levator palpebræ superioris, M. rectus superior, and M. obliquus inferior. According to Kahler and Pick, the pupillary fibres of the nervus oculomotorius run in its most anterior root bundles; while the posterior root bundles, they believe, are destined for the external muscles of the eye, and can be separated into (1) a lateral group, governing the M. levator palpebræ, the M. rectus superior and the M. obliquus superior, and (2) a medial group, innervating the M. rectus medialis and the M. rectus inferior.

The case described by Leube,‡ in which during life there had been ptosis (paralysis of the M. levator palpebræ on the right side) and dilatation of the right pupil, and in which after death a small apoplectic nodule was discovered in the dorso-lateral part of the nucleus nervi oculomotorii of the right side, is worthy of especial mention here.

---

\* Hensen, V., und C. Völkens. Ueber den Ursprung der Accommodationsnerven, nebst Bemerkungen über die Function der Wurzeln des Nervus oculomotorius. *Arch. f. Ophth., Berl.*, Bd. xxiv (1878), S. 1-26.

† Starr, M. Allen. *Op. cit.*

‡ Leube, W. Ueber Herderkrankungen im Gehirnsehenkel in der Gegend des hinteren Vierhügelpaares. *Deutsches Arch. f. klin. Med., Leipz.*, Bd. xl (1886-'87), S. 217-227.

Of especial interest, too, are the investigations which have been made by means of the method of Nissl, which, as we have seen above, has thrown so much light upon the localization of function within the gray masses inside the spinal cord. Here the studies of Bernheimer and of Schwabe have been most extensive. Bernheimer\* distinguishes between the extra-ocular and intra-ocular muscles, and finds that the extra-ocular muscles arise from the medial portion of the nucleus, while the intra-ocular muscles arise in the main from the lateral portion of the nucleus.

Schwabe,† under the direction of Hans Held, operated upon a large number of rabbits with the purpose of localizing the portions of the N. oculomotorius concerned in the innervation of the individual eye muscles. In his preliminary report he states that his results prove that the view of Mendel,‡ according to which the upper facial had its origin in the nucleus nervi oculomotorius, is probably incorrect, since on section of the nervus facialis there resulted extensive typical degenerative alterations in the nucleus nervi facialis, but not a single degenerated cell could be found in the nucleus nervi oculomotorii.

When the whole of the orbital contents were removed he found total degeneration of all the ganglion cells of the motor type of the main nucleus of the nervus oculomotorius as well as of the lateral cells lying in the fasciculus longitudinalis medialis. The relations are in part crossed, and Schwabe confirms von Gudden in that he finds that the cells in the crossed nucleus are situated in its most dorsal parts. Schwabe thinks that the only muscle which receives a crossed innervation by means of the nervus oculomotorius is the M. rectus superior. The root fibres belonging to it come out of the dorsal half of the distal portion of the opposite nucleus nervi oculomotorii, a region which corresponds approximately to the nucleus dorsalis described by von Gudden in the rabbit.

The M. obliquus inferior is innervated by fibres arising from

\* Bernheimer, S. Innervation der Augenmuskeln. Deutsche med. Wehnsehr. (1897), No. 35, S. 153.

† Schwabe, H. Ueber die Gliederung des Oculomotorius-Hauptkerns und die Lage der den einzelnen Muskeln entsprechenden Gebiete in demselben. Neurol. Centralbl., Leipz., Bd. xv (1896), S. 792-794.

‡ Mendel, E. Ueber den Kernursprung des Augen-Facialis. Berl. klin. Wehnsehr., Bd. xxiv (1887), S. 913-916. Also, Neurol. Centralbl., Leipz., Bd. vi (1887), S. 537-542.



the ventral half of the distal portion of the nucleus nervi oculomotorii of the same side. The M. rectus inferior is innervated by fibres arising from cells situated in the proximal portion of the nucleus nervi oculomotorii of the same side and from some of the lateral cells in the fasciculus longitudinalis medialis.

The cell bodies which send axones to the M. rectus medialis were not so easily determined. They do not apparently correspond to a definite well-defined group, but the cells governing it are spread out over the whole of that side of the nucleus nervi oculomotorii which lies upon the fasciculus longitudinalis medialis. These cells include the greater part of the lateral cells, a number of cells lying at the junction between the distal and proximal portion of the nucleus and about half of the cells which, together with those which govern the M. rectus inferior, form the most lateral apex of the proximal portion of the main nucleus.

The fibres governing the M. levator palpebræ superioris and the M. retrahens bulbi could not be connected with any cells, although Schwabe thinks it is possible that the levator muscle may be innervated by cells in the most lateral dorso-distal group of the nucleus, possibly of the opposite side. Interesting from the physiological standpoint is the fact that the Mm. recti superiores et obliqui inferiores, acting together in pure upward movements of the eyeball, are innervated by the distal portions of the nuclei of the two sides; and also that the cells innervating the Mm. recti inferiores et mediales are intimately mingled in the most lateral part of the proximal portion of the nucleus. This latter region might very well be called, as Schwabe suggests, the *Convergenzcentrum*.

## SUBSECTION IV.

**Neurones which enter into Conduction Relation with the Lower Motor Neurones and throw the Latter under the Influence of Other Centres (Intermediary and Upper Motor Neurones).**

---

### CHAPTER LVII.

#### INTERMEDIARY AND UPPER MOTOR NEURONES.

Relation of peripheral centripetal neurones to motor nuclei—Golgi cells of Type II intersegmental—The triangular path of Helweg or the olivary bundle of von Bechterew.

It has already been stated (*vide supra*) that collaterals, and possibly terminals, from great numbers of peripheral sensory neurones enter into direct contact relation with the dendrites and cell bodies of the motor neurones in the ventral horns (Fig. 607.) In addition to this mechanism by means of which the peripheral sensory neurones can come directly in contact with motor neurones, the fibres of the dorsal funiculi can influence the motor neurones by means of intercalated tautomeric and heteromeric neurones with shorter and longer axones. In this way one sensory fibre of a given neurotome can perhaps throw motor neurones in many segments of the cord under its influence (Fig. 608).

The lower motor neurones of the same ventral horn and of the ventral horns of the two sides can reciprocally affect one another by means of Golgi cells of Type II. This would be true of motor neurones of the same segment or of segments immediately adjacent.

**(A) Those the Axones of which help to make up the Fasciculi Proprii of the Spinal Cord.**

The motor neurones of the various segments of the cord are anatomically and functionally connected by means of longitudinal

nally extending association neurones. Thus the cell bodies of such association neurones situated in one segment of the cord send out their axones into the fasciculus ventralis proprius or the fasciculus lateralis proprius, where they may ascend or descend, or, bifurcating, both ascend and descend, usually close to the ventral gray columns, to terminate in the gray matter at a distance of one, several, or very many segments distant from their site of origin. The axones which connect the most distant segments with one another are most peripherally situated in the white matter, while

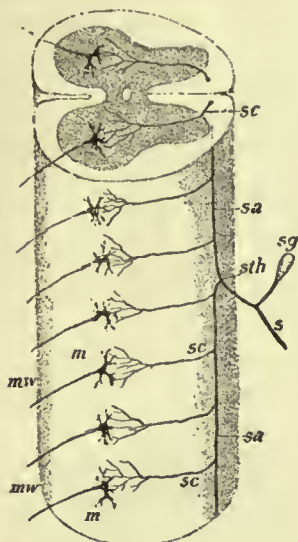


FIG. 607.—Scheme of reflex mechanism of the spinal cord. (After A. von Kölliker, *Handbuch der Gewebelehre*, Bd. ii, 1896, S. 119, Fig. 399.)

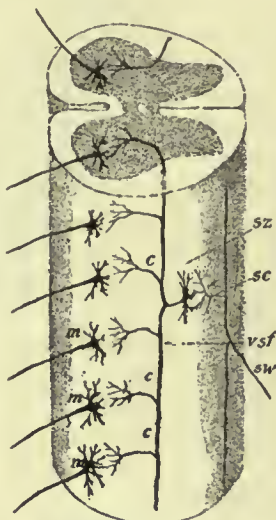


FIG. 608.—Scheme of reflex mechanism in the spinal cord. (After A. von Kölliker, *Handbuch der Gewebelehre*, Bd. ii, Leipzig, 1896, S. 122, Fig. 400.)

those connecting neighboring segments run in the white fasciculi close to the gray matter (Flatau).<sup>\*</sup> On the way these axones send off numerous collaterals to terminate in the gray matter of the segments which they pass. That there are association neurones of motor function has been proved by the cases of progressive muscular atrophy in which degenerated fibres have been found in the ground bundles without any accompanying sensory disturbance. These intermediate neurones between groups of motor

<sup>\*</sup> Flatau, E. Das Gesetz der excentrischen Lagerung der langen Bahnen im Rückenmark. Sitzber. d. Akad. d. Wiss. zu Berlin (1897).

neurones are more numerous in the lumbar and cervical enlargements than in the portions of the cord of smaller calibre. They are very abundant in the medulla oblongata and pons Varolii, where they help to form the *formatio reticularis alba*. One very important group of axones of such longitudinal association neurones is met with in the *fasciculus longitudinalis medialis* (often called the posterior longitudinal bundle), by means of which practically all the motor nuclei of the cerebral nerves are functionally connected with one another.

This place seems as suitable as any to describe the "triangular path" of Helweg,\* which extends between the nucleus olivaris inferior and the spinal cord. Whether it is olivopetal or olivofugal in direction has not yet been satisfactorily determined. In the description given by Helweg, that author stated that the system concerned consisted of an area of fine fibres triangular in shape in cross-section in the uppermost cervical cord. It was found by him in the central nervous system of individuals who during life had been insane. In the few bodies of non-insane individuals examined by him he could not find the tract mentioned, and he accordingly concluded that the fineness of the fibres in the "triangular path" represented an abnormality occurring often in the central nervous system of the insane. Though Helweg's studies were made with the carmine method, he was able to establish the relation of the fibres of his "triangular path" to the *nucleus olivaris inferior*. It was this author's idea that the path had to do in some way with the conduction of vasomotor impulses.

A comparison of Helweg's description with the plates and text of a comprehensive study of a case of degeneration following pontine hæmorrhage, published by Paul Meyer† in 1882, makes it seem certain that Meyer saw the path much earlier than did Helweg. Meyer's Fig. 12 *d* appears to correspond exactly to Helweg's path.

In 1894 v. Bechterew‡ described as the "olivary fasciculus"

\* Helweg's Dreikantenbahn. Cf. Helweg. *Arch. f. Psychiat. u. Nervenkr.*, Berl., Bd. xix (1887-'88), H. 1, S. 108.

† Meyer, P. Ueber einen Fall von Pons-hämorrhagie mit secundären Degenerationen der Schleife. *Arch. f. Psychiat. u. Nervenkr.*, Berl., Bd. xiii (1882), S. 63-98.

‡ v. Bechterew, W. Ueber den Olivenstrang des Halsmarkes. *Neurol. Centralbl.*, Leipz., Bd. xiii (1894), No. 12, S. 433.



(*Olivenstrang*) a band of fibres which in the distal region of the medulla oblongata lies close to the nucleus olivaris inferior. According to the Russian neurologist, this band of fibres belongs

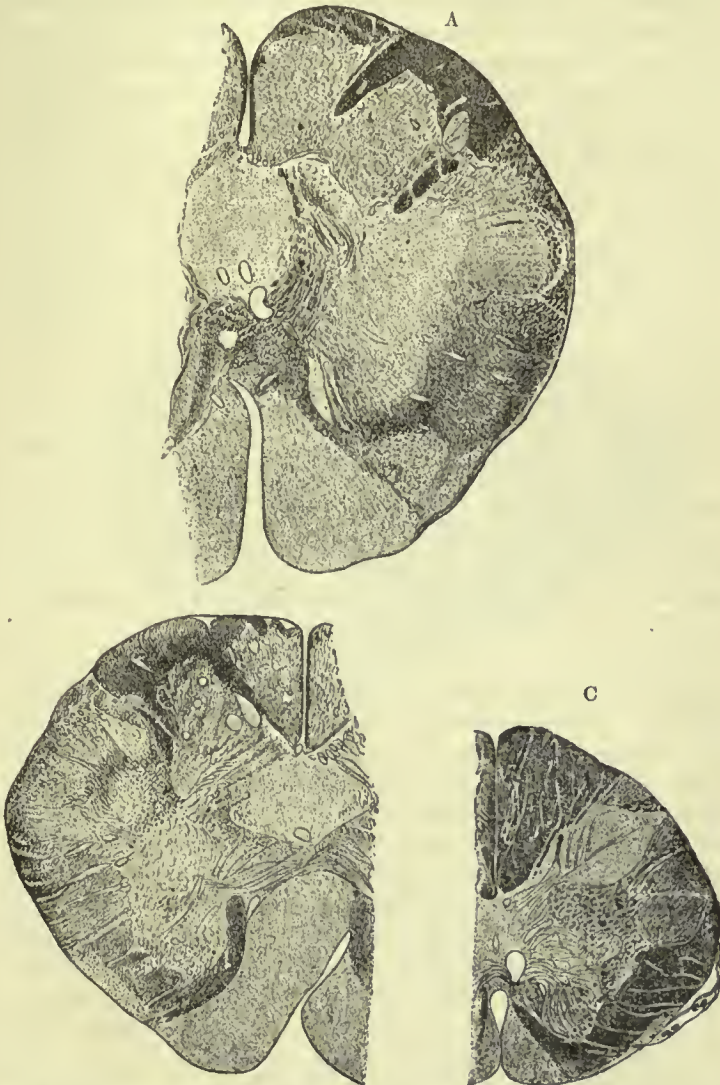


FIG. 609.—Sections through the medulla oblongata and upper cervical cord, showing the non-medullated olivo-spinal fasciculus. The pyramids are not yet medullated. (After W. von Bechterew, *Die Leitungsbahnen im Gehirn und Rückenmark*, II. Aufl., Leipz., 1899.)

to the youngest fibre systems of the spinal cord. Even the fasciculi cerebro-spinales (pyramidales) are medullated before the fibres of the *Olivenstrang*, so that it is not until some time after birth that the fibres become surrounded by myelin sheaths. Indeed, one of the easiest methods of becoming familiar with the position of the path is to study the medulla and cervical cord of the newborn babe (Fig. 609). In the cervical cord the "olivary bundle" lies at the junction of the lateral with the ventral funiculus at the region of exit of the ventral roots. In the medulla it is situated close to the lateral border of the pyramid. In cross-section the area corresponding to these fibres is lens-shaped in the lower cervical cord, triangular in the mid-cervical region. At the level of the nucleus olivaris inferior the bundle, according to von Bechterew, suddenly disappears, but this investigator grants that there is no proof that its fibres are directly related to the nerve cells of the olive.

The fibres of the olivary bundle are among the finest of the white fibres in the cord. While this bundle is medullated very late, a month after birth, the majority of the fibres of the fasciculus lateralis proprius are medullated very early in the foetus. V. Bechterew favors the view that the axones of the fibres of the *Olivenstrang* arise from perikaryons situated in the homolateral ventral horn—that is to say, the bundle, in his opinion, is spinofugal.\*

The bundle has been found degenerated in two cases by Reinhold,† and in several cases recently by Pick.‡ Reinhold inclines to the view that the bundle represents a centrifugal vasomotor path. Pick points out that the bundle is doubtless often overlooked, owing to the fact that though it can be followed as far down as the junction of the pars cervicalis with the pars thoracalis of the cord, it is usually very indistinct below the level of the second cervical segment, and the region in which it is distinctly visible is at ordinary autopsies cut through very obliquely, so that the tissue is unsuitable for study. If Chiari's myelotome be employed this difficulty is easily obviated.

\* v. Bechterew, W. Die Leitungsbahnen im Gehirn und Rückenmark. II Aufl., Leipz. (1899), S. 99–100.

† Deutsche Ztschr. f. Nervenhe., Leipz., Bd. x, S. 900.

‡ Pick, A. Beiträge zur Pathologie und pathologischen Anatomie des Centralnervensystems mit Bemerkung zur normalen Anatomie desselben. Berlin (1898), S. 222–234.

I first encountered this path in the medulla oblongata of an infant dead of an extensive superficial burn. At first I had no idea of its nature, but afterward found that it corresponded in shape and position to the Helweg-Bechterew path. Its late myelination speaks, it seems to me, in favor of its being a centrifugal rather than a centripetal tract. Moreover, the fact that when it is degenerated the olive may appear unaltered is rather against the view that this fibre system takes its origin in the nucleus olivaris inferior. Indeed, I do not feel sure that the term "olivary bundle" is well chosen. Could it not be that the fibres of the bundle come from higher parts of the nervous system, the fibres being so scattered above the level of the inferior olive that

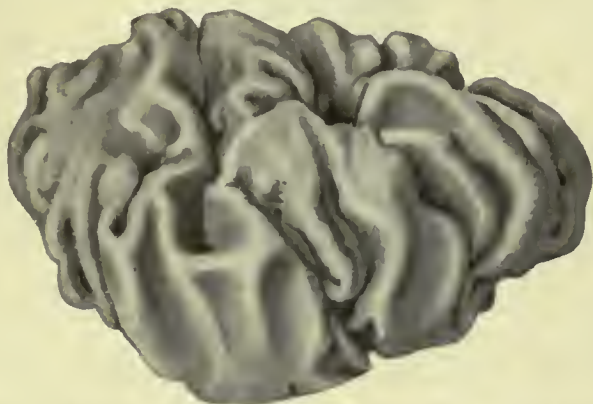


FIG. 610.—Dorso-lateral view of the nucleus olivaris inferior. (From a wax reconstruction by Miss Florence Sabin, 1899.)

they are no longer recognizable in Weigert preparations as a distinctly localizable bundle? As a matter of fact, Helweg's path in the cervical cord corresponds very closely in position to that of certain descending fibre systems in the ventro-lateral fasciculi. Pick even suggests that Loewenthal's "fasciculus marginalis anterior"\* is identical with Helweg's path. The more one thinks of this tract in connection with other centrifugal fibre systems in the ventro-lateral region of the cord the more he will be inclined, I think, to hesitate before he decides that it is a fibre-system which is entirely independent. Should it turn out that

\* Loewenthal, N. La région pyramidale de la capsule interne chez le chien et la constitution du cordon antéro-lateral de la moelle. *Rev. méd. de la Suisse rom.* (1886).

the bundle known as Helweg's *Dreikantenbahn*, or von Bechterew's *Olivenstrang*, is really only one portion of a much longer fibre system, the experience would not be a novel one; on the contrary, entirely similar steps have preceded the final unraveling

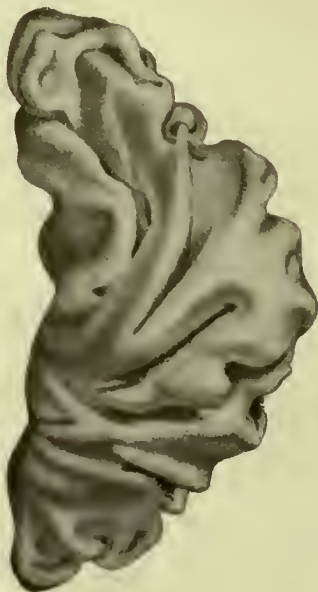

FIG. 611.—Ventral view of the nucleus olivaris inferior. (From a wax reconstruction by Miss Florence Sabin, 1899.)

in the history of the development of our knowledge of a number of the more important tracts in the central nervous system. The curious shape of the olive is shown in Figs. 610 and 611, made from drawings of a reconstruction from serial sections by Miss Florence Sabin. The gyri and sulci in the olive of the two sides agree.



- (B) Those the Axones of which run in the Fasciculus Longitudinalis Medialis and in the Formatio Reticularis Alba of the Rhombencephalon.

## CHAPTER LVIII.

### INTERMEDIARY AND UPPER MOTOR NEURONES (CONTINUED).

The vestibulo-spinal path—Distal axone systems from the gray masses of the formatio reticularis grisea.

IN the medulla and pons are situated groups of neurones with axones running down to terminate about the motor neurones of the ventral horn. Concerning the tracts which correspond to the axones of these neurones our knowledge is as yet very indefinite. One very important bundle, however, must be mentioned—namely, the bundle of axones which descends toward the spinal cord from the nucleus N. vestibularis lateralis (Deiters' nucleus). This bundle is sharply differentiated in sections of the brain of the newborn babe, stained by Weigert's method, and F. Sabin has been able to reconstruct it.

This bundle degenerates after removal of one half the cerebellum, although, according to Risien Russell and Ferrier and Turner, only when the vestibular nuclei are injured at the same time. Thomas\* is inclined to think that the bundle has its origin partly in the nucleus nervi vestibularis lateralis (Deiters) and partly in the nucleus nervi vestibularis superior (von Bechterew), a view which a careful study of Weigert preparations in the newborn babe would tend to support.

This bundle of fibres can be easily followed, especially when degenerated, deep down into the cord where the individual medullated axones turn in to terminate in the ventral horns. It is not surprising, therefore, that von Monakow, after hemisection of the spinal cord in the cervical region, found, after a long time,

---

\* Thomas, A. Le cervelet ; Étude anatomique, clinique et physiologique, Paris, 1897.

atrophy of the cells of Deiters' nucleus. He was wrong, however, in connecting the bundle with the dorsal fasciculi, for it undoubtedly descends in the ventro-lateral ground bundle.

It would seem that this uncrossed descending vestibulo-spinal neurone system has been described by various authors under different names. Many of the descending cerebello-spinal systems described by the authors in all probability correspond to the medullated axones of this system. I refer to the researches of Basilewski, Biedl, and others.

The fibres passing ventralward from Deiters' nucleus are well shown in Fig. 612. They come to lie close to the ventro-lateral portion of the upward continuation of the lateral funiculi of the spinal cord; in all probability they are more or less mixed with the axones of the ascending neurone systems which make up Gowers' tract, and with the descending axones from the red nucleus to the spinal cord. The fibres from Deiters' nucleus, however, to the cord tend to occupy a somewhat different position from the other fibres of the ventro-lateral funiculus; they come to occupy the area between the nuclei laterales and the remains of the ventral horn. Having passed downward as far as the spinal cord they lie in the peripheral parts of the zone of exit of the ventral roots, occupying the lateral portion of the ventral funiculus, and situated, in the main, ventral from the ventral horn. Some of the fibres, it is stated, extend as far as the pars lumbalis of the spinal cord, and are ultimately exhausted by branches which turn in to end in the gray matter of the ventral horn.

In addition to the descending fibres from Deiters' nucleus there appear to be many other descending fibre systems in the formatio reticularis. These have their origin in perikaryons of the formatio reticularis grisea, particularly in the inferior middle and superior central and lateral nuclei.

Those fibres descending from the nucleus centralis medius and nucleus lateralis medius (von Beehterew's nucleus reticularis tegmenti pontis) have been best worked out. A good description is to be found in Tschermak's recent article. Those axones from the nucleus centralis medius can be followed to the fasciculus longitudinalis medialis. These there divide into ascending and descending branches. The descending branches appear to run down into the ventral funiculus of the cord, there occupying the so-called fissural part of the funiculus (*Fissurenstrang* of the

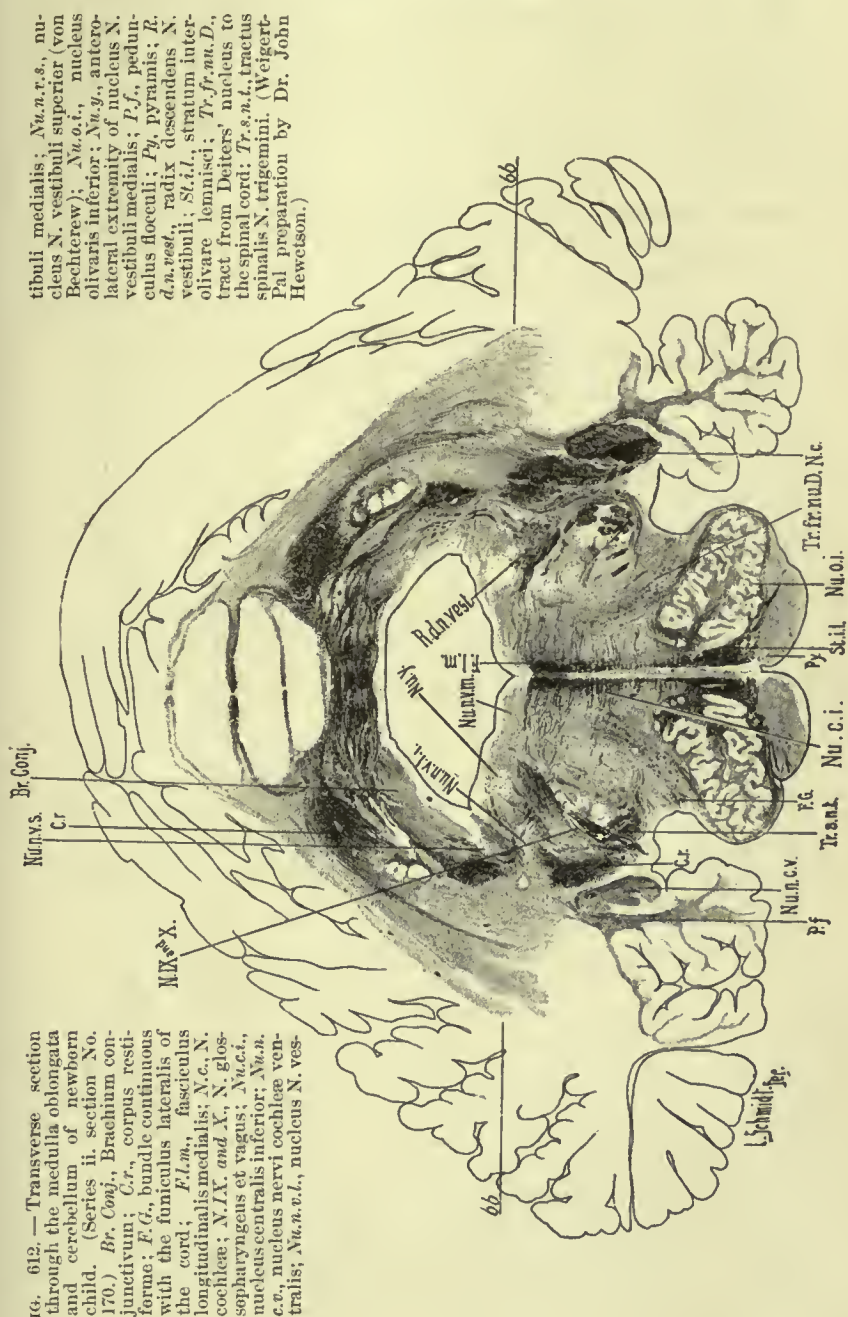


FIG. 612. — Transverse section through the medulla oblongata and cerebellum of newborn child. (Series ii. section No. 170.) *Br. Conj.*, brachium conjunctivum; *Cr.*, corpus restiforme; *F. G.*, bundle continuous with the funiculus lateralis of the cord; *F. L. m.*, fasciculus longitudinalis medialis; *N. c.*, N. cochleæ; *X. IX. and X.*, N. glossopharyngeus et vagus; *Nu. c. i.*, nucleus centralis inferior; *Nu. n. v.*, nucleus N. vestibularis; *Nu. n. v. l.*, nucleus N. vestibularis superior (von Bechterew); *Nu. o. i.*, nucleus olivaris inferior; *Nu. g.*, anterolateral extremity of nucleus N. vestibularis medialis; *P. f.*, pedunculus flocculi; *Py.*, pyramis; *R. d. n. v. s.*, radix descendens N. vestibularis; *St. i. l.*, stratum interolivare; *Tr. fr. nu. D.*, tractus from Delters nucleus to the spinal cord; *Tr. s. n. t.*, tractus spinalis N. trigemini. (Weigert-Pal preparation by Dr. John Hewetson.)

Germans). Collateral fibres are given off to the *formatio reticularis* on the way, and to the ventral horn as it is passed. Fibres of this neurone system extend throughout the whole length of the spinal cord. This might be called the uncrossed descending spinal neurone system from the *formatio reticularis*.

Another system of axones from the *nucleus centralis medius* can be followed, passing transversely through the *fasciculus longitudinalis medius* to the dorso-lateral part of the opposite side of the *formatio reticularis alba*. Having reached that situation, the fibres bifurcate, the descending branches running spinalward in the bundle lateral from the *fasciculus longitudinalis medialis*, and ventral from the *genu internum radialis nervi facialis*. The fibres lower down are more and more ventrally situated, and come to lie in the middle of the lateral zone of the *formatio reticularis dorso-lateral* from the *nucleus olivaris inferior*, and medial from the ventral angle of the mass of fibres which represents the *tractus spinalis nervi trigemini*. The fibres we are considering now come to lie between the *tractus spinalis nervi trigemini* and the *nuclei funiculi lateralis*; while in the spinal cord the bundle is situated in the dorso-lateral region of the field occupied by the lateral pyramidal tract, a little medial from the descending fibres from the red nucleus and from the direct cerebellar tract. The fibres of this crossed system from the *nucleus centralis medius* can be followed down in the spinal cord as far as the *conus terminalis*. It grows ever smaller in volume owing to the passage of terminals and collaterals which are distributed to the central zone of the *substantia grisea*.

Fusari\* has described a case of degeneration implicating the fibres here mentioned.

---

\* Riv. sperim. (1896), vol. xxii, p. 117.



(C) Those the Cell Bodies of which are Situated in the  
Cerebellum.

CHAPTER LIX.

INTERMEDIARY AND UPPER MOTOR NEURONES (CONTINUED).

The question of cerebello-spinal paths—Studies of Marchi, Ferrier and Turner, Risien Russell, Biedl, Thomas, and others.

IN the cerebellum are situated also neurones the axones of which descend in order to affect directly the lower motor neurones. As to the exact position of these neurones and their axones we are not well informed.

The studies of the descending cerebello-spinal tracts begin with the investigations of Marchi,\* who described such a bundle running down in the peripheral part of the ventro-lateral fasciculi of the cord. He believed that these fibres came mainly from the vermis, that they passed from the brachium pontis and thence by way of the fasciculus longitudinalis medialis and the stratum interolivare lemnisci into the ventro-lateral fasciculi of the cord. He followed the degeneration through the whole length of the cord, where it occupied two areas—(1) a ventro-lateral area extending from the sulcus ventralis to the ventral extremity of the direct cerebellar tract of Flechsig, and (2) a more lateral area situated just in front of the fasciculus cerebro-spinalis lateralis. He believed that these fibres terminated in the ventral horn of the spinal cord, and that a lesion of the bundle containing them led also to degeneration in the ventral roots of the spinal nerves. The ventro-lateral bundle of Marchi corresponds to the descending cerebellar bundle, which has been described by Loewenthal, Schaefer, Michael Foster, and others. The negative findings of

---

\* Marchi, V. Sull' origine e decorso dei peduncoli cerebellari e sui loro rapporti cogli altri centri nervosi. 8vo, Firenze (1891), pp. 1-38. Also in *Riv. sper. di treniat.*, Reggio-Emilia, vol. xvii (1891), pp. 357-368. Also Transl. in *Arch. ital. de biol.*, Turin, t. xvii (1892), pp. 190-201.

Ferrier and Turner,\* however, have made many neurologists skeptical as to the existence of these centrifugal spinal fibres arising in the cerebellum, especially as the English investigators state positively that when one lobe of the cerebellum is extirpated there is no degeneration at all in the spinal cord. They found degeneration, it is true, in the corpus restiforme, but this, they believed, concerns the fibres extending to the inferior olives and to the nuclei funiculi gracilis et cuneati, or when the vermis is extirpated the fibres running to the nucleus of Deiters. They assert that the degeneration described by Marchi is due to a lesion of the nucleus of Deiters or to a lesion of the lemniscus.

Another English investigator, Risien Russell,† has carried out a similar series of experiments, but, instead of employing the method of Weigert, has used the more delicate method of Marchi. On extirpation of the lateral lobe of the cerebellum, Russell finds degeneration in the corpus restiforme on the same side as the lesion. These degenerative fibres are not scattered, but are limited to the lateral border of the restiform body. On examining sections lower down, these fibres come to occupy a more ventral position inside the restiform body. They leave this bundle in large part to become distributed to the nucleus olivaris inferior of the same side and of the opposite side. A few fibres descend into the ventro-lateral fasciculi of the cord in the cervical region. These fibres, however, Russell states, are scattered and few in number, and disappear at the upper part of the thoracic region.

When the vermis is removed (to quote Russell's findings further) the corpus restiforme degenerates on both sides; the fibres become distributed in the formatio reticularis of the medulla, going to the nucleus olivaris inferior of both sides. Some fibres descend into the ventro-lateral fasciculi of the spinal cord. Russell does not lay much stress upon the descending cerebellar paths to the cord, but is inclined to agree with Ferrier and

---

\* Ferrier. A Record of Experiments Illustrative of the Symptomatology and Degenerations Following Lesions of the Cerebellum and its Peduncle and Related Structures in Monkeys. Phil. Trans. Roy. Soc., Lond., vol. clxxxv (B.) (1895), pp. 719-778.

† Russell, J. S. R. Degeneration Consequent on Experimental Lesions of the Cerebellum. Proc. Roy. Soc., Lond., vol. lvi (1894), pp. 303-305; and Experimental Researches into the Functions of the Cerebellum. Phil. Trans. Roy. Soc., vol. clxxxv (B) (1895), pp. 819-861.

Turner that the marked degeneration observed by Marchi depends upon an accidental lesion of the nucleus of Deiters.

A stout supporter of the view that extensive bundles of fibres descend directly from the cerebellum into the spinal cord is found in Biedl.\* After reviewing more or less thoroughly the bibliography of the subject this investigator describes his own anatomical findings after section of the corpus restiforme. He decides in favor of the centrifugal cerebellar path of Marchi,

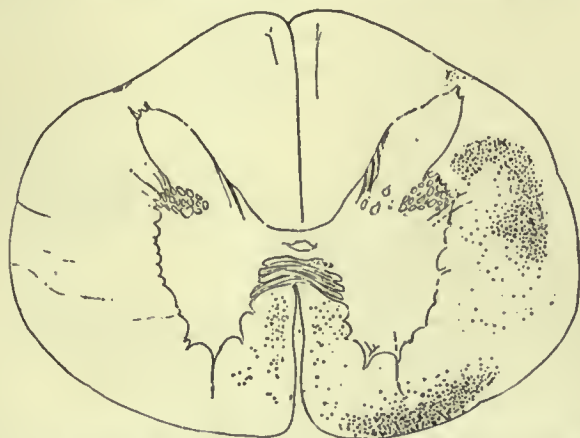

FIG. 613.—Descending degeneration in the spinal cord after experimental section of the corpus restiforme. (After A. Biedl, *Neurol. Centralbl.*, Bd. xiv, 1895, S. 441, Fig. 1.) Level of upper cervical cord. Biedl is probably wrong in thinking that these fibres come from the cerebellum.

and states that he can follow it from the uttermost portion of the cervical cord almost as far as the sacral end of the spinal cord. One bundle runs in the ventro-lateral fasciculus in the area corresponding to that described by Marchi, Loewenthal, Foster, Schäfer, and others. The other bundle descends in the funiculus lateralis, and, he asserts, in the exact area occupied by the lateral pyramidal tract—a very important finding if it be confirmed (Fig. 613). He disagrees with Marchi, however, as to the way in which the fibres get from the cerebellum to the cord. Whereas Marchi believes that they pass from the cerebellum by way of the brachium pontis through the fasciculus longitudinalis medialis, and the stratum interolivare lemnisci to the

---

\* Biedl, A. Absteigende Kleinhirnbahnen. *Neurol. Centralbl.*, Leipz., Bd. xiv (1895), S. 434, 493.

cord, Biedl believes that they go from the cerebellum to the corpus restiforme, and thence, partly through the fasciculus longitudinalis but mainly through the ventro-lateral ground bundles, to the spinal cord.

Thomas, in Paris, has also employed Marchi's method, and states that total removal of the cortex of one cerebellar hemisphere causes no degeneration in the spinal cord. On extirpation of one whole hemisphere, however, he finds distinct descending degeneration in the spinal cord of the same side in the ventro-lateral fasciculi, which can be followed as far as the lumbar region. He is of the opinion that these fibres arise in the nucleus dentatus, and that they pass through Bechterew's nucleus and

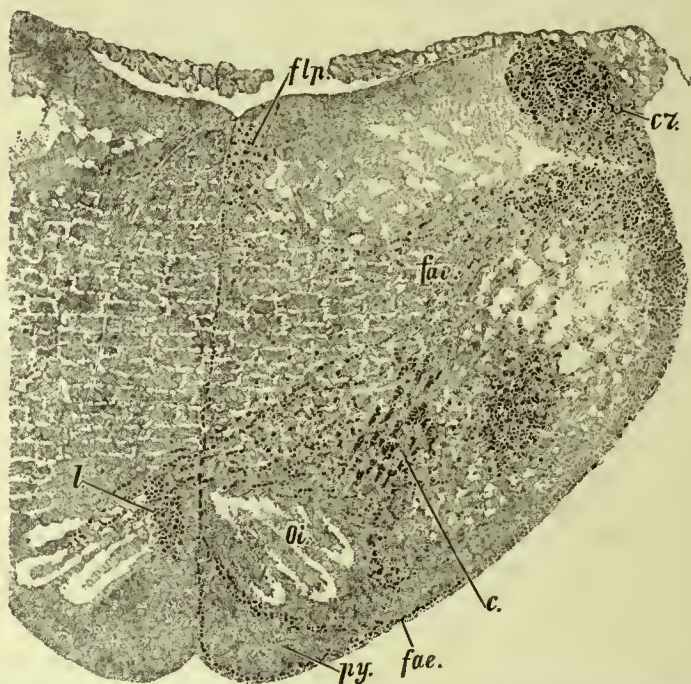


FIG. 614.—Degeneration following section of the corpus restiforme. (After a preparation of A. Basilewski, taken from W. von Bechterew, *Die Leitungsbahnen im Gehirn u. Rückenmark*, II. Aufl., Leipz., 1899, S. 390, Fig. 368.) *cz*, corpus restiforme; *flp*, fasciculus longitudinalis medialis; *fae*, fibre arcuate internæ; *fae*, fibre arcuate externæ ventrales; *l*, stratum interolivare lemnisci; *oi*, nucleus olivaris inferior; *py*, pyramis.

the nucleus of Deiters, and thence by way of the formatio reticularis to the ventro-lateral fasciculi of the cord. The path



would then occupy the same region in the formatio reticularis as does the bundle which we know descends from Deiters' nucleus to

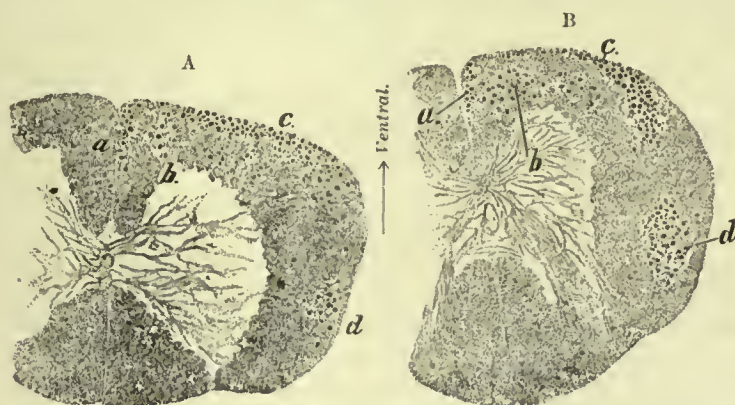


FIG. 615.—Cross section of cervical cord (A) and of lower part of the spinal cord (B), showing degeneration after section of the corpus restiforme of the dog. (After preparations by A. Basilewski, taken from von Bechterew, *Die Leitungsbahnen im Gehirn und Rückenmark*, Leipz., 1899, II. Aufl., S. 388, Figs. 366 and 367.) *a*, descending tracts of the fasciculus longitudinalis medialis; *b*, continuations of the fibres of formatio reticularis near the fasciculus longitudinalis medialis; *c*, fibre system from the median part of the corpus restiforme; *d*, fasciculus intermedius.

the spinal cord; Thomas states that if, along with the lesion of the cerebellum, the nucleus of Deiters and the nucleus of von Bechterew be injured, the descending degeneration in this descending tract is much more extensive. The findings of Basilewski after section of the corpus restiforme are illustrated in Figs. 614 and 615.

On the whole, it must be confessed that our knowledge of the descending cerebello-spinal paths is at present unsatisfactory, the results of the various investigators being markedly contradictory. As far as one can judge from the mass of conflicting data before us, it seems likely that a certain number of fibres descend from the internal nuclei of the cerebellum to the cord, and possibly a few axones from Purkinje cells in the cerebellar cortex, especially since Ramón y Cajal \* finds a few axones of Purkinje cells passing directly into the corpus restiforme.

It seems likely, however, that the influence of the cerebellum upon the spinal cord is mediated mainly by means of neurones

\* Ramón y Cajal, S. *Beitrag zum Studium der Medulla Oblongata des Kleinhirns und des Ursprung der Gehirnnerven*. Deutsch von Bresler, Leipz. (1896), S. 121.

intercalated between the cerebellum and the cord. These intercalated neurones consist, in the first place, of those having their cell bodies situated in the nucleus nervi vestibuli lateralis of Deiters, and possibly in the nucleus nervi vestibuli superior of von Beehterew, and (2) those having their cell bodies situated in the nucleus olivaris inferior of the two sides. Von Kölliker has especially emphasized the importance of the nucleus olivaris inferior as a way-station between the cerebellum and the spinal cord. We know now that, although the majority, perhaps, of the fibræ cerebello-olivares consist of axones arising from cells in the nucleus olivaris inferior and passing to the cerebellum of the opposite side, a certain number of them consist of medullated axones arising from cell bodies situated in the cerebellum of one side, and passing across the raphe to terminate in the nucleus olivaris inferior of the opposite side (von Kölliker, Russell, Biedl, Thomas). The connection between the nucleus olivaris inferior and the spinal cord must be made by means of the fasciculus ventralis proprius and the fasciculus lateralis proprius. The so-called olivo-spinal bundle has been described above. In Weigert-Pal preparations of the medulla of the newborn babe large numbers of medullated fibres can be seen extending between these fasciculi proprii of the cord and the hilus nucleoli olivaris inferioris. How many of these fibres pass from the cord to terminate in the olive, and how many pass from the olive to terminate in the cord, it is as yet impossible to say. The study of experimental degenerations and of suitable Golgi preparations must be relied upon to give us the information which we desire upon this point.

(D) Those the Cell Bodies of which are Situated in the Mesencephalon and Diencephalon.

## CHAPTER LX.

### INTERMEDIARY AND UPPER MOTOR NEURONES (CONTINUED).

The path from the superior colliculus to the spinal cord—The path from the red nucleus to the spinal cord—The fasciculus tegmenti centralis or *centrale Haubenbahn*.

THAT the lower motor neurones stand to a certain extent under the influence of neurones whose cell bodies are situated in the mesencephalon there can be but little doubt. Reference has already been made to the fact that many optic neurones and auditory neurones of the second order terminate about cell bodies in the superior colliculus of the corpora quadrigemina. The axones of these cells pass down, decussate, and sooner or later join the fasciculus longitudinalis medialis, the fibres of which, as we know, come into contact relation with the motor nuclei of the cerebral nerves, and with the ventral horns of the cervical cord. Fibres from the nucleus lateralis superior to the fasciculus longitudinalis medialis are well shown in Fig. 616. In this way the connection of the corpora quadrigemina (and of the retina) with the neurones in the cervical cord, the axones of which pass through the rami communicantes to the sympathetic and lead to alterations in pupillary contraction, may be explained.

The studies of Held and Tschermak make it appear that this crossing spinal system from the middle and deep gray matter of the superior colliculus of the corpora quadrigemina forms in large part the decussatio tegmenti dorsalis (*fontaineartige Haubenkreuzung* of Meynert). Having crossed the raphe, the fibres lie in a separate bundle which goes through the whole brain stem just ventral to the fasciculus longitudinalis medialis.\* According to Held, collaterals are given off on the way to the

---

\* *Praedorsales Längsbündel* of the Germans.

deep gray matter of the superior colliculus and to the stratum griseum centrale of the same side, and, by way of the dorsal commissure, to the opposite side. Collaterals are also sent into the nucleus nervi ocnomotorii of each side, and to the nucleus nervi trochlearis and nuclei nervi abducentis of the opposite side. Tschermak has found that the distal axones here concerned give off also collaterals lateralward to the cells of the formatio retien-

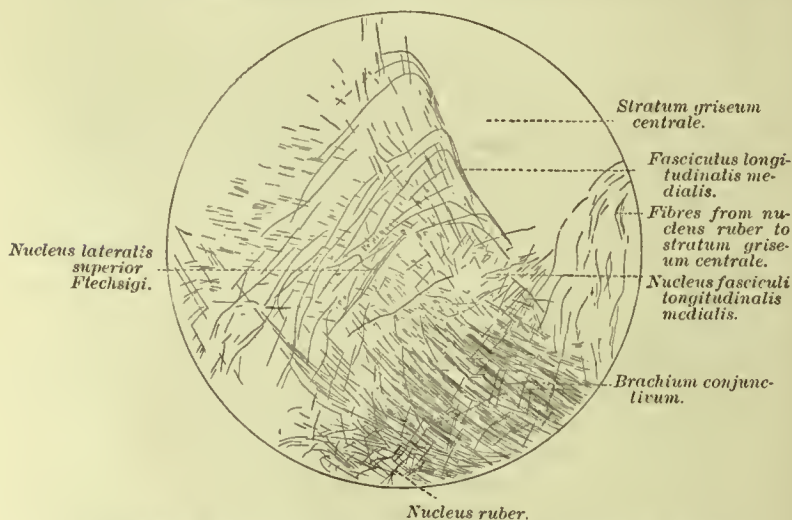


FIG. 616.—Section through the midbrain illustrating the relation of the nucleus lateralis superior to the fasciculus longitudinalis medialis. (After H. Held, Abhandl. d. sachs. Gesellsch. d. Wissensch., Leipz., 1892, Tab. iii, Fig. 11.)

laris, especially to the nucleus centralis medius and the nucleus centralis inferior. Some collaterals cross the raphe to the same nucleus of the other side. Lower down the bundle concerned comes to occupy the ventral part of the fissural portion of the ventral funiculus, and exhausts itself by giving off collaterals and terminals to the columna grisea ventralis of the same side, but partly by sending axones through the commissura ventralis alba to terminate in the contralateral columna grisea ventralis. The longest stem fibres of the neurone system here under consideration reach as far down as the lower part of the pars lumbalis. It seems likely that Loewenthal's marginal fasciculus is identical with the system here described.

A very interesting series of experiments is that made by Boyce.\*

\* Boyce, R. Neurol. Centralbl., Leipz. (1894), S. 466.



He made hemisection of the midbrain at the level of the third nerve in cats, and found, by Marchi's method, descending degeneration through the dorsal tegmental decussation of Meynert into the bundle which runs just ventral to the fasciculus longitudinalis medialis of the opposite side. He followed these fibres down into the fissural part of the ventral funiculus of the cord as far as the pars thoracalis.

Boyce also found degeneration through the ventral tegmental decussation of Forel; further down, degenerated fibres at first dorso-lateral from the lemniscus medialis, passing through the region traversed by the stem of the facial nerve; then ventral from the tractus spinalis nervi trigemini, and dorsal from the

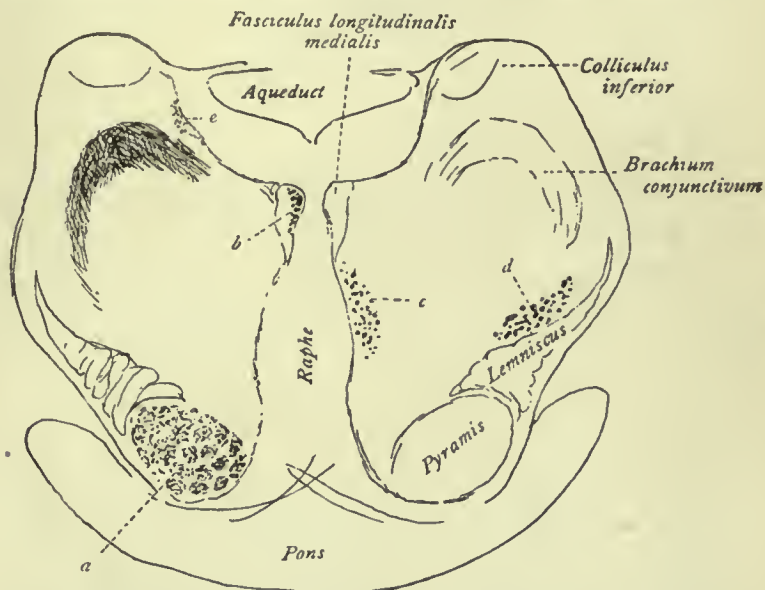


FIG. 617.—Section through the pons showing degeneration of fibres after removal of the left hemisphere. (After R. Boyce, *Neurol. Centralbl.*, Leipz., Bd. xiii, 1894, S. 467, Fig. 1.) *a*, descending degeneration of the fasciculi cerebro-spinales; *b*, descending degeneration of the fasciculus longitudinalis medialis; *c*, descending degeneration of the fibres of the fasciculus ventro-lateralis (from the decussatio tegmenti dorsalis Meynerti); *d*, descending degeneration of the fibres of the fasciculus lateralis (from the decussatio tegmenti ventralis Foreli); *e*, degeneration of the radix descendens (mesencephalica) N. trigemini.

nucleus funiculus lateralis into the spinal cord, where the fibres lay just in front of the degenerated lateral pyramidal tract. The degenerated fibres could be followed as far as the lumbar

cord. The findings in Boyce's cases are well illustrated in Figs. 617, 618, and 619.

It seems likely, as Tschermak suggests, that Boyce's bundle from the dorsal tegmental decussation corresponds to Held's

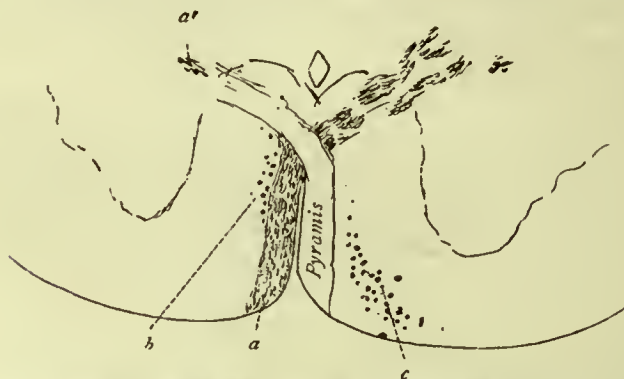


FIG. 618.—Section showing degeneration of the decussatio pyramidum after removal of the left hemisphere. (After R. Boyce, *Neurol. Centralbl.*, Leipz., Bd. xiii, 1894, S. 468, Fig. 2.) *a*, degeneration of pyramis, left side; *a'*, degeneration of fibres in the region of the fasciculus cerebro-spinalis ventralis; *b*, fibres from the fasciculus longitudinalis medialis; *c*, fibres to the fasciculus ventro-lateralis (from the decussatio tegmenti dorsalis Meynerti).

crossing spinal system from the superior colliculus to the ventral horns. Boyce's fibres from the ventral tegmental decussation probably correspond to (1) the crossing descending system from the red nucleus; (2) the crossing descending system from the nucleus centralis superior and the nucleus lateralis superior.

The crossing descending spinal system from the nucleus ruber of the tegmentum connects the nucleus ruber with the spinal cord. The axones arise from perikaryons in the nucleus ruber. They then pass through the decussatio tegmenti ventralis Foreli, and come then to be situated ventro-lateral from the nucleus ruber of the other side (Held, Ramón y Cajal). At the level of the colliculus inferior the axones of this system lie among the fibres of the medial part of the lemniscus lateralis. Further spinalward these fibres occupy a region situated between the tractus spinalis nervi trigemini and the nucleus olivaris superior. In its descent through the medulla this descending system from the red nucleus is mixed up with the fibres which ascend in Gowers' tract. The fibres pass into the region of the medulla, which corresponds to the upward continuation of the ventro-lateral funiculi of the cord. The fibres of the descending

system from the red nucleus are situated somewhat laterally in the bundle, but medio-ventrally as regards the tractus spinalis nervi trigemini, and lower down, lateral from the nucleus funiculi lateralis. In the funiculus lateralis of the spinal cord these fibres assume in the cross section the form of a comma lying medial from the direct cerebellar tract in the lateral part of the area corresponding to the fasciculus cerebro-spinalis lateralis. The comma extends from the dorsal horn ventralward as far as the region of Gowers' tract. The bundle is gradually exhausted, owing to the giving off of collaterals and terminals to the substantia grisea, especially to the lateral horn and the central zone of gray matter. The longest fibres reach as far down as the pars lumbalis medullæ spinalis. This bundle probably corresponds to that described by Ferrier and Turner as descending from the nucleus lemnisci lateralis. It appears to have been degenerated also in Biedl's cases. Tschermak is of the opinion

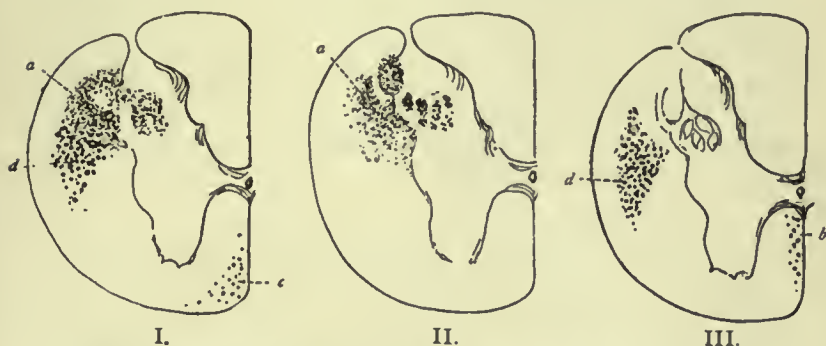


FIG. 619.—Sections through the upper part of the cervical spinal cord. (After R. Boyce, *Neurol. Centralbl.*, Leipz., Bd. xiii, 1894, S. 469, Fig. 3.) I. Degeneration after removal of the left hemisphere, right side; *a*, degeneration of fibres in the region of the fasciculus cerebro-spinalis lateralis; *c*, degeneration of fibres of the fasciculus ventro-lateralis (from the decussatio tegmenti dorsalis Meynerti); *d*, degeneration of fibres of the fasciculus lateralis (from the decussatio tegmenti ventralis Foreli). II. Degeneration after removal of the motor zone of the left hemisphere, right side; *a*, degeneration of the fibres of the fasciculus cerebro-spinalis lateralis. III. Degeneration after removal of the left hemisphere, left side; no degeneration of the fasciculus cerebro-spinalis lateralis; *b*, degeneration of fibres from the fasciculus longitudinalis medialis; *d*, degeneration of fibres of the fasciculus lateralis, section below the level of their decussation.

that in Basilewski's case, and in the experiment of Sakowitsch reported by Bechterew, this bundle from the red nucleus was also degenerated.

The view that from the diencephalon axones pass downward

which can influence the motor nuclei has met with general acceptance, though in just what portions of the corpus striatum and thalamus the cell bodies of these neurones are situated, and in what tracts their medullated axones pass downward, whether in the tegmental tract or in the bundles of the basis pedunculi, we are as yet almost completely ignorant. Von Monakow assumes that all thalamic tracts are corticopetal, and that the thalamus does not represent a motor centre intercalated between the cortex and the lower motor centres.

Von Bechterew and Flechsig have described as descending from the diencephalon a special bundle which they call the *centrale Haubenbahn*. I have referred to it in various illustrations of the region through which it passes as the fasciculus tegmenti centralis. There seems to be some doubt as to whether it has its origin in perikaryons in the thalamus or in the nucleus lentiformis. The bundle is easily isolated by the method of myelination, as the fibres are medullated very late. It has also been described degenerated in a recent case studied by von Bechterew. Thus far studies by Golgi's method of this fasciculus are wanting. It appears to terminate in the nucleus olivaris inferior. Its position in the central region of the pars dorsalis pontis gives it its name. [For figures illustrating the fasciculus tegmenti centralis the index should be consulted.]



(E) Those the Cell Bodies of which are Situated in the Telen-  
cephalon (Pallium and Rhombencephalon).

We have much more exact information concerning the neurones which throw peripheral motor neurones under the influence of the pallium. These may be divided into (*a*) neurones with medullated axones, making up the fibres of the pyramidal tract; (*b*) neurones with medullated axones corresponding to the frontal cerebro-corticopontal path; (*c*) neurones with medullated axones corresponding to the temporal cerebro-corticopontal path; (*d*) neurones which possibly connect the occipital region of the cortex with the lower motor neurones; and (*e*) neurones connecting the olfactory region of the cortex with the lower motor neurones.

## CHAPTER LXI.

### THE PYRAMIDAL TRACT.

The motor area of the cortex—Perikaryons and dendrites—Course followed by the axones—Decussatio pyramidum—Fasciculus cerebro-spinalis lateralis—Fasciculus cerebro-spinalis ventralis—Studies by the embryological method of Flechsig—Physiological experiment including electrical stimulation—Secondary degenerations of the pyramidal tract—Studies by Golgi's method.

#### 1. Those the Axones of which Correspond to the Fasciculi Cerebro-spinales or Pyramidal Tract.

(*Ad a.*) THE neurones with axones corresponding to the fibres of the pyramidal tract have been most carefully investigated, and are the best understood of all the neurones now under consideration. Their cell bodies are situated in the so-called motor area of the cortex (*zone motrice* of Charcot). Their axones extend from this situation to the motor nuclei of the cerebral nerves and to the cell bodies of the peripheral motor neurones situated in the spinal cord, some of them reaching as far as the lowermost portion of the sacral spinal cord. Thus some of the motor

axones are among the longest of cell processes occurring in the body.\*

The motor area of the cortex, corresponding to the situation of the cell bodies and dendrites of the neurones we are now describing, includes the anterior and posterior central gyri, the feet of the superior, middle, and inferior frontal gyri on the external surface of the hemisphere, and the lobulus paracentralis on the inner surface of the hemisphere. It will be immediately noticed that this area corresponds closely to the region of the cortex in which terminate the axones of the central sensory neurones which carry impressions from the periphery of the body, muscles, and internal organs to the cerebral cortex. Indeed, the motor area corresponds more or less closely to what has above been designated as the "somæsthetic area" of the cortex (*Körpergefühlshäre* of Munk, *Tastphäre* of Flechsig).† In this area are situated many millions of cortical pyramidal cells, each supplied with one main strong apical dendrite running out to branch more or less freely in the molecular layer of the cortex, with dendrites of smaller size coming off from the angles at the base of the pyramid, and with an axone which soon becomes medullated and runs into the white matter to form one of the constituent fibres of the centrum semi-ovale of the hemisphere. By no means all of the pyramidal cells situated in the motor area belong to the group of neurones which we are just now considering. Besides large numbers of Golgi cells of Type II of local significance, and cells with axones ascending to pass out toward the surface of the cortex (cells of Martinotti),‡ a great number of these cells represent the neurones of association systems connecting neighboring gyri, gyri at a distance from one another in the same hemisphere, and gyri in one

---

\* Strictly speaking, the pyramidal tract does not include the axones going to the nuclei of the cerebral nerves, but only those going through the pyramids of the medulla to the spinal cord. The tendency is becoming general, however, to extend the term.

† Tamburini has stated as a general law that motion and sensation are represented together in the pallium, and Golgi has strongly supported a similar view.

‡ Martinotti, C. Di alcuni nuovi gruppi di cellule cerebrale simili ai cosiddetti granuli del cervelletto. *Ann. di freniat. e sc. aff., etc.*, Torino (1888-'89), i, pp. 221-226.—Contributo allo studio della corteccia cerebrale, ed all'origine centrale dei nervi. *Ann. di freniat., etc.*, Torino, vol. i (1888-'89), pp. 314-332. Transl. in *Internat. Monatsschr. f. Anat. u. Physiol.*, Leipz., Bd. vii (1890), S. 69-90.

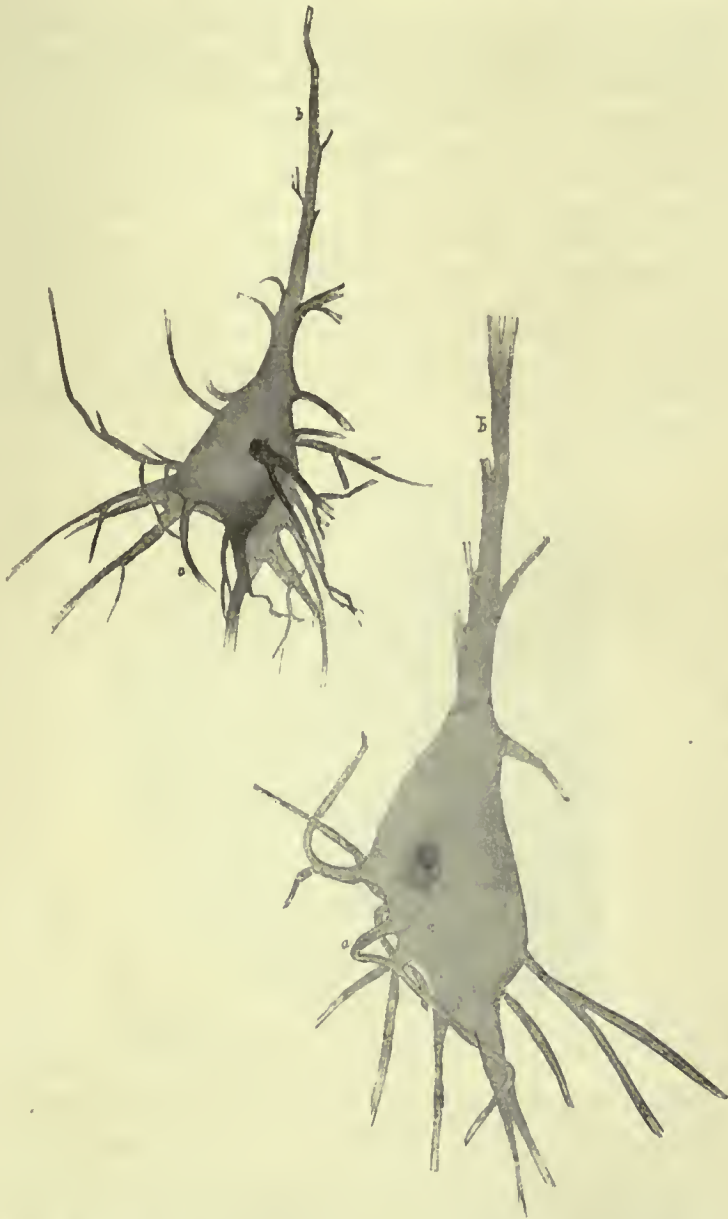


FIG. 620.—Large pyramidal cells of the cortex. (After W. von Bechterew, *Die Leitungsbahnen im Gehirn und Rückenmark*, Leipz., II. Aufl., 1899, S. 456, 457, Figs. 417, 418.) ●

hemisphere with those of the other. Indeed, only a relatively small number of pyramidal cells in the motor area of the cortex represent cell bodies of neurones, the axones of which pass downward through the cerebrospinal axis to come into conduction relation with the lower motor neurones. The cell bodies of these pyramidal cells are, as a rule, of rather larger size than their neighbors, and include the large pyramidal cells (Fig. 620) described by Bevan Lewis and by Hammarberg and the so-called giant pyramidal cells met with in these regions (Fig. 621), especially those gigantic cells in the lobulus paracentralis (*Riesenpyramidenzellen* of Betz) the axones of which have to run the longest distance (to the lumbar and sacral cord) (Fig. 622). The structure of the cortex of the gyrus centralis anterior is represented in Fig. 623.

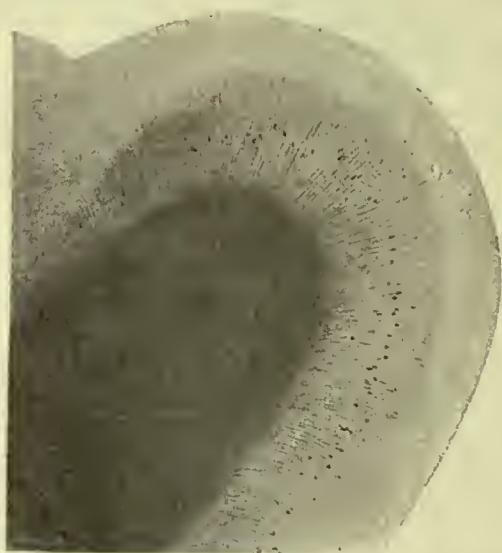

FIG. 621.—Diagram showing position and number of giant pyramidal cells in the gyrus centralis anterior of a man forty-three years old. (After A. von Kölliker, *Handbuch der Gewebelehre*, Bd. ii, S. 650, Fig. 730.)

The exact relations of the cells in this area to one another and to incoming fibres have been carefully worked out by Bevan Lewis,\*

---

\* Lewis, B. On the Comparative Structure of the Cortex Cerebri. *Brain*, vol. i (1878-'79), pp. 78-96.—Lewis, B. and H. Clarke. The Cortical Lamination of the Motor Area of the Brain. *Proc. Roy. Soc., Lond.*, vol. xxvii (1878), pp. 38-49.—Lewis, W. B. *Researches on the Comparative Structure*



Golgi,\* Ramón y Cajal,† Hammarberg, E. A. Schäfer, Andriezen, von Kölliker, and others. The cell bodies with axones

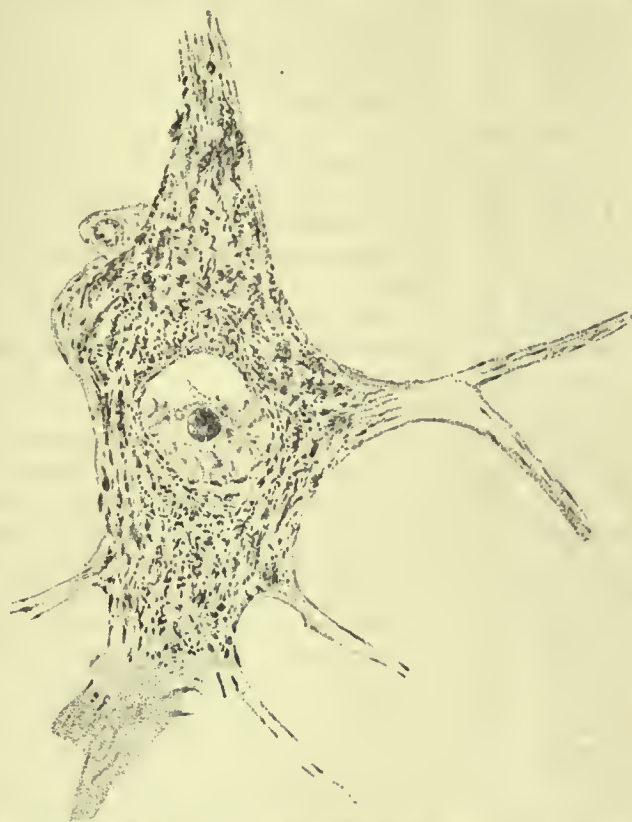

FIG. 622.—Normal Betz cell from the human paracentral lobule. (After Adolf Meyer, *Amer. Journ. of Insanity*, vol. liv, 1897.)

of the Cortex Cerebri. *Phil. Trans. Roy. Soc., Lond.*, vol. clxxi (1880), pt. i, pp. 35-64.

\* Golgi, C. *Sulla fina anatomia degli organi centrali del sistema nervoso*. Milano, 1886 (1885), Hoepli, 8vo, p. 214.

† Ramón y Cajal, S. *Sobre la existencia de células nerviosas especiales en la primura capa de las circunvoluciones cerebrales*. *Gac. méd. catal. Barcel.*, vol. xiii (1890), pp. 737-739.—*Sobre la existencia de bifurcaciones y colaterales en los nervios sensitivos craneales y sustancia blanca del cerebro*. *Gac. san. de Barcel.*, vol. iii (1890-'91), pp. 282-284, and in *Crón. méd., Valencia*, vol. xiv (1891), pp. 230-232.—*El nuevo concepto de la histología de los centros nerviosos*. *Rev. de cien. méd. de Barcel.*, vol. xviii (1892), pp. 361-376; 457-476.




FIG. 623.—Section through the gyrus centralis anterior, to show the nerve cells. (After C. Hammarberg, *Studier öfver Idiottens klinik. oeh. pathologie, etc.*, Upsala, 1893, Taf. i, Fig. 2.)

going to the motor nuclei of the face are situated on the lateral surface of the cortex just above the Sylvian fissure. Those going to the cervical enlargement of the spinal cord (governing the lower motor neurones of the neurotomes which innervate the muscles of the upper limb) are situated in the middle region, while those the axones of which run to the lumbar and sacral cord are situated in the upper portion of this area, and in the lobulus paracentralis on the inner surface of the hemisphere.

The axones shortly after leaving the cells give off collaterals which Flechsig\* has shown to be medullated. The axones of these motor neurones all stream out into the centrum semi-ovale, and run in the corona radiata of the internal capsule. Arrived at the internal capsule, they occupy (at the level most frequently described) the genu and the anterior two thirds of the posterior limb of the internal capsule.† The fibres at the knee of the capsule are those which have come from the lowermost region of the motor area (fibres governing movements of the tongue and face); behind them are situated the fibres of the middle region of the motor area (fibres governing movements of the shoulder, arm, forearm, and hand); while most posterior of all are situated the fibres from the uppermost portions of the motor area (fibres governing movements of the lower extremity). From the internal capsule these medullated axones are continued down through the base of the cerebral peduncle, of which they occupy (roughly speaking) the middle three fifths, and

\* Flechsig, P. Ueber eine neue Färbungsmethode des centralen Nervensystems und deren Ergebnisse bezüglich des Zusammenhanges von Ganglienzellen und Nervenfasern. *Arch. f. Anat. u. Physiol., Physiol. Abtheilung*, Leipz. (1889), S. 537.

† Lenticular segment of Dejerine.

then plunge into the substance of the pons, making up in it a large proportion of the fasciculi longitudinales of the pars basilaris pontis, being separated from the surface by the fibræ pontis superficiales. In the midbrain and in the pons a number of the axones terminate, coming into direct contact relation with the cell bodies and dendrites of the lower motor neurones situated in the nucleus nervi oculomotorii, nucleus nervi trochlearis, nuclei motorii nervi trigemini, nucleus nervi abducentis, and nucleus nervi facialis.\* Some fibres go into the nuclei of the same side, but the majority go into the nuclei of the opposite side. The exact place where the fibres of these nuclei leave the main bundles, and the exact paths which they follow to the nuclei, have not as yet been fully determined, but already a certain amount of valuable information bearing upon these points has been obtained (*vide infra*). The statement that nerve fibres from these bundles do pass to these nuclei is based mainly, but not solely, upon clinical experience, physiological experiment, and analogy.

As these axones pass through the pons they give off numerous collaterals which terminate in the nuclei pontis.

Leaving the pons, the axones are continued through the medulla oblongata, forming there the well-known fasciculi pyramidales, which correspond on each side to the pyramis medullæ oblongatæ, as seen from the surface. The fact that the fibres in the cord represent the continuations of those which make up the pyramids of the medulla oblongata gave rise to the name "pyramidal tract." This term was not derived from the pyramidal cells in the cerebral cortex, as some have erroneously thought.

In the medulla the bundle of axones on each side diminishes in volume owing to the exit of fibres which run to the groups of cell bodies and dendrites of peripheral motor neurones situated in this region—namely, to the nucleus ambiguus (nuclei motorii glossopharyngii, N. vagi et N. accessorii) and the nucleus hypoglossi.

In the lower part of the medulla oblongata, just above the cervical cord, the majority of the fibres of each bundle cross over to the opposite half of the neural axis, giving rise to the well-known *decussatio pyramidum* (Fig. 624). This decussation does

---

\* We have already referred to, and shall farther on again point out, the fact that fibres to the nuclei of the motor cerebral nerves are, strictly speaking, to be separated from the fibres going to the spinal cord.

not occur all at one spot, but extends for a distance of about one cm., taking place in successive bundles. The fibres which

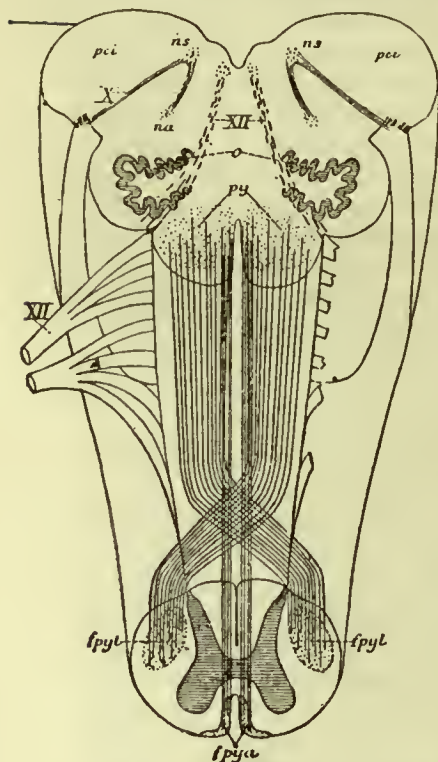


FIG. 624.—Scheme showing the decussatio pyramidum at the lower part of the medulla oblongata. (After A. van Gehuchten, *Anatomie du système nerveux de l'homme*, 1897, Fig. 565, p. 811.) *fpya*, fasciculus cerebro-spinalis ventralis; *fpyl*, fasciculus cerebro-spinalis lateralis; *na*, nucleus ambiguus; *ns*, nucleus alie cineræ; *o*, nucleus olivaris inferior; *pci*, corpus restiforme; *py*, pyramis medullæ oblongatæ; *X*, N. vagus; *XII*, N. hypoglossus.

cross from one side to the other plunge through the gray matter of the ventral horn into the lateral funiculus of the opposite side, giving rise to the fasciculus cerebro-spinalis lateralis of the opposite half of the spinal cord. A certain proportion of the fibres do not cross but go down on the same side of the cord, the majority of them in human beings occupying a region of the ventral funiculus, forming the so-called funiculus cerebro-spinalis ventralis. Some of the fibres, however, run down on the same side in the fasciculus cerebro-spinalis lateralis, so that in the spinal cord the fasciculus cerebro-spinalis ventralis is an uncrossed bundle, while the fasciculus cerebro-spinalis lateralis is in the main a crossed bundle, but contains a certain number of uncrossed fibres.

There has been a great deal of discussion during the past few years concerning the decussation of the pyramidal

fibres. The view generally held until recently was that all of the fibres of the lateral pyramidal tract were crossed fibres which terminated in the ventral horns of the same side, and that all of the fibres in the ventral tract (direct pyramidal tract) were uncrossed fibres, which, however, crossed immediately or shortly before their termination by passing through the ventral white commissure to end



in the ventral horns of the opposite side. According to this view there was, therefore, ultimately a complete decussation of the pyramidal tract fibres; that is to say, all the fibres from the pallium to one side of the spinal cord came from the opposite half of the brain, a view which was supposed to agree entirely with clinical observation and pathological findings. In 1881 and 1882, however, Pitres found, after unilateral cerebral lesion, besides the degeneration in the opposite lateral tract in the cord (heterolateral bundle), a feeble degeneration in the fasciculus cerebro-spinalis lateralis of the same side (homolateral degeneration). In an article published in 1884 he makes the statement that his homolateral degeneration could be made out in no less than ten of forty cases. These studies of Pitres have been confirmed by other pathologists. In addition, a large number of experiments on animals are in agreement with his observations; thus Franek et Pitres, Moeli, Sherrington, Melius, Fürstner and Knoblauch, Unverricht and Kusiek, Sandmeyer, F. W. Mott, Muratoff, Rothmann, Wertheimer, and Lepage, after cortical lesion experimentally produced, have studied the cord for secondary degenerations. All are agreed that besides the abundant heterolateral degeneration more or less homolateral degeneration also occurs. It is to be remembered, however, that in the animals below man, so far investigated, except in the monkey, no ventral pyramidal tract exists; all the pyramidal tract fibres of the cord must run down in the lateral funiculus, and it has been assumed that the fibres which degenerated homolaterally in animals correspond to the fibres which in man run down in the ventral funiculus. Hallopeau's suggestion that the degeneration of the homolateral bundle depended upon pressure effects exercised by degenerating fibres of one side at the level of decussation in the medulla, has been supported to a certain extent by the experiments of Rothmann. This observer, operating upon a dog and a monkey, found, after unilateral lesion of one motor zone, degeneration always in both pyramidal bundles in the spinal cord in accordance with what had been established by previous investigators. He states, however, that the degeneration is permanent in a crossed track, but in the homolateral bundle is temporary, lasting only about two months—that is, as long as pressure effects would probably be exerted at the level of pyramidal decussation. The homolateral degeneration in man, however, is permanent, but Rothmann suggests that this may be the result of defective nutrition, since in human beings spontaneous cerebral lesions are, as a rule, of vascular origin, and the nutrition of the brain may be insufficient to repair the loss in the homolateral fibres accidentally produced by the pressure at the level of decussation in the medulla. The ingenious experiments of Wertheimer and Lepage make it, however, seem probable that in the

dog there are actual homolateral fibres in the lateral column. They found that after cutting through the left half of the cervical cord excitation of the motor area in the right cortex led to movement of the extremities of the right side. In the second place, when they cut through the left half of the medulla above the pyramidal decussation and again stimulated it, the motor area of the right side, they could produce movements in the left hind leg. Again, on cutting through the left half of the cord below the decussation at the level of the first cervical nerve, movements in the right leg could be produced by electric stimulation of the sigmoid gyrus. To answer the objection that instead of innervation of the right foot by homolateral fibres the connection might be made by fibres which crossed twice between the two planes of hemisection, they made a longitudinal section of the medulla and found that excitation of the motor area on the right side was still followed by movements in the right hind foot. While the objection with regard to pressure effects at the level of decussation must be carefully considered, the evidence, I think, is, on the whole, sufficient to justify the statement that both heterolateral and homolateral fibres exist in the spinal cord, both of man and animals, in the fasciculus cerebro-spinalis lateralis. Indeed, it would be surprising, when one thinks of it and considers the nature of the impulses which set out from the cortex, if such a double-sided innervation did not exist.

The fasciculus cerebro-spinalis lateralis occupies in the cervical cord the large area in the postero-medial region of the lateral funiculus. It diminishes rapidly in volume as it descends the cord, being very much smaller in the thoracic than in the cervical, and in the lower lumbar than in the thoracic cord. In the lower part of the cord it comes to lie adjacent to the periphery, while in the cervical and thoracic cord it is separated from the periphery by the medullated axones which go to make up the fasciculus cerebro<sup>affo</sup>-spinalis previously described.

The diminution in volume as the cord is traversed depends upon the fact that at the different segments constituent fibres of the bundle turn into the gray matter to end there. The greatest loss, as one would expect, occurs in the region of the cervical and lumbar enlargements in which are situated dendrites and cell bodies of the peripheral motor neurones which govern the movements of the upper and lower extremities respectively. Below the lumbar enlargement the number of fibres is small, but a certain number can be traced to the lowermost portions of the sacral cord.

The fasciculus cerebro-spinalis ventralis also diminishes in

volume as the cord is descended, and in it too the loss is greatest at the levels of the cervical enlargement, the fasciculus being entirely exhausted on the thoracic cord. The statement that the fibres of the ventral pyramidal tract cross over just before terminating through the anterior commissure to end in the ven-

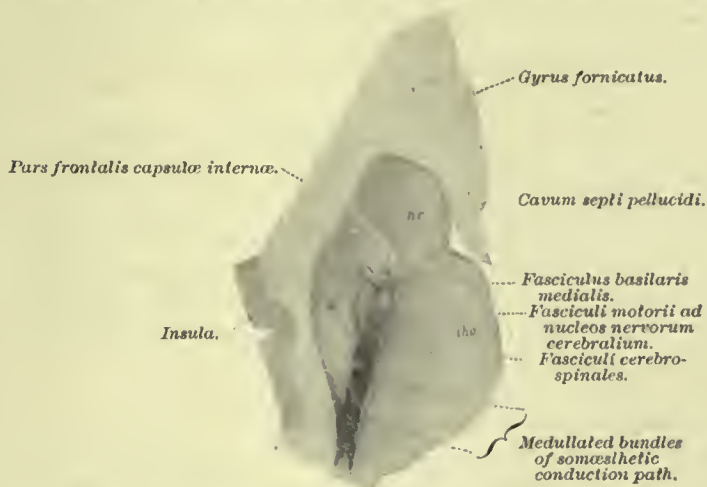


FIG. 625.—Horizontal section through brain at level of uppermost part of globus pallidus; newborn babe. *nc*, caput nuclei caudati; *tho*, thalamus; *III*, putamen. Just medial to the latter is seen the tip of the globus pallidus (nucleus lentiformis II). (After P. Flechsig, Arch. f. Anat. u. Physiol., Anat. Abth., Leipz., 1881, Taf. iii, Fig. 8.)

tral horn of the opposite side, has been vigorously combated by von Lenhossék. This investigator has made a careful study of the spinal cord of two human embryos—one thirty-three, the other thirty-five centimetres long. He states that he could never find axones from the ventral pyramidal tract entering the ventral commissure. He believes that they all run in to terminate in the gray matter of the ventral horn of the same side; that is, that the path from the motor area of the pallium to the ventral horn cells is throughout direct and uncrossed. Van Gehuchten has made the objection that at this period of development of the human fœtus the fibres of the ventral pyramidal tract are not present. If this be true, the argument of von Lenhossék falls to the ground.

Höche with Marchi's method finds that the fibres of the ventral pyramidal tract end partly in the ventral horn of the same side, but mainly in that of the opposite side (*vide infra*).

The four principal methods for investigating the course of the axones which go to make up the pyramidal tracts are (1) the embryological method of Flechsig; (2) by physiological experiment, including electrical stimulation and the like; (3) the method of secondary degenerations, (*a*) occurring spontaneously in human beings as a result of disease; (*b*) experimentally produced in animals by cortical extirpation or by section of the bundles at some point in their course; and (4) the application of the method of Golgi.

The embryological method of Flechsig is especially well adapted for the study of the fibres of the pyramidal tract, inasmuch as at birth, or shortly before birth, all the fibres of the spinal cord have received their myelin sheaths with the exception of these fibres; and in sections stained by Weigert's method the positions occupied by the fibres of the pyramidal tract stand out clearly and sharply as pale areas in the section. This method has been of particular service in demonstrating the asymmetry of the decussation which often occurs in the human cord.

It is among the greatest achievements of Flechsig\* that he has traced out with the strictest accuracy the position of the axones of the pyramidal tract and the corresponding bundle of fibres for the innervation of the nuclei of the cerebral nerves, all the way from the cerebral cortex nearly to the termination of the fibres in the groups of cell bodies belonging to the lower motor neurones. The course of the bundles, as outlined by the embryological method, will be clear if Figs. 625-631 with their legends be consulted.

The sequence of medullation in the sensory and motor fibres

---

\* Flechsig, P. Ueber einige Beziehungen zwischen secundären Degenerationen und Entwicklungsvorgängen im menschlichen Rückenmark. Arch. d. Heilk., Leipz., Bd. xiv (1873), S. 464-469.—Die Leitungsbahnen im Gehirn und Rückenmark des Menschen auf Grund entwicklungsgeschichtlicher Untersuchungen dargestellt. 8vo, Leipzig (1876).—Ueber "System-Erkrankungen" im Rückenmark. Arch. d. Heilk., Leipz., Bd. xviii (1877), S. 101; 289; 461; and Bd. xix (1878), S. 53; 441; Centralbl. f. die medicinischen Wissenschaften (1877), Nr. 3.—Ueber die Capsula interna. Tageblatt der Naturforscher-Versammlung. München (1877), S. 226.—Zur Anatomie und Entwicklungsgeschichte der Leitungsbahnen im Grosshirn des Menschen. Arch. f. Anat. u. Physiol., Anat. Abth., Leipz. (1881), S. 12-75.—Plan des menschlichen Gehirns auf Grund eigener Untersuchungen entworfen. Leipz., 8vo, 1883.—Gehirn und Seele, Leipzig (1896).—Die Localisation der geistigen Vorgänge, Leipzig (1896).





two thirds of the posterior limb of the capsule; that is, the so-called thalamo-lentiform portion. Arriving in the internal capsule, these bundles cease to be separated by fibres of a different nature, and become aggregated in the form of a tolerably compact

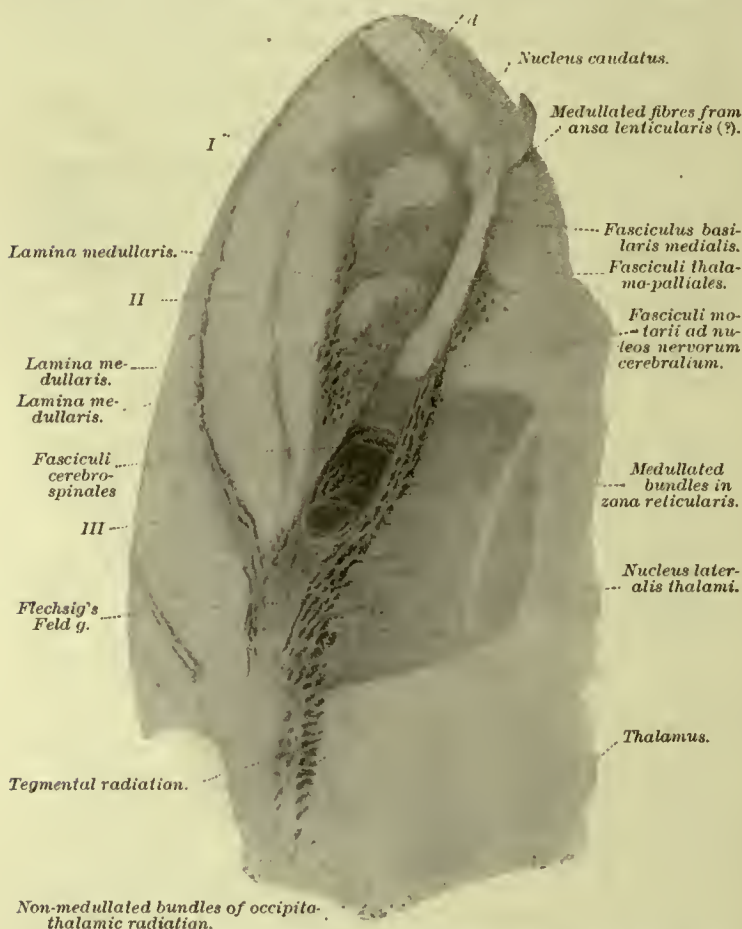


FIG. 627.—Horizontal section through uppermost portion of medial segment of nucleus lentiformis; newborn babe, 50 to 51 cm. long. (After P. Flechsig, *Arch. f. Anat. u. Physiol., Anat. Abth.*, Leipz., 1881, Taf. iii, Fig. 6.) *I*, *II*, globus pallidus; *III*, putamen; *d*, continuous with *d* of Fig. 626. Magnified four times.

fasciculus, which passes first between the nucleus caudatus and the nucleus lentiformis and farther down between the thalamus and the nucleus lentiformis, to enter the cerebral peduncle. At

about the junction of the internal capsule with the cerebral peduncle the fibres of the pyramidal tract are interwoven with transverse bands of fibres, which become medullated at a period later than that of the myelinization of the pyramidal tract. This interleaving begins at a level corresponding to the dorsal border of the nucleus hypothalamicus (corpus Luysi), and extends downward as far as the posterior and ventral extremity of Luys' body. These transverse fibres running through the pyramidal tract at this level represent in the main the fibres of the ansa lenticularis. On its way through the internal capsule the pyramidal tract is separated from the thalamus by a medial layer of

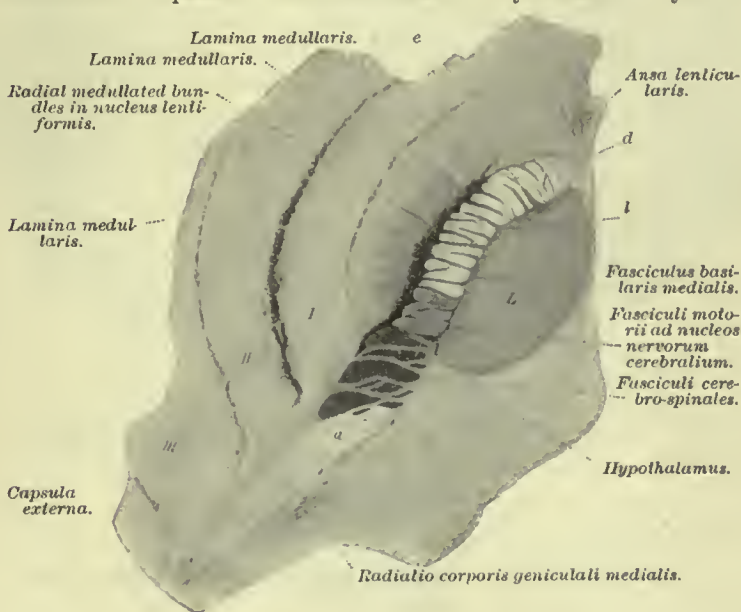


FIG. 628.—Horizontal section through brain of babe, 50 to 51 cm. long, at level of lower third of first portion of nucleus lentiformis. (After P. Flechsig, Arch. f. Anat. u. Physiol., Anat. Abth., Leipz., 1881, Taf. iii, Fig. 3.) *a*, continuation of fasciculus basilaris lateralis; *d*, fibres continuous with *d* of Fig. 627; *e*, medullated fibres extending between hypothalamic region and nucleus lentiformis; *l*, fibres of *e* which have passed through the capsula interna; *L*, nucleus hypothalamicus (corpus Luysi); *I*, *II*, globus pallidus; *III*, putamen. Magnified four times.

white matter (medullated axones of sensory neurones extending between the diencephalon and the pallium).

In the base of the cerebral peduncle, too, the position of the pyramidal tract varies according to the level examined. In the

higher regions of the base of the peduncle (or pes) the pyramidal tract occupies the third, fourth, and fifth, reckoned from the medial side, while lower down it occupies about the middle third of the base of the peduncle. At the junction of the cerebral peduncle with the pons the fibres of the pyramidal tract split up into several bundles and help to make up, in large part, the fasciculi longitudinales (pyramidales) which run through the pars basilaris pontis. At the lower end of the pons these longitudinal bundles unite on each side to form the compact *pyramis* which occupies the ventral surface of the medulla oblongata, close to the fissura mediana ventralis. In the medulla the majority of the fibres of the pyramidal tract as shown by the developmental method pass over to the opposite side of the nervous system forming the *decussatio pyramidum*. The large crossed bundle passes down as the fasciculus cerebro-spinalis lateralis through the lateral funiculus of the spinal cord. The

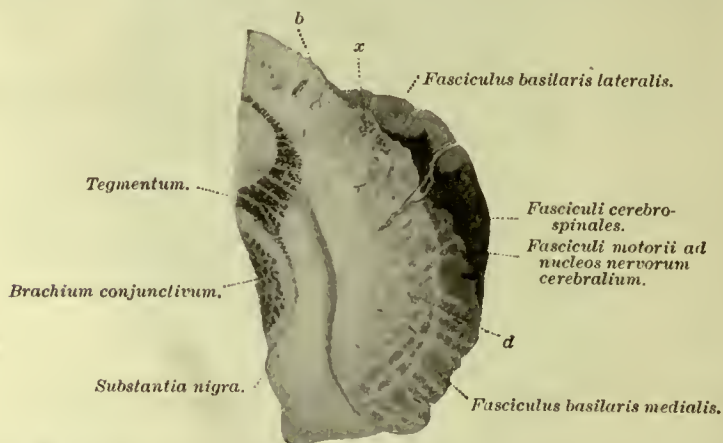


FIG. 629.—Section at right angles to the longitudinal fibres of the basis pedunculi (junction of upper with middle third); newborn babe, 50 to 51 cm. long. Müller's fluid hardening. Mounted in glycerin. (After P. Flechsig, Arch. f. Anat. u. Physiol., Anat. Abth., Leipz., 1881, Taf. iii, Fig. 1.) *b*, most lateral bundle of the dorsal stratum of the basis pedunculi; *x*, isolated bundles of medullated fibres, nature undetermined. Magnified four times.

smaller uncrossed bundle, consisting of the lateral portion of the pyramis,\* passes down as the fasciculus cerebro-spinalis ventralis of the cord.

\* It is of interest that Burdach was able to make out this point.



Flechsig has studied the decussatio pyramidum and its variations with great care.\* In about fifty per cent. of all well-studied

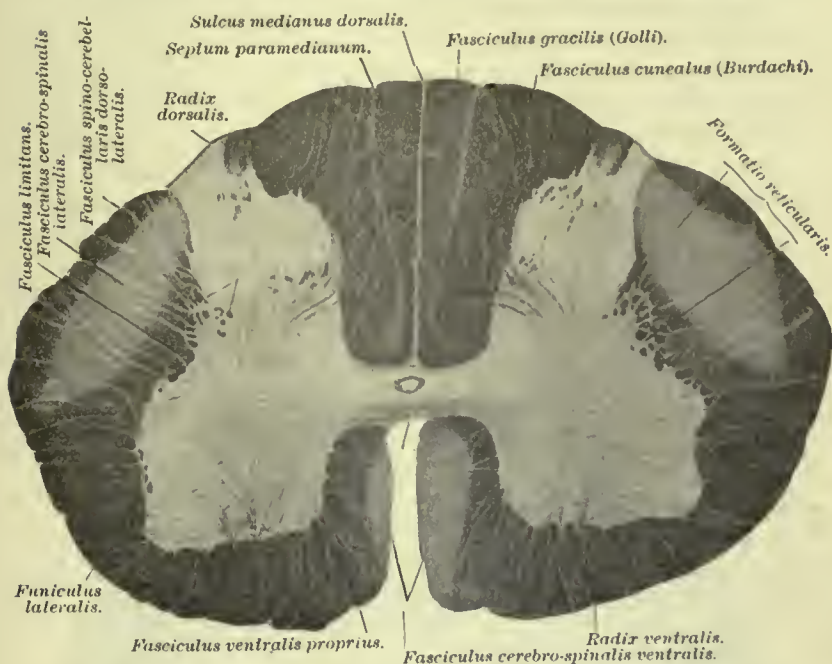


FIG. 630.—Transverse section through the spinal cord of a newborn babe, about 50 cm. long; level of sixth cervical nerve. Gold preparation. (After P. Flechsig, *Die Leitungsbahnen im Gehirn und Rückenmark*, Leipz., 1876, Taf. xix, Fig. 1.)

cases the distribution of the pyramidal tracts is asymmetrical. Thus, in a certain number of instances, all of the fibres go down in the lateral pyramidal tract and there is complete absence of the ventral pyramidal tract on each side. In these cases Flechsig assumes that the decussation is total.† In other cases he finds a

\* Flechsig, P. *Die Leitungsbahnen im Gehirn und Rückenmark des Menschen*, etc., Leipz. (1876), S. 270 *et seq.*

† From the studies of experimental degeneration to be described farther on we now know that many of the fibres which run down in the lateral pyramidal tract in the spinal cord are uncrossed fibres. It is therefore not improbable that these cases of apparent total decussation are in reality not such, but simply instances in which the uncrossed fibres all go down through the lateral tract; in monkeys this is the normal condition since the monkey possesses no ventral pyramidal tract, and yet he is not unprovided with direct (uncrossed) pyramidal fibres.

ventral pyramidal tract on one side, but none on the other. In other cases there is a ventral pyramidal tract on both sides, and in these cases the number of fibres in the ventral tract of one side as compared with the number of fibres in the lateral tract of the opposite side, and again the relation of the number of fibres in the ventral tract of one side to the number of fibres in the ventral tract of the other side, can vary within considerable limits. Flechsig concluded that the fibres arriving from a definite region of the cerebrum through the pyramids into the spinal cord may take either one of two courses, running in the ventral pyramidal tract of the same side, or in the lateral pyramidal tract of the opposite side.

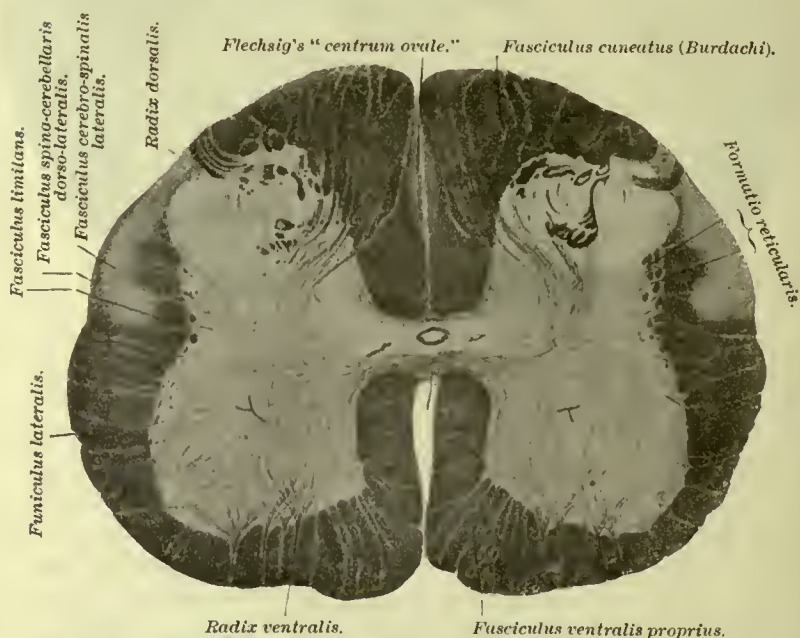


FIG. 631.—Transverse section through the spinal cord of a newborn babe, about 50 cm. long; level of fourth lumbar nerve. Gold preparation. (After P. Flechsig, *Die Leitungsbahnen im Gehirn und Rückenmark*, Leipz., 1876, Taf. xix, Fig. 2.)

The area occupied by the pyramidal tract decreases from above downward as the spinal cord is descended, owing to the fact that the medullated axones are ever running in to terminate in the adjacent gray matter apparently in the ventral horns.

The fasciculus cerebro-spinalis lateralis, or lateral pyramidal

tract, lies always in the posterior half of the funiculus lateralis. Flechsig states that the fibres never extend farther forward than an imaginary straight line drawn lateralward from the group of cells known as the *columna intermedio-lateralis*. The embryological method permits one to follow the lateral pyramidal tract downward as far as the lower end of the lumbar enlargement, or even to the level of the third or fourth sacral nerve. As regards the relation of the lateral pyramidal tract to the periphery of the cord, this varies considerably at different levels. Thus, at the level of the third cervical nerve it reaches, as a rule, to the surface of the posterior part of the lateral funiculus, even coming in contact with the pia mater. In the cervical enlargement the lateral pyramidal tract is separated from the pia mater by the compact bundle of the *fasciculus cerebello-spinalis* of Flechsig (direct cerebellar tract). From the middle of the thoracic cord downward the dorsal portion of the lateral pyramidal tract reaches the periphery, although the ventral part of the lateral surface of the bundle still remains separated from it. In the lower portion of the spinal cord the lateral pyramidal tract, now grown small, is situated close to the periphery of the cord.

The *fasciculus cerebro-spinalis ventralis*,\* or direct pyramidal tract, lies, as a rule, on the medial surface of the ventral funiculus. The area in cross section is variable. It may extend from the ventral commissure as far ventralward as the ventral margin of the *fissura mediana ventralis*. In other instances it occupies the dorsal half or the middle third of the medial surface of the ventral funiculus (Flechsig). Its longitudinal extent in the cord varies much. Sometimes it ceases even at as high a level as the middle of the cervical enlargement. In other cases it extends to the upper thoracic or, most commonly, to the mid-thoracic cord. Occasionally it has been followed as far as the *intumescentia lumbalis*.

ELECTRICAL STIMULATION.—A great deal of our knowledge regarding localization of the cell bodies of these upper motor neurones in the cerebral cortex has been obtained through physiological experiments, and especially by means of electrical stimulation of the cerebral cortex.† We are indebted especially for this

---

\* This was described by Charcot as the *faisceau de Türk*.

† It is surprising how J. Hughlings Jackson, by means of clinical and pathological observation and a happy scientific imagination, arrived at very important conclusions concerning localization, which have since been in

advance to the researches of Fritsch and Hitzig\* (1870) with the galvanic current, and especially to the brilliant results obtained by Ferrier† (1873) on faradic excitation of the cerebral cortex.

The experiments of Fritsch and Hitzig showed that stimulation of certain regions only of the brain lead to movements of parts of the body, and that between the place stimulated and the part of the body set in motion strictly definite relations exist. The idea of a so-called motor cortex thus arose.

The experiments of Ferrier proved that on suitable excitation of the surface of the cerebrum with the faradic current movements can be called forth which possess a definitely purposeful character. In other words, movements of the individual parts of the body are evoked which correspond to those actually carried out voluntarily by an individual in the course of his ordinary bodily activity. With similar methods Ferrier was able to localize generally the principal movements of the face, arm, trunk, and leg in the monkey.

The general electrical experiments on the cerebral cortex were carried out with additional refinements by Horsley and Schaefer‡

---

large part confirmed by physiologists and anatomists. To be convinced of the wonderful foresight of the writer one has only to compare present knowledge with the hypotheses which he advanced in the following articles: Notes on the Physiology and Pathology of Language; Remarks on those Cases of Disease of the Nervous System in which Defect of Expression is the most Striking Symptom. *Med. Times and Gaz.*, Lond. (1866), i, pp. 659-662.—On Localization. *Med. Times and Gaz.*, Lond. (1869), i, p. 600.—On the Anatomical and Physiological Localization of Movements of the Brain. *Lancet*, Lond. (1873), i, pp. 84; 162; 232.—Observations on the Localization of Movements in the Cerebral Hemispheres, as revealed by Cases of Convulsion, Chorea, and Aphasia. *West Riding Lun. Asyl. Rep.*, Lond., vol. iii (1873), pp. 175-195.—Cases of Partial Convulsion from Organic Brain Disease, bearing on the Experiments of Hitzig and Ferrier. *Med. Times and Gaz.*, Lond. (1875), i, pp. 578; 606; 660; ii, pp. 264; 330; (1876), i, 8.

\* Fritsch, G., and E. Hitzig. Ueber die elektrische Erregbarkeit des Grosshirns. *Arch. f. Anat. Physiol. u. wissensch. Med.*, Leipz. (1870), S. 300-332.

† Ferrier, D. The Localization of Function in the Brain. *Proc. Roy. Soc.*, Lond., vol. xxii (1873-'74), pp. 229-232.—The Croonian Lecture: Experiments on the Brain of Monkeys. *Phil. Trans. Roy. Soc.*, Lond., vol. clxv (1876), pp. 433-488.—The Function of the Brain, 2d ed., Lond. (1886), p. 521, 8vo.

‡ Horsley, V., and E. A. Schaefer. A Record of Experiments upon the Functions of the Cerebral Cortex. *Phil. Trans. Roy. Soc.*, Lond., vol. clxxix (1888) (B.), pp. 1-45.



and by Beevor and Horsley.\* At present it would seem as though the results with regard to the monkey's cortex are as perfect as the limitations of the methods permit. Since the monkey's cortex, and especially that of the orang-outang, so closely resembles that of man, these results are of the highest importance for the physician and surgeon. Over and over again it has been possible in human cases to localize with great accuracy the existence of an irritative lesion in the motor domain of the cortex, and in many instances surgical interference has been resorted to with success. Of course the improvements in the technique of brain surgery in recent times have resulted in the more frequent resort to operative interference on the brain of human beings, so that it has been possible in quite a notable number of instances to carry out actual electrical excitation of the human cortex, owing to which we already possess a certain amount of definite information regarding localization in the human cortex, which has been obtained directly (*vide infra*).

Beevor and Horsley (1887) decided, from the results of their experiments, that the anterior central gyrus is much more concerned in the motor functions than is the posterior central gyrus. They concluded, too, that in the area of motor representation for the upper limb, the regions for the larger joints are at the upper parts of the area, while those for the smaller joints and more differentiated movements lie peripherally at the lower part of the area. The movements of extension, they believe, are represented rather in the upper part of the area, while those of flexion appeared to be related to the lower part. In between these two areas is situated a zone of confusion (Fig. 632). In their earliest experiments they studied not only the primary movements which result from electrical stimulation, but also the subsequent "march" of the movements as the electrical stimulus became diffused through the cortex. A remarkable correspond-

---

\* Beevor, C. E., and Victor Horsley. A Minute Analysis (experimental) of the Various Movements produced by Stimulating in the Monkey Different Regions of the Cortical Centre for the Upper Limb as Defined by Professor Ferrier. Phil. Trans. Roy. Soc., Lond., vol. clxxviii (1887) (B.), pp. 153-167.—A Record of the Results obtained by Electrical Excitation of the So-called Motor Cortex and Internal Capsule in the Orang-Outang (*Simia satyrus*). Phil. Trans. Roy. Soc., Lond., vol. clxxxi (1890) (B.), pp. 129-158.—A Further Minute Analysis by Electrical Stimulation of the So-called Motor Region (facial area) of the Cortex Cerebri in the Monkey (*Macacus sinicus*). Phil. Trans. Roy. Soc., Lond., vol. clxxxv (1894) (B.), pp. 39-81.

ence was found between the progress of these marches and the farsighted observations of J. Hughlings Jackson in cases of epilepsy. In Figs. 7 and 8 accompanying their article the mode of march is clearly illustrated, and it is seen to be in harmony with the representation of primary movements in the various points in the area. They decided that there is no absolute line of demarkation in the monkey between the area of localization in the cortex of one movement and that of another, each movement having a centre of maximum representation which gradually shades off into the surrounding cortex.

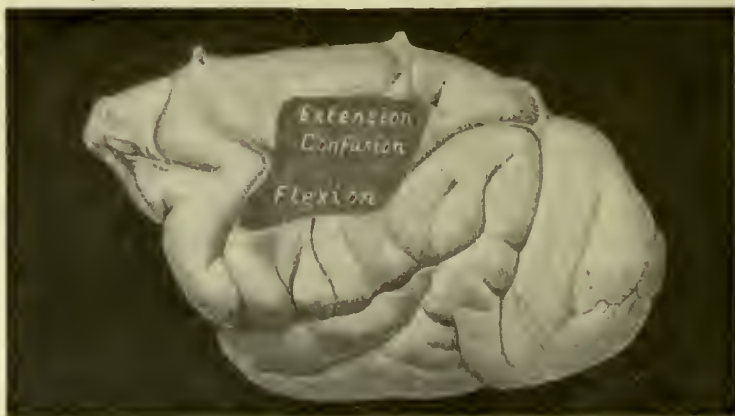


FIG. 632.—Early experiments of Beevor and Horsley at motor cerebral localization. (After C. E. Beevor and V. Horsley, *Phil. Tr., Lond.*, 1887, pl. vii, Fig. 3.)

These preliminary researches of Beevor and Horsley were soon followed by the exhaustive studies of Horsley and Schaefer (1888), who attempted to localize centres for voluntary movement and also for sensation by means of electrical excitation and ablation. In the prefrontal region the results of electrical excitation were negative as long as the electrodes were applied in front of the sulcus præcentralis; but as soon as stimulation was applied behind this sulcus these observers began to get lateral movements of the head and eyes such as Ferrier had described.

The main motor area of the cortex as outlined by physiological experiment includes a large region in the neighborhood of the sulcus centralis Rolandi. The motor cortex corresponds in the main to that of the two central gyri (anterior and pos-

terior) and the lobulus paracentralis, although stimulation of the feet of the three frontal gyri as well as of certain other points in the cortex may occasionally call forth a motor reaction.

Ferrier had found, as we have said, the principal areas of representation for the various movements of the face and of the upper and lower extremity. By stimulation of the excitable portion of the lateral surface of the cerebral hemisphere he obtained (1) on the middle of the frontal lobe, movements of the head and eyes; (2) just behind this area on the anterior central gyrus, movements of the hand and arm; (3) on the posterior central gyrus, movements of the fingers and wrist; (4) on stimulation about the inferior extremity of the sulcus centralis Rolandi, including parts of both central gyri, movements of the face, jaw, and tongue.

Horsley and Schaefer described the arm area as occupying a triangular portion of the surface, broad behind and narrow in front. It comprises most of the upper half of the posterior central and anterior central gyri (in the monkey) from a little below the level of the sagittal part of the sulcus præcentralis below nearly to the margin of the hemisphere above, together with a small portion of the adjacent part of the frontal lobe. The shoulder muscles react most strongly when the electrode is applied near the superior limit of the area; while the muscles moving the forearm and wrist come into activity when it is applied near the central and inferior portions of the area, and the muscles of the wrist and fingers react to stimulation along the posterior border. It is significant that these observers, like all others who have experimented on the cortex, find that movements and not individual muscles are represented here. The facial area described by Horsley and Schaefer includes the area of representation not only for the movements of the facial muscles, but also for those of the mouth, throat, and larynx. It comprises the whole of the posterior central and anterior central gyri, inferior to the arm area, extending downward as far as the fissure of Sylvius and including the lateral surface of the operculum. It is in the upper third or half of this area that blinking or closure of the eyelids along with elevation of the ala nasi and retraction of the angle of the mouth are initiated. This portion of the area they have therefore justly designated the "upper face centre." The lower third of the area, stimulation of which is accompanied by varying movements of the jaw

and tongue, some of them much like those of mastication, they call the "lower face centre."

"The *head area* or *area for visual direction* corresponds to an oblong portion of the surface of the frontal lobe extending from the margin of the hemisphere, around which it dips for a short distance outward and somewhat backward to the upper and anterior limit of the face area." It is bounded posteriorly by the arm area and in front by nonexcitable cortex. On excitation of this area they obtained opening of the eyes, dilatation of the pupils, and turning of the head to the opposite side with conjugate deviation of the eyes to that side. Strong retraction of the ears could frequently be elicited if the electrode was applied near the angle of the sulcus præcentralis.

The *leg area* (*vide supra*) is situated partly upon the medial surface of the hemisphere, but extends also over a certain portion

Diagram I.



FIG. 633.—Motor cerebral localization in the monkey. (After V. Horsley and E. A. Schaefer, *Phil. Tr.*, Lond., 1888, p. 6, diagram 1.)

of the lateral surface of the hemisphere occupying an area in front of the fissura parieto-occipitalis almost as far forward as the



level of the anterior extremity of the small sulcus marked *x* in their diagram.

Diagram II.

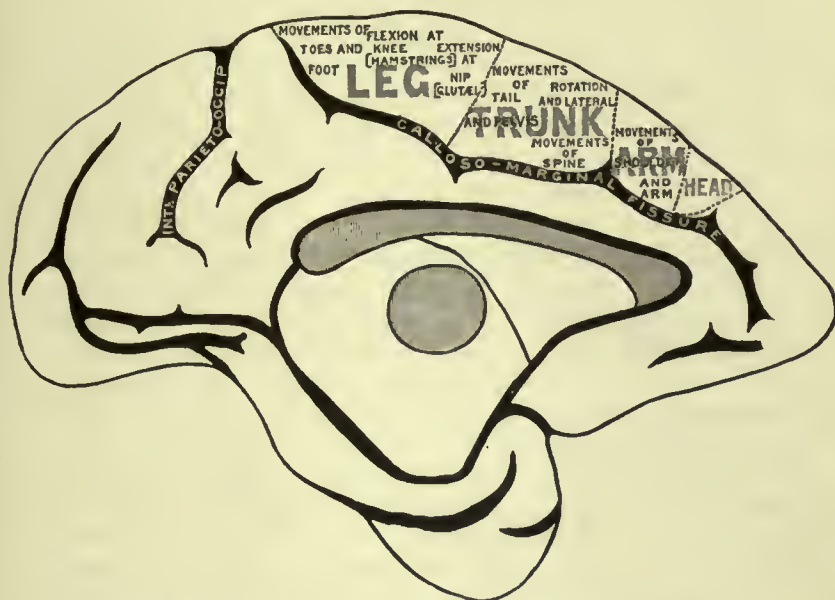

FIG. 634.—Motor cerebral localization in monkey. (After V. Horsley and C. A. Schaefer, *Phil. Tr., Lond.*, 1888, p. 10, diagram 2.)

The *trunk area* is situated mainly on the medial surface of the hemisphere, extending for only a short distance over the margin to reach the lateral surface. The general results of their findings are beautifully illustrated in the accompanying diagram (Fig. 633).

In addition to their careful study of the lateral surface of the hemisphere, Horsley and Schaefer extended their experiments to the lobulus paracentralis and to the medial surface of the gyrus frontalis superior. To give briefly their results on stimulating the excitable portion of this area on the medial surface of the hemisphere, it may be stated that on applying the electrodes at successive points from before backward they obtained (1) movements of the head; (2) of the forearm and hand; (3) of the arm at the shoulder; (4) of the upper (thoracic) part of the trunk; (5) of the lower (pelvic) part of the trunk; (6) of the leg at the hip; (7) of the lower leg at the knee; (8) of the foot and toes. It

will thus be seen that in the monkey the head, arm, trunk, and leg are all represented to a certain extent upon the *facies medialis cerebri* (Fig. 634).

The physiological results of ablation in the motor areas of the cortex were quite in accord with the findings with regard to function as determined by electrical excitation. In this connection the studies, not only of Horsley and Schaefer, but also of Ferrier and Yeo, of Schiff, Munk, Luciani, and others should be consulted.

In 1890 the results of an important research were published by Beevor and Horsley in which appeared their findings on electrical excitation of the motor areas of the cortex in the orang-outang. Since the anthropoid ape is much nearer to man than the bonnet monkey, this study is clinically more applicable than the observations which were carried out upon the *Macacus sinicus*. One remarkable difference between the effects of excitation of the cortex of the orang-outang and that of the monkey is the fact that very few "marches" reproduce. It is evident, therefore, that the muscular movements of each individual segment are much more fully represented in the cortex of the orang-outang than in that of the monkey. And, indeed, it seems to be a general law that the higher the animal the greater is the area of representation not only of individual segments but of individual movements belonging to one segment in the cerebral cortex. Beevor and Horsley have been able to show that in the bonnet monkey the representation of the segments of the various parts of the body is arranged along the sulcus centralis Rolandi in horizontal levels, and that the boundary lines of these pass across the sulcus. The same arrangement was found to hold in the orang-outang. The comparative relations in the bonnet and the orang-outang will be clear if the accompanying figure (Fig. 635) be consulted, in which the segments are placed in successive order. It will be seen that the general plan of arrangement of the representation of the segments in the two animals corresponds closely, the variations being due to the exaggeration of the sinuities in the gyri of the orang rather than to any central anatomical characteristics. It is to be noted that the plan of the segments of the lower limb is truly horizontal in the orang but antero-posteriorly placed in the bonnet, the difference in representation being ascribed by Beevor and Horsley to the habits of the two animals. It is further to be noted that the representa-

tion in the brain of the anthropoid ape and man differs from that in the monkey in that the excitable area in the cortex of the former is not continuous, being much interrupted by spaces from which no effect could be obtained even by the application of strong stimuli. These unexcitable areas are situated, in the main, between the areas of representation of the larger divisions of the body. They are not intercalated between the individual segments of the single large divisions. The higher the plane of the animal the more perfect the integration of representation.

BONNET.

ORANG.

## LONGITUDINAL FISSURE

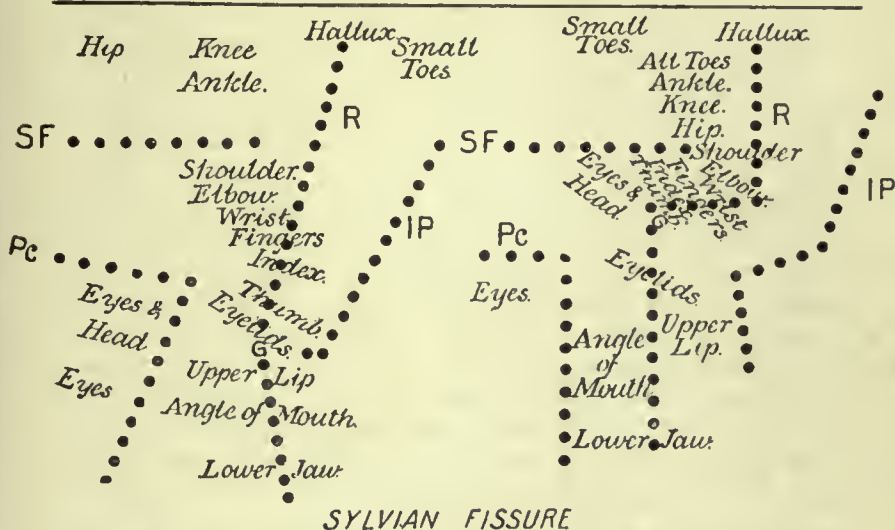


FIG. 635.—Comparison of motor representation in the bonnet monkey and in the orang-utang. (After C. E. Beevor and V. Horsley, *Phil. Tr., Lond.*, 1890, p. 150, Fig. 4.)

Subsequently to these fundamental investigations a number of others have been undertaken to localize still more accurately certain of the individual movements in the different areas. Among these the study of the facial area by Beevor and Horsley in 1894 may perhaps be singled out. They analyzed minutely the facial area of the bonnet monkey with reference to the facial, lingual, and pharyngeal movements. They undertook in this study especially a detailed investigation of the so called bilateral representation. This work was very thorough, and the results

are embodied in a long series of tables accompanying the original article, to which the reader who is interested can easily refer. The report is especially valuable in containing a tabular representation of the series of "marches" observed on stimulation of various parts in the monkey's cortex.

While *a priori* there could have been no doubt, after the studies upon the brain of animals, that the human brain also is electrically excitable, the direct proof of this was first established by observations of Bartholow\* and Sciamanna.† Victor Horsley established the fact that excitation with a feeble interrupted induced current in the facial area of the cortex of a boy produced movements in the opposite side of the face only when the electrodes were applied at points distant from each other and not at intermediate points. Again in 1888 Keen, of Philadelphia,‡ localized in the cortex of a man under anæsthesia the representation for the movements of the wrist, the shoulder, elbow, and face. He extirpated the focal representation of the wrist, and after operation the left hand was found to be paralyzed as regards all movements both of the fingers and wrist. The elbow was weak, but the shoulder and face were entirely unaffected. In the same year Lloyd and Deaver\* also stimulated the cortex faradically and brought further evidence in favor of the view that the integration of movement representation is much more marked in man than it is in the monkey or even in the anthropoid ape. It was made out that considerable areas did not appear excitable at all to the strength of current employed, definite movements corresponding to the epileptic seizures from which the individual had suffered being elicited on stimulation of com-

---

\* Bartholow, R. Experimental Investigations into the Functions of the Human Brain. Amer. Jour. Med. Sc., Phila., n. s., vol. lxvii (1874), pp. 305-313.

† Sciamanna, E. Gli avversari delle localizzazioni cerebrali. Arch. di psichiat., etc., Torino, vol. iii (1882), pp. 209-218.

‡ Keen, W. W. Three Successful Cases of Cerebral Surgery, including (1) the Removal of a Large Intracranial Fibroma; (2) Exsection of Damaged Brain Tissue; and (3) Exsection of the Cerebral Centre for the Left Hand; with Remarks on the General Technique of such Operations. Amer. Jour. Med. Sc., Phila., n. s., vol. xevi (1888), p. 329; 452.

\* Lloyd, J. H., and J. B. Deaver. A Case of Focal Epilepsy successfully treated by Trephining and Excision of the Motor Centres. Amer. Jour. Med. Sc., Phila., n. s., vol. xevi (1888), pp. 477-487.



paratively restricted areas. Similar observations were made by Nancrede\* with Morris J. Lewis.

For the localization of function in the cortex, therefore, electrical excitation has been of immense value. But no less fruitful results have been obtained by the same method with regard to the localization of function in the bundles of fibres which pass through the internal capsule. Here again our most important knowledge has been derived from the experiments of Beevor and Horsley.† Valuable results by the method of excitation have also been obtained by Burdon Sanderson‡ and Franck and Pitres.\*

In experiments upon the internal capsule it is essential that the exact anatomical location of the fibres stimulated be mentioned, for in different horizontal planes the motor fibres occupy entirely different positions. The term *capsula interna* is a bad one, but has been so uniformly employed that it seems necessary, at least for the present, to retain it. By it is indicated the white fibres bounding the *nucleus lentiformis* on its medial side. The term is, however, more loosely employed and is made to include all the descending and ascending fibres of the *corona radiata* which pass between the basal ganglia—between the *nucleus caudatus* and the *optic thalamus* on the medial side and the *nucleus lentiformis* on the lateral side. Above, the *capsula interna* is directly continuous with the *corona radiata*, while below it is directly continuous with the base of the cerebral peduncle. The upper and lower limits of the internal capsule must, therefore, be arbitrarily defined. The upper level would

---

\* Nancrede, C. B. Two Successful Cases of Brain Surgery. *Med. News, Phila.*, vol. liii (1888), pp. 584-588.

† Beevor, C. E., and Victor Horsley. An Experimental Investigation into the Arrangement of the Excitable Fibres of the Internal Capsule of the Bonnet Monkey (*Macacus sinicus*). *Phil. Trans. Roy. Soc.* (1890), Lond., vol. clxxxi (1891) (B), pp. 49-88; A Record of the Results obtained by Electrical Excitation of the So-called Motor Cortex and Internal Capsule in the Orang-Outang (*Simia satyrus*). *Phil. Trans. Roy. Soc.* (1890), vol. clxxxi (B.), Lond. (1891), pp. 129-158.

‡ Sanderson, J. B. Note on the Excitation of the Surface of the Cerebral Hemispheres by Induced Currents. *Proc. Roy. Soc., Lond.*, vol. xxii (1873-'74), pp. 368-370.

\* Franck, F. *Leçons sur les fonctions motrices du cerveau (réactions volontaires et organiques) et sur l'épilepsie cérébrale*. 8vo. Par. (1887), pp. 21-22.

correspond to a plane resting upon the upper surfaces of the caudate and lenticular nuclei; the lower level is usually defined as the region corresponding to the posterior and inferior limit of the fibres of the ansa lenticularis which pass through the internal capsule at its junction with the cerebral peduncle.

The capsula interna has been compared not inaptly to a mass of fibre bundles arranged like the rays of a fan; the handle corresponding to the base of the cerebral peduncle, the sides of the fan corresponding to the antero-ventral and postero-dorsal borders of the internal capsule, where it joins the corona radiata. This appearance is well shown in a sagittal section passing through the cerebrum (Fig. 636).

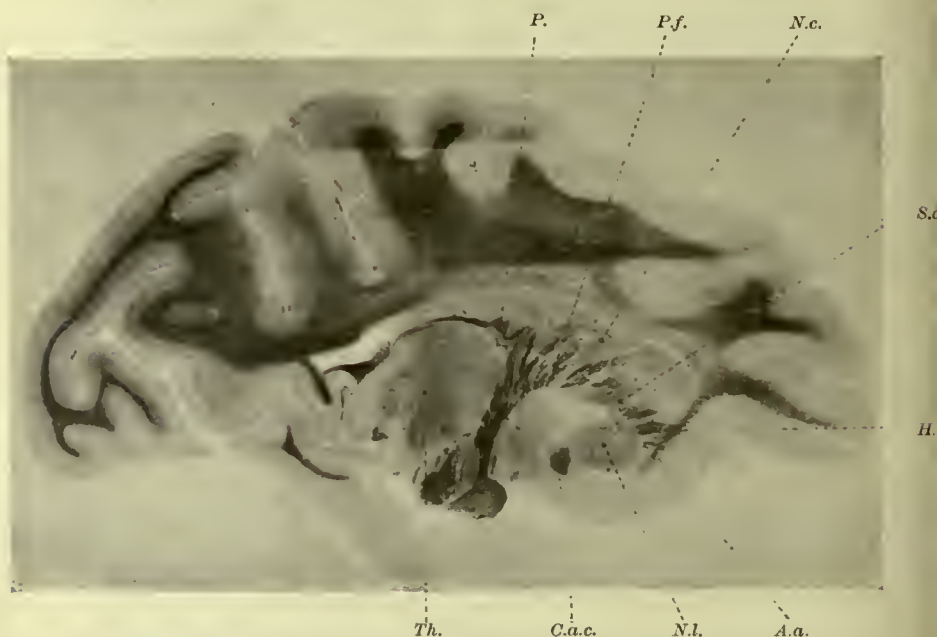


FIG. 636.—Sagittal section through the brain of the monkey, illustrating the internal capsule. (After C. E. Beevor and V. Horsley, *Phil. Tr., Lond.*, 1890, pl. xi, Fig. 3.) *A.a.*, anterior or ascending fibres of the pars frontalis of capsule; *H.*, horizontal fibres of the same; *S.d.*, superior or descending fibres of the same; *P.f.*, pyramidal fibres (excitables); *P.*, fibres entering the pars occipitalis of the capsule; *N.c.*, nucleus caudatus; *N.L.*, nucleus lenticiformis; *Th.*, thalamus; *C.a.c.*, commissura anterior cerebri.

In horizontal section the appearance of the capsule varies enormously at different levels, as is shown by the accompanying figure (Fig. 637). At the horizontal level of the capsule most

frequently described (that is, a horizontal section which strikes the ventral end of the genu corporis callosi, the pulvinar, and the

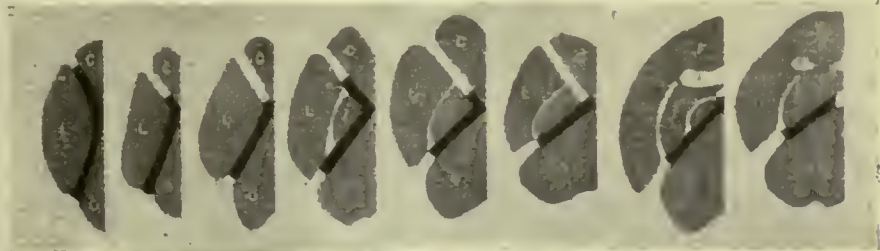

FIG. 637.—Position of fibres at various levels of the capsula interna of the monkey. (After C. E. Beevor and V. Horsley, *Phil. Tr., Lond.*, 1890, pl. v, Fig. 1.)

polus occipitalis, Fig. 638), one sees that it can be divided, as Charcot suggested, into an anterior limb and a posterior limb, which meet at an oblique angle to form the so-called genu capsulæ internæ. The anterior limb is known as the pars frontalis capsulæ internæ, while the posterior limb is designated the pars occipitalis capsulæ internæ.

The pars frontalis (sometimes known as the lentiformo-striate portion) is smaller than the pars occipitalis and consists at this level almost exclusively of fibres running nearly horizontally and made up in the main of axones running corticalward from the thalamus. As the genu is approached the fibres assume a more vertical direction.

The pars occipitalis can be further subdivided into a thalamo-lenticiiform portion (that situated between the thalamus and the nucleus lentiformis) and a retro-lentiform portion, namely, that portion situated lateral to the thalamus, but behind the posterior extremity of the nucleus lentiformis.

The fibres which pass through the genu capsulæ internæ are not located in the same antero-posterior position in all horizontal planes, since the position of the genu alters; in the more inferior horizontal planes it is situated far more posteriorly than in planes higher up. In the same way the pars frontalis capsulæ internæ is shorter in inferior planes than in superior planes. The importance of recognizing these differences in position at different levels can not be too much emphasized; much of the confusion in pathological literature with regard to the internal capsule is due to the fact that clinicians and pathological anatomists have paid





FIG. 638.—Horizontal section through the right cerebral hemisphere cut at a distance of 61 mm. below its superior border; natural size. (After J. Dejerine, *Anatomie des Centres Nerveux*, Paris, 1895, p. 408, Fig. 226.) *AM*, claustrum; *C*, cuneus; *CA*, hippocampus (cornu ammonis); *Ce(g)*, genu corporis callosi; *Ce*, capsula externa; *Cy*, gyrus dentatus; *Cia*, pars frontalis capsulae internae; *Ci(g)*, genu capsulae internae; *Cing*, horizontal bundle of the cingulum; *Cing(p)*, posterior bundle of the cingulum; *Cip*, pars occipitalis capsulae internae; *Cirl*, retrolenticular portion of internal capsule; *cm*, sulcus cinguli; *CO*, centrum semiovale; *cop*, commissura posterior cerebri; *Cse*, gyrus subcallosus; *do*, cornu posterius ventriculi lateralis; *F<sub>1</sub>*, gyrus frontalis superior; *F<sub>2</sub>*, gyrus frontalis medius; *F<sub>3</sub>*, gyrus frontalis inferior; *f<sub>1</sub>*, sulcus frontalis superior; *f<sub>2</sub>*, sulcus frontalis inferior; *F<sub>2</sub>(c)*, pars triangularis gyri frontalis inferioris; *Fli*, fasciculus longitudinalis inferior; *FM*, fasciculus retroflexus Meynerti; *Fm'*, fasciculus inferior or minor of the fornix; *Gh*, nucleus habenulae; *Gp*, corpus pineale; *Ia*, insula (pars anterior); *Ip*, insula (pars posterior); *K*, fissura calcarina; *K<sub>4</sub>po*, union of the fissura calcarina with the fissura parieto-occipitalis; *L<sub>1</sub>*, gyrus cinguli; *L(i)*, isthmus gyri fornicati; *lc*, lamina cornea and fibres of the tenia semicircularis; *Lg*, gyrus lingualis; *lmc*, lamina medullaris lateralis nuclei lentiformis; *lmi*, lamina medullaris medialis nuclei lentiformis; *lms*, lamina medullaris superficialis; *mF<sub>1</sub>*, facies medialis gyri frontalis superioris; *NC*, caput nuclei caudati; *NC'*, cauda nuclei caudati; *Ne*, nucleus lateralis thalami; *NL<sub>1</sub>*, *NL<sub>2</sub>*, globus pallidus (of nucleus lentiformis); *NL<sub>3</sub>*, putamen (of nucleus lentiformis); *O<sub>1</sub>*, *O<sub>2</sub>*, gyri occipitales; *oa*, sulcus occipitalis anterior of Wernicke; *OF*, fasciculus occipito-frontalis; *oi*, sulcus interoccipitalis; *Op*, *F<sub>2</sub>*, pars opercularis gyrus frontalis inferioris; *OpR*, Rolandic operculum; *PaTh*, pedunculus anterior thalami; *po*, fissura parieto-occipitalis; *Pul*, pulvinar; *pel*, cuneo-limbic fold; *πplp*, posterior parieto-limbic fold; *RTh*, radiatio occipito-thalamica Gratioleti; *S(p)*, ramus posterior fissurae cerebri lateralis Sylvii; *S(r)*, ramus ascendens; *scc*, sinus corporis callosi; *Sgc*, substantia grisea centralis; *Sge*, subependymal gray matter; *T<sub>1</sub>*, gyrus temporalis superior; *T<sub>2</sub>*, gyrus temporalis medius; *t<sub>1</sub>*, sulcus temporalis superior; *Tup*, tapetum; *tec*, tenia tecta; *Tya*, anterior pillar of the fornix; *TgV*, ventriculus lateralis; *Th*, thalamus; *Tp*, gyrus temporalis transversus; *tp*, sulcus temporalis transversus; *V<sub>3</sub>*, ventriculus tertius; *V'*, stripe of Vieq d'Azyr; *VA*, fasciculus thalamo-mammillaris Vieq d'Azyr; *Vf*, cornu anterius ventriculi lateralis; *Vsl*, cavum septi pellucidi; *Zr*, zona reticularis.



but little, if any, attention to the variations in the structure of the capsule at different horizontal levels. In every case in which at autopsy a circumscribed lesion of the internal capsule is found the pathologist should take care to describe accurately the exact localization of the lesion with regard to planes taken in the three dimensions of space.

On the whole it may be said that the fibres passing through the internal capsule correspond very well in position to the gyri to which or from which they radiate, those farthest forward being connected with the frontal lobe, those in the middle with the central gyri, while those more posteriorly situated run to or from the temporal and occipital gyri.

Beevor and Horsley found that the *pars frontalis capsulae internæ* is for the most part entirely unexcitable, or rather that electrical excitation applied to it leads to no motor response.

The fibres which on stimulation call forth definite movements occupy positions in the level most frequently described, the genu and the thalamo-lentiform portion of the internal capsule; that is, the genu and the anterior two thirds of the *pars occipitalis capsulae internæ*. From before backward in the internal capsule the arrangement of the fibres is as follows: Farthest forward stimulation causes movements of the eyes. A little farther back the fibres for the opening of the mouth are situated; then come those governing the movements of the head and eyes, and next the fibres for the tongue and for the angle of the mouth. Immediately behind these are situated the fibres governing the movements of the upper limb—first those for the shoulder, and next those for the wrist, fingers, and thumb respectively. After these come the fibres for the trunk, and last of all the fibres governing the movements of the lower limb in the following order: Hip, ankle, knee, hallux, toes. The arrangement in the capsule is therefore seen to be but a reproduction of that on the cortex, which in its turn, as has been pointed out above, corresponds to a peripheric projection of the order of the metameres of the whole body. In the accompanying drawing (Fig. 639) the relation between the localization of motor or efferent function in the cortex and that in the capsule are clearly shown. In the capsule, as in the cortex, segmental movements and not individual muscles are represented. It is interesting to note with regard to the lateral juxtaposition of the fibres in the capsule that those most medially situated in the thalamo-lentiform portion of the *pars*

occipitalis, when stimulated, yielded no motor response, since, as we have seen, when studying the axones of diencephalo-telencephalic sensory neurones, this region of the capsule is that in which many of these axones are situated.

The study of the internal capsule of the orang-outang by the method of electrical excitation yielded, according to Beevor and Horsley, results very similar to those obtained with the bonnet monkey. The localization is epitomized in the following table:

MOVEMENT.	EXTENDS	
	From	To
Eyes turn to opposite side .....	M. 1 max. 2	M. 5
Eyelids closing (blinking).....	3	5
Retraction of angle of mouth to opposite side .....	4	7
Tongue flattened and tip directed to opposite side ..	4	6
Flexion of thumb.....	5	8
Flexion of fingers.....	5	9'
Flexion of wrist.....	4	10
Flexion of elbow.....	6	..
Abduction of shoulder.....	8	..
Adduction of shoulder.....	..	10'
Flexion of toes .....	10	10'
Eversion of ankle.....	9'	..
Plantar extension of ankle.....	10	..

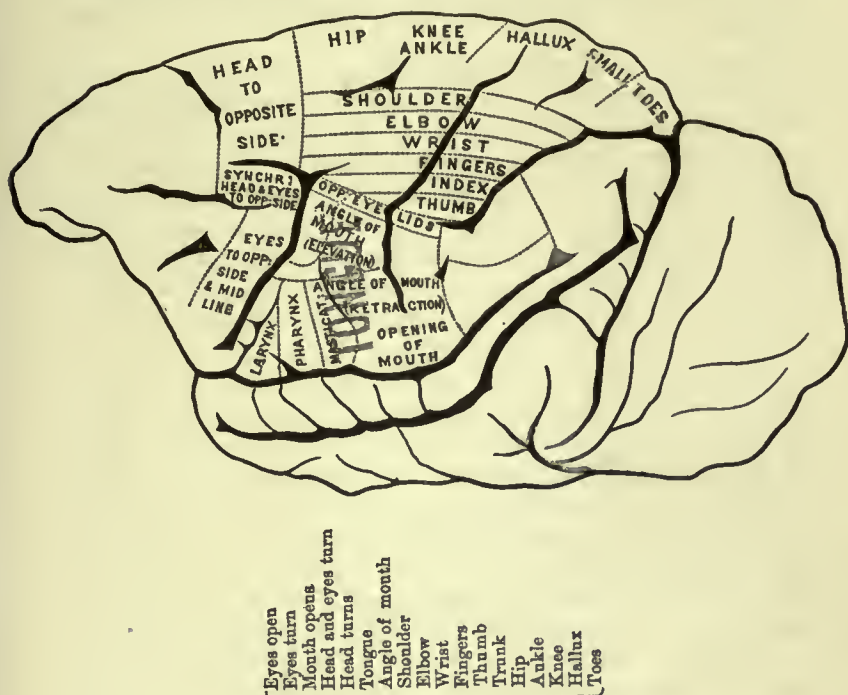
The length of the pars occipitalis of the internal capsule in the orang-outang, which they studied, was 18 mm.

The fibres running from the pallium to the motor nuclei of the cerebral nerves leave the other motor fibres in the pons and medulla oblongata. These fibres throwing the nuclei of the motor cerebral nerves under the influence of the pallium are not, strictly speaking, included in the term "pyramidal fibres."

The "pyramidal tract" proper consists of the fibres which go through the pyramids of the medulla and form the fasciculi cerebro-spinales laterales and the fasciculi cerebro-spinales ventrales of the spinal cord; that is to say, the fibres of the pyramidal tract, strictly speaking, innervate mainly the lower motor neurones by means of which the movements of the upper and lower extremity are executed. Many writers, however, especially English and American neurologists, include the fibres going to the lower motor neurones of the cerebral nerves, as well as those going to the lower motor neurones of the spinal cord, under the term pyramidal tract. This is a matter of nomenclature and of but little significance. The main point for the student to grasp is that



both sets of fibres have a similar function—to throw the lower motor neurones under the influence of the pallium.



Arrangement of excitible fibres in the internal capsule.

FIG. 639.—Drawn from a photograph (magnified twice) of the outer surface of a monkey's (*Macacus sinicus*) left hemisphere. (After C. E. Beevor and V. Horsley, *Phil. Tr., Lond.*, 1890, p. 81, Fig. 7.)

From the fact that in the cortex and in the internal capsule the bundles of fibres are arranged in groups corresponding to the different movements, and from the fact that in the spinal cord fibres which run for the longest distance tend to be more peripherally situated than those which run for shorter distances, it is not surprising to learn that in the fasciculus cerebro-spinalis lateralis of the spinal cord there is a definite grouping of the fibres corresponding to segmental movements. Direct proof of this, however, was adduced only recently. In 1897 Gad and Flatau \*

\* Gad, J., und E. Flatau. Ueber die grobere Localisation der für verschiedene Körperteile bestimmten motorischen Bahnen im Rückenmark. *Neurol. Centralbl., Leipz.*, Bd. xvi (1897), S. 481.

excited with the faradic current different areas of the fresh-cut section of the pyramidal tract of the spinal cord of the dog. Their results are well illustrated in the accompanying diagrams. (Fig. 640).

The study of secondary degenerations has yielded results second in importance only to those afforded by the embryological method of Flechsig with regard to the paths followed by the axones of the neurones extending between the pallium and the motor nuclei of the cerebral and spinal nerves. The knowledge afforded by the study of secondary degenerations has been derived from two sources: (1) the study of human cases observed clinically and pathologically, and (2) the study of the nervous system of animals in which the motor tract has been experimentally injured.

The first to investigate in man degenerations in the domain of the pyramidal tract was Türck in 1851,\* who in cases of long-standing hemiplegia observed degeneration not only in the spinal cord but also in the posterior and superior part of the internal capsule and in the middle of the base of the cerebral peduncle. The illustrations accompanying his publications are very crude, but nothing but praise can be said of the accuracy of his observations. Türck stated that when definite parts of the cerebrum were destroyed in any way, as a result there became diseased in every instance definite bands of fibres which are situated in the internal capsule, the base of the cerebral peduncle, the ventral part of the pons, the medulla oblongata, and the spinal cord. This "secondary disease," which he observed in a large series of cases, manifested itself in the appearance first of numerous fatty particles and later by atrophy. Türck observed that this secondary disease occurred not only when the lesion was situated in the cerebrum, but also whenever the bands of fibres in their course between the cerebrum and the spinal cord, or even in the spinal cord itself, became interrupted. He made out by the study of these secondary degenerations the decussation of the pyramidal tract in the medulla oblongata, and it is to him also that we owe the recognition for the first time of the existence of a direct pyramidal tract (although not recognized by Türck as such)

---

\* Türck, L. Ueber sekundäre Erkrankung einzelner Rückenmarkstränge und ihrer Fortsetzungen zum Gehirn. Ztschr. d. k.-k. Gesellsch. d. Aerzte zu Wien (1852), ii, 511; (1853), ii, 289.

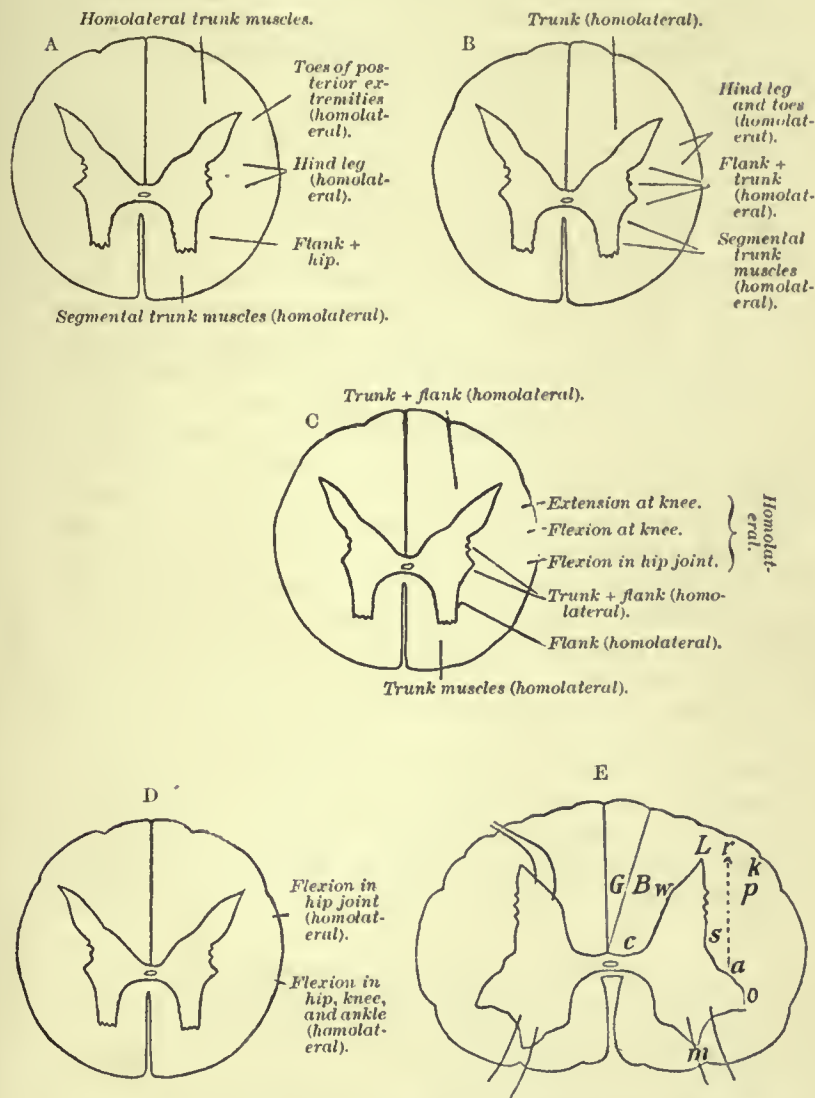


FIG. 640.—Experimental stimulation of freshly cut substantia alba of dog's spinal cord. (After J. Gad und E. Flatau, *Neurol. Centralbl.*, Leipz., Bd. xvi, 1897, S. 483-485, Figs. 1-5.) A. Level of T IX. B. Level of T VII. C. Level of T X. D. Level of T X. E. Level of C VIII. Stimulation at B and G, movements of trunk (homolateral); at p, thigh + skin of abdomen; at a, homolateral segmental trunk muscles + extension of homolateral foreleg (plantar flexion and adduction of toes); at k, no muscular contraction.

which passes down in the ventral column of the cord on the same side without decussation.\* He asserted that these tracts degenerated only in a descending direction from the side of the lesion, although he recognized that above a given lesion there were many fibres which degenerated in an ascending direction. Türk suggested that the cause of the secondary degeneration was probably the interruption of conduction, and inclined to the view that the conduction direction could be concluded from the direction assumed by the degeneration in a given case.

This preliminary knowledge of secondary degenerations was much expanded by the investigations of Bonchard,† Chareot,‡ Pierret,§ Nothnagel,|| von Monakow, and others. It has been possible in a large number of human cases to follow the secondary degeneration not only of the whole pyramidal tract, but also of the separate portions of this tract, to their destination. A good example of the secondary degeneration of the pyramidal tract after a cerebral hæmorrhage in the region of the internal capsule is illustrated in the accompanying sections (Figs. 641). From what has been said of localization, it is obvious that lesions of the cerebral cortex will be likely to cause only partial secondary degeneration of the pyramidal tract, since, in order to lead to complete degeneration of the tract, an enormous area of cortex would have to be involved, and, as a matter of fact, hæmorrhages and other lesions implicating the cortex of the pallium and centrum ovale are not sufficiently large to lead to destruction of the cell bodies or axones of all the neurones extending between the pallium and the groups of lower motor neurones. Unfortunately for human beings, however, the most frequent place in which the pyramidal tract suffers injury is the internal capsule. Here the fibres are closely pressed together

\* Türk designated this the *Hülsen-Vorderstrangbahn*.

† Bouchard, C. Des dégénéralions secondaires de la moelle épinière. Arch. gén. de méd., Par. (1866), i, pp. 272: 441; 561; 578; ii, 273.

‡ Chareot, J. M. Leçons sur les maladies du système nerveux faites à la Salpêtrière, 8vo, Paris (1872-'73).

§ Pierret. Considérations anatomiques et pathologiques sur le faisceau postérieur de la moelle épinière. Arch. de physiol. norm. et path., Par., t. v (1873), pp. 534-546.

|| Nothnagel, H. Experimentelle Untersuchungen ueber die Functionen des Gehirns. Arch. f. path. Anat., etc., Berl., Bd. lvii (1873), pp. 184-214; Bd. lx (1874), S. 129-149.





FIG. 641.—Degeneration, following hæmorrhage of six months' duration, in the nucleus lateralis thalami and in the lenticulo-optic portion of the capsula interna. (After C. von Monakow, *Gehirnpathologie*, Wien, 1897, Figs. 171–175.) A. Oblique horizontal section through the anterior part of the nucleus hypothalamicus, corpus Luysi; *II*, cystic nodule filled with transformed blood; *HI*, *E*, pericystic softening; *ci*, capsula interna; *D*, secondary degeneration in the capsula interna, dotted red; the pyramidal tract is interrupted and totally degenerated; *J*, insula; *LC*, nucleus hypothalamicus; *Ped*, pedunculus cerebri; *II*, tractus opticus; *Li*, nucleus lentiformis; *Str*, corpus striatum; *lat*, nucleus lateralis thalami; *vent*, nucleus ventralis thalami; *lme*, lamina medullaris. B, C, D, fronto-horizontal sections (plane of Meynert) through the brain stem of the same case; B, level of the colliculus superior and of the pedunculus cerebri; C, middle of pons; D, medulla oblongata. The degenerated pyramidal tract is red. *Aqu*, aqueductus cerebri; *III*, nervus oculo-motorius; *III K*, nucleus nervi oculo-motorii; *sch*, lemniscus medialis; *HL*, fasciculus longitudinalis medialis; *BA*, brachium conjunctivum; *BrA*, brachium pontis; *Ped*, pedunculus cerebri; *pyr*, pyramidal tract degenerated on the right side; *cr*, corpus restiforme; *V. aufst*, tractus spinalis nervi trigemini. E. Degenerated fibres in the spinal cord of the same case; 1–3, pars cervicalis; 4–8, pars thoracalis; 9–12, pars lumbo-sacralis; *pyr*, fasciculus cerebro-spinalis ventralis; *pyra*, fasciculus cerebro-spinalis lateralis.

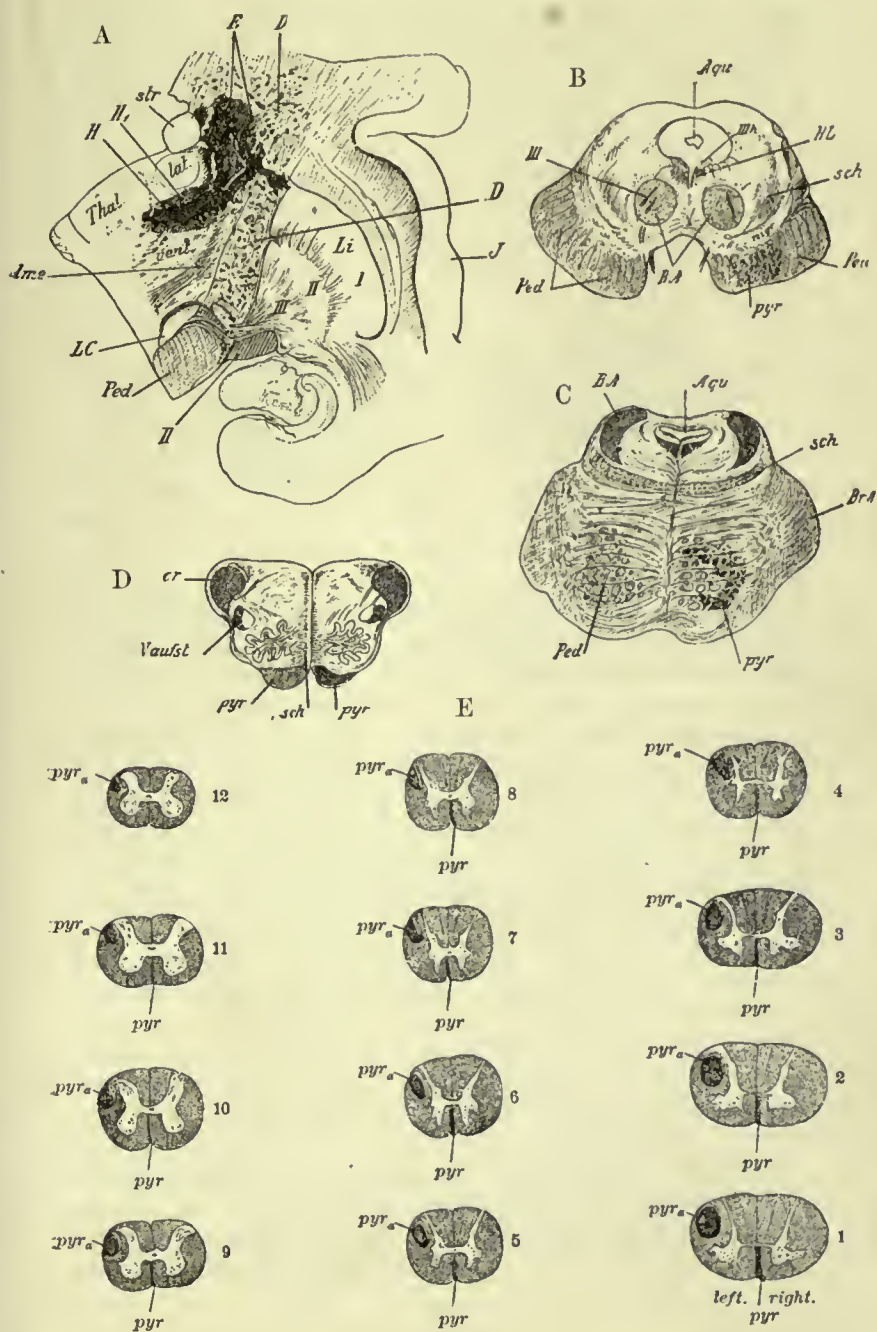


FIG. 641.

into a compact bundle, and a tolerably circumscribed lesion will suffice to lead to complete interruption of all the descending motor axones. This region of the internal capsule is supplied in the main by the so-called lenticulo-striate artery of Duret, and in by far the greater proportion of cases of hæmorrhage this artery is involved. So frequently does hæmorrhage take place at this site that this artery has been designated by Charcot as the "artery of cerebral hæmorrhage." This explains why it is that in the majority of instances of cerebral hæmorrhage there results total hemiplegia of the opposite side of the body. At autopsy the motor tract below the lesion will be found degenerated, and the area of degeneration can be distinctly made out in the cerebral peduncle, in the pons, in the medulla, and in the spinal cord as far as the lowest level to which the fasciculi cerebro-spinales penetrate. If an autopsy be made before too long a period has elapsed, the area corresponding to the position of the motor fibres shows a diminished consistence, and on cross section the area may look somewhat darker and rather more gelatinous than normal. If bits of the tissue be placed in Müller's fluid for a few days the degenerated area presents on cross section a typical appearance. One makes out a clear, sharply circumscribed zone, distinctly visible to the naked eye. If sections be examined shortly after the lesion has occurred, numerous cells containing fat droplets, the so-called granular corpuscles, will be found present in the degenerated area. Specimens stained by Marchi's method show the degenerated fibres stained a deep black color. If the individual have lived for a long time (more than three months) after the lesion has occurred, Marchi preparations may not show the degenerated area well, owing to the absorption of the myelin of the degenerated fibres, but Weigert's method will, at this stage, bring out clearly the area of degenerated fibres. Instead of a mass of normal, black-stained, medullated nerve fibres, a yellowish patch, in which only a few normal nerve fibres are retained, can be made out. It is important to emphasize, however, the fact that in such degenerated areas a certain number of fibres nearly always escape degeneration. This is owing to the fact that in the area ordinarily designated in the spinal cord, for example, as the fasciculus cerebro-spinalis lateralis or lateral pyramidal tract, there are, in addition to the medullated axones of this tract proper, a number of other axones which do not belong to it. Probably no absolutely



pure tract exists in the spinal cord, but there is everywhere a greater or less admixture of fibres of different tracts. This accounts, therefore, for the preservation of certain normal medullated fibres in the area of the pyramidal tract even after all the motor fibres descending from the pallium have undergone secondary degeneration. Another reason, however, for the persistence of healthy medullated fibres in the region of one lateral pyramidal tract after unilateral cerebral lesion is the presence in each

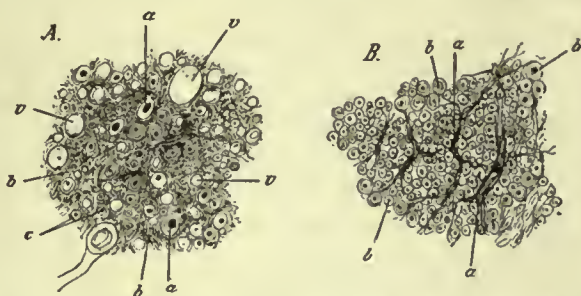


FIG. 642.—A. Portion of pyramidal in tract in cross section which has undergone secondary degeneration; *a*, axones; *b*, granular and finely fibrous area of transformed neuroglia; *c*, single normal nerve fibres remaining uninjured; *v*, cavities which have arisen by the breaking down and absorption of nerve fibres. B. Section of the normal pyramidal tract; *a*, connective-tissue septa; *b*, healthy nerve fibres. (After C. von Monakow, *Gehirnpathologie*, Wien, 1897, S. 724, Fig. 176.)

lateral pyramidal tract of medullated axones from both cerebral hemispheres. As we shall see farther on, it has been proved that besides the crossed axones in the lateral pyramidal tract there are always a certain number of axones which descend in the lateral bundle uncrossed from the cerebral hemisphere of the same side. The differences in appearance of the healthy pyramidal tract and of that which has undergone secondary degeneration are represented in Fig. 642.

## CHAPTER LXII.

### INTERMEDIARY AND UPPER MOTOR NEURONES (CONTINUED).

Fibres from the pallium to the motor nuclei of the cerebral nerves—Studies of Hoche and others—Results of extirpation of localized areas of the cortex—Significance of uncrossed fibres of the pyramidal tract—Intercalation of dendroxones between upper motor neurones and lower motor neurones—The centrifugal cortico-muscular conduction path—Clinical symptoms following lesions of different portions of the path.

#### 2. Those the Axones of which run to the Motor Nuclei of the Cerebral Nerves.

THE study of the degenerated descending motor axones in human beings by means of the method of Marchi has in recent years thrown a flood of new light upon the distribution of these axones. As a single instance of the applicability of this method and of the special advantages afforded by it, may be mentioned the recent research of Hoche\* in connection with two fatal cases occurring close together in which there was softening of one cerebral hemisphere. His findings are very remarkable in many ways, and it is as yet too early to pass judgment upon them. More cases must be studied by the same method before the last word can be said. It had been generally believed that in the cerebral peduncle the fibres coming from the pallium to the motor nuclei of the cerebral nerves were most medially placed, while those for the arm and leg were more laterally placed; and there is much clinico-pathological evidence in favor of this assumption. Hoche's cases, however, did not support the prevailing view. The area in the section of the pes, corresponding to that ordinarily taken to be the one in which the fibres innervating the motor nuclei of the cerebral nerves are situated, was in Hoche's case entirely free from degeneration, although clinically the

---

\* Hoche, A. Beiträge zur Anatomie der Pyramidenbahn und der oberen Schleife nebst Bemerkungen ueber die abnormen Bündel in Pons und Medulla oblongata. Arch. f. Psychiat. u. Nervenkr., Berl., Bd. xxx (1898), II. i, S. 103.

paralysis had involved the domain of the cerebral nerves. On the other hand, in Hoche's case lateral from the area usually designated as the motor area, in a section of the cerebral peduncle which has always been believed to be an area through which sensory fibres pass upward into the cerebrum, degeneration had occurred in a centrifugal direction. Hoche followed the degeneration from the base of the cerebral peduncle and downward. The pyramidal tract proper (for the upper and lower extremities) corresponded closely to the descriptions usually given of it. Thus no fibres were given off from it to the nuclei of the nervi oculo-motorii, although a great number were followed from it to the nucleus nervi facialis and to the nucleus nervi hypoglossi. Hoche found fibres going from the pyramidal tract of one side to the nucleus nervi facialis of the same side, and also across the raphe to the nucleus nervi facialis of the opposite side. A large number of fibres going from the pyramidal tract to the nucleus nervi hypoglossi of the same side and a few to the nucleus nervi hypoglossi of the opposite side could also be made out. In the spinal cord degenerated fibres could be traced from both pyramidal tracts into the gray matter of the ventral horns; and it is worthy of note that from the lateral pyramidal tract fibres go not only to the ventral horn of the same side, but some of them pass through the ventral white commissure to enter the ventral horn of the opposite side.

Hoche also asserts that the fibres from the ventral pyramidal tract (*fasciculus cerebro-spinalis ventralis*) run in to terminate in the gray matter of the ventral horns of both sides, but mainly in the ventral horn of the opposite side of the cord. Hoche's finding, that fibres of upper motor neurones run to the cerebral motor nuclei of both sides, brings these nuclei closely into accord with the motor nuclei of the spinal cord.

Still more interesting, however, than these double relations of the pyramidal tract to the cerebral motor nuclei are the observations of Hoche with regard to another descending motor tract. In his first case, especially, he was able to prove that the nucleus nervi facialis and the nucleus nervi hypoglossi receive medullated axones from the cerebrum by a path entirely separate from the pyramidal tract, which descends through what we have been accustomed to consider as an almost purely sensory region—namely, that of the medial lemniscus. Coming out of the lemniscus medialis in the pons and extending between it and the

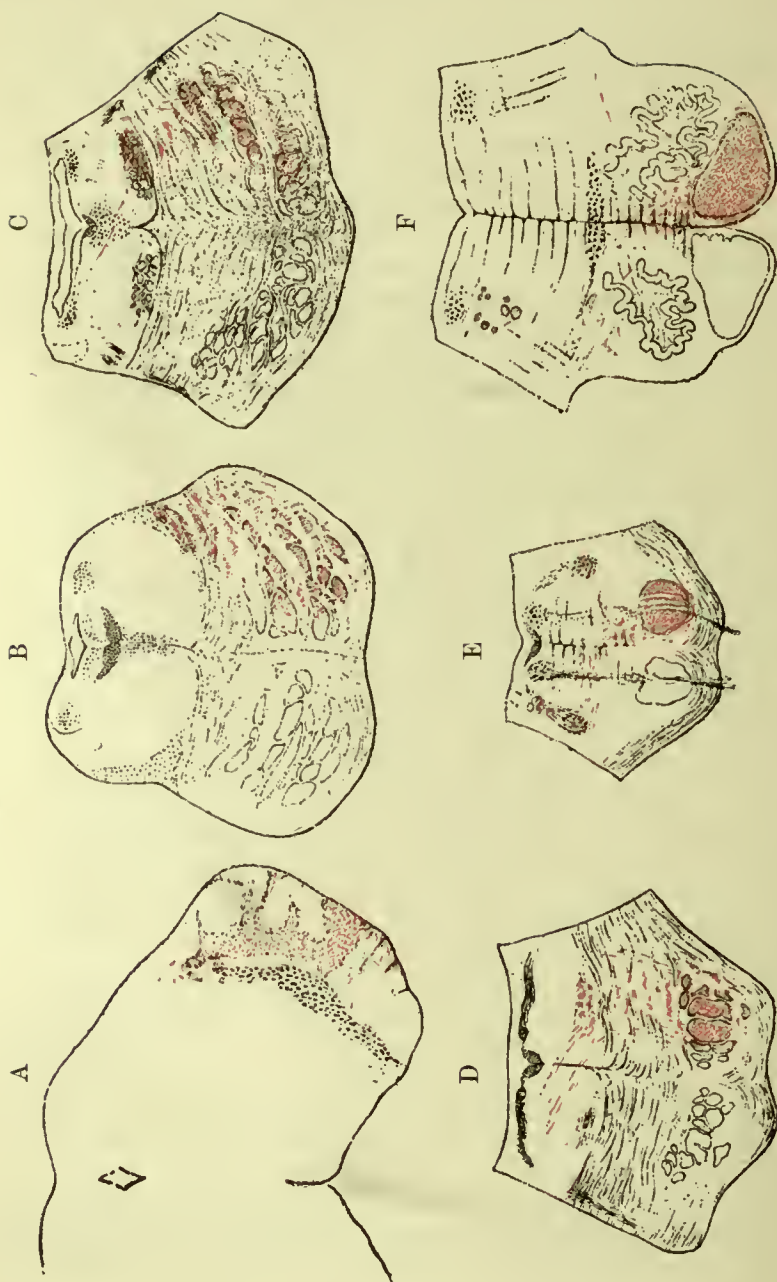



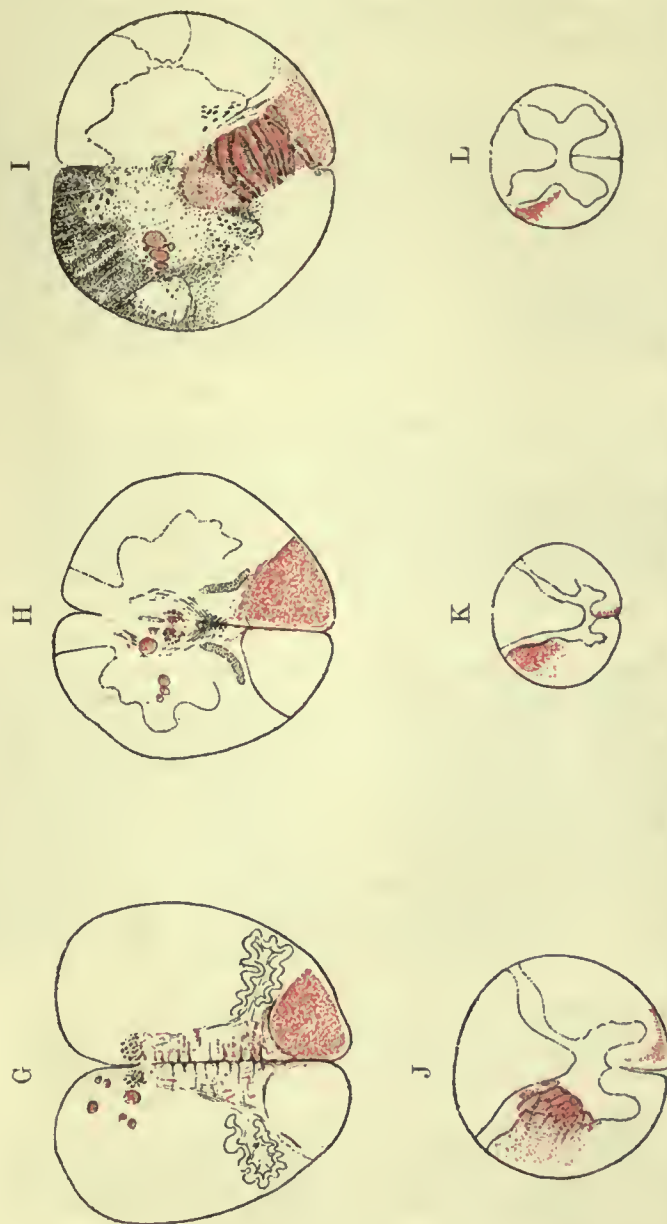


FIG. 643.—Secondary degeneration of motor fibres from the pallidum after extensive cerebral lesion. (After A. Hoche, Arch. f. Psychiat., Berl., Bd. xxx, 1898, Taf. iii, Figs. 3, 4, 6, 7, 8, 10, 12, 13, 15, 16, 18, 20.) A. Area of degeneration in the basis pedunculii. C to J, degenerated fibres of pyramidal tract. K, level of C<sub>1</sub>. L, Level of C<sub>6</sub>. M, Level of L<sub>4</sub>.

nucleus nervi facialis of the same and of the opposite side could be made out a number of degenerated fibres. In the same way, coming out from the stratum interolivare lemnisci of one side, could be seen a number of degenerated fibres extending from it to the nucleus nervi hypoglossi of the same side and through the raphe of the nucleus nervi hypoglossi of the opposite side (Fig. 643). That these fibres are entirely distinct from the majority of the fibres of the lemniscus medialis is proved not only by the fact that they degenerate in a descending direction, but also by the fact that higher up in the nervous system they are entirely separated from the rest of the fibres of the lemniscus medialis. Thus in the uppermost planes of the cerebral peduncle these fibres do not lie in the region of the lemniscus at all; they are situated in the base of the peduncle in the immediate neighborhood of the fibres of the pyramidal tract, but are placed lateral to them. These fibres in reality appear to come out of the internal capsule, whence they go into the base of the cerebral peduncle, occupying a position just lateral to the fibres of the pyramidal tract. In the pons, however, they become somewhat separated from the fibres of the pyramidal tract and become displaced into the region of the lemniscus medialis, running downward in this bundle for a considerable distance. It is interesting to note that this descending centrifugal bundle of the medial lemniscus had been made out many times before, though its significance had not been properly valued. Thus it had long been known from the researches of Flechsig and von Bechterew that a certain number of the fibres from the medial lemniscus become medullated at a much later period than do the majority of its fibres. Von Bechterew had even given this bundle a special name.\*

Hoche has studied the position of the fibres in the brain of the newborn babe, when they are easily distinguishable owing to the fact that they are non-medullated and appear as pale areas (Fig. 644).

It is especially interesting that in Hoche's two cases the most medial parts of the base of the cerebral peduncle (Flechsig's frontal cerebro-corticopontal path) were entirely free from

---

\* von Bechterew designated it the *accessorische Schleife*. Schlesinger calls it the *laterale pontine Bündel*. It is not, however, identical with the temporal cerebro-corticopontal path of Flechsig; for in the base of the peduncle Hoche's fibres lie between the temporal cerebro-corticopontal path of Flechsig and the fibres of the pyramidal tract.

degeneration; and that also the most lateral portions of the base of the peduncle (Flechsig's temporal cerebro-corticopontal path, *Bündel von der Schleife bis zum Fuss*) were also entirely free from secondary degeneration.

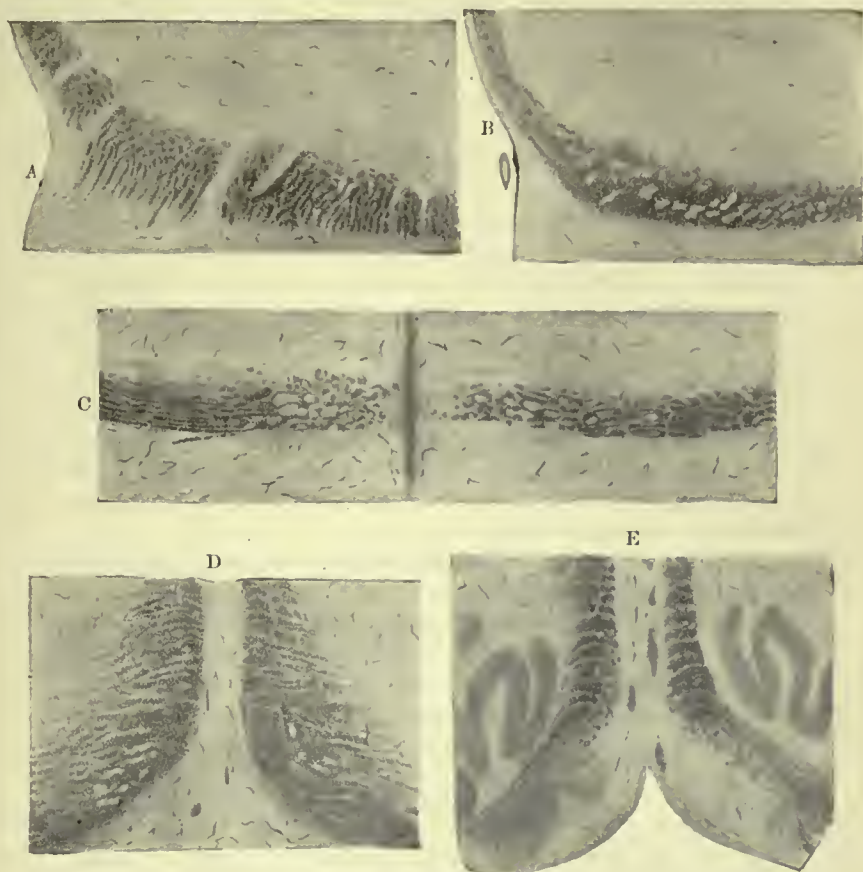


FIG. 644.—Non-medullated fibres in the lemniscus at birth corresponding to the centrifugal bundles of the lemniscus. (After A. Hoche, *Arch. f. Psychiat.*, Berl., Bd. xxx, 1898, Taf. iv, Figs. 24 to 28.) A. Level of the colliculus inferior. B. Level of superior part of pons. C. Level of nervus trigeminus. D. Level of spinal extremity of nucleus nervi facialis. E. Level of nervus vagus.

In the most medial part of the peduncle, Flechsig and others have located the path from the pallium to the nuclei of the motor cerebral nerves, while by Spitzka it was placed in the lateral part of the pes, in the so-called bundle from the lemniscus to the pes.

It seems probable, therefore, on comparing Hoche's researches with those of other investigators, that the nuclei of the motor cerebral nerves can be thrown under the influence of the pallium by means of fibres which run in two entirely different paths—(1) a path situated in the pes medial to the pyramidal tract, and (2) a path in the pes lateral from the pyramidal tract. That different motor paths destined for the cerebral motor nuclei may possibly exist is of the highest interest in connection with the puzzling clinical problems met with in the domain of distribution of the cerebral motor nerves. We may hope that further investigations with the Marchi method of secondary degeneration after cerebral lesions will clear up anatomically these clinical differences, especially with regard to paralyses of the face and tongue which have so long puzzled us.

In one of Hoche's cases there was degeneration of an abnormally placed bundle of fibres of the pyramidal tract, which evidently corresponds to the abnormal bundle described by Pick,\* Heard,† of Pittsburg, and others. It would seem that in a few instances a bundle leaves the pyramidal tract of one side, undergoes premature decussation in the raphe, and takes an abnormal course through the medulla oblongata, fusing finally again with the fasciculus cerebro-spinalis lateralis below the level of the general pyramidal decussation.

One of the most fruitful of all the modes of investigation for the determination of the course of the fibres of the pyramidal tract, especially of individual portions of this tract, is that of extirpation of the whole, or, more particularly, of limited areas of the motor cortex, with subsequent study of the nervous system for secondary degenerations. The earlier studies of von Gudden,‡ von Monakow,\* Franck and Pitres,|| and Moeli^ were carried

---

\* Pick, A. Ueber ein abnormes Faserbündel in der Menschlichen Medulla oblongata. Arch. f. Psychiat. u. Nervenkrankh., Bd. xxi (1889).

† Heard, J. D. Ueber abnorme Nervenbündel in der Medulla oblongata des Menschen. Arb. a. d. Inst. f. Anat. u. Physiol. d. Centralnervensyst. an d. Wien. Univ., Leipz., u. Wien (1894), H. ii, S. 86-90.

‡ von Gudden. Cor.-Bl. f. schweiz. Aerzte (1872), No. 4.

\* Experimentelle Beiträge zur Kenntniss der Pyramiden- und Schleifenbahn. Cor.-Bl. f. schweiz. Aerzte, Basel, Bd. xvi (1884), S. 129; 157.

|| Franck, Francois, et A. Pitres. Des dégénérationes secondaires de la moelle épinière consécutive à l'ablation du gyrus sigmoïde chez le chien. Gaz. méd. de Par., 6. s., t. ii (1880), pp. 152-154.

^ Moeli, C. Ueber sekundäre Degeneration. Arch. f. Psychiat. u. Nervenkr., Bd. xiv (1883), S. 173.



out with the aid either of the carmine method or the method of Weigert, but the newer studies have been much more exact owing to the possibility of greater accuracy afforded by the delicate method of Marchi. With this method Marchi and Algeri,\* Muratoff,† Mellus,‡ Langley and Sherrington,\* and Sherrington|| have obtained important results.

Of these experiments, those which have been carried out upon monkeys are of course most valuable, since they yield conclusions more applicable to man. In general it may be said that they have shown that the course outlined for the fibres of the pyramidal tract by the embryological method and by the method of electrical excitation is correct. The experiments have also cleared up the puzzling findings in human cases, in which after unilateral cerebral lesion degenerations in both lateral pyramidal tracts of the spinal cord were observed, since they prove conclusively that, after extirpation even of minute areas of the cerebral cortex in the motor region, fibres of the pyramidal tract degenerate, not only in the lateral pyramidal tract of the opposite side of the spinal cord, but also in the lateral pyramidal tract of the same side of the cord. Each cerebral hemisphere in the monkey is connected with the ventral horns of both sides of the spinal cord.

The explanation of the appearance of degenerated fibres in both lateral pyramidal tracts has been attempted by Sherrington and by Mellus. Sherrington's earlier researches led him to believe that there was a total crossing of the fibres of the pyramidal

---

\* Marchi, V., e G. Algeri. Sulle degenerazioni discendenti consecutive a lesioni sperimentali in diverse zone della corteccia cerebrale. *Riv. sper. d. freniat.*, Reggio-Emilia, vol. xii (1896-'87), pp. 208-252.

† Muratoff, W. Secundäre Degenerationen nach Zerstörung der motorischen Sphäre des Gehirns in Verbindung mit der Frage von der Localisation der Hirnfunctionen. *Arch. f. Anat. u. Physiol.*, Anat. Abth., Leipz. (1893), S. 97-116.

‡ Mellus, E. L. Preliminary Note on Bilateral Degeneration in the Spinal Cord of Monkeys (*Macacus sinicus*) following Unilateral Lesion of the Cortex Cerebri. *Proc. Roy. Soc., Lond.* (1894), May 23.—Experimental Degenerations following Unilateral Lesions of the Cortex Cerebri in the Bonnet Monkey (*Macacus sinicus*). [Abstr.] *Proc. Roy. Soc., Lond.*, vol. lviii (1895), pp. 206-214.

\* Langley, J. N., and C. S. Sherrington. Secondary Degeneration of Nerve Tracts following Removal of the Cortex of the Cerebrum in the Dog. *J. of Physiol.*, Lond., vol. v (1884-'85), pp. 49-65.

|| Sherrington, C. S. Note on Experimental Degeneration of the Pyramidal Tract. *Lancet*, Lond., i (1894), p. 265.

tract. Mellus concluded that, instead of a total crossing, certain of the fibres of the pyramidal tract did not cross at all—a conclusion with which Sherrington in his more recent articles appears to agree.

The experiments of Mellus, which were carried out under the direction of Victor Horsley in London, and which are still being continued in Dr. Mall's laboratory in Baltimore, may be referred to somewhat more in detail. Mellus operated upon the bonnet monkey, extirpating small areas from the motor cortex, sometimes from the hallux centre, sometimes from the thumb centre, sometimes from the various centres in the facial area. The animals were killed in from two to five weeks after the operation, and the brains studied by the method of Marchi (Fig. 645).

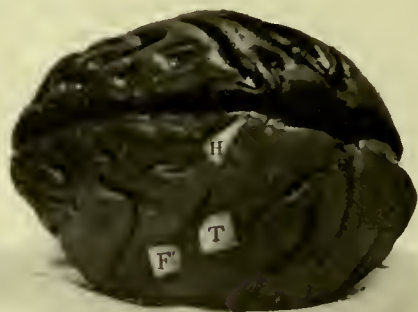

FIG. 645.—Brain of monkey (*Macacus sinicus*), showing cortical area extirpated. H, hallux; T, thumb; F, facial. Being the upper border of facial area upon the anterior central gyrus, the movement represented being closure of the opposite eye and retraction of the opposite corner of the mouth. (Experiments of E. L. Mellus.)

After lesions of the hallux centre, there degenerated many association fibres, both coarse and fine, which pass from the central gyri down as far as the level of the inferior genu of the sulcus centralis Rolandi. Some fine association fibres were found to pass to the lobulus parietalis superior, others to the posterior part of the gyrus frontalis superior, and both coarse and fine association fibres were found to connect the hallux centre with the lobulus paracentralis. This centre was further connected, by means of fibres which passed through the corpus callosum, with the hemisphere of the opposite side being distributed in the opposite hemisphere in an area on the whole similar to that whence they arose.

The projection fibres which degenerate after lesion of the hallux centre could be followed through the medial half of the centrum

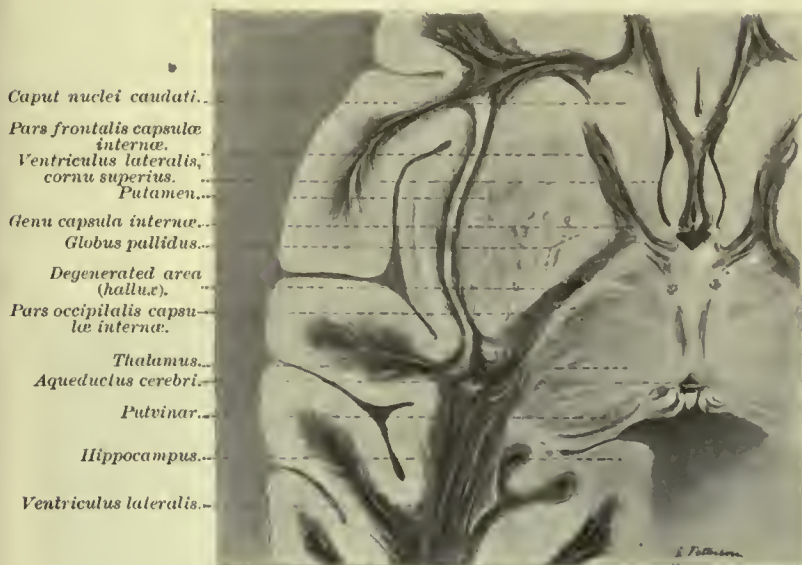


FIG. 646.—Horizontal section of monkey's brain showing area of degeneration in internal capsule, following lesion of hallux centre. (Experiment and preparation by E. L. Mellus.)

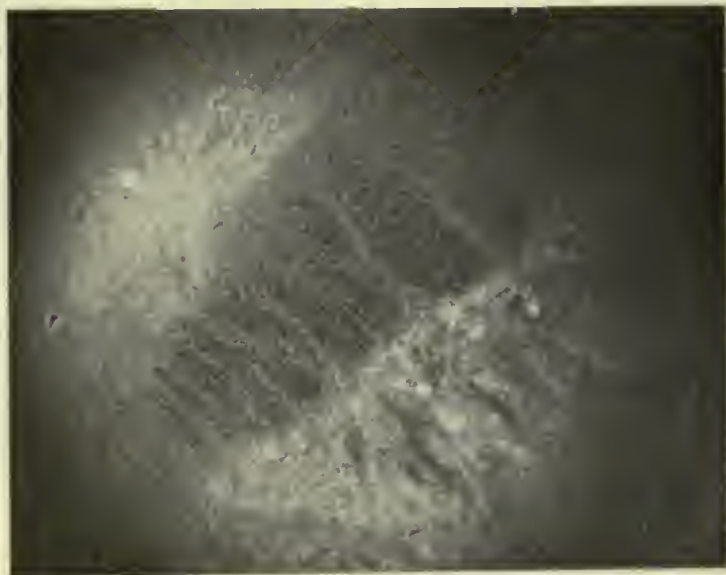


FIG. 647.—Degenerated area in Fig. 646, enlarged. (Experiment and photomicrograph by E. L. Mellus.)

semiovale to the internal capsule, in the lower levels of which they are located in the middle third of the pars occipitalis or posterior limb (Figs. 646 and 647). Here a great many fine degenerated fibres pass out of the internal capsule into the thalamus. The hallux fibres in the basis pedunculi are somewhat evenly scattered over the middle third, and it is especially important that a number of coarse degenerated fibres pass into the substantia nigra apparently to terminate there.

At the level of the decussatio pyramidum (Fig. 648) the hallux fibres undergo partial decussation, the majority passing over into

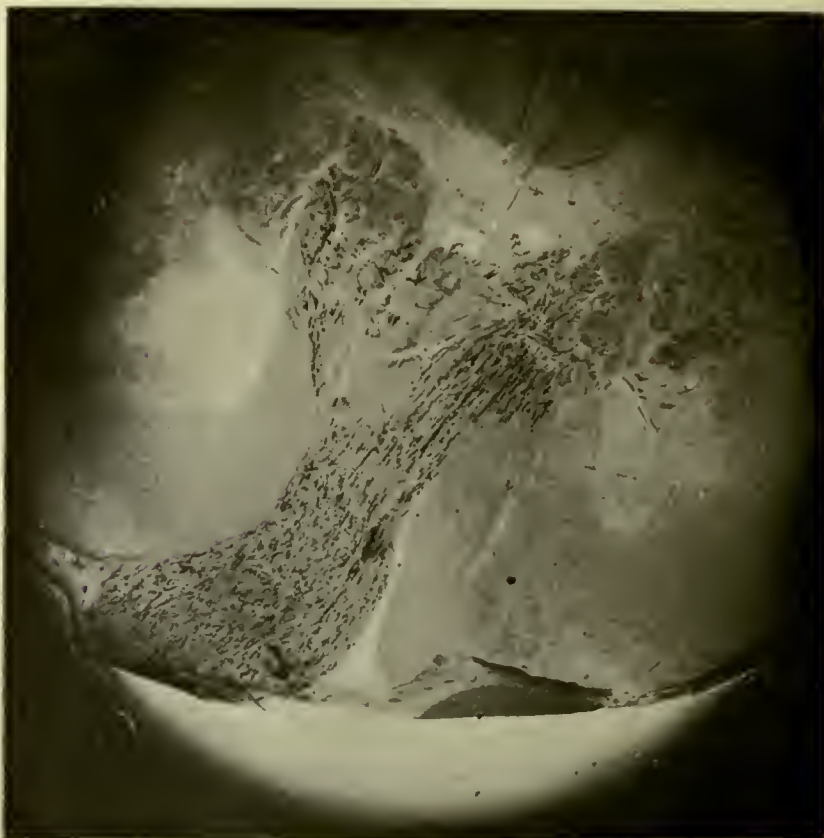


FIG. 648.—Decussatio pyramidum, hallux lesion, showing degenerated fibres passing to fasciculus cerebro-spinalis lateralis of both sides. (Experiment and photo-micrograph by E. L. Mellus.)

the fasciculus cerebro-spinalis lateralis of the opposite side of the cord, a smaller portion going to the fasciculus cerebro-spinalis lat-



eralis of the same side. The relative number of crossed and uncrossed fibres varies considerably in the different animals experimented upon. A few fibres pass down in the fasciculus ventralis

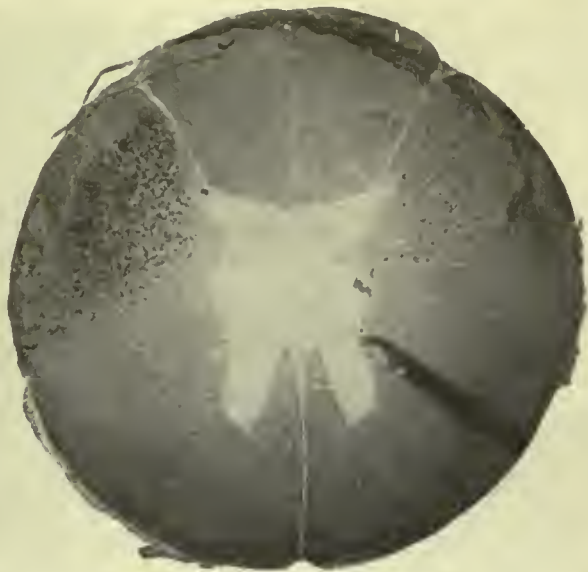

FIG. 649.—Spinal cord at the level of eleventh thoracic root, hallux lesion. Bilateral degeneration. (Experiment and photo-micrograph by E. L. Mellis.)

of the cord of the same side, which proves that in the monkey, contrary to the general statement, there is a very feebly developed fasciculus cerebro-spinalis ventralis (Fig. 649). The degenerated fibres could be followed down through the cervical and thoracic cord without showing diminution in number, but in the lumbar region of the cord the degeneration in the lateral tracts of both sides and in the ventral tract on the same side begins to disappear, although certain fibres extend below the level even of the third sacral root.

Following extirpation of the thumb centre (cortex of posterior central gyrus between inferior extremity of sulcus interparietalis and sulcus centralis Rolandi, a little above the inferior genu of the latter sulcus in the bonnet monkey) association fibres degenerate to the anterior and posterior central gyri, the posterior portion of the gyrus frontalis medius and the gyrus frontalis inferior and to other gyri of the cortex. A certain number of association fibres from the thumb centre pass through about the middle third of the corpus callosum to the hemisphere of the opposite side.

Fine and coarse projection fibres degenerate from the thumb centre downward through the centrum semiovale. The fine fibres

terminate in the thalamus, the large fibres (pyramidal tract fibres) occupy in the lower horizontal levels of the internal capsule the middle third of the pars occipitalis or posterior limb. In the base

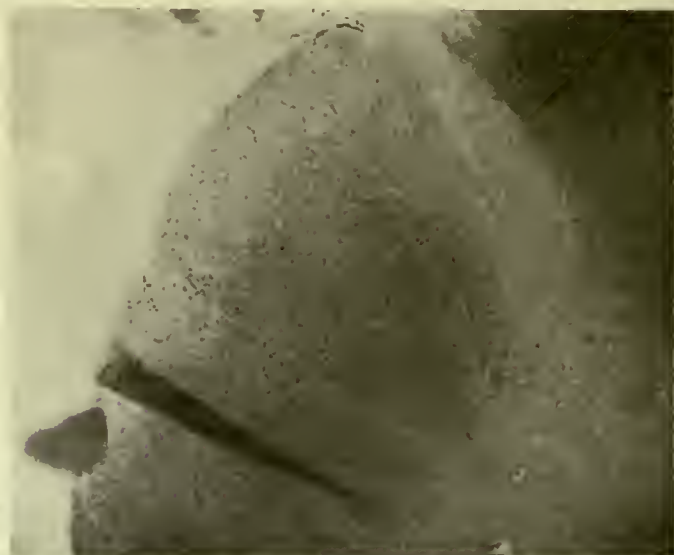

FIG. 650.—Section of spinal cord at the level of first cervical root; degeneration in right fasciculus cerebro-spinalis lateralis after excision of thumb centre of left hemisphere. (Experiment and photo-micrograph by E. L. Mellus.)

of the cerebral peduncle the thumb fibres occupy the middle third of the area as seen on cross section. A large number of the degenerated fibres pass to the substantia nigra. Mellus states that from a half to nearly the whole of the degeneration, following lesion of the thumb centre, which extends as far as the cerebral peduncle, terminates in the substantia nigra. At the pyramidal decussation in the medulla the majority of the fibres cross over into the lateral pyramidal tract of the opposite side, although a few go down in the lateral funiculus (Fig. 650), and still fewer in the ventral funiculi of the same side. It is interesting that the degenerated fibres do not stop in the upper cervical levels, but, as might have been expected from the experiments of Ferrier and Yeo, begin to leave the white matter from the level of the seventh cervical root downward, the degenerating fibres steadily and gradually disappearing by turning into the gray matter until at the level of the third thoracic root no degenerated fibres remain.

It would take too long to describe all of the experiments made by Mellus in connection with the facial area of the cortex, but in-

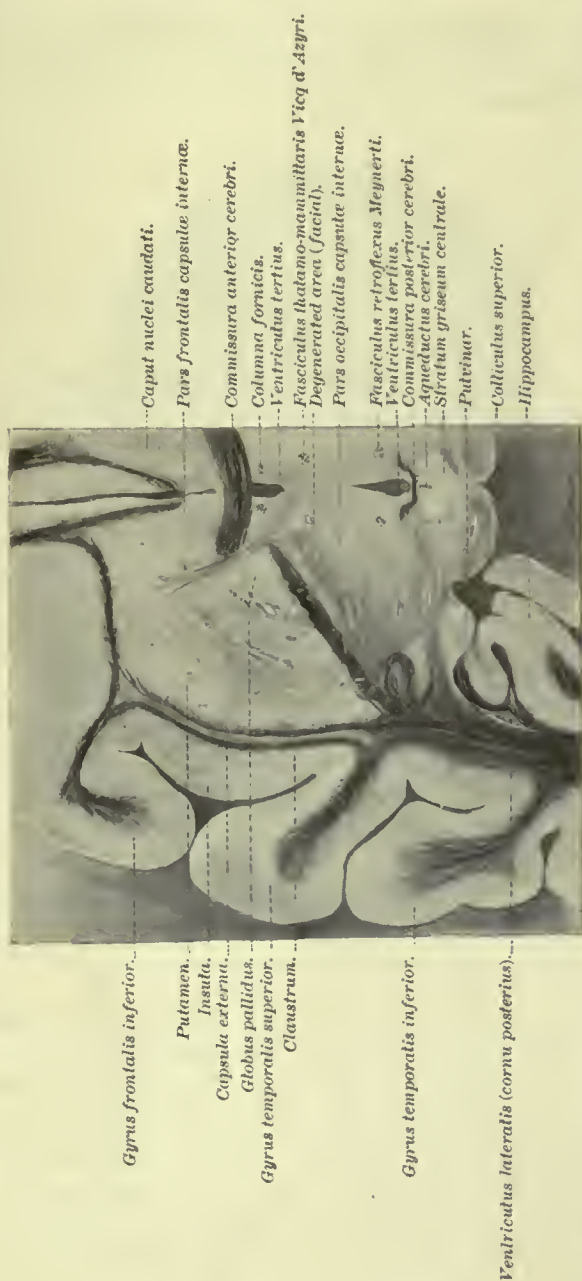


FIG. 631.—Horizontal section of monkey's brain, showing location of degeneration following lesion of the facial area. (Experiment and preparation by E. L. Mellus.)

asmuch as he worked principally with the cortical area corresponding to the motor representation for opening the mouth straight, his results after extirpation of this area may be briefly described. The association fibres from this area were carefully studied as well as

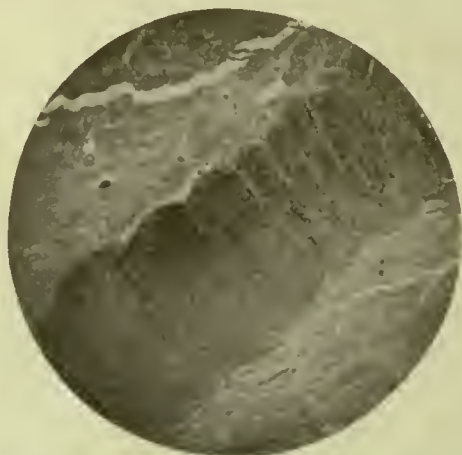


FIG. 652.—Degenerated area in Fig. 651, enlarged. (Photo-micrograph by E. L. Mellus.)

the projection fibres. As regards the latter, both fine and coarse fibres degenerated, the fine fibres terminating in the thalamus, the coarse (fibres of the pyramidal tract) extending through the anterior portion of the capsule (in its upper levels) and the middle third of the posterior limb of the capsule (in its lower levels) (Figs. 651 and 652) to enter the cerebral peduncle. In the cerebral peduncle the fibres are scattered evenly over the middle third of the area, as seen on cross section, encroaching a little upon the lateral third (Figs. 653 and 654). Some fibres leave the tract here to terminate in the substantia nigra or in the hypothalamic region.

Farther down the remaining degenerated fibres begin to leave the pyramidal tract at the junction of the pons and medulla oblongata, and single degenerated fibres could be followed to the nucleus nervi facialis of the same side and of the opposite side to the motor nuclei of the N. glossopharyngeus and N. vagus of both sides.

Mellus emphasizes the fact that all the degenerated pyramidal fibres from the hallux and thumb regions enter the internal capsule at or near its posterior extremity, while the corresponding fibres from the lesions in the facial area enter the capsule at or near its anterior extremity. The former fibres become displaced forward at lower levels, the latter backward, until in the lower levels of



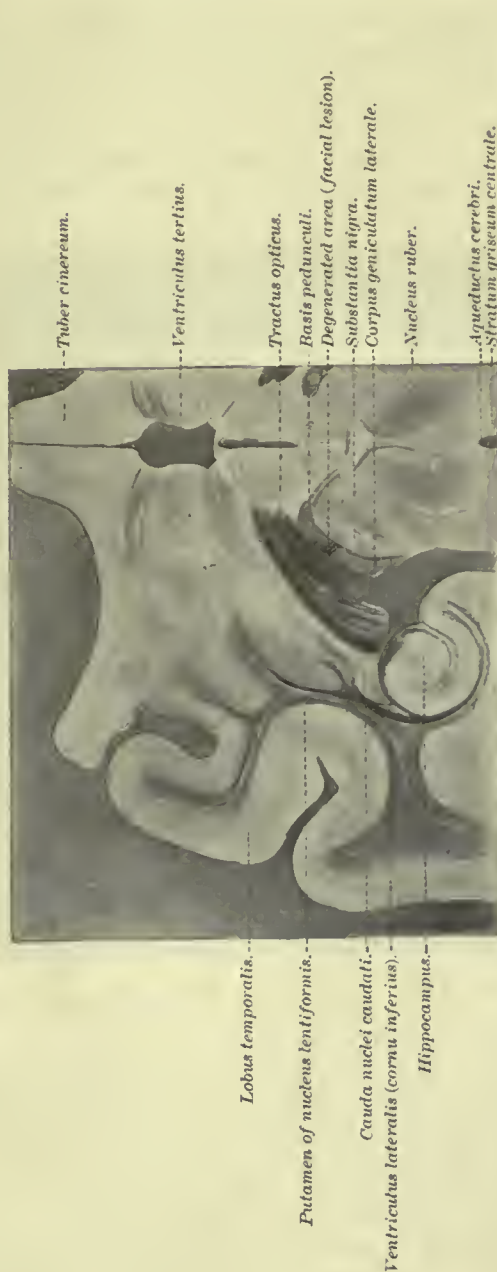

Fig. 653.—Horizontal section of monkey's brain through basis pedunculi, showing location of degeneration following excision of area marked *F* in Fig. 645. (Experiment and preparation by E. L. Mellus.)

the internal capsule the fibres are all crowded together at about the middle third of the posterior limb. "It is also shown that a line can be drawn from the fissure of Sylvius forward, so dividing the motor area into two parts—that of the facial lesions from which fibres enter the anterior portion of the capsule would be in the anterior division, and all the hallux and thumb lesions from which fibres enter the posterior portion of the capsule would be in the

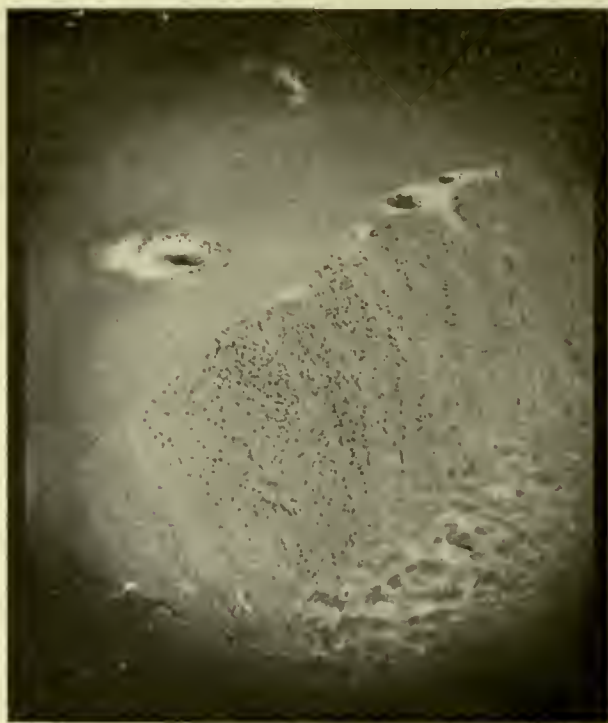


FIG. 654.—Degenerated area in Fig. 653, enlarged. (Photo-micrograph after Mellus.)

posterior division. In the movement of the facial fibres backward between the upper and lower levels of the capsule they would necessarily, at some level, envelop the genu, which would account for the fact that they have always been described as occupying that position." The striking agreement of the findings in these cases of experimental degeneration with those following upon electrical excitation will be clear if the two be compared with one another (*vide supra*). Mellus emphasizes the fact that in the base of the cerebral peduncle in the monkey the facial fibres are mixed up in

the middle third of the area, as seen on cross section, and do not occupy a space by themselves medial to the fibres of the pyramidal tract.

The significance of the uncrossed fibres of the pyramidal tract is somewhat difficult to understand. Now that we know that a certain number of fibres remain uncrossed even to their termination, and the proof has been brought that each cerebral hemisphere stands in connection with the groups of lower motor neurones on both sides of the rhombencephalon and spinal cord, it does not seem unlikely that in the uncrossed fibres we may find the anatomical explanation for the physiological peculiarities of the so-called bilaterally innervated movements. It is not impossible, too, that herein is to be sought the explanation of the curious behavior of the so-called residual paralyses after cerebral hemiplegia, which have been ably described by Wernicke and Mann, of Breslau. The cases of hemiplegia following homolateral lesion of the brain have also to be thought of in this connection, though it is not yet clear that the explanation of this unusual phenomenon is to be found here.

The light thrown upon the upper motor neurones by studies undertaken with the method of Golgi concerns mainly (1) the interrelations of the cell bodies and dendrites of these neurones with one another, and with those of other neurones in the cerebral cortex; (2) the collaterals given off by the axones of these neurones in various parts of their course; and (3) the terminal relations of these axones.

For the interneuronal relations in the cerebral cortex the reader is referred to the studies of Ramón y Cajal.\* His scheme is reproduced in Fig. 655.

The studies of Starr, Strong, and Leaning include investigations in this area. In Fig. 656 their scheme is shown.

As to the collaterals given off by the axones of the pyramidal tract a number arise in the first place while the axones are still in the cerebral cortex; others are given off shortly after their entrance into the corona radiata. In the pons, collaterals from the pyramidal tract are distributed to the nuclei pontis. In the gray matter in which the axones of the pyramidal tract terminate

---

\* Ramón y Cajal, S. Les nouvelles idées sur la structure du système nerveux chez l'homme et chez les vertébrés. Par. (Reinwald et Cie), (1894), pp. 39-69.

many collateral branches are given off; indeed it may be said that the axones become exhausted through the projection of numerous collaterals.

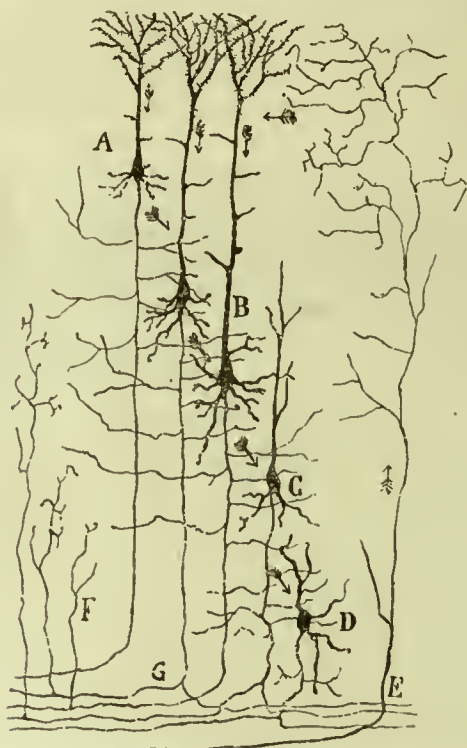

FIG. 655.—Scheme showing the probable course of impulses and the interneuronal connections in the cortex cerebri. (After S. Ramón y Cajal, *Les nouvelles idées*, etc., Azoulay, Paris, 1894, p. 66, Fig. 16.) *A*, small pyramidal cell; *B*, large pyramidal cell; *C*, *D*, polymorphous cells; *E*, terminal centripetal projection fibre; *F*, collaterals from the substantia alba; *G*, axone bifurcating in the substantia alba.

It is highly desirable that the exact terminal relations of the axones of the upper motor neurones be more thoroughly studied by means of the method of Golgi, for we find in the bibliography two diametrically opposite views with regard to the relations of the terminals of these axones of the cell bodies and dendrites of the lower motor neurones. Von Monakow\* believes that the

\* von Monakow, C. Experimentelle und pathologisch-anatomische Untersuchungen ueber die Haubenregion, den Sehhügel und die Regio subthalamica, nebst Beiträgen zur Kenntniss früh erworbener Gross- und Kleinhirndefecte. *Arch. f. Psychiat. u. Nervenkr.*, Berl., Bd. xxvii (1895), S. 1; 386.






FIG. 656.—Diagram of the cells of the cerebral cortex. (After Starr, Strong, and Leaming, *Atlas of Nerve Cells*, New York, 1896, p. 72, Fig. 10.) *I*, superficial layer; *a*, fusiform; *b*, triangular; *c*, polygonal cells of Ramón y Cajal; *II*, layer of small pyramids; *d*, smallest; *e*, small; *f*, medium-sized pyramidal cells with axones descending to the white matter and giving off collaterals in their course; *III*, layer of large pyramidal cells; *g*, largest (giant) pyramidal cells; *k*, large pyramidal cells with very numerous dendrites; all pyramidal cells are seen to send long apical dendrites up to *I*; *m*, Martinotti cell with descending dendrites and ascending axone; *n*, polygonal cells; *IV*, deep layer; *p*, fusiform cell; *q*, polygonal cell; *V*, the white matter containing the axones from the pyramidal cells *d*, *e*, *f*, *g*, and from a cell of the deep layer *q*; *r*, neuroglia fibres.

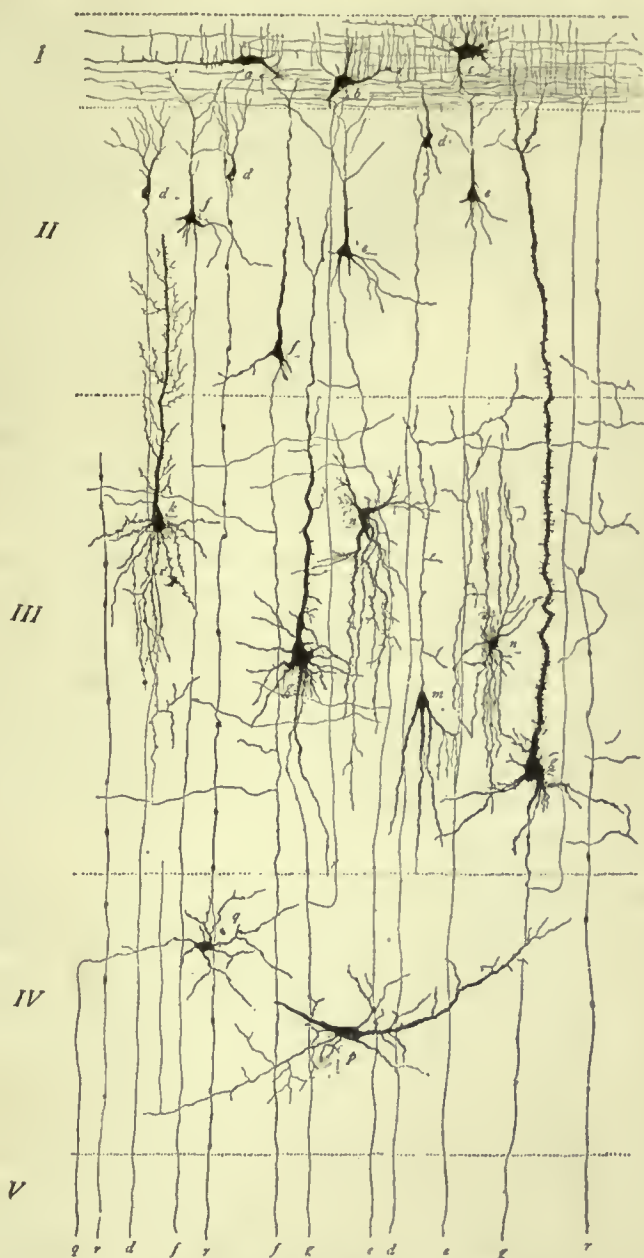


FIG. 656.

axones of the pyramidal tract in all probability do not enter into direct conduction relation with the lower motor neurones at all. He is of the opinion that in between the upper motor neurones and the peripheral motor neurones are intercalated dendraxones (Golgi cells of Type II, von Monakow's *Schaltzellen*). By means of these dendraxones the peripheral motor neurones are aggregated into groups, so that one or more pyramidal axones acting upon the dendraxone could set into activity all the motor neurones requisite to innervate the muscle fibres concerned in the production of a given movement. By means of this intercalation of dendraxones von Monakow would account for the production of so many different movements with so limited a number of fibres as the pyramidal tract contains. This highly ingenious view is not purely theoretical, for von Monakow states that in his extensive series of secondary degenerations of the pyramidal tract he finds that the degenerated fibres do not extend into the ventral horns of the spinal cord, inasmuch as the substantia gelatinosa does not atrophy and disappear there. On the other hand, there is with lesion of the pyramidal tract a disappearance of the substantia gelatinosa in the region of the processus reticulares near the lateral horn. Von Monakow, therefore, suggests that in this part of the gray matter are situated the dendraxones which receive the impulses directly from the fibres of the pyramidal tract, and which by means of their axones in turn distribute them to the dendrites and cell bodies of the lower motor neurones. This view of von Monakow has been supported with a good deal of vigor by Redlich.\*

On the other hand, von Kölliker assumes that, taking into consideration the number of collaterals given off by the terminals of the axones of the pyramidal tract, the total number of fibres coming into relation with the lower motor neurones is quite sufficient to account for the liberation of the impulses concerned in the various voluntary movements without the assumption of the existence of intercalated dendraxones. For the present it seems wise to leave the question open. A most favorable field for work with Golgi's method is here represented.

The whole conduction path from the cerebral cortex to the muscles, involving at least two sets of superimposed neurones, is

---

\* Redlich, E. Ueber die anatomischen Folgeerscheinungen ausge-  
dehnter Exstirpationen der motorischen Rindencentren bei der Katze.  
Neurol. Centralbl., Leipz., Bd. xvi (1897), S. 818-832.







in the effects of lesions involving on the one hand the lower motor neurones and on the other the upper motor neurones. Gowers described these as (1) lesions of the lower motor segment and (2) lesions of the upper motor segment.

If the lower motor neurones be seriously injured there results the so-called flaccid paralysis. The muscles undergo rapid atrophy, and exhibit the so-called electrical reaction of degeneration. On the application of the galvanic or the faradic current to the degenerated nerve there is no response. But when the muscle is stimulated, while there is no response to the faradic current, there is a response when the galvanic current is applied, which, however, is not that which normally occurs. Instead of being sharp and quick, the contraction is slow and lazy, and, in opposition to the rule in health, the anodal closure contraction may be greater than that on cathodal closure. Since the reflex arc is destroyed when the lower motor neurones are degenerated, the so-called deep reflexes are in such instances abolished and the muscular tension is diminished. The groups of muscles paralyzed give the clue to the localization of the lesion.

When the upper motor neurones—for example, those the axones of which correspond to the pyramidal tract—are degenerated there is also paralysis, but of an entirely different nature. Instead of the flaccid, markedly atrophic paralysis of the muscles with electrical reaction of degeneration, there occurs the so-called spastic paralysis, accompanied, as a rule, by no more atrophy in the muscles than that which would naturally follow disuse. The deep reflexes in such instances are of course exaggerated, and the tension of the muscle may be markedly increased. The distribution of the paralysis will of course be entirely different from that which occurs with lesions of the lower motor neurones, and the situation of the lesion may be ascertained by careful consideration not only of the nature and distribution of the paralysis, but by a consideration of the accompanying phenomena due to associated lesions in other nerve paths.\*

---

\* Cf. Section on Nervous Diseases in Osler, W. *Principles and Practice of Medicine*, 3d ed., New York (1898).—Gowers, W. R. *A Manual of Diseases of the Nervous System*. Philadelphia (1892).—Mills, C. K. *The Nervous System and its Diseases*. Philadelphia (1898).

## CHAPTER LXIII.

### INTERMEDIARY AND UPPER MOTOR NEURONES (CONTINUED).

The frontal cerebro-corticopontal path, or fasciculus pallio-frontalis, pars frontalis.

#### 3. Those the Axones of which Correspond to the Frontal Cerebro-Corticopontal Path.

THIS path, described by Flechsig as the *frontale Grosshirnrinde-Brückenbahn*, is assumed by him to arise in those regions of the cerebral cortex which correspond to the distribution of the system of sensory fibres which he designates as No. III; that is to say, the feet of the three frontal gyri, and possibly also the middle portion of the gyrus fornicatus (Fig. 659). The axones from the large pyramidal cells of this region of the somæsthetic area running in the centrifugal direction toward the internal capsule become medullated at a period somewhat later than the fibres of the pyramidal tract. The fibres pass through the pars frontalis of the capsula interna near the genu, pass through the base of the cerebral peduncle medial to the fibres of the pyramidal tract, and, according to Flechsig, terminate in the nuclei pontis. It is Flechsig's opinion that this frontal cerebro-corticopontal path is concerned with the movements of bilaterally innervated muscles, such as those of the eyes, neck, and trunk. The motor impulses concerned in the speech movements may also, he believes, be carried by fibres of this path. There is a good deal of evidence, however, that the speech path is separate and distinct from the frontal cerebro-corticopontal path. By means of neurones extending between the nuclei pontis and the cerebellum by way of the brachium pontis, the frontal cerebro-corticopontal path throws the cerebellum under the influence of the opposite cerebral hemisphere.

In the pars basilaris pontis the frontal cerebro-corticopontal path at first occupies the dorso-medial portion of the longitu-



dinal fibres, but in more caudal planes it turns ventralward, so that it comes to lie ventral and somewhat medial to the fibres

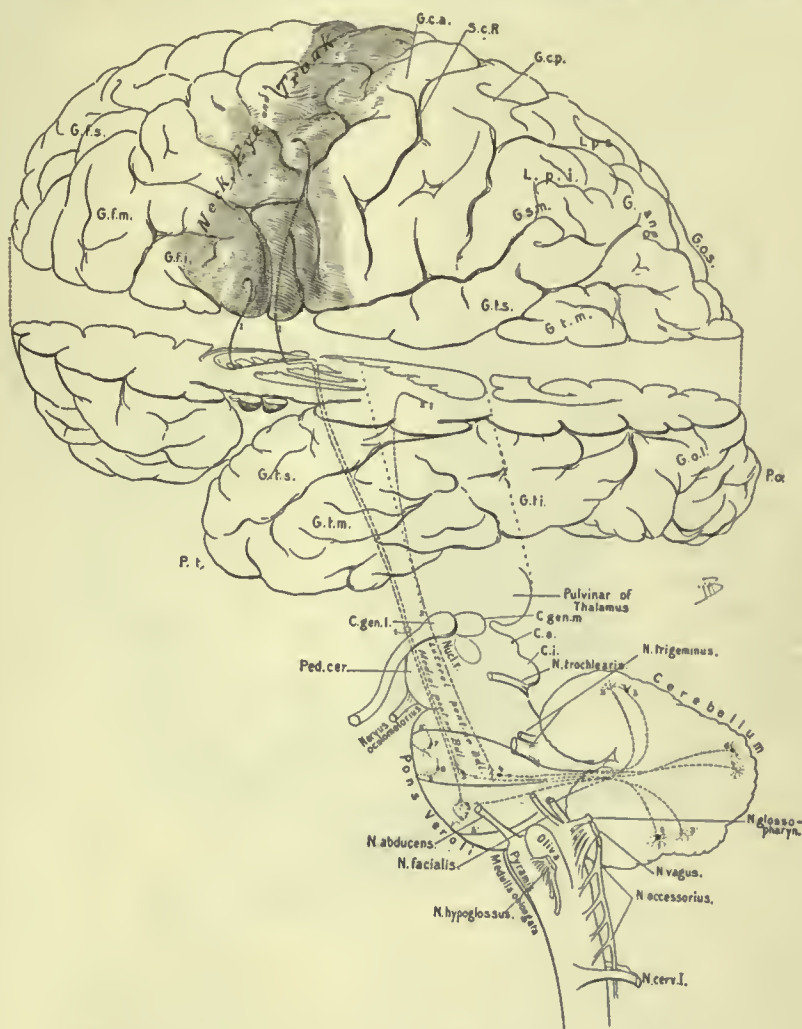


FIG. 659.—Scheme of frontal cerebro-corticopontal path. Lettering as in Plate II.

of the pyramidal tract (Fig. 660). This tract may degenerate after lesions of the middle and inferior frontal gyri, in which event the dorsal bundle of the anterior limb of the internal capsule undergoes secondary degeneration, and the frontal cere-

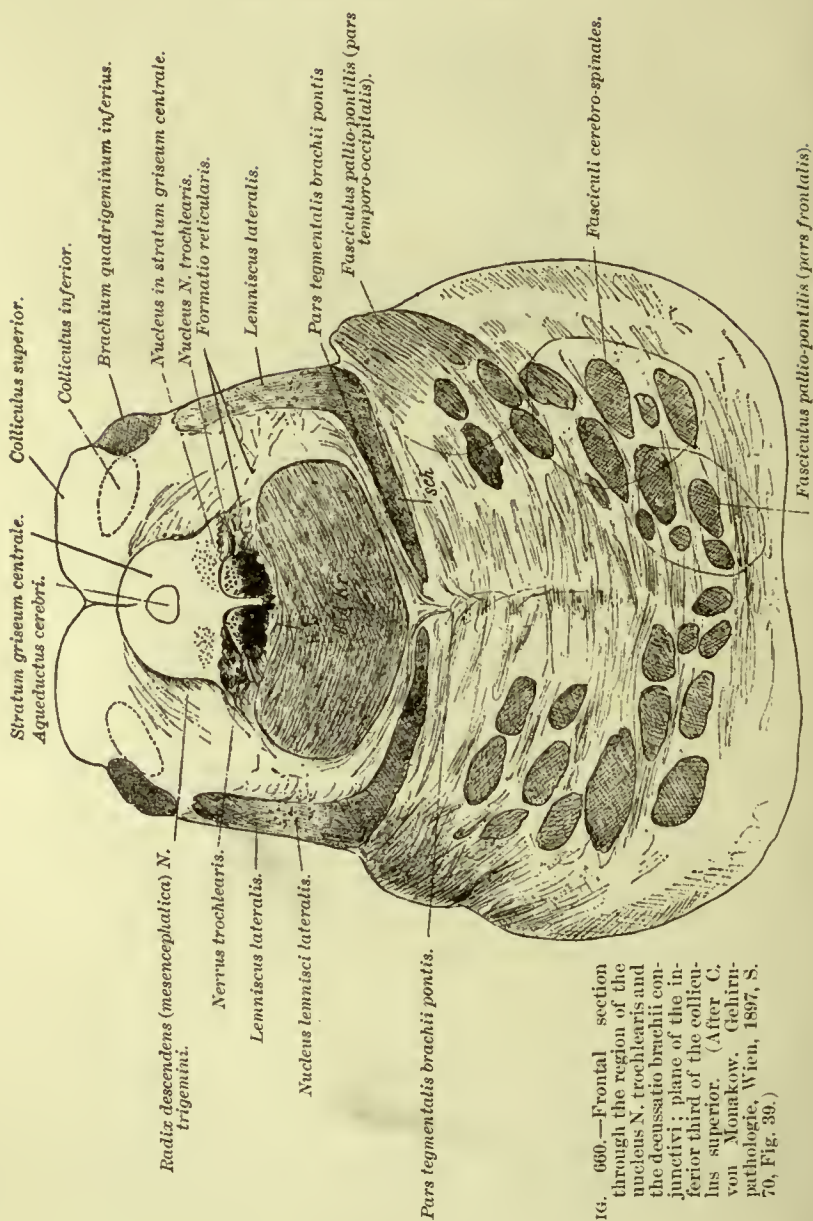


FIG. 660.—Frontal section through the region of the nucleus N. trochlearis and the decussatio brachii conjunctivi; plane of the inferior third of the colliculus superior. (After C. von Monakow. *Gehirn-pathologie*, Wien, 1897, S. 70, Fig. 39.)




FIG. 661.—Secondary degeneration following lesion in the left middle and inferior frontal gyri; the degenerated frontal cerebro-cortico-pontal path is shown. (After C. von Monakow, *Gehirnpathologie*, Wien, 1897, Figs. 186-189.) A. Transverse section at the level of the middle of the thalamus passing through the nucleus hypothalamicus (corpus Luysi); *ant*, nucleus anterior thalami; *ci*, capsula interna; *CL*, nucleus hypothalamicus (corpus Luysi); *gitt*, stratum reticulatum; *II.str.*, radiations from capsule of red nucleus (Hau- benstrahlung); *Li. lat*, nucleus lateralis thalami; *Li*, nucleus lentiformis; *Lisch*, ansa lenticularis; *med*, nucleus medialis thalami; *med.d*, degeneration in nucleus medialis thalami; *Ped.d*, degenerated frontal cerebro-cortico-pontal path; *Ped.(Pyr. bahu)*, fasciculi cerebro-spinales (pyramidales); *str*, nucleus caudatus; *vent.ant*, nucleus ventralis (anterior) thalami; *zi*, zona incerta; *BV*, fasciculus thalamo-mammillaris Vieq d'Azyri. B. Transverse section through the posterior extremity of the thalamus and the retrolenticular portion of the capsula interna; *BA*, brachium conjunctivum; *II.N*, tractus opticus; *Pyr*, fasciculi cerebro-spinales (pyramidales); *Ped*, pedunculus cerebri, pars basilaris; *RK*, nucleus ruber; *Thal*, thalamus; *vent*, ventral group of nuclei in the thalamus. C. Transverse section through the pons and junction of the colliculus superior with the colliculus inferior; *BA*, brachium conjunctivum; *BrA*, brachium pontis; *sch*, lemniscus. D. Transverse section through the uppermost part of the medulla oblongata; degeneration no longer demonstrable; *BrA*, brachium pontis; *III*, fasciculus longitudinalis medialis; *Ol*, nucleus olivaris inferior; *sch*, stratum interolivare lemnisci; *VII K*, nucleus N. abducentis; *VII*, radix N. facialis pars secunda; *VIII K*, nucleus N. facialis; *Pyr*, pyramids.



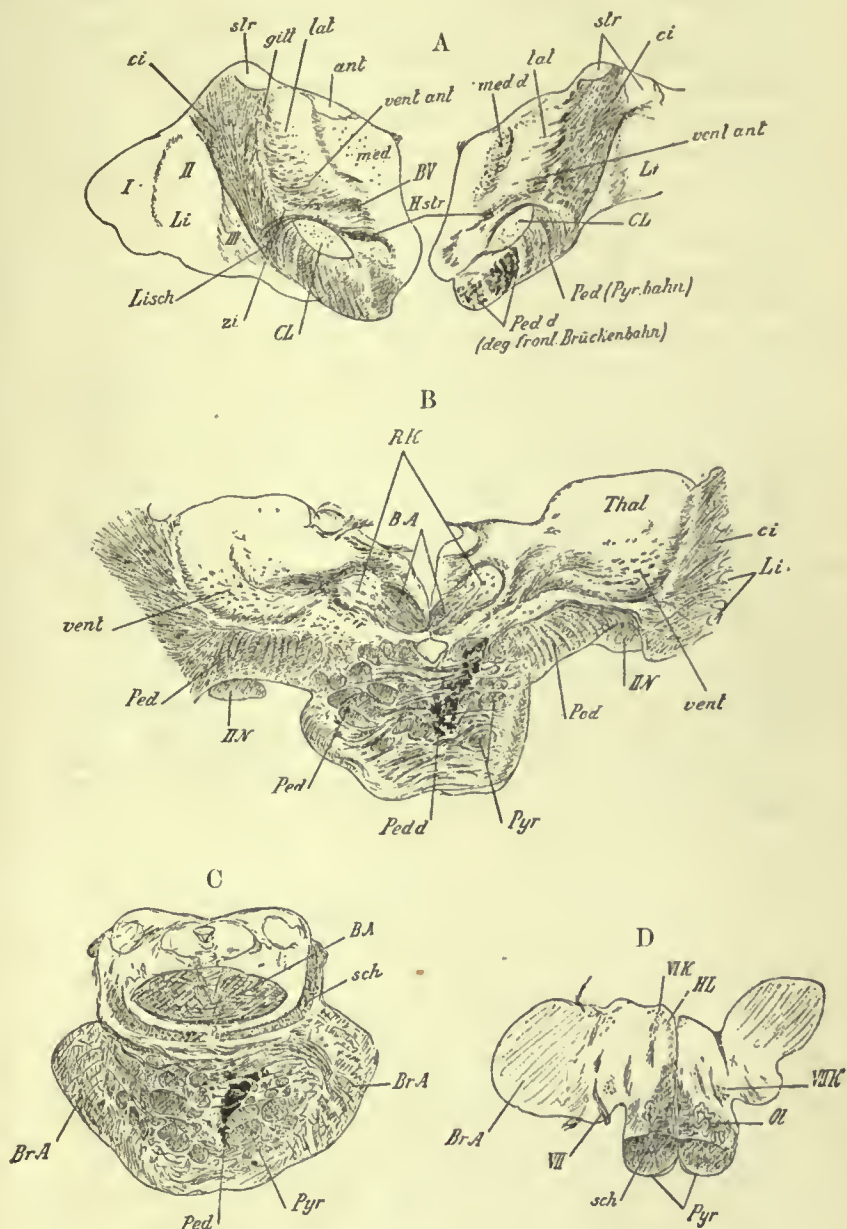


FIG. 661.

bro-corticopontal path can be followed into the most medial portion of the base of the cerebral peduncle. In such instances the radiation of the nucleus medialis thalami and a portion of that of the nucleus lateralis thalami atrophies, and after a time disappears (von Monakow). An example of degeneration of the frontal cerebro-corticopontal path is shown in Fig. 661. This bundle, especially in the base of the cerebral peduncle, has been called, though improperly, Arnold's bundle.

Zacher\* has recently denied any connection between the frontal lobe and the medial segment of the base of the cerebral peduncle. In his case, in which the medial bundle of the pes was degenerated, the anterior portion of the posterior limb of the internal capsule was entirely free from degeneration. He believes that the medial bundle of the pes has its origin in all probability from fibres which run in at the base of the nucleus lentiformis in its posterior part from the outside. These fibres, he believes, in part at least, have their origin in the island of Reil. Dejerine attributes the origin of the fibres to the Rolandic operculum and adjacent part of the frontal operculum. One of Spiller's† cases would indicate that at least a portion of the bundle has an origin anterior to the Rolandic operculum.

---

\* Zacher, T. Beiträge zur Kenntniss des Faserverlaufes im Pes pedunculi sowie ueber die corticealen Beziehungen des Corpus geniculatum internum. Arch. f. Psychiat. u. Nervenkr., Berl., Bd. xxii (1890-'91), S. 654-698.

† Spiller, W. G. A Contribution to the Study of Secondary Degeneration following Cerebral Lesions. Trans. Am. Neurol. Assoc., 1897, New York (1898), pp. 210-228.

## CHAPTER LXIV.

### INTERMEDIARY AND UPPER MOTOR NEURONES (CONTINUED).

The temporal cerebro-corticopontal path—Paths from the lobus occipitalis to the corpora quadrigemina—Olfactory reflex paths.

#### 4. Those the Axones of which Correspond to the Temporal Cerebro-Corticopontal Path.

THESE are the neurones the medullated axones of which occupy the most lateral segment of the base of the cerebral peduncle designated by Flechsig as the *temporale Grosshirnrinde-Brückenbahn*. The bundle is usually called Türrck's bundle, quite improperly it would seem, since the bundle concerned is separated by a wide area from the region found diseased by Türrck in hemianæsthesia.\* Flechsig believes that the cell bodies and dendrites which give origin to the axones of this path are situated in the auditory sense area of the cerebral cortex (gyrus temporalis superior et gyri temporales transversi). The axones, he believes, pass down through the posterior portion (retro-lentiform portion) of the pars occipitalis capsulæ internæ to the lateral region of the base of the cerebral peduncle. Thence they go into the pons and end there in some way unknown to Flechsig, perhaps, he suggests, going over directly into transverse fibres of the pons or ending in the nuclei pontis. He is inclined to think that, like the frontal cerebro-corticopontal path, this temporal path represents a mode of connection by way of the brachium pontis of one cerebral hemisphere with the opposite cerebellar hemisphere. The fibres are medullated at a later period than the fibres of the pyramidal tract.

Von Monakow describes the temporal cerebro-corticopontal path as occupying, in the cerebral extremity of the pons, a dorso-lateral field, which it follows until it becomes exhausted in the gray matter at the caudal extremity of the pons, except that from

---

\* *Op. cit.*

the middle of the pons on it is located exactly dorsal to the fibres of the pyramidal tract. The fibres of this bundle, like all the other fasciculi longitudinales of the pars basilaris pontis, are separated from one another by fibræ transversæ pontis and by the masses of gray matter which make up the nuclei pontis.

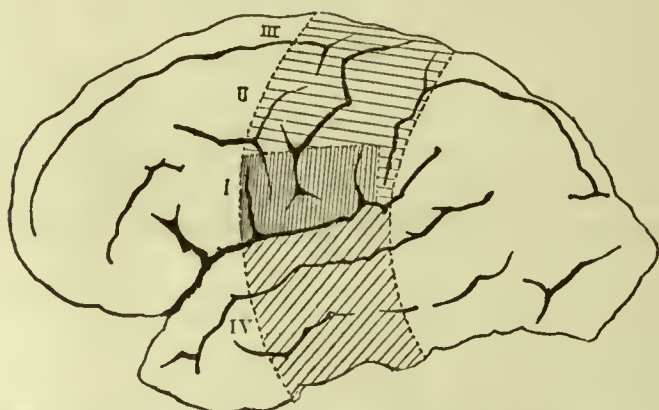


FIG. 662.—Zone of the cerebral cortex, lesion of which causes degeneration of all the fibres of the basis pedunculi. (After J. Dejerine, from A. van Gehuchten's text-book.) *I*, cortical centre for the lower facial and the hypoglossus; *II*, cortical centre for the upper extremity; *III*, cortical centre for the lower extremity; *IV*, cortical centre for the lateral bundle of the basis pedunculi.

The fibres of the temporal cerebro-corticopontal path degenerate in a descending direction (Zacher, Kam, von Monakow, and Dejerine). According to Dejerine,\* the bundle arises from the whole temporal lobe, but by no means solely from the gyrus temporalis superior. Indeed, he favors the view that the fibres arise mainly in the G. temporalis medius and the G. temporalis inferior. Moreover, Dejerine asserts that the fibres on their way from the temporal lobe to the base of the cerebral peduncle do not pass through the capsula interna at all, but instead go below the nucleus lentiformis to join the other fibres which enter the cerebral peduncle in the hypothalamic region. In Fig. 662 is reproduced a diagram in which is shown the cortical zone, which, when destroyed (according to Dejerine), will lead to complete degeneration of all the fibres of the basis pedunculi.

In this connection a case of the highest importance has

\* Dejerine, J. Sur l'origine corticale et le trajet intracérébral des fibres de l'étage inférieur ou pied du pédoncule cérébral. *Compt. rend. Soc. de biol., Par.*, 9. s., t. v (1893), pt. 2, pp. 193-206.



recently been carefully studied by Mills and Spiller.\* This case makes it difficult to understand the view of Flechsig, for it seems hard to conceive how in such a case, where there was no degeneration in the lateral bundle of the base of the cerebral peduncle, the fibres which form this bundle could have their origin in the gyrus temporalis superior (Flechsig). It seems strange that the origin and distribution of the axones of the lateral bundle of the pes have not been approached from the experimental side. It is not too much to hope that we shall soon have data to record in this connection. Ferrier and Turner have extirpated the gyrus temporalis superior and have obtained secondary degeneration in the lateral bundle of the pes, thus supporting the doctrine of Flechsig, though their studies support Dejerine in part, in that they find that the fibres pass lateral and ventral to the nucleus lentiformis.

5. Those the Axones of which Connect the Lobus Occipitalis with the Nuclei Governing the Movements of the Eyes.

Flechsig, in his descriptions of the lateral bundle of the base of the cerebral peduncle, thinks it probable that a certain number of the fibres of this bundle may arise in the visual sense area of the occipital lobe. His views are supported by the embryological studies of von Bechterew.† That there are neurones extending between the visual sense area in the occipital cortex and the eye-muscle nuclei, or at least the superior colliculus of the corpora quadrigemina, seems extremely probable from the studies of secondary degeneration after animal experiment carried out by von Monakow and the studies of anophthalmia conducted by his students. Excitation of the cortex of the occipital lobe, as Munk, Schaefer, Horsley, and others have shown, is followed by movements of the eyes. The results of these researches render

\* Mills, C. K., and W. G. Spiller. A Case of Cerebral Abscess Situated at the Posterior Part of the External Capsule (involving the Medullary Substance of the First Temporal Convolution, also the Posterior Part of the Lenticular Nucleus, and extending into the Subthalamie Region), with Some Considerations in Regard to the Constitution of the External Bundles of Fibres in the Cerebral Peduncle. *Med. and Surg. Reporter*, Phila., vol. lxxiv (1896), p. 742; also in the *J. Nerv. and Ment. Dis.*, N. Y., vol. xxiii (1896), pp. 622-628.

† von Bechterew, W. Zur Frage ueber die secundären Degenerationen des Hirnschenkels. *Arch. f. Psychiat. u. Nervenkr.*, Berl., Bd. xix (1887), S. 1-17.

it probable that the giant pyramidal cells of the third cortical layer send their axones through the radiatio occipito-thalamica Gratioleti and the brachium quadrigeminum superius to the colliculus superior of the corpora quadrigemina and the stratum griseum centrale aqueductus cerebri. Whether or not any of these axones actually reach the nucleus nervi oculo-motorii and the other eye-muscle nuclei directly is not known; it may be that another neurone is interposed between the terminals of the occipito-mesencephalic neurone and the lower motor neurones. Indeed, this is the view which von Monakow is inclined to support, and it is quite in accord with the prevailing ideas with regard to the superior colliculus, which is generally looked upon as the central organ for the government of the eye-muscle nuclei. That the fibres from the occipital cortex to the mesencephalon do actually pass through the lateral segment of the cerebral peduncle is made very probable by the studies of Zacher.\* He believes that the fibres from the occipital lobe are most laterally placed, those from the temporal lobe being situated between these and the fibres of the pyramidal tract. The cases of Sioli † and Winkler ‡ make it not impossible that some fibres from the lobus parietalis also pass through the lateral segment of the base of the cerebral peduncle.

#### 6. Those the Axones of which Connect the Rhinencephalon with the Lower Motor Neurones.

These have already been dealt with in connection with the olfactory sensory neurones of the second and higher orders, to which the reader is referred.

---

\* Zacher, T. Beiträge zur Kenntniss des Faserverlaufes im Pes pedunculi sowie ueber die corticalen Beziehungen des Corpus geniculatum internum. *Arch. f. Psychiat. u. Nervenkr.*, Berl., Bd. xxii (1890-'91), S. 654-698.

† Sioli. Ueber die Fasersysteme im Fuss des Grosshirnschenkels und Degeneration derselben. *Centralbl. f. Nervenhe.*, Leipz., Bd. xi (1888), S. 438-441; also in *Breslau aerztl. Ztsch.*, Bd. x (1888), S. 181.

‡ Winkler, C. Secundaire neerdalende degeneratie van den meest lateraal gelegen bundel in den pars pedunculi cerebri (Den bundel van Türek). *Nederl. Tijdschr. v. Geneesk.*, Amst., 2. R., xxii (1886), pp. 585-591. Also see *Neurol. Centralbl.* (1887), S. 239.

## SUBSECTION V.

### Projection Neurones, Commissural Neurones, and Association Neurones of the Telencephalon.

It seems desirable to refer briefly to the main telencephalic neurones by themselves. It is customary to divide the fibres in the telencephalon into projection fibres, commissural fibres, and association fibres. The complexity of the fibres of different sorts in the gray matter of the cerebral cortex is well illustrated in Fig. 663. Now that we know that no white fibres exist which have not their origin in cell bodies—that is to say, which are not the axones of neurones—it seems more logical to speak of projection neurones, commissural neurones, and association neurones.

---

#### (A) Projection Neurones.

#### CHAPTER LXV.

##### PROJECTION NEURONES OF THE TELECEPHALON.

Groups of projection neurones—Cerebral appanages or dependencies—  
Phylogenetically young parts of the brain.

By these are understood the neurones which connect directly the cortex of the telencephalon (pallium and rhinencephalon) with lower portions of the nervous system. The medullated axones may pass in either direction—from the cortex to lower centres, or from lower centres to the cortex. In the former instance the cell bodies of the neurones are situated in the cortex, and the axones descend—that is to say, the conduction is corticofugal. In the latter instance the cell bodies of the neurones are situated in the lower centres, and the axones ascend to terminate in the cerebral cortex. The latter are corticopetal in conduction.

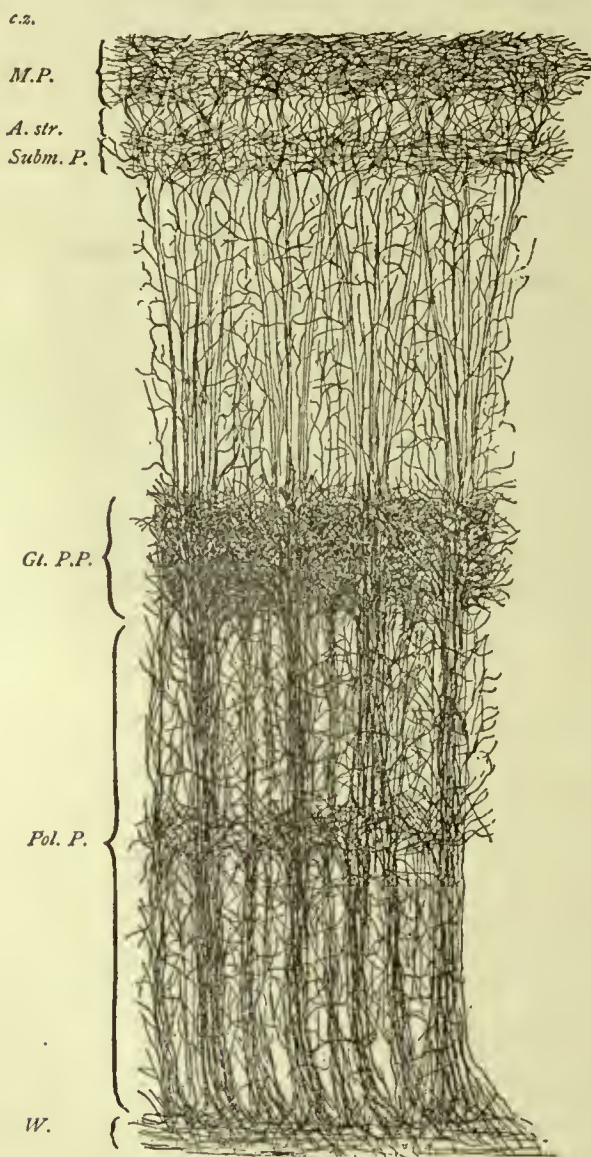


FIG. 663.—Cortex of human brain illustrating the systems and plexuses of nerve fibres (combination of the methods of Weigert and Golgi). (After L. Andriezen, *Brain*, Lond., vol. xvii, 1894.) *c.z.*, clear zone free from nerve fibres; *M.P.*, Exner's plexus in the molecular layer; *A.str.*, ambiguous cell stratum; *Subm.P.*, submolecular plexus; *Gl.P.P.*, great pyramidal plexus; *Pol.P.*, polymorphic plexus; *W.*, white matter.



The majority of these neurones have already been described in connection with (1) the sensory neurones of the higher order and (2) the upper motor neurones. Thus (*a*) the diencephalo-telencephalic neurones of the general sensory path, (*b*) the radiatio occipito-thalamica Gratioleti of the visual conduction path, and (*c*) the radiatio corporis geniculati medialis of the auditory conduction path represent corticopetal projection neurones. Again, the fibres of (*a*) the pyramidal tract, (*b*) the frontal cere-

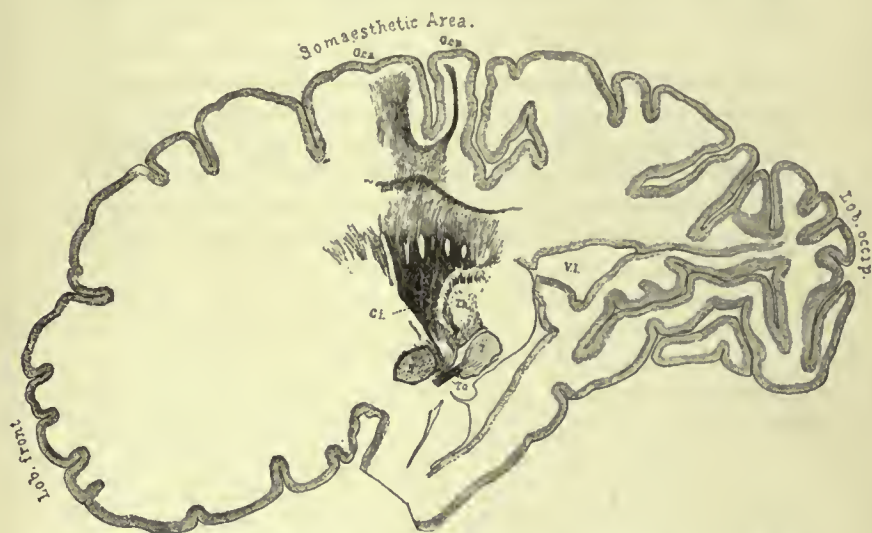

FIG. 664.—Sagittal section No. 148, through the brain of a babe shortly after birth, illustrating the projection fibres to the somæsthetic area. *Cl.*, capsula interna; *G.c.a.*, gyrus centralis anterior; *G.c.p.*, gyrus centralis posterior; *Lob. front.*, lobus frontalis; *Lob. occip.*, lobus occipitalis; *Th.*, thalamus; *T.o.*, tractus opticus; 5, nucleus lentiformis; 7, corpus geniculatum laterale; *V.L.*, ventriculus lateralis.

bro-corticopontal path, (*c*) the temporal cerebro-corticopontal path, and (*d*) the fibres running from the occipital lobe to the mesencephalon represent the axones of corticofugal projection neurones. The ease with which these projection axones can be followed in the medullating brain is well illustrated in Fig. 664.

If an area of the cerebral cortex be extirpated, especially in the young animal, the axones of projection neurones, whether they be corticopetal or corticofugal, undergo a change. In the case of the corticofugal axones secondary degeneration with absorption rapidly takes place; in the case of the corticopetal axones

there is less rapid degeneration or atrophy, which can be traced to their infracortical origin. These infracortical areas in which the corticopetal telencephalic projection fibres originate, and which, like the fibres themselves, undergo atrophy or degeneration after extirpation of the area of the cortex in which they terminate, are known as "cerebral appanages" or "dependencies." Von Monakow has recently paid a good deal of attention to these areas, and has described them under the term *Grosshirnantheile*. He believes that they are phylogenetically young, for they are absent in lower forms, and increase progressively in size and number in direct proportion to the development of the cerebrum. According to his view, the majority of the nuclei of the thalamus and geniculate bodies, the substantia nigra, and portions of the corpora quadrigemina and of the pons belong to this category. The various cerebral dependencies are of different age, as far as can be judged from phylogenetic studies, the olfactory organ, the visual sense, and hearing having been successively developed.

(B) Commissural Neurones.

CHAPTER LXVI.

COMMISSURAL NEURONES OF THE TELEENCEPHALON.

Heteromeric telencephalic neurones—Hecateromeric neurones—Corpus callosum—Commissura anterior cerebri—Commissura hippocampi.

By these are meant neurones with cell bodies situated in one hemisphere of the telencephalon, while their axones are distributed in the cortex of the opposite hemisphere. They might, therefore, well be designated the intrinsic heteromeric telencephalic neurones. Studies by Golgi's method go to show that some of the axones bifurcate, one of the limbs of bifurcation passing into the opposite hemisphere, the other being distributed in the hemisphere of the same side. Such neurones might well be called intrinsic hecateromeric telencephalic neurones.

The main groups of neurones here to be considered are (1) those with axones corresponding to the medullated white fibres of the corpus callosum, (2) those with axones corresponding to the fibres of the commissura anterior cerebri, and (3) those with axones corresponding to the commissura hippocampi.

1. Those the Medullated Axones of which correspond to the Fibres of the Corpus Callosum.

The fibres of the corpus callosum represent the axones of the majority of the intrinsic commissural neurones of the telencephalon, and it has been well designated the *commissura maxima*. The main body of this is known as the *truncus corporis callosi*. The anterior border of the *truncus* bends sharply downward to form the *genu corporis callosi*. As a result of the curvature there arises a ventral horizontal piece of the corpus callosum, about two centimetres in length, which, on median section, looks wedge-shaped. This is the so-called *rostrum corporis callosi*.

Its thin, medullated, leaflike extremity, extending backward to the lamina terminalis, is known as the lamina rostralis. At its posterior border the truncus goes over into the much-thickened splenium corporis callosi.

The axones of which the corpus callosum is formed pass in both directions, some going to and some going from each of the cerebral hemispheres. These converging and diverging fibres form what is known as the radiatio corporis callosi; that portion of it corresponding to the lobus frontalis is known as the pars frontalis of the radiation. In the same way there is a pars parietalis,

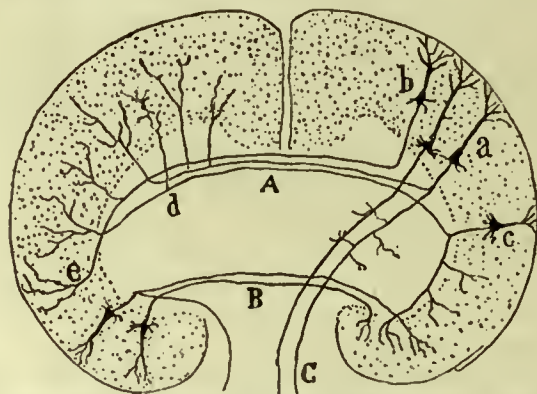


FIG. 665.—Scheme of a transverse section through the brain showing the probable disposition of the commissural and projection fibres. (After S. Ramón y Cajal, *Les nouvelles idées*, etc., Azoulay, Paris, 1894, p. 60, Fig. 15.) *A*, corpus callosum; *B*, commissura anterior cerebri; *C*, fasciculi cerebro-spinales (pyramidales); *a*, pyramidal cells giving rise to axones of pyramidal tract; one sending a limb of bifurcation through the corpus callosum to the opposite hemisphere; *b*, pyramidal cell sending axone through corpus callosum; *c*, pyramidal cell with an axone which bifurcates; one going through the corpus callosum to the opposite hemisphere, the other being distributed to the cortex of the hemisphere of the same side; *d*, collaterals from callosal fibres; *e*, terminals of callosal fibres.

a pars temporalis, and a pars occipitalis. The tapetum is also considered by many to form a portion of the radiation of the corpus callosum, although, as has been seen above, recent investigations are in opposition to this view.

The cell bodies which give rise to the axones of the corpus callosum are, Ramón y Cajal believes, those of the small or medium-sized pyramidal cells, or the polymorphous cells of the cerebral cortex. It may be that some of the axones helping to form the corpus callosum are collaterals from the axones of long association neurones, or even of the axones of projection neurones (Fig. 665).



Studies of secondary degeneration indicate that through the corpus callosum the activities of a given centre in the cerebral cortex of one side are associated with the activities of a precisely similarly located cortical area in the opposite cerebral hemisphere. Hamilton\* is of the opinion that the fibres of the corpus callosum after passing into the opposite hemisphere do not go out to the cortex of that hemisphere, but pass directly downward into the internal capsule and parts below. He believes, however, that the cell bodies of these axones are situated below, and that the fibres pass up through the internal capsule and then through the corpus callosum into the opposite hemisphere. Thus impulses would pass along them from the lower centres to the higher, which are of significance in educating the motor cortex—that is, serve as a means of conveying impulses to arouse the motor area of the brain. This view has not as yet received the general support of neurologists, and the extirpation experiments of Mellus, Muratow, and others do not tend to confirm it. Ferrier and Turner, however, in a recent article seem to support, in part at least, the hypothesis of Hamilton.

**2. Those the Medullated Axones of which correspond to the Commissura Anterior Cerebri.**

This bundle of medullated axones is situated just in front of the columnæ fornicis as they plunge into the tuber cinereum. It is in reality situated in the region of the diencephalon, but the cell bodies, which give rise to the axones which constitute it, are situated in the telencephalon, partly in the rhinencephalon, partly in the pallium.

The anterior commissure can be divided into two parts—(1) a pars anterior and (2) a pars posterior (Fig. 666). The pars anterior belongs apparently wholly, or almost wholly, to the rhinencephalon connecting the olfactory cortex of one side with that of the other side. It is much larger in many animals, especially in macrosmatic mammals, than in man. The pars anterior atrophies *in toto* after extirpation of the bulbous olfactorius on one side (Ganser), or after extirpation of the lobus olfactorius of one side (A. Meyer).

---

\* Hamilton, D. J. On the Corpus Callosum in the Adult Human Brain. *J. Anat. and Physiol.*, Lond., vol. xix (1884-'85), pp. 385-414.—On the Structure and Functional Significance of the Human Corpus Callosum. [Summary], *Proc. Roy. Soc.*, Lond., vol. xxxvi (1883-'84), p. 349.

The pars posterior of the anterior commissure is believed to associate the activities of a portion of the temporal and of the



FIG. 666.—Scheme of the commissura anterior cerebri; *p.t.*, pars posterior; *p.a.*, pars anterior. (After A. Rauber, *Lehrbuch der Anatomie des Menschen*, V. Aufl., Bd. ii, Leipz., 1898, S. 388, Fig. 336.)

basal part of the occipital lobe of one side with those of similar cortical areas on the opposite side. In developmental stages of the organism the pars posterior of the anterior commissure stands in intimate relation

to the ventral portion of the splenium corporis callosi, and is really morphologically widely separated from the pars anterior.

The view is prevalent that the commissura anterior cerebri is a supplement to the corpus callosum, its axones originating and terminating in areas of the cortex unprovided for by that body. The comparative anatomy of the structure has been studied by Osborn,\* C. J. and C. L. Herrick,† Edinger,‡ Smith,§ Symington,|| and by Adolf Meyer.△

\* Osborn, H. F. The Origin of the Corpus Callosum, a Contribution upon the Cerebral Commissures of the Vertebrata. *Morphol. Jahrb.*, Leipz., Bd. xii (1886-'87), S. 223; 530.

† Herrick, C. J. The Cerebrum and Olfactories of the Opossum *Didelphys Virginiana*. *J. Comp. Neurol.*, Cincinnati, vol. ii (1892), pp. 1-20.—The Commissures and Histology of the Teleost Brain. *Anat. Anz.*, Jena, Bd. vii (1891), S. 676-681.—Additional Notes on the Teleost Brain. *Anat. Anz.*, Bd. vii (1892), S. 422-431.—The Callosum and Hippocampal Region in Marsupial and Lower Brains. *J. Comp. Neurol.*, Granville, vol. iii (1893), pp. 171-182.—Also C. L. and C. J. Herrick. Contributions to the Morphology of the Brain of Bony Fishes. *J. Comp. Neurol.*, vol. i (1891), p. 211; 333; and vol. ii (1892), pp. 21-72.

‡ Edinger, L. Vergleichend-Entwicklungsgeschichtliche und anatomische Studien im Bereich der Hirnanatomie. *Anat. Anz.*, Jena, Bd. viii (1893), S. 305-321.

§ Smith, G. E. Notes upon the Morphology of the Cerebrum and its Commissures in the Vertebrate Series. *Anat. Anz.*, Jena, Bd. xi (1895), S. 91-96.—Morphology of the True Limbic Lobe, Corpus Callosum, Septum Pellucidum, and Fornix. *J. Anat. and Physiol.*, Lond., vol. xxx (1895-'96), pp. 157; 185; 450.

|| Symington, J. The Cerebral Commissures in the Marsupialia and Monotremata. *J. Anat. and Physiol.*, Lond., vol. xxvii (1892-'93), pp. 69-84.

△ Meyer, Adolf. Ueber das Vorderhirn einiger Reptilien. *Inaug. Diss.*, Leipz. (1892), S. 1-73.—Zur Homologie der Fornix commissur und des Septum lucidum bei den Reptilien und Säugern. *Anat. Anz.*, Jena, Bd. x (1894-'95), S. 474-482.

3. Those the Medullated Axones of which correspond to the Fibres of the  
Commissura Hippocampi.

This in man and mammals consists of a bundle of medullated axones extending between the crura fornicis of the two sides and connecting the hippocampi with one another. Fibres run in both directions, forming apparently a true commissure, the so-called psalterium or lyre of David. It can be divided into two parts, one more dorsally, the other more ventrally located. This is especially true of the commissura hippocampi of animals. The axones probably have their origin in the pyramidal cells of the hippocampus.

(C) Association Neurones of the Telencephalon.

CHAPTER LXVII.

ASSOCIATION NEURONES OF THE TELENCEPHALON.

Tautomeric telencephalic neurones—Fibræ propriæ—Stratum calcarinum—Fasciculus occipitalis perpendicularis—Fasciculus occipitalis transversus cunei—Fasciculus occipitalis transversus gyri lingualis—Stratum proprium cunei—The eingulum—The fasciculus longitudinalis superior—The fasciculus uncinatus—Association bundles of the fornix—The tapetum.

THESE might well be called the intrinsic tautomeric telencephalic neurones. By them is to be understood neurones which connect a portion of one hemisphere with another portion of the same. These association neurones may be divided into (1) those with short axones and (2) those with long axones.

The association neurones with short axones include the fibræ propriæ of the cerebral gyri.\* Some of them are medullated very late. In many of the convolutions almost all the white fibres present consist of these short axones. The shortest axones are most superficial; the longer ones pass deeper into the white matter. They vary in direction corresponding to the position and curves of the different gyri. They are evidently for the purpose of co-ordinating the functions of neighboring gyri.

Ramón y Cajal believes that the axones of the association neurones arise from the polymorphous cells of the smaller and larger pyramidal cells of the cerebral cortex. They give off numerous collaterals so that the excitation of one of these neurones can lead to alterations in the neural activity of many other neurones situated in various parts of the cerebral cortex. A

---

\* These are the neurones the axones of which were described as fibræ arcuatæ by Arnold and as U-shaped fibres by Meynert. They include also the external layer of tangential fibres, the so-called stripe of Gennari, and the super-radial plexus of Edinger in the external zone of the cortex as well as the interradianal plexus situated in the deeper portion of the cortex.



schematic representation of Ramón y Cajal's views concerning the association neurones is reproduced in Fig. 667.

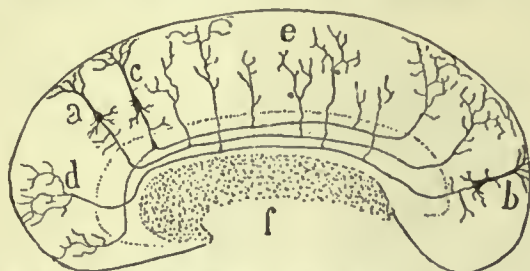


FIG. 667.—Scheme of an antero-posterior section through the cerebrum showing the disposition of the axones of association neurones which connect the lobus frontalis with the lobus occipitalis. (After S. Ramón y Cajal, *Les nouvelles idées*, etc., Azoulay, Paris, 1894, p. 59, Fig. 4.) *a, b, c*, pyramidal cells; *d*, terminal of an axone; *e*, collaterals of association axones; *f*, fibres of corpus callosum cut transversely.

#### 1. Those with Short Axones.

The short association neurones have been most carefully described, especially in the occipital and frontal lobes, by Wernicke,\* Sachs,† Viallet,‡ and Dejerine.\*

Among these may be mentioned for the occipital lobe :

(1) The *stratum calcarinum* (Fig. 668), uniting the superior lip of the calcarine fissure to its inferior lip by its shorter fibres, and the medial surface of the cuneus to the inferior and medial surface of the gyrus lingualis by its longer fibres.

(2) The *fasciculus occipitalis verticalis*, or *perpendicularis*, of Wernicke,|| uniting the superior border of the occipital lobe to its inferior surface. As a matter of fact, it connects the gyri occipitales superiores with the gyri occipitales laterales and the

\* Wernicke, C. *Lehrbuch der Gehirnkrankheiten für Aerzte und Studierende*. Kassel u. Berlin (1881-'83).

† Sachs, H. *Das Hemisphärenmark des menschlichen Grosshirns*. I. *Der Hinterhauptlappen*. Leipz. (1892), p. 31, 4to.—*Vorträge ueber Bau und Thätigkeit des Grosshirns und die Lehre von der Aphasie und Seelenblindheit für Aerzte und Studierende*. Breslau, p. 296, 8vo (1893).

‡ Viallet, N. *Les centres cérébraux de la vision et l'appareil nerveux visuel intra-cérébral*. Par. (1893).—*Note sur l'existence à la partie inférieure du lobe occipital d'un faisceau d'association distinct, le faisceau transversale, du lobule lingual*. *Compt. rend. Soc. de biol., Par.*, 9. s., t. v (1893), pp. 793–795.

\* Dejerine, J. *Anatomie des centres nerveux*. Par. (1895), pp. 742–786.

|| *Stratum proprium convexitatis* of Sachs.

gyrus fusiformis. Anteriorly it extends between the gyrus angularis and the gyrus temporalis medius and the gyrus temporalis inferior.

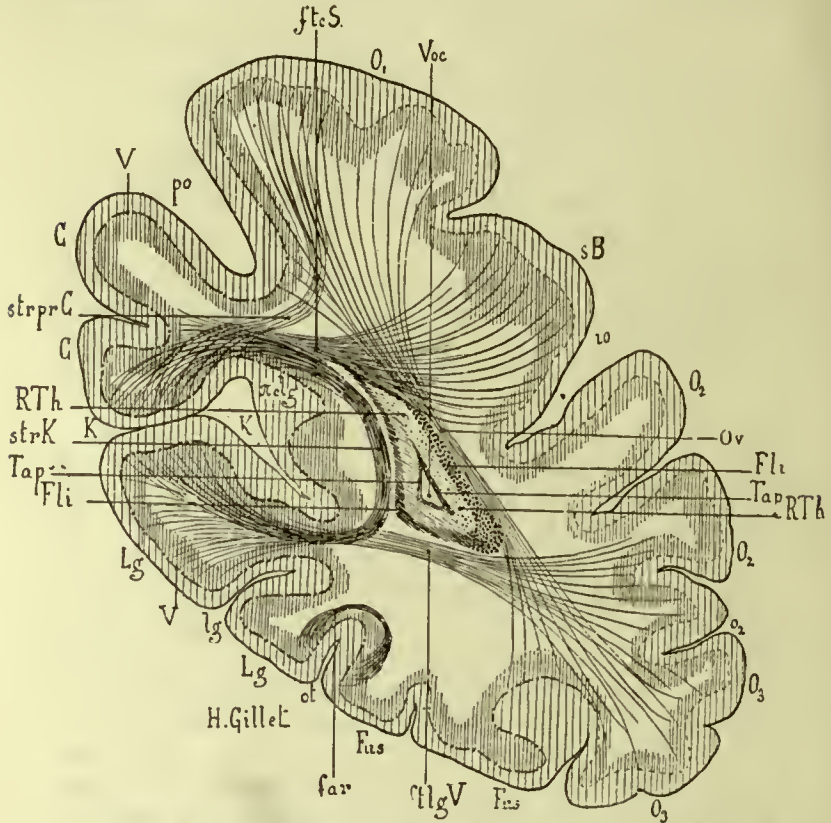


FIG. 668.—Vertical transverse section of the left occipital lobe to show the origin and course of the short association fibres of the lobus occipitalis (partly schematic). (After J. Dejerine, *Anatomie des centres nerveux*, Paris, 1895, p. 783, Fig. 389.) *C*, cuneus; *far*, fibre propriae; *Fli*, fasciculus longitudinalis inferior; *flgV*, fasciculus occipitalis transversus gyri lingualis; *fteS*, fasciculus occipitalis transversus cunei; *Fus*, gyrus fusiformis; *io*, sulcus occipitalis; *K*, fissura calcarina; *Lg*, gyrus lingualis; *lg*, sulcus of gyrus lingualis; *O1*, *O2*, *O3*, gyri occipitales; *ov*, sulcus occipitalis; *Or*, fasciculus occipitalis verticalis; *ot*, fissura collateralis; *po*, fissura parietalis occipitalis; *relg*, gyrus profundus connecting cuneus with the gyrus fornicatus; *RTh*, radiatio occipito-thalamica Gratioleti; *sB*, stripe of Baillarger; *strK*, stratum calcarinum; *strprC*, stratum proprium cunei; *Tap*, tapetum; *V*, ribbon of Vieq d'Azyr; *Voc*, cornu posterius ventriculi lateralis.

(3) The *fasciculus occipitalis transversus cunei*\* extends from the superior lip of the calcarine fissure lateralward and

\* Stratum cunei transversum of Sachs.

then curves upward and probably terminates in the cortex of the convex surface of the occipital lobe. According to Sachs, some fibres go obliquely forward and lateralward to the lobulus parietalis superior and the gyrus angularis.

(4) The *fasciculus occipitalis transversus gyri lingualis* of Sachs and Vialet extends from the inferior lip of the calcarine fissure (gyrus lingualis) lateralward to the convexity of the occipital lobe (gyri occipitales laterales). It is for the inferior lip of the calcarine fissure what the fasciculus occipitalis transversus cunei is for the superior lip of the calcarine fissure.

(5) The *stratum proprium cunei* of Sachs consists of vertical fibres extending from the superior lip of the calcarine fissure vertically upward to radiate out into the cortex near the junction of the medial with the lateral surface of the hemisphere.

In the frontal lobe fewer distinct bundles of short association fibres have been made out. According to Dejerine, the fibræ propriæ of the frontal lobe are grouped around the corona radiata, some extending transversely between the medial surface of the frontal lobe and its orbital and lateral surfaces, others extending vertically and connecting the various gyri of the lobe with one another. Still other bundles assume a sagittal direction, especially those in front of the substantia perforata anterior.

Similar short association neurones have been described in the lobus temporalis as well as in the insula. But thus far our knowledge of these bundles is too limited to make their detailed consideration of profit in this place.

## 2. Those with Long Axones.

The association neurones possessing long axones have been better studied, but the opinions of various investigators concerning them are still markedly contradictory. Without entering into the various polemics the following statements may be considered to represent the consensus of opinion at present regarding these bundles. Of the long association neurones the most important are (1) the cingulum, (2) the fasciculus longitudinalis superior, (3) the fasciculus uncinatus (4), association bundles of the fornix, and (5) the tapetum.

The *cingulum*\* belongs, properly speaking, to the rhinen-

---

\* This bundle was described under this name by Burdach. It was called the fornix periphericus by Arnold.

cephalon. The bundle extends in a sagittal direction close to the medial surface of the cerebral hemisphere in the white matter of

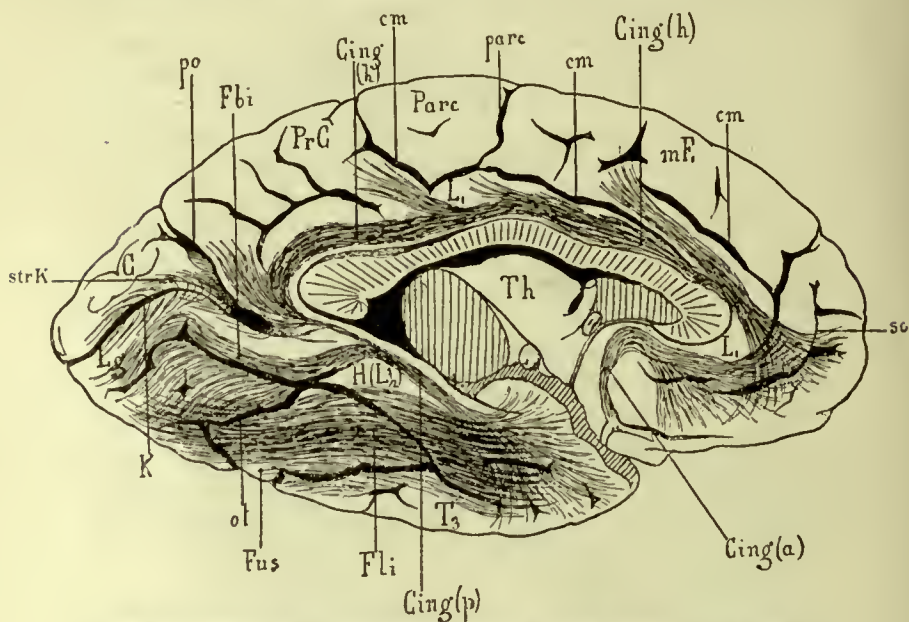


FIG. 669.—Facies medialis hemisphærii sinistri showing the cingulum, the fasciculus longitudinalis inferior, and other bundles of association fibres. (After J. Dejerine, *Anatomic des centres nerveux*, Paris, 1895, p. 752, Fig. 374.) *C*, cuneus; *Cing(a)*, fasciculus anterior of the cingulum; *Cing(h)*, horizontal or superior bundle of the cingulum; *Cing(p)*, posterior bundle of the cingulum; *cm*, sulcus cinguli; *cm'*, vertical portion of sulcus cinguli; *Fbi*, basal internal fasciculus of Burdach; *Flt*, fasciculus longitudinalis inferior; *Fus*, gyrus fusiformis; *H(L)*, gyrus hippocampi; *K*, fissura calcarina; *L*, gyrus cinguli; *Lq*, gyrus lingualis; *mF*, medial surface of gyrus frontalis superior; *ot*, fissura collateralis; *Pare*, lobulus paracentralis; *pare*, sulcus in front of lobulus paracentralis; *po*, fissura parieto-occipitalis; *PrC*, præcuneus; *sc*, sulcus sub-orbitalis of Broca; *strK*, stratum calcarinum; *T3*, gyrus temporalis inferior; *Th*, thalamus.

the two main parts of the gyrus fornicatus, namely, the gyrus cinguli and the gyrus hippocampi. Dejerine describes it as an arcuate bundle which turns around the rostrum, genu, truncus and splenium of the corpus callosum. At the isthmus gyri fornicati it goes into the depth to enter the gyrus hippocampi, through which it extends toward the uncus. The bundle, however, is not made up of axones which extend the whole length of the cingulum, but of a great number of shorter axones which are ever entering and leaving the bundle. According to



Beevor,\* it consists of three independent fasciculi—one anterior, a second horizontal, and a third posterior (Fig. 669). The anterior bundle, he believes, connects the substantia perforata anterior, and especially the region of the termination of the medial olfactory stria, with the anterior extremity of the frontal lobe. The horizontal fasciculus extends between the medial lateral surface of the frontal lobe and the gyrus cinguli, while the posterior fasciculus situated chiefly in the gyrus hippocampi connects this gyrus with the gyrus lingualis, gyrus fusiformis, and the cortex of the poles temporalis. The cingulum in the developing brain is shown in Fig. 670.

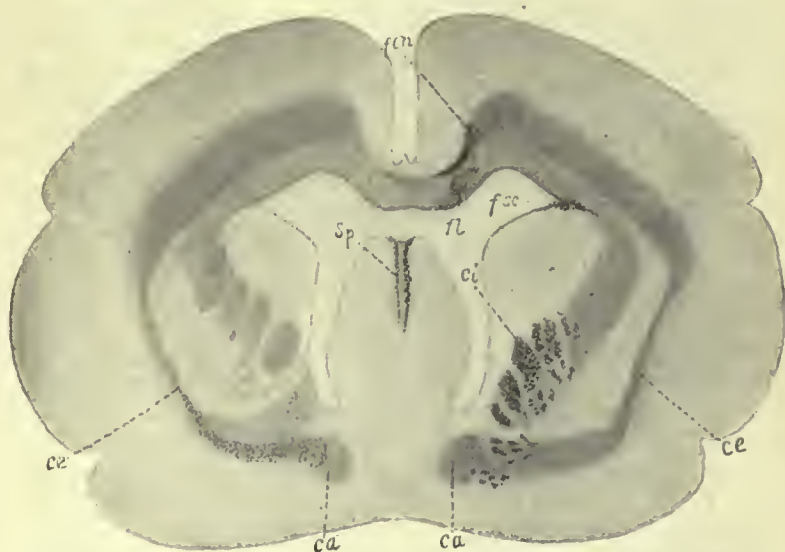

FIG. 670.—Marchi preparation showing degeneration in dog's brain after destruction of the lobus frontalis. (After Shukowski, taken from W. von Bechterew, *Die Leitungsbahnen im Gehirn und Rückenmark*, Deutsch von R. Weinberg, II. Aufl., Leipzig, 1909, S. 568, Fig. 535.) *ca*, commissura anterior cerebri containing degenerated fibres, which on the left side go over into the external capsule; *ce*, capsula externa; *ci*, capsula interna markedly degenerated; *fsc*, cingulum; *fl*, fornix longus on its way through the corpus callosum; *fsc*, fasciculus subcallosus; *sp*, fornix fibres in the septum.

The *fasciculus longitudinalis superior*,† triangular in coronal sections of the brain, extends as a curved bundle in a sagittal

\* Beevor, C. E. On the Course of the Fibres of the Cingulum and the Posterior Parts of the Corpus Callosum and Fornix in the Marmoset Monkey. *Phil. Trans. Roy. Soc.*, 1891, Lond. (1892), vol. clxxxii (B.), pp. 135-199.

† Fasciculus arcuatus of Burdaeh.

direction, apparently between the frontal lobe and the occipital lobe (Fig. 671). The cell bodies of the neurones, which give rise to the axones which constitute it, have not been well localized.

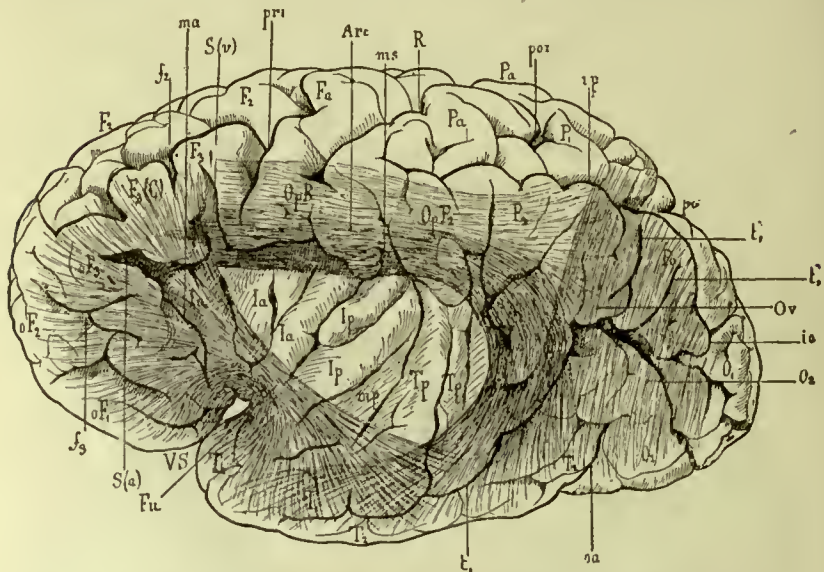


FIG. 671.—Lateral surface of the left cerebral hemisphere. The edges of the fissura cerebri lateralis (Sylvii) have been removed, and the gyri pulled apart to show the insular and retroinsular region. The fasciculus uncinatus, the fasciculus longitudinalis superior, and the fasciculus occipitalis verticalis are seen in transparency. (After J. Dejerine, *Anatomie des centres nerveux*, Paris, 1895, p. 757, Fig. 377.) *Arc*, fasciculus longitudinalis superior; *F<sub>1</sub>*, *F<sub>2</sub>*, gyrus frontalis medius and gyrus frontalis inferior; *f<sub>1</sub>*, sulcus frontalis inferior; *f<sub>2</sub>*, sulci orbitales; *F<sub>2</sub>(C)*, gyrus frontalis inferior, pars triangularis; *Fa*, gyrus centralis anterior; *Fu*, fasciculus uncinatus; *Ia*, *Ip*, gyri insule; *ip*, sulcus interparietalis; *ma*, *mp*, *mf*, sulcus circularis Reili; *o<sub>1</sub>*, *o<sub>2</sub>*, gyri occipitales; *oa*, sulcus occipitalis anterior of Wernicke; *oF<sub>1</sub>*, *oF<sub>2</sub>*, *oF<sub>3</sub>*, orbital portion of frontal gyri; *OpR*, operculum, pars frontalis; *OpF<sub>2</sub>*, operculum, pars parietalis; *Or*, fasciculus occipitalis verticalis; *P<sub>1</sub>*, lobulus parietalis superior; *P<sub>2</sub>*, lobulus parietalis inferior; *Pa*, gyrus centralis posterior; *Pc*, gyrus angularis; *Ppo*, fissura parieto-occipitalis; *por*, portion of sulcus interparietalis behind the upper part of the gyrus centralis posterior; *pri*, sulcus precentralis; *R*, sulcus centralis Rolandi; *S(a)*, *S(v)*, anterior and vertical ramus, anterior horizontal, and ramus anterior ascendens of fissura cerebri lateralis (Sylvii); *T<sub>1</sub>*, gyrus temporalis superior; *T<sub>2</sub>*, gyrus temporalis medius; *t<sub>1</sub>*, sulcus temporalis superior; *t<sub>1</sub>*, *t<sub>1</sub>*, vertical rami of the sulcus temporalis superior; *Tp*, gyri temporales transversi; *VS*, fossa cerebri lateralis (Sylvii).

It would appear that the axones of the bundle are of variable length, the majority of them not running through the whole extent of the fasciculus, but, as with so many of the association bundles, axones are ever entering and leaving this fasciculus. Among the axones in it are doubtless some extending between

the gyrus temporalis superior and the inferior frontal gyrus. This bundle on the left side is therefore, in all probability, of the highest importance in connection with the functions of speech, since in the gyrus temporalis superior is located the centre for word memories, while in the gyrus frontalis inferior is situated the centre for memories of the movements concerned in the articulation of words (Broca's centre). It is highly probable that axones run in both directions in the fasciculus longitudinalis superior.

The *fasciculus longitudinalis inferior*\* is usually described as extending between the lobus occipitalis and the lobus temporalis. It runs for a large part of its course close to the radiatio occipito-thalamica Gratioleti, but can, as a rule, be easily distinguished from the latter (Fig. 672). In it, too, in all probability, are axones running in both directions; in the one case the cell bodies of the neurones to which these axones belong are situated in the occipital lobe; in the other the cell bodies are situated in the more anterior parts of the brain. The majority of the axones, however, appear to have an occipitofugal direction. It is believed by the majority of investigators that a great many of these axones terminate in the temporal lobe, especially in the gyrus temporalis superior, and the idea at once arises that this bundle is the one concerned in connecting the visual sense area of the occipital cortex with the auditory sense area of the temporal cortex. These areas are undoubtedly connected, directly or indirectly, by means of association neurones. That the fasciculus longitudinalis inferior is, however, the bundle concerned is by no means definitely proved. The difficulty lies in the fact that in the anterior part of its course it is extremely difficult to differentiate fibres which belong to it from other fibres which are adjacent to it or even mixed up with it—for example, the medullated axones from the corpus geniculatum mediale and many of the cortipetal axones from the nuclei of the thalamus. Flechsig apparently denies a connection of the fasciculus longitudinalis inferior with the temporal lobe; indeed, he inclines to the view that much of this bundle consists of the medullated axones of projection neurones. The majority of investigators, however, insist upon the connection above described, and attribute many

---

\* Stratum sagittale externum (Sachs): *faisceau sensitif* (Charcot, Ballet).



of the visual disturbances accompanying aphasic lesions to interruption of the fibres of this path.

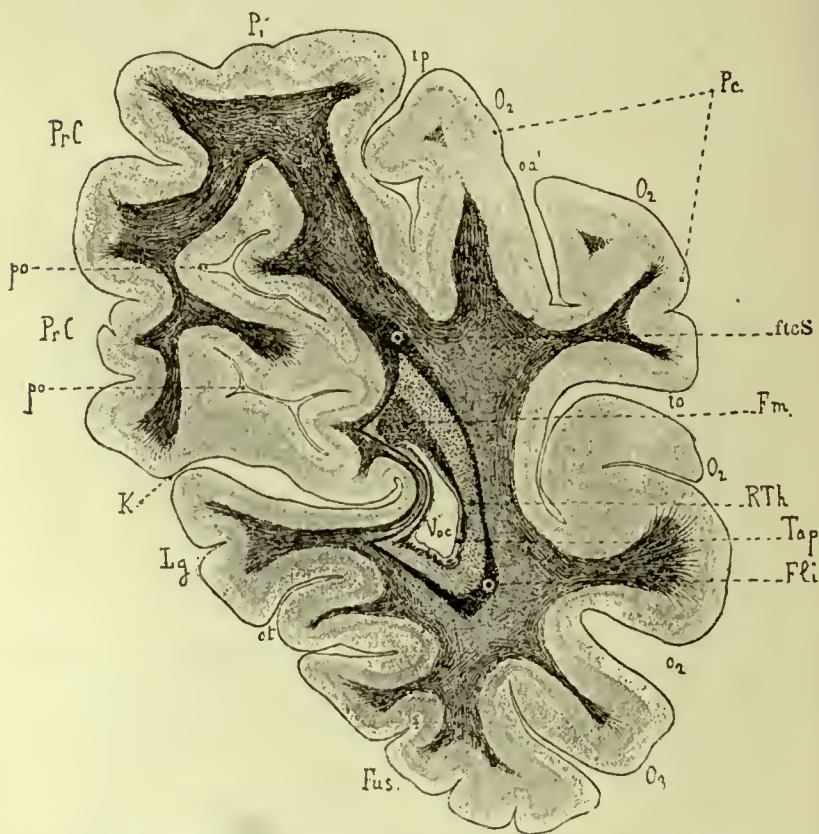


FIG. 672.—Vertical transverse section passing through the posterior part of the precuneus, the fissura parieto-occipitalis, the fissura calcarina, etc. Method of Weigert. (After J. Dejerine, *Anatomie des centres nerveux*, 1895, p. 768, Fig. 384.) *Fli*, fasciculus longitudinalis inferior; *Fm*, forix major; *fcs*, fasciculus transversus cunei; *Fus*, gyrus fusiformis; *io*, sulcus occipitalis; *ip*, sulcus interparietalis; *K*, fissura calcarina; *Lg*, gyrus lingualis; *O1*, *O2*, gyri occipitales; *oa'*, incisura of the sulcus occipitalis anterior of Wernicke; *ot*, sulcus collateralis; *P1*, lobulus parietalis superior; *Pe*, gyrus angularis; *po*, fissura parieto-occipitalis; *PrC*, præcuneus; *RTh*, radiatio occipito-thalamica Gratioleti; *Tap*, tapetum; *Voc*, cornu posterius ventriculi lateralis.

The *fasciculus uncinatus* is a bundle of medullated axones which extends between the uncus and the basal portions of the frontal lobe. It would appear to be an association bundle belonging to the rhinencephalon, connecting as it does the temporal



sense area with the olfactory sense area in the base of the frontal lobe. Authors are, however, by no means agreed as to its exact origin or as to its functions.

Many of the axones of the *fornix* are to be looked upon as the medullated axones of long association neurones. Especially is this true of the so-called olfactory bundle of the fornix which connects the hippocampus with the substantia perforata anterior.

The *tapetum*, usually described as a part of the radiation of the corpus callosum, is now believed by many to have nothing at all to do with that body, but to represent a bundle of medullated axones of long association neurones which connect the occipital and frontal lobes with one another. Thus, in instances of congenital absence of the corpus callosum it has been stated that the tapetum has been found normally developed (Fig. 673) (Forel and Onufrowicz,\* Kaufmann,† Hochhaus,‡ Bruce.§) Forel and others believed that the tapetum, therefore, represents a portion of the fasciculus longitudinalis superior, but this is vigorously opposed by Sachs and by Dejerine. Sachs thinks that the tapetum really belongs to the corpus callosum, and that, in cases of congenital absence of the latter body, instead of passing through from one hemisphere to the other, its fibres are transformed into a sagittal bundle which does not leave the hemisphere in which the fibres belong. Dejerine holds, on the contrary, that the tapetum belongs neither to the fasciculus longitudinalis superior nor to the corpus callosum, and that it is not, as Sachs would have us believe, a displaced bundle of the corpus callosum. He thinks that it is an independent sagittal association bundle, differing from the fasciculus longitudinalis superior in that it is located medial to the corona radiata forming the roof of the lateral ventricle, while the fasciculus longitudinalis superior is situated lateral from the corona radiata, its most inferior fibres being situated lateral from those of the ex-

\* Forel, A. Fall von Mangel des Balkens in einem Idiotenhirn. Tageblatt d. 54. Vers. deutsch. Naturf. u. Aerzte in Salzburg (1881).

† Kaufmann, E. Ueber Mangel des Balkens im menschlichen Gehirn. Arch. f. psychiat. u. Nervenkr., Berl., Bd. xviii (1887), S. 769; Bd. xix (1888), S. 229.

‡ Hochhaus, H. Ueber Balkenmangel im menschlichen Gehirn. Deutsche Ztschr. f. Nervenhe., Leipz., Bd. iv (1893-'94), S. 79-93.

§ Bruce, A. On a Case of Absence of the Corpus Callosum in the Human Brain. Proc. Roy. Soc., Edinb. (1887-'88), vol. xv (1889), pp. 321-341.

ternal capsule. He prefers, therefore, to describe it as the *fasciculus occipito-frontalis*, identifying it with the bundle described by Meynert as the radiation of the nucleus caudatus and

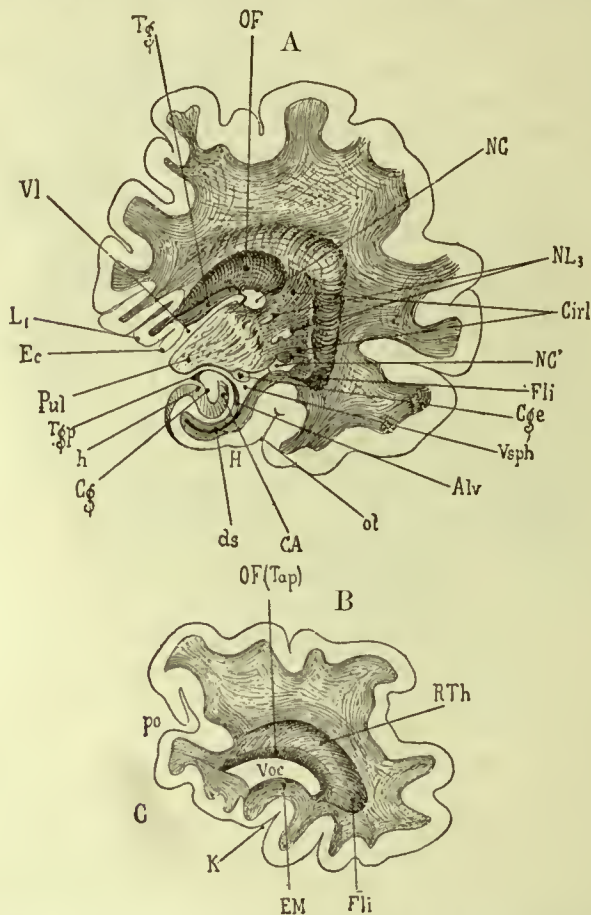


FIG. 673.—Two vertical transverse sections from a cerebral hemisphere, with agenesis of the corpus callosum. (After Forel and Onufrowicz, from J. Dejerine's text-book.) A. Section passing through pulvinar of optic thalamus. B. Section about 20 mm. farther back. A. *Alv*, alvens; *CA*, hippocampus (cornu ammonis); *Cg*, fascia dentata hippocampi; *Cge*, corpus geniculatum laterale; *Cirl*, retrolenticular portion of capsula interna; *ds*, diverticulum of the subiculum; *Ec*, edge of cerebral cortex; *Fli*, fasciculus longitudinalis inferior; *H*, gyrus hippocampi; *h*, fissura hippocampi; *L4*, gyrus cinguli; *Nc*, nucleus caudatus; *Nc'*, cauda nuclei caudati; *NL3*, putamen; *OF*, fasciculus occipito-frontalis of Forel and Onufrowicz; *ot*, fissura collateralis; *Pul*, pulvinar; *Tg*, corpus fornicis; *Tgp*, fimbria hippocampi; *V7*, ventriculus lateralis; *Vsph*, cornu inferius ventriculi lateralis. B. *C*, cuneus; *Em*, calcar avis; *Fli*, fasciculus longitudinalis inferior; *K*, fissura calcarina; *Of(Tap)*, fasciculus occipito-frontalis of Forel and Onufrowicz, forming the tapetum of the cornu posterius; *po*, fissura parieto-occipitalis; *RTh*, radiatio occipito-thalamica Gratioleti; *Voc*, cornu posterius ventriculi lateralis.

with the bundle described by Wernicke as the bundle from the corpus callosum to the internal capsule (Fig. 674).\* It is Dejerine's opinion that the bundle arises in the whole cortex of the lobus frontalis. Behind, after passing through the tapetum,

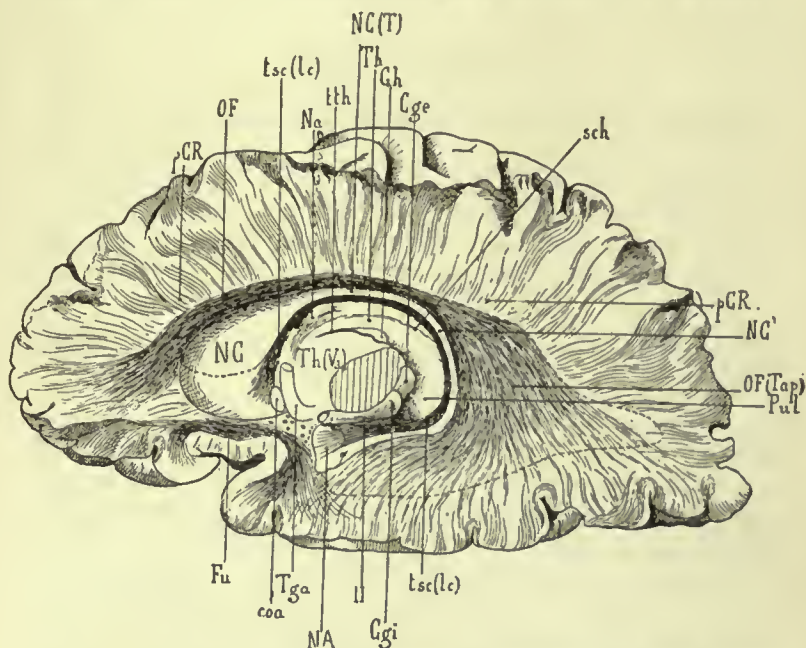


FIG. 674.—Fasciculus occipito-frontalis, tænia semicircularis and fasciculus uncinatus. The corpus callosum and the cingulum have been removed and the corona radiata dissected out. The preparation shows the inferior wall of the upper part of the lateral ventricle and the roof of the cornu posterius and cornu inferius. Partly schematic. (After J. Dejerine, *Anatomie des centres nerveux*, Paris, 1895, p. 762, Fig. 381.) *Cge*, corpus geniculatum laterale; *Cgi*, corpus geniculatum mediale; *coa*, commissura anterior cerebri; *Fu*, fasciculus uncinatus; *Th*, nucleus habentule; *NA*, nucleus amygdalæ; *Na*, nucleus anterior thalami; *NC*, caput nuclei caudati; *NC'*, cauda nuclei caudati; *Ne(T)*, corpus nuclei caudati; *OF*, fasciculus occipito-frontalis; *OF(Tap)*, part of fasciculus occipito-frontalis forming the tapetum; *pCR*, foot of corona radiata; *Pul*, pulvinar; *sch*, fissura chorioidea; *Tga*, columna fornicis; *Th*, thalamus; *Th(V<sub>2</sub>)*, part of thalamus projecting into third ventricle; *tsc(1c)*, tænia semicircularis, some fibres of which are situated in the lamina cornea; *tth*, tænia thalami; *II*, tractus opticus.

these fibres are distributed to the lateral surface and inferior border of the lobus occipitalis. It is stated that the tapetum does not degenerate after experimental section of the corpus callosum, while it does degenerate after lesions of the cortex of the frontal lobe (Muratow).

\* *Balkenbündel zur inneren Kapsel* (Wernicke).

## CHAPTER LXVIII.

### ASSOCIATION NEURONES OF THE TELENCEPHALON (CONTINUED).

Localization of association neurones in the cerebral cortex—Flechsig's association centres—The so-called silent areas of the brain—Functions of association centres—Functions of sense centres—The anterior association centre—The large posterior association centre—Criticisms of Flechsig's work—Studies of von Monakow, Sachs, von Kölliker, and others.

#### 3. Localization of Association Neurones in the Cerebral Cortex. Flechsig's Doctrine of Association Centres.

THE exact localization of the association neurones in the cerebral cortex is a topic attracting an ever-increasing amount of attention. While it seems almost certain that there are association neurones situated in every portion of the cortex, there is much reason to believe that certain areas of the cortex consist almost entirely of such association neurones. In this connection the researches of Flechsig are worthy of especial recognition. It is Flechsig's belief that the areas of the cortex in which projection neurones play a part in the architecture are much more limited in extent than we have been accustomed to suppose.

Flechsig has traced by means of the embryological method the various bundles of the axones of corticopetal projection neurones to their terminal stations in the cortex, and has also traced the course of the bundles of medullated axones of corticofugal (motor) projection neurones from their origin in the cortex to their lower end stations, a process rendered comparatively easy by the fact that the various bundles become medullated at different periods of antenatal and postnatal development.

The best articles in regard to the quantitative relations of the fibres of the cortex are those of Kaes.\*

---

\* Kaes, T. Beiträge zur Kenntniss des Reichthums der Grosshirnrinde des Menschen an markhaltigen Nervenfasern. *Arch. f. Psychiat., Berl.*, Bd. xxv (1893), S. 695-758.—Ueber den Faserreichthum der ii u. iii Meynert's-



But even when all the sense areas and motor areas of the cortex, extensive as they are, have become medullated, only about one third of the surface of the cerebrum has been involved. The individual sense areas are isolated, not touching one another directly. They are separated by regions which have no direct connection, at any rate at this stage of development, with the centres below or with the periphery of the body. It will have been noticed that the somæsthetic area, that portion of the cortex at which bodily sensory impulses arrive, includes within it what has usually been described as the motor zone of the cortex. In all probability also from the visual, from the auditory, and from the olfactory sense areas, corticofugal, probably motor, conductions also go out.

As far as Flechsig has been able to make out, all or very nearly all of the projection fibres of the cerebrum are accounted for when the corticofugal and corticopetal paths of the different sensory-motor areas, as outlined by him, are summed up. But nearly two thirds of the whole of the cortex yet remains to be accounted for. What is the significance, then, of the regions which are not provided with projection fibres? The studies of Flechsig have thrown these portions, which in large part correspond to what we have been accustomed to call the "silent areas" of the cerebral cortex, into bold relief. His anatomical investigations, especially when their results are compared with the findings of pathological anatomy in cases which have been carefully studied clinically, indicate that these hitherto insufficiently explored regions possess functions of the greatest importance and interest.\*

If the limits described for the different sense areas be recalled it will be seen that the regions left over include in the frontal lobe the anterior portions of the superior and middle frontal convolution, portions of the inferior frontal convolution, and the gyrus

---

sehen Schicht sowie ueber vergleichende Messungen der gesammten Hirnrinde und deren einzelner Schichten. *Neurol. Centralbl.*, Leipz., Bd. xii (1893), S. 119-122.—Ueber die markhaltigen Nervenfasern in der Grosshirnrinde des Menschen. *Ibid.*, Bd. xiii (1894), S. 410-412.

\* Thomas, speaking in this connection, says: "Flechsig's association centres are what have been called the silent areas of the brain; but we are forced to believe that they are silent, not because they do not speak, but because we are too dull of understanding to hear what they say." Cf. Thomas, H. M., and Keen, W. W. A Successful Case of Removal of a Large Brain Tumor, etc. *Am. J. M. Sc.*, Phila., n. s., vol. cxii (1896), pp. 503-522.

rectus; further, the greater part of the island of Reil, the superior and inferior parietal lobules, the middle and inferior temporal convolutions exclusive of the internal temporal pole, the gyrus fusiformis, gyrus lingualis, and the whole of the occipital

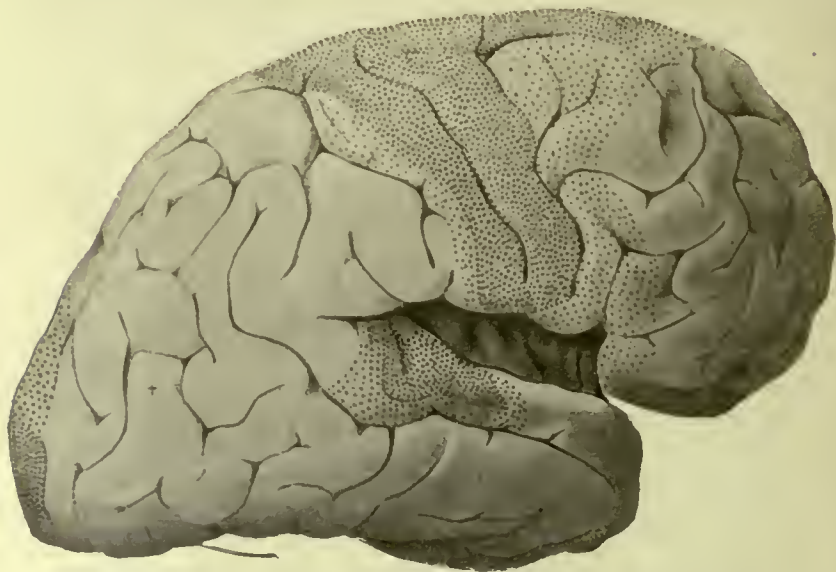

FIG. 675.—View of lateral surface of right cerebral hemisphere, showing sense centres and association centres. (After P. Flechsig, *Gehirn und Seele*, II. Aufl., Leipz., 1896, Taf. iv, Fig. 7.) The more closely dotted areas show the regions in which the majority of the sensory projection axones terminate. The large portions between the dotted areas represent the association centres.

lobe not included in the visual sense area. In the diagram these relations are shown very clearly (Figs. 675 and 676). The sense areas are dotted, the regions in which the majority of the sensory fibres terminate being closely studded with dots, while in between the different sense areas the large undotted regions correspond to the portions of the cortex entirely devoid of projection fibres, or at most provided with extremely few of such fibres. At the periphery of each sense area is a marginal zone in which projection fibres are less thickly distributed.

The white matter corresponding to all the cortical regions between the sense areas, with the exception, perhaps, of that beneath the angular gyrus, becomes medullated considerably later than that of the sense centres, so that, even in children three months old, the former are sharply distinguishable from the latter by their

poverty in myelin. Flechsig finds, however, that medullated paths gradually grow out from the sense centres into these non-medullated regions. Further, between the individual gyri of the non-medullated regions, bands of association fibres gradually ripen, connecting the individual gyri with others near them and also with gyri at a distance. By means of the corpus callosum the gyri in one hemisphere are connected with those of the opposite hemisphere. Flechsig, on account of the marked predominance of association systems in these areas, has designated them "association centres of the cerebral cortex."\* He does not, as did Meynert, believe

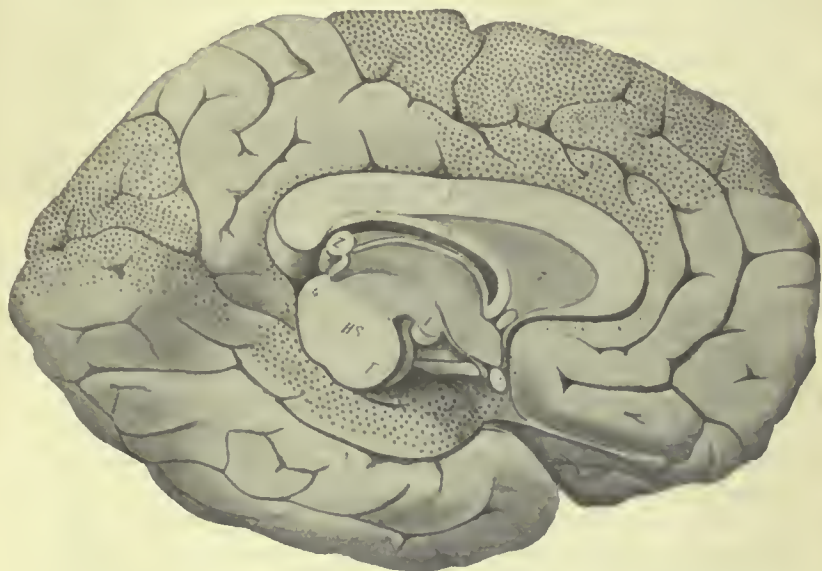

FIG. 676.—View of the medial surface of the left cerebral hemisphere, showing sense centres and association centres. (After P. Flechsig, *Gehirn und Seele*, II. Aufl., Leipz., 1896, Taf. iv, Fig. 8.) 1, corpus mammillare; 2, median section of chiasma opticum; 3, commissura anterior cerebri; 4, colliculus superior; 5, corpus callosum; 6, fornix; 7, septum pellucidum; z, corpus pineale; HS, tegmentum; T, basis pedunculi.

that the individual sense centres are connected directly with one another, but thinks that, on the contrary, they are connected rather indirectly by means of the association centres. The lat-

\* It is surprising to find how closely many of the views recently expressed by Flechsig accord with some of the doctrines promulgated by the English neurologist Broadbent.

ter, receiving conduction fibres from adjacent sense centres and from adjacent as well as distant association centres, furnish an anatomical mechanism which makes possible the working up into higher units of simple sense impressions and of combinations of simple sense impressions of the same quality and of different qualities. Thus Flechsig denies the function ascribed by many to the so-called fasciculus longitudinalis inferior which would make it a system associating directly two sense centres with one another. He thinks that, on the contrary, it has an entirely different significance, which, however, I shall not discuss at this time.

The position of the individual areas of association probably throws some light upon the functions which they subserve (Figs. 675 and 676). Thus the large region which Flechsig designates as the posterior large association centre and which includes the præcuneus, all the parietal gyri except the posterior central gyrus, part of the gyrus lingualis, the fusiform gyrus, and the middle and inferior temporal gyri, as well as all portions of the occipital gyri not concerned in the visual sense area, is situated between the visual, the somæsthetic, and the auditory sense areas. The island of Reil is surrounded by the somæsthetic area, the auditory area, and the olfactory area, and into it run bands of fibres from these sense areas, so that it, Flechsig thinks, is properly designated as the middle association centre. The main portion of the frontal lobe, Flechsig's anterior association centre, is very intimately connected with the somæsthetic area, and with the olfactory sense area.\*

While the anatomical evidence which Flechsig has brought forward would seem to be sufficient to indicate in general the essential nature of the functions of the different regions of the cortex described, there has been already collected a mass of clinical and pathological data which, when reviewed in the light of the newer anatomical knowledge, affords confirmatory proof of his views. Lesions involving the sense centres are followed by a train of symptoms of an entirely different character from those which accompany lesions of the association centres. This will be clear if certain familiar examples be recalled. All the evi-

---

\* As Flechsig remarks, however, it is not probable that its function is confined to the association of olfactory impressions with sensations which tell us about the condition of our bodies, for the olfactory sense in man is relatively little developed, while the frontal lobe is developed *ad maximum*.



dence goes to show that the phenomena of sharp, clean-cut sensations as they appear in consciousness have their origin in the sense centres. As a result of a lesion of a given sense centre this sharpness of sensation for the particular sense quality concerned disappears. If the visual area on both sides of the brain be destroyed, the patient no longer sees. He may occasionally believe that he still possesses visual sensation, but on closer examination it will be found that the picture in his consciousness is a memory-picture, not a perception. Patients suffering from double-sided destruction of the auditory sense area are absolutely deaf,\* and it is to be imagined that if both somæsthetic areas were entirely destroyed the individual would, if he continued to live at all, be deprived of sensations informing him of the condition of his body, of the skin, and of the viscera.† Injury to the central gyri on the left side about their middle has been followed by loss of power to recognize correctly the form of a given object when the right hand alone has been used to feel it. Irritation of the posterior central gyrus may lead an individual to believe that he experiences movements of his thumb even when his eyes convince him that it has not moved. Tumors pressing upon the olfactory sense area have given rise to subjective odors, while mental images of colored figures and the like have occurred in individuals in whom after death cysts involving the visual area of the occipital lobe have been found. Irritative lesions of the auditory sense area can give rise to noises and to other sound-images. Destruction of the sense centre concerned with the sensations of any given sense quality is associated with the so-called perceptive sensory disturbances.

The sense centres are concerned not only in the bringing into consciousness of the individual elementary sense impressions, but the distinction of the spatial and temporal relations of these impressions, if Flechsig be right, is also to be attributed to the

---

\* Cf. a very important case described by Friedländer, C., and C. Wernicke. Ein Fall von Taubheit infolge doppelseitiger Läsion des Schläfelappens. *Fortschr. d. Med.*, Bd. i (1883).

† For evidence as to the paramount importance of the somæsthetic area for the development of a personality, the reader is referred to the thorough studies which were made of the brain of Laura Bridgman. Cf. Donaldson, H. H. Anatomical Observations on the Brain and Several Sense Organs of the Blind Deaf-Mute, Laura Dewey Bridgman. *Am. J. Psychol.*, vol. iii (1890), pp. 293-342.

activities of the cortical sense spheres. Thus "perceptive word-deafness" has been shown to depend, in right-handed individuals, upon disease of the left auditory sense area. When words are spoken the individual hears only confused noises and does not understand them. Wernicke believed that in such cases there is a permanent loss of the memory pictures of the sounds of words. This is denied by Flechsig, who holds that here we have to deal rather with an incapacity of separating the sounds which follow one another in the spoken words, of distinguishing tone intervals correctly between syllables and words. The patient does not perceive an orderly combination of sounds, but an undecipherable chaos of tones and noises. If in such cases we have to deal with pure lesions of the auditory sense area the patients can speak spontaneously a large number of words correctly, so that the ordinary observer might scarcely notice any disturbance in his speech, a fact which makes it seem likely that the memory pictures of the sounds of words have been retained in spite of the destruction of the auditory sense area. On the other hand, if the periphery of the auditory sense area be destroyed, as in Heubner's well-known case, and the auditory sense area itself remain uninjured, the clinical picture is exactly reversed; the patient in this transcortical sensory aphasia (in the sense of Lichtheim and Wernicke) can speak spontaneously only very few words (amnesic aphasia), or there exists a high degree of paraphasia. The patient, however, can from the beginning repeat correctly words which are spoken before him, which is evidence in favor of the view that he has heard the words correctly and has retained the capacity for perceiving correctly the intervals between syllables and words. If, in spite of this, word-deafness exists, the reason, perhaps, lies in the fact that the words correctly heard do not call forth by association into consciousness the memory pictures which belong to them, and which help to make up the sense ("apperceptive word-deafness" of Herbart). Of course, these forms are seldom met with pure, for in the majority of cases the auditory sense area and its periphery are diseased more or less together, and mixed forms are of no use for the decision of the question whether and in how far diseases of the auditory sense area alone have disturbances of memory as a result.

If the cortical form of "perceptive word-deafness" does not depend on the loss of memory pictures of the sounds of words

it is highly probable that it is a "sensory atactic" disturbance—the temporal arrangement of the auditory sensations is lacking. If Flechsig be correct about this, the essential basis for spatial and temporal perceptions is to be sought in the sense spheres.

Flechsig thinks that the tactile disturbance, described by Wernicke, associated with disease of the somæsthetic area, is due to loss of the capacity of uniting properly tactile stimuli to a mental image (that is to say, the spatial arrangement of the single impressions is no longer possible). It is rather an atactic disturbance of perception than, as Wernicke thinks, a defect of memory capacity. It is quite analogous to the perceptive word-deafness dependent upon lesion of the auditory sense area. It is probable that the organic traces of the more extensive memory pictures, built up of no matter what sense qualities, are associated with the cells of the association centres which lie between the sense centres.

Before passing to the description of the functions of the association centres, however, a few special points in connection with the sense centres must be considered. With regard to the somæsthetic area it has long been known that disease of the central convolutions is accompanied frequently with loss of the kinæsthetic sensations, so that the mental images of position and movement for the extremities and the region of the mouth may be absent or defective (Bastian). Along with these symptoms, especially where the foci of disease are small, the cutaneous sensations suffer only as regards the tactile sense and its exact localization. As a result of lesion of the arm region there is an incapacity to recognize external objects by feeling their form. Indeed, these disturbances of the stereognostic sense seem to be characteristic of cortical lesions.

If the inferior frontal convolution be diseased, the capacity for calling up images of movements, or rather the capacity to feel the position of the organs which participate in speech, suffers, so that sensory system No. 3, connected with the inferior frontal gyrus, is accordingly not different in the sensation quality mediated from the sensory paths of the central gyri, but simply in regard to the region of the body whence the sensations come; the newborn infant, for purposes of self-preservation, makes use far earlier of his extremities, his lips and his tongue, than of his trunk and speech muscles, and this fact of experience agrees extremely well with the developmental finding that the sensory



and motor paths of the extremities develop earlier than those for the trunk and the special organs of speech (Flechsig). Certain of the fibres of system No. 2 have apparently to do with muscle sense, but our knowledge is as yet insufficient concerning this group. There is a good deal of evidence, too, that the somæsthetic area plays an important part in the coming into consciousness of many of the bodily processes accompanying or constituting the emotions, and that thence start out many of the movements which serve as the expression of the emotions, a point of view which, if confirmed, is of infinite importance for psychiatry.

Let us now turn to the subject of the functional activities of the association centres. We have seen before that from the anatomical arrangement these areas appear to exist for the purpose of uniting the activities of the various sense centres. Clinical and pathological evidence, too, is in favor of Flechsig's view that they are concerned in the higher manifestations of the intellect, in the processes of memory, recognition, judgment and reflection. It is in disease of these areas that we see, above all, disturbances of memory and of the associative processes. When the posterior large association centre, for example, is diseased, the lesions are not accompanied with phenomena of perceptive deafness, of perceptive blindness, or of perceptive tactile anaesthesia, providing the adjoining sense centres remain unaffected. But instead of these an entirely different group of clinical phenomena becomes manifest. Here we meet sometimes with the conditions known as mind-blindness, mind-deafness, and the like; with apraxia or agnosia; sometimes there is weakening of the power of visual imagination. There may be an incapacity to call into consciousness melodies which the individual formerly knew well, and in lesions of this area on the left side in certain portions, sensory (optic) alexia, optic aphasia (amnesic color-blindness), apperceptive (transcortical) word-deafness, verbal paraphasia, and sensory amnesic aphasia (incapacity to call up the memories of the sounds of words corresponding to the mental images in consciousness). The memory capacity may in such instances be affected apparently in either or both of two ways—(1) by destruction of the association paths concerned in setting free given mental images, and (2) by actual, permanent destruction of the organic memory traces in the nerve cells. It would appear, therefore, that the posterior large association centre is concerned in the formation and collection of ideas concerning the external



world—that is, of actual knowledge concerning external objects, of combinations of sounds, and the union of all these with one another. In these regions are stored up the elements of our positive knowledge as well as the factors which come into play in the exercise of the fantasy. It is here that preparation is made for speech which shall accord with the thoughts; in short, this region more than any other in the cerebral cortex appears, Flechsig believes, to be the site of the processes concerned in what we ordinarily mean when we speak of the “intellect.”

The anterior association centre—that is, the association centre of the frontal lobes—has manifold connections with the somæsthetic area, and hence also with the motor regions concerned in conduct. So that here, in all probability, Flechsig states, is to be sought the anatomical mechanism by means of which memory traces of all conscious bodily experiences, especially of acts of the will, are stored up. The study of the functions of this region of the brain is extremely difficult, and as yet only general statements can be made regarding them. It would appear that the positive knowledge of the individual concerning external objects does not necessarily suffer in diseases of this portion, at least at first, although the appreciation of the value of this knowledge and its relations to the individual himself may be diminished. The man may lose interest in the external world as well as in himself and cease to participate personally in what is going on about him. Indeed it is in the diseases affecting this area and the neighboring somæsthetic area that most marked alterations in the character of the individual are met with. The phenomena of attention, of reflection, and of inhibition are possibly especially connected with this frontal association centre. Wundt has for some time believed that the “active apperception” is to be localized in this region.

If Flechsig be correct in his views, it is evident that the study of the normal functions of the association centres is of the highest importance and will in the future represent pre-eminently the task of psychology; while the phenomena which result when the association centres are diseased will afford the especial topic of investigation for psychiatry. The study of cases in the literature, more especially of general paresis, in which careful pathological examinations have been made after death, has already thrown considerable light upon the function of these areas. Of course, in the majority of cases of this disease

the lesions involve very different regions of the cortex at the same time. While in some instances, however, the disease has affected preferably the association centres alone without involving the sense centres, in a few cases the frontal association centres, it is asserted, have been the ones chiefly involved, and in others the large posterior association centres have been the ones mainly affected.

Such material permits of an analysis of the functions of the individual areas. Thus where the frontal lobes on both sides of the brain have been diseased the main symptoms recognizable during life have been those referable to an alteration or loss of ideas regarding the individual's personality and his relations to what is taking place inside and outside his body—symptoms which are highly suggestive when compared with the results of extirpation of the frontal lobes in higher apes, as carried out by the Italian investigator Bianchi. The symptoms may vary much—probably according as the lesion is irritative or destructive in its nature. Thus, in some instances, there is an over-appreciation of self. The patient's egotism is unbounded. All things are possible to him. He is a multi-millionaire, a genius, or a high dignitary. In other cases he shows remarkable self-depreciation and lack of confidence in his personal capacity. The speech may for a long time remain unaffected; but the capacity for judgment as to what is right and what is wrong, what is beautiful and what hateful, is often involved so that the individual will exhibit in his conduct characteristics entirely incompatible with what his friends knew of him earlier in his life. Such persons lack self-command, even when uninfluenced by violent emotions; and when they are exposed to unusual stimulation, to anger, or to sexual excitement, they lose all control of their conduct and are guilty of outrageous acts. Finally, if the disease progress far enough, imbecility appears, and the individual may lose completely his ideas concerning his personality.

When the posterior large association centres have been mainly affected the clinical picture is very different; in these cases it is the knowledge of the external world rather than that of his body and of his personality which is defective, just as one would expect from what has been said above concerning the phenomena of sensory aphasia met with in focal softening of the cortex due to vascular disease. In these individuals the ideas regarding the personality may be tolerably clear; they may have almost perfect

self-possession, but their friends notice, and they may themselves be aware, that they are unable to recognize objects seen and felt or to associate the elementary sensory impressions with the memories of experiences in their past lives. Such a patient will name external objects wrongly, misunderstand their use, confuse persons, and be mixed up in his ideas of time and space. He is unable to put into words the images which float in his consciousness, and suffers on the whole from a poverty of ideas. Yet with all this he may perhaps have a normal regard for himself and for his friends.

With combined diseases of the different association centres, and especially with combinations of disease of the sense centres with disease of the association centres, the possible variations in the clinical picture become almost innumerable. For the analysis of these symptoms and their anatomical localization psychiatry has been provided in these researches of Flechsig, should they be confirmed, with a most important aid.

It will be of especial interest to study the functional diseases of these different areas, disturbances of a temporary nature which can be ascribed to faulty metabolism, in the different areas dependent upon various factors such as imperfect nutrition, certain intoxications, prolonged emotion, excessive mental and physical activity, and the like. The protean symptoms of neurasthenia and hysteria often in individual cases bear a special stamp which may enable us in the future to suggest with some probability the portion of the brain mainly responsible for their appearance.

Representing as they do ideas which fundamentally affect our general concept of the structure and function of the brain, these researches of Flechsig have, as might have been expected, not passed unchallenged. After his address at Frankfurt a number of leading neurologists and psychiatrists discussed his findings and his views. It may be interesting to consider briefly some of the objections which have been offered to them.

A number of investigators are unwilling to grant that the areas of the cortex to which projection fibres are distributed are as limited as Flechsig would have us believe. Thus, von Monakow asserts that projection fibres go to nearly all parts of the cortex, though certainly some parts of it receive fewer by far than others. Hitzig, too, grants that the number of projection fibres going to the frontal lobe is very small. Von Monakow bases his objection upon the results of his studies of secondary



degenerations. He finds degenerations in the thalamus after lesions of certain of the regions falling within the domains which Flechsig calls association centres. He believes, too, that motility and sensation are represented in the cortex in ways fundamentally different from one another. His studies have convinced him that the sense areas occupy much more extensive fields of the cerebral surface than those indicated by Flechsig in his diagrams. Thus, the area for cutaneous and muscular sensations, von Monakow thinks, extends far beyond the central gyri, since to produce atrophy of the lemniscus and of the nucleus funiculi gracilis and the nucleus funiculi cuneati of the opposite side, destruction of the cortex (in both animals and man) of a far greater extent than that which represents the "motor zone" must have preceded. In answer to this Flechsig suggests (1) that a totally insufficient amount of material has been studied by the secondary degeneration method to afford conclusive results; and (2) that in many instances not sufficient attention has been paid to the exact localization of the lesions; that is to say, not enough care has been taken to determine whether it has been purely cortical or whether it has involved also the sub-cortical white matter. He points out, for example, that lesions of the parietal cortex have been followed in a number of instances by degenerations of projection fibres, but in all such instances he believes the cortical nodule has affected bundles of projection fibres belonging to other parts of the cortex, but situated beneath the area diseased. The results of experimental degenerations in animals following extirpation of cortical zones can not properly be directly applied to human beings, for in man there is a development of the association centres not reached in the brain of any other animal.

Another objection which very properly has been offered by Sachs and others is this: That after a certain period of development the medullation has become so diffuse in the cerebrum that it would be impossible to deny that later projection fibres passing to the association centres may become medullated. It must be granted that Flechsig can claim the limitation of sense centres, as he defines them, only for a definite period of development. It is certain, however, that at this period the primary sense centres are sharply marked off from the rest of the cortex.

Von Kölliker's objection to designating the association centres as intellectual centres is based upon his view that there is no



essential difference between the pyramidal cells of the various regions of the cortex. In the first place, however, as Flechsig points out, the time is not yet ripe for the building up of a psychology based upon the histology of the cortical cells. One need only refer to the attempt which has recently been made by Ramón y Cajal.\* As a matter of fact, however, the sense centres do differ very essentially, not only in the correlation of the elements present in them, but also in the actual shape and position of the individual nerve cells. A skilled histologist who has studied sections from these regions can easily distinguish a section from the middle part of the gyrus fornicatus from one taken from the neighborhood of the calcarine fissure, from the middle of one of the central gyri, or from the angular gyrus.

These studies of Flechsig, taken together with the researches of Edinger, show that the anatomical mechanisms underlying the mental processes in human beings as well as in animals are organically membered, and are only secondarily fused together into an organic whole. From the study of the gradual development of the individual organs of the brain, as shown by ontogenetic and phylogenetic investigations, we have the promise of a clear and sharply defined picture of the various anatomical substrata which in definite sequence are concerned in the gradually increasing complexity of the organizing intelligence. While it is probable that many of the theories which go far beyond actual findings, which Flechsig has advanced regarding psychology, will, with further knowledge, be entirely given up or much modified,† still every one who reads his papers carefully will be ready to grant that many of them are too well founded to be overthrown. At any rate, he has supplied us with a mass of material and data which must form the starting point of a whole series of subsequent investigations.

In deciding as to the relative value of the results of the recent work of Flechsig, all will probably agree with His, of Leipzig, who suggests that his most striking achievements have been (1) the bringing of the anatomical proof of the existence of primary

---

\* Ramón y Cajal, S. Einige Hypothesen ueber den anatomischen mechanismus der Ideenbildung, der Association und der Aufmerksamkeit. *Arch. f. Anat. u. Physiol., Anat. Abth., Leipz.* (1895), S. 367.

† Cf. Jacobi, M. P. Considerations on Flechsig's "Gehirn und Seele." *J. Nerv. and Ment. Dis., N. Y.* (1897).

sensory sense centres in the cerebral cortex and of the connection of these centres with the nervous apparatus situated lower down; and (2) the determination of the *successive* medullation of the fibres going to the single cortical areas and the exact periods of such medullation.

## INDEX OF AUTHORS.

---

- Aequisto, V., 289, 402.  
 Adamkiewicz, A., 132.  
 Agababow, A., 412, **271**.  
 Algeri, G., 1023.  
 Allbutt, Clifford, 341.  
 Allis, E. P., 921.  
 Altmann, R., 145, 154.  
 Ambronn, H., 89, **54**.  
 Anaximander, 220.  
 Anderson, H. K., 441.  
 Andriezen, L., 29, 979, **663**.  
 Apáthy, S., 38, 47, 52, **23**, 54, **24**, **25**,  
     **26**, 56, **27**, **28**, 58, 59, **29**, **30**, 60,  
     62, 63, 67, 70, 73, 96, 136, 137, 138,  
     140, 156, 265, 271, 272, 273, 359,  
     896.  
 Argutinsky, P., 888, **568**.  
 Arndt, R., 104, 655.  
 Arnold, J., 667, 1044, 1058.  
 Arnstein, C., 33, 374, **277**, 421, 530.  
 Auerbach, L., 78, 82, 191, 593, 602,  
     604.  
 Ayers, H., 499.  
 Azoulay, **206**, **350**, **665**.  
  
 Baas, K., 832.  
 Babes, V., 25, 289.  
 Babinski, 413.  
 Bacon, Francis, 274.  
 Baer, K. E. von, 193, 790.  
 Baer, W. S., 245, 246.  
 Baginski, B., 504, 836, 852.  
 Baillarger, 821.  
 Baker, Frank, 40.  
 Balfour, F. M., 179, **121**.  
 Ballet, G., **151**, 238, 289, 1065.  
  
 Barbacci, O., 306, 441, 442, 446, 452,  
     951.  
 Barker, Lewellys F., 40, 43, 111, 253,  
     589.  
 Bartholow, R., 1002.  
 Basilewski, A., 960, **614**, **615**, 967,  
     973.  
 Bastian, 442, 1077.  
 Batten, F. E., 418.  
 Baungarten, P., 786, 792.  
 Beale, 102.  
 Beard, J., 179, 200.  
 Beecherew, W. von, 28, **13**, 82, **45**,  
     268, 270, 319, 424, 427, 428, 429,  
     430, 473, 501, 504, 505, 509, 511, 523,  
     **349**, 529, 565, 569, 570, **382**, 577,  
     **386**, 592, 605, 608, 609, **401**, 612,  
     **402**, 613, 614, **403**, **404**, 618, 630,  
     632, 635, **424**, 655, 658, **431**, 659,  
     **432**, 664, 684, 688, **446**, 692, 694,  
     700, 705, **456**, 708, 715, 716, 805,  
     **515**, 808, 830, 831, 836, 843, 852, 864,  
     865, 872, 888, 954, **609**, 956, 957, 958,  
     960, 966, **614**, **615**, 967, 968, 974,  
     **620**, 1020, 1047, 1063, **670**.  
 Beck, A., 289.  
 Becker, 96, 137.  
 Beevor, C. E., 346, 995, 996, **632**,  
     1000, 1001, 1003, **635**, **636**, **637**,  
     1007, 1008, **639**, 1063.  
 Bell, Sir Charles, 3, 897.  
 Bellonei, G., 831.  
 Bemmelen, J. F. van, 201.  
 Benda, C., 105, 111, 112, 122, 127, 128,  
     136, 141, 164.  
 Bérard, 229.

- Berdez, 441.  
 Berger, H., 94.  
 Bergmann, G. H., 840.  
 Berkley, H. L., 10, 11, 29, **37, 38, 71, 76, 39, 239, 153, 154, 285, 288, 381, 402, 411, 418, 892.**  
 Bernheimer, S., 235, 911, 942, 945, 946, 950.  
 Bert, P., 900.  
 Bethe, A., 34, 36, 37, 38, 46, 96, 137, 138, 139, 145, 153, 265, 271, 272, **162, 273, 316, 213, 365, 366, 368, 219, 474.**  
 Bettmann, M., 129.  
 Betz, 108, 112, 135, 978.  
 Bianchi, 1080.  
 Biedermann, W., **80, 960, 965, 613, 966, 968, 973.**  
 Biedl, A., 231, 235, 960, 965, **613, 966, 968, 973.**  
 Bielschowsky, M., 705, 717.  
 Biesiadecki, A. von, 788.  
 Bignami, A., 590.  
 Bindseidler, 33.  
 Binswanger, O., 94.  
 Birge, E. A., 5.  
 Blix, M., 330.  
 Blumenau, 565, 568, 576, 577, 580, 581.  
 Boedeker, 290.  
 Boehm, A. A., **362.**  
 Bogroff, 830.  
 Bolk, L., 195, **131, 132, 133, 134, 135, 205, 208, 136, 209, 137, 138, 211, 139, 140, 141, 142.**  
 Boll, 7, 104.  
 Bolton, T. L., 531.  
 Bonnet, R., **225, 226, 374.**  
 Born, G., 318, 791.  
 Bouchard, C., 1012.  
 Bonin, 37.  
 Boyce, R., 970, 971, **617, 972, 618, 619.**  
 Braseh, F., 289.  
 Brauer, L., 287.  
 Bregmann, E., 231, 232, **147, 148, 306, 522.**  
 Bregmann, L. E., 930.  
 Brieger, L., 241, 459.  
 Brissaud, E., 201.  
 Broadbent, 1073.  
 Broca, P., 748, 749, 750, 751, 755, 762, 1065.  
 Bruce, A., 456, 458, 461, 565, 569, 587, 608, 609, **406, 637, 717, 459, 933, 598, 1067.**  
 Brunn, A. von, **352, 532.**  
 Bruns, L., 336, 442, 450, 532, 594.  
 Brux, 651.  
 Buck, A. H., 783.  
 Buhler, A., 148.  
 Bumm, 790, 836.  
 Bunting, C. H., **207.**  
 Burdaeh, K. F., 24, 436, 439, 468, 565, 570, 576, 667, 673, 674, 680, 681, 705, 786, 990, 1061, 1063.  
 Busch, C., 601.  
 Butschli, O., 138, 141, 145, 147, 154.  
 Cabannes, C., 289.  
 Cadiat, O., 194.  
 Cajal. See Ramón y Cajal.  
 Calleja, C., 262, 761, **487, 488.**  
 Campacci, G., 306.  
 Carnoy, J. B., 154.  
 Cattani, 246.  
 Cavazzani, E., 358.  
 Ceni, C., 228.  
 Chantemesse, 301, 302.  
 Charcot, J. M., 428, 650, 975, 993, 1005, 1012, 1014, 1065.  
 Chiari, 956.  
 Chiarugi, 928.  
 Chiozzi, L., 290.  
 Chipault, **201.**  
 Christomanos, 413.  
 Ciaccio, G. V., 405, **264, 265, 266, 267, 410, 411.**  
 Ciaglinski, A., 619.  
 Clarke, H., 978.  
 Clarke, J. Lockhart, 172, 463, 474, 504, 576, 581, 851, 913.  
 Coën, 246.  
 Cohnheim, J., **214, 362.**  
 Cole, 921.  
 Colenbrander, 911.  
 Collins, J., 905, 910.  
 Corning, 919, **589, 591.**



- Corti, **112**, 545, 546, 836, 839.  
 Cox, W. H., 10.  
 Crauer, A., 290, 505, 518, 569, 651, 664, 716, 930.  
 Cruveilhier, 229.  
 Cuccati, G., 381, 411.  
 Cushing, Harvey W., 339.  
 Czokor, 368.  
  
 D'Abundo, 402.  
 Dana, C. L., 339, 340, 341, **197**, **198**.  
 Darkschewitsch, L. O., 231, 306, 569, 614, 618, 716, 719, 721, 724, 725, 805, 881, 917, 944, 945.  
 Darwin, Charles, 76.  
 Davidoff, M. von, **362**.  
 Dawson, P. M., 245.  
 Daxenberger, H., 450, 452.  
 Dean, John, 504, 851.  
 Deaver, J. B., 1002.  
 Deen, Van, 897.  
 Dees, O., 623.  
 Dehio, 288.  
 Dehler, 148.  
 Deiters, O. F. C., 4, **1**, 5, 12, 102, 122, 131, 504, 505, 507, 508, 509, 511, 512, 523, 568, 575, 630, 631, 632, 636, 637, 638, 849, 960, 964, 965, 966, 967, 968.  
 Dejerine, J., 289, 290, 442, 458, 655, 668, 674, **445**, 705, 707, 716, 731, 732, **511**, **638**, 1044, 1046, 1047, 1059, **668**, 1061, 1062, **669**, 1062, **671**, **672**, 1067, **674**, 1069, **673**.  
 Dejerine, Mme. J., 705, 707, 717, 731, 732.  
 Demoor, L., 418.  
 De Quervain, Fritz, 111, 290.  
 Dereum, F. X., 832.  
 De Witt, Lydia, 417, **275**, 419, **276**, **278**.  
 Dexter, Franklin, 175.  
 Dickinson, 229.  
 Diotima, 220.  
 Disse, J., 184, 526.  
 Dixon, A. F., 525.  
 Dmitrijewski, P., **236**, 382.  
 Dogiel, A. S., 34, 36, 37, 105, 141, 145, 184, **115**, 185, **116**, 262, 365, **216**, **217**, **218**, 370, **240**, **241**, 386, **243**, **244**, 388, 390, 393, **252**, 394, **253**, 400, **259**, **260**, **261**, **262**, 418, 421, 534, 540, 897.  
 Dogiel, J., 418.  
 Dohrn, A., 170, 195, 201.  
 Donaldson, H. H., 42, 80, 251, 275, 531, 1075.  
 Donders, F. C., 835.  
 Driesch, 221.  
 Du Bois-Reymond, E., 252.  
 Dufour, 450, 457, 458.  
 Duret, 1014.  
 Dutil, A., **151**, 238, 290.  
 Duval, M., 100, 942, 947.  
  
 Ebbinghaus, 835.  
 Eberstaller, 754.  
 Eberth, 365.  
 Eckhardt, C., 330.  
 Edinger, L., 10, 29, 38, 44, 254, 316, 463, 523, 565, 569, 590, 598, 599, 664, 715, 748, 764, 766, **489**, 775, **500**, 804, 902, 908, 933, 942, 944, 945, 1056, 1058.  
 Ehrenberg, 3.  
 Ehrlich, P., 31, 32, 33, 36, 37, 47, 67, 101, 127, 128, 186, 241, 365, 394, 402, 411, 459, 530, 897.  
 Eisenlohr, 413.  
 Eisler, P., 195, **186**, **187**.  
 Emmert, 3.  
 Engelmann, 142, 157, 359.  
 Erb, 244, 899.  
 Erlanger, J., **150**, 237, 295, **176**, 308, 911.  
 Eve, F. C., 278.  
 Ewart, 921.  
 Ewing, J., 289.  
 Exner, S., 252.  
  
 Ferrier, D., 565, 570, 572, **383**, 573, **384**, **385**, 580, **394**, 655, 708, 717, 823, 899, 900, 964, 973, 994, 995, 996, 997, 1000, 1028, 1047, 1055.  
 Fieschi, D., 246.  
 Fischer, A., 131, 141.  
 Fish, P. A., 43.

- Flatau, E., 231, 235, **149**, 277, 280,  
 285, 286, 289, **174**, **178**, 301, **179**,  
 302, **180**, **181**, **182**, 306, 308, 310,  
 450, 458, 911, 914, 953, 1009, **640**.  
 Flechsig, P., 25, 44, 87, 89, 92, 244,  
 256, 265, 316, 424, 425, **280**, 427,  
 428, 429, **281**, **282**, 430, 436, 452,  
 453, 458, 461, 463, 473, 504, 505, 509,  
 563, 568, 575, 577, 581, 583, **389**,  
**391**, 592, 593, 598, 605, 608, 609,  
 614, 647, 657, 667, 681, 684, 685, 686,  
 688, 689, 697, 699, 700, 702, 703, 704,  
 705, 707, 714, 715, 721, 730, 731, 733,  
 734, **466**, **736**, **467**, **468**, 738, 753,  
 759, 772, 806, 816, **525**, 822, 823, 830,  
 836, 837, 843, 852, 875, 876, **561**,  
 878, 963, 974, 976, 980, **625**, 986,  
 987, **626**, **627**, **628**, **629**, 991, **630**,  
 992, **631**, 993, 1010, 1020, 1021,  
 1040, 1045, 1047, 1065, 1070, 1071,  
**675**, 1073, **676**, 1074, 1075, 1076,  
 1077, 1078, 1079, 1081, 1082, 1083.  
 Fleming, R. A., 232.  
 Flemming, W., 104, 105, **63**, 113, 135,  
 141, 145, 154, 156, 281.  
 Flesch, M., 123.  
 Flexner, Simon, 247, 297.  
 Foerster, 826, 828.  
 Forel, A., 9, 15, 17, 18, 20, 22, 26, 231,  
 651, 653, 655, 657, 668, **435**, 670,  
**436**, 671, 672, **437**, 673, **438**, 674,  
 675, 682, 684, 685, 686, 692, 704, 727,  
 730, 731, 732, 772, 798, 805, 812, 836,  
 841, 873, 971, 1067, **673**, 1067.  
 Forgue, E., 900.  
 Forster, Laura, 412, 413, 414.  
 Foster, M., 86, 554, 963, 965.  
 Fraenkel, 413.  
 Franck, F., 983, 1003, 1022.  
 Franeke, C., 42.  
 Francotte, 591.  
 Frankl-Hochwart, 747.  
 Franklin, Mrs. Christine Ladd, 835.  
 Freud, S., 569, 716.  
 Frey, M. von, 253, 255, 330, 372, 392.  
 Friedlaender, C., 229, 1075.  
 Friedmann, M., 290.  
 Fritsch, G., 994.  
 Frommann, 102, 154.  
 Froiep, 350, 927.  
 Fürbringer, M., 195, 920.  
 Fürstner, 983.  
 Fusari, 962.  
 Gad, J., 235, 258, 1009, **640**.  
 Galeotti, G., 141.  
 Ganser, S., 668, 761, 767, 768, 784, 788,  
**506**, 798, 807.  
 Gardiner, 7.  
 Gaskell, 888.  
 Geberg, A., 370, **223**, **224**.  
 Gebhard, F., 716.  
 Gegenbaur, 195, 919, 921.  
 Gehuchten, A. van, 9, **5**, **15**, 29, 45,  
**31**, **34**, **48**, **55**, 142, 144, 171, 182,  
**110**, **114**, 184, 254, 260, 261, 262,  
**158**, 266, 270, 299, 309, **194**, **195**,  
**196**, 215, 365, 374, 375, **292**, 465,  
 467, **303**, **304**, 499, 500, 514, **342**,  
 523, 530, 546, 606, 618, 650, 673, 675,  
**454**, 721, 725, 775, 803, 826, **530**,  
 832, 885, 914, 926, 932, **599**, 942,  
 945, **605**, **624**, 985.  
 Gennari, 821, 1058.  
 Gerlach, J. von, 5, **2**, 6, 7, 13, 42, 60,  
 463, 884.  
 Giese, 450.  
 Gieson, Ira van, 108, 110, 142, 155,  
 239, 522.  
 Gilbert, 229.  
 Gildersleeve, Basil L., 40, 667.  
 Goepfert, 35.  
 Goethe, Johann Wolfgang von, 221.  
 Goldscheider, A., 251, 253, 255, 277,  
 280, 285, 286, 289, **178**, 301, **179**,  
 302, **180**, **181**, **182**, 307, 308, 309,  
 330.  
 Golgi, C., 9, 10, 11, 12, 13, 14, 15, 17,  
 18, 21, 22, 25, 26, 28, 29, 36, 37, 42,  
 47, 48, 50, 63, 64, 67, 68, 75, 76, 78,  
 79, 80, 81, 82, 84, 90, 93, 94, 96, 98,  
 101, 115, 139, 140, **78**, **150**, **85**, 152,  
 153, 172, 184, 239, 240, 257, 258, 259,  
 261, 265, 270, 317, 365, 370, 374,  
 376, 378, 386, 392, 394, 396, 402,  
**263**, 405, 409, 410, 411, 424, 430,

- 457, 459, 461, 464, 465, 466, 467,  
468, 470, 473, 511, 518, 526, 530, 531,  
534, 580, 632, 636, 637, 659, 664, 667,  
694, 719, 725, 738, 768, 775, 784, 791,  
800, 803, 812, 823, 832, 840, 843, 852,  
859, 862, 870, 872, 875, 885, 887, 892,  
932, 947, 952, 968, 974, 976, 979, 986,  
1033, 1034, 1036, 1053.
- Goll, 24, 424, 425, 427, 428, 429, 430,  
433, 435, 436, 439, 564, 705.
- Goller, A., 835.
- Goltz, 705.
- Gombault, A., 442, 450, 452, 453, 454,  
456, 458, 461.
- Gotch, F., 274.
- Gowers, W. R., 45, 589, 590, 591, 592,  
593, 594, 598, 599, 601, 602, 604, 605,  
640, 740, 786, 960, 972, 973, 1037,  
1039.
- Graf, A., 155.
- Grandry, M., 369, 370, **222**.
- Grashey, H., 231, 785, **514**.
- Gratiolet, 667, 814, 816, 823.
- Greiwe, J., 717.
- Grigorieff, 229.
- Gruetzner, P., 790, 792.
- Grünbaum, A. S., 418.
- Guarnieri, G., 590.
- Gudden, B. von, 18, 44, 106, 231, 306,  
308, 654, 697, 755, 767, 772, 777, 784,  
785, 786, 787, **504**, **505**, 790, 791,  
793, 796, 798, 804, 805, **514**, 807,  
831, 899, 942, 945, 950, 1022.
- Gudden, H., 517.
- Haberlandt, 307.
- Haeckel, 65.
- Haller, B., 7, 17, 38, 64.
- Halliburton, W. D., 132.
- Hallopeau, 983.
- Hamaker, J. I., 149.
- Hamilton, Aliee, **500**, 781.
- Hamilton, D. J., 1055.
- Hanmarberg, C., 822, **528**, 878, **563**,  
978, 979, **623**.
- Hammond, G., 905, **583**.
- Hampe, 244.
- Hannover, 787, 805, 807.
- Harris, H. F., **130**.
- Harrison, R. G., **96**, 195, 202, 203,  
**919**.
- Hasse, C., 328, **201**.
- Hayem, 229.
- Hayez, F., 651.
- Head, H., 198, 339, 340, 341, **199**, **200**,  
346.
- Heard, J. D., 1022.
- Heidenhain, M., 281.
- Held, H., 4, 38, 47, 48, **18**, **19**, **20**, 50,  
**21**, **22**, 67, **49**, 85, **54**, 89, 94, **58**,  
109, 111, 128, 129, 130, **75**, 131, **76**,  
**77**, 132, 133, 134, 140, 141, 143, 144,  
**81**, **82**, 145, 147, **83**, **86**, 153, 155,  
156, 218, 235, 241, 265, 281, 319, 480,  
484, **326**, **327**, 501, 505, 511, 514,  
**368**, **369**, 555, 577, 580, 609, 615,  
618, 632, **418**, 637, **422**, 655, 675,  
725, 772, **493**, **494**, 804, 812, 832, 836,  
837, **535**, 839, 842, 843, 849, 851,  
853, 854, 855, 857, **546**, **547**, 862,  
**551**, 864, 866, **554**, 868, **555**, **556**,  
**557**, 872, **570**, 947, **606**, 950, 969,  
**616**, 972.
- Helmholtz, H., 3, 787, 835.
- Helweg, 954, 957, 958.
- Henle, J., 3, **340**, **372**, **373**, **374**, **375**,  
**376**, **377**, 787, 796, **509**, **524**, 890,  
**588**.
- Henri, 330.
- Henschen, S. E., 717, 793, 826, 827,  
828, 832.
- Hensen, V., 949.
- Heraclitus, 220.
- Herbart, 1076.
- Herbst, G., 221, 393.
- Hering, E., 835.
- Hermann, **347**.
- Herrenheiser, 793.
- Herriek, C. J., 5, 44, 781, 921, 922,  
**592**, 924, 1056.
- Herriek, C. L., 1056.
- Herringham, W. P., 332.
- Herter, 241.
- Hertwig, O., 65, 154, **125**.
- Hess, P., 289.
- Heubner, 1076.

- Hewetson, John, **308, 309, 310, 311, 312, 313, 314, 315, 316, 317, 318, 319, 320, 321, 322, 323, 324, 328, 378, 380, 381, 405, 414, 415, 416, 420, 426, 427, 430, 447, 448, 449, 452, 453, 461, 462, 463, 537, 538, 539, 552, 595, 596, 597, 601, 602, 603, 612.**
- Heymans, J. F., 418.
- Hill, A., 11, 77.
- Hill, W., 3, 9, 15, 16, 17, 20, 22, 26, 44, 70, 94, 136, 159, **89, 160, 90, 91, 92, 164, 93, 94, 165, 166, 95, 167, 168, 169, 170, 171, 98, 172, 100, 102, 103, 104, 105, 177, 179, 180, 181, 183, 113, 190, 194, 195, 212, 214, 225, 266, 273, 317, 202, 203, 424, 307, 501, 513, 537, 748, 749, 750, 751, 755, 774, 496, 784, 587, 1083.**
- Hill, W., Jr., **117, 123, 191, 330, 331, 514.**
- Hitzig, E., 994, 1081.
- Hoch, A., 244, 290, 291, 292, 293, 306.
- Hoehe, A., 450, **296, 453, 454, 297, 298, 456, 299, 457, 458, 462, 301, 302, 398, 598, 602, 615, 617, 985, 1016, 1017, 643, 1020, 644, 1022.**
- Hochhaus, H., 1067.
- Hodge, C. F., 275, **163, 277, 164, 165, 166, 279.**
- Hoen, A. G., 11, 126, **96, 122.**
- Hoesel, 44, 644, 697, 699, 702, 703, 704, 707, 714, 717, 731.
- Hoffmann, J., 717.
- Hofrichter, E., 442.
- Holm, H., 621, **408.**
- Holmgren, 46.
- Homén, E. A., 227, 229, 230.
- Honegger, 727, 732.
- Horsley, V., 274, 415, 441, 994, 995, 996, **632, 997, 633, 999, 634, 1000, 1001, 635, 1002, 1003, 636, 637, 1007, 1008, 639, 1024, 1047.**
- Howell, W. H., 227, 245.
- Huber, G. Carl, 36, **66, 114, 227, 245, 416, 417, 275, 419, 276, 278, 892.**
- Hun, H., 522.
- Huxley, T. H., 65, 195, 921.
- Izquierdo, 400.
- Jackson, J. Hughlings, 993, 996.
- Jacobi, M. P., 1083.
- Jacobsohn, L., 280, 786.
- Jacques, P., 402, 419.
- Jakob, C., 705.
- Jakovenko, V., 718.
- Johnston, J. B., 921.
- Joseph, 258.
- Jowett, B., 220.
- Juliusburger, 290.
- Kaes, T., 1070.
- Kahler, O., 439, 948.
- Kaiser, O., 884, 885, 905, **578, 579, 580, 581, 582, 914.**
- Kallius, E., 360, 368, 394, 400, 897.
- Kam, 1046.
- Karnsin, P., 424, 430.
- Kästner, S., 201.
- Kaufmann, E., 1067.
- Keen, W. W., 1002, 1071.
- Kellermann, M., 786.
- Kelly, A. O. J., 43.
- Kempner, W., 301.
- Kersehner, L., 412, 413, 415.
- Key, E. A. H., 104.
- Kingsbury, B. F., 921.
- Klimoff, I. A., 665.
- Knapp, P. C., 346, **201, 349.**
- Knies, 832.
- Knoblauch, 983.
- Kocher, T., 339, **201.**
- Kolk, Schröder van der, 851.
- Kölliker, A. von, 3, 5, 9, **4, 6, 11, 26, 28, 29, 14, 39, 40, 35, 78, 79, 40, 46, 81, 50, 51, 52, 90, 92, 56, 94, 100, 102, 142, 148, 155, 167, 106, 111, 256, 258, 259, 261, 266, 270, 462, 463, 465, 467, 468, 474, 475, 477, 480, 501, 511, 514, 518, 523, 351, 554, 577, 581, 606, 618, 621, 632, 636, 637, 641, 655, 668, 674, 675, 676, 439, 679, 725, 755, 756, 478, 479, 480, 481, 482, 483, 484, 485, 486, 766, 767, 768, 490, 770, 775, 497, 777, 779, 783, 790, 793, 800, 801,**



- 513**, 807, 808, 809, **518**, 822, 832, 837, 841, 843, **536**, 851, 852, 853, 859, 862, 865, **553**, 868, 895, 928, 942, 945, **607**, **608**, 968, **621**, 979, 1036, 1082.  
 Kollmann, J., 88, 165, **99**, **117**, **118**, **119**, **123**, **126**, **127**, **129**, 202, **307**, **331**, 587, 919, **589**, **590**, **591**.  
 Korolow, P., **230**, 381.  
 Korschelt, E., 307.  
 Koshewnikow, 231.  
 Kossel, A., 142.  
 Kraepelin, E., 244.  
 Krause, R., 500.  
 Krause, W., 229, 230, 331, 386, 392, 393, 412, 541, 784, 785, 895, 899.  
 Kries, J. von, 835.  
 Kromayer, 64.  
 Kronenberg, 897.  
 Kronthal, 105.  
 Kühne, W., 400, 412, 413, 895, **574**, 896, **575**, **576**.  
 Kupffer, C. von, 63, 136, 165, 919.  
 Kusick, 983.  
  
 Laborde, J. V., 942, 947.  
 Lambert, M., 278.  
 Laneisi, 764.  
 Lange, 442.  
 Langley, J. N., 441, 1023.  
 Laslett, E. E., 288.  
 Laura, 584.  
 Lavdowsky, 36.  
 Leaming, 10, 1033, **656**.  
 Lebrun, H., 154.  
 Lenhossék, M. von, 9, 15, 21, 25, **12**, 28, 29, 36, 37, 39, **32**, 73, 74, **36**, 79, **41**, 81, 90, 91, **55**, 92, 93, **57**, 94, 105, 109, **64**, 110, 111, 112, **65**, 113, 130, 139, 148, **84**, 155, **101**, 179, **109**, 184, 188, 252, 258, 260, 262, 265, 266, 267, 269, 270, **161**, 307, 308, 309, 316, 358, **209**, **210**, 430, 446, 450, 458, 459, 463, 465, 467, 568, 470, 471, 472, **306**, 473, 474, 475, 500, **333**, **329**, 526, 527, **348**, 543, **360**, **363**, 582, **388**, 590, 606, **400**, 885, **567**, 887, 905, 985.  
 Leonowa, O. von, 179, 785, 823.  
 Lepage, 983.  
 Lenbe, W., 949.  
 Levi, G., 143.  
 Lewis, Bevan, 294, 078.  
 Lewis, Margaret, 149.  
 Lewis, Morris J., 1003.  
 Leyden, E., 832.  
 Leydig, F., 102, 147, 273.  
 Liehtheim, 1076.  
 Lilienfeld, 132, 133.  
 Lissauer, H., 423, 425, 427, 430, 435, 436, 466, 468, 474.  
 Lloyd, J. H., 1002.  
 Loey, W. A., 195.  
 Loeb, J., 221, 247, 316.  
 Loewenthal, N., 444, 592, 602, 716, 957, 963, 965, 970.  
 Lord, J. R., 293.  
 Loven, 525.  
 Lubarsch-Ostertag, 164, 239.  
 Luciani, 246, 1000.  
 Luderitz, C., 884.  
 Ludwig, 5.  
 Lugaro, E., 143, 153, 156, 278, 279, 285, **172**, 289, 290, 310, **183**, 311, **184**, 358, 523, 665, 932, 935.  
 Luys, J., 667, 671, 672, 673, 674, 680, 694, 700, 702, 705, 707, 734, 738, 783, 989.  
  
 Macallum, A. B., 132, 133, 134, 218, 365.  
 MacCallum, J. B., 147.  
 Mackenzie, J., 339.  
 Magini, 279.  
 Mahaim, A., 580, 619, 651, 653, 654, 655, 697, 700, 701, 707, 716, 731, 806.  
 Mall, F. P., 178, **107**, **108**, 181, **120**, **124**, 194, 195, **130**, 204, 266, 267, 338, 784, 791, 866, 1024.  
 Mallory, 64.  
 Mandelstamm, E., 788.  
 Manersi, 288.  
 Mann, G., 68, 129, 278, **168**, 583, 1083.  
 Mann, L., 451.  
 Manz, 784.

- Mareacci, A., 900.  
 Marchand, F., 786, 792.  
 Marchesini, 136.  
 Marchi, V., 45, 107, 232, 235, 238, 241, 242, 438, 443, 444, 447, 450, 453, 456, 458, 459, 461, 462, 463, 513, 553, 570, 573, 575, 592, 593, 594, 598, 599, 601, 603, 617, 654, 655, 657, 659, 664, 665, 694, 709, 712, 793, 795, 810, 841, 963, 964, 965, 966, 971, 985, 1014, 1016, 1022, 1023.  
 Marguliés, A., 442, 443, 444, **293**.  
 Marie, P., 355, 447, **294**, 450, 457.  
 Marina, A., 239.  
 Marinesco, G., 45, 229, 230, **146**, **173**, 289, 290, 295, 299, 301, 302, 303, 308, 309, 462, 623, 911.  
 Mark, E. L., 921.  
 Marshall, H. T., 245.  
 Marshall, John, 179.  
 Martin, J., 261.  
 Martin, P., 505, 659, 664, 849, 927.  
 Martinotti, C., 153, 976.  
 Masetti, E., 288.  
 Masius, Jean, 37.  
 Mayer, C., 34, 442, 717.  
 Mayer, P., 201.  
 Mayser, 231.  
 Mazzoni, 392, 396, 411.  
 McClure, C. F. W., 149.  
 Meder, E., 717.  
 Meissner, G., 78, 82, 191, 225, 384, 386, 390, 392.  
 Melkich, 411, **270**.  
 Mellus, E. L., 107, 983, 1023, 1024, **645**, **646**, **647**, **648**, **649**, 1028, **650**, **651**, 1080, **652**, **653**, 1032, **654**, 1055.  
 Mendel, E., 231, 664, 831, 950.  
 Menidia, 924.  
 Menzel, 655.  
 Merkel, F., 188, 360, 366, 367, 368, 369, 374, 377, 384, 541, 855, 938.  
 Merkel-Bonnet, 12, 164, 360, 424.  
 Meyer, A., 155, 781, **622**, 1055, 1056.  
 Meyer, C., 443.  
 Meyer, P., 716, 954.  
 Meyer, S., **545**, 857.  
 Meynert, T., 42, 98, 502, 667, 668, 670, 672, 685, 689, 713, 714, 715, 725, 732, 741, 772, 775, 777, 783, 805, 812, 868, 873, 971, 1058, 1068.  
 Michel, J. von, 788, 789, 791.  
 Mihalkovies, Von, 790.  
 Millon, 132.  
 Mills, C. K., 161, 668, 1039, 1047.  
 Mingazzini, G., 475, 654, 717, 731.  
 Minot, C. S., 40, 164, 748.  
 Mirto, 657.  
 Mislawsky, N., 267.  
 Misslawsky, 614.  
 Möbius, P. J., 244.  
 Moeli, C., 983, 1022.  
 Monakow, C. von, 18, 28, 44, 504, 580, 588, 650, 651, 657, 667, 668, 674, 679, 680, 681, **440**, 682, **441**, **442**, 685, **444**, 686, 689, 693, 697, 698, 700, 701, 702, 707, 716, 727, 730, 731, 768, 784, 785, 798, **510**, 800, 802, 814, **521**, 815, **522**, **523**, 817, **526**, 822, 823, **529**, 826, 827, **531**, **532**, 830, 833, 836, 837, 841, **540**, 849, 852, 853, 861, **550**, 862, 868, 873, **559**, 875, **564**, 881, 949, 974, 1012, **641**, **642**, 1022, 1034, 1036, **660**, **661**, 1044, 1045, 1046, 1048, 1052, 1081, 1082.  
 Mondino, 246.  
 Monroe, 774.  
 Montgomery, T. H., 145.  
 Monti, A., 71, 132, **152**, 239, 246, 285, 290.  
 Morgenstern, M., 379, 381.  
 Morill, A. D., 36.  
 Mott, P. W., 251, 299, 441, 444, 463, 570, 574, 580, 583, 590, **395**, **396**, 594, 598, 599, 600, 601, 602, 701, 717, 888, 983.  
 Mourek, J., 288.  
 Muir, R., 456, 458, 461.  
 Müller, E., 104, **231**, 382, 402.  
 Müller, F., 717.  
 Müller, G. E., 835.  
 Müller, Heinrich, 10, 443.  
 Müller, Johannes, 255, 787, 897.  
 Müller, Wilhelm, 587, 539.

- Munk, H., 232, 607, 733, 792, 825, 976, 1000, 1047.  
 Munzer, E., 241, **292**, 439, 441, 443, 459, **800**, 570, 580, 717, 786, 795.  
 Muratoff, W., 983, 1023, 1055, 1069.  
 Nägeli, 65, 154.  
 Nageotte, J., 442, 443.  
 Nanerode, C. B., 1003.  
 Nansen, F., 17, 147, 257.  
 Nasse, 223.  
 Neal, H. V., 195.  
 Neppi, A., 303, 306.  
 Nicati, W., 790.  
 Nicholls, J., 289.  
 Niernack, 365.  
 Nissl, F., 45, 62, 67, 96, 97, **59**, 98, **60**, **61**, 104, 105, 106, 107, 108, 109, 110, 111, 113, 115, 116, **67**, 117, **68**, 118, **69**, 119, **70**, **71**, 120, 121, **72**, 122, 123, 124, 125, 127, 128, 129, 130, 133, 134, 135, 136, 138, 139, 140, **87**, 155, 156, 157, 231, 233, 234, 235, 238, 239, 242, 245, 280, 281, 282, 283, **169**, 284, **170**, 285, **171**, 287, 291, 292, 293, 295, 297, 299, 302, 303, 306, 308, 311, 358, 623, 632, 667, 676, 677, 678, 679, 680, 808, 875, 888, **569**, 910, 911, 914, 929, 950.  
 Nothnagel, H., 747, 1012.  
 Notthaft, A. von, 227.  
 Nussbaum, 46, 195.  
 Obersteiner, H., 108, 451, 452, 461, 518, 523, **387**, **390**, 614, 632, 804, 930, 933, 942, 947.  
 Oddi, R., 441, 444.  
 Onufrowicz, B., 502, 836, 841, 1067, **673**.  
 Orru, E., 376.  
 Osborn, H. F., 1056.  
 Osler, William, **199**, **200**, 1039.  
 Ostroumow, P., **228**, 377.  
 Ottolenghi, D., 290.  
 Owsiannikow, P., 260.  
 Pacini, 390, 393.  
 Pal, 34.  
 Paladino, G., 444.  
 Pándi, K., 288.  
 Panizza, B., 807, 900.  
 Paterson, A. M., 195, 201, 332.  
 Patrick, Hugh T., 462, 584, 589, 594, **397**, 601, 603.  
 Peláez, P. L., 465.  
 Pellizzi, G. B., 444.  
 Peretti, 830.  
 Pergens, E., 280.  
 Perlia, 942, 943, 944, **604**, 945.  
 Peyer, J., 330, 899.  
 Pfeiffer, R., 442, 443.  
 Pflueger, 147.  
 Philippe, Cl., 446, 450, 452, 453, 454, 456, 458, 461.  
 Piccolomini, 840.  
 Piek, A., 793, 949, 956, 957, 1022.  
 Pierret, 428, 473, 1012.  
 Pilez, 108.  
 Pinkus, 921.  
 Pitres, A., 983, 1003, 1022.  
 Plato, 47, 220.  
 Platt, Julia B., 195.  
 Pollack, B., 301.  
 Popoff, N., 246, 290.  
 Pribytkow, G., 805.  
 Pognat, C. A., 278.  
 Purkinje, 120, 212, 135, 138, 139, 967.  
 Purtscher, O., 786.  
 Pusateri, E., 289, 402.  
 Rabl, 919.  
 Rabl-Rückhard, H., 100.  
 Ramón, D. S., 775.  
 Ramón y Cajal, P., 800, 811.  
 Ramón y Cajal, S., **3**, 9, 10, 20, 21, **8**, **22**, **23**, **9**, **10**, **24**, **25**, **26**, **28**, **29**, **36**, **37**, **70**, **33**, **77**, **81**, **42**, **43**, **82**, **44**, **47**, **84**, **92**, **94**, **97**, **128**, **141**, **142**, **166**, **97**, **184**, **186**, **260**, **261**, **262**, **157**, **266**, **269**, **270**, **206**, **232**, **382**, **402**, **459**, **465**, **467**, **468**, **470**, **305**, **474**, **480**, **484**, **487**, **329**, **500**, **502**, **334**, **505**, **511**, **512**, **338**, **514**, **518**, **343**, **346**, **522**, **523**, **350**, **530**, **534**, **354**, **537**, **356**, **357**, **358**, **540**, **359**, **370**, **371**, **555**, **564**, **577**, **582**, **606**, **618**, **409**, **410**, **626**, **627**,

- 629, **412**, **413**, 631, 632, **417**, 637, **419**, 640, 641, 642, **421**, 644, 654, 659, 662, **433**, 663, **434**, 664, **460**, **464**, **465**, 768, 769, 770, **491**, **492**, 772, 784, **503**, 795, 800, **512**, 803, 809, 810, 811, **519**, **527**, 821, 822, 832, 833, 837, 842, 843, 847, **541**, **542**, 853, 854, 855, 857, 858, 859, **548**, **549**, 862, 864, 865, 866, 889, **571**, 926, **594**, 935, **600**, 938, 967, 972, 979, 1033, **655**, 1054, **665**, 1058, **667**, 1083.
- Rauber, A., 40, **125**, **128**, 209, **185**, **186**, **187**, **188**, **189**, **190**, **350**, **204**, **205**, **235**, **277**, **340**, **364**, **428**, **456**, **572**, **588**, **666**.
- Ranvier, L., 3, **53**, 104, 183, 184, 224, 227, 306, 333, **254**, 413, 470, 855.
- Ravn, E., 194.
- Rawitz, 17, 143.
- Redlich, E., 446, 452, 473, 1036.
- Reich, M., 788.
- Reichert, 697.
- Reid, 892.
- Reil, 667, 671, 688, 692, 697, 714, 717, 750, 1044, 1072, 1074.
- Reinhold, 956.
- Reisner, A., 421.
- Remak, R., 3, 102, 142, 197, 899, 900.
- Retzius, G., 9, 29, 34, **16**, 36, 73, 90, 104, 188, 262, 266, **159**, 269, **160**, 356, **208**, 361, **211**, **212**, 374, **227**, 376, **229**, 378, **233**, 394, **256**, **257**, **258**, 421, **279**, 465, 499, **332**, 526, **361**, 546, **364**, 751, **473**, 752, **474**, **475**, **476**, 754, **477**, 897.
- Reuter, 919, **590**.
- Riese, H., 34.
- Rolando, 24, 116, 473, 474, 606, 888.
- Roller, C. F. W., 502, 614, 621.
- Romberg, 191.
- Rose, C., 381.
- Rosenheim, S., **144**, **145**, 448, **295**.
- Rosenthal, 3.
- Rosin, H., 107, 108, 127, 128, 135.
- Ross, James, 339, 340, 341.
- Rossi, U., 441, 444.
- Rossolimo, G. J., 601, 602, 604, 716.
- Roux, W., 155, 247.
- Roth, 413.
- Rothmann, 983.
- Rubner, M., 249.
- Rüdinger, **340**, **588**.
- Ruffini, Angelo, **245**, **246**, 390, **247**, 391, **248**, **249**, 392, **250**, 396, **255**, **416**, **273**, **274**.
- Ruge, 195.
- Rumpf, Th., 308.
- Russell, J. S. R., 598, 632, 655, 901, 902, 914, 964, 968.
- Ryder, J. A., 202.
- Sabin, Florence R., 318, **325**, 504, 505, **335**, 507, 508, 509, 549, **367**, 568, **407**, **411**, 632, 690, 694, 721, 777, 837, 843, **593**, 943, 958, **611**.
- Sabrazès, J., 289.
- Sacerdotti, C., 239, 290.
- Saehs, B., 668.
- Saehs, H., **520**, 815, 823, 1059, 1060, **1061**, 1082.
- Saehs, K. von, 155, 372.
- Saehs, S., 826, 828.
- Saehs, Z., 830.
- Sadovsky, S., 235.
- Sala, C. L., 259, 260, 505, 632, 849.
- Salzer, F., 785.
- Sanete de Sanctis, **392**, **393**.
- Sanderson, J. B., 1003.
- Sandmann, G., 894.
- Sandmeyer, 983.
- Sano, F., 911, 912, **585**, **586**.
- Sarbó, A., 288.
- Saxter, F., 717.
- Scarpa, 499.
- Schäfer, E. A., 28, 29, 39, 40, **47**, **53**, 307, 594, 963, 979, 994, 996, 997, **633**, 999, **634**, 1000, 1047.
- Schaffer, K., 111, 149, 290, 444, 458, 462, 471, 592, 716.
- Schaper, A., 167, 168.
- Schiefferdecker, P., 89, 142, **79**, **239**, 441, 446, 884, 894, **573**, 896.
- Schiff, 1000.
- Schleiden, 2.



- Schlesinger, H., 684, 717.  
 Schmaus, F., 446.  
 Schmidt, 541.  
 Schmidt-Rimpler, H., 786.  
 Schnopfhagen, 805.  
 Schröder, A., 716.  
 Schreiber, 46.  
 Schultze, Fr., 142, 442, 448, 450, 451, 458, 716.  
 Schultze, H., 141.  
 Schultze, Max, 4, 102, 103, **62**, 112, 137, 140, 141, 142, 504, 529, **353**.  
 Schulze, F. E., 365.  
 Schwabe, H., 911, 950, 951.  
 Schwalbe, G., 79, 104, 170, 505, 525, 748, 750, 884.  
 Schwann, 2, 784.  
 Sciamanna, E., 1002.  
 Selavunos, G., **235**, 382.  
 Scott, 133, 134.  
 Sedgwick, A., 44.  
 Sfameni, P., 392.  
 Sherrington, C. S., 66, 86, 251, 299, 332, 333, **191**, **192**, **193**, 336, 337, 338, 341, 415, 463, 554, 576, 983, 1023, 1024.  
 Shimamura, S., 241, **155**.  
 Shore, 921.  
 Shukowski, **670**.  
 Siegfried, 132.  
 Siemerling, E., 792, 949.  
 Sihler, C., 417, 896.  
 Singer, J., 439, **292**, 441, 443, 570, 580, 717, 786, 795.  
 Sioli, 1048.  
 Smirnow, A., 15, 34, 36, 269, 386, **242**, **268**, 411, **269**.  
 Smith, G. E., 1056.  
 Soerates, 220.  
 Sölder, F. von, 463, 598, 601.  
 Sottas, J., 442.  
 Soukhanoff, S., 290.  
 Souques, A., 442, 462.  
 Spencer, Herbert, 7, 65.  
 Spiller, 415, 458, 1044, 1047.  
 Spiras, 184.  
 Spitzka, E. C., 699, 716, 851, 852, 942, 947, 949, 1021.  
 Spronck, 241.  
 Staderini, 926.  
 Stannius, 224.  
 Starr, M. Allen, 10, 339, 340, 902, 903, 942, 949, **656**.  
 Stein, Gertrude, 721, 725, 875.  
 Steiner, J., 316.  
 Stephen, Leslie, 221.  
 Stieda, 424, 930.  
 Stilling, B., 172, 474, 581, **423**, **650**.  
 Stirling, 45.  
 Stöhr, A., 155.  
 Stricker, S., 102, 668, 783.  
 Stroebe, H., 245, 290.  
 Strong, C. S., 10, 29, 921, 1033, **656**.  
 Strossner, 413.  
 Strümpell, A., 243, 244, 423, 428, 448, 473.  
 Swierezowsky, 279.  
 Sylvius, 724, 938, 997.  
 Symington, J., 1056.  
 Szymonowicz, W., 36, 365, 368, **220**, **221**, 383, **238**, 384, 392, **251**.  
 Tamburini, 246, 976.  
 Tanzi, 100.  
 Tartuferi, F., 38, 534, 540, 784, 800, 804, 809, 810.  
 Tedeschi, A., 246, **156**.  
 Testut, 598.  
 Teuscher, R., 9, 405.  
 Thoma, **143**.  
 Thomas, A., 290, 442, 513, 553, 655, 657, 841, 966, 967, 968.  
 Thomas, H. M., 1071.  
 Thorburn, W., 194, **195**, 339, 340, **196**.  
 Tigges, 246.  
 Timofeew, D., **234**, 382, **237**.  
 Tirelli, V., 246.  
 Tomsa, 279.  
 Tooth, H. H., 227, 439, 441, 446, 450, 457, 591.  
 Trepinski, 424, 430, 432, 433, 434, 435, 436, 437.  
 Trinchese, S., **272**, 415.  
 Tumarzew, 418.

- Türk, L., 225, 227, 306, 331, 332, 732, 1012, 1045.  
 Turner, W. A., 523, 565, 570, 572, **383**, 573, **384**, **385**, 580, **394**, 650, 655, 708, 717, 747, 748, 749, 964, 965, 973, 1055.  
 Tschermak, A., 318, 319, 320, 568, 570, 575, 601, 602, 603, 604, 615, 617, 618, 681, 682, 683, 684, 685, 694, 701, 702, 703, **455**, 704, 708, 709, **457**, **458**, 711, 712, 713, 714, 715, 741, 960, 969, 970, 972, 973.  
 Tschisch, W. F. von, 674, 676, 681, 736.  
 Unverricht, 983.  
 Uskow, N., 194.  
 Valentin, G., 223.  
 Valentine, 3.  
 Vanlair, 229, 230.  
 Vas, F., 278, **167**, 288.  
 Vater, 393, 396.  
 Vejas, P., 654, 716.  
 Veratti, 140.  
 Vesalius, 795.  
 Violet, N., 1059, 1061.  
 Vicq d'Azyr, 671, 768, 771, 821, 878.  
 Vieussens, 594.  
 Vignal, W., 167.  
 Virchow, R., 215.  
 Vitzon, A. N., 246.  
 Völckers, C., 949.  
 Vollmer, E., 421.  
 Vulpian, 229.  
 Wagner, R., 3, 384.  
 Waldeyer, W., 5, 12, 29, 39, 40, 42, 43, 47, 60, 63, 154, 235, 266, 400, 463, 473, 884, 888, 904, 913.  
 Wallenberg, A., 646.  
 Waller, A., 18, 224, 227, 228, 233, 306, 308.  
 Walsh, J., 332.  
 Walter, G., 261.  
 Warrington, W. B., 45, 133, 240, 288, **177**, 299, 309, 914.  
 Watase, 149.  
 Weigert-Pal, 627, 694, 728, 777, 859, 968.  
 Weigert, C., 12, 25, 44, 45, 64, 92, 106, 238, 239, 242, 254, 423, 432, 447, 463, 466, 473, 474, 573, 580, 617, 621, 676, 725, 730, 768, 788, 854, 868, 929, 938, 957, 964, 986, 1023.  
 Weinberg, R., **446**, **456**, **515**.  
 Weismann, August, 155.  
 Weissmann, 413.  
 Welch, William H., 10.  
 Werdnig, G., 716.  
 Wernekinck, 653.  
 Wernicke, C., 671, 814, 818, 830, 832, 1033, 1059, 1069, 1075, 1076, 1077.  
 Wertheimer, 983.  
 Westphal, C., 423, 428, 448, 473, 484, 917, 942, 943, 944, 945, 949.  
 Whitman, C. O., 44.  
 Wiedersheim, 100.  
 Wiener, H., 241, 459, **300**.  
 Wiesener, 154.  
 Wilbrand, H., 826, 827.  
 Wilder, B. G., 40, 161.  
 Wilson, E. B., **84**, 154.  
 Wijhe, J. W. van, 195, **125**, 201, 919.  
 Winkler, C., 1048.  
 Wolfstein, D. I., 43.  
 Wollenberg, 243.  
 Wolter, 102.  
 Worcester, W. L., 311.  
 Worotynski, B., 598.  
 Wright, H. K., 288.  
 Wrisberg, 350.  
 Wundt, W., 258.  
 Yeo, G. F., 899, 900, 1000, 1028.  
 Young, H. H., 37, 421.  
 Zaehner, T., 1044, 1046, 1048.  
 Zappert, J., 451.  
 Zuckerkandl, E., 748.

## SUBJECT INDEX.

The numbers in ordinary type refer to pages in the text in which the subject is discussed: the numbers in black-face type refer to numbers of figures in which the objects are illustrated.

- Abducent nerve, see *N. abducens*.  
 Aberrant bundle (von Bechterew), see  
     *Fasciculus ventro-lateralis superficialis*.  
 Accessory olivary nucleus, see *Nucleus olivaris accessorius*.  
 Acoustic cortical path, direct (Held), 839.  
     tubercle, see *Nucleus N. cochleæ dorsalis*.  
     reflex paths in *formatio reticularis*, 557.  
 Acustico-facial complex, 117.  
 Acustico-lateral component of cerebral nerves, 922.  
 Acute cell disease (Nissl), 291.  
 Adendritic neurones, 73, 74, 36.  
*Aeusere graue Zone*, see *Cappacineæ*.  
     *weise Lage*, see *Stratum zonale colliculi superioris*.  
*Aeuserer Kern* (Burdach), 673.  
 After-brain, see *Myelencephalon*.  
 Agnosia, 1078.  
 Ala cinerea, see *Nucleus ala cinereæ*.  
 Alteration with rarefaction around the nucleus (Hoch), 293.  
 Alveolar zone, inner (Apáthy), 56, 58.  
     zone, outer (Apáthy), 56.  
 Amacrine cells, 82, 44, 537.  
 Ampharkyochrome cell, 118, 119.  
 Ampulla membranacea superior, 361.  
     *membranacea lateralis*, 361.  
     *membranacea posterior*, 361.  
 Amputation, changes in nervous system after, 229.  
 Amygdaloid nucleus, see *Nucleus amygdalæ*.  
 Anaxones, 82, 45.  
 Angeiotome, 196.  
 Angular gyrus, see *Gyrus angularis*.  
 Angulus lateralis, 752.  
 Anophthalmia, congenital, 823.  
 Anosmatic animals, 749.  
 Ansa hypoglossi, 186.  
     *lenticularis*, 685.  
     *peduncularis*, 685.  
 Anterior central gyrus, motor functions of, 995.  
     *cerebral vesicle*, 88.  
     *commissure*, axones of mitral cells in, 758.  
     *commissure*, termination in gyrus hippocampus, 764.  
     *lateral nucleus of thalamus*, 677.  
     *medial nucleus of thalamus*, 677.  
     *nucleus of thalamus*, dorsal and ventral, 679.  
     *olfactory lobe*, 90, 749, 472.  
 Antero-lateral ascending tract, see  
     *Fasciculus ventro-lateralis superficialis* (Gowersi).  
 Apáthy's fibrils, 54.  
     *Elementargitter*, 60, 273.  
 Apáthy, theory of, 273.  
 Apex columnæ dorsalis, 387.  
 Aphasia, 1076.

- Aphasia, optic, 1078.  
 sensory amnesic, 1078.
- Apraxia, 1078.
- Aqueductus cerebri, **315-321**.
- Arched or arcuate fibres, see *Fibræ areolatae*.
- Area of Broca, see *Area parolfactoria*, *parolfactoria Brocæ*, 750.
- Arkyochrome cell, 117, 121, **67**.
- Arkyostichochrome cell, 117, 121.
- Arnold's bundle, 1044.
- Arsenic, action of, on neurones, **169**,  
 • **172**.
- Ascending cerebellar tract, see *Fasciculus spino-cerebellaris*.
- Association centres of cerebral cortex, **675**, **676**, 1073.  
 centres of cerebral cortex, lesions of, 1078.  
 fibres, *lobus occipitalis*, **668**.  
 neurones, **667**.
- Ataxia, sensory, 1077.
- Atrial plexus of heart, **123**.
- Atrophy, indirect, of nerve fibres, 18.
- Auditory conduction paths, 836.  
 conduction paths, neurones of, **565**,  
**566**.  
 conduction paths, nuclei of, 839.  
 ganglion, origin of, 186.  
 nerve, see *N. acusticus*.  
 nucleus, see *Nucleus N. cochleæ*.  
 path, cortical termination of, 878.  
 sense area, 839.  
 sense area, cells in cortex of, 878,  
**563**.
- Avalanche conduction, 84.
- Axis-cylinder process, see *Axone*.
- Axodendrites, 270.
- Axone, **40**, **41**, **62**, **79**, **80-4**, **78**, 103,  
 142, 145.
- Axone-hillock, structure of, **41**, **64**,  
**569**, 82, 111, 169.
- Axopetal impulse, 267.
- Axospongium, **81**, **82**, 144.
- Basis pedunculi, Plate I, **5**, **441**, **442**.
- BATH of Forel, **436**, 670, 730.
- Bethe's staining method, 137, 138.
- Bethe, theory of, 272, 273.
- Betz cell, 978, **622**.
- Biceps musele, cells innervating, 911.
- Bilateral representation in cerebral cortex, 1001.
- Bindearm-Linsenkernstrahlung*, 686.
- Bipolar cells, formation of, **113**, **114**.
- Blindness, mind, 1078.
- Blind spot, see *Papilla nervi optici*.
- Blood supply, effect of alterations in, 217.
- Blumenau's nucleus, 565.
- Bodenplatte*, **100**.
- Body temperature, effect of artificial increase in, **179**, 302.
- Bone segment, 196.
- Botulinus poisoning, 301.
- Boyce's bundle, 972.
- Brachium conjunctivum, **89**, **311**,  
**312**, **313**, **314**, **315**, **318**, **319**,  
**321**, **322**, **323**, **324**, **386**, **414**,  
**416**, **423**, **632**.  
 conjunctivum, cells of, origin of  
 fibres of, 659.  
 conjunctivum, centripetal and cen-  
 trifugal fibres of, 657.  
 conjunctivum, degenerations fol-  
 lowing section of, 653.  
 conjunctivum, dorsal, middle, and  
 ventral bundles of, **424**.  
 conjunctivum, fibres from lemnis-  
 cus lateralis to, 864, **552**.  
 conjunctivum, myelinization of,  
 657, 659, **431**.  
 conjunctivum, terminations of fi-  
 bres of, 730.
- Brachium pontis, **550**.  
 quadrigeminum inferius, 843, 873,  
**559**.  
 quadrigeminum inferius, termina-  
 tions of fibres of, **876**, **561**, **562**.
- Broca, area of, see *Area parolfactoria*.
- Brush cells, **482**.
- Bulb, see *Medulla oblongata*.  
 olfactory, see *Bulbus olfactorius*.
- Bulbo-hypothalamic neurones, 694.
- Bulbo-mesencephalic neurones, 694.



- Bulbo-pontal neurones, 694.  
 Bulbous plexus of heart, 123.  
 Bulbus olfactorius, 529.  
     layers of, 755, 478, 479.  
*Bündel vom Fuss zur Schleife*, 688, 446.  
 Burdach's column, see Fasciculus cuneatus.  
     nucleus, see Nucleus funiculi cuneati.  
 B. T. c. (von Gudden), see Commissura hypothalamica anterior.  
  
 Calcar avis, 673.  
 Calcarine fissure, see Fissura calcarina.  
 Callosomarginal fissure, see Sulcus cinguli.  
 Calyculi gustatorii, 525, 347, 348.  
 Canalis centralis, 308, 915.  
 Cappa cinerea of superior colliculus, 809, 810, 519.  
 Capsula, externa, 638.  
     interna, hæmorrhage into, 1014, 641.  
     interna, motor fibres in, 980, 987.  
     interna, retro-lenticular portion of, 898.  
     interna, structure of, 1003, 636-638, 1007, 639.  
 Capsule of red nucleus, see Nucleus ruber.  
 Caryochrome cells, 115, 117, 122.  
 Caudate nucleus, see Nucleus caudatus.  
 Cell body of perikaryon, changes in, after section of axones, 233, 234.  
 Cell bridges (Apáthy), 60, 62.  
 Cell shrinkage, 292.  
 Cells of Martinotti, 976.  
 Cellulifugal conduction, by axones, 266.  
     by medullated collaterals, 270.  
 Cellulipetal conduction by dendrites, 266.  
 Central gray matter of mid-brain, see Stratum griseum centrale.  
     gyri, see Gyri centrales.  
 Central gyri, sensory path from medulla to, 704.  
     neurones of olfactory conduction path, 748.  
     optic path, 821, 527.  
     suleus, see Suleus centralis.  
     paths of brain (von Bechterew), 456.  
*Centrale Haubenbahn*, see Fasciculus tegmenti centralis.  
*Höhlegrau*, see Stratum griseum centrale.  
*Centre antérieur*, 674.  
     *médian*, 674.  
     *moyen* (Luys), 673.  
 Centre, medullary, of cerebral hemisphere, see Centrum semiovale.  
 Centrifugal, cerebellar path, 965, 613.  
     fibres in lemniscus medialis, descending, 1017, 644.  
 Centripetal fibres conducting bodily impulses, 666.  
     trigeminal neurones, central, 641.  
 Centrum ovale of Flechsig, see *Triangle médian* of Gombault and Philippe.  
     semiovale, hallux fibres in, 1027.  
 Cephalic myotomes, relation of muscles to, 919.  
 Cerebellar path, centrifugal, 965, 613.  
 Cerebello-cerebral paths, 647, 733.  
 Cerebellopetal degeneration, 664.  
 Cerebello-spinal paths, 963.  
 Cerebellum, 89.  
     axones entering, 648, 741.  
     axones from nucleus dorsalis to, 714.  
     connection with cortex cerebri, 733.  
     degenerations following lesions of, 964.  
     worm (vermiform process) of, see Vermis.  
 Cerebral hemispheres, see Hemisphærium cerebri.  
     nerves, components of, 922.  
     nerves, control by pallium of, 1022.  
     nerves, relation to central nervous system, 917, 588.

- Cerebral nerves, sensory components of, 924, **592**.  
vesicles, 88, 163.
- Cerebro-spinal meningitis, nerve cells in, **175**.
- Cerebrum (brain), 163, **340**.  
cortex of, see Pallium.
- Cervical enlargement of cord, see Intumescencia cervicalis.  
sclerozones, **139**.
- Chromatic zones, 56, 58.
- Chromophile cells, 115, 123, **73**.
- Chiasma opticum, 90, **508**, 795.  
opticum, decussation of fibres in, 785.  
opticum, degeneration of, 789, **504**.
- Cingulum, 1061, **669**.
- Circumcellular plexuses, **115**.
- Clarke's nucleus or column, see Nucleus dorsalis.
- Claudius, cells of, **364**.
- Clava (club), 560, **372**.
- Climbing fibres, 85, **52**.
- Column of Türk, see Fasciculus cerebro-spinalis ventralis.
- Cochlear root of auditory nerve, see N. cochleæ.
- Cœlom, unsegmented, 197.
- Cold points, 253.
- Collaterals, 21, 22, 90.  
from axones of pyramidal tract, 1033.  
reflex, 26.
- Colliculus facialis, **372**.  
inferior, **314**, **318**, **319**, **369**, **382**, **535**, 838, 843, 847.  
inferior, relation to auditory path, 873.  
superior, **316-324**, **369**, **382**.  
superior, fibres from lateral lemniscus to, 868, **555-558**.  
superior, fibres to occipital cortex from, 819.  
superior, path to spinal cord from, 969.  
superior, termination of optic fibres in, 803.  
superior, zones of, 803, 809.
- Columna extremitatis inferioris, 914.  
extremitatis superioris, 914.  
grisea dorsalis, **373**.  
grisea ventralis, **374**, **407**.  
intermedio-lateralis, 913, **585**, **586**.  
lateralis, 915.  
medialis, 913, **585**, **586**, 915.  
posterior, see Columna grisea dorsalis.
- Comma of Schultze, 390, **295-298**, 448, 451, 454-457.
- Commissura ansata of Hannover, 807.  
anterior alba, see Commissura ventralis alba.  
anterior (cerebri), 1055, **666**.  
anterior grisea, see Commissura ventralis grisea.  
cerebri maxima, see Corpus callosum.  
dorsalis (spinal cord), 474, **305**.  
hippocampi, 766, 1057.  
hypothalamica anterior, 807, **517**.  
hypothalamica media (Meynert), 713.  
inferior (Guddeni), 507.  
posterior (cerebri), **321**, **322**, **386**, **419**.  
superior (Meynert), **507**, **514**, **515**, **713**, 805.  
ventralis alba, **387**, **390**.  
ventralis grisea (spinal cord), **387**.
- Commissural cells, see Neurones, heteromeric.  
fibres of cerebrum, **665**.
- Commissure between Bechterew's nuclei (ventral part of brachium conjunctivum), **315**, **319-323**, **415**, 632, **420**.  
between inferior colliculi, **315**, **414**.  
optic, see Chiasma opticum.
- Conarium, see Corpus pineale.
- Concrecence (Held), 50, 70, 94.
- Conducting anastomosis (Apáthy), **60**.
- Conduction avalanche, see Avalanche conduction.  
path, 319.

- Conduction path, sensory, from medulla to central gyri, 704.  
 path, somæsthetic, *résumé* of, 739, 469-471.
- Conductor sonorus, 840.
- Confusion zone, 995, 632.
- Connecting plexus of heart, 123.
- Contact theory of transmission of impulses, 262, 263.
- Convergenzzentrum*, 951.
- Cornu ammonis, see Hippocampus.  
 antierius, see Ventricle lateral.  
 inferius, see Ventricle lateral.  
 posterius, see Ventricle lateral.
- Corpora albicantia (white bodies), see Corpus mamillare.
- geniculata, see Corpus geniculatum.
- quadrigemina, 89, 372, 536.
- quadrigemina, relation of lemniscus lateralis to, 556.
- quadrigemina, significance of, in animal series, 804.
- quadrigemina, termination of optic fibres in, 803.
- Corpus callosum, 1053.
- callosum, degenerations of, 1055.
- ciliare, see Nucleus dentatus.
- dentatum, see Nucleus dentatus.
- geniculatum laterale, 536, 800, 813, 511, 823, 831.
- geniculatum laterale, degeneration of cells in, 817, 526.
- geniculatum laterale, nuclei of, 679, 796, 510.
- geniculatum laterale, termination of optic fibres in, 798, 800, 510, 512.
- geniculatum mediale, 386, 843, 847.
- geniculatum mediale, degeneration in, 875, 559.
- geniculatum mediale, fibres to internal capsule from, 875, 560.
- geniculatum mediale, nuclei of, 875.
- geniculatum mediale, termination of optic fibres in, 804.
- Laysi, see Nucleus hypothalamicus.
- mamillare, 90, 386.
- Corpus inamillare, connection of hippocampus with, 766.
- mamillare, nuclei of, 768.
- parabigeminum, 569, 386.
- pineale, 90, 831.
- restiforme, 309-312, 318-321, 377, 385, 504, 575, 391, 412, 413, 417, 419, 586, 587.
- restiforme, degeneration following section of, 614, 615, 967.
- striatum, 89.
- subthalamicum, see Nucleus hypothalamicus.
- trapezoideum, 313, 324, 367-369, 551, 553, 402, 415, 417, 612, 537, 538, 843.
- trapezoideum, transverse fibres of, 859.
- trapezoideum, terminals of axones on cells in, 545, 546, 547, 857.
- Cortex of human brain, 663.
- Corti's membrane, 362.
- Cortical lemniscus, 697, 699.
- Cortico-muscular conduction path, 1037, 657, 658.
- Crista ampullaris, 499.
- Crossed pyramidal tract, see Fasciculus cerebro-spinalis lateralis.
- Crus cerebri, see Pedunculus cerebri.
- Cuneate funiculus, see Fasciculus cuneatus.
- tubercle, see Tuberculum cuneatum.
- Cuneus, 524, 534, Pl. I, 3.
- Cylinder furrow, 100.
- Cylindrodendriten*, 90.
- Cytochrome cells, 115, 121.
- Cytodendriten*, 270.
- Darkschewitsch, nucleus of, 721, 724, 462, 463.
- Deckplatte*, 100.
- Deafness, mind, 1078.
- word, 1076.
- Decussatio brachii conjunctivi, 316, 322-324, 415, 420, 429.
- lemniscorum, 308, 563, 447.
- nervorum oculomotorium, 942.

- Decussatio nervorum trochlearium, **314, 940, 602.**  
 pyramidum, 981, 990, 991, **624.**  
 subthalamica anterior, see Commissura hypothalamica anterior.  
 tegmenti dorsalis, 772, 969, **435, 492, 617, 618.**  
 tegmenti ventralis, **429, 435, 619, 971.**
- Decussation in optic chiasm, complete (von Gudden), 790.  
 in optic chiasm, theories of, 785.  
 of fillet, see Decussatio lemniscorum.  
 of pyramids, see Decussatio pyramidum.
- Decussationes tegmentorum, **316, 317, 324, 495, 492, 493, 495, 772, 812, 969.**
- Deep cells of nuclei N. trigemini, 642.  
 optic path, 821.
- Degeneration after amputation, 228.  
 after lesion of cerebellum, 964-967.  
 after lesion of gyrus centralis posterior, 702, **455.**  
 after removal of eye, 787, **504.**  
 after section of corpus restiforme, **967, 614, 615.**  
 of cell-body on removal of afferent impulses, 229, **177.**  
 of nerve cells after section of axone, **233, 234.**  
 retrograde, 229.  
 secondary or Wallerian, 18, 46, 224, **227, 143, 144.**
- Deiters, cells of, **364.**
- Deiters' nucleus, see Nucleus N. vestibuli lateralis (Deiters).  
 nucleus, tract to spinal cord, **311, 312, 321, 322, 368.**
- Dendraxone, 14, 70, **41, 55.**
- Dendraxones between upper motor neurones, 1036.
- Dendrites, 4, 15, **16, 37, 70, 111, 139.**  
 effect of injury to, 239.  
 origin of, 169.  
 theory as to nature of, 258.
- Dermatome, 196.
- Descending centrifugal bundle of lemniscus medialis, 1017, **643, 644.**  
 cerebellar spinal tract, 963.  
 spinal neurone system from formatio reticularis, uncrossed, 962.  
 spinal neurone system from nucleus ruber, crossing, 972.
- Diaphragm, development of, **124.**  
 innervation of, 194.
- Diazonal nerve trunk, 209, **137, 138.**
- Diencephalon, 159, **89.**  
 motor neurones in, 969.
- Diffuse cells of retina, 783.
- Diplomeric muscles, 201.
- Direct cerebellar tract, see Fasciculus spino-cerebellaris dorso-lateralis.  
 pyramidal tract, see Fasciculus cerebro-spinalis ventralis.
- Directe acustische Rindenbahn*, (Held), 868.  
*Rindenschleife*, 667.
- Dorsal commissure, see Commissura dorsalis.  
 decussation of tegmentum, see Decussatio tegmenti dorsalis.  
 funiculus, see Funiculus dorsalis.  
 horn, see Cornu dorsale.  
 nucleus of lateral geniculate body, 679.  
 nucleus of reticular zone, 677, 679.  
 root, see Radix dorsalis.  
 white matter of nucleus hypothalamicus, 684.
- Dreikantenbahn* (Helweg), 958.
- Ductus cochlearis, **361, 362.**  
 endolymphaticus, **361.**  
 reuniens, **361.**  
 semicircularis lateralis, **361.**  
 utriculosaccularis, **361.**
- Ectoblast, 165.
- Ehrlich's vital staining, 31.
- Electrical stimulation of cerebral cortex, 993.  
 stimulation of neurones, indirect, 276.
- Elementary fibrils of Apáthy, 54.



- Elementargitter*, see Apáthy's *Elementargitter*.
- Embolus, see Nucleus emboliformis.
- Eminentia interpeduncularis of isthmus, 90.
- Enarkyochrome cells, 118, 119, 68.
- Encephalon, 163.
- End-brain, see Telencephalon.
- End-bulbs of Krause, 251, 392, 396.
- Enlargements of cord, see Intumescencia.
- Enteromere, 196.
- Entry zone, 423, 424, 427.
- Epistratum, 500, 781.
- Epithalamus, 89.
- Equivalent picture of nerve cell, 133.
- Ersatz-Theorie* of tabes (Edinger), 254.
- External capsule, see Capsula externa.
- Extirpation of facial area, 651, 1029.  
of hallux centre, 646-650, 1024.
- Eye, development of, 118, 119.  
muscles, innervation of, 950.
- Eyes, effects of extirpation of, 787, 504.
- Facial area of cortex, extirpation of, 651, 1029.  
nerve, see Nervus facialis.
- Facies medialis cerebri, motor localization in, 1000, 634.
- Fasciculi cerebro-spinales pyramidales, 172, 313, 314, 315, 316, 317, 374, 376, 377, 975, 981, 1008, 1010, 625-631, 640.
- cerebro-spinales pyramidales, medullation of, 987.
- longitudinales (pyramidales), see Fasciculi cerebro-spinales.
- pedunculo-mammillares, 768, 492.
- pedunculo-mammillares, pars basilaris, 386, 772.
- pedunculo-mammillares, pars tegmentalis, 772.
- proprii, motor neurones for, 952.
- Fasciculus anterior proprius (Flechsigi), see Fasciculus ventralis proprius.
- Fasciculus antero-lateralis superficialis (Gowersi), see Fasciculus ventro-lateralis, etc.
- basilaris medialis, 625-629.
- centralis tegmenti, 401, 403, 404, 728, 974.
- cerebellaris lateralis descendens, 663.
- cerebello-spinalis, see Fasciculus spino-cerebellaris dorso-lateralis.
- cerebro-spinalis anterior (pyramidalis anterior), see Fasciculus cerebro-spinalis ventralis.
- cerebro-spinalis lateralis (pyramidalis lateralis), 281, 282, 306, 390, 609, 984, 992, 630, 631, 1045.
- cerebro-spinalis ventralis, 306, 390, 933.
- cerebro-spinalis ventralis of monkey, 1027, 649.
- cruciatas, 785, 507.
- cuneatus (Burdachi), 25, 280, 293, 295, 301, 302, 304, 308, 318-322, 372, 373, 376, 405, 443-457, 461, 462, 468.
- dorsalis proprius, 559.
- dorso-lateralis (Lissaueri), 25, 280, 281, 390, 423-435, 468.
- gracilis (Goll), 8, 26, 304, 308, 318-322, 372, 373, 376, 405, 443-468.
- gracilis, degenerations of, 280, 292, 293, 442-447.
- gracilis, origin of, 439-442; termination of, 301, 302, 461, 462.
- lateralis limitans, 608, 609, 399.
- lateralis proprius (Flechsig), 306, 415, 559, 611-614, 740.
- lateralis ventralis, 740.
- longitudinalis inferior, 1065, 672.
- longitudinalis medialis, 309-317, 319-324, 386, 401, 404-406, 414-417, 420, 613-619, 627, 637, 422, 668, 675, 718, 721.
- longitudinalis medialis, connection with cord, 459.
- longitudinalis medialis, motor neurones for, 959.

- Fasciculus longitudinalis superior*, 881, 1063, 671.  
*macularis cruciatus*, 507, 795.  
*macularis noncruciatus, dorsalis et ventralis*, 507, 795.  
*marginalis anterior*, 957.  
*noncruciatus*, 785, 505, 506, 507.  
*occipitalis transversus cunei*, 1060.  
*occipitalis transversus gyri lingualis*, 1061.  
*occipitalis verticalis*, 1059.  
*occipito-frontalis*, 1068.  
*pallio-frontalis*, 1040.  
*pallio-frontalis, degeneration of*, 661.  
*retroflexus (Meynerti)*, 317, 323, 324, 386, 775, 777, 498.  
*retroflexus (Meynerti), relation to red nucleus*, 499, 778.  
 ↘ *spino-cerebellaris dorso-lateralis*, 308, 320, 575, 390, 585-589, 395, 396, 975.  
 ↘ *spino-cerebellaris ventro-lateralis restiformis*, 608.  
*thalamo-mammillaris (Vieq d'Azyri)*, 386, 768, 771.  
*uncinatus*, 1066.  
*ventralis proprius*, 559, 306, 308, 401, 406, 610-614.  
*ventrolateralis superficialis (Gowersi)*, 559, 301, 302, 306, 390, 590-598, 396, 397, 398, 601-604.  
*Fatigue, influence of, on neurones*, 276, 277, 164, 166.  
*Feld H*, 655, 436, 671.  
*Feld H<sub>1</sub>*, 672, 438.  
*Feld H<sub>2</sub>*, 672, 438.  
*Feld H<sub>2</sub>, fibres from fasciculus longitudinalis medialis to*, 668.  
*Feltwork (Neuropilum)*, 17.  
*Fibræ arcuatæ externæ*, 308, 376, 565, 575.  
*arcuatæ internæ*, 308, 309, 320-324, 563, 565, 568.  
*arcuatæ internæ from nuclei terminales N. trigemini*, 422.  
*arcuatæ internæ, relation to nucleus alæ cineræ*, 624.  
*Fibræ arcuatæ internæ, relation to nucleus funiculi cuneati*, 420.  
*arcuatæ internæ (vestibular)*, 319, 627, 866, 553.  
*pontis*, 312.  
*Fibres cortico-rubriques directes*, 732.  
*Fila olfactoria*, 478, 500.  
*Fillet, see Lemniscus.*  
*Fissura calcarina*, 638.  
*cerebri lateralis, Plate I, 3.*  
*chorioidea*, 90.  
*parieto-occipitalis, Plate I, 3.*  
*prima*, 749.  
*rhinica*, 749.  
*Sylvii*, 633.  
*Fissurenstrang*, 960.  
*Flechsig's embryological method*, 25.  
*sensory systems*, 735, 466-468.  
*Flocculus*, 372, 411.  
*peduncle of, see Pedunculus flocculi.*  
*Fontaineartige Haubenkreuzung of Meynert, see Decussationes tegmentorum.*  
*Food-stuffs of neurones*, 218.  
*Forebrain, see Prosencephalon.*  
*Forel's ventrale Haubenkreuzung*, 772, 492.  
*Formatio arcuata*, 100.  
*reticularis*, 176, 615, 728, 401, 412, 464, 465, 560, 611, 618, 629, 690.  
*reticularis alba*, 727, 959.  
*reticularis grisea*, 721, 960, 460.  
*reticularis, optic and acoustic fibres in*, 557.  
*Fornix*, 1067.  
*Fossa cerebri lateralis (Sylvii), Plate I, 3.*  
*Fovea, anterior or superior*, 372.  
*Funiculus anterior, see Funiculus ventralis.*  
*dorsalis*, 22, 563, 306.  
*dorsalis, fibres from nuclei of*, 709, 711, 713.  
*dorsalis, function of*, 709.  
*dorsalis, injury to*, 708.  
*dorsalis, myelinization of*, 281-288, 424-437.

- Funiculus dorsalis, origin of, 457-461.  
   lateralis, 8, **310, 311, 403, 915**.  
   lateralis, fibre system from nucleus  
     ruber to, 422.  
   posterior, see Funiculus dorsalis.  
   ventralis, **373**.  
   ventro-lateralis, fibres from Deiters'  
     nucleus to, 960.  
*Fusschleife* (Flechsig), 684.
- Ganglia, sensory, cells of, 68, **31, 179, 108**.  
   trunci sympathici, 190, **185**.
- Ganglion cells of Apáthy, 52, 54.  
   commissural, see Nucleus commis-  
     suralis.  
   geniculi, 513.  
   habenulæ, see Nucleus habenulæ.  
   jugulare, 478.  
   nodosum, 478.  
   petrosum, 478.  
   semilunare (Gasser), 514.  
   spinale, 185, **183, 310, 311, 207, 209, 210**.  
   spirale, **112, 117, 545**.  
   superius, 478.  
   vestibulare (Scarpæ), 499.
- Ganglionic ridge, **109**.
- Gasserian ganglion, see Ganglion  
   semilunare.
- Gastrocnemius muscle, nerve endings  
   in, 894.
- Gemmules, 76, **37, 39**; loss of, 240.
- Geniculate body, external, see Corpus  
   geniculatum laterale.  
   body, internal, see Corpus genicu-  
     latum mediale.
- Genital corpuscles, **256, 261, 396**.
- Genu capsulæ internæ, 1005.  
   N. facialis, **368, 411, 930**.
- Gerlach's diffuse network, 7, 60.
- Giant cells of substantia gelatinosa,  
   643, **421**.  
   pyramidal cells, 978, **621**.
- Gitterschicht*, 677, **438**.  
*Gitterschichtkerne*, 679.
- Glandula pinealis, see Corpus pineale.  
   pituitaria, see Hypophysis.
- Globus pallidus, Plate I, **3**.
- Glomerulus olfactorius, **50, 531, 757**.
- Golgi's cell of Type I, **11, 12**.  
   cell of Type II, **12, 13**.  
   cells, Type II, intersegmental, 952.  
   cells, Type II, between upper and  
     lower motor neurones, 1036.  
   diffuse network, 15.
- Golgi-Mazzoni corpuscles, **255, 396**.
- Golgi's method, 9.
- Goll's fasciculus, see Fasciculus gra-  
   cilis.
- Gowers' tract, see Fasciculus ventro-  
   lateralis superficialis.
- Gracile nucleus, see Nucleus funiculi  
   gracilis.
- Grande lobe limbique, see Gyrus for-  
   nicatus.
- Grandry's corpuscles, **220-224**.
- Granule layer of Flechsig's *temporale*  
   *Riechsphäre*, 759.
- Gratiolet's radiation, see Radiatio occi-  
   pito-thalamica (Gratioleti).
- Gray commissure of cord, see Com-  
   missura grisea medullæ spinalis.  
   matter, central, see Substantia gri-  
     sea centralis.  
   substance, see Substantia grisea.
- Grosshirn*, see Cerebrum.
- Ground-bundle, antero-lateral, see  
   Fasciculus ventralis proprius.
- Gryochrome cells, 117, 121.
- Gudden, commissure of, see Commis-  
   sura inferior Guddeni.  
   law of, 18, 44.
- Gustatory conduction path, central  
   neurones of, 747.  
   neurones, see Neurones, gustatory.
- Gyri cerebri, Plates I and II, **638**.  
   occipitales laterales, Plate II, **1, 638**.  
   occipitales superiores, Plate I, **3, 638**.
- Gyrus ambiens rhinencephali, 752,  
   **501**.  
   angularis, 823.  
   centralis anterior, Plate II, **1**.

- Gyrus centralis posterior, lesion of (Flechsig and Hoessel), 702, **455**.  
 cinguli, Plate I, **4**, **638**, **669**, 1061.  
 fornicatus, Plate I, **3**.  
 frontalis inferior, Plate II, **1**.  
 frontalis medius, Plate II, **1**.  
 frontalis superior, function of, 999.  
 hippocampi, 764.  
 lingualis, Plate I, **4**.  
 olfactorius lateralis, 751, **473**, **474**, **475**.  
 olfactorius medialis, 751, **473**.  
 semilunaris rhinencephali, 752.  
 subcallosus, **501**, **502**, **638**.  
 supramarginalis, Plate II, **1**.  
 temporalis medius, Plate II, **1**.  
 temporalis superior, **563**, 878.  
 uncinatus, see Uncus.
- Hair cells of organ of Corti, **364**.  
 Hallux centre, degeneration following extirpation of, **646-659**, 1024.  
 centre, pyramidal fibres from, 1030.  
 centre, decussation of, 1026, **648**.  
*Haubenbündel des Linsenkernelnes*, 674.  
*des rothen Kernes*, 674.  
*des Thalamus*, 674.  
 of von Gudden, see Fasciculus pedunculo-mammillaris.  
*Haubenfascikeln* (Forel), **435**, 670.  
*Haubenkreuzung*, see Decussationes tegmentorum.  
*Haubenstrahlung*, 667, 730.  
*Hauptschleife*, see Lemniscus medialis.  
*der Schleifenschicht*, 687.  
*Haupttheil der Schleifenschicht*, 687.  
 Head area of cerebral cortex, 998.  
 cavities, 918, 919.  
 fold, 88.  
 plate, 88.  
 Heart, plexuses of, **123**.  
 Heteromeric neurones, see Neurone, heteromeric.  
 Held's method, 129.  
 Hemianopsia, 825, 826.  
 Hemispharium cerebri, lateral surface, 675.  
 Hemispharium cerebri, medial surface, 676.  
 Hemispheric bundle of von Gudden, 807, **516**.  
 Hensen, cells of, **364**.  
 Herbst's corpuscle, see Pacinian corpuscle.  
 Heteromeric neurones, see Neurone, heteromeric.  
*Heteropodere Nervenzellen*, 81.  
 Hibernating animals, nervous system of, 280.  
 Hilus thalami, 683.  
 Hind-brain, see Metencephalon.  
*Hintere Langsbündel Formation* (Hönniger), 727, 732.  
 Hippocampus, cells of, 68, 72, **35**.  
 connection of uncus with, **489**.  
*Hirnklappenschleife* (Meynert), 868.  
*Hirnschenkelsschlinge* of Flechsig, 685.  
 Hoche, researches on pyramidal tracts, 1016.  
 Homonymous bilateral hemianopsia, 789.  
 Horseshoe commissure of Wernekinck, 653, **429**, **430**.  
 Hypoglossal nerve, nucleus of, 924, **593**.  
 nucleus of Roller, small-celled, 926.  
 Hypothalamus, **90**.  
 layers of, 671.  
 limits of, 671.  
 paths to, 668.  
 region of, 666.  
 Inaxones, 81.  
 Individuality of neurones, 38.  
 Infections, changes in neurones in, 289.  
 Inferior colliculus, nucleus of, see Nucleus colliculi inferioris.  
 colliculus, relation to auditory path, 872.  
 fillet, see Lemniscus lateralis.  
 Infraconscious impulses, 250.  
*Innerer Kern* (Burdach), 673.  
*Inselschwelle* (Schwalbe), 750.  
 Insula, Plate I, **3**.



- Inter-brain, see Dienecephalon.  
 Intercellular bridges, see Cell bridges.  
 Interinsular cells, 421.  
 Intermediary lamina medullaris, 439.  
   motor neurones, 952.  
 Internal capsule, see Capsula interna.  
 Interneuronal relations in cerebral cortex, 655, 656.  
   substances, 90.  
 Interolivary layer, see Stratum interolivare lemnisei.  
 Intersegment, 196.  
 Interstitial cells of sensory nucleus of trigeminus, 642, 421.  
 Intoxications, changes in neurones in, 282.  
 Interparietal sulcus, see Sulcus interparietalis.  
 Intumescencia cervicalis, motor neurones of, 885, 905, 578-582.  
   lumbalis, neurones of, 887.  
 Irritability of neurones, 248.  
 Island of Reil, see Insula.  
*Isolotes olfativos*, 761, 487, 488.  
 Isthmus of brain, see Isthmus rhombencephali.  
   rhombencephali, 89.  
 Iter a tertio ad quartum ventriculum, see Aqueductus cerebri.  
  
 Kaiser's nucleus extremitatis superioris, 914.  
*Keimzellen*, 167.  
*Körperfühlsphäre*, 667.  
 Krause's end-bulbs, see End-bulbs of Krause.  
*Kreuzende Hinterstrangkern-Grosshirnrindensystem* (Tschermak), 714.  
*Hinterstrangkern - Grosshirnrind-Thalamussystem* (Tschermak), 714.  
  
 Labyrinthus membranaceus, 361.  
 Lamina basilaris (Corti's organ), 362, 364.  
   terminalis, 90.  
 Laqueus, see Lemniscus.
- Large-celled nucleus of thalamus (Nissl), 677.  
 Lateral column, see Funiculus lateralis.  
   fillet, see Lemniscus lateralis.  
   geniculate body, see Corpus geniculatum laterale.  
   horns, grouping of cells in, 888, 568.  
   line, 200.  
   nucleus, see Nucleus lateralis.  
   nucleus of corpus mammillare, 768.  
   nucleus of reticular zone, 677.  
   nucleus of thalamus, anterior and posterior, 680.  
   pyramidal tract, see Fasciculus cerebro-spinalis lateralis.  
*Laterales absteigendes Kleinhirnbündel*, 663.  
 Lautermann's segmentation, 4.  
 Leg area of cortex, 998.  
*Leitungsbahn*, 319.  
 Lemniscus or laqueus, 686.  
   lateralis, 314, 315, 318-322, 369, 386, 553, 404, 405, 414, 415, 687.  
   lateralis, divisions of, 861.  
   lateralis, fibre arcuate internæ from, 866, 553.  
   lateralis, finer structure of, 860.  
   lateralis, lesions of, 861, 550.  
   lateralis, nuclei of, 864.  
   lateralis, origin of axones of, 862, 551.  
   lateralis, relation to nucleus colliculi inferioris, 863.  
   lateralis, termination of axones of, 866, 554.  
   medialis, 313-317, 386, 564, 570, 401, 404, 414, 415, 687, 689, 448, 449.  
   medial accessory, 688, 446.  
   medialis (accessory bundles of von Bechterew), 404.  
   medialis, descending centrifugal bundle in, 1017, 643, 644.  
   medialis, direct fibres to cerebral cortex from, 699.

- Lemniscus medialis, origin of fibres of, 694.  
 medialis, termination of fibres of, 694, **450, 451**.  
 medialis, views concerning course of, **454, 666, 697**.  
 superior, **320, 321, 540**.  
 Ligamentum spirale cochleæ, **362**.  
 Limen insulæ, 751.  
*Linsenkerschlinge* (Fleehsig), 685.  
 Lissauer's column or tract, see Fasciculus dorso-lateralis Lissaueri.  
 Lobulus paracentralis, function of, 999.  
 paracentralis, lesions of, 701, **455**.  
 Lobus occipitalis, 1047.  
 olfactorius, **90, 749, 472**.  
 Localization, motor, in spinal cord, 899.  
 of function in cerebral cortex, 995, 1002.  
 of function in spinal cord, 903-905, 909, **583**.  
 Locus cæruleus, **372**.  
 Longitudinal bundle, posterior or dorsal, see Fasciculus longitudinalis medialis.  
 Lower face area, 998.  
 facial nerve, 930.  
 motor neurones, see Neurones, lower motor.  
 Lumbar enlargement of cord, see Intumescencia lumbalis.  
 Luys' body, see Nucleus hypothalamicus (corpus Luysii).  
 Lyra, see Commissura hippocampi.  
 Macrosmatic animals, 749.  
 Macula acustica sacculi, **333, 361, 500**.  
 Macula acustica utriculi, **361**.  
 lutea, 825, 826.  
 lutea, fibres in optic nerve from, 795.  
 Malon-nitril, effects of, **178, 301, 302**.  
 Mammals, nerve endings in muscle fibres of, 894.  
 Mann's method, 129.  
 Mantle, see Pallium.  
 Marchi's method, 45, 242, 243.  
 Marginal bundle of Lissauer, see Fasciculus dorso-lateralis Lissaueri.  
 cells of sensory nucleus of trigeminus, 642, **421**.  
 furrow, **100**.  
 veil, 166.  
 Mastication, development of muscles of, 919, **590**.  
 Medial accessory lemniscus, 688, **446**.  
 column of motor cells, 615.  
 geniculate body, see Corpus geniculatum mediale.  
 nucleus of corpus mammillare, 768.  
 nucleus of thalamus, 679, **442**.  
 ventral nucleus of thalamus (von Monakow), 681.  
*Mediale accessorische Bündel der Schleife* (von Bechterew), see Medial accessory lemniscus.  
 Medulla oblongata, **308-312, 318-324**.  
 oblongata, lamellation of, 177.  
 oblongata, pyramidal tract fibres in, 981.  
 sensory conduction path to central gyri, 704.  
 spinalis, 204.  
 spinalis, commissura, **387**.  
 spinalis, commissura dorsalis, **305, 390, 474**.  
 spinalis, commissura grisea, **387**.  
 spinalis, cornu dorsale, **387**.  
 spinalis, cornu ventrale, **387, 390, 473, 608**.  
 spinalis, cornu ventrale, relation to fasciculus longitudinalis medialis, 617.  
 spinalis, nucleus of posterior horn of Waldeyer, 473.  
 substantia grisea of, 473.  
 Medullary groove, 88.  
 plate, 165, **93**.  
 Medullated nerve fibres, 4.  
 Medullation of fibres, sequence of, 986.

- Meissner's tactile corpuseles, 239, 240, 241, 245.
- Mercury, effects of, 287.
- Mesencephalon, 159, 89, 316-324.  
horizontal section through, 427.  
lower motor neurones of, 915.  
motor neurones in, 969.
- Mesial fillet, see Lemniscus medialis.
- Metabolism of neurones, 217.
- Metameres, 195.
- Metathalamus, 89.
- Metazonal nerve trunks, 209, 135, 138, 139.
- Metencephalon, 159, 89, 312-316, 318-324.  
pyramidal fibres in, 89, 981, 990.
- Meynert, bundle of, see Fasciculus retroflexus Meynerti.  
commissure of, see Commissura superior Meynerti.
- Meynert's *fontaineartige Haubenkreuzung*, 772, 492.
- Microsmatic animals, 749.
- Midbrain, see Mesencephalon.
- Middle cerebellar peduncle, see Brachium pontis.  
cerebral vesicle, 88.  
decussation of tegmentum, 772.  
horn of lateral ventricle, see Ventricleus lateralis, cornu inferius.  
lemniscus, see Lemniscus medialis.  
or soft commissure, see Massa intermedia.
- Mittelzellensäulen*, 888.
- Mittlere weisse Lage*, see Stratum album medium.
- Mitral cells, 532, 757, 481.
- Monostriated cells of the retina, 503, 733.
- Motor area of cortex, 976, 996.  
axone, ending in muscle fibre of, 893, 573.  
cells, medial and lateral columns of, 915.  
cerebral nerves, control by pallidum of, 1022.  
cortex, degeneration following extirpation of areas in, 646-654.
- Motor cortex, extirpation of areas of, 1022, 645.  
fibres from the cortex, termination of, 981.  
function in cerebral cortex, localization of, 995, 632-635, 1002.  
localization in spinal cord, 899, 583.  
nerve spindle, 53, 60.  
neurones, lower, 883, 577.  
neurones of cervical enlargement, 885.  
neurones of the cord, commissural group of, 885, 567.  
neurones, grouping of, 884.  
neurones of rhombencephalon, 915.  
neurones of thoracic, lumbar, and sacral cords, 887.  
neurones, relation of upper and lower (von Monakow), 1036.  
neurones, upper and intermediate, 952.  
nuclei of lumbar enlargement, 586.  
telodendrion of the frog, 575.  
telodendrion of lacerta, 574.  
telodendrion of the rabbit, 576.  
telodendrion, relation to neurolemma, 896.
- Movements, bilaterally innervated muscles, 1040.
- Müller's fibres, 356, 537.
- Multipolar ganglion cell, 4, 69, 32, 34.
- Muscles of the eye, innervation of, 950.
- Muscle-segment, see Myotome.
- Myelencephalon, 159, 89, 372.
- Myelin sheath, 41, 86.
- Myelination of brachium conjunctivum, 657-659, 431.
- Myocommata, 198.
- Myoseptum, 198.
- Myotome, 195, 126, 199, 200.
- Myotomes, proötic and postötic, 919.  
relation of muscles to cephalic, 919.
- N. abducens, 932, 313, 320-324, 340, 415.

- N. abducens accessorius*, 186, 307, 322, 323, 340, 374, 927, 595, 928.
- acusticus*, see *N. cochleæ* and *N. vestibuli*.
- auricularis magnus*, 186.
- axillaris*, 186, 189.
- cochleæ*, 307, 311, 312, 361, 368-370, 546, 413, 416.
- cutaneus antibrachii lateralis*, 189.
- cutaneus antibrachii medialis*, 189.
- cutaneus brachii dorsalis*, 189.
- cutaneus brachii medialis*, 189.
- cutaneus colli*, 186.
- cutaneus femoris lateralis*, 190.
- cutaneus femoris posterior*, 187, 190.
- dorsalis scapulæ*, 186.
- facialis*, 307, 312, 319-324, 340, 361, 368, 411, 417, 929.
- femoralis*, 187.
- glossopharyngeus*, 307, 309-311, 320, 321, 326, 329, 340, 377, 477.
- glossopharyngeus*, lower motor neurones of, 929.
- glutæus inferior*, 187.
- glutæus superior*, 187.
- hypoglossus*, 102, 186, 309, 321-324, 340, 376, 377.
- hypoglossus*, in the embryo, 926.
- iliohypogastricus*, 187, 189.
- ilioinguinalis*, 187, 190.
- intermedius*, 514.
- lumboinguinalis*, 187, 190.
- medianus*, 186, 189.
- musculocutaneus*, 186.
- obturatorius*, 187, 190.
- oculomotorius*, 317, 323, 324, 340, 941, 949.
- opticus*, 733, 782, 795, 507.
- opticus*, coarse and fine fibres of, 785.
- peronæus communis*, 187.
- peronæus superficialis*, 190.
- phrenicus*, 186.
- plantaris lateralis*, 190.
- plantaris medialis*, 190.
- N. abducens pudendus*, 187.
- radialis*, 186.
- sapheus*, 190.
- spermaticus externus*, 187, 190.
- subclavius*, 186.
- suprascapularis*, 186.
- suralis*, 190.
- thoracobraehialis*, 186.
- tibialis*, 414.
- trigeminus*, 522, 307, 313-319, 321-324, 340, 386, 514, 523, 531, 414, 933.
- trigeminus*, sensory paths of, 664.
- trochlearis*, 315-320, 340, 386, 601, 938.
- ulnaris*, 186, 189.
- vagus*, 102, 307, 309-311, 320, 321, 326, 329, 330, 340, 477.
- vagus*, fibres from the terminal nuclei of, 728, 464, 465.
- vagus*, lower motor neurones of, 929.
- vestibuli*, 307, 310-312, 318-320, 324, 340, 361, 368, 370, 416, 418, 419, 499, 500, 502, 510, 511.
- vestibuli*, radix descendens, 407.
- Nates*, see *Colliculus superior*.
- Nerve*, auditory, see *N. acusticus* and *N. cochleæ*.
- eighth*, see *N. acusticus*.
- eleventh*, see *N. accessorius*.
- fifth*, see *N. trigeminus*.
- first*, see *Nn. olfactorii*.
- fourth*, see *N. trochlearis*.
- ninth*, see *N. glossopharyngeus*.
- second*, see *N. opticus*.
- seventh*, see *N. facialis*.
- sixth*, see *N. abducens*.
- spinal accessory*, see *N. accessorius*.
- tenth*, see *N. vagus*.
- third*, see *N. oculomotorius*.
- twelfth*, see *N. hypoglossus*.
- "Nerve-cell" of *Apáthy*, 52.
- Nerve-endings*, see *Neurones*, bodily peripheral centripetal, peripheral endings.
- Nerve-roots*, anterior, see *Radix ventralis*.



- Nerve-roots, posterior, see Radix dorsalis.  
 spinal, see Nn. spinales.
- Nerves, sensory, see Neurones, peripheral centripetal.  
 sensory, cutaneous distribution of, 188, 204, 330-349.
- Nervus trigeminus (portio minor), 422.  
 trigeminus, radix descendens (mesencephalica), 422, 600, 935.  
 trigeminus, sensory terminal nuclei of, 641.
- Neural tube, section through, 94, 95, 96.  
 segment, 195.
- Neurilemma, 41, 86.
- Neuroblasts, 16, 44, 169.  
 wandering of, 172.
- Neurofibrils of Apäthy, 52, 54, 145.
- Neuroglia, proliferation in secondary degeneration of white fibres, 228.
- Neuromere, 195.
- Neurone, 39, 41.  
 ampharkyochrome, 118, 119.  
 apyknomorphous, 123, 68, 69, 71.  
 archiplasmic radiation, 148.  
 arkyochrome, 67, 117, 121.  
 attraction sphere, 148, 84.  
 auditory, first order, 836, 839.  
 auditory, second order, 839.  
 auditory, third order, 839.  
 axone hillock, 111, 64, 82.  
 axone, structure of, 142, 145.  
 axospongium, 144, 81, 82.  
 bulbo-hypothalamic, 694.  
 bulbo-mesencephalic, 694.  
 bulbo-pontal, 694.  
 earyochrome, 115, 117, 122.  
 centrosome, 148-150, 84.  
 changes produced by arsenic in, 169, 172.  
 changes produced by fatigue in, 276, 277, 164, 166.  
 changes produced by injury to dendrites of, 239.  
 changes produced by ligature of abdominal aorta in, 173.
- Neurone, changes produced by mercury in, 287.  
 changes produced by phosphorus in, 283, 170.  
 changes produced by poisons in, 282-288, 295.  
 changes produced by section of axone in (Nissl), 233, 234.  
 changes produced by section of axone and of dorsal root in, 177.  
 changes produced by strychnine in, 285.  
 changes produced by veratrin in, 283, 171.  
 chromophile, 115, 123, 73.  
 chromophilic corpuscles, 110.  
 chromophobic, 123.  
 conception of, 40.  
 cytochrome, 115, 121.  
 cytoplasm, 147.  
 cytoreticulum, 142.  
 cytospongium, 147, 82.  
 dendrites of, see under Dendrites.  
 elementary spherules (Arndt), 104.  
 enarchyochrome, 118, 119, 68.  
 endoplasm, 155.  
 exoplasm, 155.  
 fibrillar theory of Schultze, 102.  
 fibrils of, 112, 136, 139, 62.  
 ground substance of (unstainable substance of Nissl), nature of, 135-153.  
 ground substance, fibrils of, 102, 136, 140.  
 ground substance, honeycomb structure, 138, 141, 147, 156.  
 ground substance, network, 139, 140, 78.  
 gustatory, 525.  
 hecateromeric, 171.  
 heteromeric, 171, 101.  
 hyaloplasm, 147.  
 hypothalamic, 694.  
 investment of, 150-153.  
 internal morphology of, 101, 157.  
 mesencephalic, 694.  
 parapyknomorphous, 123, 67.

- Neurone, peripheral auditory, 544.  
 peripheral centrifugal, 883.  
 peripheral olfactory, 529.  
 pigmentary deposits, 107.  
 pyknomorphous, 123, 70.  
 somatochrome, 115, 121, 67, 68.  
 spongioplasm, 147.  
 stainable substance of Nissl, see under Tigroid.  
 stiehoehrome, 117, 121, 70, 71.  
 system, 318.  
 system, crossed gracilar nucleocerebellar, 565.  
 system, uncrossed gracilar nucleocerebellar, 565.  
 tautomeric, 171.  
 tautomerie, classification of, 606.  
 threshold (*Neuronschwelle*), 253.  
 unstainable substance of Nissl, see under Neurone, ground substance.  
 visual, 533.
- Neurones, bodily peripheral centripetal, 350-360, 204, 206, 207, 208, 209, 210.  
 bodily peripheral centripetal, classification of, 321-322.  
 bodily peripheral centripetal, peripheral endings, 361-420, 211, 279.  
 bodily peripheral centripetal, peripheral endings, cornea, 214, 216, 217, 262, 400.  
 bodily peripheral centripetal, peripheral endings, conjunctiva, 218, 243, 252.  
 bodily peripheral centripetal, peripheral endings, bill of duck, 222, 224.  
 bodily peripheral centripetal, peripheral endings, bladder, 212.  
 bodily peripheral centripetal, peripheral endings, ciliary body, 270, 271.  
 bodily peripheral centripetal, epididymis, 234.  
 bodily peripheral centripetal, genital tract, 250-261.
- Neurones, bodily peripheral centripetal, hair, 225-228.  
 bodily peripheral centripetal, kidney, 279.  
 bodily peripheral centripetal, liver, 230.  
 bodily peripheral centripetal, mammary glands, 236.  
 bodily peripheral centripetal, mesentery, 254.  
 bodily peripheral centripetal, muscle, 263, 268, 272, 278, 412, 421, 893, 573, 576.  
 bodily peripheral centripetal, œsophagus, 211.  
 bodily peripheral centripetal, palate, 213, 219, 223.  
 bodily peripheral centripetal, prostate, 237.  
 bodily peripheral centripetal, salivary glands, 233.  
 bodily peripheral centripetal, skin, 215, 242, 244, 245, 246.  
 bodily peripheral centripetal, corpuscles of Meissner in, 239, 240, 241.  
 bodily peripheral centripetal, Ruffini, 247, 248, 249, 250.  
 bodily peripheral centripetal, *Tastzellen* (Merkel), 220, 221.  
 bodily peripheral centripetal, tubuli seminiferi, 235.  
 bodily peripheral centripetal, villi, 232.  
 lower motor, 41, 883, 577.  
 lower motor, lesion of, 1039.  
 lower motor, relation to upper motor neurones, 1036.  
 lower motor, segmental arrangement in cord, 884.  
 olfactory, groups of, 501-502.
- Neuropil, 271-273.  
*Neuropodien*, 79.  
 Neuroporus, 88.  
 Neurosomes (Held), 50, 144, 145, 156, 81, 82, 83.  
 Neurospongium (His), 166.  
 Neurotome, 195.

- Nissl bodies (stainable substance), 105-134, see also Tigroid.
- Nissl's classification of cells, 115-126.  
method, 45, 106, 242, 243.
- Nn. clunium medii, **187, 190.**  
oculomotorii, decussation of, 945, **605.**  
olfactorii, 754.  
spinales, description of, **185, 322-325.**  
spinales, ganglia of, **306.**  
spinales, radix dorsalis, **281, 306.**  
spinales, radix dorsalis, ascending limb of bifurcation, **304, 468.**  
spinales, radix dorsalis, collaterals, **305, 470-475.**  
spinales, radix dorsalis, collaterals, classification of, 473-475.  
spinales, radix dorsalis, descending limb of bifurcation, **304, 468.**  
spinales, radix dorsalis, fibres of, **294, 303, 447, 465-466.**  
spinales, radix ventralis, **306.**  
spinales, rami of, **185.**  
subscapulares, **186.**  
supraclaviculares, **189.**
- Node of Ranvier, **32, 41.**
- Noyau masticateur*, see Nucleus motorius princeps N. trigemini.
- semilunaire de Flechsig*, 674.
- Nuclei arciformes, see Nuclei arcuati.
- arcuati, **376, 565, 309, 674.**  
corporis mammillaris, 769, **490, 491.**  
funiculi lateralis, **382, 402.**  
intermedio-laterales, 913, **585, 586.**  
mediales, 913, **585, 586.**  
motorii N. trigemini, **313, 933, 597, 598.**  
of thalamus, Nissl's study of, 676, 679.  
motorii minores N. trigemini, **313, 933, 597, 598.**
- N. acustici, see Nuclei N. cochleæ and Nuclei N. vestibuli.
- N. cochleæ, **310, 311, 312, 318, 323, 367, 372, 547, 549, 407, 410, 411, 415, 418.**
- Nuclei of central acoustic path, **555.**  
of cervical enlargement, 914, **585.**  
of lumbar enlargement, **586.**  
of the reticular zone, 677, 679.  
pontis, **386.**  
terminales nervi trigemini, fibræ arcuatae interne from, **422.**
- Nucleus alæ cinereæ, **309, 318, 372, 377, 479, 407, 621-624.**  
ambiguus, **329, 407, 929.**  
amygdalæ, **467.**  
amygdaliformis, see Nucleus amygdalæ.  
anterior thalami, 673, **443.**  
caudatus, **636, 638.**  
centralis inferior, 577, **322, 403, 405, 614.**  
centralis medius, 577, 962, 972.  
centralis superior, **315, 321, 322, 386, 579, 404, 405, 414, 420, 614.**  
cerebello-acusticus, 505, 511, 632.  
colliculi inferioris, **315, 386, 579, 868, 539.**  
colliculi inferioris, relation to lateral lemniscus, 868.  
commissuræ posterioris, see Nucleus fasciculi longitudinalis medialis.  
commissuralis, **308, 329, 487, 409, 410, 625, 626.**  
corporis geniculati lateralis, 814.  
corporis trapezoidei, **369, 545-547, 854, 857.**  
dentatus, **310, 368, 505, 392, 423, 424, 428.**  
dentatus, connection with cortex of vermis, **424, 425.**  
dorsalis (Stillings, Clarkii), S, 474, 559, 576, 581-583, **387.**  
dorsalis, axones from, 740.  
emboliformis, **423, 424.**  
fasciculi longitudinalis medialis, **317, 386, 401, 415.**  
fastigii, 511, 568, 575, **413, 423, 424, 852.**  
fastigii, relation to Deiters' nucleus, 636.

- Nucleus funiculi cuneati, **308, 309, 318-320, 375, 382, 385, 559, 560, 565, 402.**  
 funiculi cuneati, termination of axones from, 741.  
 funiculi gracilis, **308, 318-320, 374, 375, 382-384, 559, 560, 406.**  
 funiculi gracilis, injury to, 708.  
 funiculi gracilis, termination of axones from, 741.  
 funiculi teretis, **403.**  
 funiculi ventralis, 614.  
 globosus, **392, 423, 424.**  
 habenulæ, 775, 831.  
 hypo-thalamicus (corpus luyssi), **382, 569, 580, 671, 673, 437.**  
 impar, 943.  
 innominatus (von Bechterew), see Nucleus lateralis superior.  
 intercalato of Staderini, 926.  
 lateralis anterior (Perlia), 944.  
 lateralis inferior, 577.  
 lateralis superior, **316, 320-322, 579, 401, 405, 616, 969, 972.**  
 lateralis thalami, 673, **443.**  
 lemnisci lateralis, **314, 321, 322, 369, 382, 386, 405, 420, 846.**  
 lemnisci lateralis, inferior and superior, 861, 864.  
 lentiformis, 569, 711, 713.  
 magnocellularis of medial nucleus, 681.  
 medialis thalami, 673, **443.**  
 minimus (von Bechterew), 655.  
 motorius princeps N. trigemini, **313, 320, 407, 411, 933, 597, 598, 600, 935.**  
 N. abducentis, **312, 318, 319, 407, 411, 416, 427, 932, 947.**  
 N. cochleæ dorsalis, 851.  
 N. cochleæ ventralis, 848, **541, 543.**  
 N. facialis, **218, 312, 321, 322, 407, 416, 596, 929.**  
 N. facialis, motor fibres from medial lemniscus to, 1017.  
 N. glossopharyngeus, **377.**  
 N. hypoglossi, **309, 318-320, 329, 376, 407, 411, 593, 924.**
- Nucleus N. hypoglossi, motor fibres from medial lemniscus to, 1017.  
 N. oculomotorii, **317, 321-324, 407, 941, 943, 603, 604, 947, 606.**  
 N. oculomotorii, collaterals from fasciculus longitudinalis to, 721, **460.**  
 N. trochlearis, **316, 321, 322, 324, 407.**  
 N. trochlearis, collaterals from fasciculus longitudinalis medialis to, 721, **460.**  
 N. vestibuli, 627.  
 N. vestibuli lateralis (Deiters), **312, 318, 509, 568, 407, 411, 413, 416, 417, 418.**  
 N. vestibuli lateralis (Deiters), 634.  
 N. vestibuli lateralis, cells of, 634.  
 N. vestibuli lateralis, crossed central vestibular path, 637.  
 N. vestibuli lateralis, direct central vestibular path, 637.  
 N. vestibuli lateralis, fibres of, 637.  
 N. vestibuli lateralis, path to cord from, **415, 416, 418, 419, 420, 959.**  
 N. vestibuli medialis, **310, 311, 318, 368, 507, 407, 411, 419, 627.**  
 N. vestibuli spinalis (radicis descendentes), **411, 627.**  
 N. vestibuli superior (von Bechterew), **311, 312, 318, 509, 407, 413, 416, 418, 630.**  
 of Darkschewitsch, 721, 724, **462, 463.**  
 of Deiters, see Nucleus N. vestibuli lateralis.  
 of Edinger and Westphal, see Nucleus N. oculomotorii.  
 of metamere, 197, **127.**  
 of the middle line (Nissl), 677, 679.  
 olivaris accessorius dorsalis, **310, 377.**  
 olivaris accessorius medialis, **309, 310, 323, 324, 376, 377.**



- Nucleus olivaris inferior, 176, **309-312, 329, 376, 577, 610.**  
 olivaris superior, **313, 382, 386, 843, 851, 544.**  
 olivaris superior, fibre system to nucleus N. abducentis from, **422.**  
 olivaris superior, peduncle of, 852, **543.**  
 posterior thalami, **440.**  
 præolivaris, 843, **548, 857.**  
 radieis descendentes N. trigemini, see Nuclei motorii minores N. trigemini.  
 respiratory, of Misslawsky, see Nucleus funiculi ventralis.  
 reticularis tegmenti, **322, 386, 570, 401, 405, 420, 614.**  
 ruber, **317, 324, 670.**  
 ruber, crossing descending spinal system from, 972.  
 semilunaris, 857, 858, **549, 843.**  
 tractus solitarius, **310, 319, 479, 486, 624-626.**  
 tractus spinalis N. trigemini, **308, 309, 313, 320-322, 343, 346, 373, 375, 517, 641.**  
 ventralis thalami, **443.**  
 Y, **311, 318, 507.**  
 Nuel's space, **364.**  
 Nutrition theory (Golgi), 258.
- Obere Schleife*, 688, 692.  
*Oberer Kern*, (Burdach), 674.  
*Oculomotoriuskern* of Darkschewitsch, see Nucleus fasciculi longitudinalis medialis.  
 Obex, **372.**  
 Occipital cortex, fibres from superior colliculus to, 819.  
 cortex, lesions in, 817.  
 Oculomotor nerve, see Nn. oculomotorii.  
 Olfactory apparatus of the carp, **500.**  
 bulb, see Bulbus olfactorius.  
 conduction path, central neurones of, 748.  
 glomeruli, see Glomerulus olfactorius.  
 Olfactory granules, 756, **485.**  
 islands, 761, **487, 488.**  
 lobe, see Lobus olfactorius.  
 nerves, see N. olfactorii.  
 organon, see Organon olfactorium.  
 tract, see Tractus olfactorius.  
 Olivary fasciculus, 954, **609.**  
 Olive, inferior, see Nucleus olivaris inferior.  
 superior, see Nucleus olivaris superior.  
*Olivenstrang*, 955, **609.**  
 Operculum, **564.**  
 Ophthalmic vesicle, 118.  
 Optic chiasma, see Chiasma opticum.  
 nerve, see N. opticus.  
 neurones of higher orders, 782.  
 paths, see Visual conduction paths.  
 radiation, see Radiatio occipito-thalamica (Gratioleti).  
 thalamus, see Thalamus.  
 tract, see Tractus opticus.  
 Organon olfactorium, 188, **157.**  
 spirale (Corti), **364.**  
 Orang-outang, motor localization in cerebral cortex of, 1000, **635.**  
 Osmatic animals, 749.
- Pacinian corpuscles, **223, 245, 253, 354, 393, 394, 396.**  
 Pain points, 253.  
 Pallium, **89.**  
 extirpation of motor areas in, 1022, **645.**  
 Papilla nervi optici, 784.  
 Papillæ vallatæ, 526.  
 Paracentral lobule, see Lobulus paracentralis.  
 Paraphasia, 1078.  
 Parapyknomorphous cells, 123, **67.**  
 Paraxone, 270.  
*Paraxonen*, 90.  
 Pars basilaris fasciculi pedunculo mammillaris, 772.  
 basilaris pontis, **315.**  
 mammillaris hypothalami, **89.**  
 optica hypothalami, **89.**

- Path, frontal cerebro-cortico-pontal, **356**.  
 occipito-temporal cerebro-cortico-pontal, **386**.  
 Peduncle, inferior, see Corpus restiforme.  
 middle, see Brachium pontis.  
 of cerebrum, see Pedunculus cerebri.  
 of corpus callosum, see Gyrus subcallosus.  
 of thalamus, see Pedunculus thalami.  
 superior, see Brachium conjunctivum.  
 Pedunculus cerebelli inferior, see Corpus restiforme.  
 cerebri, **89, 386, 980, 989**.  
 cerebri, localization of fibres in, (Floche), **1020**.  
 corporis mammillaris, see Fasciculi pedunculo-mammillares, pars basilaris.  
 corporis callosi, see Gyrus subcallosus.  
 flocculi, **310, 311, 368**.  
 medius, see Brachium pontis.  
 superior, see Brachium conjunctivum.  
*Pedunculusschleife* (Flechsig), **684**.  
 Pedunculus thalami medialis, **444**.  
 Pelvis, sclerozones of, **131 132**.  
 Perforated space or lamina, anterior, see Substantia perforata anterior.  
 Perieapsular plexus, **115**.  
 Pericellular network, **150, 153, 86, 87**.  
 Perikaryon, **66**.  
 Perinuclear zone of Apáthy, **56, 59**.  
 Peripheral centrifugal neurones, see Neurones, peripheral centrifugal.  
 nerves, components of, **921**.  
 Perpendicular fissure, external, see Fissura parieto-occipitalis.  
 Pes hippocampi, see Hippocampus.  
 pedunculi, see Basis pedunculi.  
 Phosphorus, effects of, **283, 170**.  
 Planum fibrillare profundum, **642**.  
 Plexus brachialis, **186, 325**.  
 cervicalis, **186, 325**.  
 cervico-brachialis, **186, 325**.  
 coeeygeus, **187, 325**.  
 lumbalis, **187, 325**.  
 lumbo-sacralis, **187, 325**.  
 pudendus, **187, 325**.  
 pudendo-candalis, **187, 325**.  
 sacralis, **187, 325**.  
*Pli courbe*, see Gyrus angularis.  
 Pneumogastric nerve, see N. vagus.  
 Poisons, effects of, **282-288, 295**.  
 Poliomyelitis, spinal cord in, **584**.  
 Polyaxones, **81, 42, 43**.  
 Polymeric muscles, **201**.  
 Polystratified cells of retina, **783**.  
 Pons (Varoli), see Metencephalon.  
 Ponticulus, **372, 377**.  
 Posterior cerebral vesicle, **88**.  
 longitudinal bundle, see Fasciculus longitudinalis medialis.  
 nuclei of thalamus, **678**.  
 olfactory lobe, see Lobus olfactorius.  
 Post-mortem changes in nerve cells, **306**.  
 Postotic myotomes, **920**.  
 Præuneus, Plate I, **4**.  
*Prædorsalis Langsbündel*, **720, 969**.  
 Precentral sulcus of cerebrum, see Sulcus præcentralis.  
 Primary optic centres, **797**.  
 Primitive fibrils (Apáthy), **272**.  
 segments, **195**.  
 Processus cerebelli ad cerebrum (Stillings), **650, 428**.  
 Projection fibres, **665**.  
 Proötic myotomes, **919**.  
 Prosencephalon, **163**.  
 Protoplasmic commissure, **890, 571**.  
 continuity, **7**.  
 processes, see Dendrites.  
 Proximal nerve trunks, **209, 136, 138**.  
 Psalterium, see Commissura hippocampi.  
 Pulvinar, **536, 681, 440**.  
 termination of fibres from, **818**.  
 termination of optic fibres in, **513**.

- Punksubstanz* of Leydig, 273.  
Pupil, reflex contraction of, 830.  
Purkinje, corpuscles or cells of, 1, 12, 69, 72, 75, 38.  
Pyknomorphous cells, 123, 70.  
Pyramidal bundles, see *Fasciculi cerebro-spinales*.  
cells, 12, 68, 69, 75, 33, 37, 976, 620.  
tract, see *Fasciculi cerebro-spinales*.  
Pyramids, anterior, see *Pyramis (medullæ oblongatæ)*.  
decussation of, see *Decussatio pyramidum*.  
Pyramis (*medullæ oblongatæ*), 308-312, 368, 375, 990.  
Quadriceps femoris muscle, nucleus of, 905, 583.  
Quadrigeminal bodies, see *Corpora quadrigemina*.  
Radiatio corporis callosi, 1054.  
occipito-thalamica (*Gratioleti*), 814, 822, 823, 522, 523.  
occipito-thalamica (*Gratioleti*), ending of fibres of, 822, 823, 528.  
Radices nervorum cerebralis, see corresponding nerves.  
Radix descendens (*mesencephalica*)  
*N. trigemini*, see *N. trigeminus*.  
dorsalis, 559, 194-200, 333, 341.  
dorsalis, development of, 181.  
posterior, see *Radix dorsalis*.  
ventralis, 885.  
*Randschleier* of His, see *Marginal veil*.  
*Randzellen* of sensory nucleus of trigeminus, 642.  
*Rautenhirn*, see *Rhombencephalon*.  
Reaction at a distance, 297.  
Recessus geniculi, 90.  
infundibuli, 90.  
mammillaris, 90.  
utriculi, 361.  
Rectus abdominis, nerve endings in, 894.  
Red nucleus, see *Nucleus ruber*.  
Regeneration of nerve fibres, 245.  
Regio subthalamica, see *Hypothalamus*.  
subthalamica, layers of, 671.  
Reil, island of, see *Insula*.  
Restiform body, see *Corpus restiforme*.  
Reticular formation, see *Formatio reticularis*.  
zone, nuclei of, 677.  
Retina, 357, 358, 360.  
*Retinaantheil* of corpus geniculatum laterale, 798.  
Retina, bipolar cells of, 543.  
comparison with other sense organs, 541.  
ganglion cells of, 783.  
layers of, 533, 784, 529.  
origin of, 187.  
rods and cones of, 535.  
Retraction theory, 100.  
Rhinnencephalon, 748.  
divisions of, 751, 754.  
Rhombencephalon, lower motor neurones of, 915.  
Ricin poisoning, 297, 153.  
*Riesenpyramidenzellen* (*Betz*), 978, 622.  
Rolando, fissure of, see *Sulcus centralis Rolando*.  
substantia gelatinosa of, see *Nucleus tractus spinalis nervi trigemini*.  
Roller's nucleus, 926.  
Roof, ganglion of, see *Nucleus fastigii*.  
Roots of spinal nerves, see *Radix ventralis*, *Radix dorsalis*.  
of spinal nerves, groups of fibres in, 901.  
Rostrum corporis callosi, 1053.  
*Ruban de Reil*, see *Lemniscus*.  
cortical, see *Cortical lemniscus*.  
inférieur, see *Lemniscus lateralis*.  
supérieur, 680, 692.  
Ruffini, nerve endings of, 246, 247, 249, 250.

- Sacral nucleus, see Nucleus dorsalis.
- Sartorius muscle, nerve endings in, 894.
- Scala tympani, **362**.  
vestibuli, **362**.
- Scarpa's ganglion, see Ganglion vestibulare.
- Schalenförmiger Körper* (von Tschisch), 674.
- Schaltzellen* (von Monakow), 1036.
- Schizaxones, 82, **46**.
- Schleife, see Lemniscus.
- Schleife aus dem oberen Zweihügel*, **435**.
- Schultze's comina, 390, **295-298**, 448-451, 454-475.
- Scissors of the brain (Stilling), **428**.
- Sclerotome, 196, **127**.
- Sclerozone, 208.
- Secondary degeneration, see Degeneration, Wallerian.  
degeneration in pyramidal tract, 1010, **641**.  
degeneration of motor fibres after cerebral lesion, **643**.
- Segmentation of body, 193.
- Segments of spinal cord, function of, 903.
- Sehphärenantheil* of corpus geniculatum laterale, 798.
- Seitenlinie*, see Lateral line.
- Seitliche Grenzschrift der grauen Substanz*, see Fasciculus lateralis limitans.
- Semi-decussation in optic chiasm, 786.
- Sense centres, cortical, lesions of, 1074.
- Sensory components of cerebral nerves, 924, **592**.  
conduction paths to central gyri, 704.  
conduction paths to cortex, 734.  
cutaneous areas, 330-349, **188, 189, 190-195**.  
cutaneous areas (anæsthesia), **201**.  
cutaneous areas (pain), **197, 198, 199, 200**.
- Sensory ganglia, see Ganglia, sensory.  
nerve fibres, development of, 181.  
nucleus of N. trigeminus, 642.  
optic centres, 797.  
systems, I, II, III of Flechsig, 735, **466-468**.
- Septo-marginal bundle of Bruce and Muir, see *Triangle médian* of Gombault et Philippe.
- Septum pellucidum, Plate I, **3**.
- Sheath of Henle, 86.
- Side fibrils, 12, **41, 93, 57, 892**.
- Silent areas of cerebral cortex, 1071.
- Small-celled hypoglossal nucleus of Roller, 926.
- Sohlenssubstanz*, **574**.
- Solitary bundle, see Tractus solitarius.
- Somæsthetic area of the cortex, 667.  
conduction path, *résumé* of, 739, **469-471**.  
path to cerebrum by cerebellum, 647.
- Somatic components of peripheral nerves, 921.
- Somatochrome cells, 115, 121, **67, 68**.
- Somatoplasin, **53, 55**.
- Somites, 88.
- Space, perforated, anterior, see Substantia perforata anterior.
- Special senses, centres for, see Sense centres.
- Specific energy, 254, 255.
- Spinal accessory nerve, see N. accessorius.  
cord, bulb or marrow, see Medulla spinalis.  
cord, motor localization in, 899.  
nerves, see Nn. spinales.  
neurone system from formatio reticularis, 962.  
roots, groups of fibres in, 901.
- Spongioblasts, 166, **99, 537**.
- Stereognostic sense, 1077.
- Stichochrome cells, 117, 121, **70, 71**.
- Stiel des medialen Kniehöckers*, 875.
- Strato biancocinereo profundo, 809.  
biancocinereo superficiale, 809.



- Stratum album medium, 809.  
 album profundum, 809.  
 calcarinum, 1059.  
 glomerulosum of olfactory bulb, 755, 478.  
 griseum centrale, 315-317, 319-324, 386, 579, 809, 831.  
 griseum colliculi superioris, 809, 868, 555-558.  
 griseum of olfactory bulb, 755, 478.  
 griseum profundum, 809, 518.  
 interolivare lemnisci, 309-312, 321-324, 379, 563, 565, 402, 416, 422.  
 moleculare seu gelatinosum, 755, 478.  
 proprium eunei, 1061.  
*sagittale externum*, see Fasciculus longitudinalis inferior.  
*sagittale internum* (Sachs), 815, 520.  
 zonale colliculi superioris, 808, 809.
- Stria medullaris, 774.  
 medullaris thalami, relation to hippocampus and basal ganglia, 774, 497.  
 olfactoria lateralis, 756, 759.  
 olfactoria medialis, 756.
- Striæ acusticæ, see Striæ medullares.  
 medullares (seu acusticæ), 369, 372, 586, 549, 553, 840.
- Stripe of Vieq d'Azyr, 638.
- Strychnine, effects of, 285.
- Subconscious impulses, 250.
- Substantia alba of cord, stimulation of, 640.  
 gelatinosa, 306, 390, 403, 417, 419, 470, 641.  
 gelatinosa centralis, 373.  
 gelatinosa (Rolandi), see Nucleus tractus spinalis nervi trigemini.  
 grisea, 405, 414, 419, 473.  
 nigra, 316, 317, 386, 579.  
 nigra, termination of thumb fibres in, 1028.  
 perforata anterior, 590.
- Subthalamic tegmental region, see Tegmentum and Hypothalamus.
- Sulci temporales transversii, 638.
- Sulcus centralis (Rolandi), 633.  
 einguli, 92.  
 einguli, pars marginalis, 92.  
 einguli, pars subfrontalis, 92.  
 frontalis inferior, 638.  
 frontalis superior, 638.  
 hypothalamicus (Monroi), 90.  
 parolfactorius posterior, 750.  
 præcentralis, 633.  
 rhinencephali inferior, 752, 476, 477.  
 semilunaris, 752.  
 spiralis, 362.  
 subparietalis, 92.  
 temporalis superior, 638.
- Superficial arched fibres, see Fibræ arcuatae externæ.  
 optic path, 821.
- Superior colliculus, see Colliculus superior.  
 lemniscus, 688, 692.  
 medullary velum, see Velum medullare anterius.  
 olive, see Nucleus olivaris superior.  
 olivary complex, 843.
- Supramarginal gyrus, see Gyrus supramarginalis.
- Sylvian aqueduct, see Aqueductus cerebri.  
 fissure, see Fissura cerebri lateralis.  
 fossa, see Fossa cerebri lateralis.
- Sympathetic ganglia, 190.
- Sympathicus, 330.
- Synapsis, 86.
- Systema lemniscale myelencephalo-diencephalicum*, 701.  
*lemniscale myelencephalo-palliale*, 714.  
*myelencephalo-cerebellare cruciatum*, 741.  
*myelencephalo-cerebellare non-cruciatum*, 741.  
 (neuronicum) *diencephalo-palliale*, 701.  
 (neuronicum) *myelencephalo-palliale*, 701.  
 (neuronicum) *myelencephalo-thalamicum*, 714.

- Systema (neuronicum) spino-cerebellare ventro-laterale conjunctivale*, 599.
- (*neuronicum*) *spino-thalamicum ventro-laterale*, 600.
- (*neuronicum*) *spino-quadrigenum ventro-laterale superius*, 599.
- Tabes, degenerations in, 243, 244, 254, 428, 436.
- Tania chorioidea, 774, 496.
- thalami, 774, 496.
- Tapetum, 522, 523, 1054, 1067.
- Taste-buds, see Calyculi gustatorii.
- Tastzellen* and *Tastmenisci* of Merkel, 220, 221.
- Tautomerie neurones, see Neurones, tautomerie.
- Tegmental bundle of lentiform nucleus, 674.
- bundle of red nucleus, 674.
- bundle of thalamus, 674.
- projection, 96.
- Tegmentum, decussations of, 772, 492.
- paths to, 668.
- Telencephalon, 159, 89.
- motor neurones of, 975.
- Telodendrion, 41, 82.
- Telodendria of motor axone, 895, 574.
- Temporal cerebro-cortico-pontal path, 1045, 1046.
- gyri, auditory fibres ending in, 878.
- Temporale Grosshirnrinde-Brückenbahn*, see Temporal cerebro-cortico-pontal path.
- Riechosphäre* (Flechsig), 759.
- Testes, see Colliculus inferior.
- Tetanus-toxin, effects of, 181, 182, 302.
- Thalamus, 89.
- bundle from nucleus ruber to, 428.
- nucleus of, 673, 676, 678, 679.
- ventro-lateral nuclei of, 569.
- Thalamusmassiv* (Tschermak), 682.
- Thalamusschale* (Tschermak), 682.
- Threshold of island, see Limen insulæ.
- value, 253.
- Thumb area, pyramidal fibres from, 1030.
- Tigroid, 45, 47, 106, 108, 111, 112, 127, 129, 130, 132, 134, 155, 156, 64, 65, 75, 76.
- Tongue, origin of muscles of, 591, 920.
- Touch points, 253.
- Tract or tracts, antero-lateral ascending, see Fasciculus ventro-lateralis.
- Tract, comma, see Comma of Schultze and Schultze's comma.
- crossed or lateral pyramidal, see Fasciculus cerebro-spinalis lateralis.
- direct cerebellar, see Fasciculus spino-cerebellaris dorso-lateralis.
- direct pyramidal, see Fasciculus cerebro-spinalis ventralis.
- of Burdach, see Fasciculus cuneatus.
- of fillet, see Lemniscus.
- of Gowers, see Fasciculus cerebro-spinales superficialis.
- of Goll, see Fasciculus gracilis.
- of Lissauer, see Fasciculus dorso-lateralis Lissaueri.
- olfactory, see Tractus olfactorius.
- optic, see Tractus opticus.
- pyramidal, see Fasciculi cerebro-spinales.
- Tractus opticus, 796, 509, 798.
- olfactorius lateralis, 478.
- olfactorius medialis, 478.
- peduncularis transversus, 807.
- solitarius, 102, 309, 312, 318-320, 326, 327, 376, 485, 407, 626.
- spinalis N. trigemini, 308, 309, 311, 320-322, 329, 346, 377, 391, 392, 407, 411-413, 416, 417, 419, 421, 422.
- tegmento-cerebellaris (Edinger), 664.
- Trapezium, see Corpus trapezoideum.

- Trapezoidal body, see Corpus trapezoideum.
- Triangular path of Helweg, 954.
- Triangle médian* of Gombault et Philippe, 452-457.
- Triceps muscle, nerve endings in, 894.
- Trigeminal nerve, see N. trigeminus. neurones, central centripetal, 641.
- Trigeminus, fibres to formatio reticularis from terminal nucleus of, 728, **464**, **465**.
- Trigonum lemnisci, 686, 847.
- Trochlear nerve, see N. trochlearis.
- Trophic centres, 226.
- Trophicity, theories of, 306-311.
- Truncus corporis callosi, 1053.
- Trunk area of motor cortex, 999, **663**.
- Tuber cinereum, **90**.
- Tubercle, acoustic, see Nucleus N. cochleæ dorsalis.
- cuneate, see Tuberculum cuneatum.
- of optic thalamus, anterior, see Nucleus anterior thalami.
- of optic thalamus, posterior, see Pulvinar.
- Tubercules quadrijumeaux*, see Corpora quadrigemina.
- Tuberculum cuneatum, 560.
- laterale s. acusticum, see Nucleus N. cochleæ dorsalis.
- Tunnel cord, **364**.
- space, **364**.
- Türk, column of, see Fasciculus cerebrospinalis ventralis.
- Türk's degeneration, 225.
- Uncinate fasciculus, see Fasciculus uncinatus.
- gyrus, see Uncus.
- Uncus, Plate I, 4.
- connection of hippocampus with, **489**.
- termination of fibers of stria olfactoria in, 759.
- Unipolar cells, **36**, **113**, **114**.
- Upper face centre, 997.
- facial nerve, 930.
- motor neurones, 952.
- Upper motor neurones, relation to lower motor neurones, 1036.
- motor neurones, lesion of, 1039.
- Untersehleife*, see Lemniscus lateralis.
- Ursegmente*, 195.
- Urwirbelkern*, 197.
- Utriculus, **361**.
- Vagal nucleus, see Nucleus alae cinereæ.
- Vagus nerve, see N. vagus.
- Vallate papillæ, see Papillæ vallatæ.
- Valve of Vieussens, see Velum medullare anterius.
- Vascular segment, 196.
- Vater, corpuscles of, see Pacinian corpuscles.
- Velum medullare anterius, **372**.
- medullary, superior, see Velum medullare anterius.
- Ventral horn, see Columna grisea ventralis.
- horn cells of cervical cord, 905, **578-582**.
- nucleus of lateral geniculate body, 679.
- nucleus of the sixth nerve, 932.
- nuclei of thalamus, 678, 680, 681.
- tegmental decussation, see Decussatio tegmenti ventralis.
- Ventricle, fourth, see Ventriculus quartus.
- Ventricles, lateral, see Ventriculus lateralis.
- of brain, see Ventriculus lateralis et quartus.
- Ventriculus lateralis, **651**, **653**.
- quartus, **309**, **318**, **372**.
- Ventro-lateral cell-group of anterior horn, see Neurones, lower motor.
- lateral tract, ascending, see Fasciculus ventro-lateralis superficialis.
- Veratrin, effects of, 283, **171**.
- Vermiform process, see Vermis.
- Vermis, 568, 575.
- connection of nuclei of roof with, **424**, **425**.

- Vestibulo-spinal path, 959.
- Vicq d'Azyr, bundle of, see Fasciculus thalamo-mammillaris (Vicq d'Azyr).
- Villi, choroidal, see Plexus chorioideus.
- Visceral motor and sensory components of peripheral nerves, 921.
- Visual area of cortex cerebri, lesions of, 817.
- centres, connection with cord and bulb, see Visual conduction paths.
- conduction paths, **529, 532, 533, 534.**
- conduction paths, centrifugal fibres of, 832.
- conduction paths, decussation in, **530.**
- direction, cortical area for, 998.
- sense area, primary, 822, 823.
- Vital staining, see Ehrlich's vital staining.
- Vorderstrangrest*, **374.**
- Wallerian degeneration, see Degeneration, secondary or Wallerian. doctrine and the neurone-concept, 226.
- Warm points, 253.
- Wernicke's field, 814.
- hemianopic pupillary sign, 832.
- White columns of cord, see Funiculi.
- commissure of cord, see Commissura alba.
- matter of cerebral hemispheres, see Centrum semiovale.
- Worm, see Vermis.
- Zerstreute accessorische Bündel* (von Bechterew), 684.
- Zona incerta, 671, 672, **437.**
- reticularis (*Gitterschicht*), **438, 677.**
- Zone F (Munk), removal of, 697.
- Zone motrice* (Charcot), 975.
- of confusion, 995, **632.**







# LEGENDS FOR PLATES.

## PLATE I.

### SCHEMATIC REPRESENTATION OF SOME OF THE NEURONE SYSTEMS OF THE PRINCIPAL MOTOR AND SENSORY CONDUCTING PATHS IN THE NERVOUS SYSTEM.

**Fig. 1.**—Sensory and motor paths in the spinal cord.

**Black.**—*Med. oblong.*, transverse section through the medulla oblongata at the level of the decussatio lemniscorum; *Med. sp. pars cerv.*, transverse section through the medulla spinalis pars cervicalis; *Med. sp. pars lumb.*, transverse section through the medulla spinalis pars lumbalis; *Med. sp. pars thorac.*, transverse section through the medulla spinalis pars thoracalis; *Sens. surface*, sensory surface.

**Red.**—The areas of white matter in the spinal cord and medulla oblongata occupied by sensory axones are indicated by red lines or dots. The cell bodies and axones of sensory neurones are also colored red. *D. l.*, decussatio lemniscorum; *D. r. f.*, dorsal root fibre (central axone of peripheral centripetal neurone); *F. c.*, axone of fasciculus cuneatus; *F. cl.*, axone of fasciculus cerebellospinalis (direct cerebellar tract); *F. rl. G.*, axone of fasciculus ventrolateralis [Gowers]; *St. i. l.*, axones of stratum interolivare lemnisci; *I.*, cell bodies of peripheral centripetal neurones (situated in the spinal ganglia); *I'*, ascending limb of bifurcated central axone of peripheral sensory neurone extending from the pars lumbalis of the spinal cord to the medulla oblongata, being situated first in the fasciculus cuneatus, in higher levels of the cord in the fasciculus gracilis, and finally terminating in the nucleus funiculi gracilis. *I''*, ascending limb of bifurcated central axone of peripheral sensory neurone pertaining to the thoracic portion of the spinal cord. It enters the fasciculus cuneatus, and passing upward, approaches the medial border of this fasciculus without, however, entering the fasciculus gracilis. It is seen to terminate ultimately in the nucleus funiculi cuneati. *I'''*, ascending limb of bifurcated central axone of peripheral sensory neurone pertaining to the pars cervicalis of the spinal cord. It passes upward in the fasciculus cuneatus to terminate at a level higher than that indicated in the diagram. *I''''*, reflex collaterals extending from the central axones (or their subdivisions) of the peripheral sensory neurones to the ventral horns of the spinal cord, there coming into conduction relation with the cell bodies and dendrites of the lower motor neurones. *1.*, collaterals from the axones of the fasciculus cuneatus to the nucleus dorsalis [Clarkii]; *2.*, cell bodies in substantia grisea giving rise to axones of the fasciculus ventrolateralis [Gowers]; *3.*, cell bodies in nucleus dorsalis [Clarkii] giving rise to axone of fasciculus cerebellospinalis; *3'*, axone of fasciculus cerebellospinalis (direct cerebellar tract); *4.*, cells of nucleus funiculi gracilis giving rise to axones of fibre arcuatae internae which undergo decussation (decussatio lemniscorum) in the raphe; *4'*, continuation of axones of fibre arcuatae internae after decussation. They run cerebralward in the stratum interolivare lemnisci. *5.*, cells of nucleus funiculi cuneati which give rise to axones of fibre arcuatae internae which undergo decussation (decussatio lemniscorum) in the raphe. *5'*, continuation of axones of fibre arcuatae internae after decussation. Having had their origin in the nucleus funiculi cuneati of the opposite side, they now run forward in the stratum interolivare lemnisci.

**Blue.**—The areas of white matter in the spinal cord and medulla oblongata indicated by parallel blue lines correspond to the position of the fasciculi cerebrospinales (pyramidales). The cell bodies and axones of the lower motor neurones are also printed in blue. *F. cs. l.*, fasciculus cerebrospinalis lateralis or lateral pyramidal tract; *F. cs. r.*, fasciculus cerebrospinalis ventralis or ventral pyramidal tract; *F. Py.*, fasciculi pyramidales in the medulla oblongata; *Py.*, pyramis medullae oblongatae; *r. r.*, radix ventralis nervi spinalis; *1.*, cell bodies of lower motor neurones situated in the ventral horns of the gray matter of the spinal cord giving off axones which go to form the ventral roots of the spinal nerves; *3.*, axones of fasciculi pyramidales which undergo decussation in the decussatio pyramidum and pass down in the fasciculus cerebrospinalis lateralis of the opposite side of the spinal cord to terminate in the ventral horns of the cervical region. They throw the lower motor neurones which innervate the musculature of the upper extremity of one side under the influence of the pallium of the opposite side. *4.*, axones of fasci-

## LEGENDS FOR PLATES.

uli pyramidales which undergo decussation in the decussatio pyramidum and pass down in the fasciculus cerebrospinalis lateralis of the opposite side of the spinal cord to terminate in the ventral horns of the lumbosacral region. They throw the lower motor neurones which innervate the musculature of the lower extremity of one side of the body under the influence of the pallium of the opposite side. *4''*, axone of fasciculi pyramidales which does not undergo decussation in the decussatio pyramidum, but passes down in the fasciculus cerebrospinalis lateralis of the same side (homolateral fibre). *4'''*, axone of fasciculi pyramidales which does not undergo decussation in the decussatio pyramidum, but passes down in the fasciculus cerebrospinalis ventralis to terminate in the ventral horn of the same side. It would throw the lower motor neurones governing a portion of the musculature of one side under the influence of the pallium of the same side. It is probable that in addition to these fibres of the fasciculus cerebrospinalis ventralis, which terminate in the ventral horn of the same side, there are other fibres (not shown in the diagram) which, passing through the ventral commissure, terminate in the ventral horn of the opposite side. (See text.)

*Yellow*.—Cell bodies, axones, collaterals, and terminals belonging to the fasciculi proprii of the ventral and lateral funiculi.

**Fig. 2.**—Exit and entrance of Nervi cerebrales at the base of the skull. The nerves of general sensation are printed in red, the optic nerves, chiasm, and optic tracts in yellow, the olfactory nerves in orange, the cochlear nerve in green, and the motor nerves in blue. *I*, Nn. olfactorii; *II*, N. opticus; *III*, N. oculomotorius; *IV*, N. trochlearis; *V*, N. trigeminus; *VI*, N. abducens; *VII*, N. facialis et intermedius; *VIII*, N. cochleæ et vestibuli; *IX*, N. glossopharyngeus; *X*, N. vagus; *XI*, N. accessorius; *XII*, N. hypoglossus; *1*, peripheral olfactory neurones; *G. s. G.*, ganglion semilunare Gasseri.

**Fig. 3.**—Horizontal section through cerebral hemisphere at level indicated in Fig. 4 with schematic continuation of fibres above the section toward the cortical regions in which they arise or terminate.

*Black*.—*C. so.*, centrum semiovale; *Caput nucl. caud.*, caput nuclei caudati; *Cauda nucl. caud.*, cauda nuclei caudati; *Col. for.*, columna fornicis; *Corp. call.*, corpus callosum; *Fimb.*, fimbria; *Fiss. calc.*, fissura calcarina; *Fiss. c. l. S. r. p.*, fissura cerebri lateralis Sylvii, ramus posterior; *Fiss. po.*, fissura parieto-occipitalis; *Foss. c. l. S.*, fossa cerebri lateralis Sylvii; *G. c. a.*, gyrus centralis anterior; *G. c. p.*, gyrus centralis posterior; *G. f. i.*, gyrus frontalis inferior; *G. f. m.*, gyrus frontalis medius; *G. f. o.*, gyrus fornicatus; *G. f. s.*, gyrus frontalis superior; *G. insule*, gyri insule; *G. ling.*, gyrus lingualis; *Glob. pall.*, globus pallidus; *G. o. s.*, gyri occipitales superiores; *G. t. m.*, gyrus temporalis medius; *G. t. s.*, gyrus temporalis superior; *Hippoc.*, hippocampus; *M. s. of V.*, macroscopic stripe of Vicq d'Azyr; *N. a. l.*, nucleus anterior thalami; *N. l. l.*, nucleus lateralis thalami; *N. m. l.*, nucleus medialis thalami; *Radiatio occ. th. Grat.*, radiatio occipitohalamica Gratioletti; *S. c. R.*, sulcus centralis Rolandi; *Sept. pell.*, septum pellucidum; *Vent. lat. a.*, ventriculus lateralis, cornu anterius; *Vent. lat. p.*, ventriculus lateralis, cornu posterius; *Vent. tert.*, ventriculus tertius.

*Red*.—The lines represent sensory axones continued above the level of the cross section out toward their cortical terminations. The dotted lines represent the regions in which the fibres run down into the white substance below the level of the section. The red dots represent cross sections of fibres not continued above the level of the section. *I*, axones of the general sensory path belonging to Flechsig's embryological system No. 1, being distributed principally to the central gyri. *II*, axones of the general sensory path belonging to Flechsig's embryological system No. 2, being distributed partly to the central gyri, the lobulus paracentralis and the foot of the gyrus frontalis superior, and partly to the gyrus fornicatus along its whole length; *II'*, the most posterior bundles of Flechsig's embryological system No. 2, entering the egingulum and running toward Ammon's horn; *III*, axones of the general sensory path belonging to Flechsig's embryological system No. 3, being distributed principally to the foot of the gyrus frontalis inferior. A portion of the fibres pass through the anterior limb of the internal capsule and run forward in the white matter of the centrum semiovale, reaching nearly the frontal pole, where they turn back at an acute angle and become distributed partly to the gyrus fornicatus and partly to the superior and middle frontal gyri.

*Blue*.—The lines represent motor axones arising from the cerebral cortex and passing down through the internal capsule. The dots represent other motor



## LEGENDS FOR PLATES.

fibres the cortical origin of which is not shown. *II*, axones from facial area of cortex running to the knee of the internal capsule. *III*, axones from the arm area of the cerebral cortex running to the anterior portion of the occipital limb of the internal capsule. *II'*, axones from the leg area of the cerebral cortex running to the internal capsule, being situated in the latter behind the arm fibres.

*Orange*.—Axones pertaining to the olfactory sensory conduction paths. *4'*, axone of neurone extending between the corpus mamillare and the hippocampus by way of the fornix; *6*, axone extending between the substantia perforata anterior and the hippocampus by way of the septum pellucidum and the fornix.

*Green*.—Axones pertaining to the auditory conduction path. They are seen emerging from the cross section behind the internal capsule and running out to the auditory sense area of the cerebral cortex. *8*, *9*, *10*, axones of diencephalo-telencephalic (projection) neurones pertaining to the auditory conduction path. The cell bodies of these neurones are situated below, chiefly in the corpus geniculatum mediale; the axones terminate in the gyrus temporalis superior and in the gyri temporales transversi.

*Violet*.—Axones pertaining to the frontal and temporal cerebrocortico-pontal paths. The fibres belonging to the frontal path arise chiefly in the region of the foot of the gyrus frontalis inferior and the feet of the middle and superior frontal gyri, and run into the frontal limb of the internal capsule. The origin of the temporal path is still uncertain; the fibres pass down at the posterior extremity of the internal capsule.

*Yellow*.—Axones pertaining to the visual conduction path. They are seen to emerge from the section at the occipital extremity of the pars occipitalis of the internal capsule and to run through the radiatio occipitothalamica Gratiolelli, to be distributed in those regions of the cortex of the occipital lobe which are characterized by the presence of the macroscopic stripe of Vicq d'Azyr. The majority of the fibres, however, terminate near the fissura calcarina.

**Fig. 4.**—Scheme illustrating the relations of some of the principal conduction paths in the cerebrum as viewed from the medial surface. The fronto-occipital black line about the middle of the hemisphere corresponds closely to the level of Fig. 3, which is projected above. Above this line the cerebrum is made transparent.

*Black*.—*C. a.*, commissura anterior cerebri; *C. pin.*, corpus pineale (of the epithalamus); *Fiss. calc.*, fissura calcarina; *Fiss. po.*, fissura parieto-occipitalis; *Fiss. collat.*, fissura collateralis; *G. cing.*, gyrus cinguli; *G. f. s.*, gyrus frontalis superior; *G. fus.*, gyrus fusiformis; *G. hipp.*, gyrus hippocampi; *G. ling.*, gyrus lingualis; *G. t. i.*, gyrus temporalis inferior; *G. t. m.*, gyrus temporalis medius; *Lob. paracent.*, lobulus paracentralis; *P. f.*, polus frontalis; *P. o.*, polus occipitalis; *S. cinguli pars subfront.*, sulcus cinguli pars subfrontalis; *S. cinguli pars marg.*, sulcus cinguli pars marginalis; *S. subpariet.*, sulcus subparietalis; *Sept. pell.*, septum pellucidum; *Tractus olf.*, tractus olfactorius; *Trig. olfact.*, trigonum olfactorium.

*Red*.—The somesthetic area of the cerebral cortex, as seen from the medial surface, is indicated by red dots. The red area in the pars tegmentalis of the cerebral peduncle corresponds to the region occupied by the lemniscus medialis. The broken red lines correspond to various sensory axones on their way from the diencephalon to their end stations in the cortex of the pallium. *I*, axones belonging to Flechsig's embryological system No. 1, terminating in the lobulus paracentralis and adjacent central gyri; *II*, axones of Flechsig's embryological system No. 2, terminating in the gyrus fornicatus; *II'*, axone of Flechsig's embryological system No. 2, running into the cingulum and thence to the region of the hippocampus; *II'''*, axone belonging to Flechsig's embryological system No. 2, running from the nucleus lateralis thalami basalward, and entering by way of the uncus into the subiculum cornu ammonis from in front and below. *III*, axones belonging to Flechsig's embryological system No. 3, terminating in the middle portion of the gyrus fornicatus.

*Blue*.—Motor area of the cerebral cortex in which are situated the cell bodies of the neurones, the axones of which pass downward to throw the groups of lower motor neurones under their influence. The blue area in the cross section of the basis pedunculi corresponds to the region occupied by the fasciculi pyramidales. *I1'*, axones of pyramidal tract arising from the lobulus paracentralis (portion of leg area).

## LEGENDS FOR PLATES.

**Yellow.**—The visual sense area of the cerebral cortex is striated with this color. The optic nerve and the cut section of the chiasm are colored yellow. The dotted lines, 5, correspond to axones of the radiatio occipitothalamica Gratioleti. The minute yellow area in the superior colliculus of the corpora quadrigemina corresponds to the region in which are situated the mesencephalic terminals of the fibres of the optic tract.

**Green.**—The area marked by this color in the cross section of the pars tegmentalis of the cerebral peduncle corresponds to the position of the upward continuation of the lemniscus lateralis and of the brachium quadrigeminum inferius.

**Orange.**—Neurons and axones of neurons pertaining to the olfactory conduction paths. 2, 2', olfactory sensory neurons of the second order. The cell bodies are represented by the mitral cells and brush cells of the olfactory bulb, their medullated axones helping to form the white matter of the olfactory tract. 3, neurone, the cell body of which is situated in the substantia perforata anterior, its axone, 3', extending through the stria medullaris to terminate in the nucleus habenulae. 4, 4', neurone extending between the hippocampus and the corpus mamillare, the axone passing through the fornix. 6, 6', axones of neurons extending between the hippocampus and the septum pellucidum by way of the fornix. 7, axone passing through the commissura anterior cerebri. 8, olfactory axone extending along dorsal surface of corpus callosum. 9, 10, neurone connecting the temporal olfactory sense area with the hippocampus. 11, neurone, the cell body of which is situated in the nucleus habenulae, its axone running through the fasciculus retroflexus Meynerti to the interpeduncular region. 12, axone of fasciculus pedunculomamillaris, pars basilaris. 13, axone of fasciculus pedunculomamillaris, pars tegmentalis. 14, neurone extending between the substantia perforata anterior and the nucleus anterior thalami.

**Violet.**—The areas occupied by the cerebrocortico-pontal paths in the cut surface of the basis pedunculi are colored violet. The medial area corresponds to the frontal cerebrocortico-pontal path, while the lateral area corresponds to the temporal or temporo-occipital cerebrocortico-pontal path. Between the two is situated the blue area representing the fibres of the pyramidal tract.

**Fig. 5.**—Schematic representation of some of the conduction paths in the spinal cord, myelencephalon, and metencephalon.

**Black.**—*a*, transverse section through the cerebral peduncle; *b*, transverse section through the middle of the pons; *c*, transverse section near the junction of the pons with the medulla oblongata; *d*, transverse section through the middle of the medulla oblongata; *e*, transverse section through the lower extremity of the medulla oblongata near its junction with the spinal cord; *f*, transverse section through the cervical cord; *F. l. m.*, fasciculus longitudinalis medialis; *Med. oblong.*, medulla oblongata; *N. abduc.*, nervus abducens; *N. ocul.*, nervus oculomotorius; *N. n. v. l.*, nucleus nervi vestibularis lateralis (Deiters); *N. r.*, nucleus ruber; *Subst. nigra*, substantia nigra.

**Red.**—Neurons and axones pertaining to the paths of general sensation. The red area in the cross section of the cerebral peduncle indicates the region in which the lemniscus medialis is situated. *Br. conj.*, brachium conjunctivum; *Dec. lemn.*, decussatio lemniscorum; *Lemn. med.*, lemniscus medialis; *St. i. l.*, stratum interolivare lemnisci; 1, cell bodies of peripheral sensory neurons, the central axones of which help to form the nervi cerebrales; 1', axone of fasciculus gracilis running to terminate in the nucleus funiculi gracilis; 1'', axone of fasciculus cuneatus running to terminate in nucleus funiculi cuneati; 2', axone of fasciculus ventrolateralis Gowersi running to terminate in the cerebellum; 3', axone of fasciculus cerebellospinalis (direct cerebellar tract) running to terminate in the cerebellum; 4, neurone with cell body situated in nucleus funiculi gracilis, giving off axone which runs as an internal arcuate fibre to the raphe; 5, neurone of the nucleus funiculi cuneati giving off axone which runs as an internal arcuate fibre to the raphe; 6, cell body of neurone situated in the nucleus dentatus and giving off an axone which enters the brachium conjunctivum.

**Blue.**—Neurons and axones of neurons pertaining to the motor paths. *Dec. pyr.*, decussatio pyramidum; *Fasc. pyr.*, fasciculi longitudinales pyramidales; 1, cell bodies of lower motor neurons situated in the nuclei of the motor cerebral nerves; 2, motor axones derived from cells in the pallium throwing the nuclei of the cerebral nerves under the influence of the cerebral cortex by means of terminals, 2'; 3, axones of pyramidal tract terminating in the groups of lower motor neurons governing the movements of the upper

## LEGENDS FOR PLATES.

extremity; 4, axones of the pyramidal tract which terminate in the spinal cord in a region in which they can throw the lower motor neurones governing the muscles of the lower extremity under their influence.

*Orange*.—The small area of this color in the cross section of the cerebral peduncle corresponds to the fasciculus pedunculomammillaris, pars basilaris.

*Green*.—Axones of neurones pertaining to the auditory conduction path; *Lemn. l.*, lemniscus lateralis; 2, axones of lemniscus lateralis terminating in the colliculus inferior; 2'', axone of lemniscus lateralis passing through mesencephalon to terminate in the diencephalon, perhaps in the corpus geniculatum mediale.

*Violet*.—Axones and areas occupied by axones of the cerebrocorticopontal paths; 1, axone of frontal cerebrocorticopontal path. In the cross section of the cerebral peduncle it is seen to run through the medial bundle; in the cross section through the pars basilaris pontis it is seen to occupy a position somewhat ventral to that in which the pyramidal tract is situated. 2, axone of temporal or temporo-occipital cerebrocorticopontal path. In the cross section of the cerebral peduncle the bundle of axones of this path is situated lateral from the fibres of the pyramidal tract, while in the cross section of the pars basilaris pontis the axones are situated dorsolaterally as regards the fibres of the pyramidal tract. The fibres of both cerebrocorticopontal paths appear to terminate (or arise?) in large part in the nuclei pontis.

PLATE I.—Fig. 5



## LEGENDS FOR PLATES.

### PLATE II.

**Fig. 1.**—Schematic representation of some of the principal conduction paths in the central nervous system. The upper part of the cerebral hemisphere is supposed to be transparent, showing the origin of the motor and the termination of the sensory axones.

**Black.**—*C. gen. l.*, corpus geniculatum laterale; *C. gen. m.*, corpus geniculatum mediale; *C. i.*, colliculus inferior; *C. s.*, colliculus superior; *G. ang.*, gyrus angularis; *G. c. a.*, gyrus centralis anterior; *G. c. p.*, gyrus centralis posterior; *G. f. i.*, gyrus frontalis inferior; *G. f. m.*, gyrus frontalis medius; *G. f. s.*, gyrus frontalis superior; *G. o. l.*, gyri occipitales laterales; *G. o. s.*, gyri occipitales superiores; *G. s. m.*, gyrus supramarginalis; *G. t. i.*, gyrus temporalis inferior; *G. t. m.*, gyrus temporalis medius; *G. t. s.*, gyrus temporalis superior; *L. p. i.*, lobulus parietalis inferior; *L. p. s.*, lobulus parietalis superior; *N. glossopharyng.*, nervus glossopharyngeus; *N. cerv. l.*, nervus cervicalis primus; *Nucl. dentatus*, nucleus dentatus; *Nucl. hy. l.*, nucleus hypothalamicus (corpus Luysi); *Nucl. r.*, nucleus ruber; *P. o.*, polus occipitalis; *P. t.*, polus temporalis; *Ped. cer.*, pedunculus cerebri; *S. c. R.*, sulcus centralis Rolandi.

**Red.**—Neurones and axones of neurones pertaining to the general sensory path. *B. c.*, brachium conjunctivum (superior cerebellar peduncle); *Lemn. med.*, lemniscus medialis; *N. IX*, nervus glossopharyngeus; *I*, projection sensory neurones pertaining to Flechsig's embryological system No. 1; *II*, projection sensory neurones of Flechsig's embryological system No. 2; *III*, projection sensory neurones of Flechsig's embryological system No. 3; *III'*, axone of Flechsig's system No. 3, terminating in the gyrus frontalis inferior; *III''*, axone of embryological system No. 3, terminating in the foot of the gyrus frontalis medius. It will be noticed that the axones of projection systems 1, 2, 3 terminate in the somæsthetic area of the cortex—namely, the area indicated by red dots. It will be seen also that the somæsthetic area corresponds, in part at least, with the motor area (blue), as well as with the area of the cortex (violet) connected with the frontal cerebrocorticopontal path. *1*, cell bodies of peripheral sensory neurones situated in ganglia on the peripheral nerves. *1''*, ascending limb of bifurcated central axones of peripheral sensory neurone pertaining to the nervus cervicalis primus. It passes upward in the fasciculus cuneatus to terminate in the nucleus funiculi cuneati. *2*, axone of fasciculus ventrolateralis Gowersi passing upward through the medulla oblongata and pons, to turn back superior to the level of the nervus trigeminus into the velum medullare anterius, by way of which it enters the cerebellum, and ultimately terminates in the cortex of the vermis. *2'*, collateral given off to nucleus dentatus from axone of fasciculus ventrolateralis Gowersi in the cerebellum. *3*, axone of fasciculus cerebellospinalis (direct cerebellar tract) passing through corpus restiforme to enter cerebellum, where it terminates in the cortex of the vermis. It gives off in its course a collateral, *3'*, to the nucleus dentatus. *6*, cell bodies of neurones situated in the nucleus dentatus giving off axones which enter the brachium conjunctivum. *7*, axone of neurone arising from cell body in the nucleus hypothalamicus and terminating in the globus pallidus of the nucleus lentiformis.

**Blue.**—The light-blue striated area in the cerebral cortex corresponds to the motor region of the convex surface of the hemisphere. The dark-blue cell bodies and axones represent the motor neurones. *Dec. pyr.*, decussatio pyramidum; *Fasc. long. py.*, fasciculi longitudinales pyramidales; *II*, axones of upper motor neurones, the cell bodies of origin of which are situated in the face area of the cortex; *III*, axones of upper motor neurones derived from pyramidal cells situated in the arm area of the cortex; *IV*, axones of upper motor neurones derived from pyramidal cells in the leg area of the cortex; *I*, cell bodies of lower motor neurones; *2, 2'*, axones of pyramidal tract distributed to the groups of lower motor neurones pertaining to the cerebral nerves; *3*, axones of pyramidal tract distributed to groups of lower motor neurones, the axones of which innervate the muscles of the upper extremity; *4*, axones from pyramidal tract which terminate in the groups of lower motor neurones, the axones of which innervate the muscles of the lower extremity.

**Yellow.**—Neurones of visual conduction path. *1*, bipolar cells of the retina; *2*, ganglion cells of the retina, the axones of which enter the nervus opticus; *2'*, axones from nervus opticus entering the tractus opticus of the same side (fasciculus non-cruciatu); *2''*, axones of nervus opticus passing through the chiasm into the optic tract of the opposite side (fasciculus cruciatus). The fasciculus cruciatus of one side, *2''*, decussates in the chiasm with the



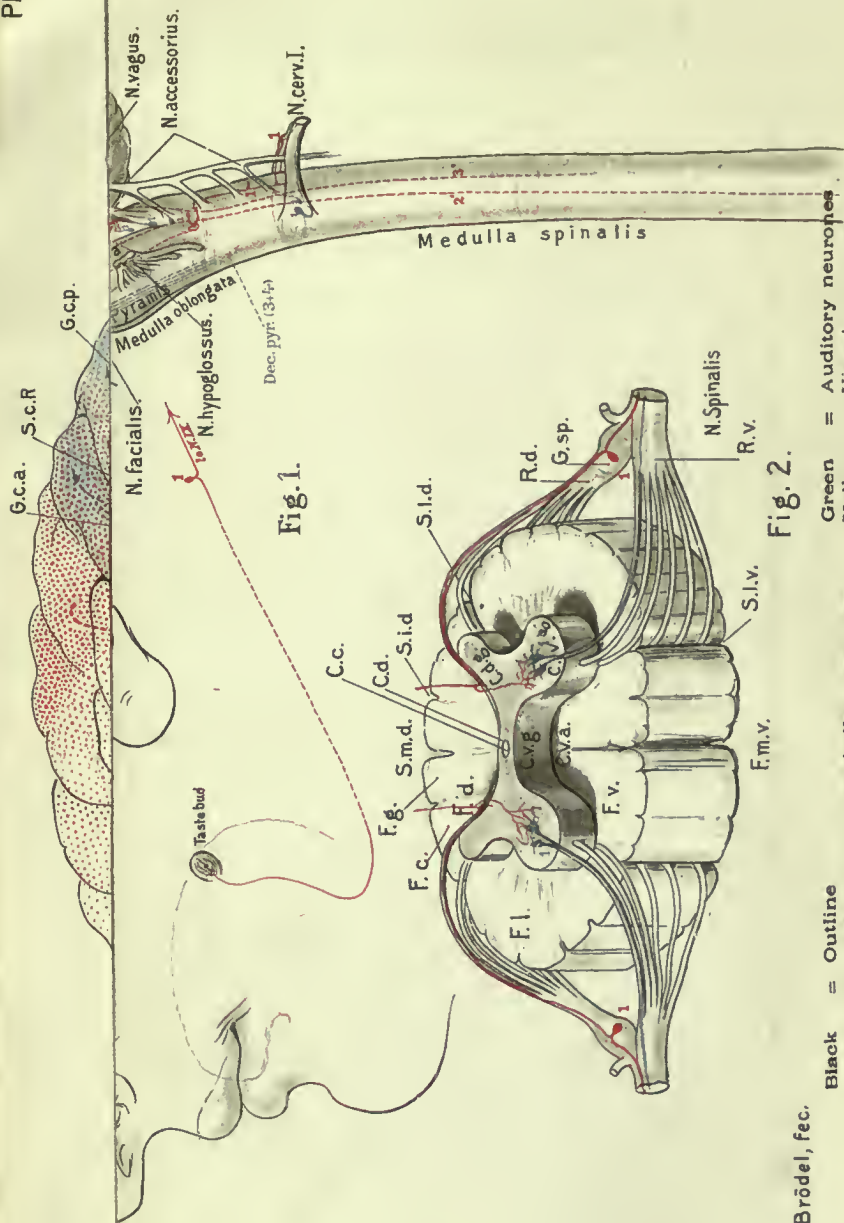


Fig. 1.

Fig. 2.

M Brödel, fec.

Black = Outline  
Violet = Cerebro-ponto-cerebellar neurones  
Blue = Motor neurones

Green = Auditory neurones  
Yellow = Visual neurones  
Orange = Olfactory neurones  
Red = General sensory neurones



## LEGENDS FOR PLATES.

fasciculus cruciatus of the opposite side,  $\mathcal{Z}''$ . It is seen that of the axones of the tractus opticus of one side, a part terminate in the mesencephalon (colliculus superior), another part in the diencephalon (corpus geniculatum laterale and pulvinar); 3, cell body of neurone in the corpus geniculatum laterale giving off an axone which passes by way of the occipitohthalmic radiation to the occipital lobe; 4, cell body in colliculus superior giving off axone which runs toward the cerebral cortex; 5, radiatio occipitohthalmica (Stratioletti), the constituent axones of which terminate in the visual sense area of the occipital cortex (region indicated by yellow stripe in the diagram).

*Green*.—Neurones of auditory conduction path. 1, peripheral auditory neurone, the cell body being situated in the ganglion spirale; its peripheral process is distributed to the organ of Corti, its central process forming one of the axones of the nervus cochleæ. 2, cell bodies of neurones situated in the nuclei terminales nervi cochleæ. Their axones pass by way of the corpus trapezoidum (not shown in the diagram) to enter the lemniscus lateralis of the same, more often of the opposite, side.  $\mathcal{Z}$ , axone from lemniscus lateralis terminating in colliculus inferior.  $\mathcal{Z}'$ , axone of lemniscus lateralis extending past the mesencephalon to terminate in the corpus geniculatum mediale. 3, cell body of neurone situated in the nucleus colliculi inferioris sending an axone cerebralward by way of the brachium quadrigeminum inferius. 4, cell body of neurone situated in corpus geniculatum mediale sending axone toward the auditory sense area of the cerebral cortex. 5, 7, diencephalo-telencephalic auditory projection axones terminating in the auditory sense area of the cortex. The auditory sense area in the temporal lobe is indicated by the green stripe. *Lemn. lat.*, lemniscus lateralis.

*Orange*.—Neurones and axones of neurones of the olfactory conduction path. 1, peripheral olfactory neurone; 2,  $\mathcal{Z}$ , olfactory neurones of the second order; 3, olfactory neurone of the third order connecting (by its axone,  $\mathcal{Z}'$ ) the substantia perforata anterior with the nucleus habenule; 4, axones in the columna fornicis belonging to neurones which connect the hippocampus with the corpus mamillare; 5, axone of olfactory neurone connecting the frontal olfactory sense area with the nucleus lentiformis.

*Violet*.—Neurones of the cerebrocorticopontal paths and of the pontocerebellar paths. The area of the cerebral cortex, probably connected with the frontal cerebrocorticopontal path, is indicated by violet stripe. 1, axones of frontal cerebrocorticopontal path derived from pyramidal cells in the cortex of the lobus frontalis; 2, axone of temporal or temporo-occipital cerebrocorticopontal path. The exact cortical origin is unknown. 3, frontal cerebrocorticopontal path forming the medial bundle of white fibres in the basis pedunculi; 4, temporal or temporo-occipital cerebrocorticopontal path forming the lateral bundle of white fibres of the basis pedunculi; 5, cell body in nuclei pontis giving off an axone to terminate in the opposite cerebellar hemisphere; 6, cell body in nuclei pontis connected with temporal cerebrocorticopontal path giving off axone to the opposite cerebellar hemisphere; 7, 8, Purkinje cells in cerebellar cortex giving off axones to nuclei pontis, reaching these by way of the brachia pontis; 9, 10, cell bodies in nuclei pontis sending axones cerebralward.

**Fig. 2.**—Schematic representation of the portion of a spinal cord corresponding to the attachment of the ventral and dorsal roots of one pair of spinal nerves.

*Black*.—*C. c.*, canalis centralis; *C. d.*, commissura dorsalis; *C. d. g.*, cornu dorsalis grisea; *C. v. g.*, cornu ventralis grisea; *Cm. v. a.*, commissura ventralis alba; *Cm. v. g.*, commissura ventralis grisea; *F. c.*, funiculus cuneatus; *F. g.*, funiculus gracilis; *F. d.*, funiculus dorsalis; *F. l.*, funiculus lateralis; *F. m. v.*, fissura mediana ventralis; *F. v.*, funiculus ventralis; *G. sp.*, ganglion spirale; *R. d.*, radix dorsalis nervi spinalis; *R. v.*, radix ventralis nervi spinalis; *S. l. d.*, sulcus lateralis dorsalis; *S. l. v.*, sulcus lateralis ventralis; *S. m. d.*, sulcus medianus dorsalis; *S. i. d.*, sulcus intermedius dorsalis.


*Red*.—Peripheral sensory neurones. The cell bodies, 1, are situated in the spinal ganglia. The peripheral processes enter the peripheral nerves, the central axones pass by way of the radix dorsalis into the fasciculus cuneatus of each side. There each axone bifurcates into an ascending and descending limb, giving off also collaterals to the gray substance.

*Blue*.—Lower motor neurones. The cell bodies, 1, are situated in the ventral horns. They send their axones by way of the ventral roots into the peripheral nerves.

The neural mechanism generally believed to form the basis of the simplest reflex arc is illustrated in the figure. Another conception of the anatomical mechanism underlying simple reflexes has been illustrated in Fig. 162, p. 272.









84423

MA

B

Author Barker, Lewellys Franklin

Title The ne



UNIVERSITY OF TORONTO  
LIBRARY

Acme Library Card Pocket  
Under Pat. "Ref. Index File."  
Made by LIBRARY BUREAU, Boston

